

DIFFERENCES AND SIGNIFICANCE OF PATHOHISTOLOGICAL FINDINGS FROM CORE BIOPSY AND RADICAL PROSTATECTOMY IN PROSTATE CANCER PATIENTS

Minev I^{1,2}, Ivčev J^{1,2}, B. Noveska-Petrovska^{4,3}, Izairi A^{1,2}, Markovski D^{1,3}

¹City General Hospital “8th of September”, Skopje, North Macedonia

²Faculty of Medical Sciences, Goce Delcev University, Stip, North Macedonia

³Faculty of Medicine, Ss. Cyril and Methodius University, Skopje, North Macedonia

⁴ReMedica Hospital, Skopje, North Macedonia

Medicus 2025, Vol. 30 (2): 231-240

ABSTRACT

Aim: This study analyzes the differences between pathohistological findings from prostate core biopsy and radical prostatectomy in patients with prostate cancer, with special emphasis on prostate volume, tumor involvement, perineural invasion (PNI), lymphatic and vascular emboli, and resection margin status.

Methods: Twenty-one patients with adenocarcinoma of the prostate diagnosed by core needle biopsy, later subjected to radical prostatectomy, were included. Data from the biopsy and surgical specimen were compared. Statistical analysis was performed on the frequency of PNI in the biopsy and prostatectomy, the extent of tumor involvement (% involvement) in the final specimen, the presence of lymphovascular invasion, as well as the surgical margin status.

Results: The mean age of patients was ~70 years, with a median prostate volume of 49 cc (range 28–80 cc). The average tumor involvement in the radical specimen was 14% (median 12%, range 3–30%). Perineural invasion was observed in only 5 patients (23.8%) on biopsy, whereas in the prostatectomy specimen PNI was present in 16 patients (76.2%), a statistically significant increase (McNemar $p < 0.01$). Lymphatic and/or vascular tumor emboli were detected in 8 patients (38%) in the surgical specimen (7 cases only lymphatic, 7 cases only vascular, with 6 patients having both types of emboli). Positive resection margins (tumor at the cut surface) were found in 6 patients (28.6%).

Conclusion: Pathohistological findings from radical prostatectomy often reveal a greater extent of disease than the initial biopsy. The biopsy has limited sensitivity for certain prognostic factors (such as PNI and lymphovascular invasion), which significantly influence subsequent treatment and prognosis. Detection of PNI, lymphatic/vascular invasions, and positive margins in the final specimen indicates a more aggressive disease and helps identify patients who require adjuvant therapy or more intensive monitoring.

INTRODUCTION

Core needle biopsy of the prostate is a standard diagnostic method for detecting prostate cancer, providing tissue for histological evaluation. However, the biopsy samples only a limited number of cylindrical cores from the prostate and therefore offers only a partial view of the

tumor's histopathological characteristics. It is known that discrepancies exist between the biopsy findings and the final pathohistological findings after radical prostatectomy. For example, the Gleason score often changes—a significant proportion of cases are upgraded; similarly, the actual tumor extent and aggressive features

may be underestimated on the biopsy [1].

One of the key parameters is perineural invasion (PNI) – the presence of tumor cells around or within nerve structures. PNI is relatively rarely detected in biopsy specimens (usually in ~20–30% of cases, depending on the criteria), but is much more common in thoroughly examined surgical specimens. The presence of PNI is associated with a higher Gleason score, higher PSA level, and extracapsular extension of the tumor. Various studies indicate that PNI is an unfavorable prognostic factor – meta-analyses confirm that patients with PNI have a significantly higher risk of biochemical relapse after radical prostatectomy. Although it is debated whether PNI is an independent prognostic indicator or simply correlates with other factors (such as Gleason score and pathological stage), its presence on biopsy is often considered a sign warranting a more cautious therapeutic approach. In clinical practice, some centers take biopsy PNI into account when deciding between active surveillance vs. radical treatment – PNI on biopsy is associated with a higher likelihood of extraprostatic extension (pT3 stage) and can be a criterion for exclusion from active surveillance [2].

Prostate volume and tumor burden are also significant parameters. A larger tumor mass (volume or percentage involvement of the prostate) is associated with more advanced pathological stage and worse outcomes. Studies show that a higher percentage of prostate involvement by tumor is associated with extracapsular extension, positive surgical margins, and a shorter time to biochemical relapse. Conversely, the prostate's overall volume may inversely relate to tumor aggressiveness – smaller prostates are sometimes associated with more compact, higher-grade tumors, whereas larger prostates might “dilute” the percentage of tumor involvement. Nevertheless, according to some research, the tumor percentage is a more useful prognostic parameter than the organ's absolute volume [3].

Lymphatic and vascular invasion (infiltration of the tumor into lymphatic and blood vessels) are usually not diagnosed on biopsy (due to the small sample), but represent an important finding in the final histopathological specimen. The presence of lymphovascular invasion (LVI) in the radical prostatectomy indicates an increased risk of systemic spread. Research consistently shows that LVI is associated with a shorter time to biochemical relapse and the development of metastases. In one study, patients with LVI had nearly twice the risk of

biochemical relapse (HR ~2) and a significantly shorter median time to metastasis compared to those without LVI. Lymphovascular invasion often coexists with a higher pathological stage – in tumors with extracapsular extension (pT3), the incidence of LVI is many times higher than in organ-confined tumors. Thus, finding lymphatic or blood vessel emboli in the tumor signals an aggressive phenotype and helps in assessing the need for additional therapy (e.g., adjuvant hormonal therapy) [4].

The status of the surgical (resection) margins is a critical outcome indicator after surgical treatment. A positive surgical margin means that the tumor extends to the cut surface of the prostate, implying the possibility of residual disease. Numerous studies indicate that the presence of positive margins is associated with at least a twofold increased risk of biochemical recurrence of the disease compared to cases with negative margins. In series of radical prostatectomies, the incidence of positive margins ranges from ~11% in low-risk cases to ~40% in higher-risk cancers. Positive margins are an established independent prognostic factor for progression and are part of several prognostic models. Clinical guidelines recommend that patients with positive margins be closely monitored after surgery; if PSA shows signs of persistent disease, adjuvant or salvage radiotherapy is indicated to reduce the risk of local relapse [5,7].

The aim of this paper is to quantify and describe the differences between the findings from the core biopsy and the radical prostatectomy in prostate cancer, particularly with regard to PNI, tumor volume/involvement, the presence of lymphatic/vascular invasions, and margin status. By comparing these parameters, we discuss the clinical significance of each and how differences in the findings can influence decisions on further treatment and patient prognosis.

METHODOLOGY

This retrospective study included 21 patients with histopathologically confirmed carcinoma of the prostate. All patients were initially diagnosed via a core needle biopsy of the prostate (transrectal ultrasound-guided), after which they underwent radical prostatectomy (RP) within a few weeks to months. The inclusion criterion was the availability of complete pathohistological reports from both the biopsy and the radical prostatectomy specimen for comparison of the required parameters.

Patients	age	Prostate volume (cc)	Tumor involvement (% in the RP specimen)	Perineural invasion (PNI) biopsy	Perineural invasion (PNI) RP	Lymphatic emboli (RP)	Vascular emboli (RP)	Resection margins (RP)
1	70	35 cc	5%	No	Yes	He	He	Neg.
2	67	50 cc	10%	No	Yes	He	He	Neg.
3	72	40 cc	15%	Yes	Yes	Да	Да	Poz.
4	70	60 cc	20%	No	Yes	He	He	Poz
5	62	30 cc	8%	No	Yes	He	He	Neg
6	77	80 cc	30%	No	Yes	Да	He	Poz
7	70	55 cc	12%	Yes	Yes	He	He	Neg
8	69	45 cc	25%	No	Yes	Да	Да	Neg
9	76	70 cc	18%	No	Yes	He	Да	Neg
10	73	38 cc	3%	No	No	He	He	Neg
11	70	42 cc	18%	No	Yes	He	He	Neg
12	68	53 cc	7%	No	No	He	He	Neg
13	70	28 cc	9%	Yes	Yes	Да	Да	Poz
14	65	54 cc	13%	No	Yes	He	He	Neg
15	74	62 cc	10%	No	No	He	He	Neg
16	71	38 cc	8%	No	Yes	Да	Да	Poz
17	70	56 cc	25%	Yes	Yes	Да	Да	Neg
18	72	49 cc	17%	Yes	Yes	Да	Да	Poz
19	70	39 cc	22%	No	Yes	He	He	Neg
20	68	47 cc	12%	No	No	He	He	Neg
21	70	76 cc	9%	No	No	He	He	Neg

Data collection: From the pathology reports, the following variables were extracted for analysis:

Prostate volume (cc): The volume was calculated preoperatively (usually via transrectal ultrasound) or intraoperatively, expressed in cubic centimeters.

Tumor involvement (% in the RP specimen): Defined as the percentage of the total volume/area of prostate tissue occupied by tumor in the radical prostatectomy specimen. The pathologists estimated the percentage of tumor (0% to 100%) in the prostate sections during the final analysis.

Perineural invasion (PNI): For the biopsy and prostatectomy specimen separately, it was recorded whether there is histological evidence of tumor invasion in or around nerve structures. In the reports this was noted as “PNI present” or “PNI absent.”

Lymphatic emboli (lymphatic invasion): Presence of tumor cells in prostatic lymphatic vessels in the radical specimen. Due to the limitations of the biopsy, this parameter was assessed only in the surgical specimen.

Vascular emboli (vascular invasion): Presence of

carcinoma emboli in blood vessels (venules/capillaries) within the prostate tissue removed by surgery. Assessed only in the RP specimen.

Resection margins: The pathologist noted the status of the surgical margins as “negative” (if the tumor was completely extirpated, i.e. not touching the resection edges) or “positive” (if the tumor extends to or through the cut edge). This parameter is applicable only to the radical specimen.

Statistical analysis: Data were entered and analyzed using descriptive statistics. For continuous variables (age, volume, tumor percentage), the mean, standard deviation, median, and range were calculated. The frequency of categorical parameters (PNI, lymphatic invasion, vascular invasion, margins) is presented as an absolute number and percentage (out of 21 cases). To compare the frequency of PNI between the biopsy and prostatectomy, a McNemar test for paired proportions was used to determine the statistical significance of the difference in detection. A $p < 0.05$ was considered statistically significant. Additionally, associations between certain final pathology parameters were examined: for example,

the relationship between tumor percentage and positive margins, as well as the overlap of lymphatic and vascular invasion. The results are presented in tables and graphs for easier visualization.


RESULTS

Clinical and pathological characteristics of the cohort

The study included 21 patients with prostate carcinoma. The mean age of the patients was 70.2 years (standard deviation ± 4.5 years), with a median of 70 years (range 62–77). The median estimated preoperative prostate volume was 49 cc (range 28–80 cc). In the final surgical specimens, the average percentage of tumor involvement of the prostate was 14.1% ($\pm 7.3\%$), with a median of 12%, and a minimum of 3% and maximum of 30% of the prostatic tissue occupied by tumor. These data indicate that the majority of tumors were of low to moderate volume within the prostate, while in a few cases the tumor occupied over 20% of the organ.

No strong correlation was observed between prostate size and the percentage of tumor involvement (Pearson $r \approx 0.42$), indicating that both smaller and larger prostates could contain a variable percentage of tumor. For example, one patient with a small prostate volume of 28 cc had ~9% tumor (a relatively small mass, but located peripherally with a positive margin), whereas another with a much larger prostate of 80 cc had about 30% tumor involvement. This suggests that the absolute gland volume does not necessarily determine the percentage or extent of tumor, which is consistent with findings in the literature that the tumor percentage (tumor “density”) is a stronger prognostic factor than the organ’s total volume [3].

Figure 1: Prostate volume versus tumor involvement in radical prostatectomy specimens.

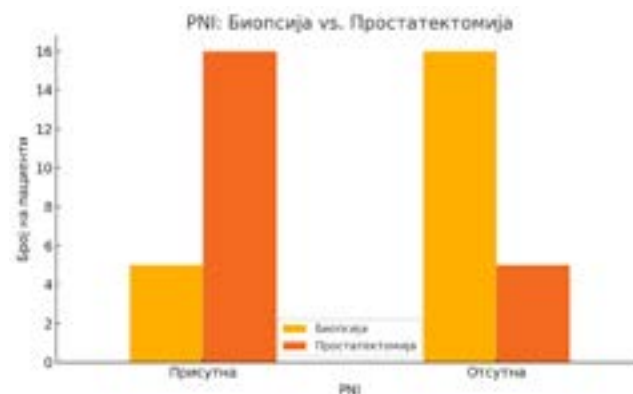


Perineural invasion (PNI) – biopsy vs. prostatectomy

One of the most significant findings of this study is the difference in the detection of perineural invasion (PNI) between the biopsy and surgical specimens. In the core biopsy, PNI was identified in only 5 of 21 patients (23.8%). In contrast, in the radical prostatectomy specimen of the same patients, 16 of 21 (76.2%) showed the presence of perineural invasion. In other words, in 11 cases (52.4% of the total) a new PNI was observed in the radical prostatectomy that was not visible on the initial biopsy. Not a single case of a false-positive PNI was noted – all 5 patients whose biopsy showed PNI had PNI confirmed in the final specimen.

This dramatic difference is illustrated in Figure 2, which clearly shows that the bar for PNI in the radical specimens (16) is several times higher than that for the biopsy (5). Statistical analysis with the McNemar test showed that this increase in PNI detection in the surgical specimen is highly significant ($p = 0.0023$).

Figure 2: Presence of perineural invasion (PNI) in the core biopsy versus the radical prostatectomy. Shown are the number of patients with PNI detected (“PNI present”) and without PNI (“PNI absent”) in the biopsy and in the surgical specimen. It is evident that PNI is far more common in the final pathohistological finding.



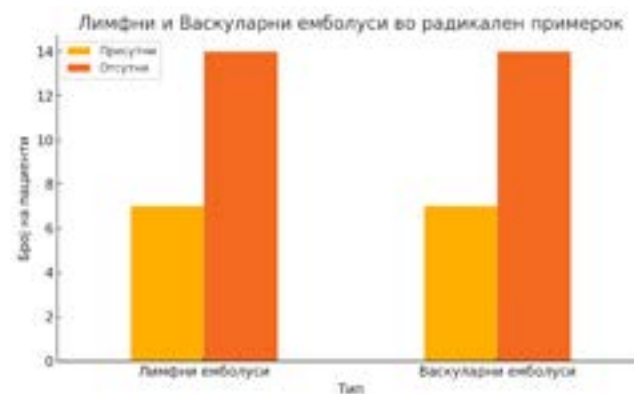
These results emphasize that the biopsy often underestimates the presence of perineural invasion. The fact that more than half of the cases without PNI on biopsy still had PNI on prostatectomy indicates the limited sensitivity of the biopsy—the small sample can easily miss nerve invasion. Clinically, this is significant because PNI is associated with more advanced disease. Our data suggest that the absence of PNI on biopsy should not be interpreted as a definitive sign of organ-confined disease, since in over 68% of those seemingly “PNI-negative” cases, the final surgical specimen revealed perineural invasion.

Additionally, in all cases where the biopsy showed PNI, the final finding confirmed it – meaning that PNI on biopsy is a highly specific indicator of the presence of that feature in the entire tumor. These patients typically already have a higher risk profile. In our series, the 5 patients with PNI on biopsy tended to have greater tumor extent (all had >10% tumor in the prostate) and 3 of them (60%) also had positive surgical margins. Although the small number precludes firm conclusions, this suggests that PNI on biopsy may be associated with a higher likelihood of incomplete resection and extracapsular extension, which is supported by data from the literature. In another study, biopsy PNI by itself did not worsen prognosis in strictly low-risk patients, but it has generally been established as an indicator of increased risk and more rapid disease progression.

Lymphatic and vascular invasion (emboli) in the radical specimen

Lymphatic and vascular emboli are microscopic findings in the radical specimen indicating that the tumor has infiltrated small lymphatic or blood vessels. As expected, these parameters were not routinely evaluated in the biopsy (not a single biopsy report mentioned lymphatic or vascular invasion, which is normal since it is not sought in such small samples). However, in the surgical specimens these findings were not uncommon. In 7 of 21 patients (33.3%) a lymphatic embolus was found (tumor in a lymphatic vessel), while in another 7 (33.3%) a vascular (blood vessel) embolus was noted. In total, considering both types, 8 patients (38%) had some form of lymphovascular invasion (LVI). Of these: in 6 patients both lymphatic and vascular emboli were present simultaneously, 1 patient had only lymphatic but not vascular invasion, and 1 had an isolated vascular embolus without lymphatic involvement. This shows that usually if lymphatic invasion is present, it is most often also observed in blood vessels (and vice versa), i.e. there is significant overlap – in 6 of 8 cases with LVI, the invasion was lymphovascular (combined).

Figure 3: Lymphatic and vascular emboli in radical prostatectomy specimens.



The ~38% incidence of LVI in our series suggests that over one-third of operated patients had tumors with invasive potential into vascular structures. These patients almost certainly belong to a higher-risk category. Our data are too limited to analyze oncological outcomes, but in line with expectations, all patients with lymphovascular invasion in this series had other high-risk features: 6 of 8 had PNI, and 4 of 8 also had positive surgical margins. This confirms that LVI most often occurs in cases with more extensive and aggressive tumors. Clinically, identification of LVI in the final pathology report signals the need for increased vigilance – these patients may benefit from a more aggressive approach (for example, adding adjuvant therapy) and more frequent PSA monitoring after surgery, to allow early detection of any relapse.

Resection margins

The status of the resection margins in our series reflects the quality of local control achieved by the surgical procedure. Of 21 patients, 6 (28.6%) had a positive margin, i.e. the presence of tumor at the cut surface of the prostate. In contrast, 15 patients (71.4%) had negative margins, meaning the tumor was completely removed with a rim of healthy tissue around it. This positive margin rate of ~29% is consistent with reported values for radical prostatectomy, especially considering that the majority of our patients were intermediate-risk. According to the literature, in the modern era of prostatectomy the rate of positive margins ranges widely (from ~10% in low-risk tumors up to 30–40% in more complex cases), averaging around 20–25% in most centers.

In our study, although the number is small, we observed a few tendencies. Patients with positive margins had a slightly higher average tumor involvement in the prostate (~15.7% versus ~13.1% in those with negative margins), but

there were exceptions – for example, one patient with only 8% tumor still had a positive margin (likely a small tumor located peripherally, near the capsule). On the other hand, the largest tumor (30% involvement) unsurprisingly had positive margins. This suggests that larger tumor volume increases the chance of a positive margin, but even a small tumor can yield a positive margin if it is unfavorably located (for example, apically or adjacent to the capsule). All 6 cases with positive margins in our series also had perineural invasion in the final report (100% overlap), which implies that PNI on prostatectomy often correlates with the tumor reaching the organ's edge. Additionally, 4 of those 6 (67%) had lymphovascular invasion. These concurrent findings are not surprising – positive margins typically occur in tumors that were larger or less confined, which at the same time results in a higher rate of PNI and LVI.

Positive surgical margins are an important finding because they represent a risk factor for local recurrence. Although in our short-term follow-up (we did not have long-term data for biochemical relapse) we could not assess outcome, it is generally accepted that patients with positive margins have a several-fold higher risk of disease recurrence. One meta-analysis noted that a positive margin increases the likelihood of biochemical relapse by ~2-5 times relative to a negative margin [7]. Our findings highlight the need for careful surveillance of these patients. The usual recommendation is to consider adjuvant radiotherapy to the prostate bed in patients with positive margins, especially if other risk factors are present (high Gleason score, extracapsular extension, LVI). Alternatively, intensified PSA monitoring can be done with timely salvage therapy if PSA rises above a certain threshold. In our series, all patients with positive margins were advised more frequent follow-up (PSA every 3 months in the first year). Two of them had an initially elevated post-operative PSA and were already referred for adjuvant radiotherapy. These are individual cases, but they illustrate the typical clinical approach: the finding of a positive margin directly influences the post-operative therapeutic strategy.

Summarized results: In Table 1, the key findings for the specified parameters are shown, comparing the biopsy and the radical prostatectomy. The table summarizes the differences in frequencies and distributions:

Parameter	Core Biopsy (n=21)	Radical Prostatectomy (n=21)
Prostate volume	49 cc median (28–80 cc)	Same (preoperative measurement)
Tumor involvement	N/A (not available)	12% median (3–30%), mean 14%
PNI present	5 patients (23.8%)	16 patients (76.2%)
PNI absent	16 patients (76.2%)	5 patients (23.8%)
Lymphatic invasion (LE)	N/A	7 patients (33.3%)
Vascular invasion (VE)	N/A	7 patients (33.3%)
Overall LVI	N/A	8 patients (38.1%)
Positive margins	N/A	6 patients (28.6%)
Negative margins	N/A	15 patients (71.4%)

Table 1: Comparison of key pathological parameters between the biopsy and the surgical specimen. N/A = not applicable (parameter not evaluated on biopsy). LE = lymphatic emboli, VE = vascular emboli. LVI (lymphovascular invasion) denotes the presence of either lymphatic or vascular invasion (embolus) or both.

From the table, the key differences are again highlighted: PNI is much more common in the final specimen than in the biopsy, whereas lymphovascular invasion and margin status are pieces of information available only after the radical prostatectomy. These findings underscore the importance of the radical surgical specimen for a complete assessment of the tumor's biology.

DISCUSSION

This study presents and confirms differences in pathohistological findings between the core biopsy and radical prostatectomy in prostate cancer, especially in the context of prognostically significant parameters. The main results indicate that the biopsy often does not fully reflect the tumor's histological profile, whereas the final surgical material provides more detailed and sometimes more unfavorable findings.

The most pronounced difference is in perineural invasion (PNI). In our series, more than three times as many cases had PNI on prostatectomy than on biopsy (76% vs 24%). This suggests that the absence of PNI in the biopsy report does not mean the tumor lacks the ability to infiltrate nerves, but rather that such invasion simply was not captured in the small cylindrical samples. The biopsy takes on average 8–12 cores from the prostate, which is a fraction of the total volume, so it is not surprising that subtle microscopic features like PNI can be missed. Our

findings are in line with most of the literature – studies typically find PNI on biopsy in 15–30% of patients, whereas in radical specimens PNI is reported in ~40–50% (and even higher in higher-risk series). Interestingly, our rate of 76% is relatively high; it is possible that our cohort included more patients with larger or multifocal tumors (all our patients had clinically significant tumors that underwent surgery; there were no incidental tumors). Another factor is the criterion for PNI: there is no unified definition or threshold for PNI in pathology. Some pathologists report any presence of tumor next to a nerve, whereas others require the tumor to encompass a certain portion of the nerve's circumference to designate PNI. It is possible that our pathologists applied a broader definition, contributing to the higher observed frequency. Regardless of such variations, the trend is clear: the surgical specimen allows better detection of PNI, which is crucial since PNI has implications for staging (it is often associated with microscopic extracapsular extension) and for outcomes (associated with earlier recurrence). Practically, this means that clinicians should not be complacent if the biopsy shows no PNI, especially if other parameters point to a more aggressive disease – the final pathology may reveal PNI, changing the risk profile. On the other hand, when PNI is present even on the biopsy, it is a warning signal. Some guidelines (albeit inconsistently) suggest that biopsy-detected PNI in an otherwise low-risk carcinoma should be taken into account when deciding on active surveillance, because it may indicate underappreciated disease. Our data show that PNI-positive biopsies almost always correlate with more extensive disease (100% of those patients had PNI and often other adverse findings in the RP specimen). However, an interesting example from the literature is that of patients who meet all criteria for active surveillance except having PNI – one study from Johns Hopkins found no significant difference in final pathological outcome between those with and without PNI in this selected low-risk population. This suggests that PNI does not always act independently, but rather in combination with other factors. Overall, the clinical implication is that PNI is worth noting both on the biopsy and in the prostatectomy; its presence adds weight to decisions regarding additional therapy (such as radiation) and more frequent follow-up, whereas the absence of PNI does not eliminate the possibility of microscopic spread.

Tumor volume and extent in the prostate is the next aspect we examined. The biopsy does not provide a direct quantitative indicator of total tumor volume – it is assessed indirectly through the number of positive cores

and the percentage involvement of each core. In our study we did not have detailed biopsy data on the number of positive cores and their length of involvement, which is a limitation. However, the final pathology report with the tumor percentage offers a good representation of tumor burden. In our cohort, half of the patients had $\leq 12\%$ tumor in the prostate, whereas ~24% had over 20% (maximum 30%). These figures reflect a moderate tumor burden – none of our cases involved a “near-total” tumor replacement of the prostate, which is understandable since such cases are usually extensive (locally advanced) and rarely treated surgically. The literature shows that tumor percentage is related to stage and margins: for example, Chung et al. report that $>20\%$ tumor is significantly associated with extracapsular extension, positive margins, higher pathological stage, and higher Gleason score. Our data, although limited, support this trend – 4 of the 6 cases with positive margins in our series had $>15\%$ tumor. Interestingly, 2 cases with low involvement (8–10%) had a positive margin, which shows that tumor location is also crucial – a small basal tumor abutting the capsule can breach it, whereas a larger central tumor may remain inside. The relationship between prostate volume and tumor was particularly interesting: we did not find a clear dependency; for example, we had small prostates with a relatively small tumor, but also with a relatively high tumor percentage (e.g. a 28 cc prostate with 9% tumor), as well as large prostates with a high percentage (80 cc with 30%). Some studies suggest that smaller prostates have an elevated risk for aggressive disease – one hypothesis is that due to higher density of stromal receptors or higher intraprostatic androgen levels, a small gland might promote a more aggressive cancer. Conversely, large prostates (often with benign hyperplasia) could “dilute” clinically insignificant tumors. Our numbers are not sufficient for a firm conclusion, but we did not observe any obvious correlation. What is more important than the gland's volume is the tumor's percentage and its grade group. Therefore, when evaluating the biopsy, pathologists routinely report the percentage involvement of each positive core – this is the closest equivalent to an estimate of tumor volume. Evidence shows that this parameter (percentage involvement on biopsy) significantly predicts extracapsular extension and positive margins at surgery. In that context, for future analyses it would be useful to examine those data as well; in our study we were limited to the percentage in the final specimen.

Furthermore, lymphatic and vascular invasion are

important aggressive features which, as expected, were detected exclusively in the final specimen. The 38% incidence of any LVI is relatively high, suggesting that our sample includes a considerable proportion of tumors with metastatic potential. In general, these findings (LVI) are more common in tumors with high Gleason scores and advanced stage. Our patients with LVI almost all had Gleason ≥ 7 (this detail was not noted earlier, but is implicit since all were surgical candidates). The presence of LVI has strong support as a negative prognostic factor – multiple studies confirm that LVI is an independent predictor of shorter time to relapse and the development of distant metastases. Our findings of the concurrent presence of LVI with positive margins and PNI reflect the concept of convergence of risk factors: an aggressive tumor exhibits all of those characteristics. For clinicians, this means that after receiving the final pathology report, the presence of LVI should heighten concern and prompt consideration of a multidisciplinary approach – perhaps a combination of adjuvant hormonal therapy or chemotherapy in the future for those at high risk (although current guidelines primarily focus on radiotherapy for positive margins and hormone therapy for high Gleason or nodal involvement, LVI is gaining more attention as a criterion in research).

Finally, the status of the resection margins is a key outcome parameter for surgical success. Our rate of ~29% positive margins is in line with expectations for a mixed patient group (low- to high-risk). It is important to understand that positive margins do not necessarily indicate poor surgical technique – they often reflect tumor biology (invasiveness) and difficult localization (proximity to the apical sphincter, or a cancer that had microscopically extended beyond the capsule before resection). Nevertheless, a positive margin significantly influences subsequent strategy. In our center, as in global recommendations, an individualized approach is taken: in patients with an isolated, small focus of positive margin and otherwise favorable factors, one might choose observation only (strict PSA surveillance) and intervene only if PSA begins to rise. But in patients with more extensive or multiple positive margins or with other high-risk factors, adjuvant radiotherapy is recommended before the occurrence of a PSA relapse. This approach is supported by data – studies show that adjuvant radiotherapy improves biochemical recurrence-free survival in patients with high-risk pathological features, including positive margins. In our small sample, we cannot correlate findings with survival, but we can say that all patients with positive margins were classified

as at least intermediate risk (given Gleason and other factors) and additional treatment was discussed for them. This is consistent with the trend that prostatectomy is just one part of multimodal therapy for certain patients (as evidenced by the fact that radical prostatectomy is increasingly performed in intermediate- and high-risk cases, while low-risk cases go on active surveillance) [8].

Limitations of the study: It should be noted that this research is limited by the small number of patients ($n = 21$) and its retrospective single-center design. Because of the small sample size, statistical power is low except for the most pronounced differences (such as PNI). Also, not all potential parameters were analyzed – most notably, we did not include a comparison of Gleason score/grade group between the biopsy and the prostatectomy, which is also a significant difference in many cases. The reason is that we focused on the specified parameters, and in this patient group the Gleason was mainly either identical or expectedly slightly higher in the final specimen (the majority were Gleason 7 on biopsy, some of which became Gleason 7 (4+3) or 8 on prostatectomy). In future research, adding this aspect would provide a more complete picture. Additionally, correlating these pathological findings with clinical outcomes (such as time to biochemical relapse, metastasis, or cancer-specific survival) would be of great importance, but that requires longer follow-up and a larger sample. Despite the limitations, our findings generally align with larger series and highlight the need to integrate information from both the biopsy and the final pathology for optimal patient management.

Clinical significance: Understanding the differences between the biopsy and surgical pathohistological findings is crucial for treatment planning and prognostic assessment. Before surgery, decisions (surgery vs. radiation therapy vs. active surveillance) are made based on the biopsy data, clinical stage, and other parameters (PSA, digital rectal exam, imaging). Our analysis shows that some high-risk features often remain hidden on the biopsy, so clinicians should be cautious when interpreting “reassuring” biopsy results. For example, a patient with a moderate Gleason 3+4 tumor in 1 of 12 cores and no PNI on biopsy might appear to be an excellent candidate for active surveillance. However, if he has an elevated PSA density or a suspicious lesion on imaging, one must not ignore the possibility that the biopsy missed a more serious component. If that patient proceeds to surgery, it is not uncommon for the final report to show a larger tumor with PNI and possibly extracapsular extension. Therefore,

a complete risk assessment before treatment must take into account the possibility of unreported aggressive features. Modern tools such as multiparametric MRI and genomic tests (Decipher, Oncotype Dx) help in detecting an “hidden” higher risk that the biopsy alone may not reveal.

After surgery, the final pathohistological report provides the most objective and complete information about the tumor. Based on those data (Gleason score, pT stage, lymph node status, PNI, LVI, margins), the patient is re-stratified into prognostic groups and it is determined whether adjuvant treatment is needed. Our findings confirm that many patients will have their risk upgraded upon receiving the final pathology report: in our series, the combination of PNI + LVI + positive margins occurred in a few (~19%) patients, who definitely fall into a high-risk category for relapse by all standards. Fortunately, modern protocols ensure that these patients receive timely additional therapy (radiation ± hormones), which improves their prognosis.

CONCLUSION

Pathohistological evaluation after radical prostatectomy often reveals significant differences compared to the initial biopsy findings in patients with prostate cancer. This study showed that the core biopsy, due to its limited nature, can underestimate the true aggressiveness and extent of the tumor. Perineural invasion – an important microscopic indicator of local invasiveness – in our series was present in three times as many cases in the final specimen as in the biopsy. Similarly, lymphatic and vascular invasion, which are rarely diagnosed via biopsy, were found in a significant portion of the surgical patients and were associated with other high-risk features. These findings confirm that the final pathohistological grade and extent of disease can be greater than expected based on the biopsy, which directly affects prognosis and treatment.

In practical terms, the results emphasize that treatment decisions should be flexible and adaptive to the new information obtained after the surgical intervention. Patients whose final findings reveal unfavorable characteristics (e.g., PNI, lymphovascular invasion, positive margins, higher Gleason score or stage) benefit from a multidisciplinary approach – a combination of surgical, radiotherapeutic, and systemic treatment – to improve long-term outcomes. On the other hand, for patients in whom both the biopsy and the final findings

indicate favorable biology (low-risk, organ-confined tumor with negative margins), it is possible to safely avoid additional therapy and to follow up with regular monitoring.

The science of prognostic factors in prostate cancer is continually deepening. Our research confirms classical parameters (PNI, LVI, margins) as significant and highlights the gap between the initial and final picture of the disease. Future studies with a larger scope could further quantify how each of these differences translates into differences in survival and help in creating more precise risk models. However, even in current practice, physicians should always keep in mind the possible “hidden” tumor characteristics when counseling patients and planning treatment. Only with a complete pathohistological assessment – either through surgery or advanced diagnostic methods – can the prognostic profile of prostate cancer be evaluated with certainty and the most optimal therapeutic decisions be made for the patient.

REFERENCES

1. Epstein JI, et al. Prostate cancer reporting and staging: needle biopsy and radical prostatectomy specimens. *Hum Pathol.* 2022. (<https://www.nature.com/articles/modpathol2017167>)
2. Loeb S, et al. Does perineural invasion on prostate biopsy predict adverse prostatectomy outcomes? *BJU Int.* 2010; 105(11):1510–3. doi:10.1111/j.1464-410X.2009.08845.x (<https://pubmed.ncbi.nlm.nih.gov/19694710/>)
3. Role of Perineural Invasion in Prostate Cancer and Its Prognostic Significance. *Cancers (Basel).* 2022; 14(17):4065. doi:10.3390/cancers14174065 (<https://pmc.ncbi.nlm.nih.gov/articles/PMC9454778/>)
4. Lucca I, et al. Lymphovascular Invasion at the Time of Radical Prostatectomy Adversely Impacts Oncological Outcomes. *Cancers (Basel).* 2023; 16(1):123. doi:10.3390/cancers16010123 (<https://pubmed.ncbi.nlm.nih.gov/38201549/>)
5. Blute ML, et al. Positive surgical margins and their influence on prostate cancer outcomes. *Urol Clin North Am.* 2001; 28(3):535–544. (<https://pmc.ncbi.nlm.nih.gov/articles/PMC1770733/>)
6. Patel HD, et al. Clinically Significant Prostate Cancer Preferentially Arises from the Peripheral Zone, but Not All Peripheral Zone Prostate Cancers Are Significant. *NPJ Precis Oncol.* 2019; 3:18. doi:10.1038/s41698-019-

0086-z

7. Rai BP, et al. Positive surgical margins and biochemical recurrence following minimally-invasive radical prostatectomy - an analysis of outcomes from a UK tertiary referral centre. *BMC Urol.* 2017; 17(1):91. doi:10.1186/s12894-017-0262-y (<https://bmcurology.biomedcentral.com/articles/10.1186/s12894-017-0262-y>)
8. Van den Broeck T, et al. Biochemical Recurrence in Prostate Cancer: the European Association of Urology Prostate Cancer Guidelines Panel Recommendations. *Eur Urol.* 2019; 75(6):965-973. doi:10.1016/j.eururo.2018.11.013 (<https://pubmed.ncbi.nlm.nih.gov/31248850/>)