

**International Journal of Recent Research in Arts and  
Sciences ISSN: 1857-8128**



**MIT  
UNIVERZITET  
SKOPJE**



**JOURNAL**

**International Journal  
of Recent Research in  
Arts and Sciences  
Volume 20**

**Skopje, Republic of North Macedonia**

**March, 2025**



MIT UNIVERSITY  
SKOPJE

**International Journal of Recent Research in Arts and Sciences**

**ISSN: 1857-8128**

**Owner and General Manager**

**MSc Biljana Apostolova**

**Marketing Manager**

**MSc Bozjidar**

**Mladenov**

**Editor in Chief**

**PhD Marjan**

**Madjovski, MIT**

**University**

**Lecture in English**

**Anita Dimitrijovska-**

**Jankulovska**

**EDITORIAL BOARD**

**Zvonimir Jankuloski**, PhD, MIT University Skopje, Macedonia

**Antonio Georgiev**, MD, MSc, PhD, Faculty of Medicine, University “Ss. Cyril and Methodius” - Skopje, Republic of North Macedonia

**Berta Gonzalvo**, PhD Mechanical Engineering Macedonia

**Branislav Mitrovic**, PhD, University of Belgrade, Belgrade

**Rusana Manceva**, PhD, Southwest University - Neofit Rilski, Blagoevgrad, Bulgaria

**Sinisha Zaric**, PhD, Economic faculty, Belgrade

**Daniela Georgieva**, MD, MSc, PhD, University Clinic for Orthopedic Surgery; Clinical Center “Mother Teresa”- Skopje; “Ss. Cyril and Methodius University” Skopje, Macedonia



MIT UNIVERSITY  
SKOPJE

**International Journal of Recent Research in Arts and Sciences**

**ISSN: 1857-8128**

**Dariusz Majchrzak**, PhD, National Defense University, Warsaw, Poland

**Ejup Chota**, PhD, University of Tirana, Plan Protection Department, Albania

**Elizabeta Popova Ramova**, PhD, MIT University, College of Wellness, Spa and Physiotherapy, Skopje, Macedonia

**Gabriela Dragan**, PhD, Romanian American University, Bucharest, Romania

**Georgi Georgiev**, PhD, New Bulgarian University, Sofia, Bulgaria

**Herba Safeyedin**, PhD, House of Egyptian Architecture, Cairo, Egypt

**Igor Maric**, PhD, Institute of Architecture and Urban&Spatial Planning of Serbia, Belgrade

**Ilija Nasov**, PhD, MIT University Skopje, Macedonia

**Karol Janas**, PhD, Alexander Dubcek University of Trencin, Slovakia

**Kresimir Rotim**, PhD, University of Zagreb, Faculty of Medicine, Zagreb, Croatia

**Lidija Geto**, PhD, University Josip Juraj Strossmayer, Osijek, Croatia

**Magdalena Punceva**, PhD, MIT University, Faculty of Security Sciences, Skopje, Macedonia

**Maja Jakovcevski**, PhD, University of Kraguevac, Faculty of Medicine, Kraguevac, Serbia

**Magdalena Cara**, PhD, University of Tirana, Plan Protection Department, Albania

**Mila Pucar**, PhD, Institute of Architecture and Urban&Spatial Planning of Serbia, Belgrade

**Milica Denkovska**, MA, MIT University Skopje, Macedonia

**Mirjana Devetakovic**, PhD, University of Belgrade, Faculty of Architecture, Belgrade

**Mirjana Jovanovska Stojanovska**, MIT University, Faculty of Psychology, Skopje, Macedonia

**Nenad Mikulic**, PhD, Polytechnic of Zagreb, Zagreb, Croatia

**Niko Herakovic**, PhD, University of Ljubljana, Faculty of Mechanical Engineering, Slovenia

**Patrizia Cinelli**, PhD in Chemistry at Pisa University, Italy



MIT UNIVERSITY  
SKOPJE

**International Journal of Recent Research in Arts and Sciences**

**ISSN: 1857-8128**

**Recep Guloglu**, PhD, Istanbul University, Istanbul, Turkey

**Safak Sahir Karamehmetoglu**, PhD, Istanbul University, Istanbul, Turkey

**Susana Paixão**, PhD, Polytechnic of Coimbra/Coimbra Health School, Portugal

**Svetlana Dushanich Gachic**, PhD, Banja Luka College, Bosnia and Herzegovina

**Stipica Popovski**, PhD, MIT University, Faculty of Dental Medicine, Skopje, Macedonia

**Teuta Gjuladin-Hellon**, PhD, Faculty for Food Industry, England

**Vladan Djokic**, PhD, University of Belgrade, Faculty of Architecture, Belgrade



MIT UNIVERSITY  
SKOPJE

International Journal of Recent Research in Arts and Sciences

ISSN: 1857-8128

## CONTENTS

### Natural and Technical-technological Sciences

<b>LIPID MARKER APOLIPOPROTEIN A1 AS A PREDIKTOR FOR CORONARY ARTERY DISEASE IN PATIENTS WITH TYPE 2 DIABETES MELLITUS WITH AND WITHOUT DIABETIC NEPHROPATHY.....</b>	<b>9</b>
<b>CORRECTIVE OSTEOTOMY OF THE FIBULA IN POORLY HEALED BIMALLEOLAR FRACTURE.....</b>	<b>29</b>
<b>EPIDERMOID INCLUSION CYST – CASE REPORT.....</b>	<b>36</b>
<b>EVALUATION OF TOTAL BLOOD LOSS AFTER ADMINISTRATION OF TRANEXAIC ACID IN TOTAL HIP ARTHROPLASTY.....</b>	<b>44</b>
<b>USE OF FREE GINGIVAL GRAFT TO RESOLVE GINGIVAL RECESSION OF LOWER INCISORS - CASE REPORT.....</b>	<b>55</b>
<b>PERSISTENT FORAMEN OVALE AS A CAUSE OF CEREBRAL STROKES IN YOUNG INDIVIDUALS - CASE REPORT .....</b>	<b>66</b>
<b>MUCOCELE OF THE APPENDIX .....</b>	<b>77</b>
<b>MULTIPLI VENTRICULAR SEPTAL DEFECTS – A CASE REPORT.....</b>	<b>82</b>
<b>USING A STICKY BONE FOR GBR AND SOCKET PRESERVATION.....</b>	<b>90</b>
<b>PYOGENIC GRANULOMA OF THE GINGIVA - CLINICAL CASE REPORT.....</b>	<b>99</b>



MIT UNIVERSITY  
SKOPJE

**SURGICAL TREATMENT OF RADICULAR CYST IN MAXILLA -  
A CASE REPORT .....107**

**VITAMIN C FOR HEALTHY SKIN.....116**

**HEALTH BENEFITS OF INDIVIDUAL STRUCTURES  
OF THE RASPBERRY PLANT.....130**

**WELLNESS AND SPA THERAPY FOR ADOLESCENTS AND  
CHILDREN AS COMMUNITY THERAPY FOR IMPROVING  
MENTAL AND PHYSICAL HEALTH.....142**

**METHODOLOGICAL APPROACH TO REACTIVATION OF URBAN  
SPACES.....154**

**ATTITUDES OF MEDICAL PERSONNEL TOWARDS  
ORGANIZATIONAL CHANGES IN HEALTH ORGANIZATIONS IN R.N.  
MACEDONIA.....170**

## **Social Sciences and Humanities**

**CRIMINAL PROFILING: THEORY AND PRACTICE .....180**

**THE SILENT ENGINE OF SUCCESS: MANAGING COMMUNICATION  
IN MODERN ORGANISATIONS.....194**

**SISTERHOOD BY DINA DUMA: EXPLICIT FEAR FROM  
THE CONTEMPORARY COMMUNICATION FORMS.....205**



MIT UNIVERSITY  
SKOPJE

International Journal of Recent Research in Arts and Sciences

ISSN: 1857-8128

<b>THE IMPACT OF DRUG ABUSE .....</b>	<b>229</b>
<b>THE IMPACT OF RISING INFLATION ON DIFFERENT INCOME GROUPS AND ITS EFFECT ON DEBTORS AND SAVERS .....</b>	<b>269</b>
<b>CHILD TRAFFICKING.....</b>	<b>279</b>
<b>SWOT ANALYSIS AS A METHOD OF STRATEGIC PLANNING .....</b>	<b>309</b>
<b>THE IMPORTANCE OF FORMULATING THE STRATEGY FOR THE OPERATION OF THE ENTERPRISE.....</b>	<b>321</b>
<b>ELEMENTS OF RESIDENTIAL SPACE .....</b>	<b>337</b>
<b>IMPORTANCE OF MOTIVATION IN THE LEARNING PROCESS.....</b>	<b>353</b>
<b>HISTORICAL DEVELOPMENT OF TAXES .....</b>	<b>371</b>
<b>CRITICAL NOTES ON JEAN PIAGE'S THEORY: EGOCENTRISM AND CENTERED THINKING IN CHILDREN IN THE PREOPERATIONAL PHASE OF COGNITIVE DEVELOPMENT .....</b>	<b>386</b>
<b>RELATIONSHIP BETWEEN SOCIAL MALADAPTATION AND ANXIETY IN HOSPITALIZED PATIENTS WITH CYSTIC FIBROSIS .....</b>	<b>406</b>
<b>THE ROLE OF THE FAMILY AND THE PARENTAL STYLE IN THE PSYCHOSOCIAL DEVELOPMENT OF ADOLESCENTS .....</b>	<b>415</b>
<b>JUSTICE AND EQUITY.....</b>	<b>426</b>



MIT UNIVERSITY  
SKOPJE

**International Journal of Recent Research in Arts and Sciences**

**ISSN: 1857-8128**

## **USING A STICKY BONE FOR GBR AND SOCKET PRESERVATION**

Markovska Arsovska M<sup>1</sup>, Trajculeski S<sup>2</sup>, Mencheva Zh<sup>3</sup>, Stojanova I<sup>2</sup>, Temelkova S<sup>4</sup>,  
Zabokova Bilbilova E<sup>5</sup>

<sup>1</sup>Faculty of Medical Sciences, Goce Delcev University, Stip, North Macedonia

<sup>2</sup>Departement of oral surgery, Dental Clinical Center ``St. Pantelejmon``

<sup>3</sup>Faculty of Dental Medicine, MIT University, North Macedonia

<sup>4</sup>PHU Zabna ordinacija dr. Snezana Temelkova, Veles

<sup>5</sup>Department of Pediatric and Preventive Dentistry. Faculty of Dentistry, Skopje, University ``St. Cyril and Methodius`` Skopje, RN Macedonia

### **Abstract**

The loss of the tooth causes the resorption of the alveolar bone. The consequence is the change of the morphology of the alveolar ridge. Bone regeneration is a natural process where your body creates new bone tissue. In dentistry, we harness this process to restore lost bone volume in your jaw. Guided bone regeneration (GBR) and autologous bone graft are the most common techniques for alveolar bone augmentation. Platelet-rich fibrin (PRF) is a healing biomaterial having potential for bone and soft-tissue regeneration without inflammation. It can be used alone or along with bone graft. Compressed PRF membrane acts as a barrier membrane. The aim of this study was to evaluate the amount of bone gained following horizontal ridge augmentation procedure and socket preservation by using Sticky bone and PRF membrane. Bone graft regeneration and socket preservation was performed on a 54-year-old after a difficult extraction of the upper right lateral incisor, which resulted in a bone defect and she wanted to correct it. The bone that was planned to be applied was previously prepared as adhesive bone using the previously prepared PRF, and covered with PRF membrane, that served as a barrier to protect the migration of soft tissue elements into the bone tissue and to obtain bone healing of the wound. GBR by sticky bone which is obtained by mixing iPRF and bone graft together supported by PRF membrane is an efficient method for guided bone regeneration and socket



preservation after tooth extraction. This method achieves a satisfactory width and height of the alveolar ridge.

### **Introduction**

The loss of the tooth causes the resorption of the alveolar bone [1]. As to stop the stimulus induced by the periodontal ligament, the vestibular cortical bone is subjected to resorption and the marrow component of the alveolous gradually disappeared [2,3,4]. The consequence is the change of the morphology of the alveolar ridge, which, in limited form for number of teeth lost, configure the degree of the alveolar defect and by extension, condition of more pronounced atrophy [5]. The gradual disappearance of the alveolar process involves the reduction of sagittal size and then vertical size of the jaws, as described firstly by the classifications of Cawood and Howell [6] and then by Misch and Judy [7] leading to a subversion of intermaxillary relations and functional abnormality which makes incompetent the two dental arches. Bone regeneration is a natural process where your body creates new bone tissue. In dentistry, we harness this process to restore lost bone volume in your jaw. This is often necessary when tooth loss, gum disease, prior dental procedures, or injuries have caused your jaw bone to deteriorate over time. Preserving as restoring a sufficient bone volume to support the prosthetic load, and also the insertion of the dental implant as a support for prosthesis, requires the use of surgical protocols that enable the bone regeneration on the deficient sites, using the principles of osteogenesis, osteoinduction and osteoconduction.

There is a variety of techniques to stimulate bone regeneration, including:

- **Bone grafting:** This involves adding bone material to the deficient area. The graft can come from your own body, a donor, or synthetic materials.
- **Guided bone regeneration (GBR):** A special membrane is used to create a protected space for new bone to grow.
- **Growth factors:** These proteins stimulate the body's natural bone-building cells.

Guided bone regeneration (GBR) and autologous bone graft are the most common techniques for alveolar bone augmentation.[8,9]



MIT UNIVERSITY  
SKOPJE

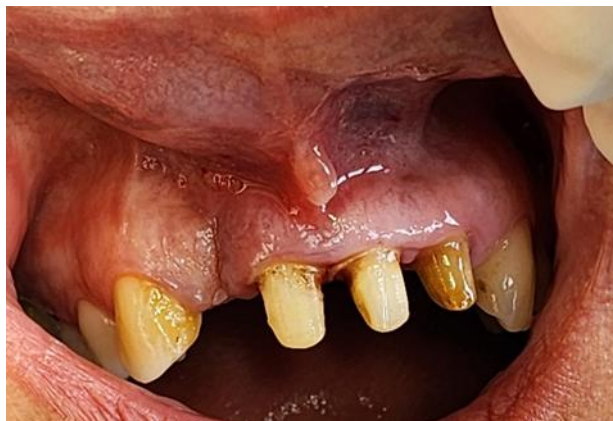Platelet-rich fibrin (PRF) is a healing biomaterial having potential for bone and soft-tissue regeneration without inflammation.[10] It can be used alone or along with bone graft. Compressed PRF membrane acts as a barrier membrane. Mixing Injectable platelet rich fibrin (IPRF) with the granules of bone graft resulted in the formation of sticky bone. After placing sticky bone, a barrier membrane was used to support the grafted bone to the tissue.

### **Aim**

The aim of this study was to evaluate the amount of bone gained following horizontal ridge augmentation procedure and socket preservation by using Sticky bone and PRF membrane.

### **Case report**

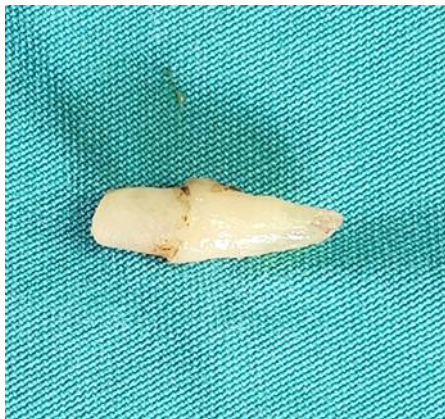Bone graft regeneration and socket preservation was performed on a 54-year-old woman who came to the Clinic of Oral Surgery. In the anamnestic data, she provided information that she previously had a difficult extraction of the upper right lateral incisor, which resulted in a bone defect and she wanted to correct it. On clinical examination, in addition to the bone defect, bone retraction was also seen from the distal side of the upper right central incisor of more than two-thirds of the root. (Picture 1)



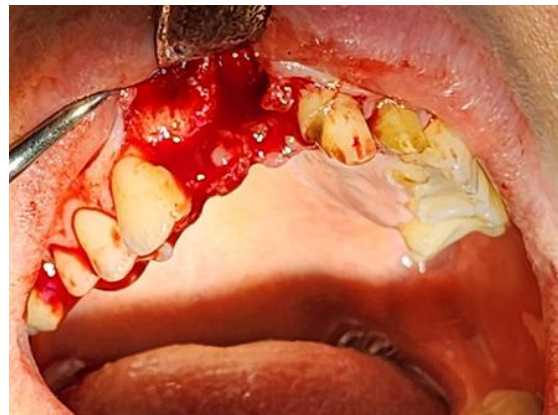
Picture 1. Bone defect

The bone width, in the socket preservation area, measured with the bone measurement caliper was 10 mm in the middle of the alveolar ridge. The high was measured with graduated

periodontal probe. In the region of the central incisor papilla was 3 mm, and the high of the alveolar ridge was 4,5 mm. The bone width in the planed GBR area was 7 mm, and the high was 4,5 mm in the region of canine, and 3 mm in the middle of the alveolar ridge. An X-ray confirmed the large loss of bone tissue in the area of the upper lateral incisor and from the distal side of the upper central incisor. After the examination and the X-ray, an indication for surgical intervention was set. It was planned to remove the right maxillary central incisor and at the same stage to perform guided bone regeneration of the defect in the area of the lateral incisor and socket preservation in the area of the central incisor. Before the intervention, blood was taken from the patient's cubital vein to prepare iPRF. The intervention was performed under local anesthesia with Scandonest 2%. After elevation of the mucoperiosteal flap and extraction of the central incisor (Picture 2 and 3), correction of sharp edges and bone retention was performed by using a drill.



Picture 2. Extracted central incisor



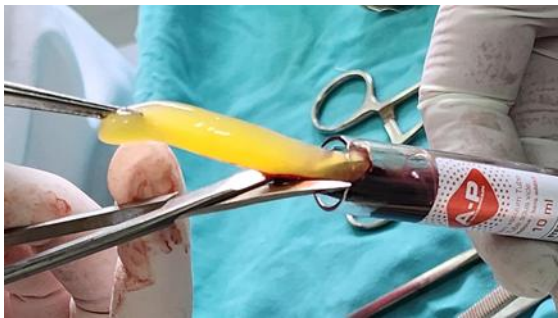
Picture 3. Elevation of mucoperiosteal flap

The bone that was planned to be applied was previously prepared as adhesive bone (Picture 7, 8, 9) using the previously prepared PRF that was taken from one of the tubes (Picture 4, 5), and from the other tube the PRF was placed in a box to form a PRF membrane (Picture 6),

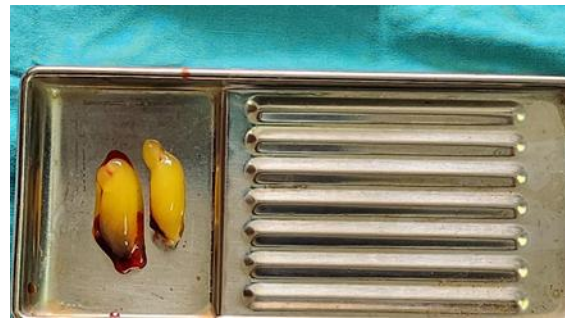

MIT UNIVERSITY  
SKOPJE

that would serve as a barrier to protect the migration of soft tissue elements into the bone tissue and to obtain bone healing of the wound.



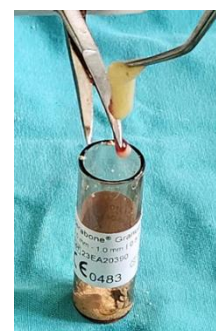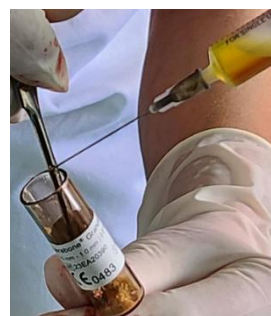Picture 4. Tube with PRF



Picture 5. PRF clothe



Picture 6. PRF membrane

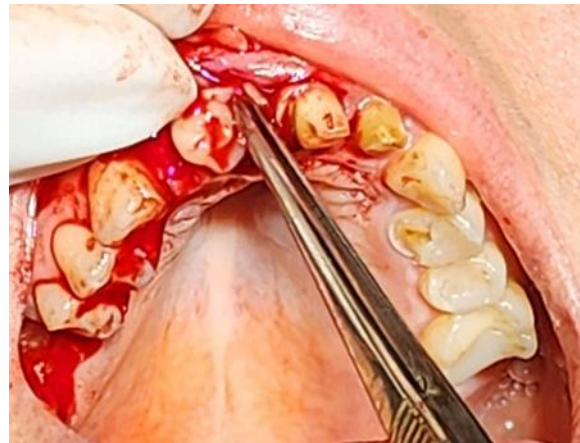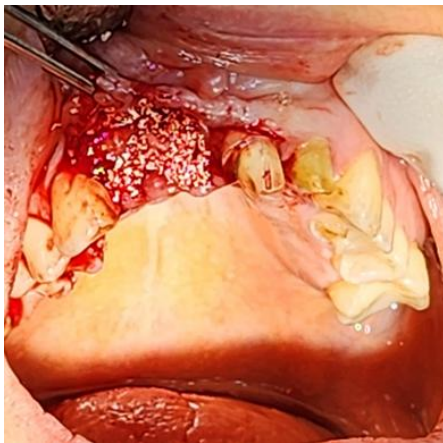


Pictures 7, 8, 9. Sticky bone preparing



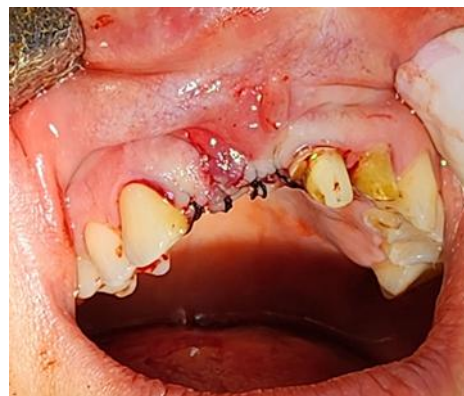MIT UNIVERSITY  
SKOPJE

The prepared sticky bone was placed in the width and height in the lateral incisor region of the bone tissue and in the socket of the central incisor. The PRF membrane was applied over the placed bone, which was adapted from the palatal, coronal and vestibular sides. (Picture 10, 11)



Pictures 10, 11. Sticky bone, PRF membrane

The mucoperiosteal flap, which had previously been relaxed to avoid tension, was returned over the membrane and suture was placed. (Picture 12)



Picture 13. Suturing



Control examinations were performed on the second and seventh days. On the second day, mild edema was noted in the patient. The patient did not complain of pain. On the seventh day, there were no changes extraorally or intraorally. The suture was removed on the fourteenth day. After 1 month the bone width and high were with the increased dimension due to bone application. Only in the middle ridge in region of extracted central incisor was 6 mm, which is a minor bone loss.

### **Discussion**

This case report represent a guided bone regeneration by using a sticky bine and PRF membrane. In the study of Mendoza et al.[11] the bovine bone with or without block graft and the collagen membrane was used to enlarge the bone tissue.

The histological studies have been important as proof of concept, they have not provided explanations on how the presence of a membrane influences the cellular and molecular events during the consecutive phases of bone healing (inflammation, bone formation, and remodeling) in the under lying defect. In fact, the traditionally proposed explanation for how the membrane promotes bone formation is that the membrane acts as a passive barrier for soft-tissue invasion, rather than directly promoting the sequences of biological processes that lead to bone regeneration and filling of the defect with mature, remodeled bone. [12] In our case we used a PRF membrane as a barrier to prevent a soft tissue migration.

The study of Renvert et al. [13] demonstrates good long-term sustainability following reconstructive surgical treatment with guided bone regeneration (GBR) treatment of peri-implantitis-related bony defects which improves healing in comparison to open flap debridement (OFD) during 36 months.

Since disuse atrophy persists if not restored, many issues with vertical and horizontal bone loss can occur. To minimize bone loss, extraction socket preservation (ESP) can be made, where bone graft is performed at the time of extraction. [14] In this case report socket preservation was made after extraction of maxillar lateral incisor to reduce the bone lose.

For making a sticky bone we used iPRF, what matches with the case report of Romesh et al.[15]



### **Conclusion**

GBR by sticky bone which is obtained by mixing iPRF and bone graft together supported by PRF membrane is an efficient method for guided bone regeneration and socket preservation after tooth extraction. This method achieves a satisfactory width and height of the alveolar ridge.

### **References**

- [1] Atwood DA. Reduction of residual ridge: A major oral disease entity. *J Prosthet Dent.* 1971;26(3):267–279.
- [2] Neufeld JO. Changes in the trabecular pattern of the mandible following the loss of teeth. *J Prosthet Dent.* 1958;8(4):685–697.
- [3] Ulm C, Solar P, Blahout R, et al. Reduction of the compact and cancellous bone substances of the edentulous mandible caused by resorption. *Oral Surg Oral Med Oral Pathol.* 1992;74:131–6.
- [4] Botticelli D, Berglundh T, Lindhe J. Hard tissue alterations following immediate implant placement in extraction sites. *J Clinical Periodontol.* 2004;31(10):820–8.
- [5] Cho JY. The periodontist and the edentulous area-localised ridge augmentation. *Int Dent J.* 1998;48(3 Suppl1):326–9.
- [6] Cawood JI, Howell RA. A classification of the edentulous jaws. *Int J Oral Maxillofac Surg.* 1988;17:232–236.
- [7] Misch CE. *L'odontoiatria implantare contemporanea. I edizione italiana* Antonio Delfino Editore. 2000. Suddivisione dell'osso disponibile; pp. 89–108.
- [8] Cortese A, Pantaleo G, Amato M, Howard CM, Pedicini L, Claudio PP. Platelet-rich fibrin (PRF) in implants dentistry in combination with new bone regenerative flapless technique: Evolution of the technique and final results. *Open Med (Wars)* 2017;12:24-32.



MIT UNIVERSITY  
SKOPJE

- [9] Soni R, Singh A, Vivek R, Baranwal HC, Chaturvedi TP, Srivastava A. Immediate implant placement in mandibular anterior region with dehiscence. *J Dent Implant* 2013;3:177-80
- [10] Cortese A, Pantaleo G, Borri A, Caggiano M, Amato M. Platelet-rich fibrin (PRF) in implant dentistry in combination with new bone regenerative technique in elderly patients. *Int J Surg Case Rep* 2016;28:52-6.
- [11] Mendoza- Azpur et al. Horizontal ridge augmentation with guided bone regeneration using particulate xenogenic bone substitutes with or without autogenous block grafts: A randomized controlled trial. *Clin Implant Dent Relat Res.* 2019;1–10.
- [12] Elgali et al. Guided bone regeneration: materials and biological mechanisms revisited, review. *Eur J Oral Sci* 2017; 125: 315–337
- [13] Renvert et al. The efficacy of reconstructive therapy in the surgical management of peri-implantitis: A 3-year follow-up of a randomized clinical trial. *J Clin Periodontol.* 2024;51:1267–1276.
- [14] Young-Kyun K, Jeong-Kui K. Extraction socket preservation. *J Korean Assoc Oral Maxillofac Surg* 2020;46:435-439.
- [15] Romesh et al. Bone augmentation with sticky bone and platelet-rich fibrin by ridge-split technique and nasal floor engagement for immediate loading of dental implant after extracting impacted canine. *Nat J Maxillofac Surg.* 2019: 10 (1); 98- 101.