

# Labor and Delivery with Deep Vein Thrombosis, Case report

Baldzieva, S.<sup>1</sup>, Zlateska, A.<sup>1</sup>, Zlateska S.<sup>1</sup>, Baldzieva, A.<sup>2</sup>, Markov, P.<sup>2</sup>, Damjanovikj, D.<sup>3</sup>

1.University Clinic for Gynecology and Obstetrics Skopje, Republic of North Macedonia

2.General Hospital Strumica, Republic of North Macedonia

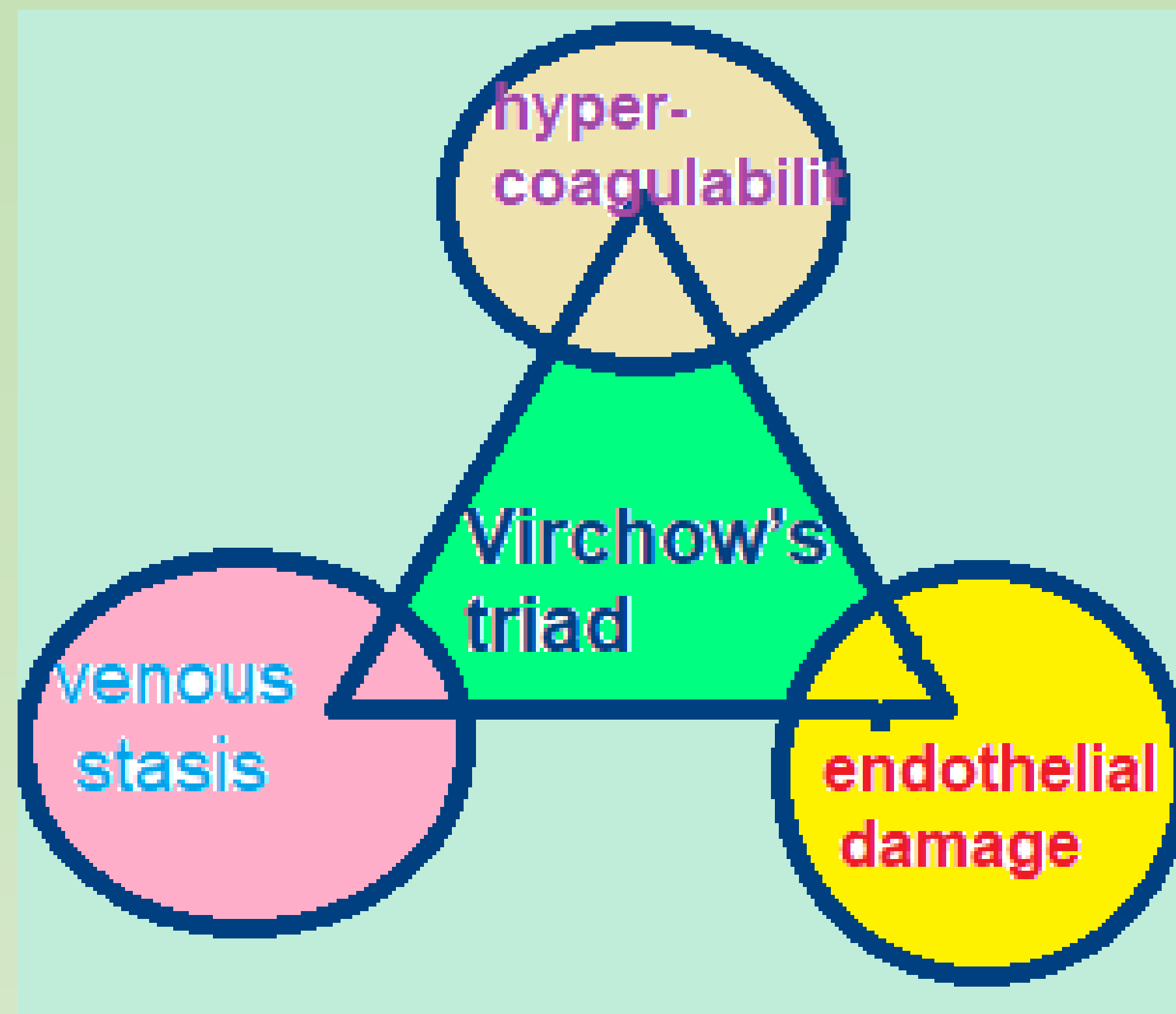
3. University. Clinic of Orthopedic Surgery Skopje, Republic of North Macedonia

## Objective

Pregnancy is a prothrombotic state and it has all components of Virchow's triad: venous stasis, endothelial damage and hypercoagulability. The incidence of all thromboembolic events is about 1 in 1000 pregnancies. Pulmonary embolism still remains leading cause of maternal sudden death, especially in the first 6 weeks postpartum. Deep vein thrombosis(DVT) is considered highest in the early third trimester and is present in otherwise healthy women. In pregnancy the risk of DVT is a five times higher than non-pregnant women. The risk for thromboembolism is approximately doubled in patients with multifetal gestation, anemia, hyperemesis, haemorrhage and cesarean delivery, as well as in pregnancies complicated by postpartum infections. The aim is to describe different cases of DVT with spontaneous and cesarean delivery and postpartum recovery period and bleeding.

## Methods

Patients with deep vein thrombosis of iliofemoral veins were examed, with a clear clinical presentation of unilateral leg edema, which was warm and reddened in relation to the other leg, with pain and visibly restricted movements. Patients were without previous history of DVT, BMI <30, thrombophilia, or other comorbidities, <35 years. Patients had DVT on left leg, which is present in 82% of cases of DVT in pregnancy. The diagnosis was made by determining of haemostasis, d-dimer and ultrasound color Doppler.



One patient was 25 years old, at week 26 of pregnancy. The ultrasonic color Doppler showed more than 50% obstruction of the left iliac, common femoral and superficial femoral vein, with normal flow in the left popliteal vein, as well as the blood vessels of the right leg. The patient was admitted in the hospital with analyses of haemostasis that showed a hypercoagulable state with an initial count of di-dimeri over 5000IU. The obstetric findings were normal, with breech presentation of the fetus and ultrasound estimated fetal weight about 3800 grams. The other patient was 22 years old, in the 28 week of the pregnancy, Ultrasound colour Doppler showed obstruction of the left femoral vein more than 65% and normal color Doppler on the remain veins in the left leg. D-dimeri count was 3500 IU. The obstetric finding were arranged with cephalic fetal presentation and ultrasound estimated fetal weight about 3300 grams. The obstetrical pelvic measurements were normal. Due to obstetric indication, because of breech presentation and cephalo-pelvic disproportion, the first patient delivered with caesarian section. The other patient had spontaneous labor and had vaginal delivery

## Results

Patients were treated until the delivery with high initial doses of Low-Molecular-Weight Heparin(LMWH). In the last month of pregnancy, low-molecular-weight heparin was replaced by unfractionated heparin (UFH), and administrated up to 24 hours prior the cesarean section. The anticoagulant therapy in the other patient was stopped at the time of spontaneous rupture of the fetal membranes. In the first patient, 12 hours after the elective cesarean section, an anticoagulant therapy was administered. Because of the occurrence of a small hematoma in the episiotomy limit, in the patient with spontaneous delivery, administration of anticoagulant therapy was postponed to 24 hours postpartum.

Postpartum recovery did not show any difference in patients with DVT both in spontaneous and cesarean delivery. During the delivery, there was no significant blood loss, and the response to anticoagulant therapy was satisfactory. Administration of anticoagulant therapy has been in coordination with analysis of haemostasis and d-dimers, and the resolution of the clinical presentation occurred 7 to 10 days after the primary appearance of the symptoms of DVT and initiation of therapy.

## Conclusion

The hypercoagulability is the most important risk factor leading to DVT in pregnancy. The appropriate anticoagulant therapy that is properly dosed should provide both fetal and maternal well-being in this population.