

FACULTY OF MEDICAL SCIENCES,
"GOCE DELCEV" UNIVERSITY,
STIP, NORTH MACEDONIA
PROF. DR. KIRO PAPAKOCA

**„ПРОТЕТСКИ КОМПЛИКАЦИИ ВО ДЕНТАЛНАТА
ИМПЛАНТОЛОГИЈА“**

**“Prosthetic Complications in Dental
Implantology”**


9th PAN Albanian Dental Congress


24 – 26 May 2024 - Struga

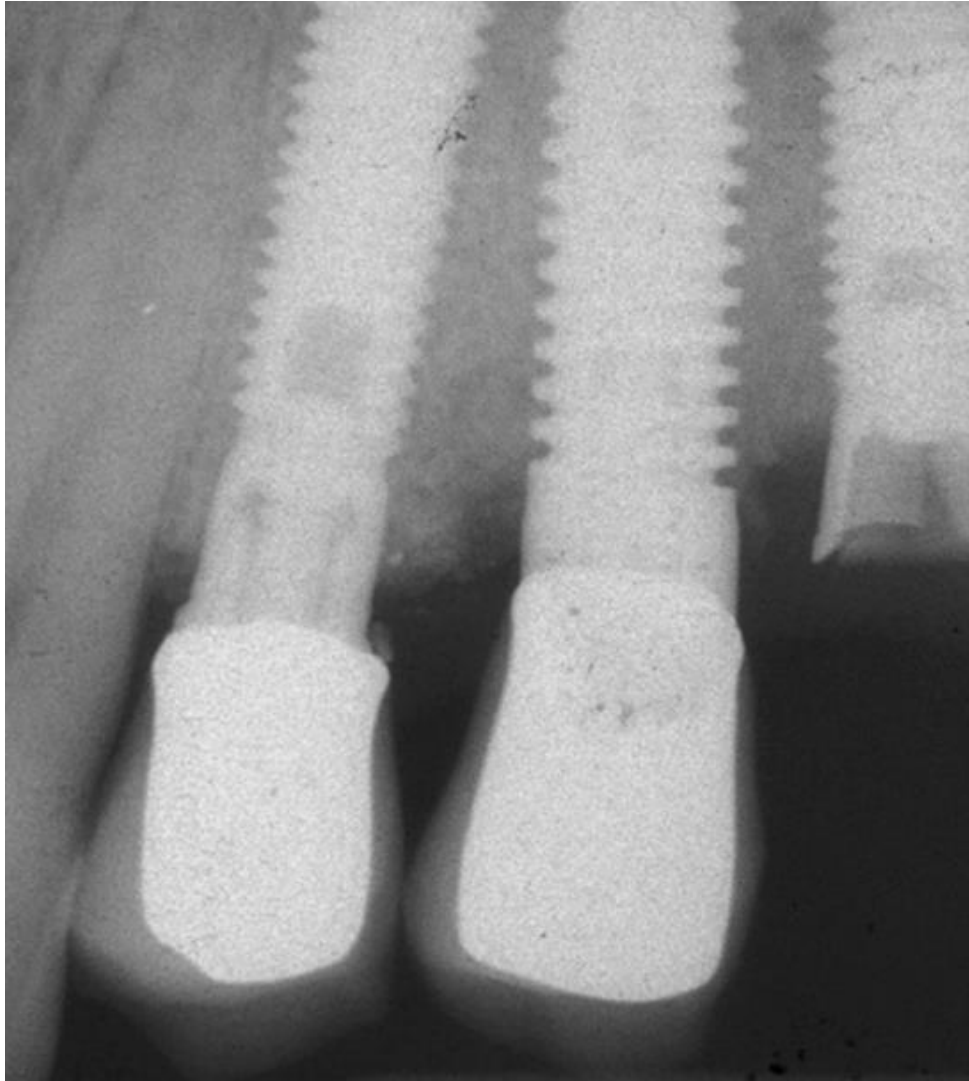
WWW.UGD.EDU.MK

WWW.DENT-ESTET.COM

KIRO.PAPAKOCA@UGD.EDU.MK
KIRO.DENTESTET@GMAIL.COM







ПРОТЕТСКИТЕ КОМПЛИКАЦИИ

Early
complications

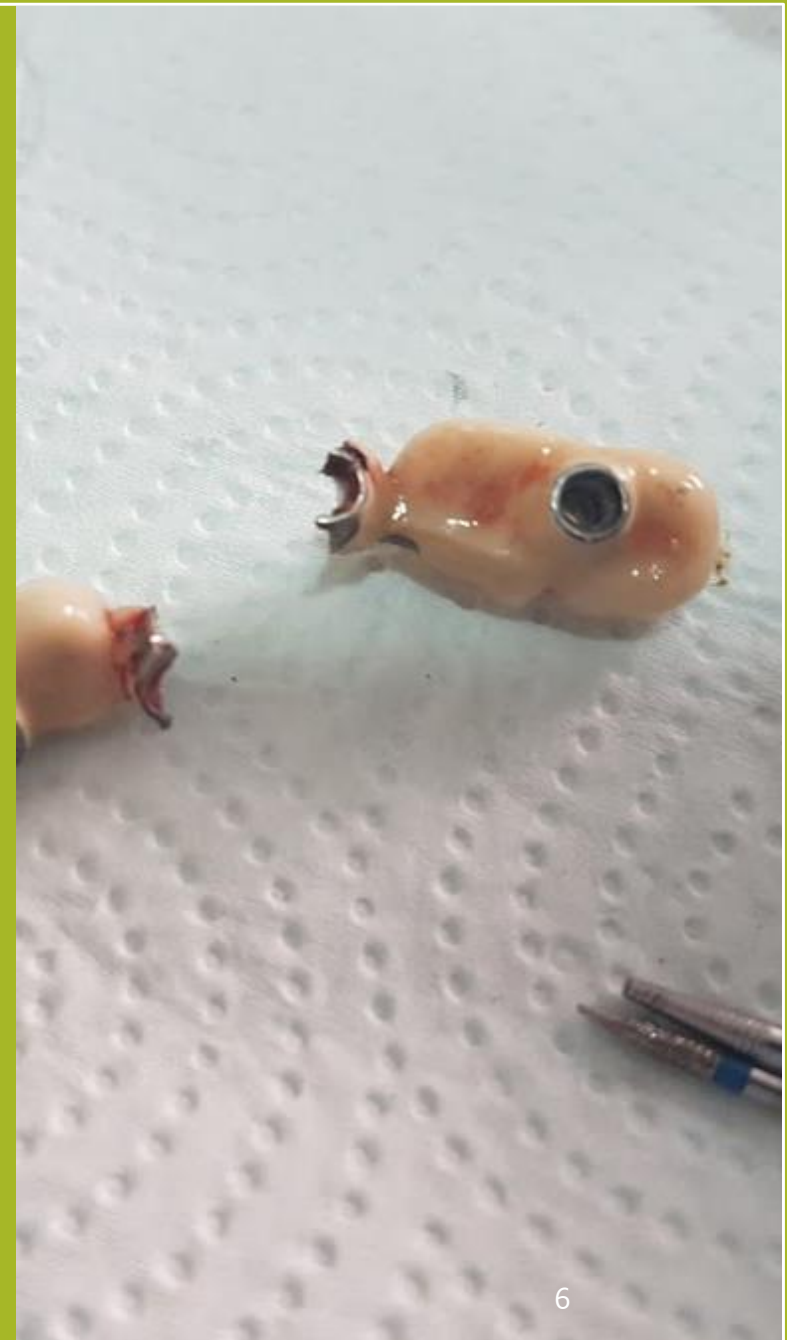Appear in the immediate postoperative period and interfere with healing

Late
complications

Arise during the process of
osseointegration.

The complications were divided into the following 6 categories:

surgical,
implant loss,
bone loss,
peri-implant soft tissue,
mechanical, and
esthetic/phonetic.



A photograph of two dentists, a man and a woman, in a clinical setting. They are both wearing white lab coats and face masks. The man is on the left, and the woman is on the right. They are looking at a computer monitor which displays a dental X-ray. The image is overlaid with a semi-transparent green filter. A white horizontal line is positioned above the text.

PLANIRANJE

- **Primary stability**




КОРЕКЦИИ КАЈ ИМПЛАНТО – ПРОТЕТСКИ ТРЕТМАНИ

A close-up photograph of a dental crown on a tooth. The crown is a light, translucent color, possibly ceramic or porcelain, and is fitted over a prepared tooth. The background is a solid, vibrant green color. A semi-transparent white rectangular box is overlaid on the image, containing the text "CEMENTED RESTAURATION" in a bold, white, sans-serif font. A thin white horizontal line is positioned below the text. On the left side of the image, there is a small, faint white letter "C".

CEMENTED RESTAURATION

C



**NO IMPLANTS,
NO SURGERY,
ONLY PROSTHETICS!**

The presents and the future ...