

Journal of Morphological Sciences

[Current](#) [Archives](#) [About](#)

[Home](#) / [Archives](#) / Vol 5 No 1 (2022): JMS



ISSN 2545-4706

<https://doi.org/10.55302/JMS>

<https://doi.org/10.55302/JMS2251>

Published: 2022-05-06

Articles

18F-FDG PET/CT IN DIFFERENTIATING EQUIVOCAL CT LESIONS IN PATIENT WITH COLORECTAL CANCER

Goran Spirov, Simon Beshliev, Niki Matveeva, Vasilcho Spirov, Ana Ugrinska

1-10

 PDF

VITAMIN D AND ASTHMA IN CHILDHOOD

Vesna Micevska, Tatjana Jakovska Maretii, Ilija Kirovski, Olivera Jordanova

11-19

 PDF

SODIUM DODECYL SULFATE-POLYACRYLAMIDE GEL ELECTROPHORESIS AS A USEFUL TOOL FOR ASSESSING THE SEVERITY OF DIABETIC NEPHROPATHY

Irena Kostovska, Danica Labudovic, Katerina Tosheska-Trajkovska, Jasna Bogdanska, Sonja Topuzovska, Hristina Ampova, Jilijana Brezovska Kavrakova, Svetlana Cekovska

20-27

 PDF

ENDOMETRIAL PATHOLOGICAL CHANGES IN PERIMENOPAUSE AND POSTMENOPAUSE - ASSOCIATION WITH SOME ANAMNESTIC AND ULTRASONOGRAPHIC PARAMETERS

Ana Kocevska, Dimche Zafirov, Gordana Petrushevska, Bashkim Ismaili, Kristina Skeparovska, Shenol Tahir

28-38

 PDF

A CASE OF CORNUAL ECTOPIC PREGNANCY THAT WAS SUCCESFULLY LAPAROSCOPICALLY TREATED

Dimitar Georgiev, Bashkim Ismaili, Shenol Tahir, Ana Kocevska, Kristina Skeparovska

39-43

 PDF

A RARE CASE OF SEROUS CARCINOMA OF THE UTERINE CORPUS THAT ARISES IN POLYP

Ana Kocevaska, Emil Bajalski, Dimitar Georgiev, Bashkim Ismaili, Kristina Skeparovska, Shenol Tahir; Aleksandar Nakov
44-48

 PDF

USE OF ULTRASONOGRAPHY FOR CONFORMATION OF CENTRAL VENOUS CATHETER PLACEMENT FOR HEMODIALYSIS - SINGLE CENTER EXPERIENCE

Vladimir Pushevski, Adrijana Spasovska-Vasilova, Mimoza Milenkova, Zoran Janevski, Lada Trajceska, Irena Rambabova Bushljetikj, Ana Marija Shpishikj Pushevaska, Petar Dejanov
49-53

 PDF

INFLUENCE OF DAILY SODIUM INTAKE ON MORTALITY IN HD PATIENTS

Galina Severova, Vlatko Karanfilovski, Ana Stojanovska- Severova, Lada Trajceska, Pavlina Dzekova- Vidimliski
54-63

 PDF

THE PREDICTIVE ROLE OF SELECTIVE LABORATORY PARAMETERS FOR THE OCCURRENCE OF “UNWANTED EVENTS” IN ADULTS WITH LAPAROSCOPIC APPENDECTOMY

Ilija Milev, Vesna Velikj Stefanovska, Aleksandar Mitevski, Panche Karagjozov, Marjan Mihailov
64-74

 PDF

INFLUENCE OF GENDER ON THE INTENSITY OF INFLAMMATIVE RESPONSE IN INFLAMMATORY GALLBLADDER DISEASES

Zarko Spasovski, Beti Zafirova, Meri Kirijas, Biljana Novevska Petrovska, Sasho Stojanoski, Stefan Krstevski
75-84

 PDF

FACTORS PREDICTING THE LIKELIHOOD OF NON-SENTINEL LYMPH NODE METASTASES IN BREAST CANCER PATIENTS WITH A POSITIVE SENTINEL LYMPH NODE: A SINGLE-CENTER STUDY

Borislav Kondov, Sinisha Stojanovski, Magdalena Bogdanova, Viktor Gruev, Risto Cholancheski, Ljubica Atanasova, Goran Kondov
85-92

 PDF

OVERLAP SYNDROME IN A REFRACTORY CASE

Filip Guchev, Snezana Mishevska Perchinkova, Georgi Bozhinovski, Ljubinka Damjanovska
93-95

 PDF

ASSOCIATION OF NOS3 GENE POLYMORPHISM rs1799983 WITH IN-STENT RESTENOSIS OF CORONARY ARTERIES

Zan Zimbakov, Oliver Busljetic, Silvana Jovanova
96-102

 PDF

THE EFFECT OF METHYLPREDNISOLONE VERSUS DEXAMETHASONE IN INCREASING THE DIABETOGENIC EFFECT OF SARS-CoV-2 INFECTION AND THE DEVELOPEMENT OF NEW-ONSET DIABETES MELLITUS

Milena Srbinoska Bogatinoska, Lidija Popovska, Tatjana Prosheva, Iskra Bitoska, Ivan Vidinic, Marija Vavlukis, Marijan Milenkovski
103-112

 PDF

KLINFELTER SYNDROME AND OTHER SEX CHROMOSOMAL ANEUPLOIDES IN THE R. OF NORTH MACEDONIA

Toso Plasheski, Iskra Bitoska, Dzuliana Mihajlovska, Sasha Jovanovska Mishevska, Snezana Markovic, Dijana Plaseska-Karanfilska, Predrag Noveski
113-118

 PDF

UNDERWEIGHT, OVERWEIGHT, GENERAL AND CENTRAL OBESITY IN 5-YEAR-OLD CHILDREN FROM NORTH MACEDONIA

Biljana Zafirova, Elizabeta Chadikovska, Biljana Trpkovska, Biljana Bojadzieva Stojanoska, Ace Dodevski
119-126

 PDF

MESIODENTES AS A MECHANICAL OBSTACLE IN THE ERUPTION OF PERMANENT TEETH- CASE REPORT

Aleksandar Bochvarov, Dejan Baldziev, Oliver Temelkov, Simona Temelkova, Ljuba Simjanovska, Mirjana Markovska Arsovska
127-131

 PDF

PERIAPICAL SURGERY: THE ISSUE OF RETROGRADE OBTURATION

Marina Kacarska

132-144



PDF

THE LINK BETWEEN THE PRESENCE OF AN ODONTOGENIC RADICULAR CYST AND THE BODY'S IMMUNE RESPONSE -CASE REPORT

Irena Stojanova, Oliver Dimitrovski, Daniela Veleska Stevkovska, Mirjana Markovska Arsovska, Vancho Spirov

145-151



PDF

NONENZYMATIC GLYCOLISATION AND GINGIVAL TISSUES: A REVIEW

Angelina Sredovska Bozhinov, Marija Nakova

152-156



PDF

LABORATORY RESULTS THAT SUGGEST USING PROGNOSTIC MARKERS IN ASSESSMENT AND DIAGNOSIS OF RHEUMATOID ARTHRITIS

Dejan Spasovski, Emilija Sandevska, Aleksandra Pivkova Veljanovska, Svetlana Krstevska Balkanov

157-162



PDF

THE EFFECT OF EXTRACORPOREAL SHOCK WAVE THERAPY IN TREATMENT OF CALCIFYING TENDINITIS OF THE ROTATOR CUFF OF THE SHOULDER

Maja Manoleva, Valentina Koevska, Biljana Mitrevska, Marija Gocevska, Cvetanka Gjerakaroska Savevska, Biljana Kalchovska Ivanovska, Liljana Malinovska Nikolovska

163-171



PDF

IMPACT OF INTENSITY MODULATED RADIATION THERAPY ON THE SALIVARY GLANDS FUNCTION AND SALIVA FLOW RATE

Sonja Rogoleva Gjurovski, Vladimir Popovski, Lenche Kostadinova, Bruno Nikolovski

172-178



PDF

ORAL-SURGICAL TREATMENT OF PERIODONTAL POCKET WITH GUIDED BONE AND SOFT TISSUE REGENERATION

Biljana Evrosimovska, Ivana Pop Janeva, Bojana PopJaneva, Bruno Nikolovski

179-186

 PDF

ORTHODONTIC APPROACH IN THERAPY OF PATIENTS WITH DIABETES MELLITUS

Vanja Ichkova, Emilija Grujoska Dimovska, Biljana Bogdanovska, Katerina Adamova

187-195

 PDF

Information

[For Readers](#)

[For Authors](#)

[For Librarians](#)

Journal of Morphological Sciences is an official journal of the **Macedonian Association of Anatomists**, published twice or three times a year in English.

powered by OJS | Open Journal Systems
PKP | PUBLIC KNOWLEDGE PROJECT

Journal of Morphological Sciences

[Current](#) [Archives](#) [About](#)

[Home](#) / [Editorial Team](#)

Editor-in-Chief

Biljana Zafirova

Deputy editors

Biljana Trpkovska

Editorial Council

Biljana Zafirova

Nikola Jankulovski

Niki Matveeva

Sonja Topuzovska

Beti Zafirova Ivanovska

Daniela Miladinova

Goran Dimitrov

Sunchica Petrovska

Jasna Bogdanska

Elena Kjosevska

Nikola Labachevski

Sonja Bojadzieva

Editorial Office

Anamarija Paunkoska

Lenche Danevska

Biljana Narashanova - secretary

International Editorial Board

Ace Dodevski, R. North Macedonia

Biljana Bojadzieva Stojanoska, R. NorthMacedonia

Elizabeta Chadikovska, R. North Macedonia

Jane Netkovski, R. North Macedonia

Katerina Kubelka Sabit, R. North Macedonia

Lazo Noveski, R. North Macedonia

Slavica Kostadinova Kunovska, R. North Macedonia

Vesna Janevska, R. North Macedonia

Vladimir Popovski, R. North Macedonia

Jasmina Trojachanec, R. North Macedonia

Sanja Mancevska, R. North Macedonia

Bruno Nikolovski, R. North Macedonia

Jasna Halilovic, Bosnia and Herzegovina

Silvia Mladenova, Bulgaria

Monika Urbaniak, Poland

Ivica Grkovic, Croatia

Simon Pkhrikyan, Armenia

Igor Sladojevic, Bosnia and Herzegovina

Ljiljana Tadic, Bosnia and Herzegovina

Biljana Srdic, Serbia

Dusica Maric, Serbia

Ivana Kavecan, Serbia

Zivka Eri, Serbia

Ljiljana Vasovic, Serbia

Mirela Eric, Serbia

Slobodan Vlajkovic, Serbia

Zoran Pesic, Serbia

Filip Vukmirovic, Montenegro

Mileta Golubovic, Montenegro

Vitaly Gargin, Ukraine

Iva Petkovska, USA

Jadranka Stojanovska, USA

Information

[For Readers](#)

[For Authors](#)

[For Librarians](#)

Journal of Morphological Sciences is an official journal of the **Macedonian Association of Anatomists**, published twice or three times a year in English.

powered by OJS | Open Journal Systems

PKP | PUBLIC KNOWLEDGE PROJECT

THE LINK BETWEEN THE PRESENCE OF AN ODONTOGENIC RADICULAR CYST AND THE BODY'S IMMUNE RESPONSE (Case report)

Irena Stojanova¹, Oliver Dimitrovski¹, Daniela Veleska-Stevkovska¹, Mirjana Markovska Arsovska¹,
Vancho Spirov¹

¹Department of Oral Surgery and Implantology, University Dental Clinical Center "St. Pantelejmon",
Skopje, R. North Macedonia

Abstract

Odontogenic radicular cysts are the most common odontogenic inflammatory cysts. Immunopathological reactions play a dominant role in their etiopathogenesis.

This study aimed to determine the presence of T and B lymphocytes, cells in the inflammatory infiltrate and, the impact of the cystic lesion on the systemic immune response by verifying the changes in the immune system by applying the immunohistochemical method in a patient with a residual cyst in the lower jaw. and one month after surgery.

Case Report: A 60-year-old woman with a residual cyst in her lower jaw was admitted to the Oral Surgery Clinic. Immunoassay of blood was performed to determine the values of immunoglobulins IgA, IgG and Ig M before surgery, cyst enucleation in toto, pathohistological and immunohistochemical analysis of CD3, CD4, CD8, CD20, and CD68 markers. Immunological blood tests were performed one month after surgery.

Pathohistological and immunohistochemical analysis confirmed the diagnosis of radicular (residual) cyst in the mandible with the presence of multilayered squamous epithelium beneath which is an inflammatory infiltrate with granulation tissue and deposited cholesterol crystals with predominant lymphadenopathy of predominant lymphadenopathy. %), are dominated by macrophages and histiocytes. Serum immunoglobulin IgA, Ig G, and IgM levels were reduced after surgery.

The use of pathohistological and immunohistochemical analyzes proves the presence of cellular and humoral immune responses and their role in the etiopathogenesis and development of cysts, while immunoassays confirm the presence of human immunoglobulin this suggests the importance of early detection and therapeutic approach to radicular cysts.

Keywords: residual cyst, pathohistological, immunohistochemical and immunological analysis, human immune response.

Introduction

Odontogenic inflammatory cysts are pathological lesions that are often present in clinical practice and also often end with complications due to untimely or inadequate treatment, their bad impact on general health, and the possibility of potential focal foci affecting other organs and systems in the body. Cysts are usually the result of more complex pathogenetic mechanisms in which the influence of the pathogenetic effect of the causative agent is often mentioned and the reduced immune defense locally in the tissue, but also the whole organism.

In recent years it has been considered a dominant role in the pathogenesis of cysts occupying immunopathological reactions. In a narrower sense, immune mechanisms are based on the action of nonspecific and specific immunity through the activity of the humoral and cellular immune responses.

According to the latest revision of the World Health Organization (WHO) Classification of Odontogenic Inflammatory Cysts from 2017 [1], they are divided into two major groups:

- radicular (apical periodontal cysts, residual, lateral) and
- collateral inflammatory cysts

Radicular cysts are the most common cysts in the jaws and their inflammatory origin is associated with the presence of an avital tooth.

This group includes residual cysts remaining in the jaws after extraction of affected teeth in case of insufficient curettage or inadequate cystectomy and lateral radicular cysts associated with the lateral root canal of the teeth.

The remaining inflammatory cysts are in the second group under the term inflammatory collateral cysts. These are periodontal cysts arising from the lower third molars and mandibular buccal bifurcation cysts that occur on the buccal surface during the eruption of the lower first and second molars. The etiopathogenesis of these pathological lesions is still completely unknown.

The detection of monoclonal antibodies and their application in immunohistochemical analysis has a serious involvement in the detection of the presence of B lymphocytes and certain subclasses of T lymphocytes such as T-helper T-Ly that produce cytokines and cytotoxic T- lymphocytes.

It is considered that immunohistochemical analysis with the use of immunohistochemical markers provides a more uniform approach to diagnosis and they are indicators in the prognosis of the pathology of odontogenic inflammatory cysts.

Aim

This study aimed to determine the phenotypic profile of cells present in the humoral and cellular response (B and T lymphocytes) in the inflammatory infiltrate, their presence, and distribution by applying a relevant immunohistochemical method in a patient with a residual cyst.

The presence of a local cystic lesion and its effect on the systemic immune response was also established by verifying changes in serum immunoglobulins before and one month after surgery.

Material and method

A 60-year-old woman reports to the Clinic for Oral Surgery for rehabilitation of the tooth for further preparation of upper and lower partial prosthesis. Intraoral examination shows remaining teeth for repair in the upper and lower jaw, normally repainted gingiva, resorbed alveolar ridge in the lower jaw from previous tooth extractions, without signs of inflammation. The patient is without subjective symptoms but gives information that two years ago she had swelling in the lower jaw left in the area of the already extracted premolars which disappeared after some time. She has not had an X-ray before their extraction. The patient denied the existence of any systemic diseases.

2D panoramic and retro alveolar imaging (Figure 1 and Figure 2) with dimensions 11,2x12,02 mm showed the presence of a residual cystic lesion, well-defined homogeneous illumination of the left mandibular bone bounded by the surrounding tissue, and lined with a thin zone of condensed bone. Illumination is in the projection of extracted premolars.

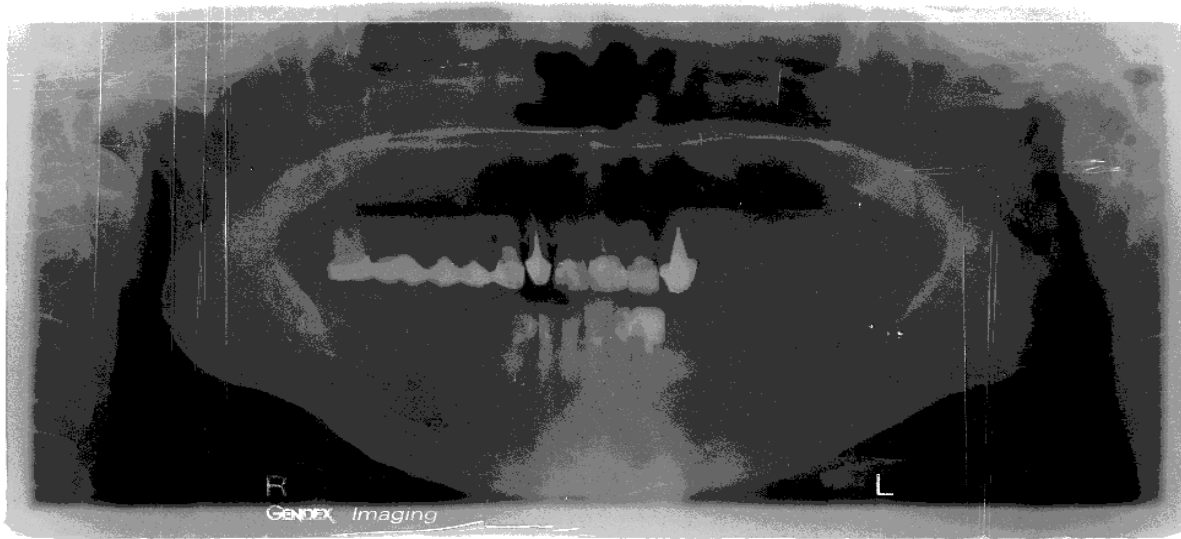

Figure 1. X-ray panoramic image.

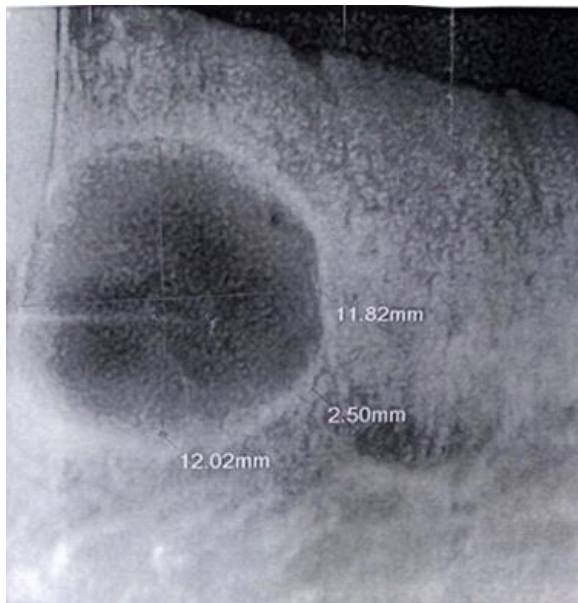


Figure 2. Retro alveolar image (cyst dimension 11,2x12,02 mm).

Immediately before the surgery, the patient's immune status was examined, which is registered as a quantitative and qualitative test of humoral immunity in the blood. A venous blood sample (9 ml) was taken at the Clinic of Clinical Biochemistry by the Vacutainer venipuncture method, followed by the presence of a humoral immune response by determining serum IgG, IgM, and IgG immunoglobulin values in the Cobas 6000 model c501 (Roche, Germany).

The surgery was performed under local anesthesia with the formation of L-mucoperiosteal flap, cystic sacculus exposure, and enucleation of the cyst in toto, cystectomy Partch II. The material was sent

for pathohistological examination at the Institute of Pathology for pathohistological verification of the cyst and establishing the diagnosis- Radicular(residual) cyst.

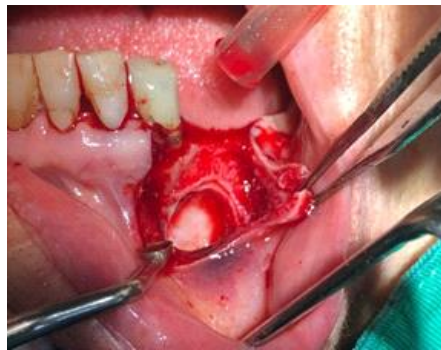

Figure 3. Formation of a mucoperiosteal flap.

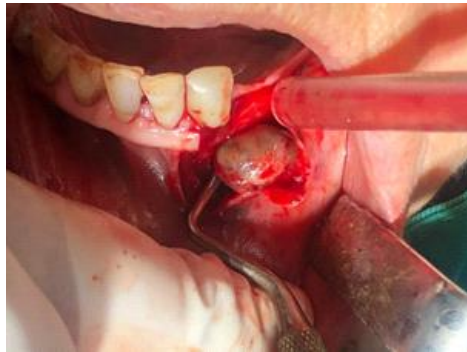

Figure 4. Enucleation of Figure.

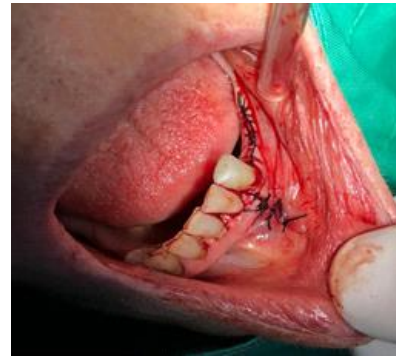

Figure 5. Suture setting cyst.

The staining of the material was by standard histochemical procedure after Hematoxylin Eosin (HE).

Immunohistochemical assays were performed using monoclonal antibodies to CD3, CD4, CD8, CD20, and CD68 cell markers to visualize and mark the required antigens. A primary antibody was used, and the reaction was visualized with the Dako En Vision Flex detection system.

Results

The values of immunoglobulins in the patient's serum were examined before surgical therapy (Table 1).

Table 1. The levels of immunoglobulins in the patient's serum before surgical therapy.

Immune status	Results	Units	Reference values	AB n	Method
Ig A(S)	3,4	g/L	0,7-4,0	N	TURB
IgG(S)	12,7	g/L	7,0-16,0	N	TURB
IgM(S)	0,93	g/L	0,4-2,3	N	TURB

The values of immunoglobulins in the patient's serum were also examined one month after surgical therapy when complete clinical wound healing without postoperative complications or early relapses had already occurred.

Table 2. The levels of immunoglobulins in the patient's serum one month after surgical therapy.

Immune status	Results	Units	Reference values	AB n	Method
Ig A(S)	3,2	g/L	0,7-4,0	N	TURB
IgG(S)	12,0	g/L	7,0-16,0	N	TURB
IgM(S)	0,92	g/L	0,4-2,3	N	TURB

After the obtained pathohistological finding, the diagnosis of radicular-residual cyst in the lower jaw was confirmed.

Macroscopic finding: Cyst with 1,2x1x0,7 cm dimensions, wall thickness 0,1 cm. The lymphatic side is with smooth surface and a brown pasty mass is seen in the lumen.

The sample is taken in one mold for pathohistological analysis. The sections are colored with HE and immunohistochemically for CD3, CD4, CD8, CD20, CD68.

Microscopic finding: microscopically the sections show partially denuded multilayered squamous epithelium beneath which there is inflammatory infiltration with granulation tissue and deposited cholesterol crystals. Immunohistochemically dominated by the presence of CD3+, CD4+, CD8+ T lymphocytes, and CD68+histiocytes. CD20 is positive in 3-5 % of cellular inflammatory infiltration.

Discussion

Pathohistological and immunohistochemical analysis confirmed the presence of odontogenic radicular cyst in the mandible with the presence of multilayered squamous epithelium under which is an inflammatory infiltrate with granulation tissue and deposited cholesterol crystals with the predominant prevalence of% 3% macrophages and histiocytes dominated.

The findings may help to explain the role of the cellular and humoral immune response in the etiopathogenesis and development of radicular cysts.

Surgical therapy and removal of the cyst also affect the values of serum immunoglobulins IgA, Ig G I IgM, the systemic immune response in the patient, and they were reduced after surgery.

The findings of our research correspond to the findings of A. Zizzi et al [2] and C. Kalvelage et al [3] in which the presence of lymphocyte phenotypes in the inflammatory infiltrate in radicular cysts has been evaluated using immunohistochemical markers for B lymphocytes (CD20) and T lymphocytes (CD3), T helper (CD4), and T cystophocyte / suppressor CD8 as well as the endothelial marker CD34 demonstrating that the inflammatory infiltrate consists of T and B lymphocytes which play an important role in stimulating neoangiogenesis and the subsequent formation and development of radicular cysts. A higher percentage of T lymphocytes has been found compared to B lymphocytes in both the epithelium and the fibrous capsule.

Our finding also coincides with an immunohistochemical study by S. Liapatas et al. [4] who used monoclonal antibodies for CD4, CD8, CD3, CD20, and CD68 and confirmed the presence of B and T lymphocytes and macrophages that make the most of the inflammatory infiltrate.

The presence of macrophages (CD68) and their subpopulations in our study is consistent with the studies of G. de Franca et al [5], A. Lukik et al. [6], C. de Oliveira Rodini [7], E. F de Carvalho [8] and B. Albertini et at [9] which confirm the immune theory of the formation of inflammatory cysts as a reaction of antigens through the role of antibodies, complement system, NK cells, cytotoxic T lymphocytes, and macrophages whose presence is detected by immunohistochemistry using CD68 antibodies. Macrophages participate in the immune response through their complex role in the process of phagocytosis and the production of inflammatory mediators that activate the humoral and cellular immune responses and participate as antigen-presenting cells. They interact directly with the cyst epithelium by releasing TNF -

alfa which regulates bone growth and resorption. Due to their role, the immune theory in the formation of inflammatory cysts can be explained.

Our results correspond to the findings in the review paper of L. Bernardi et al. [10] which included 12 published studies from 1979 to 2011 describing the proliferative epithelium in the periapical space of granulomas undergoing cystic transformation and showing a higher incidence of CD8 cells compared to CD4 cells in diffuse infiltrate. C cells are less present indicating the fact that antibody-associated reactions are not involved in the initial stage in the development of a periapical cystic lesion. Polymorphonuclear cell infiltration was present in the proliferative epithelium.

The immunological analyzes obtained from our research correspond to the study of O. Dimitrovski et al. [11] in which tests of humoral immunity were performed through blood tests of immunoglobulins before surgery and one month after it.

Serum immunoglobulin IgG and IgM levels were increased in periodontal and residual cysts before surgery and significantly decreased one month after cyst enucleation.

Conclusion

The use of pathohistological and immunohistochemical analyzes proves the presence of cellular and humoral immune responses to local tissue destruction and their role in the etiopathogenesis and development of odontogenic radicular cysts, while immunological examinations confirm the presence of humoral immune response at the system level.

This confirms the importance of early detection of radicular cysts and the effectiveness of a therapeutic intervention on the capacity of the body's immune defenses.

References

1. The World Health Organization Classification of Odontogenic Lesions: A Summary of the Changes of the 2017 (4th) Edition Merva Soluk Tekkenesini, John M. Wright², Turkish Journal of Pathology 2017 (12-15)
2. A Zizzi¹, SD Aspriello², L Ferrante³, D Stramazotti, G Colella⁴, P Balercia⁵, L Lo Muzio⁶, M Piemontese², G Goteri¹, C Rubini. Oral diseases, 2012(1-8).
3. Christine Kalvelage Philipp¹ Pantelis Varvaki Rados² Manoel Sant'Ana Filho² João Jorge Diniz Barbachan² Onofre Francisco de Quadros. Distribution of CD8 and CD20 Lymphocytes in Chronic Periapical Inflammatory Lesions. Brazilian Dental Journal February, 2013(3), (182-186).
4. S. Liapatas¹, M. Nakou¹ & D. Rontogianni Inflammatory infiltrate of chronic periradicular lesions: an immunohistochemical study. International Endodontic Journal, 36, 2003 (464-471).
5. Glória Maria de Franca Andréia Ferreira do Carmo Hugo Costa Neto Ana Luiza Dias Leite de Andrare, Kenio Costa de Lima), Hébel Cavalcanti Galvao. Macrophages subpopulations in chronic periapical lesions according to clinical and morphological aspects Brazilian Oral Res. 2019 (33-47).
6. Aleksandra Lukić*, Vesna Danilović*, Renata Petrović, Lukić A Comparative immunohistochemical and quantitative analysis of inflammatory cells in symptomatic and asymptomatic chronic periapical lesions. Vojnosanitetski Pregled 2008; 65,(435-440).
7. Camila de Oliveira Rodini and Vanessa Soares Lara, Study of the expression of CD68+ macrophages and CD8+ T cells in human granulomas and periapical cysts Oral Surgery, Oral Medicine, Oral Pathology, Oral Radiology and Endodontology 2001; 92(221-227).
8. Emerson Filipe de Carvalho Nogueira, Elder Gyress Feitosa Farias Luciano Barreto Silva Alexandrino Pereira dos Santos Neto Emanuel Sávio de Souza Andrare Gerhilde Callou Sampal. Analysis of the presence and location of mast cells in periapical cysts and periapical granulomas Revista Gaúcha de Odontologia Porto Alegre, 64, 4, 2016, (376-381).
9. Bárbara Albertini. Roquim Alcantara Marina Lara de Carli Luiz Alberto Beijo Alessandro Antônio Costa Pereira, João Adolfo Costa Hanemann. Correlation between inflammatory infiltrate and

- epithelial lining in 214 cases of periapical cysts Brazilian Oral Research. Oral Pathology, 2013 Nov-Dec;27(6), (490-495).
10. Lisiane Bernardi , Fernanda Visioli ,Carolina Nor, BPharm, PhD,and Pantelis Varvaki Rados, Radicular Cyst An Update of the Biological Factors Related to Lining Epithelium Review Article.Journal of endodontics 2015(1-11).
 11. Oliver Dimitrovski, Vancho Spirov, Blagoja Dastevski, Filip Koneski. The Levels of Serum Immunoglobulin A, G and M in Oral Inflammatory Cysts before and after Surgical Therapy. Balcan journal of dental medicine-2018-0014(81-86).