

# Treatment Algorithm for Chronic Anal Fissure – A Review of Literature and it's Apply in University Clinical Center Mother Teresa – Skopje

Marjan Dzeparoski\*

*Bionika Pharmaceuticals, Skopje, Republic of Macedonia*

## Abstract

**Citation:** Dzeparoski M. Treatment Algorithm for Chronic Anal Fissure – A Review of Literature and it's Apply in University Clinical Center Mother Teresa – Skopje. *Maced J Med Sci.* 2014 Sep 15; 7(3):529-531. <http://dx.doi.org/10.3889/MJMS.1857-5773.2014.0430>.

**Key words:** fissure in ano; treatment algorithm; nifedipine and lidocaine; digital anal dilatation; botulinum toxin; lateral internal sphincterotomy.

**Correspondence:** Mr. Marjan Dzeparoski. Bionika Pharmaceuticals, Skupi 15, Skopje 1000, Republic of Macedonia. E-Mail: [marjan.dzeparoski@bionikapharm.com](mailto:marjan.dzeparoski@bionikapharm.com)

**Received:** 17-May-2014; **Revised:** 06-Jul-2014; **Accepted:** 20-Jul-2014; **Online first:** 30-Jul-2014

**Copyright:** © 2014 Dzeparoski. This is an open access article distributed under the terms of the Creative Commons Attribution License, which permits unrestricted use, distribution, and reproduction in any medium, provided the original author and source are credited.

**Competing Interests:** The authors have declared that no competing interests exist.

Chronic anal fissure is one of the most frequent anorectal disorders. Symptoms vary but typically include bright red rectal bleeding, itching and discomfort or pain during and after defecation. Treatment has undergone a transformation in recent years from surgical to medical, all approaches sharing the goal of reducing the spasm.

According to the researched treatment guidelines and the experience at the "University Clinical Center Mother Teresa" (Clinic of Gastroenterohepatology and Clinic of Abdominal Surgery) in Skopje, Macedonia, we propose the following algorithm for treatment of chronic anal fissure in three steps: from topical nifedipine + lidocaine cream (first-line) to second course of nifedipine + lidocaine cream or digital anal dilatation or botulinum toxin type A injection (second-line) to lateral internal sphincterotomy (third-line).

The proposed treatment algorithm allows patients to start with the least invasive treatment. There is no doubt that patients are willing to try less invasive modalities with the hope of avoiding surgery, with its risk of permanent disability. It should be up to the patients to decide which treatment they prefer. Although chemical sphincterotomy is less successful from lateral internal sphincterotomy, the algorithm allows feasibility, efficacy and cost-effectiveness, as well as risk reduction for surgical morbidity.

## Introduction

Chronic anal fissure (CAF) is one of the most frequent anorectal disorders [1]. It occurs mostly between the second and fourth decades of life with a lifetime incidence of 11%; frequency is approximately equal between genders [2, 3]. Typical fissures are almost universally single, and in the posterior midline. Up to 10% of typical fissures in women and 1% of those in men are found anteriorly [4]. Up to 11% of women develop the condition after childbirth [5]. The condition is also seen in children, but it is not certain that there is exact comparability to CAF in adults [6].

Symptoms vary but typically include bright red rectal bleeding, itching and discomfort or pain during and after defecation [7, 8]. The lesion may either be acute and self-limiting, or it may develop features of chronicity, including sentinel fibrous skin tag,

hypertrophic anal papilla, exposure of the anal sphincter muscle fibers and elevated edges of the lesion. Most acute fissures heal spontaneously [8]. Conservative therapy consists of increased fluid and fiber ingestion, sitz baths, stool softeners and topical analgesics [7, 8]. If the fissure doesn't heal for 6 weeks with conservative treatment, it may be considered chronic. Fissures with other underlying pathology such as Crohn's disease, HIV, tuberculosis, syphilis or anal carcinoma are excluded (secondary fissures). The pathophysiological mechanism for nonhealing remain a matter of debate [1, 9], but reduced local blood supply has been suggested [1, 10]. Chronic fissure is usually associated with internal anal sphincter spasm, the relief of which is central to promote fissure healing. Treatment has undergone a transformation in recent years from surgical to medical, all approaches sharing the goal of reducing the spasm [11-13]. Reduction of anal pressure by

sphincterotomy or by anal dilatation improves anodermal blood flow at the posterior midline, resulting to fissure healing. However, the postoperative period may be marked by surgical risks, complications, and a late incidence of incontinence that is sometimes permanent. Recently, new pharmacologic therapies have been used to create a reversible chemical reduction of sphincter pressure until the fissure has healed [14]. Searches of the Cochrane Database and PubMed MEDLINE were performed using keywords. From the reviewed literature, additional articles of particular importance published in earlier years were identified.

## Treatment algorithm

According to the researched treatment guidelines and the experience at the "University Clinical Centre Mother Teresa" (Clinic of Gastroenterohepatology and Clinic of Abdominal Surgery) in Skopje, Macedonia, we propose the following algorithm for treatment of CAF, which allows patients to start with the least invasive treatment:

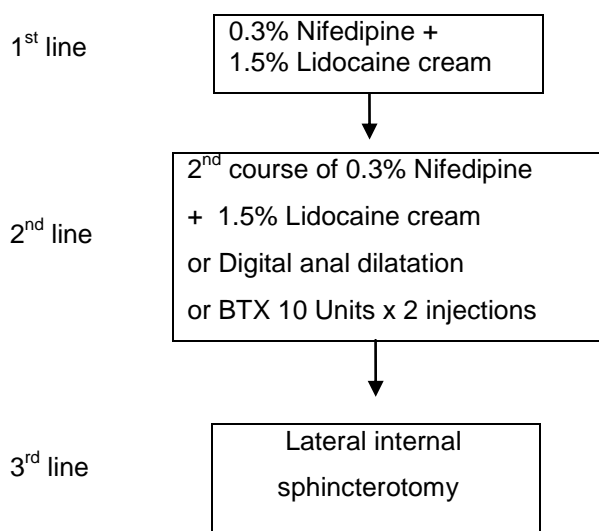


Figure 1: Treatment algorithm for chronic anal fissure

### First-line medical therapy

#### Topical nifedipine with lidocaine

In our treatment algorithm as first-line medical therapy is proposed topical nifedipine with lidocaine cream to be used twice daily for 21 days. Nifedipine is calcium channel blocker (CCB) which reduces the muscle tone by direct intracellular calcium depletion. Topical nifedipine has been associated with healing of chronic anal fissures in 65% to 95% of patients [15]. According to Cochrane reviews the healing rate is 48.9% with fewer side effects [6]; according to Perrotti headache in up to 25% of patients [14]. 0.3% nifedipine + 1.5% lidocaine cream is present since

June 2012 in Macedonia. There are no other equivalent medicines on the market.

### Second-line therapy

#### Repeat topical nifedipine with lidocaine

The optimal approach is further medical therapy with an additional course of topical nifedipine with lidocaine for the relapsing patients; these patients were treated successfully [14, 16].

#### Digital anal dilatation after failed nifedipine with lidocaine

Anal dilatation belongs to surgery procedures; is a simple procedure first described by Racamier in 1829 and for many years was the primary treatment for CAF [17]. At the "University Clinical Centre Mother Teresa" is performed as out-patient procedure with gentle manual dilatation with four fingers without anaesthesia. According to Watts et al. the success rates are 87 to 100%, with fissure recurrence from 16% of patients. Around 25% of patients experience some form of incontinence [17-18]. According to Hawley the average success rate ranges from 70-80% [19]. According to Strugnell the healing rate of CAF is 89% [20]. Some authors support a policy of gentle anal dilatation as the treatment of choice [21]. Incontinence is a concern and endo-anal ultrasonography provides an insight as to the degree of damage associated with this procedure; fragmentation is often seen [18]. Experience of the doctor and the skills and knowledge needed for digital dilatations are very important, because both force and magnitude of the stretch have to be tailored to the patient.

#### Botulinum toxin after failed nifedipine with lidocaine

Botulinum toxin (BTX) is effective in treating fissures that have failed to heal with topical agents. It blocks cholinergic transmission, injected into anal sphincter reduces resting anal pressure, which effect lasts 2-3 months [22]. According to third revision of the American Society of Colon and Rectal Surgeons (ASCRS) guidelines BTX injection allows healing in 60%-80% of fissures and higher rates than placebo with recurrence in up to 42% of cases. The most common side effects are temporary incontinence to flatus in up to 18% or stool in 5% and perianal thrombosis or hematoma [15]. According to Cochrane reviews BTX and CCBs are equivalent to glyceryl trinitrate in efficacy with fewer side effects; and they are all marginally but significantly better than placebo in healing anal fissure. Medical therapy for chronic anal fissure, currently consisting of topical glyceryl trinitrate, botulinum toxin injection or the topical calcium channel blockers nifedipine or diltiazem in

acute and chronic fissure and fissure in children may be applied with a chance of cure that is marginally better than placebo [6]. BTX can also be combined with nifedipine [23] or surgery [24]. Because of its cost and vial content of 100 U grouping of patients improves cost-effectiveness. At the Clinic of Gastroenterohepatology it is for the first time used since February 2014.

### Third-line therapy

#### *Lateral internal sphincterotomy after failed nifedipine with lidocaine*

Lateral internal sphincterotomy (LIS) is still considered gold standard in the treatment of CAF, with reported cure rates of 94-100% [6]. It carries a risk of incontinence to stool and flatus which ranges from 3% to 16% [25-27]. ASCRS also provide a strong recommendation for LIS as the therapy of choice [15]. LIS is generally contraindicated for patients with impaired continence, chronic diarrhea due to concrete chronic diseases or previous anal injuries.

### Conclusion

In the search for optimal therapy for CAF, it should be fully understood the real physiological benefit provided by sphincterotomy – chemical or surgical. Since years there are debates worldwide about first-line therapy for CAF, which still continue. The first-line treatment of CAF with topical agents has led to management algorithms that can be employed effectively [28].

There is no doubt that patients are willing to try less invasive modalities with the hope of avoiding surgery, with its risk of permanent disability. It should be up to the patients to decide which treatment they prefer.

Although chemical sphincterotomy is less successful from LIS, the algorithm allows feasibility, efficacy and cost-effectiveness, as well as risk reduction for surgical morbidity.

### References

- Sinha and Kaiser. Efficacy of management algorithm for reducing need for sphincterotomy in chronic anal fissure. *Colorectal Disease*. 2011; 14: 760-764.
- Cross KLR, Massey EJD, Fowler AL, Monson JRT. The Management of Anal Fissure: ACPGBI Position Statement. *Colorectal Disease*. 2008; 10 (Suppl. 3): 1-7.
- Lock MR, Thompson JPS. Fissure in ano: the initial management and prognosis. *Br J Surgery*. 1977; 64: 355-8.
- Etzioni DA. Current management of anal fissure. *Semin Colon Rectal Surg*. 2011; 22:2-8.
- Martin JD. Postpartum anal fissure. *Lancet*. 1953; 1: 271-273.
- Nelson RL, Thomas K, Morgan J, Jones A. Non surgical therapy for anal fissure. *Cochrane Database of Systematic Reviews* 2012, Issue 2. Art. No.: CD003431. DOI: 10.1002/14651858.CD003431.pub3.
- Madoff RD, Fleshman JW. AGA technical review on the diagnosis and care of patients with anal fissure. *Gastroenterology*. 2003;124: 235-45.
- Orsay C, Rakinic J, Perry WB et al. Practice parameters for the management of anal fissures (revised). *Dis Colon Rectum*. 2004; 47: 2003-7.
- Lund JN, Binch C, McGrath J, Sparrow RA, Scholefield JH, Topographical distribution of blood supply to the anal canal. *Br J Surg*. 1999; 86: 496-8.
- Schouten WR, Briel JW, Auwerda JJ. Relationship between anal pressure and anodermal blood flow. The vascular pathogenesis of anal fissures. *Dis Colon Rectum*. 1994; 37: 664-9.
- Gupta PJ. A review of conservative and surgical management of anal fissure. *Acta Gastroenterol Belg*. 2005;68(4):446-50.
- Haq Z, Rahman M, Chowdhury RA, Baten MA, Khatun M. Chemical sphincterotomy-first line of treatment for chronic anal fissure. *Mymensingh Med J*. 2005;14(1):88-90.
- Lund JN, Nystrom PO, Coremans G et al. An evidence-based treatment algorithm for anal fissure. *Tech Colproctol*. 2006; 10:177-180.
- Perrotti P, Bove A, Carmine A et al. Topical nifedipine with lidocaine ointment vs. active control for treatment of chronic anal fissure: results of a prospective, randomized, double-blind study. *Dis Colon Rect*. 2002; 45: 1468-75.
- Perry WB, Dykes SL, Buie WD, et al. Practice Parameters for the Management of Anal Fissures (3rd Revision). *Dis Colon Rectum*. 2010; 53: 1110-5.
- Katsinelos P, Kountouras J, Paroutoglou G, et al. Aggressive treatment of acute anal fissure with 0.5% nifedipine ointment prevents its evolution to chronicity. *World J Gastroenterol*. 2006; 12: 6203-6.
- Watts JM, Bennett RC, Goligher JC. Stretching of anal sphincters in treatment of fissure-in-ano. *Br Med J*. 1964;2(5405):342-3.
- McDonald A, Smith A, McNeill A, Finlay IG. Manual dilatation of the anus. *Br J Surg*. 1992; 79: 1381-2.
- Hawley PR. The treatment of chronic fissure-in-ano. A trial of methods. *Br J Surg*. 1969; 56: 915-8.
- Strugnell NA, Cooke SG, Lucarotti ME, Thomson WH. Controlled digital anal dilatation under total neuromuscular blockade for chronic anal fissure: a justifiable procedure. *Br J Surg*. 1999;86(5):651-5.
- Isbister WH, Prasad J. Fissure in ano. *Aust N Z J Surg*. 1995; 65:107-8.
- Jones OM, Moore JA, Brading AF, Mortensen NJ. Botulinum toxin injection inhibits myogenic tone and sympathetic nerve function in the porcine internal anal sphincter. *Colorectal Dis*. 2003; 5: 552-7.
- Tranqui P, Trottier DC, Victor C, Freeman JB. Nonsurgical treatment of chronic anal fissure: nitroglycerin and dilatation versus nifedipine and botulinum toxin. *Can J Surg*. 2006;49(1):41-5.
- Lindsey I, Jones OM, Cunningham C, Mortensen NJMcC. Chronic anal fissure. *Br J Surg*. 2004; 91: 270-279.
- Nyam DC, Pemberton JH. Long-term results of lateral internal sphincterotomy for chronic anal fissure with particular reference to incidence of fecal incontinence. *Dis Colon Rectum*. 1999;42: 1306-10.
- Garcea G, Sutton C, Mansoori S, Lloyd T, Thomas M. Results following conservative lateral sphincterotomy for the treatment of chronic anal fissures. *Colorectal Dis*. 2003; 5: 311-4.
- Hyman N. Incontinence after lateral internal sphincterotomy: a prospective study and quality of life assessment. *Dis Colon Rectum*. 2004; 47: 35-8.
- Porett TRC, Knowles CH, Lunniss PJ. Anal fissures in a district treatment algorithm for nurse-led management. *Colorect Dis*. 2002; 2002 (Suppl. 1):72.