

## DIAGNOSTIC CHALLENGE AND CONSERVATIVE MANAGEMENT OF CERVICAL PREGNANCY WITH UTERUS PRESEVATION

Anita Morarcalieva Chochkova<sup>1</sup>, Marina Nakova<sup>1</sup>, Nevenka Velickova<sup>2</sup>, Bashkim Ismaili<sup>3</sup>,  
Blaze Chochkov<sup>1</sup>

<sup>1</sup>PHI General Hospital Gevgelija, Gevgelija, North Macedonia

<sup>2</sup>Faculty of Medical Sciences, University Goce Delcev, Stip, North Macedonia

<sup>3</sup>SHGA Mother Teresa Chair, Skopje, North Macedonia

### Abstract

Cervical pregnancy is a rare form of ectopic pregnancy in which the embryo implants in the lining of the endocervical canal. Clinical criteria and ultrasound features, supplemented by rapid assay of serum human chorionic gonadotropin (hCG), make the diagnosis easier and more accurate. Depending on the time of diagnosis and the patient's condition, management can be conservative or operative

**Case:** We present a rare case of cervical pregnancy with all the diagnostic challenges for making an early diagnosis and choosing the right treatment regimen, which can be life saving for the patients and can reduce the chance of severe hemorrhage necessitating hysterectomy or blood transfusion

Early diagnosis, appropriate methotrexate regimen and combination of necessary adjuvant conservative procedures could contribute to successful treatment with preservation of the uterus and future reproductive ability.

**Keywords:** Cervical pregnancy, human chorionic gonadotropin, transvaginal ultrasound, methotrexate, vaginal bleeding

### Introduction

Cervical pregnancy is a rare form of ectopic pregnancy in which the embryo implants in the lining of the endocervical canal. It is estimated that 0.15% of all ectopic pregnancies are cervical pregnancies [1]. The incidence is 1 in 9000 pregnancies. It is more common in pregnancies achieved through assisted reproductive technologies. Nevertheless the causes are not sufficiently described. A theory is a rapid transport of the fertilized ovum into the endocervical canal before it is capable of nidation or because of an unreceptive endometrium [2].

Several risk factors associated with cervical ectopic pregnancy include use of intrauterine device, history of abortion, local endometrial injury prior cesarean delivery or uterine curettage, pelvic inflammatory disease (PID), previous ectopic pregnancy (EP) [3].

Cervical pregnancy can easily become emergency due to high vascularity of the cervix, its lack of hemostatic mechanical capacity and insusceptibility to respond to uterotonic agents. It is often accompanied by massive hemorrhage due to vaginal bleeding, because of late diagnosing.

Clinical criteria and ultrasound features, supplemented by rapid assay of serum human chorionic gonadotropin (hCG), make the diagnosis easier and more accurate. Due to rarity of cervical pregnancy there is a lack of standard guidelines for management of this condition. Management can be conservative, by using various dose regimens of methotrexate, via systemic or intraamniotic injection and Potassium Chloride (KCl) via intraamniotic injection, or operative by curettage or hysteroscopic endocervical resection with or without prior laparoscopy assisted uterine ligation or cateter embolization [4,5].

### Case Report

A 32 year old Gravida two Para one was referred to Department of Obstetrics and Gynecology in General Hospital Gevgelija due to one week late of period and two positive urinary pregnancy tests (UPT). She had an artificial abortion by dilatation and curettage one month ago. She has one live birth by cesarean section eleven years ago.

Transvaginal ultrasound (TVUS) showed no signs of pregnancy and hCG level was 218 mIU/mL. One week later hCG level was 1513 mIU/mL and the endometrium was decidual. The patient still does not complain neither on vaginal bleeding, nor abdominal pain. Nine days after the first visit the hCG levels increased to 2687 mIU/mL and TVUS showed gestational sac (GS) with length of 12mm, below the internal os of the cervix of the uterus with viable embryo with crown rump length (CRL) 4mm, which corresponds to 6.1 gestational age (g.a) (Figure 1).

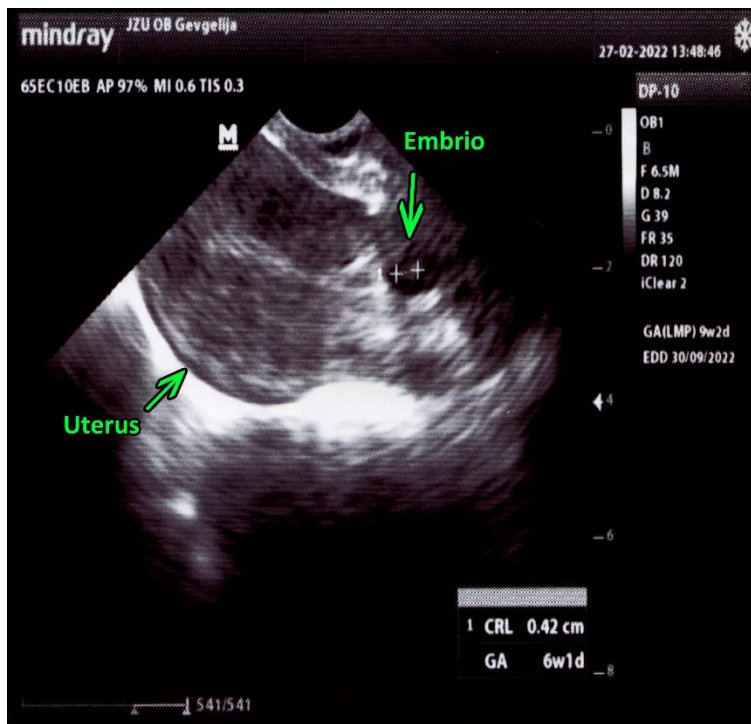
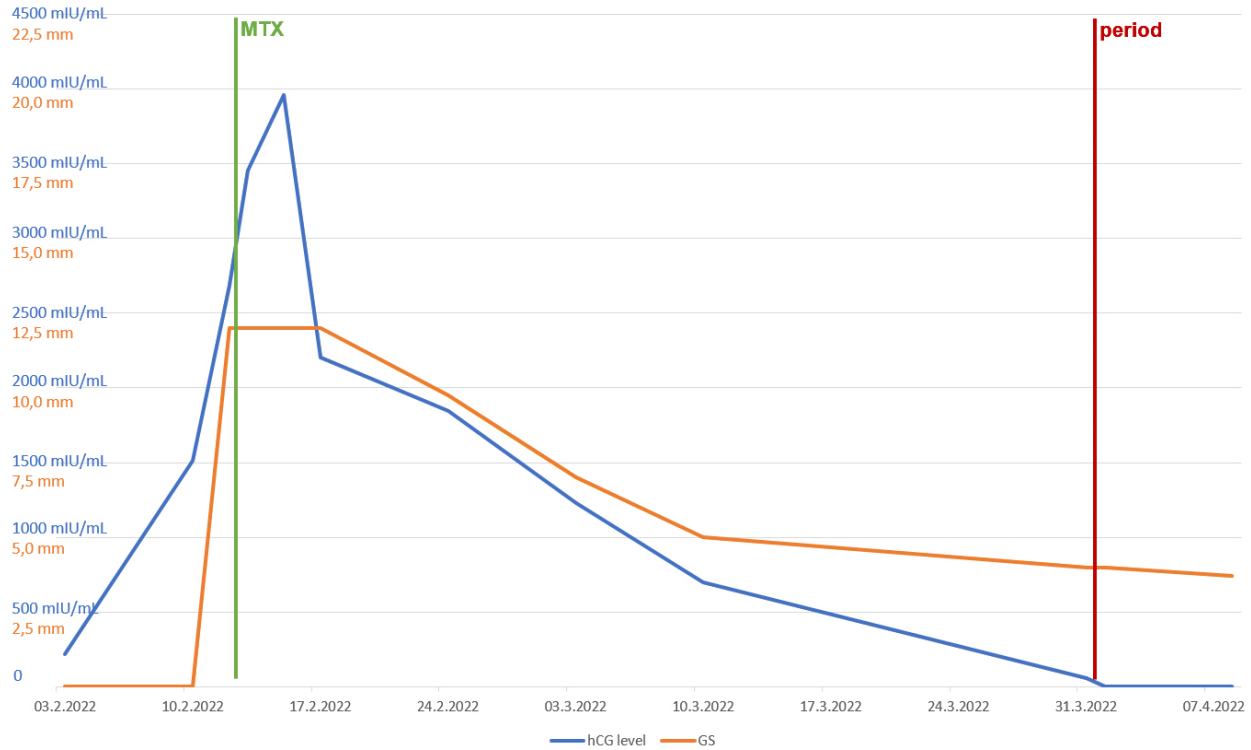

Figure 1. Cervical pregnancy

The uterine cervix was soft, thickened, with 4cm length and the external os was 1cm dilated. No vaginal bleeding was present.

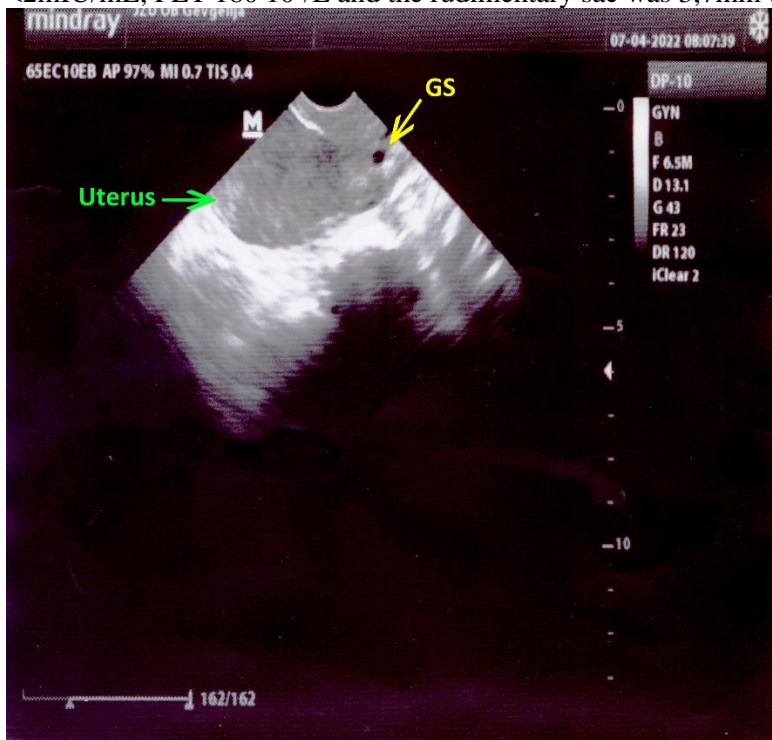The patient was put on three dose regimen of systemic methotrexate, i.e. 1.0mg/kg body weight on days 1,3,5, interspaced by leucovorin 0.1mg/kg body weight on days 2,4,6 (2,4,6). On day 2 hCG level rose on 3454 mIU/mL, on day 4 it rose 3959 mIU/mL and the completion of the regimen, the hCG level declined on 2206 mIU/mL. The platelets (PLT) were  $89 \cdot 10^9/L$  and the patient complained on scanty vaginal bleeding. A treatment with folic acid 5mg per day and corticosteroid scheme regimen (systemic dexamethasone 12mg on day 1, 8mg on day 2 and 4mg on day 3) were added. The patient was summoned for visits every week.

Three weeks after the multidose methotrexate regimen hCG level was 696 mIU/mL, PLT were  $105 \cdot 10^9/L$  and the length of the GS was 5mm with no embryo in it. Six weeks after the treatment hCG level was 57mIU/mL, PLT  $160 \cdot 10^9/L$  and the GS was rudimentary with length of 5 mm (Figure 2).



**Figure 2.** Human chorion gonadotropin (hCG) level and gestational sac (GS) length progression during conservative management of cervical pregnancy with methotrexate (MTX)

The patient resumed her normal period after 6 weeks and hCG level after the patient's period was  $<2\text{mIU/mL}$ ,  $\text{PLT } 180 \cdot 10^9/\text{L}$  and the rudimentary sac was 3,7mm (Figure 3).



**Figure 3.** Residual gestational sac (GS) after period

The patient was recommended contraceptive therapy at least for a year and was scheduled a visit six months later.

### Discussion

Cervical pregnancy is a life threatening condition and the early diagnosing can be life saving for the patient.

Proposed clinical criteria which can be of great use for diagnosis of cervical pregnancy encompasses: uterine bleeding without cramping pain following a period of amenorrhea, soft enlarged cervix, equal or longer then the fundus; product of conception confined within the endocervix; closed internal cervical os and partially opened external os . Frequent TVUS and hCG level tests are mandatory for the accuracy of the diagnosis.

The sooner the clinician make the diagnosis, the sooner the choice of therapy is made and it is very important for patient's health care [6,7].

The preservation of fertility is also preferable in patients with unfinished reproduction and the choice of treatment should be made according to cause and benefit, to reduce the chance of severe hemorrhage necessitating hysterectomy or blood transfusion and patient's wishes.

We decided to apply multidose systemic methotrexate regimen because it's an established success in the treatment of viable cervical pregnancy of 81.3% [2,4,8].

The rise of hCG levels after the initial treatment with methotrexate does not affect the success rate of the regimen. On the contrary it is expected and it should not discourage the clinician.

In most of cases no further concomitant minor operative procedure is needed. In our case the uterus returned to unpregnant status, 6 weeks after the methotrexate regimen.

The regression of the GS after the methotrexate regimen was related to the decline of the hCG levels. Nevertheless, after the establishment of the normal period pattern, there was still a rudimentary GS on TVUS examination.

### Conclusion

In cases when the patient is stable and there is no vaginal bleeding, no attempt should be made to remove the asymptomatic GS, because manipulation of the cervix may cause bleeding fraught with serious consequences.

Methotrexate related side effect, thrombocytopenia, was successfully managed with corticosteroid regimen. In conclusion, early diagnosis, appropriate methotrexate regimen and combination of necessary adjuvant conservative procedures could contribute to successful treatment with preservation of the uterus and future reproductive ability.

### References

1. Singh S. Diagnosis and management of cervical ectopic pregnancy. *J Hum Reprod Sci.* 2013 Oct;6(4):273-6. doi: 10.4103/0974-1208.126312. PMID: 24672169; PMCID: PMC3963313.
2. Антоvsка В, Стојовски М. Гинекологија. 2016. Култура-Скопје.
3. Pandja M. A rare case of cervcal pregnancy. *Indian Journal of Obstetrics and Gynecology Research.* 2014. Available from: URL: <https://orcid.org/0000-0003-4665-3069>
4. Murji A, Garbedian K, Thomas J, Cruickshank B. Conservative Management of Cervical Ectopic Pregnancy. *J Obstet Gynaecol Can* 2015;37(11):1016–1020.
5. Bermudes Musiello, R., Luiz Fava, J., Camano, L., & de Souza, E. (2020). Cervical Pregnancy Diagnosis and Management. *IntechOpen.* doi: 10.5772/intechopen.90160.
6. Samal SK, Rathod S. Cervical ectopic pregnancy. *J Nat Sci Biol Med.* 2015 Jan-Jun;6(1):257-60. doi: 10.4103/0976-9668.149221. PMID: 25810679; PMCID: PMC4367055.
7. Évora F, Hundarova K, Águas F, et al. Cervical Ectopic Pregnancy: A Multidisciplinary Approach. (2021) *Cureus* 13(10): e19113. doi:10.7759/cureus.19113.

8. Berek JS. Berek & Novak's Gynecology 16<sup>th</sup> ed. 2019. Wolters Kluwe.r