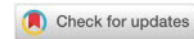


MANAGING THE MOST COMMON COMPLICATIONS OF RADIATION THERAPY IN PATIENTS WITH HEAD AND NECK CANCER

Sonja Rogoleva Gjurovski^{1*}

¹Faculty of Medical Sciences, "Goce Delcev" University, Stip, Republic of North Macedonia
e-mail: sonja.rogoleva@ugd.edu.mk



Abstract: Radiation therapy is widely used approach in treatment of head and neck cancer, unfortunately it leaves consequences that are influencing the patients' life in a negative way. During and after the treatment with ionizing irradiation it affects not only the malignant area that is being treated, but also the surrounding tissues and organs that are located near the region that is targeted (oral mucosa, jaw bones, teeth, salivary glands, surrounding muscles and the temporomandibular joints), leaving changes in their structure and functions. Many of the patients that are treated, have not been prepared optimally for the radiation treatment, what also affects the post operative condition of their tissues and organs that are located nearby to the radiation treated area. The aim of this study was to define the most common postradiation complications in patients with head and neck cancer and to evaluate the efficiency of the solutions that are used to manage them.

For this study were analyzed in details 37 published articles on the studied topic, the research was done online using the data bases NCBI, Cochrane Library, Medline, PubMed and Webmd. The inclusion criteria were: studies made in vivo; studies written in English; case reports on head and neck cancer patients; surveys on patients after radiation therapy; studies on patients with intraoral complications from after radiation therapy.

Results showed that radiation induced complications in the head and neck cancer patients can be classified in three groups as early, intermediate and late changes. The most common changes were found in the tissues (mucosa, skin, subcutaneous connective tissues, salivary glands, the bone tissues and the teeth), resulting with: hyposalivation (xerostomia), mucositis, opportunistic infections, radiation caries, dysphagia, altered taste and difficulties with the chewing and swallowing. Many studies have shown that the percent of damage on the oral mucosa is strongly related to the radiation dose and the type of ionizing irradiation that patients are being treated with. Treatment consists of application of lubricants; usage of substitutes for saliva; and stimulants for the saliva production, with preparations like pilocarpine and cevimeline, and electro stimulation. The loss of the taste after the treatment can be partial or total. Mostly affected are the sour and bitter tastes, rarely the sweet and the salty taste, and very rare is total loss on all of the flavors. Fortunately in most of the studied cases has been show that the changes in the taste were reversible after a period of time, in some cases a few months and in others it can happen even up to a few years until it reaches total recovery.

It is crucial to implement more solutions and to find new ways to manage the complications that follow after the irradiation, so the quality of the life in these patients can be spared in any possible way. Using the new approaches such as IMRT and VMAT on these patients, could also improve their condition after the treatment, and reduced dosage of the irradiation also could be tested and implemented if it is possible.

Key words: Postradiation complications, xerostomia, head and neck cancer treatment, radiation induced hyposalivation, oportunistic infections.

INTRODUCTION

Radiotherapy is considered to be a therapeutic approach that takes important place in the whole treatment of malign neoplasm in patients with head and neck cancer. In many cases it is combined with surgery or chemotherapy, and sometimes it can be used also as palliative method to prevent further spreading of the malign cells [1,2].

It is very common for negative consequences to occur after a radiation treatment in patients, due to its destructive nature [2]. During and after the treatment with ionizing irradiation, when the beams are applied on the patients, they affect not only the malignant area that is being treated, but also the surrounding tissues and organs that are located near the region that is targeted (oral mucosa, jaw bones, teeth, salivary glands, surrounding muscles and the temporomandibular joints) what causes corresponding negative reactions of these structures [3,4]. Therefore many of the patients that are treated, have not been prepared optimally for the radiation treatment, what also affects the post operative condition of their

*Corresponding author: sonja.rogoleva@ugd.edu.mk



tissues and organs that are located nearby to the radiation treated area [5,6].

Radiation induced complications in the head and neck cancer patients can be classified in three groups as early, intermediate and late changes. The most common complications after radiation therapy are the following: hyposalivation (xerostomia), mucositis, opportunistic infections, radiation caries, dysphagia, altered taste and difficulties with the chewing and swallowing [7,8]. Some of these symptoms are reversible, such as mucositis and taste loss, and they usually disappear after a few months of the last radiation treatment. However, the salivary glands hypofunction and the saliva volume reduction are irreversible consequences [9,10].

These consequences significantly affect the quality of the patients' life, what causes chronic dissatisfaction. The main reason that causes all of these symptoms to emerge is the xerostomia and reduced saliva production due to the damage of the salivary glands tissue and cells, which is considered to be almost inevitable collateral inconvenience caused by the radiation treatment [11,12].

Furthermore in some patients with general altered health condition, there can occur even more serious symptoms during and after the radiation treatment, that unfortunately can remain for many years after the treatment or even as a lifelong consequences, such as osteoradionecrosis, radiation caries, candidiasis and trismus [13]. Because of this, nowadays many of the experts in this area are working on finding a solutions for the treated patients to cope with the difficulties in their everyday life [14,15].

Aim : The aim of this study was to define the most common post radiation complications in patients with head and neck cancer and to evaluate the efficiency of the solutions and treatments that are used to manage them.

MATERIAL AND METHODS

Research strategy

We analyzed total number of 76 studies, so this survey is formed on base of narrative review on articles that are published in English, which reports results that are related to the post radiation treatment consequences and their managing in head and neck cancer patients.

The following research was made online with using the data bases such as: NCBI, Cochrane Library, Medline, PubMed and Webmd. For the search were used these keywords: radiotherapy, post-radiation complications, xerostomia, head and neck cancer treatment, radiation induced hyposalivation. In this analysis were included systematic reviews, case studies, qualitative studies and clinical surveys, that were published in the last 15 years. From the total number of 58 found studies with the first research by using the key words, 37 of them were selected for detail review and analysis that met the needed criteria for this study.

Inclusion and exclusion criteria

The articles that were used for evaluation to create this study were selected by these inclusion criteria: studies made in vivo; studies written in English; case reports on head and neck cancer patients; surveys on patients after radiation therapy; studies on patients with intraoral complications from after radiation therapy.

The exclusion criteria for this evaluation were the following: studies on patients with systematic diseases and cancer on head and neck; studies on patients with hyposalivation induced by other factors not only radiation therapy; surveys on patients with head and neck cancer on radiotherapy combined with chemotherapy; case reports and studies that have involved experiments done on animals; studies on patients treated with radiotherapy with low hygiene standards and poor oral health condition. The selected articles that met the criteria were analyzed in details and the gathered data was further processed.

EVALUATION AND RESULTS

In studies evaluating the clinical outcomes of the radiation therapy in patients with head and neck cancer, the consequences after the irradiation were found significantly in the region of head and neck. There were found changes in all of the tissues (mucosa, skin, subcutaneous connective tissues, salivary glands, the bone tissues and the teeth). The most common acute changes found in the evaluated patients, were mostly found in the oral mucosa, such as erythema [16], ulcerations covered with pseudomembranes; alteration on the salivary gland function resulting in hyposalivation, changes in the components and concentration of the saliva ingredients [17]; decreased function of the taste buds resulting in changed taste of the food; and formations found on the skin like erythema and desquamations [17].

In order of their appearance of the radiation – induced complications in the head and neck cancer patients, the consequences can be classified in three groups as early, intermediate and late changes. In the first group of early appeared changes, were found the complications related to: the oral mucosa, the salivary glands and the taste sensors. The second group (intermediate changes) consists also of complications that interfere with the salivary glands function and the taste regulation. The late changes are considered to have affect on: the salivary glands, the teeth and their supportive system, the bone tissues and the joints and connective tissues [18].

These changes happen after many months of the last therapy, or even years. Besides the fact that many preventive protocols have been applied before and during the radiation treatment in the patients, unfortunately many of these complications are very hard to be managed and to be prevented of happening [19].

Many studies have shown that the percent of damage on the oral mucosa is strongly related to the radiation dose and the type of ionizing irradiation that patients are being treated with, what is caused by mitotic death of the epithelial cells in oral mucosa. In the beginning the first reactions of the radiation therapy in patients has been shown that causes latent discomfort during eating and drinking, also followed by small difficulties in the chewing, speech and the swallowing. In the patients with the worst complications outcome sometimes it was necessary to apply nasogastric feeding [20].

In other studies was found that the spread of the damage in the salivary glands tissue is significantly correlated to the volume of irradiation that is applied on that region. Not only the salivary glands function is affected by the irradiation, but it was found that the therapy also makes influence on the saliva content. It changes the color and the concentration of the components inside, the viscosity is turning into more viscous liquid that is white or pale yellow [21].

To manage the xerostomia and the negative consequences that follow, in the past years many strategies and solutions were suggested, mostly focusing on increase of the salivary flow rate. The usual suggestions that are given to every treated patient were: to avoid dehydration by drinking enough water during the day; to make the air in the room more humid; to avoid irritation with crunchy food [22].

The other treatment options for this condition included: use of lubricants; usage of substitutes for saliva; and stimulants for the saliva production in the glands. The most used preparations for this aim were pilocarpine and cevimeline. The efficiency of these solutions was found that is directly related to the volume of the remained healthy and functional tissue from the salivary glands. The pilocarpine most often has been administrated in doses of 5 mg three times in a day during a period of at least 3 months. Cevimeline was usually administrated in 30 mg doses 3 times a day. However the usage of these preparations has shown unwanted side effects which was expected, such as: vasodilatations, diarrhea, emesis, sweating, in some patients even bronchoconstriction, bradycardia, ama rarely vision problems and hypotension [23,24].

Other often used sialogogues are anethole trithione that has main function in increasing the salivary flow rate in patients with xerostomia. However more studies are needed to confirm the efficiency of this solution [25]. Also for dry mouth treatment were used intraoral topical agents, that are more often used like chewing gums, topical spray of malic acid, topical oxygenated glycerol tri-ester, were found to be more effective in treating xerostomia in patients with head and neck cancer. The chewing gum is good alternative and also healthy way that was confirmed that increases the flow rate and saliva volume production [26,27].

For mouthwash were used substitutes like Biotene, Oral Balance or Zendium, that have shown very good results in keeping the oral mucosa moist and to prevent debris acumulation in treating xerostomia [28]. Many other oral substitutes for saliva are now available on the market, based on different polymers like carboxymethylcellulose, polyacrylic acid and xanthan gum. It was found that the mucin-based preparations may be better accepted from the patient in comparison to carboxymethylcellulose formulations. Some patients were treated with using water or ice particles to moisten the oral cavity, however the water has shown to be not very effective lubricant and substitute for saliva reduction [29,30].

To prevent the microbes from spreading in the oral cavity in radiotherapy treated patients with hyposalivation, were used saliva substitutes and mouthwashes that were had antimicrobial components in their structure. That way has been found that is also successful the prevention of mucosal and gingival inflammation. Mostly used were the products casein phosphopeptides and casein derivatives complexed with calcium phosphate [31,32].

In spite of the fact that the saliva substitutes are used in xerostomia treatment, they don't have influence on the salivary glands function and the saliva secretion, but they only have function in being a liquid that can replace in some ways the saliva, to offer humidity and to prevent friction of the soft tissues in the oral cavity. The oral substitutes that were used in treating xerostomia in patients, were in

different formulations, like gel, liquid or dissolving tablets. However, when the patients' experiences were evaluated, it has shown that the most efficient and preferred formulation of oral substitutes for xerostomia regulation, was the gel formulation [33].

Other alternative options for xerostomia treatment were tried on some patients, such as appliances for intraoral electrostimulation, that have shown good results and satisfaction in the treated patients, with increasing the volume of the secreted saliva. Of intraoral appliances most often used were the saliva stimulation device Saliwell Crown and electrostimulating device GenNarino, that has proven very satisfying results for the xerostomia treatment [34].

The acupuncture in some studies was also suggested as an alternative treatment option, however it still has not been evaluated enough and needs future studies to confirm its' efficiency [34].

In most of the treated patients with radiotherapy, after the treatment were found intraoral infections, mostly candidiasis, and Gram-negative bacilli such as *Streptococcus mutans*, *Lactobacillus* species, and *Candida* species [34]. These bacteria and their toxins are considered that might be the second reason for radiation mucositis development in the late stages, when the first reason is still the influence of the irradiation [35].

Candidiasis was found to be developed right after the radiation therapy or after a few days. For candidiasis treatment were used many topical and systemic anti fungal agents, like Nystatin rinses which was mostly used, in formulation as suspension or cream and ointment. Other also very often used topical antifungal agents were amphotericin B, clotrimazole, ketoconazole and chlorhexidine that gave satisfying results [35].

Other studies have shown also that often consequence after the radiation treatment in these patients were the changes on the taste. It can be partial or total loss. Mostly affected were the sour and bitter tastes, rarely the sweet and the salty taste, and very rare was total loss on all of the flavors. Fortunately in most of the studied cases has been show that the changes in the taste were reversible after a period of time, in some cases a few months and in others the total repair could happen even up to a few years until it reaches total recovery. The alteration of the taste in radiation treated patients with head and neck cancer, does not only happen due to the toxic influence of the irradiation on the taste buds, but it also is a result to the reduced saliva flow rate, because the saliva is necessary to dissolve the gustatory stimulants and to transport them, so they can be received from the gustatory receptors. The alterations and the taste loss fortunately has been found that are reversible changes in most of the cases, so it often had come back to normal after one year of the last treatment with radiation therapy, and in some cases it has taken more time, which depends on the dose of radiation that was applied [36].

Intensity-modulated radiation therapy (IMRT) also was used in many patients with head and neck cancer, as an improved type of radiotherapy, which is considered to be highly precise method. That is because it is using computer-controlled linear accelerators for applying precise radiation doses to the targeted places where the tissues are affected with the tumor cells. This technique allowed the doses of radiation to be more precisely applied on the treated tumor, by regulating the intensity of the radiation in multiple small beams parts. This method when used in radiation treatment has also helped in patients the doses of the radiation to be focused precisely on the tumor, sparing the surrounding healthy tissues of the negative effect that would follow after the exposure on radiation [37].

CONCLUSION

From this study it can be concluded that the post radiation changes and consequences are real problem and they affect the life of the treated patients, making it difficult to function every day. It is crucial to implement more solutions and to find new ways to manage the complications that follow after the irradiation, so the quality of the life in these patients can be spared in any possible way. It could also be considered for a new alternative fractionation schedules to be applied, such as hyperfractionation and accelerated fractionation, so the side effects can be lowered during and after the radiation therapy.

Using the new approaches such as IMRT and VMAT on these patients, could also improve their condition after the treatment, and reduced dosage of the irradiation also could be tested and implemented if it is possible.

CONFLICT OF INTEREST: None

REFERENCES

1. Wei Cheong N. & Wen_Lin C. Rahman Roslan R. (2007). Managing complications of radiation therapy in head and neck cancer patients: Part V. Management of mucositis. *Singapore dental journal*. 28. 1-3.
2. Konings AWT, Vissink A, Coppes RP (2002). Comments on extended- term effects of head and neck irradiation in a rodent (Eur J) *Cancer* 37:1938-1945, 2001). *Eur J Cancer* 38:851-852.
3. Eisbruch A, Lyden T, Bradford CR, Dawson LA, Haxer MJ, Miller AE, et al. (2002). Objective assessment of swallowing dysfunction and aspiration after radiation concurrent with chemotherapy for head-and-neck cancer. *Int J Radiat Oncol Biol Phys* 53:23-28.
4. Acauan MD, Figueiredo MA, Cherubini K, Gomes AP, Salum FG. Radiotherapy-induced salivary dysfunction: Structural changes, pathogenetic mechanisms and therapies. *Arch Oral Biol*. 2015;60:1802–10.
5. Vissink A, Mitchell JB, Baum BJ, et al. Clinical management of salivary gland hypofunction and xerostomia in head-and-neck cancer patients: successes and barriers. *Int J Radiat Oncol Biol Phys*. 2010;78(4):983-991
6. Kaae JK, Stenfeldt L, Eriksen JG. Xerostomia after Radiotherapy for Oral and Oropharyngeal Cancer: Increasing Salivary Flow with Tasteless Sugar-free Chewing Gum. *Front Oncol*. 2016;6:111. Published 2016
7. Bhide SA, Nutting CM. Advances in radiotherapy for head and neck cancer. *Oral Oncol*. 2010;46(6).
8. Cox JD, Stetz J, Pajak TF. Toxicity criteria of the radiation therapy oncology group (RTOG) and the European Organization for Research and Treatment of cancer (EORTC). *Int J Radiat Oncol Biol Phys*. 1995
9. Hunter KU, Schipper M, Feng FY, et al. Toxicities affecting quality of life after chemo-IMRT of oropharyngeal cancer: prospective study of patient-reported, observer-rated, and objective outcomes. *Int J Radiat Oncol Biol Phys*. 2013;85(4):935-940.
10. Bird T, De Felice F, Michaelidou A. Outcomes of intensitymodulated radiotherapy as primary treatment for oropharyngeal squamous cell carcinoma - a European singleinstitution analysis. *Clin Otolaryngol*. 2017
11. McBride SM, Parambi RJ, Jang JW, Goldsmith T. Intensity-modulated versus conventional radiation therapy for oropharyngeal carcinoma: long-term dysphagia and tumor control outcomes. *Head Neck*. 2014
12. Mortensen HR, Jensen K, Aksglaede K, Behrens M, Grau C. Late dysphagia after IMRT for head and neck cancer and correlation with dose-volume parameters. *Radiother Oncol*. 2013;107(3): 288-294.
13. Goepfert RP, Lewin JS, Barrow MP, et al. Predicting two-year longitudinal MD Anderson dysphagia inventory outcomes after intensity modulated radiotherapy for locoregionally advanced oropharyngeal carcinoma. *Laryngoscope*. 2017;127(4):842-848.
14. Hutcheson KA, Nurgalieva Z, Zhao H, et al. Two-year prevalence of dysphagia and related outcomes in head and neck cancer survivors: an updated SEER-Medicare analysis. *Head Neck*. 2018; 41(2):479-487.
15. Roets E, Tukanova K, Govarts A, Specenier P. Quality of life in oropharyngeal cancer: a structured review of the literature. *Support Care Cancer*. 2018;26(8):2511-2518.
16. Dirix P, Nuyts S, Vander Poorten V, Delaere P, Van den Bogaert W. The influence of xerostomia after radiotherapy on quality of life: results of a questionnaire in head and neck cancer. *Support Care Cancer* 2008.
17. Kramer B, Wenzel A, Boerger M, et al. Long-term quality of life and nutritional status of patients with head and neck cancer. *Nutr Cancer*. 2018;71(3):1-14.
18. Al-Mamgani A, Mehilal R, van Rooij PH, Tans L, Sewnaik A, Levendag PC. Toxicity, quality of life, and functional outcomes of 176 hypopharyngeal cancer patients treated by (chemo)radiation: the impact of treatment modality and radiation technique. *Laryngoscope*. 2012;122(8):1789-1795.
19. Van Daele DJ, Langmore SE, Krisciunas GP, et al. The impact of time after radiation treatment on dysphagia in patients with head and neck cancer enrolled in a swallowing therapy program. *Head Neck*. 2019
20. Kirsh E, Naunheim M, Holman A, Kammer R, Varvares M. Patient-reported versus physiologic swallowing outcomes in patients with head and neck cancer after chemoradiation. *Laryngoscope*. 2018
21. Al-Mamgani A, van Rooij P, Verduijn GM. The impact of treatment modality and radiation technique on outcomes and toxicity of patients with locally advanced oropharyngeal cancer. *Laryngoscope*. 2013
22. Motz K, Herbert RJ, Fakhry C, et al. Short- and long-term outcomes of oropharyngeal cancer care in the elderly. *Laryngoscope*. 2018;128(9):2084-2093.
23. Patterson JM, McColl E, Carding PN, Wilson JA. Swallowing beyond six years post (chemo) radiotherapy for head and neck cancer; a cohort study. *Oral Oncol*. 2018;83:53-58.
24. Bourhis J, Sire C, Graff P, et al. Concomitant chemoradiotherapy versus acceleration of radiotherapy with or without concomitant chemotherapy in locally advanced head and neck carcinoma (GORTEC 99-02): an open-label phase 3 randomised trial. *Lancet Oncol*. 2012;13(2):145-153.
25. Abel E, Silander E, Nyman J, et al. Impact on quality of life of IMRT versus 3-D conformal radiation therapy in head and neck cancer patients: a case control study. *Adv Radiat Oncol*. 2017;2(3): 346-353.
26. O'Neill M, Heron DE, Flickinger JC, Smith R. Posttreatment quality-of-life assessment in patients with head and neck cancer treated with intensity-modulated radiation therapy. *Am J Clin Oncol Cancer*. 2011
27. Graff P, Lapeyre M, Desandes E, et al. Impact of intensitymodulated radiotherapy on health-related quality of life for head and neck cancer patients: matched-pair comparison with conventional radiotherapy. *Int J Radiat Oncol Biol Phys*. 2007;67(5)
28. Taibi R, Lleshi A, Barzan L, et al. Head and neck cancer survivors patients and late effects related to oncologic treatment: update of literature. *Eur Rev Med Pharmacol Sci*. 2014;18(10):1473-1481.
29. Maurer J, Hipp M, Schafer C, Kolbl O. Dysphagia impact on quality of life after radio(chemo)therapy of head and neck cancer. *Strahlenther Onkol*. 2011;187(11):744-749.
30. Staar S, Rudat V, Stuetzer H, et al. Intensified hyperfractionated accelerated radiotherapy limits the additional benefit of simultaneous chemotherapy--results of a multicentric randomized German trial in advanced head-and-neck cancer. *Int J Radiat Oncol Biol Phys*. 2001;50(5):1161-1171.
31. Zeng L, Tian YM, Sun XM, et al. Late toxicities after intensitymodulated radiotherapy for nasopharyngeal carcinoma: patient and treatment-related risk factors. *Br J Cancer*. 2014;110(1):49-54.

32. Machtay M, Moughan J, Farach A, et al. Hypopharyngeal dose is associated with severe late toxicity in locally advanced head-and-neck cancer: an RTOG analysis. *Int J Radiat Oncol Biol Phys*. 2012;84(4):983-989.
33. Likhterov I, Ru M, Ganz C, et al. Objective and subjective hyposalivation after treatment for head and neck cancer: long-term outcomes. *Laryngoscope*. 2018;128(12):2732-2739.
34. LENT SOMA scales for all anatomic sites. *Int J Radiat Oncol Biol Phys*. 1995;31(5):1049-1091.
35. Caudell JJ, Schaner PE, Meredith RF, et al. Factors associated with long-term dysphagia after definitive radiotherapy for locally advanced head-and-neck cancer. *Int J Radiat Oncol Biol Phys*. 2009;73(2):410-415.
36. Gujral DM, Miah AB, Bodla S, et al. Final long-term results of a phase I/II study of dose-escalated intensity-modulated radiotherapy for locally advanced laryngo-hypopharyngeal cancers. *Oral Oncol*. 2014;50(11)
37. Taberna M, Rullan AJ, Hierro C, et al. Late toxicity after radical treatment for locally advanced head and neck cancer. *Oral Oncol*. 2015;51(8):795-799.