

MJA

Macedonian Journal of Anaesthesia

A Journal on Anaesthesiology, Resuscitation, Analgesia and Critical Care

Vol. 4 No 4, December 2020

Journal of the Macedonian Society of Anaesthesiologists
and Macedonian Society of Critical Care Medicine

Publisher:

Department of Anaesthesia and Reanimation, Faculty of Medicine,
"Ss. Cyril and Methodius" University, Skopje, R.N. Macedonia

- It is necessary to include the Health Insurance Fund of Republic of North Macedonia as a financier of the screening programs in order to guarantee the financial sustainability.
- More efficient activities are necessary to strengthen the awareness of the population about the need for colorectal examination, as well as education for proper use and interpretation of the FOB test.

Specific Recommendations

- It is also necessary to define indicators in accordance to the European CRC screening guidelines.
- A comprehensive approach should be applied in order the screening program to reach the entire population at risk.
- The positive tests, should be followed by a mandatory colonoscopy.
- A separate and continuous analysis is needed to compare the screening results and the endoscopic evaluations.

References

1. Council of the European Union. Council Recommendation of 2 December 2003 on cancer screening (2003/878/EC), Off J Eur Union no. L 327; 2003. pp. 34-38.
2. Brenner H et al. Protection from right-and left-sided colorectal neoplasms after colonoscopy: population-based study, J.Natl. Cancer Inst., vol. 102, no. 2; 2010. pp. 89-95.
3. Hofstad B. Colon Polyps: Prevalence Rates, Incidence Rates, and Growth Rates, in Colonoscopy: Principles and Practice, 1 edn, Waye J, Rex DK, & Williams CB (eds.), Blackwell Publishing Ltd., Oxford; 2003. pp. 358-376.
4. Jemal A et al. Cancer statistics, 2008, CA Cancer J.Clin., vol. 58, no. 2; 2008. pp. 71-96.
5. Whiting P et al. The development of QUADAS: a tool for the quality assessment of studies of diagnostic accuracy included in systematic reviews, BMC.Med.Res.Methodol., vol. 3; 2003. p. 25.
6. Council of the European Union. Council conclusions on reducing the burden of cancer. 2876th Employment, Social Policy, Health and Consumer Affairs Council meeting. Luxembourg, 9-10 June 2008 Press Office of the Council of the European Union; 10 June 2008, Brussels, Belgium, Report no. 10414/08 (Presse 166).
7. European Commission. European guidelines for quality assurance in cervical cancer screening – Secondbedition. Arbyn M, Anttila A, Jordan J, et al. (eds.) Office for Official Publications of the European Communities, Luxembourg; 2008.
8. Europa Colon is the European colorectal cancer community. Available from: <http://europa-colon.com/> Accessed 10 January 2013.
9. AitOuakrim Driss et al. Trends in colorectal cancer mortality in Europe: retrospective analysis of the WHO mortality database *BMJ* 2015; 351:h4970.
10. Navarro M, Ferrandez A, Lanás A. Colorectal cancer population screening programs worldwide in 2016: An update. *World J Gastroenterol.* May 28, 2017; 23(20): 3632-3642. doi: 10.3748/wjg.v23.i20.3632.
11. EC Europa Eurostat Statistics Explained. Cancer statistics-specific cancers. Available from: <https://ec.europa.eu/eurostat/statistics-explained/pdfscache/39738.pdf>. Accessed May 2020.
12. GLOBOCAN estimates of incidence and mortality worldwide for 36 cancers in 185 countries. *CA Cancer J Clin*, in press. The online GLOBOCAN 2018 database is accessible at <http://gco.iarc.fr/>, as part of IARC's Global Cancer Observatory.

A RARE CASE OF MENINGEAL HEMANGIOPERICYTOMA ACCOMPANIED WITH INTRAOPERATIVE BLOOD LOSS

Lazarova A¹, Gligorievski A¹, Nevcev I¹

¹ University Clinic for Surgery "Ss. Naum Ohridski", Department of Radiology, Skopje, R. Macedonia, Str.11-ūū Okūomvpu 53

Introduction: Meningeal hemangiopericytomas are rare tumors of the meninges which are aggressive and pathohistologically belong to solitary fibrous tumors of the dura. The tumor might be found throughout the entire CNS, usually superficially and closely related to the meninges. Important characteristic is that they have a strong tendency for local recurrence and also are associated with extra cranial metastasis.

Case Report: In this study, we present a case of 71 years old man primarily asymptomatic, who presented with sudden symptoms of headache, dizziness, and loss of consciousness. He was immediately transferred to the department of urgent medicine where primary computer tomography (CT) scan was done. For a certain diagnosis to be established magnetic resonance imaging (MRI) was secondly done.

MRI showed extra axial, solitary, supratentorial masses, lobulated in contour, highly vascular with a tendency to erode the nearby parietal bone. In T1 and T2 waited images it was isointense to grey matter. In Diffusion waited images (DWI) this tumor showed intermediate restricted diffusion (less than meningioma). After intravenous application of contrast medium – gadolinium, it shows vivid enhancement, heterogeneous, and a dural tail sign was seen.

Total surgical excision was done with the complication of intraoperative bleeding, and the diagnosis of meningeal hemangiopericytoma obtained on MRI was pathohistological confirmed.

Conclusion: Meningeal hemangiopericytoma (HPC) are aggressive lesions with a tendency for extracranial metastasis, also this tumor has a tendency for high rates of recurrence, and is characterized with local aggressive behavior.

On both CT and MRI modality distinguishing a hemangiopericytoma from a meningioma, sometimes can be difficult because of their similar appearance, but is important the interpretation to be adequate especially with MRI because of the need for pre-operative catheter embolization in order to prevent the intraoperative blood loss, and also adjuvant radiotherapy might be required to reduce the risk of local recurrence and distant metastasis

Key Words: *blood loss, meningeal hemangiopericytoma, MRI, surgery treatment.*

Introduction

Intracranial hemangiopericytomas (HPC) are rare vascular tumors as this tumors account for less than 1% of all intracranial tumors and pathohistologically belong to solitary fibrous tumors of the dura. HPC is more commonly located supratentorial and the younger age group has predilection for this tumor. The tumor might be found throughout the entire CNS, usually superficially and closely related to the meninges. Important characteristic is that they have a strong tendency for local recurrence and also are associated to extracranial metastasis (1,2).

Case Report

We present a case of 71 years old man primarily asymptomatic, who was presented with sudden symptoms of headache, dizziness, and loss of consciousness. He was immediately transferred to the department of urgent medicine where primary computer tomography (CT) scan was done.

The report from the CT was hyperdense mass localized in the left parietal region next to the parietal bone with lysis of the bone; there was no calcification in that mass, and its dimension was 5 cm in diameter. For more precision diagnosis magnetic resonance imaging (MRI) was secondly done.

MRI shows extra axial, solitary, supratentorial masses, lobulated in contour, highly vascular with a tendency to erode the nearby parietal bone. In T1 and T2 waited images it was isointense to grey matter. In Diffusion waited images (DWI) this tumor shows intermediate restricted diffusion (less than meningioma). After intravenous application of contrast medium – gadolinium, it showed vivid enhancement, heterogeneous, and a dural tail sign was seen.

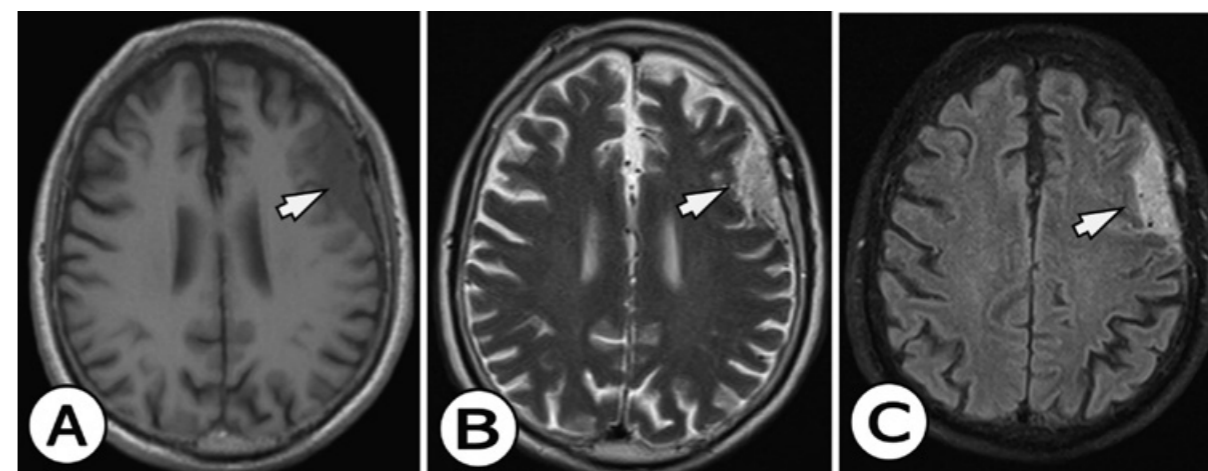
MRI as a method of establishing the diagnosis was superior to the CT scan due to the multiplanar projection, great resolution and the possibility of analyzing tumor presentation after intravenous contrast administration.

Although the size of the tumor, its lobulated contour, MRI signs of high vascularized lesion was enough to establish the suspicion of non-clear meningeal lesion, therefore in differential diagnosis option of meningeal hemangiopericytoma was taken in matter.

Total surgical excision was done with the complication of intraoperative bleeding, and the diagnosis of meningeal hemangiopericytoma obtained on MRI was pathohistologically confirmed.

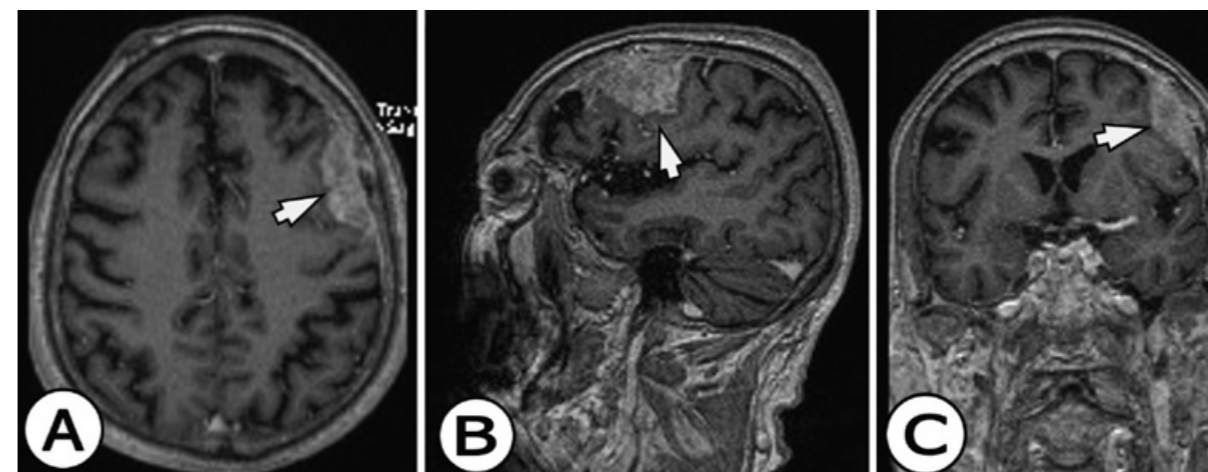
Unfortunately the option for preoperative embolization of small vessels in order to prevent intraoperative blood loss was not considered as necessary, but this case is surely giving a direction for the neurosurgeon to have that fact in mind in the cases when MRI has certainty in establishing the diagnosis.

Figures 1 A, 1 B, and 1 C.



MRI images of 71 years old man who was presented with sudden symptoms of headache, dizziness, and loss of consciousness. A) An unenhanced MRI T1 WI shows TU slightly hypointense to gray matter (white arrows). B) An unenhanced MRI T2 WI shows TU was slightly hyperintense to gray matter (white arrows). C) An unenhanced MRI T2 WI-FLAIR shows TU hyperintense to gray matter (white arrows).

Figures 2 A, 2 B, and 3 C



MRI images of 71 years old man who was presented with sudden symptoms of headache, dizziness, and loss of consciousness. A) An enhanced MRI T1 WI in the axial plane show homogenous and intensive enhancement of TU located on meninges, without the “dural tail” sign (white arrows). B) An enhanced MRI T1 WI in the sagittal plane shows homogenous and intensive enhancement of TU located on meninges, without the “dural tail” sign (white arrows). C) An enhanced MRI T1 WI in the coronal plane shows homogenous and intensive enhancement of TU located on meninges, without the “dural tail” sign (white arrows).

Discussion

Hemangiopericytomas were first described in 1942 by Stout and Murray as tumors arising from the pericytes of Zimmerman, which are modified smooth muscle contractile cells surrounding capillaries (1). Angioblastic meningioma as a term was used by Bailey et al in 1928 to describe a meningeal tumor observed in three of their cases (3).

In 1954, Begg and Garret, in their single case of a hemangiopericytoma of the meninges and six cases of angioblastic meningioma described by Cushing and Eisenhardt, proposed that all of these tumors should be designated as hemangiopericytomas (4).

In the 1993 classification of the World Health Organization (WHO) established the term hemangiopericytoma instead of angioblastic meningioma. Those tumors are aggressive, have high rate of local recurrence and also are associated to distant metastasis. Those are important reasons which highlight the need of adequate preoperative diagnosis.

By the Guthrie et al total surgical excision of intracranial hemangiopericytomas is recommended, and postoperative irradiation to minimize the risk of local recurrence is also required.

Histologically intracranial hemangiopericytomas are neoplasms of pericytes that originate in the meninges, but are actually different form without a meningioma component (5-8).

Hemangiopericytomas are well-demarcated masses attached to the dura and are associated to profuse bleeding while resection. These are aggressive lesions and give extracranial metastasis; the most common sites are the bones, lung, liver, kidney, pancreas, and adrenals. Postoperative radiation therapy and/or chemotherapy is recommended to increase the survival time (9-12).

The most frequent symptom is headache alone or accompanied with sudden loss of consensus.

Intracranial hemangiopericytomas are multilobulated tumors more than 3 cm in diameter with presentation of hydrocephalus, edema, and mass effect (13).

The location of hemangiopericytomas is similar to that of meningiomas. Hemangiopericytomas are extra axial lesions and also dural-based, might show change in the shape of the white matter. Their localization can be presented as sphenoid/ parasellar, lateral convexity, and superior parasagittal as middle fossa, anterior fossa, and posterior fossa, with a basal predominance, also parasagittal/falx, convexity, posterior fossa, and tentorial; none occurred as purely intraparenchymal masses. The most of them are supratentorial in distribution parasagittal area is the commonest location (14, 15).

Almost all hemangiopericytomas have lobulated margins and are dense on CT with contrast enhancement on CT and MRI. The main differential diagnosis of HPC includes angiomatous/anaplastic meningiomas and Solitary Fibrous Tumor (16).

MRI features are **T1 waited images:** isointense to grey matter, **T1 C+ (Gd)** vivid enhancement heterogeneous may have a narrow base of dural attachment, and dural tail sign.

T2 waited images: isointense to grey matter, multiple flow voids on MRI.

Diffusion waited images: intermediate restricted diffusion (less than meningioma).

HPC's clinical behavior is more aggressive than that of benign meningiomas and have a strong tendency for local recurrence and extracranial metastasis (17 – 19).

Sometimes the histopathologic features of an HPC and meningioma can overlap so immunohistochemistry staining is used in this situation for adequate histopathology diagnosis. Immunohistochemistry staining for MHPC shows an intense reactivity to vimentin, but not to epithelial membrane antigen (EMA), unlike meningioma that is positive for vimentin and EMA (20,21).

Conclusion

Meningeal hemangiopericytoma (HPC) are aggressive lesions with a tendency for extracranial metastasis, also this tumor has tendency for high rates of recurrence, and is characterized with local aggressive behavior.

On both CT and MRI modality distinguishing a hemangiopericytoma from a meningioma sometimes can be difficult because of their similar appearance, but it is important interpretation to be adequate especially with MRI because of the need for pre-operative catheter embolization in order to prevent the intraoperative blood loss, and also adjuvant radiotherapy might be required to reduce the risk of local recurrence and distant metastasis

References

1. Stout AP, Murray MR. Hemangiopericytoma: a vascular tumor featuring Zimmerman's pericytes. *Ann Surg* 1942; 116:26 – 33.
2. Bailey P, Cushing H, Eisenhardt L. Angioblastic meningiomas. *Arch Pathol* 1928; 6:953 – 990.
3. Begg CF, Garret R. Hemangiopericytoma occurring in the meninges: a case report. *Cancer* 1954;7: 602 – 606.
4. Cushing H, Eisenhardt L. *Meningiomas: Their Classification, Regional Behavior, and Surgical End Results*. Springfield, Ill: Charles C Thomas; 1938:43 – 45.
5. Mena H, Ribas JL, Pezeshkpour GH, et al. Hemangiopericytoma of the central nervous system: a review of 94 cases. *Hum Pathol* 1991; 22:84 – 91.
6. Goellner JR, Laws ER, Soule EH, et al. Hemangiopericytoma of the meninges: Mayo Clinic experience. *Am J Clin Pathol* 1978; 70:375 – 380.
7. Guthrie BL, Ebersold MJ, Scheithauer BW, et al. Meningeal hemangiopericytoma: histopathological features, treatment, and long-term follow-up of 44 cases. *Neurosurgery* 1989; 25:514 – 522.
8. Cosentino CM, Poulton TB, Esguerra JV, et al. Giant cranial hemangiopericytoma: MR and angiographic features. *AJNR Am J Neuroradiol* 1993; 14:253 – 256.
9. Tien RD, Yang PJ, Chu PK. "Dural tail sign": a specific MR sign for meningioma? *J Comput Assist Tomogr* 1991; 15:64 – 66.
10. Burger PC, Scheithauer BW. *Atlas of Tumor Pathology: Tumors of the Central Nervous System*. Third series, fascicle 10. Washington, DC: Armed Forces Institute of Pathology; 1994:133 – 136.
11. Jaaskelainen J, Servo A, Haltia M, et al. Intracranial hemangiopericytoma: radiology, surgery, radiotherapy, and outcome in 21 patients. *Surg Neurol* 1985; 23:227 – 236.
12. Pitkethly DT, Hardman JM, Kempe LG, et al. Angioblastic meningiomas: clinicopathologic study of 81 cases. *J Neurosurg* 1970; 32:539 – 544.
13. Kruse F. Hemangiopericytomas of the meninges (angioblastic meningioma of Cushing and Eisenhardt): clinicopathologic aspects and follow-up in 8 cases. *Neurology (Minneap)* 1961; 11: 771 – 777.

14. Osborne DR, Dubois P, Drayer B, et al. Primary intracranial meningeal and spinal heman-giopericytoma: radiologic manifestations. *AJNR Am J Neuroradiol* 1981; 2:69 – 74.
15. Elster AD, Challa VR, Gilbert TH, et al. Meningiomas: MR and histopathologic features. *Radiology* 1989; 170:857 – 862.
16. Zimmerman RD, Fleming CA, Saint-Louis LA, et al. Magnetic resonance of meningiomas. *AJNR Am J Neuroradiol* 1985; 6:149 – 157.
17. New PFJ, Aronow S, Hesselink JR. National Cancer Institute: evaluation of computed to-mography in the diagnosis of intracranial neoplasms, IV: meningiomas. *Radiology* 1980; 136:665 – 675.
18. Buetow MP, Buetow PC, Smirniotopoulos JG. From the archives of the AFIP: typical, atypical, and misleading features in meningioma. *Radiographics* 1991; 11:1087 – 1106.
19. Bydder GM, Kingsley DPE, et al. MR imaging of meningiomas including studies with and without gadolinium-DTPA. *J Comput Assist Tomogr* 1985; 9:690 – 697.
20. Aoki S, Sasaki Y, Machida T, et al. Contrast-enhanced MR images in patients with meningi-omas: importance of enhancement of the dura adjacent to the tumor. *AJNR Am J Neuroradiol* 1990; 11:935 – 938.
21. Russell EJ, George AE, Kricheff II, et al. Atypical computed tomographic features of in-tracranial meningioma: radiological-pathological correlation in a series of 131 consecutive cases. *Radiology* 1980; 135:673 – 682.

USE OF PLATELET RICH PLASMA AND SPLIT THICKNESS SKIN GRAFT IN POST-INFECTION SOFT TISSUE DEFECTS, OUR INITIAL EXPERIENCE

Nikolovska B¹, Miladinova D², Pejkova S¹, Trajkova A¹, Georgieva G¹, Jovanovska K¹

¹ *University Clinic for Plastic and Reconstructive Surgery, Faculty of Medicine, “Ss. Cyril and Methodius”, Skopje, Republic of North Macedonia*

² *Institute of Pathophysiology and Nuclear Medicine, Faculty of Medicine, “Ss. Cyril and Methodius”, Skopje, Republic of North Macedonia*

ABSTRACT

Introduction. Necrotizing soft tissue infections (NSTI) are severe, potentially life-threatening medical emergencies that are accompanied with devastating and rapidly spreading destruction of soft tissue as a result of bacterial infection and systemic toxicity. Patients with NSTI who undergo split thickness skin graft (STSG) experience high rates of complications. Platelet-rich plasma (PRP) has shown to have positive effect on the healing of acute, chronic and diabetic wounds. The aim of this study was to analyze the outcome of skin grafting with PRP in post-infectious soft tissue defects.

Materials and Methods. Fourteen patients were randomized in two groups: an experimental group – wound coverage with STSG and PRP, and control group – with STSG alone. PRP was applied to the donor site in the experimental group. Patients’ follow up was until complete heal-ing of wounds. In both groups we analyzed the healing time, the need for regrafting, secondary infections, pain and adverse effects.

Results. Patients in the PRP group have had significantly reduced healing time (32.5 days) versus control group (72.5 days). In the experimental group, the rate of skin graft success was 90.2% vs. 77.2% in the control group. The need for regrafting occurred in one patient in the control group. Pain at the donor site in experimental group was statistically significantly lower. No adverse effects were reported.

Conclusion. The combination of STSG and PRP reduces healing time and lowers the com-plication rates. It is safe to use with no adverse effect. Further studies are needed with larger number of patients to further validate its efficacy.

Key Words: *Fournier gangrene, necrotizing fasciitis, necrotizing soft tissue infections, platelet-rich plasma, split thickness skin graft.*

Здружение на лекарите по
анестезија, реанимација
и интензивно лекување



Macedonian Society of Anesthesiologists
and Intensive Care Medicine



Здружение на лекари за
критично болни пациенти