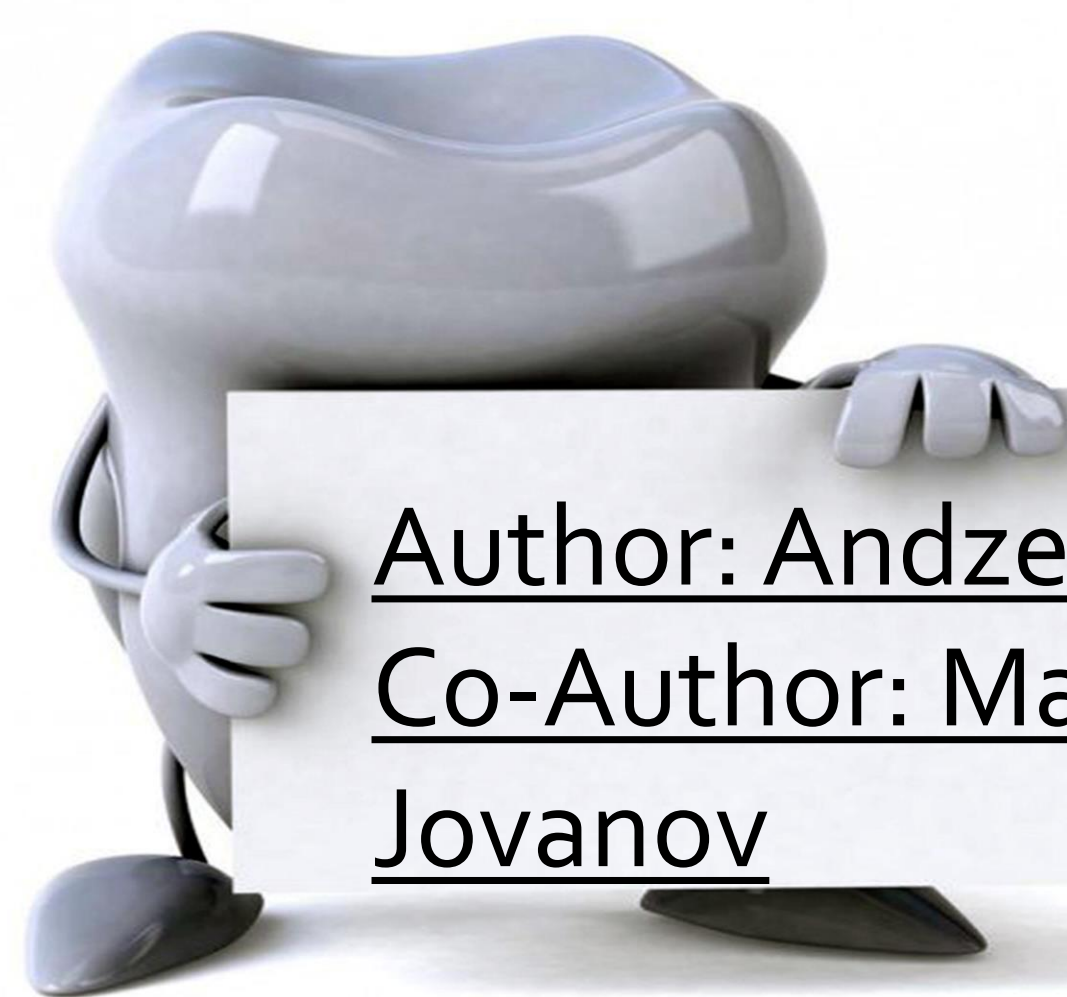

PRESENCE OF THIRD MOLAR AMONG STUDENTS FROM 3rd YEAR, DENTAL MEDICINE




Author: Andzelo Dimov
Co-Author: Mario Jovanov



Menthor: Ass. D-r Sandra Atanasova
Co- Menthor: Ass. D-r Ljubica Proseva

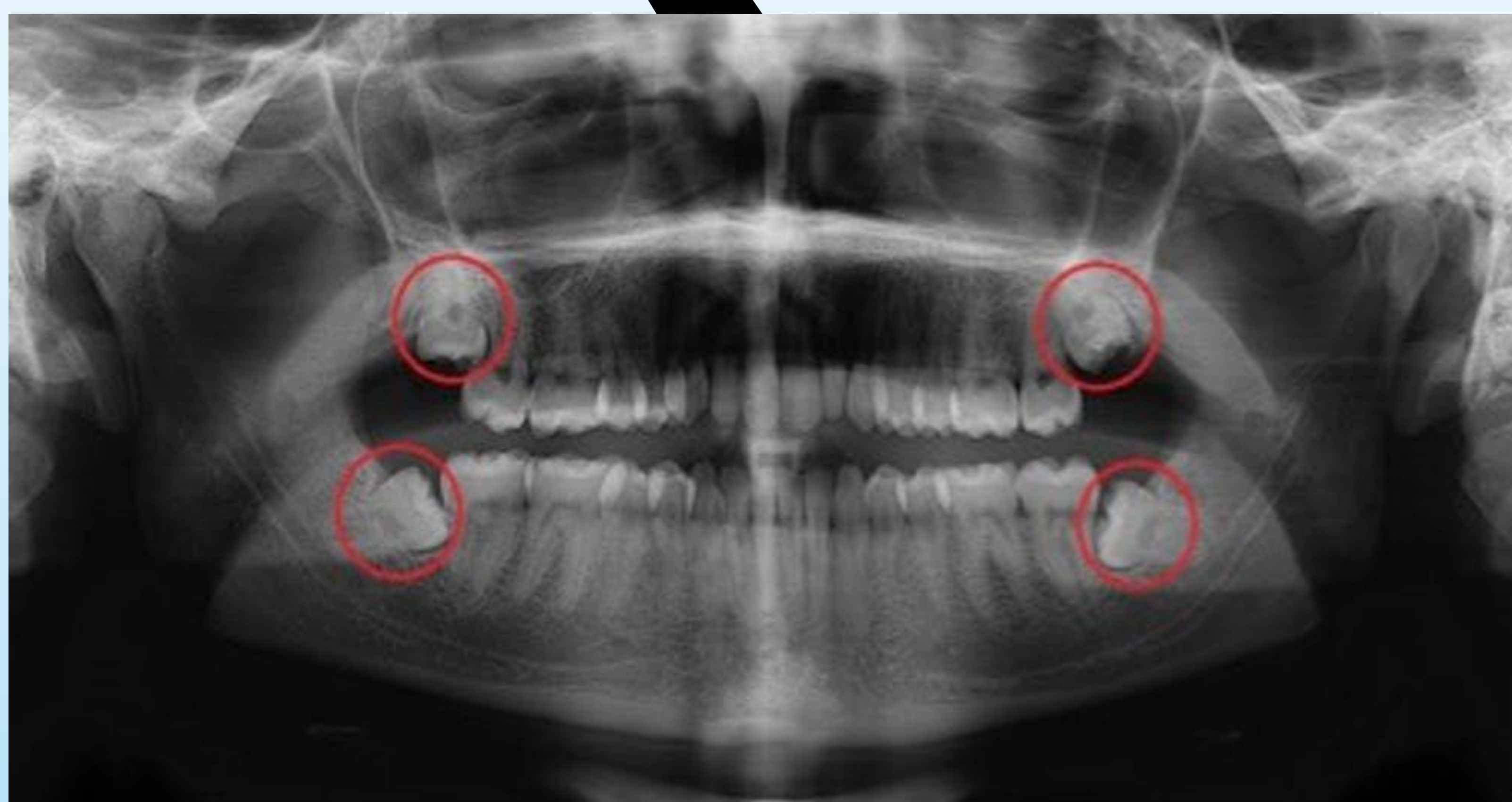Introduction

A wisdom tooth or third molar is one of the three molars and it is located distal of the dental arch. The age at which wisdom teeth erupt is variable, but generally occurs between seventeens and early twenties. Wisdom teeth usually don't need to be removed if they're impacted but aren't causing any problems. This is because there's no proven benefit of doing this and carries the risk of complications.



Aim

The purpose of this study was to analyze the dental status of third-year students and to determine the presence of third molars, as well as the situations where the extraction and impact of these teeth are taking place



Material and methods

In the analysis a total of 20 individuals were involved which of 14 were females and 6 males from their third year of dental medicine. The analysis was done with the anamnesis, in that including the information about the molars that were extracted. An intraoral exam and a RTG image was taken for seeing presence of the wisdom teeth in the oral cavity of the students.

Results

Approximately 30% of the students don't have any third molar erupted and they are all females, 20% have 1 third molar erupted and they are also females. 35% have two third molars erupted (4-Females and 3-Males). There is no presence of three third molars erupted. Only 15% have all four wisdom teeth erupted and they are only males.

Conclusion

The main conclusion from the analysis is that no student has an extracted third molar. In females' students there is only situations with one and two erupted wisdom teeth but in male students' situation is different and part of them have four erupted wisdom teeth.