

## Case Report

# Annular pancreas with choledocholithiasis in an adult male patient: a case report

Ilija Milev<sup>1\*</sup>, Panche Karagjozov<sup>2</sup>, Aleksandar Mitevski<sup>3</sup>, Marjan Mihailov<sup>4</sup>

<sup>1</sup>Department of Surgery, Clinical Hospital - Shtip, Faculty of Medical Sciences, Goce Delchev University, St. Krste Misirkov, Republic of North Macedonia

<sup>2</sup>Clinic for Digestive Surgery, Faculty of Medicine, Ss. Chyryl and Methodius University, St. 50 Divizija, Republic of North Macedonia

<sup>3</sup>Department of Surgery, Re-Medica General Hospital, Faculty of Medical Sciences, Goce Delchev University, St. Krste Misirkov, Republic of North Macedonia

<sup>4</sup>Department of Anesthesiology, Clinical Hospital-Shtip, St. Ljuben Ivanov, Republic of North Macedonia

**Received:** 25 August 2019

**Accepted:** 18 September 2019

### \*Correspondence:

Dr. Ilija Milev,

E-mail: [milevilija@gmail.com](mailto:milevilija@gmail.com)

**Copyright:** © the author(s), publisher and licensee Medip Academy. This is an open-access article distributed under the terms of the Creative Commons Attribution Non-Commercial License, which permits unrestricted non-commercial use, distribution, and reproduction in any medium, provided the original work is properly cited.

## ABSTRACT

Annular pancreas is very rarely presented with a clinical picture of obstructive jaundice, usually due to some biliopancreatic malignancy rather than choledocholithiasis which make our case unique. We are presenting a 60-year-old male patient with a 6 months old medical history of right upper quadrant pain and intermittent jaundice. On ultrasonography a common bile duct stone was detected with dilatation of the biliary tree and gallstones with edematous wall of the gallbladder. On gastroscopy narrowing of the duodenum was registered. On ERCP the papilla Vateri could not be cannulated and there was a substantial amount of retained food in the duodenal bulb and antral part of the stomach. MRCP showed extensive dilatation of the whole biliary tree from several stones in the distal part of the common bile duct. At the operation there was a ring of pancreatic tissue about 2 cm wide that surrounded the second portion of the duodenum. The operation proceeded with choledochotomy, choledocholithotomy, L-L choledochoduodenostomy and partial resection of the pancreatic ring. After three months the patient had gained weight, had no pain or any other symptoms and control gastroscopy showed normal findings.

**Keywords:** Annular pancreas, Jaundice, Choledocholithiasis

## INTRODUCTION

Annular pancreas (AP) is a rare congenital anomaly of the pancreas that consists of complete or incomplete ring of pancreatic tissue encircling the descending part of duodenum. The anomaly was first reported in 1818 by Tiedemann and got the name AP in 1862 from Ecker.<sup>1,2</sup> Vidal presented the first successful operative treatment of a case with obstructive AP.<sup>3</sup> The prevalence considering the autopsy series is estimated between 5 and 15 cases per 100 000 although recent ERCP series are showing prevalence of 400 cases per 100 000 in adult population.

The real prevalence is probably somewhere in between.<sup>4</sup> Only a small amount of cases is symptomatic and require treatment during lifetime, hence there is a limited number of reported cases worldwide. Thomford et al reviewed a total number of 77 adult patients treated for AP worldwide.<sup>5</sup> Fu et al disclosed 266 patients overall with AP reported in the English literature and most of them were infants and newborns and in 2008 according to Zyromski et al. that number was 737.<sup>6,7</sup> The awareness about the condition and the improvement in preoperative diagnosis resulted in a much higher number of reported cases and with several cohort studies published

recently.<sup>8,9</sup> Although in the past the condition was twice more common in men recent papers suggest slight female predominance.<sup>10</sup>

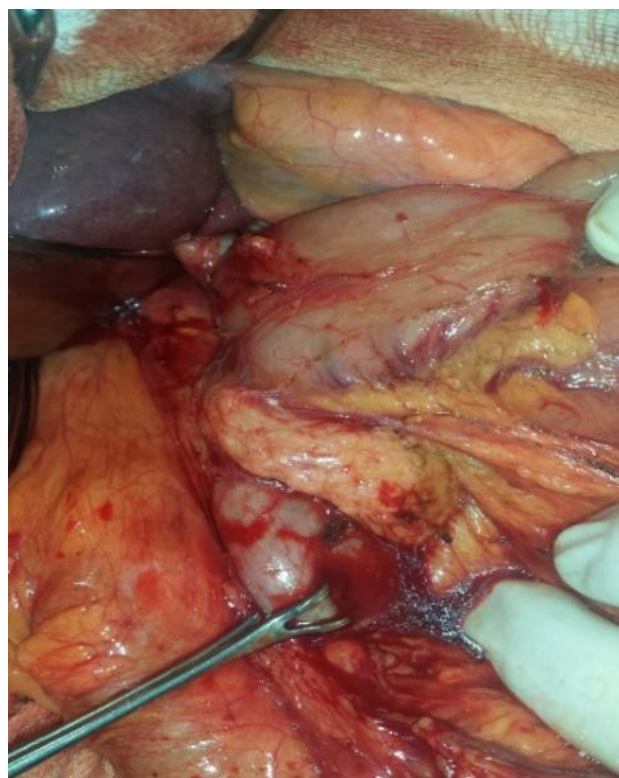
In children AP usually manifests itself with signs of duodenal obstruction in the neonatal period and require treatment immediately after birth. The diagnosis can be established by intrauterine ultrasound and after birth by plain roentgenogram recognizing the typical “double-bubble” sign, upper gastrointestinal series and ultrasound. If the condition is asymptomatic at first, in the adulthood symptoms are usually present in the third, fourth or fifth decade with upper abdominal pain as the most common. Less frequently in adulthood AP is presented as duodenal obstruction, pancreatitis, peptic ulcer and very rarely as obstructive jaundice as in our case. In fact, there are only a few reported cases of AP presented as obstructive jaundice and most of them due to concomitant biliopancreatic malignance and not due to choledocholithiasis which make this case somehow unique.<sup>7</sup> Even with the modern imaging technics still about 40% of cases are diagnosed on the operation although recent papers are showing improvement in the preoperative diagnosis. Preoperatively the ring of the pancreatic tissue encircling the duodenum can be demonstrated on computed tomography (CT), magnetic resonance imaging (MRI) and ultrasound especially endoscopic ultrasound. Usually before that one should suspect the diagnosis according to the clinical picture and findings on endoscopic retrograde cholangiopancreatography (ERCP), upper gastrointestinal series or better according to the finding on hypotonic duodenography where narrowing of the second portion of the duodenum by lateral external compression with intact mucosa should be visualized.<sup>9,11-13</sup>

The symptomatic AP is an indication for operation. Besides correction of any side condition like the choledocholithiasis in our case the options for surgical treatment are: gastro-jejunostomy with or without vagotomy, Billroth II resection of the stomach, duodeno-jejunostomy with the first part of the duodenum, duodeno-duodenostomy or resection of the ring of the pancreatic tissue. Recently the laparoscopic approach becomes very favorable also.<sup>5,14-16</sup>

## CASE REPORT

We are presenting a 60-year-old male patient with a six months old history for right upper quadrant pain and intermittent jaundice that appeared two months prior to admission at our institution. At the beginning he was treated symptomatically only with analgesic and spasmolytic therapy. The examinations started when the jaundice appeared. Then he was diagnosed with choledocholithiasis with dilatation of the biliary tree on ultrasound and transferred to the gastroenterology clinic. Here the laboratory findings were consistent with obstructive jaundice with total serum bilirubin of 183 mmol/l at admission as well as alkaline phosphatase

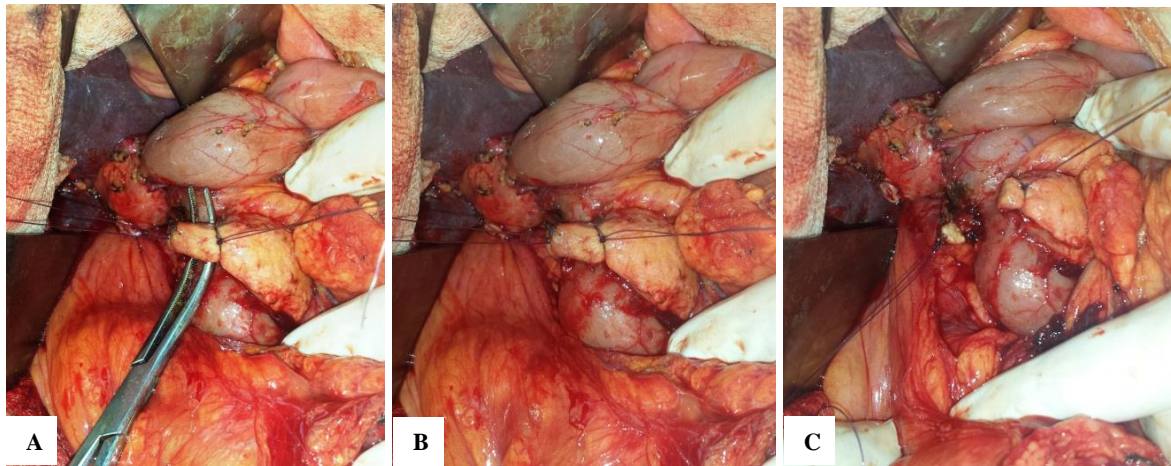
(ALP) - 946 IU/l, gamma glutamyl transpherase (GGT) - 1190 IU/l, alanine transaminase (ALT)-385 IU/l and aspartate transaminase (AST)-396 IU/l. On ultrasonography a common bile duct stone was detected with dilatation of the biliary tree and gallstones with edematous wall of the gallbladder. On gastroscopy there was inflammation of the gastric mucosa consistent with chronic gastritis and a small peptic lesion in the duodenal bulb with narrowing of the duodenum that can't be passed by the scope immediately below. Also, in the bulb there were retained food particles. On two consecutive ERCP-as the papilla Vateri couldn't be cannulated and there was a substantial amount of retained food in the duodenal bulb as well as in the antral part of the stomach especially in the second occasion. After that the digestive surgeon was consulted who proposed a magnetic resonance cholangiopancreatography (MRCP). On MRI there were no signs of a malignant lesion or any other anomaly in the region of the duodenum, pancreatic head or biliary tree and MRCP showed extensive dilatation of the whole biliary tree from several stones in the distal part of the common bile duct. With these findings it was concluded that the patient should be operated, and he was transferred to the clinic for digestive surgery. On the operation there was a substantial dilatation of the whole biliary tree that was due to stones in the common bile duct. At first no other pathologic lesion was found but during the Kocherisation of the duodenum where by the way there were no signs of a peptic lesion a ring of pancreatic tissue about 2 cm wide that surrounded the second portion of the duodenum was found and only than the diagnosis of AP was established Figure 1.



**Figure 1: Annular pancreas.**

After that the operation proceeded with choledochotomy, extraction of the bile duct stones with lavage of the biliary tree and construction of latero-lateral choledochoduodenostomy. To relief the obstruction of the duodenum a decision was made to partially resect the ring of pancreatic tissue till the point of firm adherence to the duodenum although making a bypass procedure was seriously considered in Figure 2(A-C). The postoperative

course went very well. Liquid diet was started on the 4-th postoperative day and full diet was allowed on the 6-th postoperative day. The patient was discharged on the 8-th postoperative day in a very good overall condition. After one month the laboratory findings were normal and the patient had gain weight. After three months the patient was up about 10 kilos, had no pain or any other symptom and control gastroscopy showed normal finding.



**Figure 2 (A-C): Resection of the pancreatic ring.**

## DISCUSSION

During the embryologic development the pancreas develops from the ventral and dorsal pancreatic buds that are formed in the fourth week of gestation. In the following weeks the ventral pancreatic bud rotates around and behind the duodenum in the clockwise direction and its channel that on the outer side is fused with the channel that will soon to be the common bile duct fuses with the main channel of the dorsal bud to form the main pancreatic duct of Virsung. The remaining part of the channel of the dorsal bud forms the duct of Santorini. In such manner the dorsal bud forms the tail, the body and the upper part of the head of the pancreatic gland and the ventral bud forms the lower part of the head and uncinata process. The fusion of the two buds is finished by the eighth week of gestation. Disorders of the mentioned sequence of events lead to the most common pancreatic congenital anomalies such as: pancreas divisum, abnormal pancreato-biliary junction and AP.<sup>17,18</sup>

There are two main theories about the development of AP. According to Leco's theory that is widely accepted the tip of the ventral bud becomes adherent to the duodenum at the beginning of the process of rotation, hence at the end of the rotation the ring of pancreatic tissue is formed that completely or partially envelops around the descending part of the duodenum.<sup>19</sup> The second most important theory is Baldwin's theory that recognize the hypertrophy of the ventral bud at the level of the duodenum as the reason for forming the abnormal ring of pancreatic tissue.<sup>20</sup> Rarely the ring can be

developed in a more distal position as well as in more proximal position like portal AP.<sup>21</sup>

There are several classifications of AP and although none is perfect one of them that divides the types of AP according to the pattern of fusion of the channels of the buds is particularly useful when making the decision of the type of the operation. According to these the AP can be divided in type I - "dividing AP" where the AP is in conjunction with pancreas divisum and contain a duct that is completely separated from the main duct of the pancreas, type II - "branch AP" where the duct of the AP is a branch of the main duct and type III - "main duct AP" where the duct of the AP forms the distal part of the main duct. The second type is most common, and the others are only sporadic.<sup>22</sup>

AP very rarely presents itself with a clinical picture of obstructive jaundice and mostly due to the present biliopancreatic malignancy. First paper with 15 patients with AP and obstructive jaundice was published by Morrell and Keynes.<sup>23</sup> Out of those patients only 4 were with choledocholithiasis. After then there are several reports of a sporadic cases and very small series of patients with AP and biliary obstruction and none of them were with choledocholithiasis, hence our case is a rare and unique form of presentation of AP.<sup>24,25</sup>

In our case when we removed the stones from the common bile duct and after that made a L-L choledochoduodenostomy several options to relief the duodenal obstruction were considered and at the end the decision was made to resect the ring mainly because in most of the

circumference we could very easily separate it from the duodenum and it seemed as the most physiological solution instead any type of bypass procedure like gastroenterostomy with or without vagotomy, duodeno-duodenostomy or duodenojejunosomy. The resection of the stomach was not considered as an option. The resection of the pancreatic ring as a choice of treatment is not recommended in most published papers for annular pancreas because of the possibility of serious postoperative complications like postoperative pancreatitis, postoperative pancreatic fistula or development of duodenal fistula. Considering the classification of AP where in type III particularly the duct of the pancreatic ring can be a part of the main pancreatic duct the danger of such complications is obvious. Much more the ring can sometimes be so adherent to the duodenum that can easily be open during the dissection and the preparation for resection and be the reason for devastating postoperative duodenal fistula. In our case the pancreatic ring was very easily dissected from the duodenum and then resected. This part of the operation went very quickly without disturbances of the continuity of the digestive tract. Postoperatively there were no complication of any kind and the patient is gaining weight and feeling well three months after the operation. Ladd and Madura are among the rear authors who proposed that the resection of the pancreatic ring could be safe if the annulus is partial and not densely adherent to the duodenal serosa, and the duodenal segment beneath the annulus is not fibrotic.<sup>26</sup> MacGuines et al reported a successfully treated patient with AP by resecting the pancreatic ring with stapler and in lack of firm evidence recommended that such a treatment could be safe in cases where pancreas is not firmly adherent to the duodenum and not associated with duodenal stenosis.<sup>27</sup> However, besides such reports and the success of our operation as recommendable options for treating the AP still stay any of the mentioned bypass procedures as well as partial resection of the stomach with Bilroth II reconstruction. The Whipple procedure is an option in case of malignancy or pancreatic lithiasis with chronic pancreatitis that is very rare.<sup>28</sup>

## CONCLUSION

Familiarity and awareness for such an anomaly as AP, along with contemporary imaging technics can lead to a successful preoperative diagnosis of this condition that is much more common in the recent years. The surgeon should be well-acquainted with the embryologic development and anatomic characteristics of annular pancreas in order to choose the best and safest operative solution even if it isn't seeming the be most physiologic one

*Funding: No funding sources*

*Conflict of interest: None declared*

*Ethical approval: Not required*

## REFERENCES

1. Tiedemann F. Über die Verschiedenheiten des Ausführungsganges der Bauchspeicheldrüse bei den Menschen und Säugetieren. *Dtsch Arch Physiol.* 1818;4:403.
2. Ecker A. Bildungsfehler des Pankreas und des Herzens. *Z Rat Med.* 1862;14:354.
3. Vidal E. Procès-Verbaux, Mémoires et discussion (Assoc Franc Chir). 18e Congress de Chirurgie, Paris. 1905;18:739.
4. Sandrasegaran K, Patel A, Fogel EL, Zyromski NJ, Pitt HA. Annular Pancreas in Adults. *Am J Roentgenol.* 2009;193:455-60.
5. Thomford NR, Knight PR, Pace WG, Madura JA. Annular pancreas in the adult: selection of operation. *Ann Surg.* 1972;176(2):159-62.
6. Fu PF, Yu JR, Liu XS, Shen QY, Zheng SS. Symptomatic adult annular pancreas: report of two cases and a review of the literature. *Hepatobiliary Pancreat Dis Int.* 2005;4(3):468-71.
7. Zyromski NJ, Sandoval JA, Pitt HA, Ladd AP, Fogel EL, Mattar WE, et al. Annular pancreas: dramatic differences between children and adults. *J Am Coll Surg.* 2008;206(5):1019-25.
8. Wang D, Kang Q, Shi S, Hu W. Annular pancreas in China: 9 years' experience from a single center. *Pediatr Surg Int.* 2018;34(8):823-7.
9. Nagpal SJS, Peeraphatdit T, Sannapaneni SK, Sharma A, Takahashi N, Kendrick ML, et al. Clinical spectrum of adult patients with annular pancreas: Findings from a large single institution cohort. *Pancreatol.* 2019;19(2):290-5.
10. Wani AA, Maqsood S, Lala P, Wani S. Annular Pancreas in Adults: A Report of Two Cases and Review of Literature. *JOP. J Pancreas (Online).* 2013;14(3):277-9.
11. Kandpal H, Bhatia V, Garg P, Sharma R. Annular pancreas in an adult patient: diagnosis with endoscopic ultrasonography and magnetic resonance cholangiopancreatography. *Singapore Med J.* 2009;50(1):29.
12. Patra DP, Basu A, Chanduka A, Roy A. Annular Pancreas: A Rare Cause of Duodenal Obstruction in Adults. *Indian J Surg.* 2011;73(2):163-5.
13. Sirasanagandla SR, Nayak SB, Bhat KMR. A Rare Congenital Anomaly of the Pancreas: A Cadaveric Case Report. *JOP. J Pancreas (Online).* 2013;14(4):454-7.
14. Jarry J, Wagner T, Rault A, Cunha AS, Collet D. Annular Pancreas: A Rare Cause of Acute Pancreatitis. *JOP. J Pancreas (Online).* 2011;12(2):155-7.
15. Noh TH, Lee SE, Park JM. Laparoscopic treatment of annular pancreas in adults: report of a case. *Korean J Hepatobiliary Pancreat Surg.* 2012;16(1):43-5.
16. Moon SB. Annular pancreas in an 11-year-old girl: a case report. *Int Med Case Rep J.* 2017;10:65-7.

17. Moodley S, Hegarty M, Thomson SR. Annular pancreas. *South Afr Med J.* 2004;94(1):28.
18. Kim SS, Shin HC, Hwang JA. Various Congenital Abnormalities and Anatomic Variants of the Pancreas: A Pictorial Review. *J Belg Soc Radiol.* 2019;103(1):39.
19. Lecco TM. Zur morphologie des pankreas annulare. *Sitzungsberichte der Heidelberger Akademie der Wissenschaften.* 1910;119:391-406.
20. Baldwin WM. A specimen of annular pancreas. *Anat Rec.* 1910;4:299-304.
21. Patidar Y, Arora A, Mukund A, Dev A. Portal Annular Pancreas: An Under-Reported Pancreatic Anomaly. *J Surg Tech Case Rep.* 2012;4(2):140-1.
22. Russo A, Armand-Ugon G. Annular pancreas: case report and review of the literature. *Eur J Anat.* 2015;19(2):197-200.
23. Morrell MT, Keynes WM. Annular pancreas and jaundice. *Br J Surg.* 1970;57: 814-6.
24. Alborzi F, Daryani NE, Roshan N, Mami M, Ale taha N. Annular Pancreas Presenting with Painless Jaundice: A Case Report and Review of Literature. *Govaresh.* 2015;20(3):208-12.
25. Tewari M, Verma A, Shukla HS. Carcinoma of the Ampulla of Vater Associated with Annular Pancreas. *Indian J Surg.* 2016;78(5):409-10.
26. Ladd AP, Madura JA. Congenital duodenal anomalies in the adult. *Arch Surg.* 2001;136(5):576-84.
27. McGuinness CL, Choy A, Gajraj H, Chilvers AS. Stapling technique for annular pancreas. *Br J Surg.* 1993;80(6):758.
28. Mahdi B, Selim S, Hassen T, Mongi MM, Fadhel CM, Fathi C, et al. A rare cause of proximal intestinal obstruction in adults - annular pancreas: a case report. *Pan Afr Med J.* 2011;10:56.

**Cite this article as:** Milev I, Karagjozov P, Mitevski A, Mihailov M. Annular pancreas with choledocholithiasis in an adult male patient: a case report. *Int Surg J* 2019;6:3834-8.