

International Conference on Clinical PET-CT and Molecular Imaging (IPET 2015): PET-CT in the Era of Multimodality Imaging and Image-Guided Therapy

5 – 9 October 2015
IAEA Headquarters, Vienna, Austria

Organized by the IAEA  **IAEA**
International Atomic Energy Agency
Atoms for Peace

MDACC MD Anderson Cancer Center

In cooperation with:


 Singapore General Hospital
SingHealth Singapore General Hospital (SGH)

 **ACNM** American College of Nuclear Medicine (ACNM)

 **SNMMI** SOCIETY OF NUCLEAR MEDICINE AND MOLECULAR IMAGING Society of Nuclear Medicine and Molecular Imaging (SNMMI)


 **ARSNM** Arab Society of Nuclear Medicine (ARSNM)

 SOCIETY OF Radiopharmaceutical Sciences (SRS)

 **AOFNMB** Asia Oceania Federation of Nuclear Medicine and Biology (AOFNMB)

 World Association of Radiopharmaceutical and Molecular Therapy (WARMTH)

 Asian School of Nuclear Medicine (ASNM)

 WORLD FEDERATION OF NUCLEAR MEDICINE AND BIOLOGY World Federation of Nuclear Medicine and Biology (WFNMB)

 **ARCCNM** Asian Regional Cooperative Council for Nuclear Medicine (ARCCNM)

 **WMIS** World Molecular Imaging Society (WMIS)

 Australian and New Zealand Society of Nuclear Medicine (ANZSNM)

 **BNMS** British Nuclear Medicine Society (BNMS)

 **CANM ACMN** Canadian Association of Nuclear Medicine (CANM)

 **EANM** European Association of Nuclear Medicine (EANM)

 **EFOMP** European Federation of Organisations in Medical Physics (EFOMP)

 **ESR** EUROPEAN SOCIETY OF RADIOLOGY European Society of Radiology (ESR)

 **IOMP** International Organization for Medical Physics (IOMP)

 **ISORBE** The International Society of Radiolabeled Blood Elements (ISORBE)

BOOK OF ABSTRACTS

IAEA-CN-232

The material in this book has been supplied by the authors and has not been edited. The views expressed remain the responsibility of the named authors and do not necessarily reflect those of the government of the designating Member State(s). The IAEA cannot be held responsible for any material reproduced in the book.

IAEA-CN-232/1

Comparison of Bone Scintigraphy and X-ray Imaging in Patients after Hip Arthroplasty

P. Korol

Clinical City Hospital #12

Corresponding Author: p.korol@online.ua

Background: The aim of the study was to evaluate the level of disease after hip arthroplasty using bone scintigraphy and X-ray imaging.

Methodology: 62 patients after hip arthroplasty were imaged by a standard method of whole body bone scan. Intestinal uptake was observed visually 3 hours after the intravenous administration of 740 MBq ^{99m}Tc MDP. A whole body bone scan; anterior, posterior, oblique spot views of the hip joint region were obtained. The data of bone scan were compared with X-ray imaging.

Results: Total number of 62 patients with bone scans and X-ray imaging was statistically evaluated. 38/62 pts (61%) with bone scans had inflammatory processes in the hip joint area that is indicative of instability of the hip joint endoprothesis. However, on X-ray imaging, inflammation in hip joint was identified in 6/62 pts (9 %) events only. In total there were 62 matching scans and statistical data showed overall good correlation ($r=0.58$). Within the group of different matching regions correlation varied: $r=0.51$ for head of hip; $r=0.47$ for broach of hip; $r=0.56$ for cervical of hip.

Conclusion: Bone scintigraphy is more sensitive and specific method in determining stabilities s of the hip joint than X-ray imaging in patients with endoprothesis of hip joint.

IAEA-CN-232/2

The Use of SPECT-CT for SLN Detection in Breast Cancer and Melanoma

S. Sergieva¹, E. Alexandrova², M. Dimcheva¹, A. Fakirova³

Sofia Cancer Center¹
National Oncological Hospital²
Military Medical Academy³

Corresponding Author: sonya.sergieva@yahoo.com

Background: Lymphatic mapping and radioguided SLN biopsy are accepted standard N-staging procedures in management of breast cancer and malignant melanoma. Currently, a further step forward was made with the introduction of fusion SPECT-CT techniques into this field.

Methodology: 61 patients (aged 23-78 years) with breast cancer (T1-T2) and melanoma were included for the period between July 2011 and October 2013.

46 out of all patients had early breast cancer staged as T1-T2a. One patient had metachronic multicentric breast cancer. Another patient had a multifocal tumour with the biggest lesion up to 2cm.

15 out of all patients had melanoma (7F, 8M). Surgical excision of the primary lesion was carried out in all of them.

Methods: Peri-areolar or peri-tumoural injections were performed by applying 99mTc-Nanocoll (74 – 110 MBq). Planar images were acquired 30-75 min post injection. Transmission scans using refillable 99mTc plexi-glass source were realized. SPECT-CT with low-dose CT was used (130kV; 30mA). Dynamic study after subdermal application of the tracer around the scar was acquired for 15 min (30sec/frame) followed by planar and SPECT-CT studies in melanoma patients.

Tattooing to externally localize the SLN position was accomplished.

Radioguided SLN biopsy was performed in all patients. Histological examinations were carried out using standard method H&E and/or immunohistochemistry with Cytokeratin AE1/AE3.

Results: SLNs were visualized on planar studies in 54 out of 61 patients.

Comparing planar lymphoscintigraphy with SPECT-CT, additional “hot nodes” were found which were identified only by fusion images as follows: 7 parasternal nodes, 10 axillary (I-II axillary level) nodes, 3 intramammary nodes (near-by inj. sites), 2 supraclavicular (III axillary level), 1 interpectoral lymph node, 4 iliac and 2 laterocervical lymph nodes and 2 periscapular lymph nodes. One lymph node in the contralateral axilla was visualized in 1 case which was considered as non-SLN.

Enlarged non-palpable lymph nodes without tracer uptake were imaged in 3 patients with breast cancer and one with melanoma on the CT part of fusion image. After surgical treatment metastatic involvement of these lymph nodes were proved and patients were up-staged from N0 to N1.

Single micrometastases with a size 1x1.5 µm of 2 axillary SLNs were diagnosed by immunohistochemistry in 2 patients with breast cancer, macrometastases in 5 cases. Macrometastases in the SLNs were diagnosed in 6 patients with melanoma.

Accurate SPECT-CT mapping of SLNs to identify the lymphatic drainage basin was performed in 4 patients with dorsal melanoma. This information is very useful for radio-guided SLN biopsy.

Conclusion: Our results show that SPECT-CT imaging of SLNs increased sensitivity and diagnostic accuracy of lymphoscintigraphy in patients with breast cancer and melanoma by detecting additional “hot” loco-regional nodes and discovering SLNs in cases with negative planar lymphoscintigraphy; by exact localisation of internal mammary SNs; by imaging of interpectoralis LNs; SLN close to the injection site; visualization of “cold” non-palpable enlarged lymph nodes.

IAEA-CN-232/3

The Utility of 18F-FDG-PET/CT in Diagnosis and Follow Up in Patients with Adrenal and Neuroendocrine Tumours

V. Artiko, B. Radovic, S. Odalovic, D. Sobic Saranovic, V. Obradovic

Center for Nuclear Medicine, Clinical Center of Serbia

Corresponding Author: vera.artiko@gmail.com

Background: In this paper, we have evaluated 18F-FDG-PET/CT in three groups of neuroendocrine tumour patients: MTC, chromaffin and enterochromaffin derived tumours. We have assessed FDG-PET/CT in patients with suspicion on NET and patients with proven NET after surgery and/or chemotherapy.

Methodology: In order to evaluate the fluorine-18 fluorodeoxyglucose-PET-computerized tomography (18F-FDG-PET/CT) in three groups of neuroendocrine tumours (NETs) (medullary thyroid carcinoma, chromaffin and enterochromaffin derived tumours), we have assessed 18F-FDG-PET/CT findings in 39 patients with suspicion of NET or patients with proven NETs after surgery and/or chemotherapy. This retrospective study included 18 men and 21 women, mean age 49.1 ± 14.73 years, range 12 - 71 y (median 51). The histology diagnoses were: medullary thyroid carcinoma (MTC) in 13 patients, 6 paraganglioma, 1 pheochromocytoma, 1 adult neuroblastoma, 3 typical lung carcinoids, 2 goblet cell carcinomas, 1 small cell lung carcinoma, 1 atypical lung carcinoid, 1 spindle cell carcinoma, 1 well differentiated pancreatic NET and 1 poorly differentiated NET of unknown origin. In the tumour detection, following nuclear medicine methods were also used: ^{111}In -DTPA-D-Phe1-pentetreotide, $^{99\text{m}}\text{Tc}$ (V)-dimercaptosuccinic acid, $^{99\text{m}}\text{Tc}$ HYNIC-[D-Phe1, Tyr3-Octreotide]-Tektrotyd, ^{123}I -MIBG scintigraphy.

Results: In these three tumour groups of patients (MTC, chromaffin and enterochromaffin) we calculated sensitivity of 50%, 80% and 90%; and specificity of 60%, 100%, and 100%, respectively. Average maximum standardized uptake value (SUVmax) calculated in true positive patients was notably higher in enterochromaffin tumours group (10.7 in contrast to 5.6 and 4).

Conclusion: In conclusion, we have confirmed the utility of 18F-FDG-PET/CT in evaluation of adrenal and other neuroendocrine tumours. It is especially useful in gastroenteropancreatic (i.e. enterochromaffin derived, GEP) NETs and so called more malignant tumours with disseminated metastases. Further studies are required for more in depth assessment of these preliminary observations.

IAEA-CN-232/4

Pre-Therapeutic Dosimetric Studies and Post-Therapeutic Dosimetric Verification of Nuclear Medicine Therapeutics with SPECT-CT and PET/CT Imaging Systems

G. Sarti¹, C. Fabbri¹, S. Sanniti², F. Del Dottore¹, F. Busca¹

¹ Division of Physics and Biomedical Technologies M. Bufalini Hospital, Cesena (FC), Italy

² Division of Physics and Biomedical Technologies M. Bufalini Hospital, Cesena (FC), Italy

Corresponding Author: graziella.sarti@auslromagna.it

Background: We present our experience in clinical dosimetry with SPECT-CT and PET-CT imaging systems in the treatment with ¹³¹I (in metastatic differentiated thyroid cancer) and in the radiopeptide therapy with ⁹⁰Y-DOTATOC for a personalised dosimetric evaluation which would represent the ideal approach such as in external beam radiation therapy.

In the ¹³¹I thyroid treatments, the pre-therapeutic dosimetry with SPECT-CT has the purpose of calculating the optimal activity to be administered to the targets in a single solution.

In the radiopeptide therapy, Bremsstrahlung SPECT-CT imaging, performed after ⁹⁰Y-peptide administration, has been recognized as a useful method to detect the radiopharmaceutical distribution; however, the low spatial resolution does not allow an accurate visualization of the intra-lesion activity distribution and ⁹⁰Y-PET-CT post-therapeutic dosimetric verification is performed.

Methodology: Preclinical tests were performed for imaging quantifications by a SPECT-CT and PET-CT equipment and using torso-shaped phantom containing radioactive-coplanar-spheres.

In particular, we studied on the phantom:

- Sensitivity in cps/MBq: reproducibility and linearity range (with scatter, attenuation, dead time correction-iterative method-PSF correction)
- Partial volume correction: recovery coefficients curves with isovolume method
- Segmentation method of the targets with variable threshold at different lesion/background (L/B) ratios
- Uniformity analysis in 3D

In the patients, series of images were repeated in times varying from 4, 24, 48 hours up to 7 days to study the biokinetic parameters: we apply mono- or bi-exponential models or the rule of the trapezoid for evaluations of time-integrated activity coefficients.

Results: With the ¹³¹I and the ⁹⁰Y (with Bremsstrahlung SPECT-CT or low sensitivity PET-CT):

- For lesions of known volume > 5 ml (using CT or ultrasound techniques) and homogeneous distributions, the error associated with the evaluation of the activity/activity concentration may be regarded as not higher than 20%
- For lesions of unknown volume, for target segmentation we use the method of variable threshold at different L/B ratios
- Verification of non-uniform 3D distributions of activity in the tissues is affected by the low uniformity tomographic: even for larger volumes (equivalent diameter greater 3 times full width half maximum), non-uniformity was less than 30% in SPECT and could not be assessed in PET

A minimum activity concentration equal to 0.2 MBq/ml in the volume of tissue was necessary to assess PET-CT imaging quantification.

The comparison between the ^{90}Y -PET-CT and ^{90}Y -Bremsstrahlung SPECT-CT images underlined a better evaluation of the rim of the lesion and however, a superior resolution from PET acquisitions that could bring to an evaluation of different activity distribution within the tumour.

Conclusion: The PET-CT and SPECT-CT imaging systems allow us to study the radionuclide distribution in the target tissues and to follow in the various therapeutic cycles the evolution of the lesions and the absorbed dose.

IAEA-CN-232/5

Quantitative Measurements of the Therapeutic Effect in Patients with Somatostatin Expressing Tumours Using ^{99m}Tc -Tectrotyde

I. Kostadinova¹, A. Demirev², J. Mihailova³, V. Hadjiiska⁴

¹Clinic of nuclear medicine, Medical University, Sofia

²Clinic of nuclear medicine, Medical University, Sofia

³Clinic of oncology, Medical University, Sofia

⁴Clinic of nuclear medicine, Medical University, Sofia

Corresponding Author: irdika.family@gmail.com

Background: Scintigraphy for the diagnosis of somatostatin receptor expressing (SR) neuroendocrine tumours, their staging, restaging and monitoring therapy, is known to be highly sensitive, in many cases performing superior to the conventional imaging - CT and MRI. Sometimes it is difficult to estimate visually minimal changes during therapy, especially in cases when the number of pathological lesions is nearly the same. The aim of our study was to introduce quantitative measurements in addition to the usual qualitative criteria for a precise evaluation of the response to the applied therapy in patients with SR-expressing tumours.

Methodology: In the period 2012-2014, we have performed in total 54 examinations on 22 patients (15 of them were examined twice, 8 of them three times) after 3-12 cycles of sandostatin therapy, using the somatostatin analog ^{99m}Tc -HYNIC-TOC (Tektrotyd, PL) in activity between 370-550 MBq. Whole body and hybrid imaging investigation - SPECT-CT were performed 2-4h p.i. At presentation the average level of chromogranin was 234ng/ml and dropped during therapy to 161ng/ml and the number of pathological scintigraphic changes before and after therapy was respectively 65 and 56. For a qualitative measurement of the degree of activity of the radiopharmaceutical in them, compared to the symmetrical healthy zone, an index of activity /IA/ was introduced, calculated in 1-5 target lesions, the number depended on the extent of the tumour.

Results: In 18/22 of the investigated patients, it was difficult to evaluate therapeutic response, relying only on qualitative criteria, especially in those with multiple pathological scintigraphic lesions, as their number was nearly unchanged. In 9 of all patients, there was a partial therapeutic response with an average decrease of IA by 35.6% (calculated as a sum of IA of all affected structures, divided by their number): in 3 patients there was a complete response (without any pathological uptake); in 6 patients - stable disease with IA change within +/- 15%; in 4 of the patients – progressive disease with IA increase by 34.5%. The patients with progressive disease and 2 of the patients with a stable disease / all of them with Ki 67 index above 5/ were referred to PET-CT exam for eventual visualization of undifferentiated part of the tumour and further application of a common chemotherapy or surgery.

Conclusion: In summary, we suggest that applying additional quantitative criteria to the routine qualitative one in patients with SR – tumours, using ^{99m}Tc -HYNIC-TOC, may help in many cases for a more precise evaluation of the therapeutic effect, especially in those with an advanced disease. The therapeutic strategy could be further optimized by applying ^{18}F -FDG PET-CT in some of the patients with progressive or stable disease.

IAEA-CN-232/6

A Study on Experience, Clinical Impact and Limitations of the Only PET/CT Facility in Sri Lanka

A. Pallewatte

National Hospital of Sri Lanka

Corresponding Author: asp31263@hotmail.com

Background: Currently there is only one PET/CT scanner (GE Optima 560) in Sri Lanka, installed in 2011 at a private hospital in Colombo. Since there is no cyclotron, it depends on FDG imported from abroad permitting operation only once a week. This study is aimed at analysing the experience, cost-effectiveness and its role in overall patient management decisions in the country, where other imaging modalities such as CT/MRI are widely available and performed free in government hospitals. This also identifies the problems faced by clinicians and patients due to operational patterns of this PET/CT.

Methodology: Data from consecutive PET/CT examinations in this scanner for 2 year period from 01-12-2012 to 30-11-2014 were analysed. Patients' demographic data, clinical data and radiologists' reports were obtained from hospital data bases with permission. Specialties of referring clinicians, clinical indications for PET/CT, whether first time or follow up examinations were recorded. Information on problems faced by staff, patients and clinicians due to limited operation of this facility, costs and patients' socioeconomic & medical factors were obtained.

Results: Of all 822 PET/CT examinations, 734 had complete data suitable for study. There were 53.6% (n=393) females and 46.4% (n=341) males. Their age ranged 14-81 years (mean=58.6). There were 20.9% (n=154) undergoing second PET/CT and 1.1% (n=8) a third. IV Contrast was used in 83% (n=609). The waiting list for the examinations ranged from 1 - 27 days with a mean of 5.6 days. 98.4% of referrals were from clinical oncologists, majority being breast carcinoma followed by colon and lung cancer. Referrals for non-malignant conditions made up just 1.6%, infections being the most common. All 734 patients had undergone preliminary CT/MRIs. Average activity of FDG at origin was 2490 mCi decreasing to 181 mCi at delivery due to lengthy transport (5-6 hours). This facilitated only 10-12 PET/CT scans per week. Lowest activity of 32 mCi was received thrice due to airline delays. PET/CT charges are 8-10 times higher compared to CT/MRI in same hospital. As staff, two PET/CT technologists and two radiologists were employed.

Conclusion: PET/CT referrals in Sri Lanka are currently low because clinicians have to consider patients' affordability and limited scanner availability resulting from lack of local cyclotrons, costly FDG transport etc. This underutilization causes unintended short waiting lists, referrals almost restricted to oncology patients and to those who can afford it. Accordingly, current staff and infrastructure are adequate to cover low workloads. Referring clinicians state that they have to over-depend on other cheaper imaging modalities due to current shortcomings in PET/CT set-up and cost. This creates a negative impact on overall clinical management. Therefore, country's PET/CT facilities need expansion with more scanners, trained staff and cyclotrons preferably in government hospitals, in order to make PET/CT cheaper, cost-effective and accessible to all needy patients.

IAEA-CN-232/7

Non-Hodgkin Lymphoma Staging: Relationship of Tumour FDG Uptake and Histological Variants

T. Massardo¹, R. Fernandez¹, J. Jofré²; P. Sierralta², J. Canessa³, C. Salvo⁴, I. Gallegos¹

¹Hospital Clínico Universidad de Chile

²Hospital Militar de Santiago-Chile

³Hospitales Militar de Santiago/DIPRECA -Chile

⁴Hospital Naval Almirante Nef- Chile

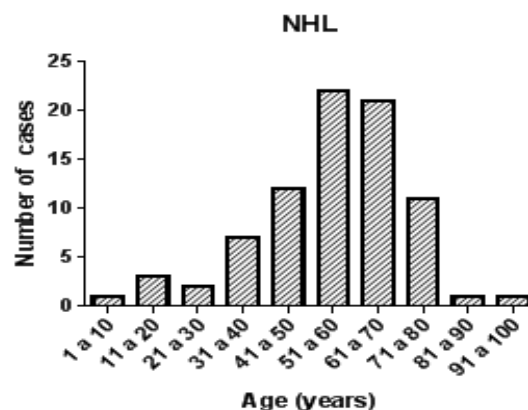Corresponding Author: teresamassardo4@gmail.com

Background: Several non-Hodgkin lymphomas (NHL) are fluorine-18 fluorodeoxyglucose (18F-FDG) avid. Metabolic imaging is currently well accepted for initial staging and therapy control, mainly in high-grade tumours, such as diffuse large B cell or follicular. Our goal was to assess the relationship of FDG tumour uptake with histological NHL variants in the cases referred for initial staging.

Methodology: We analysed the experience in initial NHL staging, since 2003. We found 81 cases; clinical data, and FDG results related with histological classification, using SUVmax in the more active lesion.

Results: The group included 59% of males (mean age: 54.4 years); 78 patients were >18 years. Age distribution is shown in Figure A.

Figure A



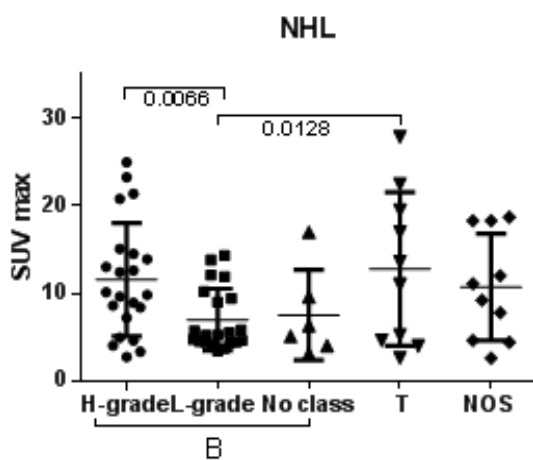
There were 60 cases of B cell NHL (27 high-grade; 26 low-grade and 7 unknown grade); 11 cases of T cell NHL and 10 not otherwise specified (NOS).

The initial disease was located at: lymph nodes (cervical, axillar, inguinal, mediastinal, retroperitoneal); head and neck (tonsils, salivary glands, rinopharynx, thyroid, lacrimal, palpebral); diverse organs in abdomen (including peritoneum); skeleton, bone marrow, central and spinal nervous system, lungs and soft tissue.

Twelve NHL staging cases were negative for FDG, without abnormal uptake suggesting tumoural disease: A. Five NHL patients submitted to total surgical resection corresponding to two cases with colonic and cecal masses, respectively; one with an amygdalin polyp (high-grade B cell); another with a mediastinal mass (T cell) as well as a case with peridural and extra-medullar infiltration (B, follicular grade 1). B. Other seven NHL patients corresponding to: one bilateral lacrimal large B cell-rich in T cell; one bone marrow Burkitt that remitted spontaneously; one gastric MALT; one salivary gland follicular grade 2; one indolent B cell marginal zone found in abdominal lymphadenopathy in kidney donation surgery; one B cell (follicular, unknown grade) with bilateral inguinal abnormal lymph nodes and two NOS, with iliac lymph nodes and thyroidal involvement, the latter case had multiple enlarged lymph nodes with regression after chemotherapy.

Then, FDG was positive in 70/76 patients (92%) with lymphoma tissue in situ. The SUVmax according to histological classification is displayed in Figure B; low-grade NHL B values were significantly inferior to high-grade B cells NHL and to T cells NHL. FDG was concordant with anatomical images (computed tomography and others) in 88% of cases with categorical report and available anatomical images (1 FDG was inflammatory or tumoural and 5 without other images). Most FDG were multifocal (81%); the metabolic scan found new disease sites in 48% cases.

Figure B



Conclusion: FDG assessment in NHL staging is fundamental confirming the presence of disease in known and new sites; it helps deciding further therapies and allows control. Our population consisted of adults, mainly with B cell disease. High grade B cell NHL and T cell NHL presented significantly more uptake than low-grade B cell. A good anamnesis and histological subtypes are important to interpret FDG; a baseline study is necessary in order to obtain a good metabolic follow-up.

IAEA-CN-232/8

Molecular Imaging in Response Evaluation to Human Embryonic Stem Cell Therapy in Neurodegenerative Diseases

P. Mohan¹, G. Shroff², H. Mahajan¹

¹Mahajan Imaging

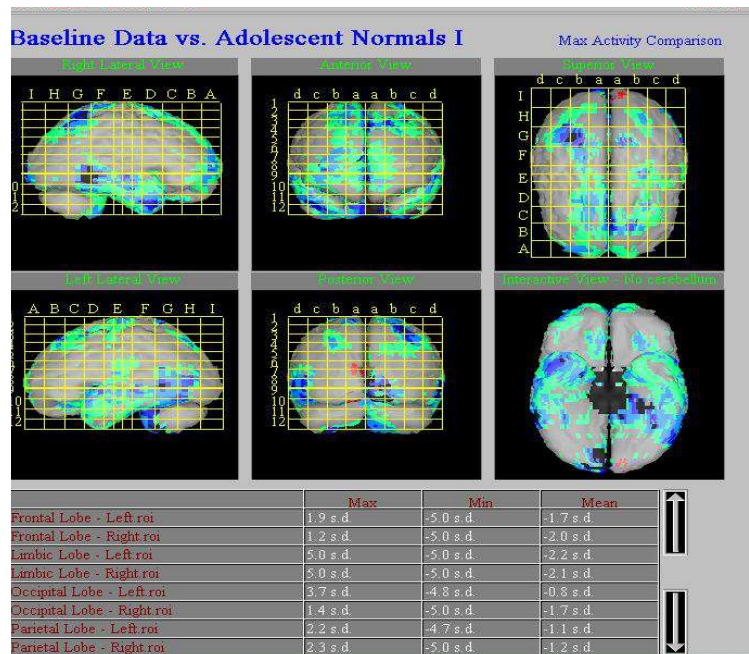
²Nutech Mediworld

Corresponding Author: drparulmohan@gmail.com

Background: Today, several suitable neuroimaging procedures are available that capture different aspects of neurodegeneration. Many diseases of the central nervous system (CNS) are characterized by "global" neural degeneration or dysfunction. Human embryonic stem cells have been proposed as a new and promising treatment modality in various pathologies of the CNS. Monitoring of these cells is currently done by use of various modes of molecular imaging, such as MRI, SPECT and PET. ^{99m}Tc HMPAO Brain SPECT quantitative analysis shows high accuracy in defining the specific cortical areas involved in neurodegenerative diseases. We evaluated the incremental value of quantitative Brain SPECT in response evaluation to stem cell therapy trials in these patients.

Methodology: We enrolled 65 consecutive patients who, according to both clinical criteria, MRI and 18 FDG PET/CT data, were classified as AD in 54/65 cases, as MS in 6/65 and traumatic brain injury in 5/65. All patients underwent brain SPECT, pre and post stem cell therapy, after 740 MBq ^{99m}Tc HMPAO i.v. injection. SPECT images were analysed both qualitatively and quantitatively, the latter applying the Talairach atlas (NEUROGAM, SEGAMI Corp.) which normalizes brain volumes and allows voxel by voxel comparative analysis of each patient in respect of an age-matched control group. The difference was expressed as standard deviation (SD) below normal value.

Results: Quantitative brain SPECT analysis demonstrated abnormalities in perfusion to various areas of brain, most notably the frontal, temporal and parietal lobes. Treatment with human embryonic stem cells resulted in resolution or improvement of abnormalities in 62/65 of patients over a 2-year period. The results were elaborated as mild improvement when 10%-30% changes were noted, moderate improvement when 30%-60% changes were noted and significant improvement when 60%-90% changes were noted. 42/65 patients had a normal brain SPECT after treatment. 3/65 patients had residual hypoperfusion after treatment. The rest showed significant improvement after treatment. None of the patient in the series showed deterioration or no improvement.



Conclusion: Firstly, the various existing MR imaging procedures as well as SPECT and PET methods provide complementary information about pathophysiologic changes associated with neurodegeneration. In consequence, depending on the clinical question and the availability of the corresponding methods, a combination of several diagnostic tools may result in optimal diagnostic results. Multimodality imaging approaches to improve diagnostic performance may gain even more momentum in the future with the introduction of recently established hybrid PET/ MR instrumentation in a single scanner. Secondly, the use of human embryonic stem cells seems to provide improvement in both clinical status and SPECT scans. Brain SPECT showed changes at the molecular level, hence may prove to be an important tool in therapy trials, attempting to detect patients on way to improvement in the very early stages.

IAEA-CN-232/9

Our First Experience in Application of MRI, PET and Invasive EEG Data in Patients with Drug-Resistant Epilepsy

I. Kostadinova¹; K. Minkin², P. Dimova³, D. Zlatareva⁴

¹ Clinic of nuclear medicine, Medical University, Sofia

² Clinic of Neurosurgery, Medical University, Sofia, Bulgaria

³ Clinic of Neurosurgery, Medical University, Sofia, Bulgaria

⁴ Clinic of Radiology

Corresponding Author: irdika.family@gmail.com

Background: Comprehensive presurgical evaluation is mandatory for patients with drug-resistant epilepsy. Presurgical work-up includes first line diagnostic methods such as long term video-EEG monitoring and MRI, but difficult cases need additional examinations to define the epileptogenic zone like PET, SPECT and invasive EEG. The aim of our study was to share our first experience in application of MRI and PET, compared to invasive EEG as methods of epileptogenic zone localization.

Methodology: Our study included 22 patients with drug-resistant epilepsy who were evaluated with MRI, 18F-FDG PET/CT / 18F-FDG activity 150-200 MBq / and invasive EEG from 2010 to 2014. 11 of them had temporal epilepsy and 11 extratemporal. All patients were evaluated with dedicated MRI epilepsy protocol. PET/CT study was fused with 3D MRI study using FSL or GE software. During invasive EEG monitoring, seizures were recorded in all patients. Long-term invasive video EEG monitoring lasted from 2 days to 2 weeks.

Results: Both MRI and PET were normal in 4 patients. From the remaining 18 patients, there were 5 patients with normal MRI and abnormal PET-CT demonstrating hypometabolism. There was partial or complete congruence between the zones of PET hypometabolism and the seizure onset zone defined by invasive EEG in 17/18 patients with hypometabolism on PET/CT. There was only 1 patient with discrepancy between the zone of hypometabolism on PET/CT and the seizure onset zone defined by invasive EEG. MRI was normal in 9 patients and structural lesions were identified in 13 patients. Partial or complete overlapping between the lesion and the seizure onset zone was observed in 11/13 cases with MRI lesion. In other 2 cases there was no overlapping between the data from invasive EEG and the MRI lesion. 14 patients were operated on, and satisfactory seizure control was achieved in 10 patients. All 10 patients with satisfactory outcome had partial or complete congruence between the invasive EEG and PET/CT hypometabolism.

Conclusion: 18F-FDG PET/CT is a sensitive non-invasive tool for defining the epileptogenic zone in patients with drug-resistant epilepsy and according to our first experience it is more accurate than MRI. It has to be applied in all cases with normal findings on MRI.

IAEA-CN-232/10

The Sum Is More than the Parts in PET/CT

V. Soroa¹, M. Volpacchio², V. Rubio³, M. Portillo⁴

¹ MD, PhD, Nuclear Medicine PET/CT, Centro Diag. Dr. E. Rossi, Argentina

² Radiology, PET/CT, Centro Diag. Dr. E. Rossi, Argentina

³ Radiology, PET/CT, Centro Diag. Dr. E. Rossi, Argentina

⁴ Technology, Nuclear Medicine, PET/CT Centro Diag. Dr. E. Rossi, Argentina

Corresponding Author: victoriasoroa@hotmail.com

Background: Tomographic image for the determination of localized metabolic activity with F18-fluorodeoxyglucose (FDG) & F18-choline (F-CH) has proved to be far more valuable than the isolated findings.

Methodology: Seven thousand four hundred FDG adult studies performed in a PET/CT Philips Gemini with 16 multi-detector tomographic slices, plus I/V iodine contrast (unless thyroid cancer or iodine intolerance) since 2009-2014. SNMMI & EANM acquisition procedure guidelines were followed with delayed 2h images, as required. F-CH in 116 patients on free diet, having early 30min, 1h and 2h images. Difference in the PET/CT data was clinically evaluated and when possible documented (50%). The data analysed was for all types of cancers and for all outcomes.

Results: PET/CT provided more information that separate methodologies, primordially in lung pathology, lymphoma with better characterization, colorectal, melanoma and all other pathologies. It enabled the differentiation of malignant from benign lesions. The hybrid scan improved re-staging and impacted on further treatment (30%). Prostate cancer with F-CH was also compared (12%) with diffusion weighted MRI (DWMRI), in order to characterize prostatitis uptake (9%).

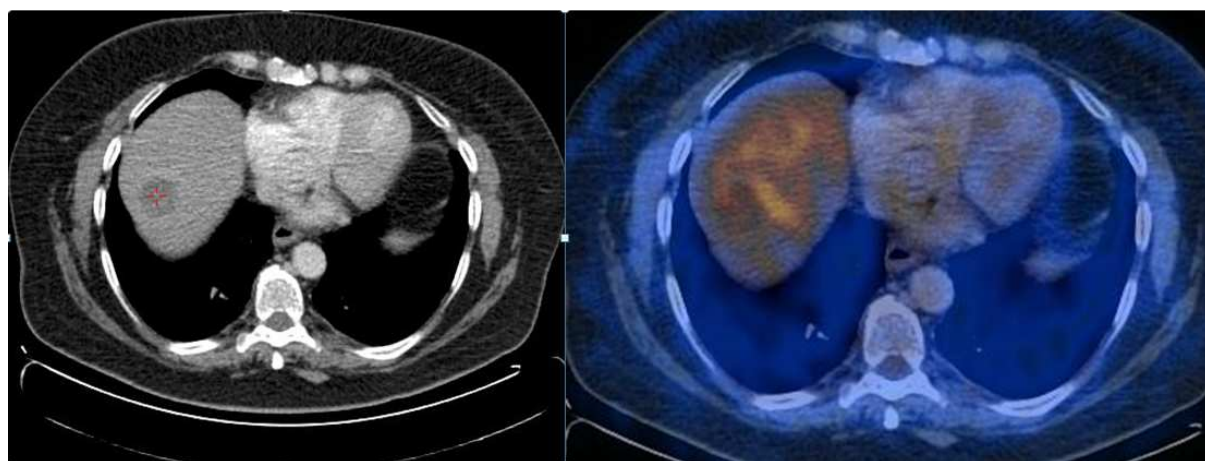


Figure 1: Colorectal cancer with liver metastasis identified in CT

Conclusion: The hybrid instrumentation helped in the diagnoses of cancer, follow-up, treatment decision. It enables signalling infection, inflammation and other pathological environments. The fusion of PET/CT data is the scintigraphic method of choice as it changed management in 30% of patients in our PET/CT facility. Prostate cancer with F-CH in 9% of patients added value with DWMRI imaging.

IAEA-CN-232/12

Fluorine-18 Fluoro-2-Deoxy-D-Glucose is Helpful in Castleman's Disease Therapy Assessment

T. Massardo¹, J. Canessa², J. Jofré³, P. Sierralta³

¹Hospital Clínico Universidad de Chile

²Hospital Militar de Santiago/DIPRECA

³Hospital Militar de Santiago

Corresponding Author: teresamassardo4@gmail.com

Background: Castleman's disease, angiofollicular lymphoid hyperplasia, corresponds to a rare lymphoproliferative disorder that may involve nodal and extranodal sites, most frequently observed as an asymptomatic mediastinal mass. The most common variant is the hyaline vascular, the others are a plasma cell variant, or a mixed form. The first, has a benign clinical course; a surgical mass excision could be effective. It is probably due to abnormal immunoregulation resulting in excessive proliferation of B lymphocytes and plasma cells. Localized and multicentric forms have been observed. Multicentric disease is associated with infection by human herpes virus 8 and HIV. The disease could mimic a lymphoma and even could be a diagnostic dilemma in benign lung parenchymal lesions. In multicentric cases or non-benign variants, diverse immunosuppressive agents have been employed.

The goal was to characterize the cases with Castleman's disease we have studied in our center.

Methodology: We reviewed our FDG data base, since 2003 searching for Castleman's disease and found three studies/over 6000 cases corresponding to 2 patients with FDG scan to assess their management.

Results: We present the cases corresponding to 0.05% of our whole body FDG PET scans.

Case 1.- A 61 year old male, diagnosed with Castleman's disease 7 months ago, in an excised submaxillar mass whose biopsy was a vascular hyaline variant. A computed tomography (CT) only showed a 23 mm hepatic cyst; FDG demonstrated hypermetabolism in right periclavicular lymph nodes (SUVmax:6.1) in 4 intense foci, the greater of 2 cm. The patient was submitted to a right cervical lymphadenectomy (levels IV and V). During the next month, a CT confirmed progression in size of bilateral cervical adenopathy, to a maximum of 16 mm. A new FDG also showed progression in size, number and intensity of nodes uptake, including right supra and infraclavicular areas in a mass of 5,1 cm (SUVmax:6.0).

Case 2.- A 30 year old female, with abdominal distension; a CT showed a nodular retropancreatic lesion and the MRI as a non-specific solid tumour. She was submitted to surgery and the lesion corresponded to an ovoid yellow-gray solid mass whose biopsy was suggestive of Castleman's disease, confirmed as a hyaline vascular variant. One year later, she was re-evaluated observing a slight diffuse prevertebral irregularity around L1-L3 level (SUVmax:3.8). She was considered as a not requiring further therapy but continue under follow-up imaging. An ultrasound, one year later, did not present any abdominal pathological features.

Conclusion: These two cases are dealing with a relative unknown inflammatory disease, considered benign, that could express in diverse forms requiring a carefully interpretation. FDG PET helped our clinicians to change therapy management. Both patients have the more benign variant, however, not the typical presentation. The first case was multifocal and progressive, with higher FDG uptake requiring

further aggressive immunotherapy. The second was a localized lesion with a lower uptake, probably related to remnant of postsurgical changes, with much better prognosis.

IAEA-CN-232/13

Correlation between Glucose Metabolic Uptake Value and Clinical Cognitive Assessment Tools in Patients with Dementia

R. Yudistiro¹, I. Dewi Muljanto², R. Fransisca³

¹MRCCC Siloam Hospital Semanggi/Universitas Pelita Harapan

²Nuclear Medicine Department MRCCC Siloam Hospital Semanggi

³Neurology department-memory clinic Siloam Hospital Lippo Village

Corresponding author: ryannuclear@gmail.com

Background: Reduction in glucose metabolic uptake in specific region of brain is traits of dementia patients suspected with Alzheimer disease. Evaluation with brain FDG PET has been shown as a biomarker imaging in Alzheimer disease. Brain FDG PET can be interpreted qualitatively and semiquantitatively. Semiquantitative data can be obtained from brain PET imaging programme software in voxel-based statistical analysis. The purpose of this study is to evaluate the correlation between semiquantitative parameter from brain FDG PET and clinical cognitive assessment scores.

Methodology: Subjects were patients in which clinical diagnosis was already made by neurologist and underwent resting brain FDG PET imaging. No structural abnormalities were found in previous anatomical imaging. Visual qualitative and semiquantitative analysis was done using NeuroQTM 3.0 Software. For semiquantitative data, regional and cluster difference uptake (patients uptake – mean asymptomatic patients uptake) and also regional and cluster number of standard deviation from mean asymptomatic patients (#SD M (AC)). Cognitive assessment tool, including MMSE, MoCA, CDT, and GDS, were assessed by neurologist. Spearman's rank correlation test in EZR software was used for statistical analysis.

Results: Nine patients (age range 22 – 79 years; 4 females) were included in this study. Range of cognitive assessment scores for MMSE was 12 – 29, MoCA was 4 – 28, CDT was 1 – 4, and GDS was 2 – 6. Range of semiquantitative data for regional difference uptake was -0.3697 - -0.1509 and cluster difference uptake was -0.2857 – -0.0747, meanwhile range for regional #SD M(AC) was -9.452 - -3.339 and cluster #SD M(AC) was -8.574 - -2.887. Significant moderate to strong correlation was found between MMSE and regional difference uptake ($r=0.736$, $p=0.02$), MoCA and regional difference uptake ($r= 0.845$, $p = 0.004$), MoCA and cluster difference uptake ($r=0.845$; $p = 0.004$), MoCA and cluster #SD M(AC) ($r=0.803$, $p=0.009$), CDT and regional difference uptake ($r= 0.694$, $p = 0.03$), CDT and cluster difference uptake ($r=0.84$; $p = 0.004$), CDT and cluster #SD M(AC) ($r=0.767$, $p=0.01$), GDS and regional difference uptake ($r= 0.908$, $p = 0.0007$), GDS and cluster difference uptake ($r=0.78$; $p = 0.001$), GDS and cluster #SD M(AC) ($r=0.716$, $p=0.03$).

Conclusion: There is a correlation between semiquantitative parameters from brain FDG PET and clinical assessment score.

IAEA-CN-232/14

Ultrasound and PET/CT Image Fusion for Prostate Brachytherapy Image Guidance

F. Hasford¹, J.H. Amuasi², A.K. Kyere², M. Vangu³

¹Radiological and Medical Sciences Research Institute, Ghana Atomic Energy Commission, Accra - Ghana

²Medical Physics Department, School of Nuclear and Allied Sciences, University of Ghana, Accra – Ghana

³Nuclear Medicine Department, CM Johannesburg Academic Hospital, University of the Witwatersrand, Johannesburg - South Africa

Corresponding Author: haspee@yahoo.co.uk

Background: Fusion of medical images between different cross-sectional modalities is widely used, mostly where functional images such as PET or SPECT are fused with anatomical data from CT, ultrasound or MRI, to improve medical diagnosis and therapy. Global data by IARC shows prostate cancer as a leading cancer incidence, with high mortality rate. Transrectal ultrasound (TRUS) and CT have been used for brachytherapy treatment planning and also for biopsy-guidance, as brachytherapy seeds and focal lesions are better visualized on CT images. PET-CT imaging modality is widely used because the integration of PET and CT scanners to provide co-registered images combine molecular quantifiable images obtained by PET with high spatial resolution and anatomical detail of CT.

Methodology: Materials and equipment employed for the study include PET-CT Biograph system, TRUS system with calibrated stepper, multimodality prostate phantom, MatLab software. The prostate phantom was set up on PET-CT system using lasers as guides to scan the prostate capsule. Ultrasound images of the capsule were obtained in similar setup condition, using ultrasound probe. The PET-CT and ultrasound images were acquired firstly without inserted brachytherapy needles and secondly, with inserted brachytherapy needles. In the case of PET-CT imaging, needles were filled with fluorine FDG. PET-CT images were acquired at slice thickness of 5 mm from the base to apex of the capsule, while ultrasound images were acquired at 5 mm scan intervals. Acquired images were fused offline using MatLab developed fusion algorithm.

Results: The acquired ultrasound and PET-CT images were fused together as shown in Figure 1. Prostate brachytherapy needles inserted into the prostate capsule served the purpose of simulating brachytherapy seeds and also as guides in the image fusion. The needle spots showed on both ultrasound and PET-CT images, and hence, used as reference marks to undertake a feature fusion procedure. PET-CT image was made the reference image and ultrasound image as the spatially aligned floating image to undertake fusion by mutual information principle. Between the two images, ultrasound showed better delineation of the prostate capsule, while PET-CT image showed better visualization of the implanted needles. The output ultrasound-PET-CT fused image was of improved information and more useful than the individual images in performing prostate brachytherapy treatment planning.

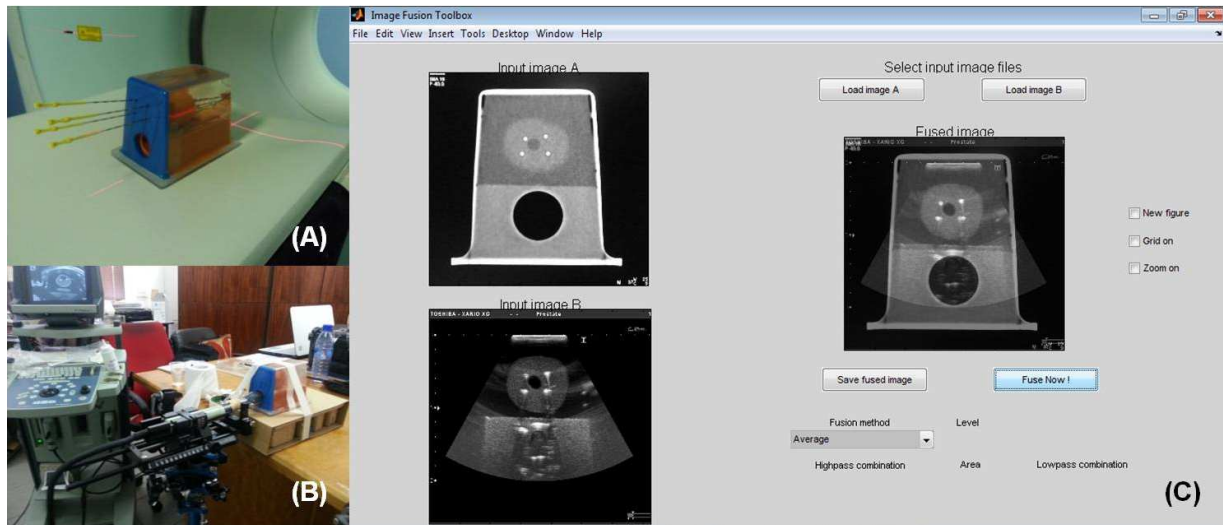


Fig. 1: Set up on PET-CT system (A), Ultrasound imaging (B), and Fused PET-CT and Ultrasound Image

Conclusion: Fusion of ultrasound and PET-CT images of the prostate provides single output image which contains a better delineation of the prostate capsule as well as implanted seeds. The resultant image is useful for a more accurate brachytherapy treatment planning, and hence better treatment outcome.

IAEA-CN-232/15

Quantitative Assessment of PET/CT Image Uniformity

F. Hasford¹, B. Van Wyk², T. Mabhengu², M. Vangu³, A.K. Kyere⁴,
J.H. Amuasi⁴

¹Medical Physics Department, School of Nuclear and Allied Sciences,
University of Ghana, P.O. Box AE 1, Accra, Ghana

²Department of Medical Physics, CM Johannesburg Academic Hospital,
Johannesburg, South Africa

³Nuclear Medicine Department, CM Johannesburg Academic Hospital,
University of the Witwatersrand, Johannesburg, South Africa

⁴Medical Physics Department, School of Nuclear and Allied Sciences,
University of Ghana, Accra, Ghana

Corresponding author: haspee@yahoo.co.uk

Background: PET-CT uniformity of a reconstructed image is measured to assess response of the PET-CT system to a homogeneous activity distribution in the axial and/or transverse field of view (FOV). Estimates of NU and CV give indication of the uniformity in the axial FOV.

Methodology: Equipment used for the study includes Siemens PET-CT Biograph system and Germanium phantom (68Ge / 68Ga source). Activity of Ge source at time of study was 0.676 mCi. Germanium phantom was mounted to PET-CT couch, positioned using lasers and axial PET-CT images acquired as shown in Figure 1. Estimation of quantitative index of non-uniformity was performed by drawing a circular area of 175 mm diameter centred inside the mid-transaxial slice of the phantom. Total of 177 orthogonal grids of square regions of interest, approximately 10×10 mm, were drawn on the selected slice inside the circular area.

Quantitative index of non-uniformity (NU) and coefficient of variation (CV) in the slice were estimated using Equation 1 and 2 respectively. Results for NU are presented in Table 1.

$$NU_{\text{slice} = i} = MAX \left\{ \begin{array}{l} 100 \frac{MAX(C_k) - AVE(C_k)}{AVE(C_k)} \\ 100 \frac{AVE(C_k) - MIN(C_k)}{AVE(C_k)} \end{array} \right\} \quad (1)$$

$$CV_{\text{slice} = i} = 100 \cdot \frac{SD_{\text{slice} = i}}{AVE(C_k)} \quad (2)$$

where

$$\text{Standard deviation, } SD_{\text{slice} = i} = \sqrt{\frac{1}{(N_{ROIs} - 1)} \sum_{k=1}^k (C_k - AVE(C_k))^2} \quad (3)$$

N_{ROIs} denote the number of the square ROIs inside the 175 mm diameter circle.

Results: The uniformity assessment in this study gave indication of the response of the PET-CT system

to a homogeneous activity distribution in the axial field of view.

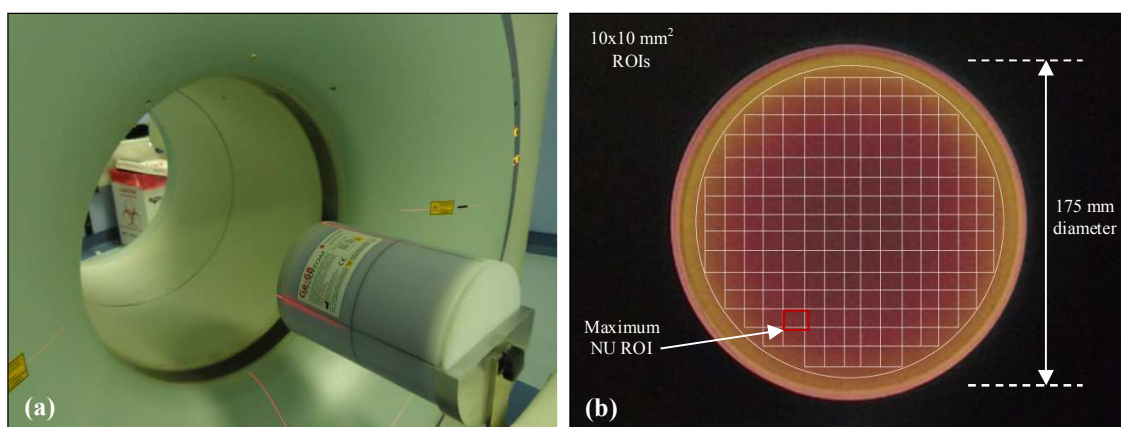


Fig. 1: PET/CT image uniformity: (a) 68Ge phantom under scanning and (b) image slice

Table 1: Non-uniformity estimation of PET/CT image

Region of Interest	Counts of Activity (C_k)			Non Uniformity (% NU)		Max NU (%)
	Max	Ave	Min	$100 \frac{\text{Max}(C_k) - \text{Ave}(C_k)}{\text{Ave}(C_k)}$	$100 \frac{\text{Ave}(C_k) - \text{Min}(C_k)}{\text{Ave}(C_k)}$	
ROI 1	107.0	88.2	75.0	21.26	15.01	21.26
ROI 2	100.0	89.3	76.0	12.01	14.87	14.87
ROI 3	105.0	87.7	66.0	19.75	24.73	24.73
ROI 4	99.0	88.4	77.0	12.03	12.87	12.87
ROI 5	100.0	87.6	78.0	14.14	10.97	14.14
ROI 6	104.0	89.6	75.0	16.03	16.32	16.32
ROI 7	101.0	88.5	78.0	14.11	11.88	14.11
ROI 8	101.0	89.7	78.0	12.59	13.05	13.05
...
ROI 155	119.0	92.5	59.0	28.60	36.24	36.24
...
ROI 177	107.0	87.7	72.0	21.95	17.94	21.95
Maximum NU (%)						36.24

Maximum non-uniformity was estimated as 36.24% in the 10×10 mm ROI 155 and the coefficient of variation in the entire axial image was 5.12%. By quantitative means, an accurate measurement of the uniformity is achieved.

Conclusion: Quantitative assessment of uniformity in the study provided the true state of the activity distribution in a homogeneous medium, which would otherwise be difficult predict qualitatively.

IAEA-CN-232/16

A Case of Unsuspected Sarcoidosis on PET/CT in Ovarian Carcinoma

M. Maharaj¹, A. Pirjol²

¹Umhlanga Molecular Imaging and Therapy: Centre of Excellence

²Amanzimtoti Oncology Centre

Corresponding Author: drmasha@yahoo.co.uk

Background: A 59 year old female presents with an abdominal mass. CT abdomen confirmed nodular cystic pelvic mass, estimated size of a 40 week uterus. Histology demonstrated a mucinous papillary tumour of the right ovary measuring 25 x 24cm, no serosal involvement. Clinical and histological stage 1 ovarian carcinoma. Post-surgical ICU CT chest demonstrated multiple mediastinal lymph nodes, perihilar and peribronchial densities and parenchymal nodules. Immediate post-surgery tumour markers were persistently elevated (CA 125 = 153). A PET/CT scan was indicated for staging.

Methodology: 350MBq 18F-FDG was administered IVI to the patient. Images were acquired 60minutes post injection. Standard fasting and preparation was followed. PET/CT was acquired.

Results: Multiple FDG avid osseous lesions were seen. Multiple FDG avid pulmonary lesions were seen in bilateral hilar regions, perihilar infiltrates and right upper lobe opacities. SUVmax range 2.76- 8.09. The features were suggestive of metastases.

The clinical and primary staging were discordant to the extent of FDG avid pathology.

The patient was clinically stable and subsequent tumour biomarkers were normal (Ca 125 = 27). Bone biopsy and bronchoscopy were done. Bone biopsy revealed non-caseating granulomatous tissue consistent with sarcoidosis.

Conclusion: The imaging features of sarcoidosis are diverse and can be seen on a variety of imaging techniques. Sarcoidosis or sarcoid reactions, which appear as FDG-avid lesions in oncologic patients, need to be differentiated from disseminated malignancies.

Any discrepancy or discordance in presentation (clinical and biological) and scan findings warrants histological correlation as demonstrated in our patient.

IAEA-CN-232/18

FDG-PET in Hodgkin's Disease Evaluation: Characteristics of the Population Referred between 2003 to 2014

J. Jofre¹, L.T. Massardo², P. Sierralta³, J. Canessa³, I. Gallegos⁴,
R. Fernandez⁴

¹Military Hospital- Santiago-Chile

²Military Hospital- University Of Chile Clinical Hospital

³Military Hospital- Dipreca Hospital

⁴University of Chile Clinical Hospital

Corresponding Author: mjjofre@gmail.com

Background: It is well known that metabolic imaging with FDG PET scan is very helpful in Hodgkin lymphoma (HL) assessment in initial staging, relapse, final and interim therapy control. Our goal was to characterize the population referred to FDG evaluation in patients with diagnosis of HL.

Methodology: We analysed our database since 2003 and obtained 510 FDG scans performed in patients with HL confirmed by biopsy. Some have a metabolic control up to 7 studies. We reviewed demographic data, histological subtypes and FDG indications.

Results: The group consisted of 321 patients between 3 and 83 y.o. (mean age: 31±16; 19% ≤18 y.o.); 52% females. There was no gender predominance in children. Age distribution and gender is displayed in Graphic A with a peak in younger adults.

There was a significant predominance of adult females with nodular sclerosis compared with mixed cellularity in all adults and also in younger adult females (p=0.009); the association was not observed in children or adults older than 35 y.o. Graphic B.

The immunohistochemistry subtypes and age are shown in Table 1 (NOS: no otherwise specified and LNPHL: lymphocytic nodular predominant HL). There was a trend to a lower proportion of adults than children with lymphocyte depletion (p=0.064).

Table 1	Classical HL					Non-classical HL
	Nodular sclerosis	Mixed cellularity	Lymphocyte predominant	Lymphocyte depletion	NOS	LNPHL
3-18 y.o.	50.0%	33%	0%	10.0%	3.3%	3.3%
>18 y.o.	63.2%	27.1%	3.5%	2.1%	0.7%	3.5%

FDG was requested due to staging in 6.8%; restaging in 30.3% and therapy control in 62.5%.

Therapy control was performed in 28% of the cases within 1 month post-chemotherapy; in 29% at 2 months, in 22% at 3 and in 13% at 4 months. Interim control was 32.5%. Our cases with radiotherapy, performed between 1 to 4 months prior FDG, did not present difficulties in the final interpretation due to active actinic inflammatory processes.

Initial staging patients were younger than restaging cases: 23.9 vs.31.8 years (p=0.005).

Regarding FDG results, 24 patients had a bulky mass in mediastinum or neck with marked positive uptake. Staging studies were positive in all with almost 100% concordance with anatomical images; the test found new foci with subsequent upstaging in some cases.

Restaging was performed between 4 months and several years post diagnosis; some cases with a clear suspicion of relapse. FDG was positive in 51%, with overall concordance with anatomical images of 71% (kappa: 0.295). Re-upstaging was also observed.

In final or interim therapy control, FDG reports were positive in 47 %. The concordance with anatomical images was 69.1% (kappa: 0.337).

In 22 cases, FDG was performed prior to bone marrow transplant and in 18 post-procedure; FDG was positive in 61.1% and 68.1% respectively (p=ns).

There was an important proportion of metabolic follow-up without computed tomography.

Conclusion: FDG was very helpful in staging, restaging and therapy control in all our HL patients. This population was similar to the one described in the literature as well the histological subtypes. Serial restaging with FDG was observed in cases without anatomical images or with negatives ones.

IAEA-CN-232/19

**Non-Hodgkin Lymphoma Experience with FDG PET:
Sample Description, Test Indications and Tumour Histology**

R. Fernández¹, T. Massardo¹, J. Jofré², P. Sierralta³, J. Canessa², I. Gallegos⁴

¹Hospital Clínico Universidad de Chile

²Hospital Militar Santiago, Chile

³Hospital Militar Santiago, Chile.

⁴Hospital Clinico Universidad de Chile

Corresponding Author: dr.renefernandez@gmail.com

Background: Fluorine-F18-deoxyglucose (FDG) imaging has shown to be a fundamental tool in non-Hodgkin lymphomas (NHL) assessment worldwide, although its high cost has limited the appropriate use of this technique. In diffuse large B cell and follicular NHL it is extensively utilized for initial staging, restaging and for treatment response assessment. In the case of peripheral T cell and mantle cell lymphoma which exhibit more variable uptake, the use of this technique is somewhat controversial. Intratherapy monitoring (interim) has shown great prognostic value in several types of NHL; whereas, monitoring for relapse is currently not recommended. Chile is a developing country where the use of PET FDG in lymphomas is not covered by private health insurance system, while in the public health system the coverage is limited to some conditions. Our goal was to characterize our NHL population referred for FDG evaluation, in order to assess demographic patient data, indications and histology.

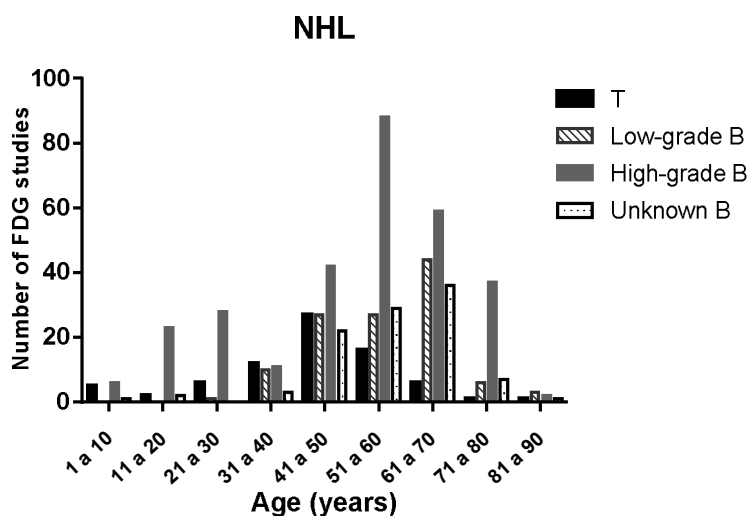
Methodology: We analysed our FDG database and collected all studies from NHL patients, since 2003. We obtained 757 scans corresponding to 488 patients, ranging from 6 to 94 y.o.; 55 % males. NHL histology was not otherwise specified (NOS) in 128 patients.

Results: There were only 23 patients younger than 19 y.o. with a mean age of 13 y.o.; adults mean age was 51 y.o. Gender was not different between adults or children ($p=ns$). We included 71 studies for staging (9.4%); 319 for restaging (42.1%); 367 for therapy control (48.4%) and only 63 corresponded to studies for interim imaging.

Control therapy patients were younger than restaging ones ($p=0.040$); no age difference was found between staging and restaging.

Histological distribution according to age is displayed in Figure A.

Figure A



T cell NHL patients were significantly younger than all other groups; see Table 1. No cases of low-grade B cell NHL were observed in children; all of them were adults (Fisher test: $p=0.045$).

Table 1 Histology	NHL B			NHL T	NHL NOS
	High Grade	Low Grade	Non-Classified		
Patients	195	69	61	35	128
Age (years)	53±18 ^{&}	58±12 [#]	55±14 [§]	45±18 ^{&*\$%}	52±17 ^{#%}

[&] $p=0.009$; ^{*} $p<0.0001$; [#] $p=0.019$; [§] $p=0.003$; [%] $p=0.023$

FDG positive results for malignancy according to histological subtypes and indications are shown in Table 2. FDG studies were less positive in restaging and final therapy control patients with low-grade than high-grade B cell NHL.

Table 2 FDG Positive studies	NHL B			NHL T	NHL NOS
	High Grade	Low Grade	Non-Classified		
Initial Staging	91.6%	80%	86%	90%	80%
Restaging	53.7% [*]	34.6% [*]	38.5%	51.5%	55.2%
Therapy Control					
Interim	64.7%	72.7%	66.6%	40%	25%
End	54.5% [#]	31.4% [#]	51.3%	46.4%	50.8%

^{*} $p=0.028$; [#] $p=0.023$

In 21% of the studies, FDG found new foci of unknown origin; concordance with anatomical images was 68% ($\kappa=0.29$) when there was available data, in 394 studies. Metabolic follow-up without anatomical images was common.

Conclusion: These results demonstrate the utility of FDG PET for assessing NHL in our media, independent of the histologic type and stage, and also emphasize the importance of a baseline study, especially for staging NHL with lower or variable uptake, which is also critical for adequate interim and final therapy control. Our group included mostly adults, with a higher proportion of high grade B cell NHL, studied for restaging and therapy assessment and less for staging. We did not have available a considerable proportion of histological and anatomical data with important information for reporting.

IAEA-CN-232/20

Hodgkin Lymphoma FDG Staging: Relationship of Tumour Uptake and Histological Subtypes in Classical and Non-Classical Variants

J. Jofre¹, T. Massardo², P. Sierralta³, J. Canessa⁴, C. Salvo⁵, I. Gallegos⁶

¹Hospital militar de Santiago

²Hospital clínico universidad de chile

³Military hospital- Dirpeca hospital

⁴Military hospital- Dipreca hospital

⁵Navy hospital

⁶University of Chile Clinical Hospital

Corresponding Author: mjjofre@gmail.com

Background: The most common Hodgkin lymphoma (HL), the classical variant, includes nodular sclerosis (NS), mixed-cellularity (MC) and lymphocyte-depletion (LD); the last is uncommon and associated to HIV. The non-classical variant is the nodular lymphocyte predominant subtype (NLPHL) corresponding only to 5%, observed mainly in males in their 4th decade, with a different biological behavior and better prognosis. There are controversies as to its therapeutic approach (it is more indolent but presents more relapses).

Our goal was to assess the relationship of tumour uptake with histological subtypes in HL classical and non-classical variants.

Methodology: We analysed the experience in HL staging, since 2003; we found 35 cases from 513 FDG scans and compared their clinical/anatomical stage pretest with FDG results and the histological subtype with the SUVmax.

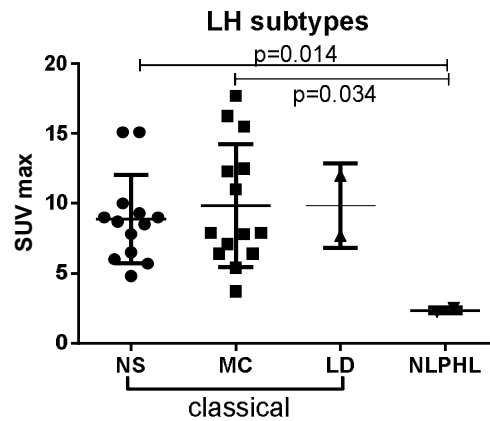
Results: The group corresponded to 18 adult patients and 17 children or adolescents (≤ 18 y.o.) between 3 and 79 y.o. (mean age: 24 ± 17); female gender was 29% in children and 61% in adults ($p = ns$). In the younger patients, there were 6 NS cases, 5 MC, 1 LD and 1 NLPHL and 4 not otherwise specified (NOS) subtypes; in adults, 9 MC, 7 NS, 1 LD and 1 NLPHL.

The pre-scan stage varied between IIA to IV; 65% presented up-stage with FDG including the 2 cases with LD and 1 NLPHL.

SUVmax in the most active lesion were 7.5 ± 2.1 in children and 10.2 ± 4.5 in adults ($p = 0.03$); NS and CM SUVmax were similar ($p = ns$). NS and CM were significantly higher than NLPHL as seen in the graphic below.

All cases were reported as positive, however, the patients with NLPHL (18 and 21 y.o. young males, both with cervical masses submitted to surgery, in one recently and the other, several months ago), one with mild diffuse cervical uptake and the other with a small cervical focus, interpreted both as possibly malignant tissue. Regarding NLPHL follow-up, the older patient was treated with standard chemotherapy, with a new PET positive showing 2 new cervical foci; he received more chemotherapy and then radiotherapy, with a negative FDG, 8 months after diagnosis. The younger patient with a resected bulky cervical mass using oncological criteria and no malignant lymph node involvement received also chemotherapy because of his initial positive FDG, despite having a normal computed tomography scan; a normal FDG was obtained 2 months later.

As expected, in the follow-up of classical HL, 86.3% were negative in their first metabolic control.



Conclusion: NLPHL was present in approximately 6% of our sample, similar to data reported, in younger males. FDG uptake was rather low, significantly inferior to the one observed in the classical HL. This feature is important to be remembered in order to improve the report accuracy and to perform strict follow-up. Immunohistochemistry is necessary to confirm the diagnosis; the tumour could change to other patterns or to B cell lymphoma.

IAEA-CN-232/21

Tailoring Therapy for Benign Thyroid Disease in Private Practice

M. Maharaj

Polokwane University

Corresponding Author: drmasha@yahoo.co.uk

Background: Targeted radionuclide therapy has the potential to selectively deliver radiation to diseased cells with minimal toxicity to surrounding tissues. The cost of radiopharmaceutical, travel, pre- and post-management has serious financial implications on the private patient.

The aim is to reduce the costs by providing effective single dose therapy using a simplified clinical and scintigraphic-based model. The total cost with average 4 visits over 12 months can be over R24000.

Previous protocol for benign thyroid therapy was radioactive iodine (RAI) administered by radiation oncologists and did not require thyroid uptake scans. The doses started from 148MBq and escalated to 296MBq and 444MBq, depending upon patient's clinical response and biochemistry, with at least 50% of patients receiving 2nd and 3rd doses.

Methodology: 12 patients (11 female and 1 male; average age 48.25 years) were referred to our centre over a period of 8 months (September 2013 - April 2014) for thyroid uptake scans and subsequently for benign thyroid therapy for hyperthyroidism. Thyroid uptake scans were done with 185MBq Per technetate. Pre- and post-injection syringes were counted for uptake measurements. Anterior, left anterior oblique and right anterior oblique images were done 20 minutes post-injection with pinhole collimator. Normal reference range used for uptake was 0.75-4.0%. Five criteria were used to tailor the dose: size of gland, distribution of activity, percentage thyroid uptake, sex of patient and age of patient. Using these criteria the minimum dose given would be 185MBq and maximum 555MBq. Response of therapy was confirmed clinically and on biochemistry based on clinical signs and symptoms of hypothyroidism and/or thyroid function tests (hypothyroid or euthyroid). This was assessed at 3 months and 6 months follow-up post-radioactive iodine administration.

Results: There was confirmed single dose response in 11 of the 12 patients. At 3 months one patient remained hyperthyroid but response was confirmed after the 2nd capsule. At 3 and/or 6 month (biochemistry and clinically confirmed) follow up 5 patients were euthyroid and 7 patients were hypothyroid started on Eltroxin therapy.

Discussion:

The main objective of radioiodine (¹³¹I) therapy of benign thyroid diseases is the treatment for hyperthyroidism aiming at euthyroidism or hypothyroidism recompensated by thyroxin medication avoiding the complications of hyperthyroidism. Guidelines have described complex methods using anatomical or compartment models and computational methods to calculate radioiodine dose. Some authors have recommended fixed doses. There has been a trend toward applying patient-specific dose calculation methods. In theory this should incorporate patient demographics, clinical presentation and scintigraphy pattern.

Conclusion: There appears to be a benefit in applying a simple clinical and scintigraphic-based model to achieve single dose patient-specific radionuclide therapy for benign thyroid disease. In view of the limited number of patients similar studies are needed to verify the reproducibility of the model.

IAEA-CN-232/22

Our Experience with 18F-FDG and Oral Propranolol to Minimize Brown Adipose Tissue (BAT) Uptake

P. Sierralta¹, J. Jofre², J. Canessa³, T. Massardo⁴

¹Hospital militar de Santiago-Chile

²Hospital Militar de Santiago

³Hospital Militar de Santiago / DIPRECA- Chile

⁴Hospital Clínico Universidad de Chile

Corresponding Author: teresamassardo4@gmail.com

Background: Classical non-shivering thermogenesis as well as cold acclimation-recruited, norepinephrine-induced thermogenesis, is brown adipose tissue (BAT) dependent. This tissue is able to increase the rate of FDG PET false positives in young patients, mostly females exposed to low temperatures before the scan. Brown adipocytes could mimic lymph nodes, mainly in the scapular girdle but they could be present even at perinephric level and not always symmetrical. Room and local temperature management and propranolol, diazepam or reserpine have been advocated as helpful. The goal was to assess the impact of propranolol diminishing FDG BAT uptake in a country with important daily temperature variations, more pronounced in summer.

Methodology: We reviewed the experience with BAT in 6.000 whole body FDG PET scans, since 2003 to date and we found 41 cases; they were evaluated according to their typical pattern and intensity and 23 meriting a repetition were cited 2 days later to complementary images after 40 or 80 mg of oral propranolol, administered 2 h prior to scanning. All patients in our centre are advised of adequate warming, especially if they already presented the problem. The repetition was with lower FDG injected activity, depending on weight.

Analysis: We compared the uptake intensity (mild, moderate or intense) and distribution of brown fat in all images.

Results: The whole group age was 27±16 (range: 7-78) years old, 65.9% of them females. There was no statistical difference in age or gender between groups with or without propranolol. The group repeated after propranolol included 78.2% of lymphoma patients (78 % Hodgkin disease); the group without repetition corresponded in 44.4% to lymphomas (63% Hodgkin); there was a difference between groups regarding the proportion of lymphomas versus other malignancies (p=0.019). One female with Hodgkin disease was evaluated twice in different controls with 40 and 80 mg of propranolol, respectively, with similar results.

BAT distribution was, as seen in the Table, mostly bilateral and symmetrical, without gender difference.

- Cases without propranolol: the uptake was mild in 11/18 (61%) and moderate in 6/18 (33%) patients not requiring repetition and intense just in 1/18 (6%); one middle age Hodgkin disease female was reported as doubtful, in a right cervical focus.

- Cases with propranolol; they initially presented moderate uptake in 17/23 (74%), mild in 3/23 (13%) and intense in 3/23 (4%) at brown fat possible location; in 2 patients the intense uptake corresponded to pathological lymph nodes because it did not change after the beta-blocker; one of those lymphomas

progressed in a further control. All the resting 21 cases uptake in BAT distribution disappeared completely (90%). No adverse effects were observed.

BAT distribution in the group	Number (%)
Scapular girdle	30 (73%)
Paravertebral (low dorsal)	20 (49%)
Cervical (higher or lower)	11 (27%)
Mediastinum	5 (12%)
Supraclavicular	5 (12%)
Infraclavicular	3 (7%)
Axillar	2 (5%)
Others: perihepatic, perisplenic, deltopectoral, intercostal	4 (10%)

Conclusion: Propranolol use helped us in selected cases, when warming instructions were not enough, to avoid BAT activation. Even though, increasing radiation dose in young oncological patients is not recommended, it is advisable to perform a good quality control and complementary images in a different day, if necessary, to report adequately.

IAEA-CN-232/23

18F-FDG PET/CT in Differentiating Dementias

**N.E. Kerik Rotenberg, I.E. Diaz Meneses, A. Reynoso Mejia,
S. Rosas Gonzalez**

National Neurological and Neurosurgical Institute, Mexico

Corresponding Author: nora.kerik@hotmail.com

Background: The clinical identification and differential diagnosis of dementias is challenging especially in the early stages, only a probable diagnosis can be reached.

Dementia is not a single nosological entity, and many types of dementia exist (Alzheimer disease, dementia with Lewy bodies, frontotemporal dementia, Creutzfeldt-Jakob dementia, etc).

Molecular neuroimaging techniques can be very useful in dementia patients, especially with the most diffuse and available radiotracer 18F-FDG.

18F-FDG is a glucose analog that allows the evaluation of the glucose brain metabolism that is an index of brain perfusion, brain activity, and synaptic density.

The utility of 18F-FDG in primary neurodegenerative dementias resides in the possibility of finding specific patterns that could aid in the diagnosis and in the differential diagnosis.

The aim of this paper is to report 18F-FDG patterns of the principal forms of neurodegenerative non-Alzheimer dementia and Alzheimer dementia at the National Neurological and Neurosurgical Institute in Mexico City, between 2013-2015.

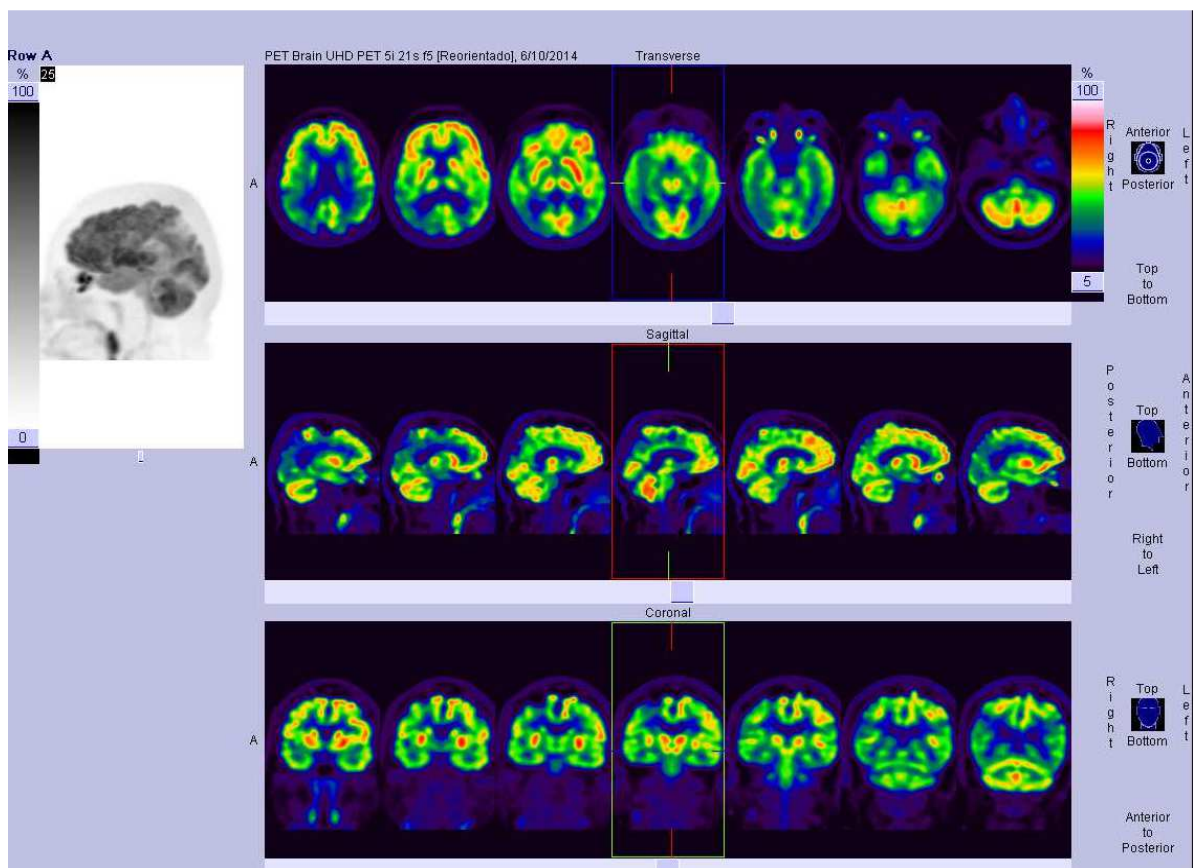
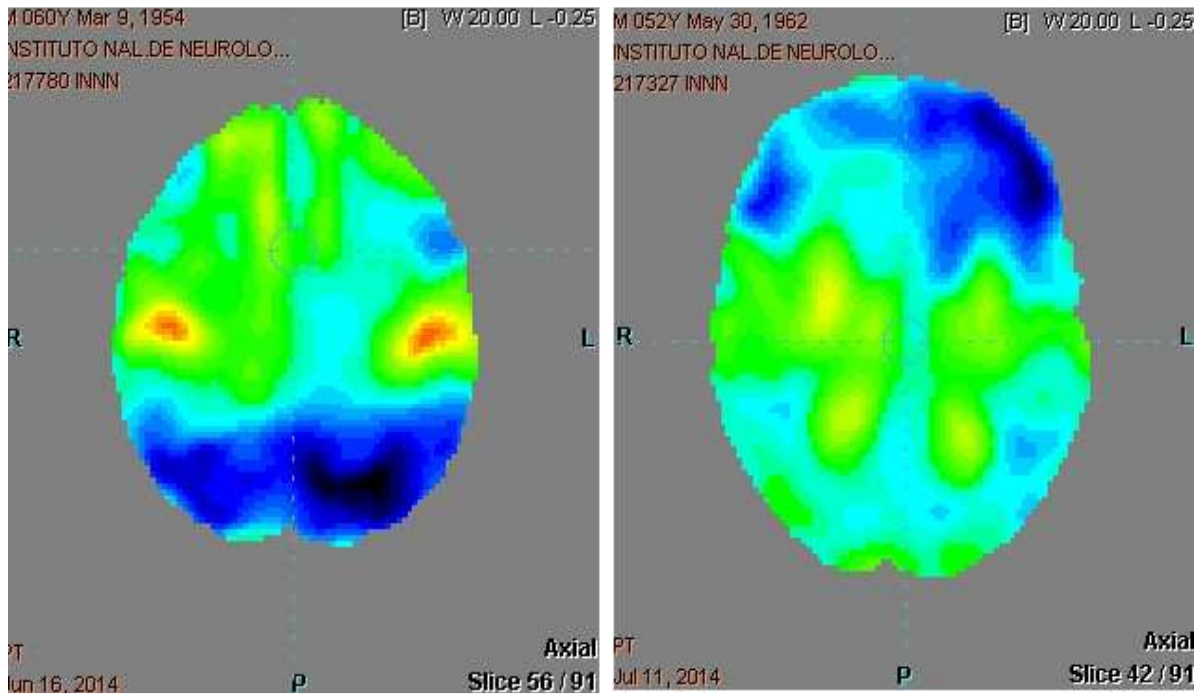
Methodology: Retrospective study from November 2013 to December 2014. Sixteen (16) patients were assessed and referred by an expert of dementia clinic to the Molecular Imaging Unit. All subjects underwent 18F-FDG-PET-CT scan (Biograph 64 mCT Siemens, with 4 mm spatial resolution).

The studies were performed as a single 8 min scan acquired 30 min after intravenous injection of 185 MBq (0.5 mCi) of 18F-FDG in a quiet, dimmed light room.

Studies with both visual assessment and surface-rendered statistical maps on reference data from healthy control subjects were included for review (brain mapping). Such studies have become part of current clinical practice.

Results: On the sixteen studies (one per patient), five were normal, and eleven were abnormal. Of the sixteen studies, from seven patients, three were positive and four negative in frontotemporal dementia. Three were positive and one negative in Lewy Body dementia. For Creutzfeldt -Jakob, both of them were positive. And for Alzheimer dementia four out of four were positive.

International Conference on Clinical PET-CT and Molecular Imaging (IPET 2015): PET-CT in the Era of Multimodality Imaging and Image-Guided Therapy



Conclusion: ^{18}F -FDG PET is an effective and safe modality to identify diagnostic patterns of glucose hypometabolism in neurodegenerative dementias as in non-Alzheimer dementias being an effective tool for diagnostic information in the assessment of patients with cognitive impairment.

IAEA-CN-232/24

Initial Clinical Experience with 11C-DTBZ PET for Movement Disorders at the National Institute for Neurology and Neurosurgery of Mexico

I. Diaz, N. Kerik

National Institute Of Neurology and Neurosurgery Of Mexico

Corresponding Author: iedm0978@yahoo.com.mx

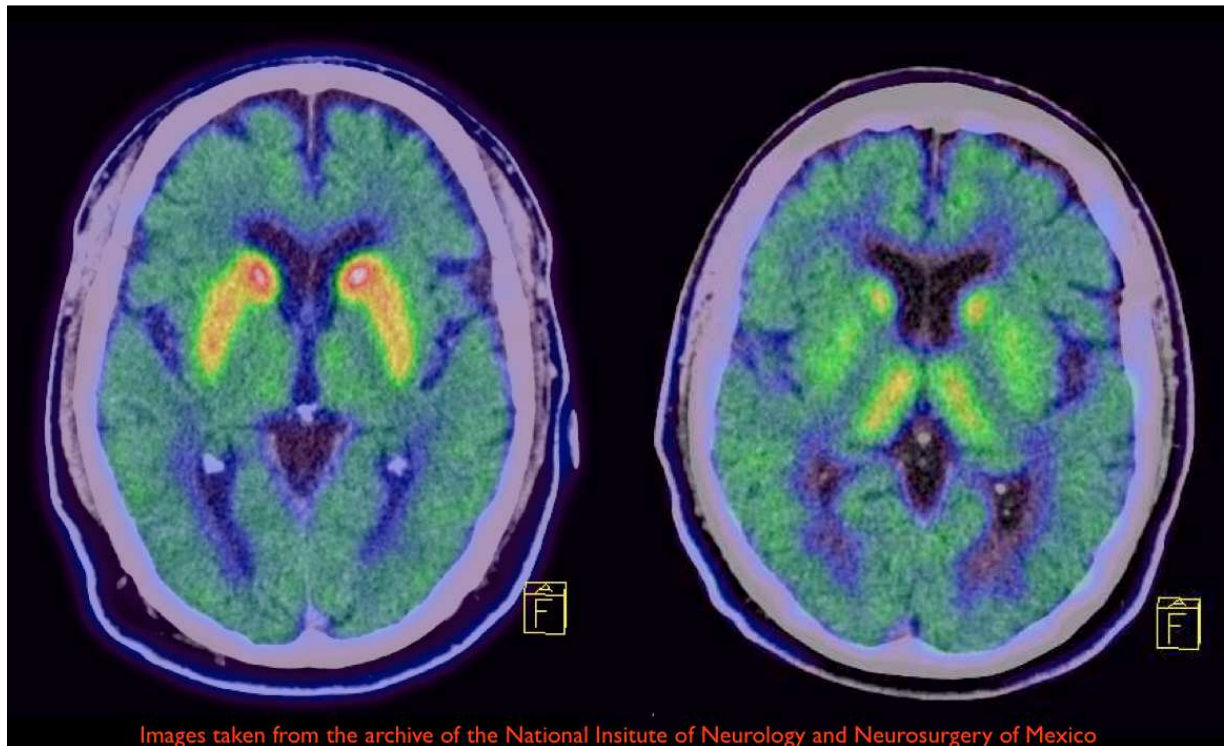
Background: Parkinsonism is a generic term for several clinical entities semiologically characterized by bradykinesia, gait disturbances, postural instability, rigidity and tremor. Precise definition of the etiology of parkinsonism by clinical data and structural imaging is complicated, especially in early stages. Thus, in most cases the follow up and the subsequent development of a more conspicuous clinical picture is needed to reach a definite diagnosis. The radiotracer 11C-Dihydrotetrabenazine (DTBZ) enables molecular imaging of vesicular monoamine transporters type 2 (VMAT2) in presynaptic neurons which have different patterns of affection depending on the cause of parkinsonism.

Methodology: This retrospective series of twelve cases took place in a neurological centre with academic, assistant and research functions, from July 2014 to December 2014. The subjects were assessed and referred by neurology experts in movement disorders to the PET/CT molecular imaging unit to perform 11C-DTBZ PET studies. The reason for performing PET/CT was differential diagnosis between following clinical entities: Parkinson's disease, multiple system atrophy, essential tremor, dementia with Lewy bodies, conversive psychiatric disorder and corticobasal degeneration.

Studies were acquired on a hybrid PET/CT device (Biograph mCT, Siemens), which provides a clinical spatial resolution of 4 mm. For the study, the images were acquired with a static and sequential protocol as follows: the first image was of 1 minute, followed by 4 images of 5 minutes each, an image 10 minutes, and finally an image of 15 minutes. These images were immediately initiated after the administration of +/- 15 mCi (555 MBq) of the radiotracer and proper patient fixation to prevent movement of the head during the study. A non-contrast enhanced CT scan with brain parameters was performed for purposes of attenuation correction and anatomic localization.

Images of maximum intensity projection (MIP) and fused tomographic images of the basal ganglia were reviewed (in that order) in a workstation by two nuclear medicine physician experts in neurological nuclear medicine studies. The assessment of the imaging findings was qualitative and categorized as normal and abnormal.

Results: Out of the twelve studies (one for patient), five were normal and seven were abnormal. In the five studies that were normal the final diagnosis was essential tremor. For the seven abnormal studies the final diagnoses were Parkinson's disease in four, Lewy body dementia in one, and multiple system atrophy in two cases. In all cases, the 11C-DTBZ PET imaging findings were useful for the differential diagnosis. None of the studies was inconclusive. An agreement between readers was present in all the studies.



Conclusion: The clinical use of ^{11}C -DTBZ PET as a biomarker of presynaptic monoaminergic nigrostriatal integrity has allowed for a more accurate and more precocious diagnosis in patients with parkinsonism.

IAEA-CN-232/25

The “Raven Sign”: A Case of Apical Left Lung Herniation into the Superior Area of the Right Lung Detected on Tc-99m MAA Lung Perfusion Scintigraphy in a Paediatric Pulmonary Tuberculosis Patient

R. Heredia, E. Limlingan, V.P. Magboo, R.A. Conlu

Section of Nuclear Medicine, University of Santo Tomas Hospital

Corresponding Author: chardx_04@yahoo.com

Background: Lung hernia is a rare finding, described as the protrusion of the lung tissue outside the pleural cavity. Lung perfusion scintigraphy is used for pre-operative assessment of high-risk patients prior to pneumonectomy.

Methodology: This is a case report of a 7-year old girl who presented with pulmonary tuberculosis-destroyed right lung and compensatory hyperinflated left lung. She underwent lung perfusion scintigraphy prior to her contemplated right lung pneumonectomy.

Results: Her lung scan exhibited segmental/subsegmental perfusion defects in the anterior and superior lingual lobes of the left lung while the right lung appeared non-functional with demonstrable absent perfusion except for the tracer activity appreciated in its superior area. This represented the apical left lung hernia.

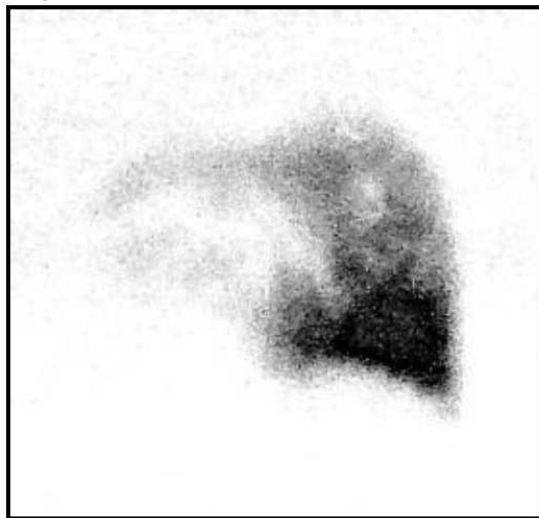


Figure 1. The “Raven Sign”

Conclusion: The apical left lung herniation into the superior area of the right lung produced a static anterior image similar to the face of a raven. Therefore, I named it the “Raven Sign”.

IAEA-CN-232/26

Clinical Translation of ^{68}Ga -PRGD2 PET/CT and $^{99\text{mTc}}$ -3PRGD2 SPECT/CT for Integrin Receptor Imaging

Z. Zhu, F. Li, X. Jin, C. Wu, K. Zheng

Peking Union Medical College Hospital, Chinese Academy of Medical Sciences and
Peking Union Medical College

Corresponding Author: zhuzhh@pumch.cn

Background: High-level $\alpha\text{v}\beta 3$ -Integrin expression has been found in a variety of diseases correlated with angiogenesis. Novel integrin receptor imaging approaches, ^{68}Ga -PRGD2 PET/CT and $^{99\text{mTc}}$ -3PRGD2 SPECT/CT, were translated into clinical use to evaluate angiogenesis in malignancies, ischemic diseases, and chronic inflammation.

Methodology: With institute review board approval and written informed consent, ^{68}Ga -PRGD2 PET/CT was performed in 64 patients with suspicious lung lesions, 12 patients with glioma, 23 patients after myocardial infarction, 16 patients after stroke, and 20 patients with rheumatic arthritis; $^{99\text{mTc}}$ -3PRGD2 SPECT/CT was performed in 65 patients with suspicious lung lesions and 40 females with suspicious breast lesions. Most patients underwent $^{18\text{F}}$ -FDG PET/CT within a week for comparison.

Results: No side effect related to the ^{68}Ga -PRGD2 or $^{99\text{mTc}}$ -3PRGD2 injection was reported in these patients. Compared with $^{18\text{F}}$ -FDG PET/CT, ^{68}Ga -PRGD2 PET/CT showed more specificity in assessing lymph node metastasis and similar efficacy in diagnosis of primary lung cancer. ^{68}Ga -PRGD2 accumulation level in glioma was significantly correlated with the tumour grading ($P=0.001$). ^{68}Ga -PRGD2 accumulation was found at or around the ischemic regions in 20/23 MI patients and 8/16 stroke patients, with the accumulation levels correlating with the disease phase and severity. In the rheumatic arthritis patients, ^{68}Ga -PRGD2 specifically accumulated in the synovia and tendon sheath with active inflammation with rich neovasculature, but not in the $^{18\text{F}}$ -FDG-avid inflammatory lymph nodes. $^{99\text{mTc}}$ -3PRGD2 SPECT/CT also showed a significantly higher value than $^{18\text{F}}$ -FDG PET/CT in assessing lymph node metastasis ($z=8.0$, $P<0.001$), which highlighted a significantly higher specificity (94.6% versus 75.0%, $P=0.004$), whereas no significant difference was found between the two methods ($P=0.410$) for differentiation of the lung lesions. The late-stage NSCLC had significantly higher $^{99\text{mTc}}$ -3PRGD2 accumulation ($P<0.05$) but similar $^{18\text{F}}$ -FDG uptake. $^{99\text{mTc}}$ -3PRGD2 imaging also showed advantages in response evaluation of lung cancer. $^{99\text{mTc}}$ -3PRGD2 SPECT/CT also showed high sensitivity in detection of breast cancer and evaluation of its metastatic characteristics.

Conclusion: Integrin receptor imaging with ^{68}Ga -PRGD2 PET/CT or $^{99\text{mTc}}$ -3PRGD2 SPECT/CT seems to be safe and efficient in diagnosis and evaluation of angiogenesis-related diseases.

IAEA-CN-232/28

**Comparison of Hybrid Positron Emission Tomography with
Computed Tomography and Multidetector Computed
Tomography in the Detection of Metastases in Non-Small Cell
Lung Cancer**

**S. Odalovic¹, V. Obradovic²; D. Sobic Saranovic³, I. Petrusic⁴, V. Artiko³,
I. Grozdic Milojevic¹**

¹Center of Nuclear Medicine Clinical Center of Serbia

²Clinical Center of Serbia

³Center of Nuclear Medicine Clinical Center of Serbia, Faculty of Medicine
University of Belgrade

⁴Faculty of Medicine University of Belgrade

Corresponding Author: dsobic2@gmail.com

Background: Treatment planning in patients with non-small lung cancer (NSCLC) requires accurate staging of disease. Integration of positron emission tomography (PET) and computed tomography (CT) increases diagnostic performance in the evaluation of disease staging.

Objective: Comparison of the findings of PET/CT and multidetector CT (MDCT) in the detection of metastases and the staging in NSCLC.

Methodology: We compared findings of MDCT and PET/CT in patients with NSCLC, which were obtained for a period not exceeding one month. In PET/CT, the conclusion criteria for a malignant change was a SUV=2.5. Interpreting the findings we were determining stage and TNM classification. Particularly, we compared findings of distant metastases in the lymph nodes, bones, and adrenal glands.

Results: A total of 83 patients matched the criteria in our study. Findings on the PET/CT and MDCT showed that the two methods differ in the staging of patients with NSCLC ($\kappa=0.084$, $p=0.439$). Statistical analysis showed that there was moderate agreement between these two methods in determining the class T ($\rho=0.531$, $p<0.001$), and poor agreement in determining the class N ($\rho=-0.009$, $p=0.933$) and class M ($\rho=0.252$, $p=0.021$). Poor agreement was also found in the detection of metastases in the lymph nodes on ipsilateral side of the mediastinum ($\rho=0.351$, $p=0.001$), and for the detection of metastases in the lymph nodes on the contralateral side of the mediastinum and supraclavicular nodes ($\rho=0.012$, $p=0.913$). Similar was shown in the detection of metastases in distant lymph nodes ($\rho=-0.090$, $p=0.416$), lung ($\rho=0.260$, $p=0.018$), bones ($\rho=0.116$, $p=0.295$), and adrenal gland ($\rho=0.302$; $p=0.006$).

Conclusion: PET/CT integrates the advantages of PET in the evaluation of the metabolic status of the cell and CT, which enables anatomical localization and change measurements. MDCT has the advantages of better resolution power display of anatomical structures. In comparison to MDCT findings, PET/CT is better in evaluating metastases in contralateral, supraclavicular and distant lymph nodes, with more precise N3 staging. PET/CT is also better in evaluating distant metastases in bones and suprarenal glands, implicating better staging of patients with NSCLC, as well as treatment planning.

IAEA-CN-232/29

Impact of Intravenous Contrast Medium on Hybrid PET/CT Images in Lymphoma Patients: Experience at PET/CT and Cyclotron Center Chiang Mai University

T. Kaewchur

Faculty of Medicine Chiang Mai University, Thailand

Corresponding Author: tkaewchur@gmail.com

Background: The intravenous contrast medium is used for clinical evaluation of the residual disease and also helps in the differential diagnosis of the new lesion, it also clearly identifies the anatomical structure. However, the attenuation correction with post-contrast CT may cause an overestimation of SUV which impacts on the interpretation. The aim of this study is to assess the influence of intravenous contrast medium on clinical and quantitative evaluation in lymphoma patients.

Methodology: Twelve lymphoma patients, who underwent whole body PET/CT using intravenous contrast medium, were enrolled into this study. PET images were reconstructed with non-contrast CT and post-contrast CT images under the same reconstructed protocol. The CT attenuation (HU), mean and maximum standardized uptake value (SUV_{mean} and SUV_{max}) were measured in the same region and same size of ROI at the subclavian vein (ipsilateral to the injected side), descending aorta, liver, spleen and bone marrow. Deauville criteria scoring of each of the two data sets were also recorded. A paired student's t test was performed to evaluate the significant difference between these two reconstructed PET images.

Results: All sixty regions of interest in twelve lymphoma patients revealed statistically significant increase in SUV_{mean} and SUV_{max} on PET attenuation correction by using post-contrast enhanced CT images, compared to non-contrast images (all P value < 0.02). However, no difference of Deauville criteria scoring was found between these two reconstructed data sets.

Conclusion: Although intravenous contrast medium causes significantly increased SUV, there is no impact on Deauville criteria scoring in each patient. Non-contrast CT images for attenuation correction may be skipped to reduce radiation exposure in lymphoma patients.

IAEA-CN-232/30

An Overview of the Impact Caused by the Quality Management Audit in Nuclear Medicine Practices (QUANUM) at the Hospital Rafael Ángel Calderón Guardia

A.C Jiménez¹, J. Villalobos Rosales², G. Castro³, A. Alfaro⁴

¹ Hospital Calderón Guardia, CCSS

² Centro Médico Radioterapia Irazú

³ CCSS

⁴ Hospital Calderón Guardia

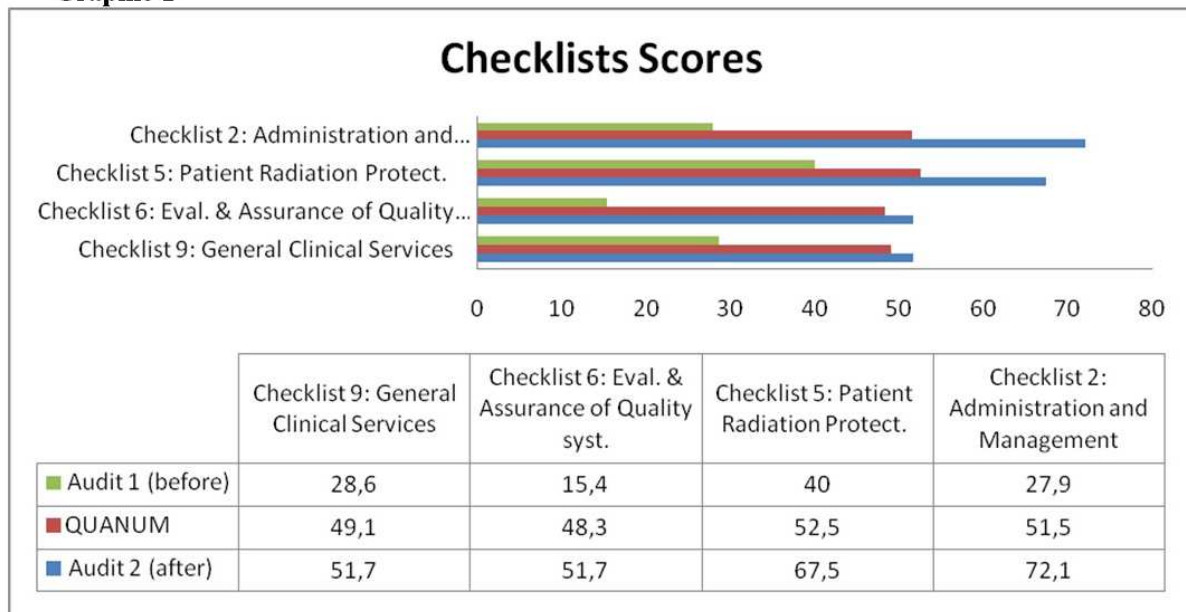
Corresponding Author: anacarojim@gmail.com

Background: Quality may be one of the most crucial parameters that differentiate an accurate or a wrong diagnosis, its tools ensure changes in the systems and processes which eventually result in superior quality images, therapies, and services in a nuclear medicine department. As part of the Project COS/9/007 “Strengthening of the Quality Management and Radiologic Protection in Nuclear Medicine in the Costa Rican Social Security” the IAEA Quality Management Audit in Nuclear Medicine Practices (QUANUM) was requested in our hospital. The aim of this study was to determine the impact that the QUANUM had in our Department of Nuclear Medicine.

Methodology: The QUANUM was held in May 19-23, 2014. An inner quality team was conformed in our department. All checklists were completed four months before the IAEA sent the expert team for the mission. A second inner audit was performed six months after the mission. All of the three audits were analysed and compared quantitatively. Other aspects outside the checklists were also considered and analysed.

Results: All of the scores showed some sort of improvement due to the implementation of the QUANUM, especially checklist number 2, 5, 6 and 9 (Graphic1). It had a positive impact on our staff while they learned more about quality processes. Each member from the expert team made its personal contribution by sharing experiences, ideas, and protocols from their countries and hospitals. We started to work more as a team and a quality responsible was designated after this visit, all workers also became interested in this topic, even one of our members decided to study a post-degree in quality management and hopefully we will have a quality manual soon. The QUANUM document report was vital to justify the need of structural improvements in the department, a project reshuffle with a radiopharmacy properly equipped and as twice as big is about to start in the coming months.

Graphic 1



Conclusion: The QUANUM is invaluable for learning and improving processes inside a nuclear medicine department; it is a tool that will help us guarantee an optimal nuclear medicine care. The quality audits are very important, because they can assess the effectiveness of different activities that constitute the quality system of an organization and the corrective and preventive action responses that will guide nuclear medicine departments in the right direction.

IAEA-CN-232/31

Feasibility of PET/CT in Costa Rica's Social Security System

G. Castro, A.C. Jimenez

Hospital R. A. Calderón Guardia

Corresponding Author: gabo16cm@gmail.com

Background: PET/CT is one of the diagnostic tools with the largest growth worldwide. It has been found to be cost-effective for different use purposes like tumour detection and differential diagnosis of benign and malignant tumours, tumour staging and prognostic stratification, evaluation of response to treatment, restaging and detection of recurrent cancer, radiation treatment planning and development of new anticancer drugs.

Methodology: To analyse the feasibility of PET/CT in Costa Rica, taking into account the leading causes of cancer mortality and incidence and also analyse the available human resources.

Results: Costa Rica has an approximate population of 4.5 million habitants. Cardiovascular disease and cancer are now leading causes of mortality.

In terms of cancer death in women in 2011, the first place corresponds to breast cancer with an adjusted rate of 10.39, followed by stomach with 7.86 and colon with 5.97, which shows a slight increase. Cervical cancer with 4.11 is on the fourth place. Leukemias take the fifth position with 3.73, followed by lung cancer with 3.46. Prostate cancer was first and stomach cancer second with respect to the mortality trend from cancer among men in the period 2000 to 2011. Lung and liver cancer show an upward trend in the last 3 or 4 years.

The health system in Costa Rica is based primarily on social security. There are three main hospitals with nuclear medicine departments, none of which have PET/CT already available. However, a project to install a cyclotron in the University of Costa Rica was already launched. The main question is how many PET/CTs should be installed because they represent costly diagnostic tests. There are some studies evidencing a high potential for PET/CT as a cost-effective approach for management of cancer, especially for staging of non-small cell cancer, differential diagnosis of solitary pulmonary nodules, restaging of Hodgkin disease and non-Hodgkin lymphoma, and restaging of colorectal carcinoma. From the point of social security health system, the use of PET in clinical practice seems justified. In the most common malignant tumours in our country, PET/CT has proven to be cost-effective.

In terms of human resources, our centres are partially prepared to respond to the needs of referring clinicians. There are three principal hospitals with nuclear medicine departments, and nine nuclear medicine physicians. Each department has at least one nuclear medicine physician with full postgraduate training programme in PET/CT of 3 years in duration as well as some nuclear medicine technologists and radiopharmacists.

Conclusion: More training in PET/CT is needed, but we have the right personnel and health system and with the support of organizations like IAEA our goals can be achieved.

The cyclotron installation will also enable for selling radiopharmaceuticals to other Central American countries and expanding the use of these technologies in developing countries.

IAEA-CN-232/32

Diagnostic Accuracy of 18F-FDG PET/CT in Recurrent Differentiated Thyroid Cancer

J. Mihailovic, N. Prvulovic, I. Majdevac, D. Manic

Oncology Institute of Vojvodina

Corresponding Author: jasnans@eunet.rs

Background: Despite the fact that differentiated thyroid carcinoma (DTC) has a good prognosis, 20–30% of patients develop recurrences during the follow-up. Standard diagnostic procedures for detection of recurrent DTC include increased Tg levels and/or positive results of imaging techniques [131I-WBS, US, CT, MRI]. However, about 30% of patients with recurrent DTC show rising serum Tg and negative 131I-WBS. In addition, DTC patients on suppressive treatment with rising Tg-Abs consequently show low Tg levels. During the last decade, 18F-FDG PET/CT was performed in the detection of recurrent DTC. Aim of the study: to assess the diagnostic accuracy of 18F-FDG PET/CT in DTC patients who were suspected of having recurrent disease.

Methodology: We retrospectively analysed 71 DTC patients with suspected recurrent disease. Inclusion criteria were: elevated Tg with negative or positive 131I-WBS, rising TgAbs, or patients with low Tg levels but abnormal findings of diagnostic procedures [cytology results after FNA, CT or MRI]. All patients underwent initial treatment including total thyroidectomy and radioiodine ablation, while some of them received additional radioiodine therapies. They were examined from January 2011 - January 2015 (42 females, 29 males; aged 22-78, mean 51.3 years) underwent 18F-FDG PET/CT examination. All patients had 131I-WBS-negative and Tg-positive results. Following at least 4 hour fasting, the patient's blood glucose was measured before examination. One hour following the injection of 18F-FDG, low dose CT images were obtained from the orbital meatal line through the mid-highs. PET images were obtained through the same region. Attenuation correction images were constructed using the CT scan. Fused images of PET and CT were interpreted independently by 2 nuclear medicine physicians and 1 radiologist as positive or negative 18F-FDG PET/CT finding.

Results: Forty one (57.7%) patients were not treated after 18F-FDG PET/CT, while 30 (42.3%) patients received additional treatment: 27 (38%) patients underwent surgery and had histological confirmation of recurrent disease (1 of those had additional external radiation), 1 patient was treated with radioiodine therapy, one patient received external radiation, while one patient received chemotherapy. 18F-FDG PET/CT scans were true positive in 31 (43.7%) patients, while both false positive and false negative in 8 (11.3%) patients. We found that 18F-FDG PET/CT had sensitivity of 80%, specificity of 75%, PPV of 79%, NPV of 75% and accuracy of 77%.

Conclusion: 18F-FDG PET/CT improves diagnostics of recurrent DTC. In patients with negative 131I-WBS and those with low Tg levels but rising TgAbs this imaging tool allows surgical treatment by precisely localizing tumour tissue. Early detection of recurrences improves management and outcome of DTC patients.

IAEA-CN-233/33

18F-FDG PET/CT in Thyroid Carcinoma

J. Mihailovic

Oncology Institute of Vojvodina

Corresponding Author: jasnans@eunet.rs

Background: Differentiated thyroid carcinoma (DTC) has a good prognosis and survival, but recurrent disease may appear during follow-up. There are several conventional diagnostic imaging procedures that help in recurrence detection, such as 131I-WBS, neck ultrasound, CT and MRI. In one-third of patients with well differentiated thyroid carcinoma, there are carcinomas with dedifferentiated tumour cells in which metastatic tissue may not concentrate radioiodine well. Consequently, 131I-WBS is negative despite elevated thyroglobulin (Tg) levels. Despite excellent morphologic characterization of metastatic nodal recurrences, MRI cannot reliably make a differentiation between benign and malignant lymph nodes. Although it detects enlarged metastatic lymph nodes, there are also many small nodal metastases that are usually missed. Recently, a positron emission tomography (PET) and computed tomography (CT) image fusion became available in diagnostics of thyroid carcinoma.

Methodology: PET/CT combines morphologic and metabolic imaging and increases diagnostic accuracy while decreasing false positive results due to artefacts and it may guide therapeutic management. 18F-FDG PET/CT allows better anatomical localization of metastatic disease and thus may improve surgical planning and provide a target for radiation therapy. This method allows changes in treatment strategy.

Results: PET changes patient management in 44-75% of cases. Although MRI helps in detection of these non-iodine avid metastases, 18F-FDG PET/CT can perform more effectively. Due to its high glycolytic rate, changes in glucose transport systems and hexokinase activity, FDG accumulates in malignant tissue and is useful to identify distant metastases in these patients. Increased uptake of 18F-FDG in differentiated thyroid cancer is associated with worse prognosis and poor biologic behaviour of the tumour. It has been reported that the volume of FDG-avid lesions is the single strongest predictor of survival. A mismatch as 131I-negative, but FDG-positive scan or 131I-positive and 18F-FDG-negative scan, is the so-called “flip-flop” phenomenon and was found in 90% of the patients. 18F-FDG uptake correlates with tumour aggressiveness, indicating that differentiated tumours with iodine avidity have low glucose metabolism in most patients, while high glucose metabolism signifies poor tumour differentiation and higher possible malignant potential. Consequently, dedifferentiated lesions with very high FDG uptake predict poor prognosis. The relationship between 18F-FDG PET/CT diagnostic accuracy and Tg levels is still controversial. Better 18F-FDG PET/CT accuracy in the detection of recurrent DTC is reported if average Tg levels are greater than 10 ng/ml. In patients with non-iodine avid recurrences additional treatment with 131I is useless. Diagnostic accuracy of 18F-FDG PET is high (85-90%).

Conclusion: 18F-FDG PET/CT is a hybrid imaging diagnostic tool which helps in the detection of recurrent DTC, especially non-iodine avid metastases. It has a role in exact localization of recurrences which will assist in the decision to remove the malignant tissue surgically.

IAEA-CN-232/35

Pharmacological Treatment and Myocardial Perfusion Abnormalities in Patients with Rheumatoid Arthritis

A. Puente, S. Rosales

ISSSTE

Corresponding author: adripuente@yahoo.com

Background: Ischemic heart disease is a common cause of mortality in patients with rheumatoid arthritis (RA). The aim of pharmacological treatment is to stop the progression of the disease and to reduce disability and cardiovascular complications. Pharmacological treatment reduces the pro-inflammatory process and the development of coronary artery disease (CAD).

Objective: To determine the relation of myocardial perfusion abnormalities in patients with RA under pharmacological treatment, evaluated with gated-myocardial perfusion single-photon computed tomography (g-SPECT).

Methodology: Gated-SPECT results (rest-stress Tc-99m sestamibi) of 91 asymptomatic patients without ischemic heart disease were analysed. Variables: age, risk factors, years of RA evolution, disease activity and pharmacological treatment: Group 1 = Disease modifying drugs (DMD): methotrexate (MTX), Group 2 = DMD+steroids, and Group 3 = biological treatment (anti-TNF α). Statistics: ANOVA, T Student.

Results: Average age was 58.7 \pm 12 years, 90% were women; 32% presented with hypertension, 36.3% with dyslipidemia, and 10% with diabetes mellitus. Gated-SPECT was abnormal in 24.6%; of these, 50% were affected at the anterior descending territory. There were no differences between myocardial perfusion abnormalities and age, gender, risk factors, RA evolution and disease activity ($p > 0.05$). The perfusion abnormalities (moderate ischemia and infarction) were most common in group 2 ($p = 0.004$) and least in group 3 ($pNS = 0.08$)

Conclusion: One quarter of asymptomatic patients with RA have perfusion abnormalities. Patients under biological treatment have fewer perfusion abnormalities, perhaps owing to a lesser degree of inflammatory response and, consequently, to a lesser development of atherosclerotic disease.

IAEA-CN-232/36

Distributions in the Eyes and Brain of Guinea Pig by Micro-Positron Emission Tomography with Dopamine Transporter Imaging Agent 18F-FECNT

L. Xingdang, L. Miao

Department of Nuclear Medicine Huashan Hospital of Fudan University

Corresponding Author: xingdliu@yahoo.com

Background: The aim of this study was to investigate dopamine transporter imaging agent 18F-FECNT distributions in guinea pig eyes, striatum, cortex and cerebellum.

Methodology: Dynamic imaging with microPET of fifteen tricolor guinea pigs was performed immediately after intravenous injection of 18F-FECNT for 60mins and 120mins, and some were extended to 240 min. ASIPro VMTM software was used to sketch and draw ROI and time activity curve of eyes, striatum and cerebellum.

Results: All subjects, aged 11 weeks, average weight 325.265g, received 10.9MBq (294.5uCi) 18F-FECNT. The drug accumulated quickly after iv in cortex, cerebellum and striatum, declined rapidly and remained stable at last. In eyes, it continued to increase, peaked at about 60 min, and remained stable at a relatively high level. The drug ratio of striatum / cerebellum at 5, 15, 30, 60, 90, 120, 180 min were respectively 1.31, 1.75, 1.70, 1.32, 1.21, 1.16, 1.14, 1.09. The retina / cerebellum ratio was respectively 0.63, 1.21, 1.81, 2.20, 2.33, 2.47, 2.51, 2.45. The total radioactivity in the eye was higher than in the basal ganglia.

Conclusions: This study demonstrates a good affinity of 18F-FECNT to DAT in guinea pig's retina and striatum, and the total uptake of radioactivity in the eye was higher than the one observed in basal ganglia.

IAEA-CN-232/37

Relationship between Serum Glucose and F-18 FDG PET/CT Biodistribution Quality in Thai Cancer Patients

T. Thientunyakit¹, N. Wongsurawat², C. Chompoonut³

¹Siriraj Hospital

²Khon Kaen University

³Siriraj Piyamaharajkarun Hospital

Corresponding Author: stanyalu@hotmail.com

Background: The objective of this study was to evaluate the relationship between fasting serum glucose and F-18 FDG biodistribution quality in Thai cancer patients. We also investigated the relationship between fasting serum glucose and standardized uptake value of the liver and bilateral gluteal muscles.

Methodology: Retrospective (case-control) study in 69 patients with different fasting serum glucose levels was done. Twenty three-altered biodistribution cases and forty six-adequate biodistribution cases who were randomized using sex, age (± 5 years) matched and lean body mass (± 5 kg) matched were analysed as to the relationship between fasting serum glucose levels and F-18 FDG biodistribution quality as well as standardized uptake value of the liver and bilateral gluteal muscles and SUV ratio of these regions. P value less than 0.05 was considered to be statistically significant.

Results: Out of sixty-nine patients (51 male, 18 female) with fasting serum glucose levels ranging from 64 to 155 mg/dL (mean 94.67 ± 17.78 mg/dL), there was no significant difference in fasting serum glucose levels between adequate biodistribution group (mean 96.00 ± 16.76 mg/dL) and altered biodistribution group (mean 95.65 ± 14.75 mg/dL) ($P=0.74$). The biodistribution quality of F-18 FDG was not significantly correlated with serum glucose level using the cut-off level of 120, 130 and 150 mg/dL (P value of 1.00, 1.00 and 0.55, respectively). There was no significant correlation between fasting serum glucose level and standardized uptake value of the liver or bilateral gluteal muscles.

Conclusion: There is neither significant correlation between fasting serum glucose level and biodistribution quality or standardized uptake value of the liver and muscles, when the fasting serum glucose level is within 155 mg/dL. However, effects of serum glucose level higher than this on biodistribution quality need to be further investigated, as well as its effect on F-18 FDG uptake in the tumour.

IAEA-CN-232/38

Quality Management in Nuclear Medicine: Experience in Siriraj Hospital, Thailand

P. Pusuwan

Faculty of Medicine Siriraj Hospital, Mahidol University

Corresponding Author: pawana.pus@mahidol.ac.th

Background: Nuclear medicine service in Thailand was first established by Professor Romsai Suwannick in the Faculty of Medicine Siriraj Hospital in 1955. At that time there was only one rectilinear scanner. Nowadays we have four SPECT/CTs, one SPECT and one PET/CT. With this complex technology, it is crucial that all services are performed accurately with high quality. Services in nuclear medicine are performed by the multidisciplinary team so there are many key areas that should be developed together at the same time such as management and human resources development, risk management, general clinical services, radiopharmacy etc. To demonstrate that we provide high quality medical care, it is essential to undergo both self and external evaluation. The program of quality management audits provided by the IAEA is a powerful tool for the external evaluation. We decided to participate in this valuable program.

Methodology: In November 2012, our team (physician, physicist and radiopharmacist) attended the IAEA workshop on “Quality management audits in nuclear medicine practices (QUANUM) for Asia and the Pacific region” organized by the IAEA and the Faculty of Medicine, Chulalongkorn University in Bangkok. The same team was fortunately participating as observers in the real quality management audits by the IAEA audit team held in the Division of Nuclear Medicine, King Chulalongkorn Memorial Hospital in 2013. These two events were very enthusiastic to our team to prepare our colleagues for the quality management audits. Head of division filled the survey form of the current status of the service and requested for IAEA assistance in quality management. An IAEA handbook on “Quality management audits in nuclear medicine practices” is a good guide to estimate quality of our services. We had quality meeting every month for discussion with the core quality team and every two months for good practice with all staffs in quality conference. As we learned that evidence of quality was very important for the reference of our services. Three working groups of clinical services, medical physicists and radiopharmacists took responsibility for reviewing and preparing all working protocols and documents required in the handbook. All this paperwork was binded into the quality manual. This quality manual also covered all information about the division which would serve as basic knowledge for new colleagues. QUANUM mission was done by an IAEA audit team in 2014. Evaluation was done by assessment of overall aspects of nuclear medicine services. There was an opportunity to discuss and learn during the mission. Conclusion and report were provided for our consideration and improvement.

Results: We were notified that our workload was reasonable by well-trained staff. There was no critical patient safety issue but there were critical findings in the area of radiation safety and radiopharmacy. Some recommendations to enhance the safety were suggested.

Conclusion: Understanding and co-operation of staff at all levels is an important key factor for success. IAEA audit mission is helpful to verify our standard and guide us to improve our services.

IAEA-CN-232/39

The Impact of 18F-Choline PET/CT in the Staging and Restaging of Prostate Cancer

H. Haidar¹, M. Haddad², F. Chehade³, A. Zaghal⁴, J. Chokr⁵

¹American University of Beirut

²Mount Lebanon hospital

³Mount Lebanon Hospital

⁴American Hospital of Beirut

⁵American University of Beirut

Corresponding Author: drmbhaidar@gmail.com

Background: The aim of this study is to evaluate the potential impact of 18F-Choline PET/CT on the staging and restaging of prostate cancer.

Methodology: We evaluated 86 consecutive patients presenting for staging of newly diagnosed prostate cancer (23 pts) and for restaging of treated prostate cancer (63pts) after mild elevation of PSA level (< 7ng/ml).

18F-Choline PET/CT was performed immediately after injection of 18F-choline with dynamic acquisition at the pelvis within 5 min followed by whole body scan 40-60 minutes later.

Positive findings were confirmed by histopathologic data status post-lymphadenectomy and were followed up by other imaging modalities or by 18F-Choline PET/CT.

Results: 18F-choline showed positive findings in 64/86 pts (74%). In the staging of patients, PET/CT detected a primary lesion within the prostate in 22/23 pts (96%), locale metastatic lymph node in 3/23pts (13%) and bone metastasis in 6/23 pts (26%).

In the restaging of patients PET/CT was negative in 21/23 pts (33%); however, there was local recurrence within the prostate bed in 22/63 pts (35%), nodal metastasis in 25/63 pts (39%) and extra nodal metastatic disease in 19/63 pts (30%).

In the staging group, patients with metastatic bone deposit were treated by pelvic radiotherapy and hormonal therapy rather than surgery.

In the restaging group, patients with localized recurrent disease (prostate bed and pelvic lymph node metastasis) were treated by radiotherapy - 16/63 pts (25%). As for patients with multiple metastatic sites, they were treated by hormonal therapy and/or chemotherapy.

Therefore, 18F-choline PET/CT played a major role in altering the therapeutic management.

Conclusion: 18F-choline PET/CT was able to detect distant metastasis in the staging of newly diagnosed prostate cancer.

It was also able to identify relapse and distant metastasis in the restaging of prostate cancer. This was even noteworthy in cases where PSA level elevation was inferior to 7ng/ml.

18F-choline PET/CT altered the therapeutic management of patients by guiding physicians towards a more suitable treatment modality especially in patients with pelvic disease only.

IAEA-CN-232/40

Lebanese Experience with 68Ga-DOTA-TATE PET/CT in the Diagnosis and Management of Neuroendocrine Tumours

M. Haidar¹, M. Haddad², F. Chehade², J. Chokr¹, A. Zaghal¹

¹American University of Beirut

²Mount Lebanon Hospital

Corresponding Author: drmbhaidar@gmail.com

Background: The objective of this study was the evaluation of the role of 68Ga-DOTA-TATE PET/CT in the diagnosis and management of neuroendocrine tumours (NET).

Methodology: 27 patients with NET underwent 68Ga-DOTA-TATE PET/CT which was performed after injection of 111-259 MBq (3-7 mCi) of 68Ga-DOTA-TATE. PET/CT images were compared with conventional imaging by two experienced nuclear medicine physicians. The results of PET/CT were correlated to histopathology results, when available and with radiological data after close follow-up.

Results: 68Ga-DOTA-TATE PET/CT showed sensitivity and specificity of 76% and 92%, respectively, for primary tumour and 98% and 100% for metastases. It was superior in the detection of both primary tumour and metastases when compared to conventional imaging modalities. It changed the management strategy in 6 patients (22%).

Conclusion: Our analysis in this relatively small patient cohort indicates that 68Ga-DOTA-TATE PET/CT is a highly sensitive and specific modality for the detection of NET especially for metastatic lesions, with better results when compared to conventional imaging modalities. This can have a significant impact on patient management.

IAEA-CN-232/41

Role of 18F-FDG PET/CT in Restaging and Management of Suspected Recurrent Breast Neoplasm

M. Haidar¹, M. Abu Samra¹, J. Chokr¹, M. Haddad², F. Chehade²

¹ American University of Beirut

² Mount Lebanon Hospital

Corresponding Author: drmbhaidar@gmail.com

Background: Breast carcinoma is known as the most common cancer in women. This study was carried out to elucidate the role of 18F-FDG PET/CT in restaging of treated breast neoplasm and to determine the impact on the management of suspected recurrence.

Methodology: Retrospective analysis was performed on the PET/CT examination of 35 women with a suspicion of recurrent breast cancer based on clinical examination, tumour marker values (CA 15-3) and/or negative or equivocal findings on other imaging modalities.

Results: PET/CT scan could detect only locoregional recurrence (mainly lymph nodes) in 12 patients, locoregional and distant metastasis in 15 patients, and only distant metastasis in 5 patients. Three patients were without evidence of recurrent disease and did not have any recurrence during a close follow up for 6 months. PET/CT led to management modification from locoregional treatment to systemic chemotherapy in 20/35 patients (57%).

Conclusion: This study demonstrates the considerable role of FDG PET/CT in restaging of breast cancer with high tumour marker values and negative or equivocal findings on other conventional imaging modalities. PET/CT led to treatment optimization mainly in cases of single recurrent lesion that could be surgically removed. In addition, PET/CT can change the management by detecting distant metastasis.

IAEA-CN-232/42

Impact of Single End of Treatment 18F-FDG PET-CT in Node Positive (N2) Squamous Cell Carcinoma (SCC) of Head and Neck after Definitive Chemoradiation for Guiding Management and Predicting Outcome

P. Choudhury¹, S. Rawat², A. Dewa², M. Gupta², A. Rao³

¹Rajiv Gandhi Cancer Institute & Research Centre Delhi India

²Rajiv Gandhi Cancer Institute Research Centre

³Rajiv Gandhi Cancer Institute

Corresponding Author: pschoudhary@hotmail.com

Background: The aim of this study was to evaluate the role of a single post-treatment 18F-FDG PET-CT study in node positive SCC of head and neck after definitive treatment.

Methodology: Forty patients, diagnosed with SCC of head and neck T (any) N2M0 on conventional staging workup during 2009-12 were included. All were treated with definitive chemoradiation (CCT RT) and underwent a single 18F FDG PET-CT study (Siemens Biograph) at 3 months after completion. No pre-treatment baseline study was performed in these patients. Standard whole body & regional PET-CT acquisition protocol was followed. CT was used for attenuation correction & localization without IV contrast. Interpretation was done jointly by nuclear medicine physician & radiologist in an integrated reporting format. Focal abnormal areas of increased metabolic activity (non-physiological) with SUV max > 3.0 (normalized to body weight) in the areas of known primary, lymph nodes or other areas of interest were taken as positive for active disease. Additional CT findings, if any, were also noted. Relevant statistical analysis was performed. End points were either minimum 12 months follow-up / disease-free survival or progression.

Results: There were 35 males and 5 females (n=40) with an average age of 54.7 years. 35% had Ca tongue, 23% Ca larynx & pharynx, 15% Ca pyriform sinus & 25% involving other areas. 30 patients (75%) had a normal PET study (Group I), 10 patients (25%) had a positive PET study (Group II). 26 had a long disease-free interval (Av.17 months) & disease progression was seen in 4 (Av time to progression 6.5 months) in group I. In group II shorter time to progression was seen in 4 patients with multiorgan metastasis and 6 patients had residual neck nodal disease on PET who subsequently underwent neck dissection (HP+ve 6/6) with a better outcome (p=0.005). Mean disease-free interval in groups I & II were 26.8 months (95% CI 23.86-29.73) and 16.20 months (95% CI 9.5-22.89) respectively (log rank test p=0.41) The sensitivity and specificity of PET was found to be 71.4% (41.9-91.6%) and 100% (86.7 – 100%) respectively with a PPV of 100% (69.1-100%) and NPV of 86.7% (69.3-96.2). The negative likelihood ratio was 0.29 with a disease prevalence rate of 35% (20.6-51.7%). The odds ratio between the groups was 4.3333 (95% CI 0.8357-22.5).

Conclusion: Our results show that a single PET study at the end of treatment, without baseline study, can direct appropriate future management strategies, individualize treatment and predict outcome. Normal study is an indicator of long disease-free survival.

IAEA-CN-232/43

**Malignant Incidental Findings on 18F-FDG PET/CT Scans
in Patients with Tuberculosis**

**M. Hodolic¹, M. Gabriel¹, Huber¹, Stelzmüller², Wunn³, Hatzl¹,
Fellner³, Lamprecht²**

¹Nuclear Medicine Physician

²Pneumologist

³Radiologist

Corresponding Author: marina.hodolic@gmail.com

Background: 18F-FDG is by far the tracer most frequently used for staging, assessment of the disease activity, therapy monitoring and follow-up in patients with tuberculosis. PET/CT is a valuable imaging modality that can give an answer regarding whole-body involvement of this disease. Patients with tuberculosis have increased risk for malignancy, especially lung tumours. The exact mechanism of a possible interaction between tuberculosis and malignancies is still unknown.

The aim of this study was to retrospectively analyse the capability of 18F-FDG PET/CT to detect concomitant malignant diseases in patients with tuberculosis undergoing routine 18F-FDG PET/CT examinations.

Methodology: Between July 2008 and December 2013, 122 patients with tuberculosis (76 males, 46 females; range: 19.6 – 88.6 years) underwent 178 18F-FDG PET/CT scans. When patients underwent more than one PET/CT scan only the initial scan was used for our study. 73 out of 122 patients had more than one and up to five 18F-FDG PET/CT scans: 1.45 scans per patient. The reports were reviewed and a consensus was reached between nuclear medicine physician and radiologist. Suspicious findings in terms of malignancy underwent further biopsies (histopathological evaluation) and/or follow-up using CT, thoracic X-rays and/or further PET/CTs.

Results: Seven out of 122 patients (5.7%) with tuberculosis had an incidental finding on 18F-FDG PET/CT scan later histologically confirmed as malignant. Histopathologically confirmed malignancies had 0 out of 15 patients in the age group < 30 years, 3 out of 63 patients (4.8%) in the age group 30 – 60 years and 4 out of 44 patients (9.1%) in age group > 60 years. Based on the histopathology, there were two adenocarcinomas of the lung (SUVmax 3.2 and 4.9), one mediastinal cell-rich fibrous tumour (SUVmax 2.6), one diffuse large-cell B-cell lymphoma (SUVmax 10.4), one multiple myeloma (SUVmax 7.3) and one squamous carcinoma of the lung (SUVmax 23). Only one false-negative finding was verified.

Conclusion: In patients with tuberculosis, malignant incidental 18F-FDG PET/CT findings were detected in a small but not negligible percentage using 18F-FDG-PET/CT. Co-existent malignancy was found in patients of advanced age with proven tuberculosis. 18F-FDG PET/CT alone cannot sufficiently discriminate between inflammatory and malignant lesions. Quantitative analysis has shown no clinical usefulness. The diagnostic CT plays an important role in enhancing the diagnostic efficacy in thoracic findings.

IAEA-CN-232/44

**Role of 18F-FDG PET/CT in Giant Cell Arteritis
Presenting as Chronic Thrombocytopenia**

I. Elangovan, S. Simon

Apollo Hospitals

Corresponding Author: drindinm@gmail.com

Background: We present the role of 18F-FDG PET/CT in establishing the diagnosis of giant cell arteritis in a patient referred with chronic thrombocytopenia to exclude the possibility of carcinoma of unknown primary (CUP).

The patient was a 72 years old woman presenting with chronic thrombocytopenia and significant weight loss, anaemia, elevated ESR with negative bone marrow aspiration and biopsy; she had undergone 18F-FDG PET/CT to exclude the possibility of malignancy.

Methodology: The patient was injected intravenously with 4mCi of 18F-FDG. After a 60 minutes uptake period, PET/CT imaging with IV contrast was performed from the skull base to the mid thighs after lowering the patient's blood sugar to less than 150mg/100ml. Scan was acquired in TOF 64 slice PETCT scanner.

Results: The scan revealed diffusely increased tracer uptake throughout the wall of thoracic and abdominal aorta with thickened aortic wall on CT image. In correlation with the elevated ESR and other systemic symptoms presented, the diagnosis of giant cell arteritis was given which excluded the possibility of malignancy. The patient was put on steroids and responded well, and followed up for future aortic aneurysms, since it is very common in these patients because of transmural inflammation.

Discussion:

Giant cell arteritis is less common in Asian population. The age factor (>72yrs) and the sex of the patient (female), systemic symptoms of weight loss, anaemia and chronic thrombocytopenia pointed towards the diagnosis which was confirmed by biopsy. The increased glucose uptake was due to activated granulocytes infiltrating the aortic wall. The positive predictive value of PET/CT was 93%. Therefore, a diagnosis of large-vessel vasculitis can often be confidently made even in the absence of a histologic diagnosis. Combination of genetic, immunogenic and environmental factors may play a pivotal role in aetiology. This case gives several important findings. 1. It gives the importance of considering GCA in the work-up of elderly Asian patients. 2. Clinicians and imaging specialists should be aware of heterogeneous constitutional symptoms as the only presenting feature. 3. In patients with a systemic inflammatory process, FDG-PET is useful to localize the inflammatory process to the blood vessel wall, therefore confirming the diagnosis of vasculitis.

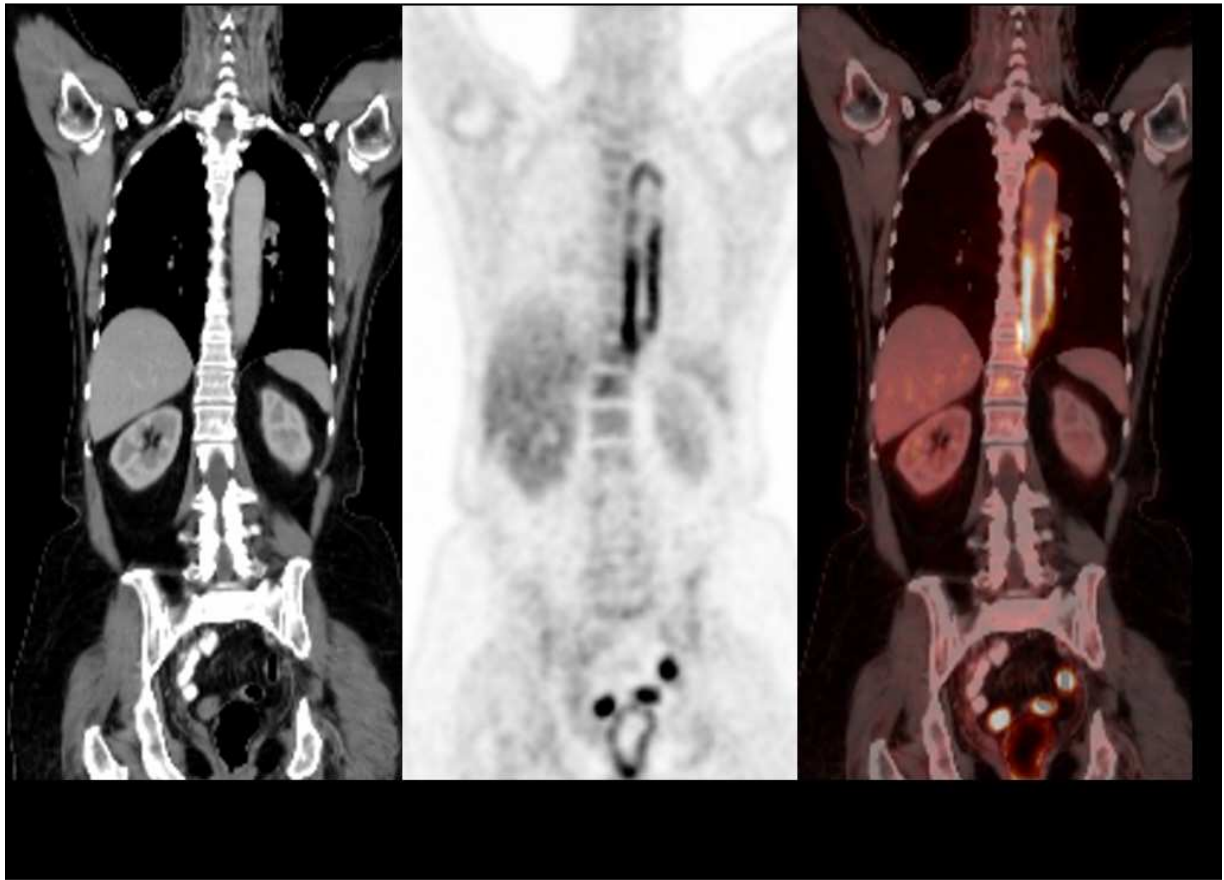


Figure 1: Increased ^{18}F -FDG uptake throughout the wall of thoracic and abdominal aorta with thickened aortic wall on CT image

Conclusion: ^{18}F -FDG PET/CT plays a major role in establishing the correct diagnosis as well as guiding the treatment, prognostication and follow-up of these patients for future events of aneurysm.

IAEA-CN-232/45

Multidisciplinary Teams Enhance Diagnosis and Treatment in Nuclear Medicine

R. Morales, R. Cano

IPEN

Corresponding Author: rmoralesgb@gmail.com

Background: Multidisciplinary teams are helpful in developing new capacities in everyday work, in many areas. In nuclear medicine it is possible to enhance better diagnosis working as a group with other physicians. In Peru, processes have been studied to improve bone scan studies, deliver iodine 131 to cancer patients sent from non-oncological hospitals and teams have been identified to manage patient data in every case.

Methodology: A check list was developed for bone scan orders and in-house software was built within the hospital system for obtaining necessary clinical data. Most of this information was automatically driven from the system to the nuclear medicine order. A graphic has been included in case of bone pain. Young physicians, medical senior staff and secretarial personnel were trained to use this software. Nuclear medicine physicians can validate data before injecting radioisotopes to patients. In thyroid cancer patients, check lists and hospital visits were arranged in order to receive enough clinical information for delivering iodine 131 treatment when it is really necessary for patients coming from non-oncological centres.

Results: Preliminary data indicate improvement in relevant information and acceptance of the new procedure and medical compliance was obtained for bone scan orders and procedures. Secretarial staff made suggestions for improvement, which are now tested in informatics. Time has been reduced in bone scan reports by using this software. Outpatients with thyroid cancer are personally treated to know if they need iodine treatment, after compiling data from their hospitals. These patients are having less consultation in the cancer hospital, diminishing costs and troublesome problems for these patients. Periodical meetings are arranged in standard manner to educate referring physicians: head and neck surgeons, endocrinologists and administrative physicians, whose responsibilities are mainly to perform iodine 131 treatment audits in cancer patients. Money has been economized by reasonable decision to treat in these patients. Bed occupation is better and timely decided.

Conclusion: Working as a team using appropriate communication and standards produces better results for diagnosis and treatment in nuclear medicine, in bone scan procedures and delivery of iodine 131 treatment for thyroid cancer patients.

IAEA-CN-232/46

18F-FDG PET/CT Detects Late Onset Sialadenitis after Radioactive Iodine Ablation Therapy

H. Song, Heesung¹, J.H Choi²

¹Department of Nuclear Medicine, Jeju National University School of Medicine

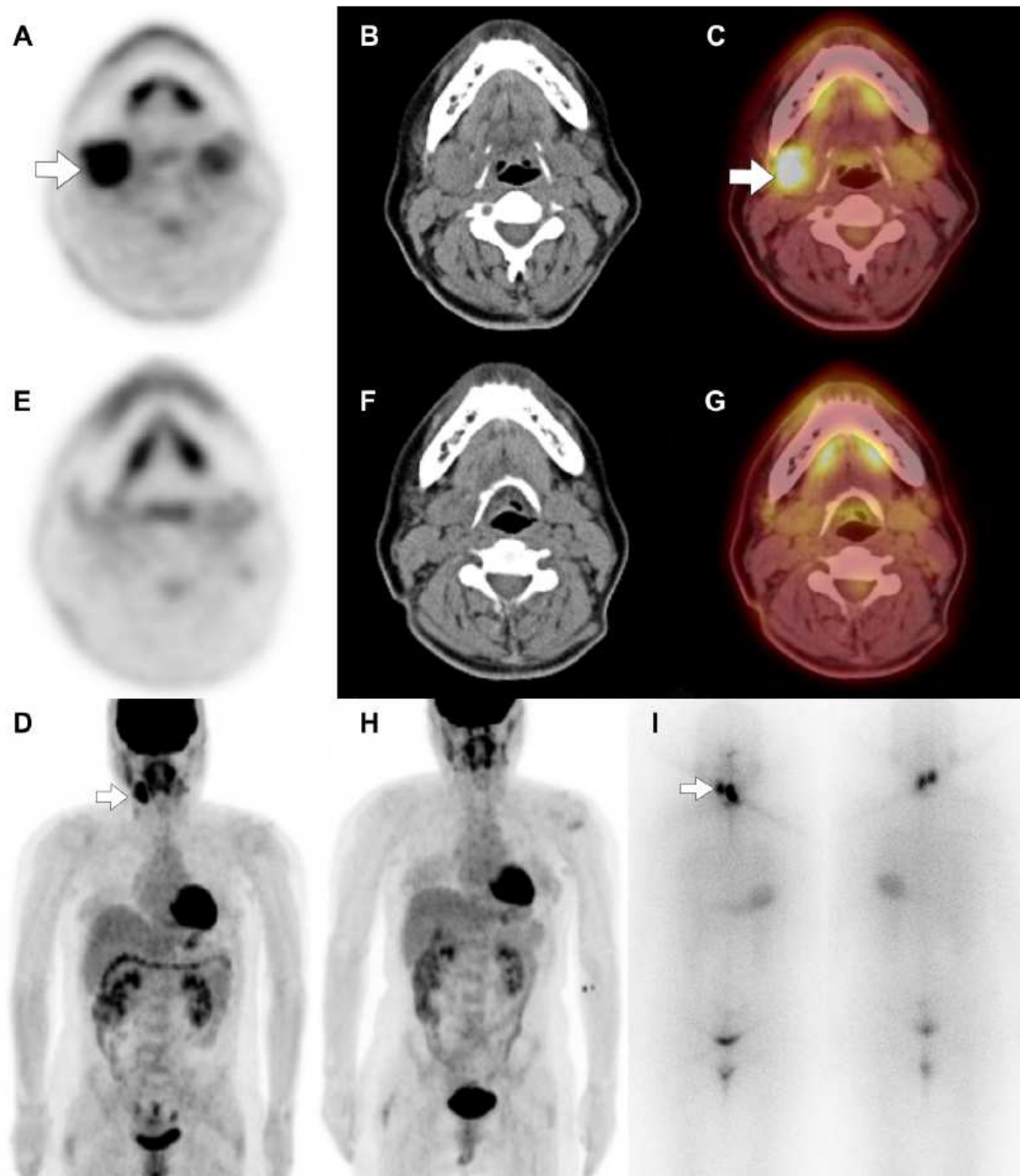
²Department of Internal Medicine, Jeju National University School of Medicine

Corresponding Author: heesung119@gmail.com

Background: Sialadenitis is a common complication arising from radioactive iodine therapy. F-18-fluoro-2-deoxyglucose positron emission tomography/computed tomography (FDG PET/CT) has been proposed to be useful in detecting not only malignant lesions but also inflammatory changes.

Methodology: A 45 year old woman underwent total thyroidectomy due to papillary thyroid cancer in 2011. High-dose radioactive iodine ablation of 3.7 GBq (100 mCi) was performed 2 months after the operation. For 3 years after discharge, she had routine follow-up tests that included physical examination, serum thyroid function tests, ultrasonography and FDG PET/CT, and the tests results were found to be normal. Thereafter she complained of a mass-like lesion that grew around the right submandibular area. Sialadenitis was suspected upon physical examination, and a planned FDG PET/CT, as routine follow-up, was carried out after 6 days.

Results: The FDG PET/CT revealed a diffuse and intense FDG uptake in right submandibular area. The present authors retrospectively reviewed imagery that had been captured 19 months prior, and found that those images contained a faint physiologic FDG uptake in both submandibular glands. The I-131 scintigraphy taken on the second day after radioactive iodine therapy of 3.7 GBq was reviewed additionally. The images showed a focal I-131 uptake in the thyroid bed area, suggesting the presence of a remnant of thyroid tissue. The other focal I-131 uptake in the right submandibular area was seen with an asymmetric pattern. The authors could exclude the presence of a salivary tumour because after conservative management, the complaint was resolve. Therefore they presume that this case of sialadenitis occurred as a result of previous radioactive iodine treatment, considering there was a significant I-131 uptake on the salivary area during post-therapy scintigraphy even though a late-onset condition after 3 years was rare. Furthermore, previous studies have shown that I-131 uptake in salivary glands is more likely to cause sialadenitis after radioactive iodine therapy. Recent research revealed FDG PET/CT to be useful for detection of infection and inflammation.



Conclusion: The present study reports on a case of late-onset sialadenitis 3 years after the radioactive iodine therapy, showing a diffuse and intense FDG uptake on FDG PET/CT. FDG PET/CT is helpful in diagnosing inflammatory diseases, such as sialadenitis.

IAEA-CN-232/47

Impact of 18F-FDG PET/CT in Predicting Treatment Plan and Prognostication for Patients with Esophageal Carcinoma

T.H. Tan¹, B.N. Lee², C.Y. Boey³

¹National Cancer Institute

²MBBS

³MD

Corresponding Author: teikhin.tan@gmail.com

Background: Accurate staging of esophageal carcinoma is essential in guiding appropriate stage-specific treatment approach such as high-risk curative surgery, definite chemoradiotherapy or palliation. 18F-FDG PET/CT has been found to have incremental value in esophageal carcinoma staging and guiding treatment. The purpose of this study is to evaluate the impact of pre-operative 18F-FDG PET/CT in predicting treatment strategy and prognostication for esophageal carcinoma with survival data.

Methodology: 50 consecutive patients with biopsied proven esophageal carcinoma were referred for 18F-FDG PET/CT evaluation in National Cancer Institute between Jan 2009 and June 2014. Patients were separated into 2 groups: pre-therapy staging (40 patients), and post-neoadjuvant therapy restaging (10 patients). PET/CT results on both groups were compared with pre- and post-therapy contrasted CT respectively. Among patients in the first group, 4 had pre- and post-neoadjuvant therapy PET/CT results and these results were compared to assess therapeutic response. Disease stage was classified according to the American Joint Committee on Cancer staging system (7th edition). All patients were followed up to assess change of therapeutic strategies. Survival after follow-up was analysed using the Kaplan–Meier product limit method.

Results: Median interval between CT and PET/CT for both groups was 1 and 2 months, respectively. Out of 40 patients in the pre-therapy staging group, PET/CT had led to stage change in 26 (65.0%) patients, of which upstaging was demonstrated in 10 (25.0%) patients and downstaging in 16 (40.0%) patients. Management modification from palliative to curative intent was seen in 13 out of 23 patients and 6 out of 17 patients from curative to palliative. In those groups of patients, median survival between patients who were candidates for surgical resection (T1 to T4a) and non-resection (T4b and M1) based on PET/CT alone was 8.5 months and 4 months, respectively. Treatment intent on the basis of PET/CT was significantly associated with survival ($P=0.013$). In the second group of patients who had received neoadjuvant chemotherapy or radiochemotherapy, post-therapy PET/CT had resulted in subsequent therapy change in 2 out of 10 patients. With or without surgery, patients with non-hypermetabolic localized disease detected by post-neoadjuvant therapy PET/CT have better survival (median 36 months) than patients with residual primary or extensive disease (median 10 months).

Conclusion: 18F-FDG PET/CT provides important information on treatment strategy and prognostication in pre-therapy staging and post-neoadjuvant restaging of esophageal carcinoma

IAEA-CN-232/49

PET/CT with 11C-Acetate versus 18F-FDG in Patients with Recurrence Biochemistry of Prostatic Carcinoma

J. Soto Andonaegui¹, P. Bezaury Rivas², J. Altamirano Ley³

¹Nuclear Medicine Physician C.T. Scanner Lomas Altas

²National Institute of Nutrition and Medical Sciences

³Unit PET/CT Cyclotron UNAM

Corresponding Author: nucleardr@hotmail.com

Background: Prostate cancer is the leading cause of mortality in the group of malignancies in men in Mexico, and is considered a public health problem in this population group. The heterogeneous spectrum of this neoplasm shows a marked increase in mortality. Patients treated with curative intent have biochemical relapse probability of 15% to 40% at 5 years and about 70% in 10 years, a fact which leads to the importance of imaging techniques that provide timely information on the evaluation of this neoplasm in subclinical stages. There is currently no diagnostic test to detect early and effective recurrence of this disease, even before the evidence of biochemical progression at low levels of prostate specific antigen (PSA) from > 0.2 ng/ml, so there is a need to study the potential of positron emission tomography and computed tomography with the use of specific radiotracers, such as 11C-acetate in patients with suspected recurrence of prostatic adenocarcinoma.

Methodology: This prospective study was conducted in the analytical unit in PET/CT cyclotron of the Faculty of Medicine UNAM in the period May 2012 to January 2013. A total of 31 patients diagnosed with prostate cancer were included; only those with defined biochemical recurrence of PSA values > 0.2 ng/ml and no evidence of other imaging methods for localization of residual tumour.

Results: A total of 31 male patients with mean age of 67, PSA levels ranging from 0.32 ng/ml to 214 ng/ml, with an average of 18.9 ng/ml. 25 studies were identified positive (83.3%) with 11C-acetate, 6 with a negative diagnosis (16.7%), whereas 18F-FDG identified 10 studies positive for malignancy (33.3%) and 21 negative (66.7%). Statistical analysis revealed a sensitivity of PET/CT with 11C-acetate of 88% and a specificity of 100%, with a confidence level of 95%, PPV was 100% and NPV 66.67%. With 18F-FDG the sensitivity observed was 45.4% and specificity 100%, calculated PPV were 100% and NPV 42.86% in the assessment of recurrence.

We calculated the correlation of evidence with respect to histopathological study. Kappa coefficient for PET/CT with 11C-acetate was 0.73 (95% IC. 0.46-1.00), while for 18F-FDG it was 0.32 (CI: 95% from 0.10 to 0.54). It was performed to measure the consistency of the test according to the criteria of Landis and Koch, revealing a substantial strength of agreement for 11C-acetate and 18F-FDG median.

Conclusion: PET/CT with 11C-acetate conclusively shows greater sensitivity in detecting prostate cancer recurrence, with a high degree of validity in comparison with 18F-FDG, supported by substantial agreement when compared with the results of histopathology, being statistically significant. It is helpful in monitoring patients with suspected relapse, leading to the imperative of its spread to related specialists as an excellent diagnostic tool for early diagnosis of this disease.

IAEA-CN-232/50

**Role of 18F-FDG PET/CT in Malignant Mesothelioma
Follow Up**

S. Simon, I. Elangovan

Apollo Hospitals

Corresponding Author: shelleynidhish@gmail.com

Background: The aim of this case report is to enlighten the role of 18F-FDG PET/CT in assessing the extent, early detection and treatment of minimal spread of disease with guidance for optimal treatment in one of the world's longest living malignant mesothelioma patients.

The patient is a 58 year old women presenting with cough and dyspnoea who underwent regular investigations to get diagnosed with malignant mesothelioma in November 2011. Left pleura pneumonectomy with fixation of left artificial hemi diaphragm was done followed by chemotherapy. Sequential PET/CT scans were done as the disease is notorious for local spread along the suture lines; the same was found and treated with radiotherapy. Further follow up in due course showed detection of very small para aortic lymph nodal disease which was successfully treated with Cyber knife, which gave excellent years of survival.

Methodology: Sequential PET/CT scans were done in Gemini TOF 64 slice CT scanner with IV contrast initially and without contrast later. Scan was acquired after 1 hour of 4 mCi of 18F-FDG injection after overnight fasting and making sure her blood sugar level were less than 150mg/100ml for all the scans and delayed two hours images of the chest were acquired when needed.

Results: Regular sequential follow up guided the management of the disease which is shown in the table and images with highest level of sensitivity and specificity as one could expect were obtained for the best treatment possible.

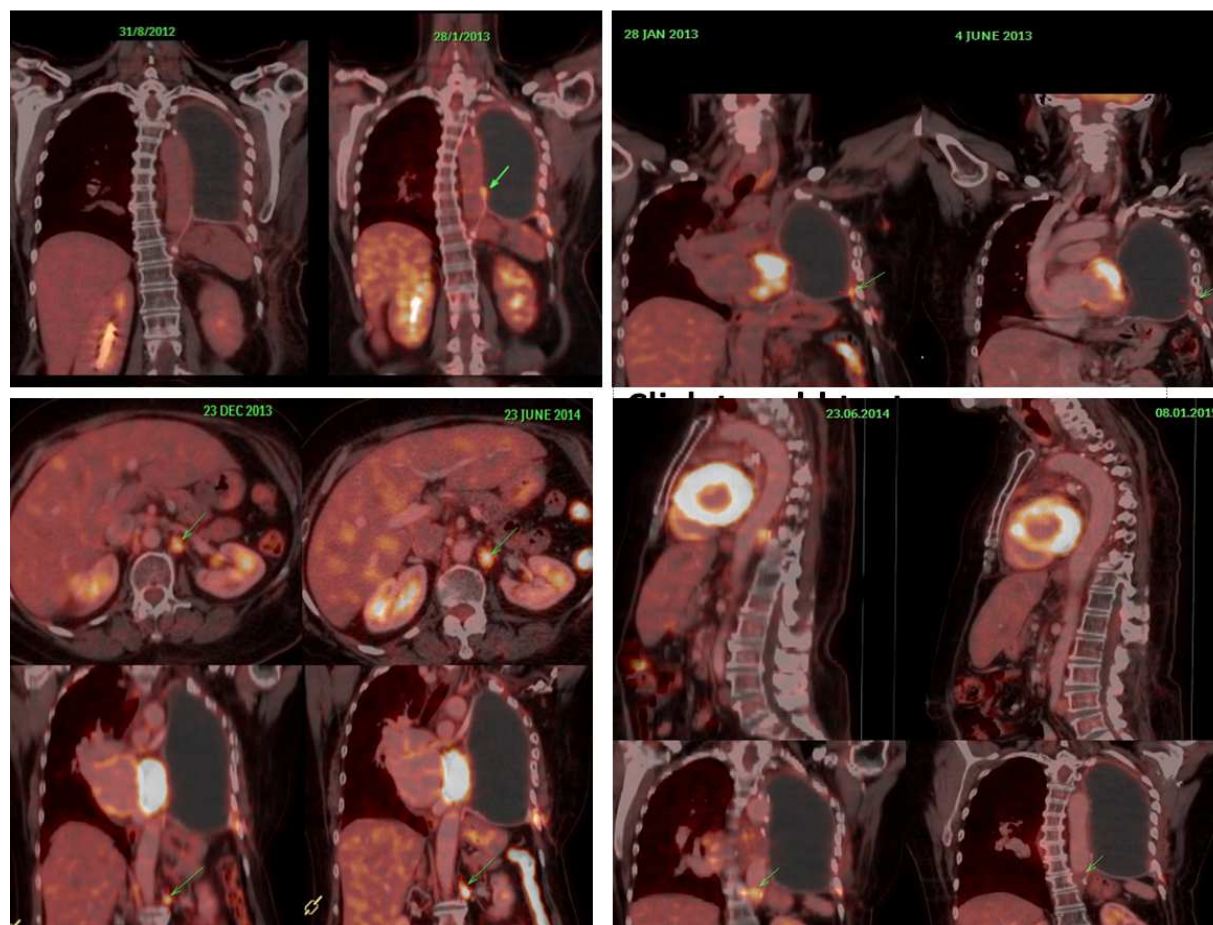


Figure 1: Sequential follow up

Table 1: Sequential follow up 18 F- FDG PETCT findings, post-surgery, post-chemotherapy

No	Date	Left lower Chest wall	FINDINGS	Prevascular node	Para aortic nodule	Treatment
1	18/4/12	Focal disease	Loculated fluid collection present	Prominent Non FDG avid	-	Radiotherapy (13/6/12)
2	31/8/12	Stable foci	stable	stable	-	Follow up
3	28/1/13	Lower mediastinal foci	stable	stable	-	RT 7 /3/13 Follow up
4	4/6/13	New left upper hemi thorax, reduction left lower hemi thorax	Mild increase	-	-	Follow up
5	23/12/13	Retro aortic nodule at D10	stable	-	para aortic node at left renal hilum	Follow up
6	23/6/14	Increase in size and activity	stable	-	Increase in size and activity	Cyber knife RT 7/14
7	8/1/15	Regression in size and activity	stable		resolution	

Conclusion: Prognosis in malignant mesothelioma is very poor and survival is usually less than two years after the initial diagnosis. 18F-FDG PET/CT has established its superiority in detecting the tiniest foci of disease which were successfully treated, thus aiding in the follow up, detecting early and tiny disease recurrence and guiding in radiotherapy treatment with cyber knife. This patient has survived for four years which makes her one of the longest surviving patients. This was due to the 18F-FDG PET/CT follow up in detecting the recurrences and initiating appropriate treatment in this case of malignant mesothelioma.

IAEA-CN-232/51

**Can We Predict Microvascular Invasion in HCC on
18F-FDG PET/CT?**

V. Agarwal, S. Pande, S. Sahu, R. Kavindran

Medanta the Medicity Hospital

Corresponding Author: stanley2005vishal@yahoo.com

Background: The purpose of this study is to correlate clinico-pathologic and PET-CT parameters with the presence of microvascular invasion (MVI) at histopathologic examination (HPE) in patients with hepatocellular carcinoma (HCC) who underwent liver transplantation.

Methodology: We assessed 224 patients with HCC undergoing liver transplantation and a pre-transplant PET-CT. Three physicians (two nuclear physicians and one radiologist) analysed the following tumour parameters in consensus: size, multi-focality, pattern of uptake, quantitative FDG uptake (SUV), pattern of enhancement and distance to closest vessel. The size and number of lesions, tumour differentiation and the presence or absence of microvascular invasion were determined at HPE and these findings were analysed vis-a-vis to the imaging parameters on PET-CT.

Results: None of the clinical parameters was predictive of MVI; however on uni-variate analysis, MVI was significantly associated with multi-focality, uptake pattern and distance to the closest vessel on FDG PET-CT. By applying multiple logistic regression analysis, uptake pattern (heterogeneous and peripheral FDG uptake) was found to be the only independent risk factor for MVI.

Conclusion: Heterogeneous and peripheral FDG uptake on PET-CT was the only parameter that correlated significantly with MVI.

IAEA-CN-232/52

**Cholangiocarcinoma with Metastases to Breast:
Rarer than a Rare Entity**

V. Agarwal, S. Pande, N. Gangrade, S. Sahu

Medanta the Medicity Hospital

Corresponding Author: stanley2005vishal@yahoo.com

Background: With over 1 million new cases in the world each year, breast cancer is the most common malignancy in women, and accounts for 18% of all female cancers. However, metastatic involvement of the breast is relatively rare, most common causes being contralateral breast cancer, malignant melanoma, lymphoma, lung cancer, ovarian carcinoma, soft tissue sarcoma, gastrointestinal tumours and genitourinary tumours. Autopsy reports indicate an incidence of 1.7% to 6.6% for non-primary breast malignancy. The clinical incidence is only from 0.5% to 1.3%.

Methodology: We present a young female aged 35 years, presenting in the hospital for pain abdomen and jaundice. On evaluation, she was found to have a liver mass with altered liver function tests. On FDG PET-CT examination, FDG avid heterogeneously enhancing irregular lesion was noted in the right breast with another FDG avid peripherally enhancing rounded lesion in the left breast. Liver showed a peripherally enhancing FDG avid SOL in segment V, VIII and IV, with ill-defined margins and irregular peripheral enhancement & lobular outline.

Results: In view of hypermetabolic heterogeneously enhancing lesions in B/L breasts and FDG avid peripherally enhancing SOL in liver, diagnoses of metastatic Ca breast was suggested and pathologic correlation was advised. However, HPE of right breast lesion confirmed it to be metastatic carcinoma rather than the primary of breast.

Conclusion: Cholangiocarcinoma is a slow growing, rare, malignant tumour of the bile duct, accounting for less than 1% of all cancers. Mostly, it spreads locally via the lymphatics to regional lymph nodes. Metastatic focus in the breast is a very rare presentation, this being probably the first reported case.

IAEA-CN-232/53

Correlation between Proliferation Index and Metabolic Activity at the Biopsy Site in Newly Diagnosed NHL

V. Agarwal, S. Batchu, S. Pande, S. Sahu, N. Gangrade

Medanta the Medicity Hospital

Corresponding Author: stanley2005vishal@yahoo.com

Background: In recent years, positron emission tomography (PET), particularly with 18F-fluorodeoxyglucose (FDG), has emerged as an alternative to computed tomography (CT) not only in treatment evaluation but also in the staging of lymphomas. It enables the assessment of the extent of lymphoma with a higher sensitivity than that of CT. In lymphoma, Ki-67 proliferating index (MIB-1 labelling index) indicates the proliferation potential of tumour cells, which often affects the prognosis. Although the correlation between the standardized uptake value (SUV) on PET and the proliferation potential of tumour cells has been reported in several tumours such as brain tumours, head and neck cancer, lung cancer, and bone and soft tissue tumours, only few studies have elucidated this in the case of malignant lymphoma, which is one of the most sensitive tumours to therapy. It is important to know the proliferation potential and, in turn, determine the speed of tumour growth to decide the appropriate regimen of initial chemotherapy.

Methodology: We did a retrospective study on 47 patients (45 were aggressive lymphomas and 2 were mantle cell) referred for initial staging of lymphoma to our nuclear medicine department in last 1 year. Inclusion criteria were newly diagnosed biopsy proven lymphoma with complete pre-treatment evaluation including history, physical examination and standard laboratory tests, whole-body FDG PET/CT for pre-treatment staging and biopsy samples evaluation using immunohistochemical staining to look for Ki-67 expression. Recurrent cases of lymphoma were excluded.

Results: All the cases exhibited high SUVs at the site of biopsy (ranging from 8.8-59.43) and high Ki-67 index, ranging from 40-100%. In 17 of the 47 patients, the biopsy site was discordant with the maximum SUV site. In the remaining 30 patients, biopsy site and the site for maximum SUV were the same. BxSUVmax showed significant positive correlation with the Ki-67 proliferation index ($r=0.56$; $p < 0.01$). Significant positive correlation was also detected between the BmSUVmax and the Ki-67 proliferation index ($r=0.52$; $p < 0.01$).

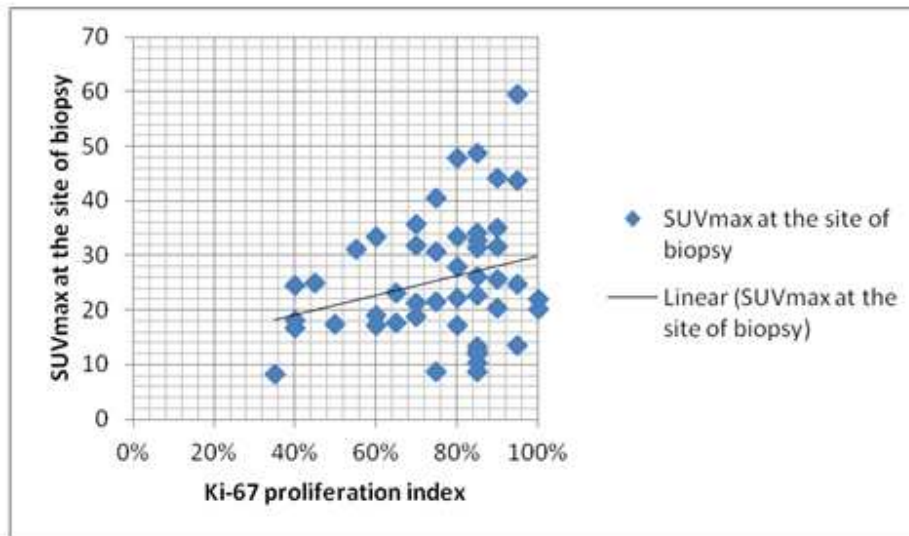


Figure 1: Correlation between BxSUVmax and Ki-67 index

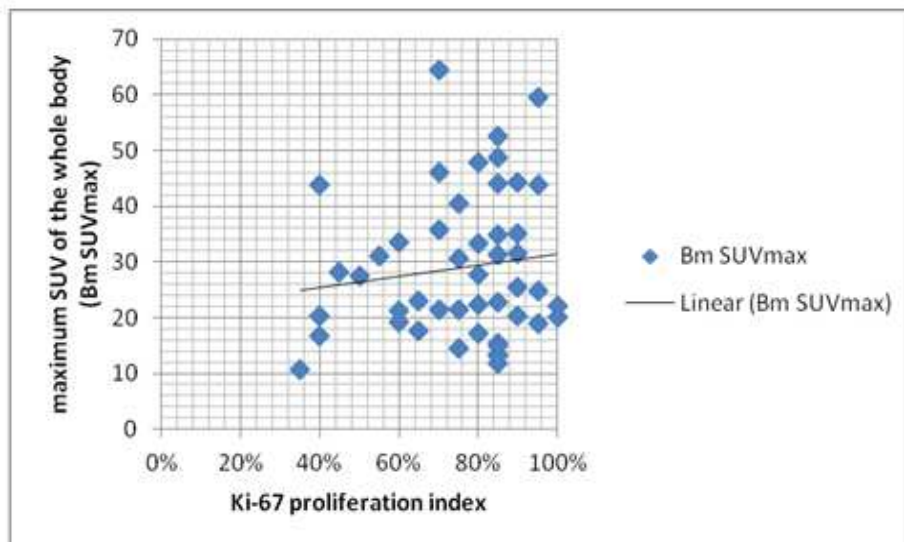


Figure 2: Correlation between BmSUVmax and Ki-67 index

Conclusion: The BxSUVmax correlated with the Ki-67 proliferation index, and a correlation was detected as well between the maximum SUV of the whole-body (BmSUVmax) and the Ki-67 proliferation index, indicating that tumour proliferation potential might be predicted in vivo by FDG-PET/CT images and thus, PET/CT may be useful to guide biopsy by selecting sites with the BmSUVmax when clinically appropriate.

IAEA-CN-232/54

Impact of Positron Emission Tomography Images in Stereotactic Body Radiotherapy of Lung Tumours

R. Mohan¹, K. Jayaram¹, B. Bob², C. Jason², M. Babaiah³; K. Krishna², R.M. Kanaparth³, H. Tadimetri⁴

¹American Oncology Institute, Hyderabad, India

²Cancer Treatment Services International, Pittsburgh, USA

³American Oncology Institute

⁴Citizens Hospital, Hyderabad, India

Corresponding Author: krmuralidhar@rediffmail.com

Background: To study the impact of treatment volume delineation and dose volume variations to the target and critical structures using positron emission tomography (PET) images for planning stereotactic body radiotherapy (SBRT) of lung tumours in treatment planning system (TPS).

Methodology: Ten lung cancer patients were chosen for this study. All patients underwent PET-CT using two beds and computed tomography (CT) with 3mm slice thickness by using GE discovery 16 slice PET-CT scanner. SUV threshold method was used to delineate the GTV in PET-CT. In PET-CT the range of Bq/ml was chosen manually based on the visibility of organs. To create biologically defined target volumes, functional information given by PET is projected onto the anatomical CT images. The CT and PET images after fusion planned for stereotactic body radiotherapy (SBRT) in Eclipse TPS for true beam STX machine using flattening filter free beams. Independent plans (50 Gy in 10 fractions) were done using CT and PET images alone and compared treatment volumes and dose to the target and other organs at risk. 18F-FDG-PET scans for all patients were carried out in the RT treatment position, with vac lock immobilization device fitted to enable direct use of PET images in RT planning.

Results: The influence of PET-CT image on gross tumour volume (GTV) delineation in lung cancer was studied on 10 patients. PET-CT is especially helpful to detect lymph node involvement and differentiate malignant tissue from atelectasis. In this study analysis was done purely on the basis of GTV delineation by PET and CT independently. PTV was derived by giving 1.5 cm margin to the GTV in all cases. Plans were implemented on both CT PTV and PET PTV as targets for analysis. The dose distribution to other organs at risk and the influence of GTV volume difference on global maximum dose, critical structure doses were reported. The average of mean dose difference for 10 cases in heart, spinal cord, esophagus, trachea, liver and global maximum dose were 10.9%, 6.44%, 0.46%, 6%, 1.14% and 0.66% respectively. There are significant changes in target volume (GTV) after the integration of 18F-FDG-PET/CT into the radiation treatment planning process ranging from -40.44% to 55.7% with average mean difference in volume being 6.42%.

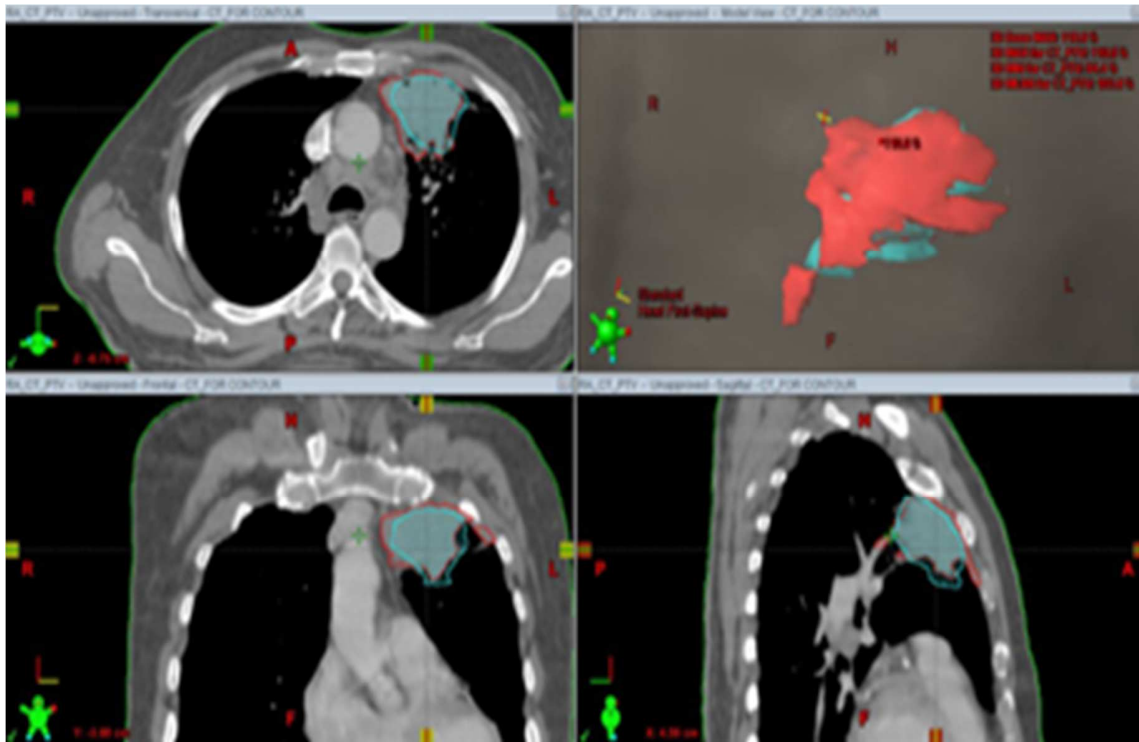


Figure: GTV delineation of lung tumour with PET (cyan) and CT (red)

Conclusion: A team of nuclear medicine physicians, radiologists, radiation oncologist, medical physicists and dosimetrists after working on 10 patients concluded that the PET-CT images influenced the dose distribution in tumour and OARs significantly. Hence by taking the biological imaging into consideration, patient treatment outcome will be influenced. The clinical management of cancer patients has improved dramatically with the introduction of clinical PET. It has a double advantage of use not only to limit therapy ports to spare normal tissue but also to include additional involved regions.

IAEA-CN-232/55

Fusion of Interictal 18F-FDG-PET and MRI is Feasible and Helpful in the Detection of Possible Epileptogenic Region

G. Bural, S. Türe, F. Gelal, G. Akhan

İzmir Katip Çelebi University

Corresponding Author: buralgonca@gmail.com

Background: In approximately one third of patients with epilepsy, seizures persist despite adequate trials of several antiepileptic drugs. Different modalities and imaging techniques have been used for the pre-operative assessment of seizures. Modern structural and functional brain imaging methodologies have made a gross impact in the diagnosis and management of subjects with epilepsy.

Methodology: A 30-year old man with seizure disorder was referred to the nuclear medicine clinic for detection and verification of the epileptogenic focus with an interictal PET scan. The patient had a 16 years long history of seizures. The seizures were under control with antiepileptic medications initially, but they became drug resistant and their frequency increased despite use of several antiepileptic medications during the follow-up. The subject was hospitalized for video-EEG, which lateralized the seizures to the right temporal lobe. He had a brain MRI, which showed volume loss and increased T2 signal in the right hippocampus. The subject had a subsequent FDG-PET/CT of the brain. The time interval between MRI and PET/CT was 20 days. PET images were acquired 60 minutes after intravenous injection of 5.7 mCi 18F-FDG; PET images were interpreted both visually and quantitatively.

Results: Visual analysis of brain PET images revealed hypometabolism in the right temporal region, predominantly in the medial area compared to the left. Quantitative analysis supported the visual findings. SUVmax and SUVmean values were lower for the right temporal lobe compared to the left (SUVmax and SUVmean for right were 4.9 and 3.9 respectively, and SUVmax and SUVmean for left were 6.2 and 5.2 respectively). Interictal PET brain images from PET/CT data were then co-registered with the interictal MRI data using the fusion software program of the PET/CT Workstation. Axial PET images and axial T2 weighted images of the MRI were used to obtain fused PET/MR images. Perfect alignment of PET and MR images was provided by means of rotating multiplanar slices with respect to certain morphological landmarks. Fused PET/MR data was then visually analysed. The abnormal right hippocampal region appeared to be within the hypometabolic right temporal lobe and hypometabolism was highly prominent in the right hippocampus. The overlap of PET and MRI data, further assessed by using fused PET/MRI images, increased the possibility that this region could be the epileptogenic focus and the patient was referred for surgery.

Conclusion: Interictal PET is a sensitive and reliable technique in localizing the possible epileptogenic focus in patients with medically intractable seizures. The objectivity and accuracy of data can be enhanced with co-registration of interictal functional data from PET with the anatomical data from MRI. The co-registration of the interictal PET images from PET/CT with high-resolution MRI structural data enhances accurate interpretation of functional abnormality noted on PET. Co-registered data for this patient enabled us to directly compare the location, pattern and extent of the hypometabolic region.

IAEA-CN-232/57

18F-FDG Uptake in Non-Paralyzed Vocal Cord: A Potential Cause of Possible Pitfall on PET/CT Imaging

G. Bural¹, A. Alacacioglu²

¹Izmir Katip Celebi University, Ataturk Research and Training Hospital

²İKCÜ-AEAH

Corresponding Author: buralgonca@gmail.com

Background: Proper interpretation of FDG-PET images requires detailed knowledge of the normal physiologic distribution of FDG, frequently encountered due to physiologic variants, and less frequently due to other benign causes. A benign cause of false-positive FDG uptake may be noted during evaluation of the extracranial head and neck for malignancy.

Methodology: A 47 year old woman with history of invasive ductal carcinoma of the breast had right partial mastectomy, followed by chemotherapy and radiation treatment. Five years after the initial treatment the patient had a neck US, which revealed new suspicious lymph nodes in the head and neck region. The patient was referred for a PET/CT scan for evaluation of new cervical lymph nodes and planning of the subsequent treatment strategy. One hour after intravenous administration of 8 mCi 18F-FDG the patient had a PET/CT scan.

Results: On the PET/CT images, the patient had multiple enlarged lymph nodes, with increased FDG uptake in the right lower cervical, left supraclavicular, bilateral upper paratracheal, prevascular, right hiler, left internal mammarian and subcarinal lymph node stations. As these were not present on the last neck and thorax CT performed three years ago, they were interpreted as metastatic lymph nodes. An incidental note of asymmetric focal increased FDG uptake was noted in the region of the left vocal cord. This uptake was interpreted as normal physiologic uptake, and paralysis of the right vocal cord, secondary to the right sided upper mediastinal lymph nodes causing compression of the right recurrent laryngeal nerve along its course in the upper mediastinum. The subject was referred to the ENT clinic for histopathological confirmation of the pathological lymph nodes noted on the PET/CT scan. Pathology of the left supraclavicular lymph node confirmed metastatic involvement. Endoscopic examination of laryngeal structures including bilateral vocal cords was within normal limits; with no evidence of metastatic or primary tumoural involvement of the left vocal cord.

Conclusion: FDG accumulates in benign and malignant disorders due to increased glucose consumption. The asymmetric FDG uptake seen in vocal cord paralysis is most likely due to the lack of FDG activity in the paralyzed cord and compensatory increased activity of the contralateral (un-paralyzed) vocal cord. The increased workload of the non-paralyzed cord likely leads to increased glucose utilization which is noted as a focal hot spot on the FDG-PET images. Pathologies arising along the course of the recurrent laryngeal nerve, such as masses or enlarged lymph nodes in the upper mediastinum or the root of the neck as seen in this case, can compress this nerve, causing vocal cord paralysis. This benign pattern of asymmetric FDG uptake in the region of vocal cord, in the presence of contralateral upper mediastinal or lower cervical pathology needs to be specifically recognized not to be falsely interpreted as abnormal pathological uptake.

IAEA-CN-232/58

First PET-CT and Cyclotron in Myanmar: Challenges and Dreams

K. Myint

Yangon General Hospital

Corresponding Author: kmnumed@gmail.com

Background: The Department of Nuclear Medicine, Yangon General Hospital, Yangon, was the first centre in Myanmar using radioactive sources for diagnostic and therapeutic applications since 1963. The centre performs routine planar and SPECT imaging and radioimmunoassays with kind guidance and assistance of the Government of Myanmar and IAEA. PET-CT is well established as an essential medical tool for diagnosis and management of cancer. Cancer is the second most common cause of morbidity and mortality in Myanmar. Currently, patients from Myanmar requiring PET-CT examination are referred to hospitals in other countries such as Thailand, Singapore, etc. This is not a cost-effective or a viable method for a developing country.

Methodology: Medical community of Myanmar is eagerly waiting for a PET-CT and cyclotron since attending the first coordination meeting of RAS 6042, held in Chiba, Japan organized by the IAEA in 2005. The Ministry of Health, Government of Myanmar has put tremendous effort and purchased a Philips time-of-flight PET-CT (Gemini 16 slices) and IBA 18 MeV cyclotron (Bunker type) in 2012, despite many technical challenges (knowledge on advanced technology, manpower shortages, radiation concern for advanced facility, complex project management and coordination).

Results: In 2013 foundation was laid for a new building to install PET/CT and cyclotron. The construction of the building has been completed as per the regulations. PET-CT installation was started in December 2014 followed by installation of cyclotron in February 2015. The whole project is expected to be completed by June 2015 and we hope clinical studies with ¹⁸F-FDG to begin by September 2015.

Conclusion: PET/CT imaging in Myanmar will help our patients in accurate diagnosis, staging and management. PET/CT is an additional boon to our health-care professionals to upgrade the health care system in Myanmar. This dream project will benefit both public and private sector hospitals and more importantly people of Myanmar.

IAEA-CN-232/60

11C-SAM: a New Potential Agent for Prostate Cancer Diagnosis

F. Zoppolo, P. Buccino, W. Porcal, P. Oliver, E. Savio, H. Engler

Uruguay Center for Molecular Imaging (CUDIM)

Corresponding Author: florencia.zoppolo@tudim.org

Background: Prostate cancer (PCa) is one of the most common solid cancers in men. In patients with localized PCa, operative therapy is effective but a substantial number of patients experience recurrent disease. 11C-choline has proved to be useful for restaging PCa in patients that suffer from biochemical failure with an absolute PSA value of > 1 ng/mL. This tracer cannot be recommended as a first-line screening procedure for primary PCa due to its limited sensitivity, its dependency on tumour configuration and its limited specificity in differentiation between PCa and benign pathologies.

Sarcosine (N-methyl glycine) has been identified as a differential metabolite that is highly increased during PCa progression to metastasis. This increase is associated to high levels of glycine N-methyltransferase (GNMT) in aggressive PCa. GNMT catalyses the methylation of glycine using S-adenosylmethionine (SAM) as co-enzyme to form sarcosine.

The aim of this study is to identify GNMT ligands as potential radiotracers for aggressive PCa diagnosis. For this purpose SAM was labelled with 11C and biological evaluation is being performed.

Methodology: The synthetic process began with the production of [11C]CO₂ in the cyclotron (GE PETtrace 16.5MeV) via the ¹⁴N(p, α)¹¹C nuclear reaction. [11C]CO₂ was delivered from the target to the automated synthetic platform (GE) TRACERlab® FX C Pro, where it was trapped for purification and further reduction to [11C]CH₄. Then, it was iodinated to yield [11C]CH₃I, having the possibility to be later converted into [11C]CH₃OTf in order to react with the precursor, S-adenosylhomocysteine. In these assays different conditions of methylating agent, solvent, precursor amount, temperature and reaction time were tested.

This agent has been biologically characterized by the following studies: a) dynamic PET/CT scans in nude mice (control as well as xenographic human PCa-bearing tumours) in the preclinical Triumph Tri-modality Scanner (Gamma Medica, Inc.); b) biodistribution in the same nude mice models at 10, 20 and 40 min; c) cellular internalization in PC3, VCap and LNCap human tumour lines.

Results: The optimum conditions for the labelling reaction were: methylating agent: [11C]CH₃OTf, solvent: formic acid, precursor amount: 5mg, temperature: 60°C and reaction time: 10min. With these conditions 11C-SAM was obtained with a purity of 34% in the reactor, as a mixture of the two stereoisomers. Further purification and formulation were done. Quality control tests included solution appearance, pH, residual solvents (GC), chemical and radiochemical purity (HPLC), radionuclide purity and identity, and specific activity. Microbiological purity was also evaluated.

Conclusion: The metabolomics study of PCa progression could lead to the characterization of the disease and give a more complete understanding of disease progression. Sarcosine and its proximal regulatory enzymes seem to have an intermediary role in neoplastic progression modulating cell invasion and migration. Thus, components of the sarcosine pathway may be used as potential biomarkers of PCa tumour progression and aggressiveness. [11C]SAM seems to be a very promising compound in PCa.

IAEA-CN-232/61

Immunoscintigraphy with ^{99m}Tc -hR3 to Evaluate the Efficacy of Treatment with Nimotuzumab in Patients with Prostate Cancer and Bone Metastases

T. Crombet Ramos¹, A. Perera Pintado², J.F. Batista Cuellar², L.A. Torrez Aroche², A. Prats Capote², I. Mendoza Hernández³, D. Ills González³, J. González González³, Y. Peña Quián²

¹Center of Molecular Immunology, Havana, Cuba.

²Isotope Center (Direction of Clinical Research), Havana, Cuba.

³National Coordinating Center for Clinical Trials, Havana, Cuba.

Corresponding Author: yamilepq@infomed.sld.cu

Background: The survival of patients with prostate cancer is strongly related with the tumour spread. When tumour is confined to the prostate gland, we can expect a median survival of 5 years. The epidermal growth factor (EGF) stimulates the growth of cell lines in EGF dependent tumours. The humanized monoclonal antibody anti-EGFr Nimotuzumab (hR3) is a recombinant EGF (without the murine antibodies side effects), capable to inhibit the growth of malignant tumours with EGF receptors expression.

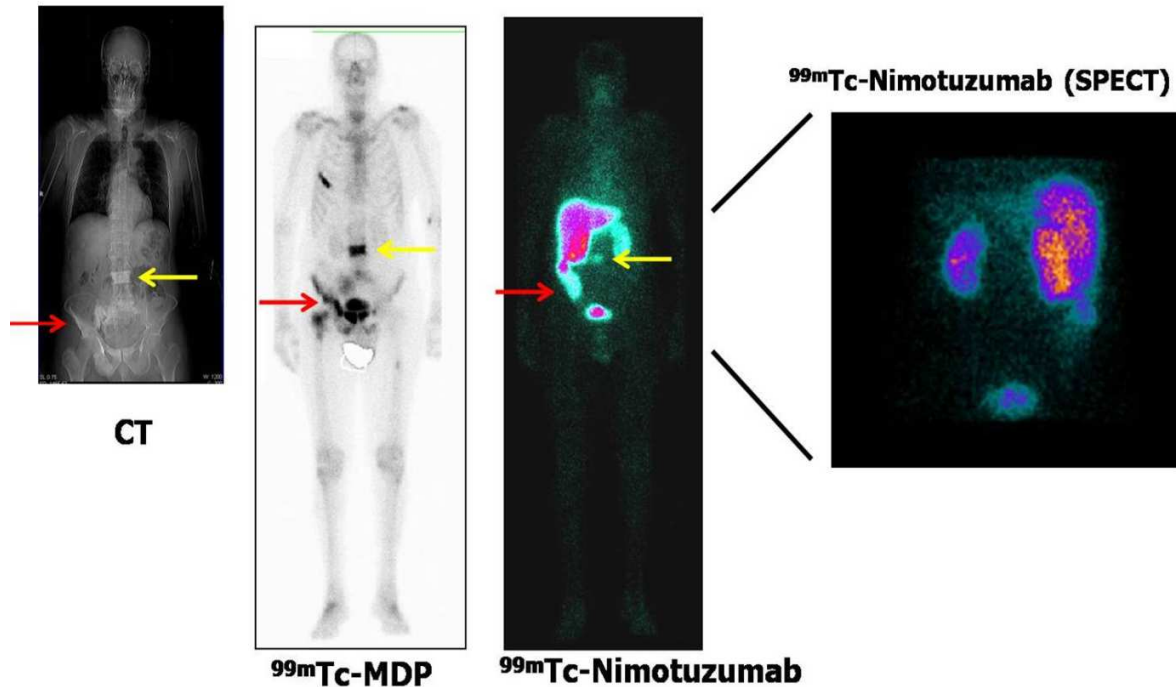
Aim: To determine the usefulness of the immunoscintigraphy by ^{99m}Tc -hR3 for evaluating the efficacy of treatment with the monoclonal antibody nimotuzumab in patients with prostate cancer and bone metastases.

Methodology: Fifty patients with diagnosis of prostate cancer and bone metastases were included. Immunoscintigraphy with ^{99m}Tc -hR3, computed axial tomography and bone scintigraphy with ^{99m}Tc -MDP were performed, before and three months after treatment with the "cold" monoclonal antibody (Nimotuzumab).

Immunoscintigraphy: Whole body (anterior and posterior view) at 4 hours and 24 hours after administration of 1110 MBq of ^{99m}Tc -hR3 and tomographic studies of the regions with bone metastases were acquired. Also, we compared the images obtained before and after treatment. The dose of Nimotuzumab administered to patients was 200 mg every 14 days.

Results: 66% of patients with metastatic lesions detected by scintigraphy with ^{99m}Tc -MDP showed positive results with immunoscintigraphy. There was correlation between the results of ^{99m}Tc -MDP and immunoscintigraphy with ^{99m}Tc -hR3. Immunoscintigraphy was useful to determine the metastatic lesions that express receptors for the hR3. 94% of patients with positive immunoscintigraphy had a good response to treatment with the cold "kit" of Nimotuzumab.

Application of Immunoscintigraphy with ^{99m}Tc -hR3 to treatment planning with MAb (Nimotuzumab).



Bone Metastasis of a Prostate Carcinoma

Conclusion: Immunoscintigraphy with ^{99m}Tc -hR3 should be useful to evaluate the effectiveness of monoclonal antibody Nimotuzumab in patients with prostate cancer. Further studies with bigger sample size should confirm our findings.

IAEA-CN-232/63

Beyond Milan Criteria in Hepatocellular Carcinoma: Does Fluorine-18-Fluorodeoxyglucose (FDG-PET) Hold the Key

D. Jangid¹, A. Sen¹, S. Pandel¹, V. Agarwal²

¹Medanta the Medicity Hospital

²Sahara Hospital Lucknow

Corresponding author: surbhipande@gmail.com

Background: Worldwide, the Milan criteria have been the standard for selection of patients with hepatocellular carcinomas (HCC) for liver transplantation, with reported 5-year survival of over 70% after transplantation. However, it is deemed to be too restrictive, and many strategies like including serum tumour marker assays or tumour biopsy to assess histological grade are being attempted to include patients who would have otherwise been denied potentially curative liver transplant without compromising survival. A modest expansion of these criteria now seems justified, in the setting of availability of living donors. The aim of our study was to assess the usefulness of positron emission tomography with fluorine-18-fluorodeoxyglucose (FDG-PET) in modification of recipient selection in more advanced tumour stage.

Methodology: FDG PET scans of 23 patients on the liver transplant service with primary tumour exceeding Milan Criteria (single tumour >5 cm and multiple tumours >3) were retrospectively reviewed. FDG positivity was defined as tumour / non tumour background ratio more than 1.5 (group A, n=13), while non-avid tumours were categorized into group B (n=11). The largest single tumour measured was 8.1 cm, and 8 cases were multicentric. Results were correlated after transplant with clinical, biochemical and radiological follow up (mean period 48 months).

Results: Of the 13 patients with FDG positivity at baseline, 11 (84.6%) presented with recurrence (intra and extra hepatic). In 8 patients (61%), the primary tumour was solitary, suggesting that metabolic information is independent of macromorphology. None of the patients with tumour to background ratio more than 3 or absolute SUV of more than 9 had tumour free survival exceeding 8 months. In group B (n=10), there were only 2 (20%) recurrences. Overall, the tumour free survival in group B was 100%, 90% and 80% at 2, 3 and 4 years, respectively. There was a significant association between recurrence and FDG avidity ($p = 0.0003$), whereas absence of FDG uptake in spite of tumour size >5cm correlated with favourable outcome.

Conclusions: In the effort to offer curative liver transplant to maximum number of patients with HCC, merely considering tumour macromorphology appears insufficient. Instead, a multidisciplinary approach including factors providing reliable insight into tumour biology would be more appropriate. In this regard, the metabolic information provided by FDG-PET could be the single most important factor in guiding the decision making process in advanced tumours.

IAEA-CN-232/64

Synthesis and In Vitro Evaluation of Radiobrominated Benzovesamicol Analogue: Ortho-Bromo-Benzovesamicol as a Potential Sigma-1 Receptor PET Ligand

T. Kozaka¹, Y. Kitamura², M.A. Azim³, K. Shiba⁴

¹ Assistant Professor, Advance Science Research Center, Kanazawa University

² Associate Professor, Advance Science Research Center, Kanazawa University

³ Senior Scientific Officer, National Institute of Nuclear Medicine and Allied Sciences, Dhaka

⁴ Professor, Advance Science Research Center, Kanazawa University

Corresponding Author: anwarri79@gmail.com

Background: The purpose of the study was to develop new PET (positron emission tomography) radioligands for imaging sigma-1 (σ -1) receptors. σ -1 receptor (S1R) radioligands have the potential to detect various neurodegenerative diseases, psychiatric disorders, including schizophrenia, paranoid psychosis and personality disorder. We have synthesized new benzovesamicol (BV) analogues with a halogen at the ortho-position of the 4-phenylpiperidine moiety of BV, which have the affinities to VAcHT and σ receptors (σ -1, σ -2).

Methodology: The key intermediate for the synthesis of ortho-bromo-trans-benzovesamicol (OBBV) was 4-(2-bromophenyl)piperidine, which was derived from ortho-bromo benzaldehyde. Coupling reaction of 4-(2-bromophenyl)piperidine with 2,3-dihydronaphthalene oxide in ethanol furnished OBBV. A bromo substituent of OBBV was replaced by a trimethylstannyl group to obtain OTBV. Treatment of OTBV with iodine in chloroform at room temperature yielded OIBV. VAcHT and σ receptors affinities of OBBV and OIBV were evaluated through in vitro competitive binding assays. In VAcHT binding assay, rat cerebral membranes were incubated for 60 minutes at 37C degrees in presence of 1,3-di-*o*-tolylguanidine (DTG) to mask the σ receptors. VAcHT antagonist, (-)-[3H]vesamicol was used as radioligand. DV, BV and (\pm)-vesamico·HCl were also studied as comparable standards. In σ -1 receptor binding assay, rat cerebral membranes were incubated for 90 minutes at 37C degrees with (+)-[3H]pentazocine as radioligand. In σ -2 receptor binding assay, rat liver membranes were incubated for 90 minutes at 37C degrees in presence of (+)-pentazocine to mask σ -1 sites. Sigma receptors selective agonist, [3H]DTG was used as radioligand. In both the σ -1 and σ -2 binding assay, DV, BV, (\pm)-vesamico·HCl, pentazocine and DTG were also studied as comparable standards. The K_i values were calculated using GraphPad Prism v4 software. The inhibition constant K_i values were calculated from $IC_{50}/(1 + C/K_d)$, where C is the concentration of the radioligand.

Figure 1: In Vivo Biodistribution of [⁷⁷Br]OBBzV.

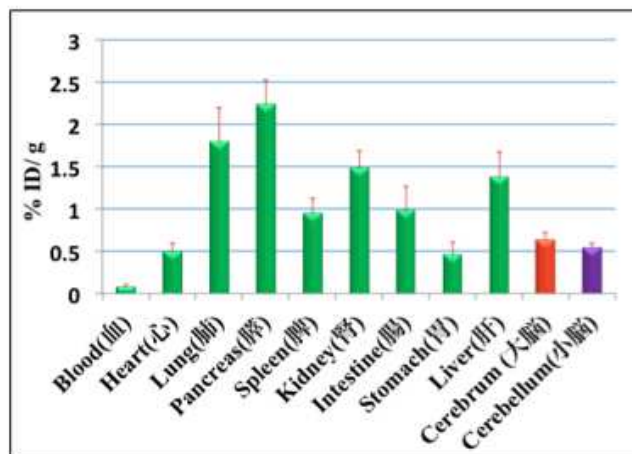


Figure 2: In vitro binding affinity of (+/-) OBBzV for VACHT, σ -1 and σ -2.

	VACHT Ki(nM)	σ -1 Ki(nM)	σ -2 Ki(nM)
(+/-)-OIBzV	38.3	65.3	259.0
(+/-)-OBBzV	43.5	19.6	163.0
(+/-)-MIBzV	7.5	26.8	35.3
(+/-)-MBBzV	7.5	34.9	23.4
(+/-)-PIBzV	11.3	10.1	8.9
(+/-)-PBBzV	10.3	6.3	10.6
(+/-)-Vesamicol	25	26.2	98.0
(+/-)-Benzovesamicol	5.49	20.9	74.5
Pentazocine		10.2	1790.0
DTG		43.8	15.4

Results: In in vitro competitive binding studies, OIBV showed no selectivity and very poor affinity to VACHT and σ receptors. On the contrary, OBBV showed high affinity to the σ -1 receptor which was almost comparable to that of (+)-pentazocine. Compared to DTG & (\pm)-pentazocine, OBBV showed higher affinity to the σ -1 receptor. The binding affinity of OBBV for the σ -1 was also prominently higher than that of σ -2 receptor. OBBV showed much lower affinity for VACHT and σ -2 receptor compared to vesamicol and DTG.

Conclusion: The findings of the in vitro binding studies indicated that OBBV could be used as a potential sigma-1 receptor ligand with high affinity and selectivity. Radiolabeling of OBBV for the further in vivo binding study is undergoing in the laboratory.

IAEA-CN-232/65

Impact of 131I SPECT/ Low Dose CT on Nodal Staging of Differentiated Thyroid Carcinoma

A. Mhiri, F. Ben Slimène

Nuclear Medicine Department-Salah Azaiez Institut

Corresponding Author: mhiri_aida@yahoo.fr

Background: In differentiated thyroid carcinoma (DTC), lymph node metastases (LNM) can be detected by elective neck dissection. However, it's not performed in a significant number of patients with DTC. Furthermore, in a few cases, LNM may elude surgical removal. Iodine-131(131I) imaging performed after radioiodine ablation also offers the possibility of nodal staging. However, hybrid imaging, combining single photon emission computed tomography with 131I and X-ray computed tomography (SPECT/CT) more accurately detects regional LNM than does planar imaging which is low in sensitivity and anatomic landmarks.

The aim of our study was to assess the diagnostic value of hybrid imaging combining 131I SPECT/CT on nodal staging of patients with thyroid carcinoma.

Methodology: We studied 65 adult patients, who previously underwent total thyroidectomy for DTC. These patients underwent planar imaging and SPECT/CT after 3 weeks of L-thyroxine withdrawal and 4 days after oral administration of 3,7-5,55 GBq (100-150mCi) of 131I. SPECT/low dose CT of the neck was acquired with a Symbia T camera with high energy collimators. Planar scans and SPECT/CT images were evaluated for cervical tracer uptake independently of each other and of the clinical findings.

Results: Planar imaging and SPECT/CT showed respectively 50 and 65 foci of uptake in 49 of 65 patients (75%). SPECT/CT confirmed all foci seen on planar imaging and identified 15 occult additional foci in 14 of the patients (21%). SPECT/CT allowed the identification of 18 lymph node metastases classified as thyroid remnant or as indeterminate on planar imaging SPECT/CT; thereby providing a gain in information on nodal stage in 15 of the 65 patients studied (23%).

Conclusion: Our study has shown that the addition of SPECT/CT improves the performance of iodine-131 planar imaging. In fact, SPECT/CT had determined lymph node involvement at radioablation performed for DTC more accurately than had done planar imaging.

IAEA-CN-232/66

**Contribution of Imaging in the Diagnosis of Stress Fractures in
Point «G» Hospital, Bamako Mali**

S. Sidibé, A.C. Koné , B. Niaré

Radiology and NM department Point "G" hospital Bamako, Mali

Corresponding Author: sidibes@hotmail.com

Background: The objective of this study was to evaluate the diagnostic value of ultrasonography, radiography and bone scintigraphy in the diagnosis of stress fractures in our radiology department.

Methodology: This was a retrospective study analysing the radiological record of 21 athletes who had to make at least standard radiography, ultrasound and bone scintigraphy of the painful bone segment. These patients, aged 16 to 48, were sent to the Point "G" hospital's radiology department for radiological assessment of pain worsened by physical activity. Radiography consisted of performing facial and lateral (when necessary) view of the painful bone segment. The ultrasound consisted of performing the longitudinal and cross sections of soft tissue around the painful area, whereas bone scintigraphy consisted of "two phases" acquisition (early phase vascular: scan on the painful bone segment; late-phase: whole-body bone scans) after injection of 185 MBq (20 mCi) diphosphonate labelled with technetium 99m.

Results: Out of the 21 cases, three tests were normal in 6 patients simultaneously. Bone injury was found on radiographs in 4 patients (4/21), on ultrasound in 10 patients (10/21) and with scintigraphy in 15 patients (15/21). If the ultrasound did not show any abnormality in one of the 4 patients with bone injuries on radiography, scintigraphy was positive in all patients with radiographic and/or ultrasound abnormality. Out of the 6 hard to diagnose, a CT scan was performed in one case and showed iliopubic injury stress fracture.

Conclusion: Medical imaging helps to improve the diagnosis of stress fractures. In our settings, where the availability of nuclear medical imaging is low, ultrasound is a useful tool for the diagnosis of these kinds of trauma.

IAEA-CN-232/67

PET/CT Imaging Protocol Optimization for Evaluation of Patients with Implanted Cardioverter Defibrillator

M. De Marco, S. Maggi, L. Falasconi

Aou Ospedali Riuniti di Ancona

Corresponding Author: marco.demarco@ospedaliriuniti.marche.it

Background: Metallic artefacts are quite common in CT images of patients who have permanent metallic implants such as cardiac pacemakers or defibrillator. The presence of these streaks not only deteriorates the quality of the CT images but also degrades the quantitative value of the corresponding CT-based attenuation correction PET images causing inaccurate quantification of tracer uptake and geometrical non-uniformities.

This study analysed three different reconstruction algorithms, filter variables and acquisition parameters with the aim of minimizing these non-uniformities.

Methodology: A NEMA water fillable torso phantom has been used to simulate patient undergoing a CT-PET examination; hot spheres and background have been filled with an ^{18}F -FDG solution (22kBq/mL and 5kBq/mL respectively) and an implantable cardioverter defibrillator has been applied on it.

The study has been conducted in two parts: (a) modifying acquisition parameters (CT tube voltage and scan time); (b) changing reconstruction algorithms and filter variables such as number of iterations and subsets. Finally, images have been geometrically and analytically evaluated measuring spheres' diameters and standardized uptake value (SUV).

Results: Geometrical distortions have been measured radially, in the opposite direction of defibrillator, namely by +11% and +35% for VUE-POINT-FX and VUE-POINT-HD algorithm respectively. Regarding SUVs measurements an overestimation of the values by approximately +34% for VUE-POINT-FX and +5% for VUE-POINT-HD was shown.

Measurements also proved that differences in SUVs may be minimized increasing the number of iterations and subsets. Practically no variations were recorded if the phantom was scanned using a lower CT tube voltage (100kV) and images were reconstructed with an increased number of subsets and iterations (24 and 4, respectively). This result comes at the expense of slightly higher reconstruction time (approximately 20 seconds for a two bed scan).

Conclusion: The study resulted in a fairly comprehensive analysis of the acquisition and reconstruction parameters that may be used in scanning patients with implanted cardioverter defibrillator.

The authors compared three reconstruction algorithms, namely VUE-POINT-FX, VUE-POINT-HD and FORE-FBP, applying different number of subsets and iterations.

Several numerical tests have been performed which suggest that VUE-POINT-HD reconstruction algorithm calculated with 4 iterations and 24 subsets produces accurate SUV measurement and significantly reduces image distortions. Moreover it was reported that applying a lower CT-tube voltage (100kVp) improves diagnostic image quality together with a significant reduction of radiation dose delivered to the patient.

IAEA-CN-232/68

PET Cardiac Imaging- Reconstruction Parameters vs. Diagnostic Information

N. Raina, A. Sen, A. Pathak, D.R. Jangid

Medanta the Medicity

Corresponding Author: namrita_raina@yahoo.com

Background: Cardiac positron emission tomography (CPET) has been validated as an imaging procedure for myocardial viability. Various tomographic reconstruction techniques enable us to choose which technique might provide the ‘best’ quality image. ‘Filter back projection’ (FBP) has gained wide acceptance in single photon emission computerized tomography (SPECT) image reconstruction, whilst ‘iterative method’ (ITR) is yet to gain clinical acceptability in CPET.

Our objective was to optimize reconstruction parameters (FBP and ITR) using Gaussian filter (GF) and Butterworth filter (BWF) in CPET images and score it for visual perception of image and its diagnostic information content.

Methodology: Twenty patients underwent CPET viability study, where first a SPECT imaging was acquired 25 min after injection of 3mCi of Tl20 (thallium chloride) on SPECT gamma camera system (Symbia ‘S’, dual headed; Siemens). This was followed by CPET metabolic imaging after injection of 5mCi 18F-FDG (fluorine-18 fluorodeoxyglucose) on Siemens mCT Biograph. CPET images were processed by FBP using BWF (Group -I), by ITR method using BWF (Group-II), by FBP using GF (Group -III), by ITR using GF (Group-IV), by ITR using BW (Group -V) and by ITR using GF (Group-VI). Four cardiac imaging specialists interpreted processed data of all six groups. For the information content and image quality, scoring was done on a scale of 0-4, with ‘0’ showing inconclusive diagnostic content and ‘4’ showing excellent diagnostic information content.

Results: Average score with standard deviations for Group I to VI were 3.5+0.08, 3.68+0.1, 3.58+0.05, 3.68+0.1, 3.58+0.05 and 3.74+0.05, respectively. Scores for diagnostic information content were not significantly different among the groups I to V; however the group VI had an edge over the rest of the groups.

Conclusion: ITR method of reconstruction using Gaussian filter may be a better choice for obtaining optimum quality of CPET images.

IAEA-CN-232/69

Radioguided Surgery in Vulvar Cancer

R. Morales, R. Cano

Instituto Peruano de Energía Nuclear

Corresponding Author: rmoralesgb@gmail.com

Background: In order to validate a combined technique in detection of sentinel nodes in vulvar cancer patients, lymphoscintigraphy and patent blue were applied in fourteen patients.

Methodology: Patients with vulvar malignant tumours, stages I and II, had sentinel node detection using lymphoscintigraphy and a gamma probe in surgical room, after injection of Tc99m dextran and patent blue dye. Images were acquired in a single head gamma camera with LEHR collimator.

Results: Thirteen patients with epidermoid vulvar carcinoma and one with vulvar malignant melanoma, 28 to 80 years old (median 68 years), were included in the study. These were consecutive patients delivered from Oncological Gynecology to the Nuclear Medicine Center of IPEN from 2000 to 2005. Sentinel nodes were seen between one and sixty minutes after injection. All sentinel nodes were located in the superficial inguinal region. Detection rate was 100% (14/14), with bilateral drainage in 29% of patients. Three out of 14 patients with vulvar cancer showed metastases in the sentinel node. Two of them had epidermoid vulvar carcinoma and one, malignant melanoma. There were no metastases in non-sentinel nodes when sentinel nodes were negative for metastases.

Conclusion: It is feasible to localize sentinel nodes in vulvar cancer, using a combined technique with Tc99m dextran and patent blue dye.

IAEA-CN-232/70

Correlation between Sentinel Node Lymphoscintigraphy and Guided Surgery in Acral Melanoma Patients

M. De La Cruz¹, V. Polar², R. Morales³, R. Cano³

¹Instituto Nacional de Enfermedades Neoplásticas

²Universidad Peruana Cayetano Heredia

³Instituto Peruano de Energía Nuclear

Corresponding Author: rmoralesgb@gmail.com

Background: Acral malignant melanoma is frequent in Peru and lymphoscintigraphy (LSG) for sentinel node (SN) localization and surgery is a routine procedure in the cancer hospital for these patients. The objective of the present work is to report lymphoscintigraphic aid to guided surgery for acral melanoma.

Methodology: LSG was performed sixteen to twenty hours before surgery using Tc99m dextran in acral malignant melanoma patients. Images were acquired with a double head SPECT gamma camera. A mark was performed in the skin for aiding localization in the operating ward. A gamma probe was used for sentinel node or nodes precise localization in the surgery ward, and material was delivered to pathology for study.

Results: From September 2013 to December 2014, 43 patients with acral melanoma had LSG previous to SN surgery and were included in the study. Forty patients had acral lentiginous melanoma, one patient, nodular melanoma; one patient had desmoplastic melanoma and another, an amelanotic acral malignant melanoma. 29 patients had thick melanoma (Breslow thickness > 4.0 mm). SN was found in all cases. In five cases there were multiple lymphatic paths, in 38 patients there was a unique path, with an ordered way. Both situations were in concordance with gamma probe guided surgery. In 29/43 patients (62%) the number of SN was the same in LSG and surgery findings. In 38% of cases, there was an underestimation of SN number.

Conclusion: LSG is an important aid for guided surgery in acral melanoma patients. Efforts should be done to improve relevant information for the surgeon, mainly number of SN to be operated.

IAEA-CN-232/71

Daily System Quality Check –Essential for PET/CT Performance

N. Raina, A. Sen, A. Pathak, D.R. Jangid

Medanta the Medicity

Corresponding Author: namrita_raina@yahoo.com

Background: The combined positron emission tomography - computed tomography (PET/CT) system provides co-registered anatomical and functional images in a single multimodal imaging, offering several major interpretative and clinical advantages in oncology.

Objective:

To ensure continued optimal operation of PET/CT equipment in terms of image quality and accuracy, before the patient is subjected to a PET/CT study.

Methodology: We have incorporated a ‘daily quality check plan’ for PET/CT system (Siemens Biograph mCT) before subjecting the patient to a PET/CT which includes:

1. Daily check of the room temperature and the humidity, before switching ‘on’ the system
2. Running of daily CT check-up procedure (which is a built-in protocol) to ensure proper functioning of CT Gantry and table, filament adaptation check, defective channel correction, calibrations check, and tube collimator check with QA phantom.
3. Performing daily PET quality check up with Germanium-68 (Ge-68) Uniform Phantom (G-UP) to ensure daily quality system parameters. G-UP is aligned in the CT field of view using the positioning lasers. ‘Setup’ is selected in ‘PET Quality Check’ from the main menu and started. This procedure checks the detector parameters in order to block noise, Scanner efficiency scatter ratio, Time Alignment, residual alignment and Scanner Efficiency Correction factor. If all the factors are within limits then the results will show ‘Passed’. Sinograms are visually inspected for any streaks and artefacts.
4. Everyday a two-bed PET/CT is acquired with G-UP and checked for any artefacts, slice reconstructions and mis-registration in the fusion image.

Results: Observations are made on the basis of five years data, where we could check and correct before a major defect is shown in actual patient study.

1. In 0.1% of cases we could see the vertical lines artefacts which we found to be due to the increased humidity in the PET/CT room.
2. In 1% of cases scatter ratio was found to be altered and was corrected by running ‘full step-up quality check’ with Ge-68 Rod sources.
3. In 1% of cases CT artefacts were seen and were corrected by running calibrations with CT phantom; the defective channel had to be replaced; or the CT tube had to be replaced.
4. Time alignment residual was found not to be within limits (2% of cases), which was corrected by running time alignment with the G-UP sources by the service engineer.
5. In 1.5% of cases block detector noise was found to be out of range, indicating the need to change the block in the detector module, which was also confirmed in sinogram image.
6. In 1% of cases daily two-bed PET/CT images showed problems in reconstruction of PET/CT images which were corrected before actual patient was subjected.

Conclusion: ‘Daily quality check plan’ enables us to be confident as far as performance of PET/CT is concerned, before actually subjecting the patient to the procedure. The plan helps to maintain consistent and high image quality, minimizes chances for artefacts, catches potential problems earlier, increases time

International Conference on Clinical PET-CT and Molecular Imaging (IPET 2015): PET-CT in the Era of Multimodality Imaging and Image-Guided Therapy

efficiency of the PET/CT system, maintains quantitative accuracy, and eliminates unnecessary repetition of scans.

IAEA-CN-232/72

**Retrospective Study to Determine the Confidence Level in
Diagnosing the Secondary Bone Deposits by Tc99 MDP Bone
Scans in National Hospital of Sri Lanka**

P. de Silva

National Hospital of Sri Lanka

Corresponding Author: prasaddes@hotmail.com

Background: Tc-99 MDP bone scans have been performed for more than 20 years at the National Hospital of Sri Lanka (NHSL) and reported with different percentage of diagnostic accuracy. This study was done to determine the diagnostic confidence level.

Methodology: Studies done in the period 1 October 2014 – 31 December 2014 were selected as a sample and have been reported by 4 different consultant radiologists independently, with experience in bone scan reporting ranging from 11 to 26 years.

Results were analysed to determine the percentage of scans with a definite diagnosis (either positive or negative) for metastasis, the percentage in which further investigation was needed to have a definitive diagnosis, and the percentage in which difficulties in giving a definitive diagnosis were encountered.

Results: Age of the patients varied from 3 years to 81 years.

There was a higher percentage of females (61.85%) than males (38.15%).

The most prevalent malignancy in the study was breast cancer (58.5%), followed by prostate cancer (34.1%).

The most effectively (100%) diagnosed malignancy was thyroid cancer without any further imaging, followed by prostate cancer, with 83.7% confidence with bone scan alone and 100% confidence with x rays.

80.4 % were diagnosed only with bone scan. 18.1 % needed plain X rays for confirmation. 1.8% needed further investigations but more than half (61%) were never given a definitive diagnosis.

Overall diagnosis was given in 80% of the cases by Tc-99m MDP scan alone.

Diagnosis was given with the combination of plain X rays in 98.1%.

Even after further investigations, which included US scans and CT scans, in 1.1% of the cases, a definitive diagnosis was not given.

Conclusion: Interpretation of Tc-99m MDP bone scans has been very good even without the help of the additional imaging.

However, after it was combined with plain x ray correlation, an excellent outcome was reached (98.1%).

Plain X rays were most beneficial in prostate cancer (83.7% without X rays, reaching 100% with the help of the X rays).

IAEA-CN-232/73

Optimization of Site Planning of PET Cyclotrons Using Monte Carlo Simulations

M. Marengo¹, A. Infantino², G. Cicoria¹, D. Mostacci²

¹Department of Medical Physics, University Hospital “S. Orsola – Malpighi”, Bologna, Italy

²Department of Industrial Engineering, University of Bologna, Italy

Corresponding Author: mario.marengo@aosp.bo.it

Background: The extraordinary growth of PET during the last 10 -15 years has determined the diffusion of cyclotrons for production of PET radionuclides, with still increasing number of installations and new models introduced into the market. The established documents giving guidance on proper site planning, shielding and risk assessment typically refer to analytical methods for the calculation of both shielding and materials activation, considering an approximate or idealized geometry set up. These valuable but outdated approaches can be nowadays integrated or replaced by the use of Monte Carlo (MC) simulations. Up-to-date MC codes have now accurate libraries for transport and interactions of neutrons and charged particles at energies below 250 MeV, and recent computers allow the systematic use of simulations with realistic geometries and high statistical accuracy in acceptable computational time.

Methodology: In our work, the MC code FLUKA has been extensively used in order to model several types of cyclotron for radionuclides production; a) the General Electric PETtrace (16.5 MeV); b) the ACSI TR19 (19 MeV); and c) the IBA Cyclone 70, including their targetry. Simulations allow for accurate estimation of the source term, in particular the effective dose rate distribution during irradiation of each specific type of target material, the effective number of neutrons produced per incident proton and neutron spectral distribution; parameters that are fundamental in order to properly calculate shielding. Moreover, simulations make it possible to assess specific components of the shielding (local shielding or additional on-purpose barriers) and the transmission of dose in ducts, mazes and doors. The activation of the structure of the cyclotron, of the ambient air, in particular for the production of ⁴¹Ar; of the structural walls and of the underground soil and water can be prospectively studied.

Results: Validation of the dose distribution around the cyclotrons PETtrace and TR19 has been made comparing predictions from the simulations with experimental measurements of neutron environmental dose equivalent with TLD, bubble detectors and rem-meter. The comparison shows an excellent agreement, within the interval of statistical fluctuations and experimental uncertainties. The study of the dose distribution around cyclotrons was fundamental in planning new installations, in particular as regards to “bad geometry” items, like ducts and wall penetrations. The estimates of ⁴¹Ar in air were validated against experimental sampling and analysis by high resolution gamma ray spectrometry. Target activation studies for ¹⁸F, ⁸⁹Zr and ^{99m}Tc gave results in agreement with experimental measurements and theoretical yields.

Conclusion: MC simulations represent an up-to-date solution for relatively complex problems of estimation of the source term, in particular in the case of accelerators, assessment of shielding and conditions of “bad geometry”. Computational time is affordable, with modern workstation or clusters,

International Conference on Clinical PET-CT and Molecular Imaging (IPET 2015): PET-CT in the Era of Multimodality Imaging and Image-Guided Therapy

giving scientists in the biomedical field a powerful tool for optimization of radiation protection.

IAEA-CN-232/74

Incremental Value of Routinely Including Brain as a Part of the Whole Body 18F-FDG PET/CT and Use of Contrast for Staging NSCLC - Its Efficacy and Comparison with MR Imaging of Brain for Detection of Asymptomatic Brain Metastases

S. Ray, J. Das, A. Chandra, R. Shrimali, S. Chatterjee

Tata Medical Center

Corresponding Author: drsoumenray@gmail.com

Background: Brain MRI is the accepted standard to detect asymptomatic brain metastases (ABM) although some centres propose the use of contrast enhanced brain CT in staging non-small cell lung cancers (NSCLC). In most centres, staging with fluorodeoxyglucose (FDG) PET-CT protocol for NSCLC does not include the brain. We investigated the benefit of routinely including brain CT with contrast as a part of the PET-CT staging protocol in NSCLC and compared their asymptomatic brain metastases detection rates to MRI.

Methodology: Data from the first 100 consecutive patients was retrospectively analysed. TNM staging information was tabulated. Comparison of brain image of the whole body PET-CT, non-contrast plain CT and contrast enhanced CT (CECT) images of the brain not fused with PET and dedicated brain PET images was performed in correlation with brain MRI.

Results: T3/T4 primary was found in 52% patients with 89.2% having N2/N3 nodal disease on PET-CT scan. 18% had ABM on MRI, 61.1% of whom had adenocarcinoma. Amongst adenocarcinoma, 72.2% and 88.9% had T3, T4 lesions or N2, N3 disease respectively in the ABM group, compared to 45.1% and 64.6% in those without ABM. Similarly, in squamous cell carcinoma 100% versus 32.3% had either T3/T4 and/or N2/N3 disease respectively in the ABM versus non-ABM groups. Table 1 shows the differential detection of brain metastases using the various techniques: 4 of the 14 brain metastases detected in PET-CT had FDG avidity and in other 10 cases it was photopenic. MRI brain detected metastases in 4 extra cases (size range 4-8mm) compared to CECT.

Brain metastasis	MRI	PET-CT	CECT	PLAIN CT	DEDICATED BRAIN PET
Present	18	14	14	9	15
Absent	82	86	86	91	81
Total	100	100	100	100	96
SENSITIVITY		77.8%	77.8%	50%	83%

Conclusion: Routine inclusion of brain CECT as part of FDG PET-CT protocol could detect asymptomatic brain metastases in 77.8% cases therefore negating the requirement of an additional brain

staging MRI in NSCLC. This could enable resource optimised use of MRI staging in more advanced T/N stages. There is no significant difference in sensitivity between CECT brain and fused PET-CT image of the brain. Non-contrast plain CT has very poor sensitivity (only 50%) for detection of brain metastasis. Addition of dedicated brain PET to CECT enhances the sensitivity for identification of brain metastasis to 83%. We recommend routine inclusion of brain in the whole body protocol for staging with PET-CT in NSCLC along with use of iodinated contrast and preferably an additional dedicated brain PET acquisition.

IAEA-CN-232/76

PET-CT-MRI Triple Fusion and its Application in Head and Neck Oncology: An Alternative to Integrated PET-MRI in Developing Countries

P. Choudhury, A. Jena, M. Gupta

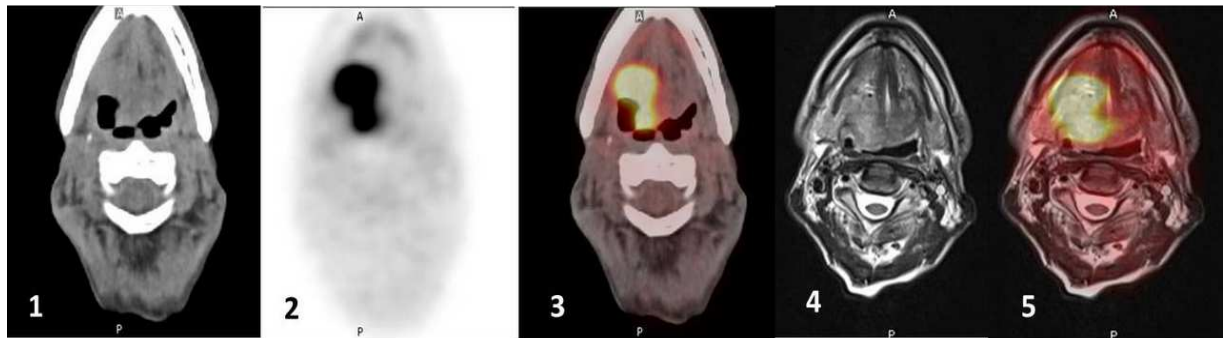
Rajiv Gandhi Cancer Institute Research Centre, Delhi, India

Corresponding Author: pschoudhary@hotmail.com

Background: MRI is preferred to CECT in the evaluation of head and neck malignancies. PET has added a new dimension, especially in the post treatment setting. PET-MRI seems to be a better solution here but is beyond the reach of the developing world. We herewith present our experience with a software based accurate 'triple fusion' and its clinical utility.

Methodology: Sixty eight consecutive patients (Jan-Dec 2012) with primary head and neck cancer who received local and/or systemic treatment based on conventional staging methods, being evaluated for assessment of response or suspected recurrence, who underwent whole body PET-CT and contrast enhanced MRI of the neck on the same day, under our institutional PET-MRI protocol, were included. MRI was performed first with multiple sequences including post contrast images and then whole body 18F-FDG PET with NCCT. Regional head and neck high count image was acquired in a specially designed flat bed with a head holder mimicking the MRI bed. The PET-CT and MRI images were separately read by nuclear physician and MRI specialist in their respective stations blinded to each others findings. PET-MRI fusion was done in a dedicated console with triple fusion software which is a mutual registration based deformable algorithm using radial basis function as its model of the deformable field. CT and MRI algorithm has its parameters optimized for diagnostic MRI to CT. DIR was used to correct for differences in patient positioning providing semi-transparent overlays, checker boards and inset views to assess the quality of the deformation. Regional PET-CT images and MRI sequences were used for evaluation. T2 images were used for PET-MRI fusion. Other sequences were used if required.

Results: 68 patients, having HP correlation/ minimum 12 months follow-up, were included in analysis. Patients with distant metastasis were excluded. 88.2% were males. Age was 13-83 years (mean \pm SD 53.76 \pm 12.19) with 53 as median. Co-relating PET findings with outcome showed 62.5% PET positive had disease progression whereas 93.3% PET-negative remained disease free till endpoint. Negative PET was associated with better outcome ($p=0.009$). Sensitivity was 62.5% and specificity 93.3%. PPV and NPV were 83.3% and 82.4% respectively, with accuracy of 82.6% (AUC 0.85). Co-relating MRI with outcome showed 87.5% MRI positive patients had disease progression and 60% disease free patients also had positive MRI ($p=0.345$). No significant co-relation between MRI and progression was noted. Sensitivity was 87.5% and specificity 40%. PPV and NPV were 43.8% and 85.7% respectively, with accuracy of 56.5% (AUC 0.68). Comparing PET and MRI, 46% were MRI negative with negative PET. On the other hand 94.6% were MRI positive with PET being also positive ($p < 0.001$). Co-registered PET and MRI was better with specificity of 94.12% (AUC 0.83).



Case of Ca Tongue Post RT in 2013. Now showing metabolically Active altered signal intensity lesion in right base of tongue suggesting Recurrence: 1 : CT; 2 : PET; 3 : PET-CT fused; 4: MRI ; 5 : PET-MRI fusion

Conclusion: Clinically accurate registration is feasible with triple fusion software under a two equipment same day standardized institutional protocol. This fused study can be reported as an integrated PET-MRI with accurate clinical results.

IAEA-CN-232/77

Usefulness of 11C-Choline PET/CT in Disease Staging and Therapeutic Management of Prostate Cancer Patients

J. García, M. Soler, M. Moragas, M.P. Cozar, P. Bassa, E. Riera, J. Ferrer

CETIR-ERESA

Corresponding Author: jrgarcia@cetir.es

Background: Prostate cancer is the most frequent cancer form in men and second cause of death. Therapeutic approach is influenced by age, comorbidity, PSA level, Gleason score, D'Amico classification and TNM. Increased PSA after radical treatment is sensitive for recurrence detection, but imaging techniques are needed to locate the site(s), which is crucial to enable therapeutic approach. CT/MRI shows limited sensitivity for lymphatic involvement. Bone scan shows low specificity for bone metastases. 18F-FDG PET/CT shows low affinity for prostate cancer patients (PCa). The aim was to determine: 1. Usefulness of 11C-Choline PET/CT in detecting lymphatic/haematogenous involvement in intermediate/high-risk PCa, 2. Diagnostic performance in detection rate of biochemical recurrence, 3. Impact on therapeutic management for the different stages.

Methodology: 959 PCa who underwent 11C-Choline PET/CT (June 2006 – December 2014) for initial staging (20.2%) and biochemical recurrence (78%). 11C-Choline was synthesized in onsite-cyclotron. 296±185 MBq was administered with patient placed in PET-camera. Acquisition was immediately started: after CT, two consecutive whole-body PET studies were acquired without the patient moving (both PETs reconstructed with initial CT). Early and delayed images were evaluated visually and according to SUVmax. Two dynamic patterns were considered: stable/increasing and decreasing. PET/CT findings were compared with other imaging techniques and/or monitoring PSA. Due to ethical reasons, only lesions that would change staging were histologically confirmed.

Results: Initial staging - extraprostatic disease was found in 26.3%: Single site in 60.8%: 77.4% infradiaphragmatic; 6.5% supradiaphragmatic; 16.1% bone metastases. Multifocal disease was found in 39.2%, including 5.0% lung metastases. For treatment purposes, patients were classified as: 40% locoregional disease; 33.3% oligometastatic; 16.7% multimetastatic. Locoregional/oligometastatic patients (73.3%) underwent intensity-modulated-radiation-therapy with dose-escalation based on 11C-choline uptake.

Biochemical recurrence - In 68.4% of patients, one or more 11C-choline foci were found. Single recurrence was found in 33.1%: 13.3% prostate; 50.3% infradiaphragmatic; 5.8% supradiaphragmatic; 28.3% bone metastases; 1.7% lung metastases; 0.6% penis. Recurrence was multifocal in 66.9%, including 2.3% lung metastases; 1.1% hepatic metastases. Moreover, in 2.1% of patients a synchronic malignancy was detected: 0.6% lung; 0.4% colorectal, 0.4% meningioma; 0.4% esophagus; 0.2% parathyroid; 0.2% lymphoma.

Relationship between increased PSA and rate of recurrence detection was: 40% with PSA < 1ng/ml; 60% with PSA 1-4ng/ml; 83% with PSA > 4ng/ml. PSA kinetics were analysed in the group <1ng/ml, and PSA_{dt} was 4.13±2.63 months for a positive PET/CT study, and 13.14±9.63 months for a negative PET/CT.

Conclusion: Dual-phase-¹¹C-choline PET/CT was technically feasible despite the short physical half-life of the tracer. ¹¹C-choline PET/CT was useful for N/M evaluation of intermediate/high-risk PCa, and allowed selection and planning of radiation therapy. Sensitivity of ¹¹C-choline PET/CT for detection of biochemical recurrence was related with PSA, and allowed for an early therapeutic approach.

IAEA-CN-232/78

SPECT/CT and PET/CT in Patients with Differentiated Thyroid Cancer Metastases Treated by Stereotactic Ablative Radiotherapy

M. Havel¹, O. Kraft¹, P. Sirucek¹, J. Cvek², G. Havlova²

¹ Faculty of Medicine, University of Ostrava and University Hospital Ostrava

² University Hospital Ostrava

Corresponding Author: havel.martin@gmail.com

Background: Thyroid cancer is the most frequent malignancy of the endocrine system. Papillary and follicular types represent about 90% of thyroid cancers, its therapy and follow-up investigation is a domain of nuclear medicine specialization. Methods of therapy of differentiated thyroid cancer (DTC) involve combination of surgery, therapy with iodine-131 (¹³¹I), and eventually external beam therapy. The situation becomes more complicated in the case of inoperable metastases or non-iodine accumulating masses. Stereotactic ablative radiotherapy (SABR) with robotic device CyberKnife brings new opportunities. We present two cases where the hybrid imaging modalities engaging SPECT/CT and PET/CT played an essential role in the guidance and evaluation of this specialized method of therapy.

Methodology: 57 year old man (SUBJECT A) with papillary thyroid cancer, with oncological multiplicity, was treated surgically and with megadoses of ¹³¹I repeatedly owing to the accumulating neck and mediastinal metastases, until full scintigraphic regression achievement. Consequent PET/CT examination revealed metastatic ¹³¹I non-avid focus in the upper lobe of the right lung. Histologically the lesion corresponded to the metastasis of thyroid gland origin. The patient underwent SABR therapy aimed to the focus (30 Gy in 1 fraction).

74 year old woman (SUBJECT B) with follicular thyroid cancer, with elevated thyroglobulin levels, was re-treated six times with ¹³¹I because of accumulating foci on the neck. Full scintigraphic regression was not achieved. PET/CT was negative, but SPECT/CT revealed focus of higher iodine accumulation behind the trachea. Biopsy confirmed follicular cancer metastasis, its localization made surgery impossible. The patient underwent SABR targeted on the lesion (48 Gy in 16 fractions).

Results: In “SUBJECT A” the anti-thyroglobulin level dropped from >3000 to 452 U/ml during following sixteen months, and what is most important, the control PET/CT after the SABR therapy did not find any pathological focus in the right lung, even any post-radiation changes. In “SUBJECT B” the radioiodine whole-body scan after SABR with added SPECT/CT stated full scintigraphic regression of the lesion in the neck, the thyroglobulin level had decreasing tendency.

Conclusion: Hybrid imaging techniques SPECT/CT and PET/CT are necessary modalities when diagnosing metastatic disease in DTC, targeting external beam therapy and also when assessing efficiency of the treatment.

IAEA-CN-232/79

False-Positivity of Regional Nodal Metastasis on 18F-FDG PET/CT Imaging in Primary Cutaneous Squamous Cell Carcinoma

S. Park¹, J.H. Song², J. Oldan³

¹ Wonkwang University School of Medicine, Iksan, Jeonbuk, Republic of Korea

² Wonkwang University School of²Medicine, Iksan, Jeonbuk, Republic of Korea

³ Cleveland Clinic Foundation, Cleveland, OH, USA.

Corresponding Author: nmbach@wonkwang.ac.kr

Background: F18-fluoro-2-deoxy-D-glucose positron emission tomography/computed tomography (FDG PET/CT) scan can provide important information regarding regional lymph node status for developing treatment plans, and provide prognostic guidance for cutaneous malignancies. However, a small portion of cases with false-positive metastases have been reported in the primary cutaneous malignancies. Here we report two cases with false-positive regional nodes mimicking metastasis on an FDG PET/CT scan performed for staging of primary cutaneous squamous cell carcinoma (cSCC).

Methodology: FDG PET/CT had been performed for staging in two patients. The first patient was a 49-year-old male diagnosed with pathology-proven cSCC in the skin of his right thumb. He had a past four-year history of necrotizing skin ulceration and dermatitis in his right hand, resulting from previous excessive occupational radiation exposure many years ago in his right hand. The second patient was a 48-year-old male diagnosed with recurrent cSCC in his left buttock. He had suffered from steatocystoma multiplex with skin ulceration for the past three years, and he was initially diagnosed with cSCC three years ago.

Results: In the first patient, FDG PET/CT revealed high metabolic activity with maximal standardized uptake value (SUVmax) of 2.6 in the enlarged right axillary lymph node and of 7.6 in the pathology-proven right thumb primary. No metabolically active inflammatory focus was seen elsewhere in his right hand, and no other distant metastatic disease was observed on FDG PET/CT scan. In the second patient, there was a metabolically active mass (SUVmax of 8.4) pathology-confirmed cSCC abutting the gluteus maximus muscle in the cutaneous and subcutaneous layers of the left buttock, as well as multiple metabolically active (SUVmax of 3.8) enlarged left inguinal lymph nodes. No other inflammatory foci or distant metastatic disease were observed in the other body sites on FDG PET/CT. The metabolically active lymph nodes on FDG PET/CT scan in the two patients were biopsied, and all lymph nodes were confirmed as reactive lymphoid hyperplasia pathologically.

Conclusion: Our study demonstrates that a reactive lymphadenitis mimicking regional nodal metastases could be a potential problem for interpreting FDG PET/CT in patients with primary cSCC and a history of previous chronic cutaneous/subcutaneous inflammation, even though the inflammatory focus has resolved. These cases suggest that FDG-avid regional lymph nodes in patients with primary cSCC and a multi-year history of chronic inflammation should be taking into account the patient's clinical history.

IAEA-CN-232/80

Preparation and Preliminary Biological Evaluation of Lu-177 Labeled DOTATATE

F. Liu, H. Zhu, Z. Yang

Peking University Cancer Hospital

Corresponding Author: liufei0808@126.com

Background: The purpose of this work was to explore the possibility of ^{177}Lu labeled somatostatin analogue Octreotide as a diagnostic and therapeutic radiopharmaceutical for neuroendocrine tumours. Recently, the individualized therapy targeting peptide receptor radionuclide therapy (PRRNT) guided by molecular imaging has become a new treatment for cancer patients. Radiolabeled Octreotide can be used in SSTR positive neuroendocrine tumours for targeting, tumour staging and treatment, which results in a high activity concentration in tumour tissue, which has made ^{177}Lu radiolabeled Octreotide a new method in cancer diagnostic and therapeutic applications. Herein, we developed Lu-177 labeled Octreotide conjugated with DOTA for imaging and therapy of somatostatin receptor positive tumours.

Methodology: The peptide compound, DOTA-TATE, was synthesized and radiolabeled with ^{177}Lu to yield ^{177}Lu -DOTA-TATE (Figure.1). The precursor DOTA-TATE was labeled with ^{177}Lu in sodium acetate buffer (pH 4.0) by heating at $100\text{ }^\circ\text{C}$ for 15 min and the products were determined by instant Radio thin-layer chromatography and radio-HPLC. In vitro stability experiments were undertaken in 5% human serum albumin, NaAc (pH 5.5) and PBS (pH 7.4) at room temperature ($25\text{ }^\circ\text{C}$) for different time periods. After purification by a Sep-pak column, 12.95 MBq of ^{177}Lu -DOTA-TATE was injected intravenously to BALB/c nude mice bearing human HT29 colon tumours via tail vein, meanwhile controlled group of nude mice were injected with the same radioactivity of ^{177}Lu -DOTA-TATE and 0.5 mg DOTA-TATE (250 eq block dose). The SPECT/CT images were taken at 2 h, 4 h, 6 h after injection.

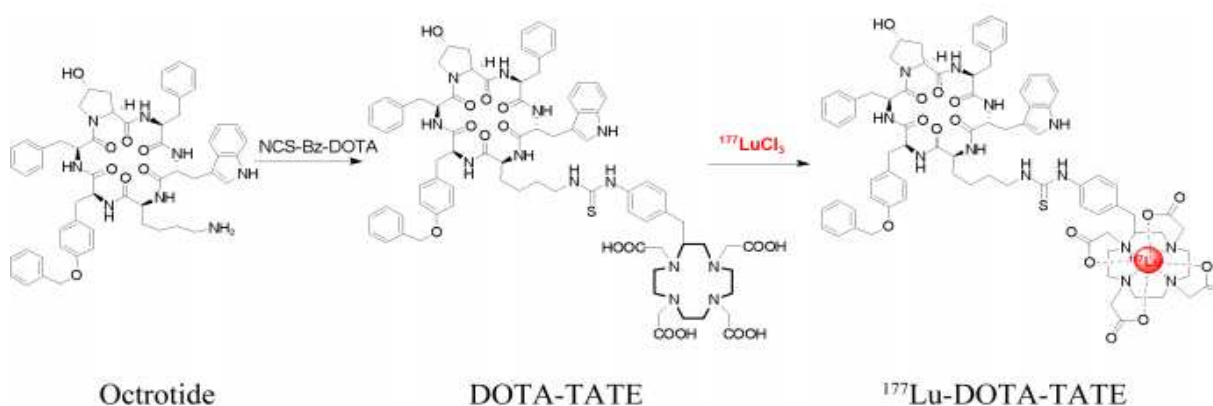


Figure.1 Synthesis and radiolabeling of ^{177}Lu -DOTA-TATE

Results: DOTA-TATE was radiolabeled with ^{177}Lu in >99% radiochemical yield as determined by radio-TLC and radio-HPLC. In vitro stability experiments showed ^{177}Lu -DOTA-TATE was stable in 5% human serum albumins, NaAc (pH 5.5) and PBS (pH 7.4) after 120 hours of incubation. In vivo, the HT29 cell xenograft tumours uptake of ^{177}Lu -DOTA-TATE increased, and could be clearly visualized by 6 h postinjection. The accumulation of ^{177}Lu -DOTA-TATE in HT29 tumours could be significantly reduced after co-injection with an excess amount of DOTA-TATE. Biodistribution studies in KM mice demonstrated that ^{177}Lu -DOTA-TATE was mainly excreted by kidneys.

Conclusion: In this study, we describe the radio-synthesis and characterization of ^{177}Lu labeled cyclic peptide ^{177}Lu -DOTA-TATE. We found that ^{177}Lu -DOTA-TATE could be taken up by HT29 cell xenograft tumours. It is found to have high labeling efficiencies and high tumour cell uptake. In brief, the ^{177}Lu labeled somatostatin analogue ^{177}Lu -DOTA-TATE may be useful both for SSTR positive neuroendocrine cancer diagnostic and therapeutic applications.

Acknowledgements: Supported by grant #81172083, grant #81371592 and grant #81401467 from the National Natural Science Foundation of China and by #7132040 from the Beijing Municipal Natural Science Foundation of China.

IAEA-CN-232/81

Radio-labeling Micro-PET Study of Ga-68 Labeled Somatostatin Analogue Pasireotide-DOTA for Tumour Imaging

F. Liu¹, H. Zhu¹, C. Xiong², C. Li², Z. Yang¹

¹ Peking University Cancer Hospital

² The University of Texas MD Anderson Cancer Center

Corresponding Author: liufei0808@126.com

Background: The purpose of this work was to develop a new somatostatin analogue for tumour noninvasive positron emission tomography (PET) imaging. Although Octreotide has been widely used for somatostatin receptor positive tumours, it only has a high affinity of SSTR 2 among the five somatostatin receptors. Recently, Pasireotide was reported to have a better binding affinity for SSTR 1, 3, 5 and similar affinity for SSTR 2 compared with Octreotide. Herein, we developed novel Ga-68 labeled Pasireotide conjugated with p-SCN-Bn-DOTA for PET imaging of somatostatin receptor positive tumours.

Methodology: The cyclic peptide amide DOTA-Pasireotide coupled with bi-functional chelating agent (p-SCN-Bn-DOTA) was synthesized and radiolabeled with ⁶⁸Ga to yield ⁶⁸Ga-DOTA-Pasireotide PET probe. The samples Pasireotide and DOTA-Pasireotide were analysed by liquid chromatography-mass spectrometry (LC-MS) before radiolabeling and the ⁶⁸Ga labeled compounds were determined by radio-HPLC (Figure.1). The precursor DOTA-Pasireotide was labeled with Ga-68 in sodium acetate buffer (pH 4.0) by heating at 100 °C for 20 min. After purification by a Sep-pak C18 column, 12.95 MBq of ⁶⁸Ga-DOTA-Pasireotide was injected intravenously to BALB/c nude mice bearing human HT29 colon tumours via tail vein. The PET images were taken 2 and 4 hours after radiotracer injection.

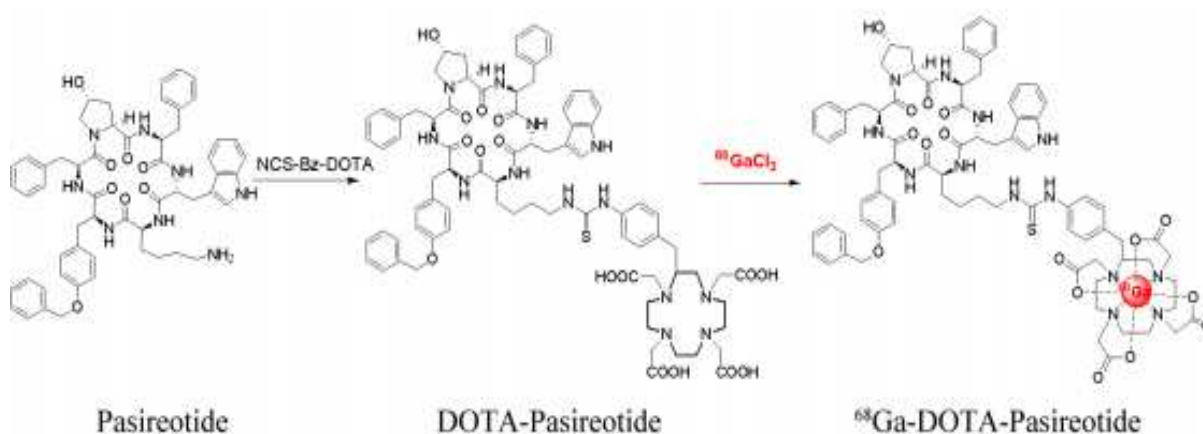


Fig.1 Synthesis and radiolabeling of ⁶⁸Ga-DOTA-Pasireotide

Results: ^{68}Ga was radiolabeled with DOTA-Pasireotide in 98% radiochemical purity as determined by radio-HPLC. In vitro stability experiments showed that after 2 hours ^{68}Ga -DOTA-Pasireotide was stable in 5% human serum, NaAc (pH 5.5) and PBS (pH 7.4). In vivo, the HT29 cell xenograft tumours uptake of ^{68}Ga -DOTA-Pasireotide increased with time, and was clearly visualized 4 h postinjection.

Conclusion: In this study, we described the synthesis and characterization of ^{68}Ga labeled cyclic peptide ^{68}Ga -DOTA-Pasireotide. We found that ^{68}Ga -DOTA-Pasireotide could be taken up by HT29 cell xenograft tumours. In brief, the somatostatin analogue ^{68}Ga -DOTA-Pasireotide may be useful for imaging somatostatin receptor positive tumours such as neuroendocrine tumours.

Acknowledgements: Supported by grant #81172083, grant #81371592 and grant #81401467 from the National Natural Science Foundation of China and by #7132040 from the Beijing Municipal Natural Science Foundation of China.

IAEA-CN-232/82

**Preparation and Preliminary Biological Evaluation of Lu-177
Labeled Somatostatin Analogue DOTA-Pasireotide
for Tumour Imaging**

F. Liu¹, H. Zhu¹, C. Xiong², C. Li², Z. Yang¹

¹ Peking University Cancer Hospital

² The University of Texas MD Anderson Cancer Center

Corresponding Author: liufei0808@126.com

Background: The purpose of this work was to develop a new somatostatin analogue for tumour peptide receptor radionuclide therapy (PRRNT). Octreotide and its derivatives have been widely used for somatostatin receptor positive tumours therapy; however, they only have high affinity for SSTR 2 among the five somatostatin receptors. Recently, Pasireotide was reported to have a better binding affinity for SSTR 1, 3, 5 and similar affinity for SSTR 2 compared with Octreotide. As the contemporary β - and γ -emission of ¹⁷⁷Lu makes it a suitable radionuclide both for therapeutic and diagnostic purposes, herein we report the new somatostatin analogue Pasireotide labeled by ¹⁷⁷Lu to present a preliminary evaluation of its behaviour in vivo and to explore the possibility of its usage as a diagnostic and therapeutic radiopharmaceutical for neuroendocrine tumours and PRRNT.

Methodology: Cyclic peptide amide DOTA-Pasireotide was synthesized and radiolabeled with ¹⁷⁷Lu to yield ¹⁷⁷Lu-DOTA-Pasireotide (Figure 1). The precursor DOTA-Pasireotide was labeled with ¹⁷⁷Lu in sodium acetate buffer (pH 4.0) by heating at 100 °C for 15 min and the products were determined by radio-instant thin-layer chromatography (TLC) and radio-HPLC. In vitro stability experiment was undertaken in 5% human serum albumin, NaAc (pH 5.5) and PBS (pH 7.4) at room temperature (25 °C) for about 120 hours of incubation. After purification by Sep-pak C18 column, 12.95 MBq of ¹⁷⁷Lu-DOTA-Pasireotide was injected intravenously to BALB/c nude mice bearing human HT29 colon tumours via tail vein. The SPECT/CT images were taken 2 h, 4 h, 8 h after radiotracer injection.

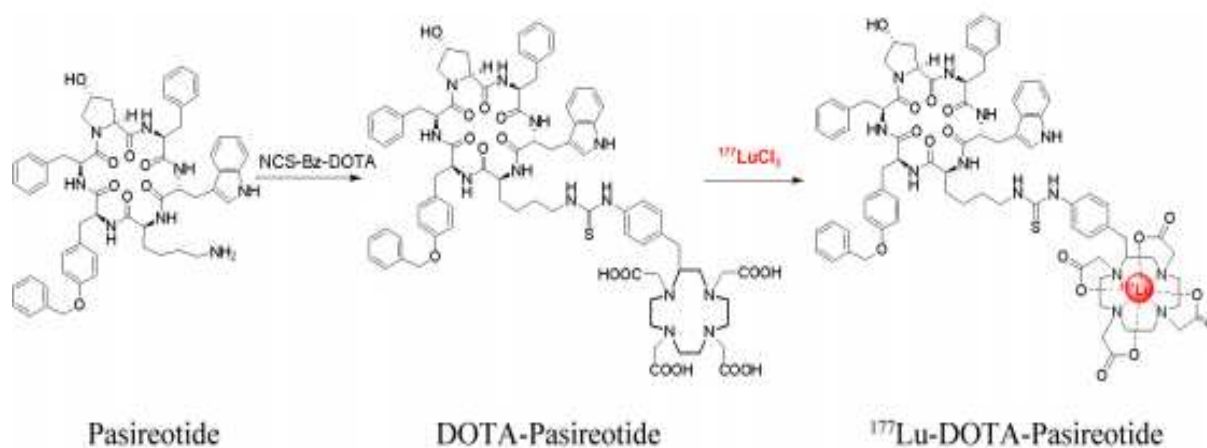


Figure.1 Synthesis and radiolabeling of ¹⁷⁷Lu-DOTA-Pasireotide

Results: DOTA-Pasireotide was radiolabeled with ¹⁷⁷Lu in 98% radiochemical yield as determined by radio-TLC and radio-HPLC. In vitro stability experiments showed that after 120 hours ¹⁷⁷Lu-DOTA-Pasireotide was stable in 5% human serum albumin, NaAc (pH 5.5) and PBS (pH 7.4). In vivo, the HT29 cell xenograft tumours uptake of ¹⁷⁷Lu-DOTA-Pasireotide increased with time, and was clearly visualized at 8 h postinjection. Biodistribution studies in KM mice demonstrated that ¹⁷⁷Lu-DOTA-Pasireotide was mainly excreted by kidneys.

Conclusion: In this study, we describe the radio-synthesis and characterization of ¹⁷⁷Lu labeled cyclic peptide ¹⁷⁷Lu-DOTA-Pasireotide. We found that ¹⁷⁷Lu-DOTA-Pasireotide could be taken up by HT29 cell xenograft tumours. It is found to have high labeling efficiencies, short labeling time and high tumour cell uptake. In brief, the ¹⁷⁷Lu labeled somatostatin analogue ¹⁷⁷Lu-DOTA-Pasireotide may be useful both for cancer diagnostic and therapeutic applications.

Acknowledgements: Supported by grant #81172083, grant #81371592 and grant #81401467 from the National Natural Science Foundation of China and by #7132040 from the Beijing Municipal Natural Science Foundation of China.

IAEA-CN-232/83

FDG-PET/CT in the Diagnostics of Unknown Primary Tumours

V. Hadzhiyska¹, Z. Mihaylova², M. Garcheva-Tsacheva¹

¹University Hospital "Alexandrovska" Sofia

²Military Hospital-Sofia

Corresponding Author: marina.garcheva@gmail.com

Background: The mortality of patients with unknown primary tumour (CUP) is high in the first year period after presentation. CUPs are by definition metastatic cancers, and the prognosis for patients with CUP is poor. However, appropriate diagnostic work-up can help to identify a minority of CUP patients who can expect to benefit from directed therapy.

Whole-body-2 deoxy-2-[18F] fluoro-D-glucose –positron emission tomography (FDG-PET/CT) is recognized as a convenient method for diagnostics in this challenging topic. The aim of the study is to evaluate its place in the diagnostic algorithm and for shortening the decision for further management of patients.

Methodology: Forty three patients (aged from 33 to 79 years) were evaluated and followed up during a two years period by FDG-PET/CT on GE Discovery 16T, using the weight adjusted activity, 60 minutes delay between injection and registration, hydration of patients with diuretic stimulation and oral contrast intake. The inclusion criteria were patients with proved malignant histology by lymph node biopsy (gr. LN, n= 23), patients with histological proof of malignancy from brain surgery (gr. BS, n=7), patients with imaging proofs of malignancy by other imaging methods (gr. Im, n= 13).

Results: 58% (25/43 patients) had positive PET results. Five patients from gr. LN with advanced disease proved by PET were directed for chemotherapy, 2 patients with proved lung and ovarian carcinoma needed operation, and 2 with head and neck (H&N) tumours were sent for radiotherapy. From gr. BS all 5 positive cases were lung carcinoma. Three of them were sent for fibrobronchoscopy (FBS) and radiotherapy planning, 2 with advanced disease for chemotherapy. From gr. Im: 3 (cholangio- and pancreatic carcinoma) without dissemination were sent for surgery, and 2 to SRS (somatostatin receptor scintigraphy), because of suspicion of NET (neuroendocrine tumours). Five patients with data of advanced disease were sent for chemotherapy. The whole body PET/CT directed to treatment 9 patients from gr.LN, 2 from gr.BS, 8 from gr.Im. Three patients were sent for FBS, 2 patients needed additional imaging examinations, besides the group with PET negative studies (2+18 patients, 46%).

Conclusion: PET/CT was positive in the majority of patients (58%) sent for the detection of unknown primary. It reduced the need of additional imaging examinations in 54% of patients and directed to therapy 19 (44%) of patients (unfortunately the majority of them with advanced disease). In 4.5% (H&N tumours with regional spread) PET/CT examination seems able to improve the patients' prognosis and survival. FDG-PET/CT may contribute to the management of patients with CUP tumours and especially those with cervical adenopathies and single metastases (IV,B).

IAEA-CN-232/84

124I PET/CT Dosimetry for Nuclear Medicine Therapy

G. Rossi¹, S. Fattori¹, E. Brianzoni², E. Biggi²

¹ Medical Physic ASUR Marche AV3 Macerata Hospital, Italy

² Nuclear Medicine ASUR Marche AV3 Macerata Hospital, Italy

Corresponding Author: gloria.rossi@sanita.marche.it

Background: In patients with differentiated thyroid cancer (DTC) the amount of 131I activity to administer in the ablation of the remnants is still debated between fixed or personalized activity. In case of lesions, planning the right administrable activity is fundamental in order for it to be effective, and is possible only with a PET imaging.

The aim of our study is to determinate the dose estimation by using 124I-PET/CT as diagnostic and quantification tool before therapy.

Methodology: We studied the remnants in 69 patients (51 females and 18 males, aged 21-79 years, mean age 40 years) with DTC submitted to a total (or near-total) thyroidectomy, off L-thyroxine therapy and 9 lesions in a DTC plurimetastatic patient (PMP).

For the remnants, on the first day we collected blood samples for TSH, hTG, AbhTG; afterwards a tracer dose of 124I (30-37 MBq) was administered orally.

On the second day, we performed a PET/CT, an ultrasound scan and an uptake of the neck by an external probe.

We evaluated the successful radioablation 7-8 months later through a 131I whole body scan and hTG value.

In PMP we studied 9 lesions in a patient at the third treatment off L-thyroxine for DTC with negative FDG-PET. We administered 75 MBq of 124I, collected 5 blood samples and 5 external counts by a NaI probe and 5 PET/CT scans.

Following dosimetric study we administered 9217 MBq of 131I and after 9 months we considered and studied the number, position, uptake and extension of metastases.

Results: For the remnants we found that the values pre-therapy were: TSH mean 129 UI/ml (range 34-176; SD 42) and hTG mean 5.5 ng/ml (range<0.5-69.8; SD 15.3), AbhTG was detectable in 15 patients. The uptake values were: mean 3.7% (range 0.2-28%). The delivered doses were: mean 2146.5 MBq (range 1016-5506; SD 1239; Moda 1105; Median 1846). Moreover, by double blind comparing the 124I PET/CT and the post-therapeutic 131I scan images, we found a complete agreement in 91.3% of the cases (63/69) for the number, the site and the extension of the remnants and other pathological foci. Complete ablation was obtained in 90% of the cases (62/69).

To PMP we delivered:

Medium low cervical area	39 Gy
IV spinal column vertebra	44 Gy
VIII spinal column vertebra	66 Gy
Rib of the left thorax	42 Gy
Left pelvis bone	17 Gy
Right pelvis bone	83 Gy
Pubic symphysis	76 Gy
Sternum	60 Gy
Lumbar vertebra	95 Gy

Lesions present in the follow up: dorsal, lumbar and cervical vertebrae, pubic symphysis, rib of the left thorax and left pelvis bones. All of them were reduced in volume (30%) and some of them had a reduced uptake value (pubic symphysis and lumbar vertebra). Lesion of sternum and right pelvis bone are undetectable.

Conclusions: ^{124}I PET/CT allows for an excellent pre-therapy evaluation of an individualized dose, through a fast and simple method, without stunning on the therapeutic effectiveness. It shows a good percentage of success of radioablation and is a good compromise for the lesion's kinetic evaluation. It could be very useful in the planning of ^{131}I radiometabolic therapy.

IAEA-CN-232/85

Comparative Evaluation of Pramipexole Encapsulated Theranostic Liposomes and Niosomes for Parkinson's Disease

M. Silindir¹, A.Y. Ozer², S. Erdogan², D. Guilloteau³, S. Chalon⁴

¹ Department of Radiopharmacy, Faculty of Pharmacy, Hacettepe University, 06100, Sıhhiye, Ankara, Turkey and UMR INSERM U930, Faculty of Medicine, Université François Rabelais de Tours, Tours, France

² Department of Radiopharmacy, Faculty of Pharmacy, Hacettepe University, 06100, Sıhhiye, Ankara, Turkey

³ UMR INSERM U930, CNRS ERL 3106, Université François Rabelais de Tours, Tours, France

⁴ UMR INSERM U930, Faculty of Medicine, Université François Rabelais de Tours, Tours, France

Corresponding Author: msilindir@yahoo.com

Background: Parkinson's disease (PD) is defined as a degenerative disorder of CNS. It is a chronic and progressive movement disorder. Its motor symptoms result from the death of dopamine generating cells in the substantia nigra of midbrain. PD is assumed as one of the most recently observed neurodegenerative disease among geriatric diseases diagnosed generally over age 50 all around the world. However, it can also be seen in 5% of young people. PD is hard to diagnose. By using the imaging modalities such as positron emission tomography (PET) and single photon emission computed tomography (SPECT), the decline in the accumulation of the radiotracer in substantia nigra can be detected.

For PD treatment, drug therapy is one of the mostly used methods. Limited amount of drug penetrating into the brain is one of the most crucial points. It is needed to increase the drug concentration by not causing any rise in side effects. Passively or actively targeted nanosized drug delivery systems such as liposomes and niosomes have many advantages in brain delivery for the purpose of either therapy or diagnosis. Recent studies performed around this issue generally depend on development of new drug delivery systems in which diagnosis can be managed together with therapy, which is called theranostics, and therapy effectiveness can also be evaluated.

Methodology: In this research, liposomes and niosomes were formulated for the diagnosis and therapy of PD through passive brain targeting; they were coated in polyethylene glycol (PEG), nanosized, neutral or positively charged, ^{99m}Tc labeled for SPECT imaging, encapsulated with pramipexole dihydrochloride monohydrate (pramipexole). Following preparation of liposomal and niosomal dispersions, their characterization and release kinetics were evaluated and compared.

Results: In both formulations nanosized particles and proper zeta potentials and about 10% pramipexole encapsulation efficiency was observed.

Conclusion: Promising characterization and release profiles for both diagnosis and therapy of PD were obtained with these theranostic systems. To obtain better results it is needed to perform further in vivo animal studies and our studies are continuing.

(The authors would like to thank for generous gifts of Abdi Ibrahim İlaç for Pramipexole, to Lipoid for PEG-PE. This study was supported by the grant of TUBITAK (Project No: 112S244)).

IAEA-CN-232/86

FDG-PET/CT for Treatment Response Assessment in Head and Neck Squamous Cell Carcinoma: A Systematic Review and Meta-Analysis

N. Helsen, L. Carp, S. Stroobants, T. Van den Wyngaert

University of Antwerp

Corresponding Author: nils.helsen@uza.be

Background: Head and neck cancer accounts for approximately 2% of all cancers worldwide with about 60% of the patients diagnosed with locally advanced disease. A routine neck dissection was the preferred treatment in these patients, but is associated with considerable morbidity. Therefore, routine neck dissections in patients with N2-N3 disease are being questioned but early identification from the residual nodal involvement remains crucial. 18-fluorodeoxyglucose positron emission tomography combined with computed tomography (FDG-PET/CT) is increasingly used to evaluate treatment response in head and neck squamous cell carcinoma (HNSCC). The purpose of this analysis was to assess the diagnostic value of FDG-PET/CT to detect residual disease after treatment.

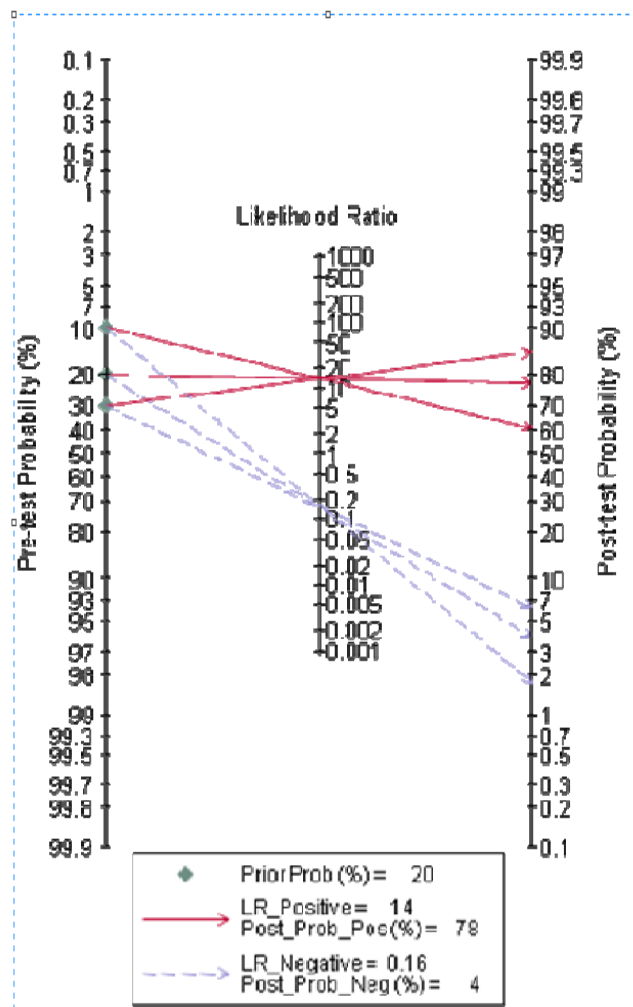
Methodology: A systematic review was performed using the MEDLINE and Web of Knowledge databases. Study quality was assessed using the QUADAS instrument. The results were pooled using a bivariate random effects model of sensitivity and specificity. Results are reported according to PRISMA guidelines.

All selected studies evaluated treatment response after radiation therapy with or without concomitant chemotherapy or biological in node positive HNSCC patients within 6 months after completing therapy. A minimum study size of 15 HNSCC patients was required, and only English or French language papers were included.

Results: We identified 16 studies with a total of 893 patients. The pooled estimates of sensitivity, specificity, positive and negative likelihood ratio, and diagnostic odds ratio (with 95% CI) were 85% (76-91%), 94% (89-97%), 13.9 (7.8-24.7), 0.16 (0.09-0.26) and 88 (43-180), respectively. With the prevalence of residual nodal disease set at 20%, the positive and negative predictive value (PPV/NPV) was estimated at 78% and 96%, respectively (see figure 1). QUADAS revealed a high risk of inapplicability on patient selection and there was significant heterogeneity between the different trials ($p < 0.001$).

Figure 1:

The post-test probability of residual/recurrent disease after a positive/negative FDG-PET/CT result with the prevalence of residual disease set at 10, 20 and 30%. The red line shows that a patient will have a 78% chance of having residual/recurrent disease in the neck if the FDG-PET/CT scan is positive and 4% if the scan is negative if the pre-test probability is 20%.



Conclusions: Our results show that FDG-PET/CT performed within the first six months after treatment is a reliable tool for the detection of residual/recurrent lymph node disease in node positive patients with HNSCC. A negative PET/CT scan is highly indicative for the absence of disease and may obviate the

need for neck dissections in patients with positive lymph nodes at diagnosis. The positive predictive value should be evaluated in consideration of the pre-test probability of the disease and confirmation of a positive signal should be done in case of a low probability. Nevertheless, further standardization of PET acquisition protocols and reporting is required.

IAEA-CN-232/87

Our Experience Using F-18 Florbetapir Brain Imaging as Diagnostic Aid in Alzheimer's Disease in a University Hospital in United Kingdom

P.S. Chuah, R. Brown, S. Vinjamuri

Nuclear Medicine Department, Royal Liverpool University Hospital

Corresponding Author: pshan.chuah@gmail.com

Background: The diagnosis of Alzheimer's disease (AD) has always been challenging especially in patients presenting with multiple co-morbidities. The ability of β -Amyloid PET imaging to detect β -amyloid neuritic plaques which are associated with AD, has the potential to aid in early and accurate diagnosis of AD. Nevertheless, its utility in clinical practice requires careful consideration. To ensure appropriate use of β -Amyloid PET scan, the Amyloid Imaging Task Force (AIT) of the Alzheimer's Association and Society for Nuclear Medicine and Molecular Imaging has recommended specific patient selection criteria. The main objective of our study is to demonstrate our experience with the use of F-18 Florbetapir PET-CT imaging. The secondary objective is to evaluate the appropriate use of amyloid PET imaging based on the criteria recommended by AIT.

Methodology: A retrospective review of 11 patients (median age 67, 6 female and 5 male) who underwent F-18 Florbetapir PET-CT imaging in a single centre university hospital in the United Kingdom between May 2014 and January 2015 was performed. Images were reviewed by two experienced nuclear medicine physicians.

Results: Patients presenting with persistent or progressive unexplained mild cognitive impairment (n=6), mixed aetiology presentation (n=4) and early onset progressive dementia (n=1) were the main indications. The presence of β -amyloid plaques on F-18 Florbetapir PET-CT was identified in three patients and they presented with mild cognitive impairment. Of these patients with positive scans, two had family history of AD. Additionally, 4 out of 5 patients who had features suggestive of AD on previous HMPAO-SPECT, had absent β -amyloid plaques on the amyloid PET-CT scans.

Conclusion: In our centre, all the patients were correctly referred. Amyloid PET imaging is useful to aid and improve the diagnostic certainty of β -Amyloid disease. As it is a relatively novel diagnostic test, it is prudent that the clinical indications and previous brain imaging are carefully reviewed. The results of the imaging should also be discussed in clinical outcome meetings.

IAEA-CN-232/88

War on Breast Cancer Goes Nuclear - High Resolution Breast Positron Emission Tomography: An Emerging Diagnostic Weapon

G. Estrada, M. Lara-Tamburrino, L. Azpeitia, M. Jiménez

C.T. Scanner del sur

Corresponding Author: dragiselaus@yahoo.com

Background: Breast cancer remains the most prevalent cancer form among women worldwide. Mammography remains the screening modality of choice for breast cancer. About 10 to 15% of cancers are missed by conventional screening imaging tools.

High resolution breast PET, known before as positron emission mammography (PEM) is a high-resolution molecular imaging technology that has shown great sensitivity and specificity.

This modality uses 18F-FDG, a positron-emitting analogue of glucose, to detect metabolic alterations within cells. Also, more specific tracers are used, such as estradiol analogue (18F-FES).

18F-FES may be helpful in identifying patients who will benefit from endocrine therapy (like tamoxifen) and predict the likelihood of response to specific treatment hormonal regimens.

Several prototypes and commercial systems have been proposed using very different detector geometries and scintillator crystals.

Methodology: The main indication is for patients with diagnosed breast cancer who are best treated by conservative surgery, by defining the surgical margins, and evaluating for multifocal or multicentric disease, even in dense breast, potentially avoiding inadequate treatment, unnecessary or additional surgeries. Occult ductal carcinoma in-situ (DCIS) lesions measuring 2–3 mm in width, not well characterized by any other imaging modality may be revealed.

The method is well suited for patients who cannot tolerate or undergo a MRI scanning.

18F-FDG uptake ratio is not affected by hormonal changes, unlike breast MRI.

Breast compression is needed to obtain adequate images.

It is possible to perform a biopsy in patients at the same time of their high resolution breast PET procedure.

False-positive or -negative results: hypermetabolic and inflammatory processes, fibrocystic changes, fat necrosis, some fibroadenomas, post-biopsy changes, lobular carcinomas.

High resolution breast PET and MRI have an overall similar accuracy.

MRI is limited by specificity. Increased cancer detection was reported when high resolution breast PET and MRI were combined compared to MRI alone.

The average effective dose in a high resolution breast PET study is 5 mCi (3.5 mSv).

The method can be used when monitoring response to neoadjuvant chemotherapy.

High resolution breast PET will be better suited for high-risk screening of positive BRCA patients.

Results: The first step is identification of hot spots. Once identified, the size, location, and 18F-FDG uptake of the lesion is obtained. Because of the lack of attenuation correction, a “lesion-to-background” ratio (LTB) for semiquantitative analysis is required. An LTB of > 2.5 is more likely to be malignant. Breast tumours of higher histological grade have significantly higher values than those with lower grade. Final assessment of the lesion is based on both morphology and semiquantitative 18F-FDG uptake considered together with findings of other recent breast imaging procedures.

Conclusion: High resolution breast PET is a sensitive and specific tool for the evaluation of suspicious breast lesions. It has a great reliability in detecting DCIS and has the potential to play a major role in improving the diagnosis of breast cancer.

High resolution breast PET defines the surgical margins, evaluates multifocal or multicentric disease even in dense breast, potentially avoiding inadequate treatment, unnecessary or additional surgeries. It is useful in differentiating recurrent disease from post-treatment changes and monitoring response to neoadjuvant chemotherapy.

IAEA-CN-232/89

**Well Differentiated Thyroid Cancer: The Efficiency of
Thyroid Remnant Ablation with I-131 after RHTSH
Stimulation and after Thyroxin Withdrawal: A Prospective
Randomized Control Trial**

**S. Mohamed¹, R. Al-Mazroui², H. Bererhei¹, O. Elshafie¹, S.
Sawhney¹, N. Woodhouse¹, A. Al Jabri¹**

¹ SQUH

² OMSB

Corresponding Author: samirhus@gmail.com

Background: Our aim was to compare the efficacy of post-surgical thyroid remnant ablation using I-131 in patients whose thyrotropin (TSH) levels are elevated due to either thyroxine (T4) withdrawal, or the administration of exogenous recombinant human thyroid stimulating hormone (rhTSH) in patients with well differentiated thyroid cancer (WDTC).

Methodology: 74 patients with histologically confirmed WDTC referred to Sultan Qaboos University Hospital for I-131 ablation dose from 2008 to 2012 were studied. After written informed consent was obtained they were enrolled into 2 groups by consecutive selection.

Group (A) 40 patients stopped thyroxine intake for 4 to 6 weeks before administration of a 2.7 GBq I-131 ablation dose. Group (B) 34 patients continued taking thyroxine but they received two injections of rhTSH intramuscularly (0.9 mg) before administration of a 2.7 GBq I-131 ablation dose.

The efficacy of either method was assessed by I-131 whole body scintigraphy (I-131 WBS), uptake in the neck, serum thyroglobulin (Tg) level, serum thyroglobulin antibody (TgAb) titre and thyroid remnant size or lymph nodes seen on ultrasound (US) or MRI of the neck.

Our exclusion criteria included age less than 18 years, pregnancy, breast feeding, patients unable to care for themselves and metastatic disease outside the neck.

The thyroid ablation was considered successful if Tg level was <1 ng/ml, serum TgAb titre and I-131 WBS were negative 6 months after the ablation.

The results were analysed by statistician blind to the treatment protocol used in the two groups.

Results: Of 74 patients there were 64 females with a ratio of female: male of 6:1, and age range of 20 to 84 years and a mean of 36 years (range of 20 to 84).

There was no significant difference between the groups according to sex, age, I-131 ablation dose, histopathology type and stage of the thyroid cancer (P value > 0.05).

There were 13 patients (17%) with thyroglobulin antibodies (9 in Group A and 4 in Group B).

The Tg level < 1 ng/ml after excluding patients with positive TgAb was similar in both groups - in Group A 30 patients (97%) and in Group B 26 patients (87%) (P value 0.15).

Negative I-131 WBS was similar in both groups - in Group A 32 patients (80%) and in Group B 25 patients (74%) (P value 0.51).

There was no significant difference in ablation success rate between the two groups - in Group A 31 patients (78%) (95% CI 62.5- 87.5), in Group B 25 patients (74%) (95% CI 56.9-85.4) (P 0.692) with a relative risk of 0.95 (95% CI 0.73- 1.23).

Conclusion: This study showed that there is no significant difference in I-131 thyroid remnant ablation

between patients using rhTSH stimulation or thyroxine withdrawal to raise circulating TSH levels. As rhTSH can successfully ablate thyroid remnant in WDTC, this will obviate the need for thyroxine withdrawal and potential side effects of prolonged hypothyroidism.

IAEA-CN-232/90

**18F-FDG PET/CT in Fever of Unknown Origin in
Putrajaya Hospital, Malaysian Experience**

Z.H. Awang, M.F. Khalil

Ministry of Health Malaysia

Corresponding Author: zoolhilmi_75@hotmail.com

Background: In Malaysia, Putrajaya hospital is a government hospital, which has a F-18 FDG PET/CT scanner since 2009 and it is widely used for oncologic compared to non-oncologic applications. It has become a common practice for most of the Asian countries. Infection plays an important role in patients' morbidity and mortality in Malaysia. This is a retrospective study to evaluate the role of PET/CT using F-18 FDG in the investigation of fever of unknown origin (FUO) at Putrajaya hospital from the period of 2009 to 2013.

Methodology: A total of 7 patients consisting of various ethnicities – 5 of Malay ethnicity, 1 Chinese and 1 Indian (2 men, 5 women, age range 18 – 80) with FUO underwent F-18 FDG PET/CT scan from 2009 to 2013 at Putrajaya hospital, Malaysia. FUO was defined as a fever of more than 38.3 on several occasions and uncertain diagnosis after 1 week. F-18 FDG PET/CT has been used to identify the aetiology of FUO and we have used the findings from the scan for our final diagnosis in this study.

Results: F-18 FDG PET/CT showed normal physiological uptake in 2 patients. In 5 of the positive F-18 FDG PET/CT studies, FUO was identified and diagnosed in 2 patients, 2 patients had an indeterminate diagnosis and 1 patient was diagnosed with a malignancy.

Conclusion: Within the period 2009 – 2013 over 3000 patients underwent F-18 FDG PET/CT scan in Putrajaya Hospital, out of which only 7 patients underwent the examination for indications of FUO. Although the available data and the availability of PET/CT scan are still limited, this should not be the reason to exclude the use of this modality in the developing countries like Malaysia. We should also encourage clinicians to refer patients to F-18 FDG PET/CT and provide them with more information regarding the availability of this service.

IAEA-CN-232/91

**Follicular Thyroid Cancer with Skull Metastasis:
A Case Report**

A. Elliyanti

Indonesia

Corresponding Author: aelliyanti@yahoo.com

Background: Follicular thyroid cancer is differentiated thyroid cancer (DTC). It is a slow growing tumour and has a good prognosis. However if a distant metastasis is present the prognosis usually becomes poor. Iodine-131 has been used for 70 years to treat thyroid cancer. Patients with follicular and papillary cancer who undergo total or near total thyroidectomy are subsequently treated with I-131. However, bone metastases sometime fail to uptake radioiodine.

Methodology: A 51 year-old woman was referred to our department complaining of lump size increase at her head. She was diagnosed with adenomatous goiter and eight years later, she complained of lump growing at her head. Biopsy results showed follicular thyroid cancer. She underwent a total thyroid surgery and was followed by I-131 treatment (100 mCi). She never came back to the hospital for follow up. We examined TSH, thyroglobulin, anti-thyroglobulin level and performed thyroid, bone and whole body scintigraphy.

Results: After four weeks of thyroxin withdrawal, TSH, thyroglobulin, and anti-thyroglobulin results were 2.77 mU/L, 1.78 ng/mL, and negative, respectively. Thyroid scintigraphy using ^{99m}Tc showed no uptake in thyroid bed. ^{99m}Tc-methylene diphosphonate (MDP) bone scintigraphy demonstrated high uptake in the right parietal bone. On the contrary, I-131 whole body scan did not show radioiodine uptake in thyroid bed or skull bone.

Conclusion: It is difficult to make a distinction between benign and malignant follicular thyroid cancer. Identification of genes expressed in follicular adenomas and carcinomas of the thyroid will permit molecular differentiation in suspicious cases. Prognosis of DTC is poorer once distant metastases have occurred. Furthermore, non-responsiveness to radioiodine can be caused by cell dedifferentiation. This is due to the fact that cell dedifferentiation results in loss of ability to accumulate I-131. Metastases behave like thyroid tissue, and withdrawal of thyroxin did not increase TSH or thyroglobulin levels.

IAEA-CN-232/92

Role of 68-Ga Labelled PSMA PET CT Scan in the Evaluation of Prostate Cancer and its Correlation with Histopathology Findings - Preliminary Analysis

P. Pankaj, A. Kumar

Department of Nuclear Medicine and PET CT, Mahajan Imaging Centre, and Ganga Ram Institute for Postgraduate Medical Education and Research (GRIPMER), Sir Ganga Ram Hospital, New Delhi- 110060, India.

Corresponding Author: promilapankaj@gmail.com

Background: Prostate carcinoma remains a major public health problem in developed countries. Adenocarcinoma of the prostate is the second most common cause of cancer death among men. The occurrence of metastases is one of the major causes of morbidity and mortality in prostate cancer patients. The development of locally advanced and metastatic disease is usually insidious and, for most patients presenting with symptoms, the tumour is all too frequently incurable and treatment remains essentially palliative. The early detection of these metastatic or recurrent lesions is of high clinical relevance for staging, prognosis, and therapy management. The prostate-specific membrane antigen (PSMA) represents a cell surface target suitable for imaging metastatic lesions as it is expressed by nearly all prostate cancer cells with enhanced expression levels in poorly differentiated, metastatic, and hormone-refractory carcinomas.

The aim of the study was to evaluate the role of 68-Ga labeled PSMA PET/CT scan in the evaluation of prostate cancer and its correlation with histopathology findings in suspected or diagnosed cases of prostate cancer.

Methodology: We studied 200 patients, who were suspected to have prostate cancer based on clinical and biochemical evaluation and patients of prostate cancer proven by histopathology. All the patients were injected with 132-222 MBq (4-6 mCi) of 68Ga-PSMA and PET/CT was acquired from the vertex to the mid-thigh using a dedicated GE Discovery STE PET/CT scanner within 45 ± 15 minutes after injection. A delayed sequence of pelvis was acquired after lasix injection in all patients.

Results: 68Ga-PSMA PET/CT scan is a very sensitive technique for detection of primary prostate cancer, small lymph node, bone and liver metastases and cancer relapses, with improved contrast even at low PSA levels due to significantly high radiotracer uptake in the lesion and very low background uptake.

Conclusion: Our preliminary results show that 68Ga-PSMA PET/CT scan is a very sensitive and reliable technique in the evaluation of patients with carcinoma prostate.

IAEA-CN-232/93

Role of Medical Imaging in the Diagnosis and Monitoring of Thyroid Cancer in Bamako, Mali

S. Sidibé

Radiology and NM department Point "G" hospital Bamako, Mali

Corresponding Author: sidibes@hotmail.com

Background: Thyroid cancer represents 6.33% of all thyroid diseases and 0.89% of all cancers in Mali. If the diagnosis is made by needle biopsy or surgery, ultrasound helps to select the nodes to be punctured. This retrospective study aimed to evaluate the role of imaging techniques, especially ultrasonography in the diagnosis and follow up of thyroid cancer in our practice.

Methodology: This retrospective study was done through analysing the radiologic data of patients suffering from thyroid cancer to identify those who had at least an initial and follow up neck ultrasonography. 40 out of 58 patients' data were analysed.

Results: After data analysis we found that a nodule with blurred edges without full hypothyreosis, or anechoic perinodular halo, with calcifications in it and a predominant intranodular vascularization is highly suspicious of malignancy in our practice. Additionally, in the preoperative phase, ultrasound plays a key role in helping to find locoregional lymph nodes whose presence changes the surgery (lymphadenectomy). Also, after surgery, ultrasound monitoring is essential for a local recurrence and lymph node recurrences, especially in the case of a suspicious clinical or biological pattern. In the particular case of medullary thyroid cancer (MTC), lymph node and/or distant metastatic spread is much more common. Follow-up requires multiple morphologic imaging procedures for chest (lung, mediastinum), liver, and skeleton.

Conclusion: Ultrasound plays an important role in the diagnosis and monitoring of thyroid cancer in our practice.

IAEA-CN-232/94

Prognostic Significance of 18-F-FDG PET Imaging in Anal Canal Squamous Cell Carcinoma (SCC): a Systematic Review and Meta-Analysis of the Literature

M.A. Qodsi Rad, R. Sadeghi

Corresponding Author: gho.rad81@gmail.com

Background: Prognostic significance of 18F-FDG PET imaging in anal canal SCC has been evaluated in several studies. In the current study we reviewed the pertinent literature in this regard and reported the results in a systematic review and meta-analysis format.

Methodology: A comprehensive literature search of MEDLINE and Scopus was done by the following keywords: “anal AND FDG”. Relevant articles concerning the prognostic performance of FDG-PET in anal canal SCC were included into the study. No language restriction was used.

Results: Six articles had enough prognostic information and were included into the systematic review. PET metabolic response (incomplete vs. complete response based on FDG-PET uptake) was an important prognostic factor for both overall survival (OS): pooled HR=6.58 [2.14-20.24], p=0.001 and progression free survival (PFS): pooled HR=4.56 [1.79-11.58], p=0.001. Inguinal uptake of FDG-PET was another prognostic factor for PFS although statistically non-significant: pooled HR=1.41 [0.81-2.43], p=0.21. SUVmax and metabolic tumour volume (MTV) of the primary tumour were also associated prognosis in two reported studies; however data was incomplete to perform a meta-analysis.

Conclusion: FDG-PET can be of prognostic importance in anal canal SCC. PET metabolic response, inguinal uptake, SUVmax, and MTV of the primary tumour were all associated with prognosis. Larger multicentre studies are needed to validate the results of the current systematic review.

IAEA-CN-232/95

Radiation Safety Analysis during the Design of PET/CT Facilities

C.F. Calderón¹, J.J. González González¹, C. Duménigo Ámbar², W. Quesada Cepero¹, B. Sinconegui Gómez¹, Y. Solá Rodríguez¹, M. Guerrero Cancio³

¹Institute of Oncology and Radiobiology (INOR)

²National Centre for Nuclear Safety (CNSN)

³Center for Medical and Surgical Research (CIMEQ)

Corresponding Author: cfcald@infomed.sld.cu

Background: Radiation safety is essential during the clinical application of ionizing radiations. Cuban legislation considers as obligatory the risks analysis as part of safety evaluation in those centres where nuclear medicine practices are performed. The risk matrix (R-M) method has been used for risk analysis in radiotherapy and some experiences in nuclear medicine has been reported in Cuba. In the actual work the results of a safety analysis using the R-M method for the first PET/CT centre built at the Institute of Oncology and Radiobiology, in Havana, are presented.

Methodology: The facilities will work as a satellite centre and production of 68Ga-radiopharmaceuticals is also conceived. The images will be acquired using a Philips Gemini TF64 scanner. Several steps and sub-steps in general considering the facilities design, instrumentation QC programmes, imaging study indication reviewing, reception and activity fractionation procedures, 68Ga-radiopharmaceuticals production, patient management during the administration of radiopharmaceuticals and positioning, etc., were taken into account. The initiator events (IEs), available barriers and reducing frequency (RFMs) and consequence (RCMs) measures for each step were identified. The incidence in the reduction of risks was evaluated as the times it is used to total number of IEs ratio. IEs sequences for CT explorations were also considered. The calculations of R-M were made by modelling the practice with the SEVRA "Risk Assessment System" code.

Results: As result, 76 IEs were identified, distributed as 72.4% targeting patients, 7.9% public and 19.7% occupationally exposed workers (OEWs). 89.5% of overall IEs have human mistake origin. Barriers, reducing consequences and frequency measures available produce a risk distribution of 2.6% high-risk IEs, 64.5% medium-risk and 32.9% low-risk. The high risk IEs are related to errors in shielding requirements calculations that produce high public exposure and high concentration of 68Ge in the Ge-Ga generator elution. In order to reduce the frequency of high risk IEs the facilities were designed by following the recommendations given by well-known international methodologies, like AAPM TG108, NCRP No107 and IAEA Human Health Series 11 reports. A QC program for 68Ga-radiopharmaceuticals production according to the recommendations given by the European Pharmacopeia was also implemented. The RFMs and RCMs with highest incidence in risk reduction (>10% of IEs) were those related to personnel training, good clinical procedures and protocols, and periodical internal/external audits. The OEWs staff in charge of the instrumentation acceptance, starting up jobs and maintenance was previously trained in hospitals with high experience in clinical routine.

Conclusion: The IEs were identified and the risks in patients, public and OEWs were evaluated. Because most IEs have a human mistake origin, training of personnel before their inclusion in the staff and the implementation of a QC programme for releasing of 68Ga-radiopharmaceutical production are strongly recommended. The implementation of a QA system led to increased safety in this centre.

IAEA-CN-232/96

The Novel Quantitative Software Tool for PET/CT in Staging and Predicting Prognosis of 18F-FDG Avid Lymphoma

W. Zhai, W. He

Huadong Hospital

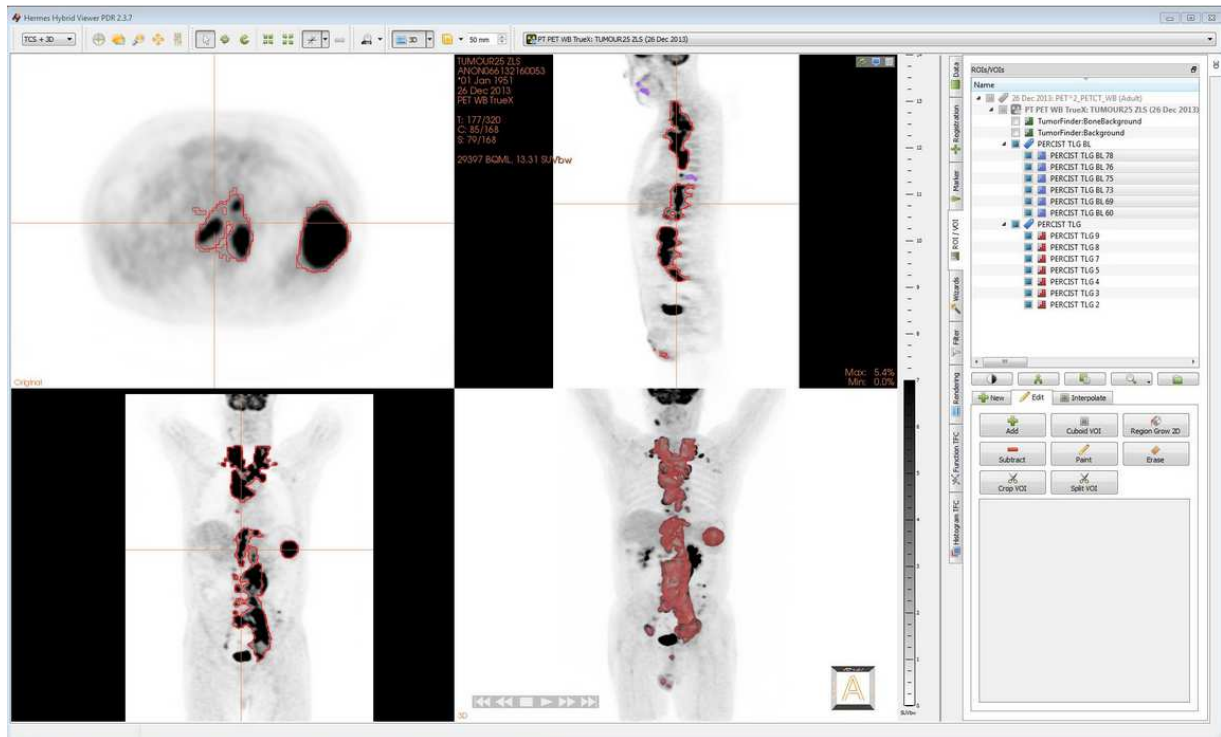
Corresponding Author: weihaozhai@hotmail.com

Background: The objective of this study was to evaluate the efficiency and accuracy of this novel PET/CT quantitative method for staging and follow up of 18F-FDG avid lymphoma, and its impact on increasing the dependence on PET for evaluation of bone marrow involvement and compare it with manual analysis reporting.

Methodology: 44 patients with newly diagnosed B-cell lymphoma were enrolled into this study. Mean liver SUV was measured by placing a 14 ml cubic volume of interest into the liver, a smoothing filter to segmented bones from CT to create a bone mask was applied. For each patient, all lesions were segmented by using a HERMES tumour finder application with automatic 3D region-growing algorithm with a defined minimum SUV threshold [$\text{LiverSUV}_{\text{mean}} + \text{SD} * 2.00$]. This computation, after removal of physiological activity above the measured threshold, defined the metabolic tumour volume (MTV), and the total lesion glycolysis (TLG) was then calculated as [$\text{TLG} = \text{SUV}_{\text{mean}} * \text{MTV}$]. Processing time was recorded for each study. Automatic staging and follow up results were compared with manual analysis method.

Results: 31 bone lesions were detected by quantitative application while 13 lesions by visual analysis ($P < 0.05$). The quantitative application resulted in a change of disease staging in 7 patients (15.9%), upstaging in 5 (11.4%) and downstaging in 2 (4.5%). Lower values of total MTV and cumulative TLG were highly predictive of favourable outcomes in progression-free survival (PFS) in ROC analysis. In addition, the average processing time of quantitative and manual analysis was 2 ± 0.2 , and 21.2 ± 3.2 minutes respectively.

International Conference on Clinical PET-CT and Molecular Imaging (IPET 2015): PET-CT in the Era of Multimodality Imaging and Image-Guided Therapy



Conclusion: This quantitative method is user friendly, independent, much faster repeatable and reliable. It should be used in structured quantitative clinical reporting for routine clinical practice for staging and follow up of 18F-FDG avid lymphomas.

IAEA-CN-232/97

Local Experience with the Use of 90Y-SPECT/CT and 90Y-PET/CT in the Assessment of 90-Yttrium microsphere Biodistribution Following Selective Internal Radiation Therapy for Liver Tumours

P.S. Chuah, R. Brown, I. Hufton, G. Jones, S. Vinjamuri

Nuclear Medicine Department, Royal Liverpool University Hospital, Liverpool, United Kingdom

Corresponding Author: pshan.chuah@gmail.com

Background: Selective internal radiation therapy using 90-Yttrium radiolabelled microspheres in the treatment of liver cancer has recently been introduced into clinical practice in the United Kingdom. SPECT-CT has conventionally been used to assess intra-hepatic distribution. It has emerged that Y-90 also emits positron, providing the basis of PET-CT as an alternative form of imaging. The aim of the study is to demonstrate our experience with the use of 90Y-SPECT/CT and 90Y-PET/CT in the assessment of post-therapeutic biodistribution of microspheres.

Methodology: A retrospective review was performed in ten patients with liver malignancy who underwent 90Y microsphere radioembolisation since 2010. 5 patients were treated with SIR-Spheres® and the remaining with Therasphere®. Images from 90Y-SPECT/CT and 90Y-PET/CT were compared by an experienced nuclear medicine physician. The two methods were also compared for ease of analysis, cost-effectiveness and clinical relevance.

Results: 11 sessions of 90Y microsphere radioembolisation were performed in 10 patients; 3 patients had solitary targeted liver lesions and 7 patients with multifocal lesions. There was good concordance in the image findings of 90Y-SPECT/CT and 90Y-PET/CT. PET/CT demonstrated better resolution with more accurate localisation at the periphery of tumour deposits and the number of affected lesions. In contrast, on SPECT/CT, smaller lesions were presented as solid spots and homogenous radioactivity concentration in larger lesions.

Conclusion: 90Y-PET/CT has a theoretical advantage over 90Y-SPECT/CT in terms of superior image quality, and in our small study, this is confirmed. However, more studies are required to determine its usefulness in the context of cost-effectiveness and clinical relevance.

IAEA-CN-232/98

Changes in SUV Values on 18F-FDG PET/CT after 2 Cycles of Neoadjuvant Chemotherapy May Predict Early Response in Patients with Locally Advanced Ductal Breast Carcinoma

C. Gonzalez¹, G. Bruno², M.E. Azar³, C. Tinetti¹, S. Traverso¹, F. Jaimez¹, N. Bustos¹, C. Noblia³, A. Osorio¹

¹Fundación Centro Diagnostico Nuclear

²Instituto Roffo

Corresponding Author: christiangonzalez71@hotmail.com

Background: The objective of the study was to demonstrate if the changes in the maximum standardized uptake values (SUVmax) after 2 cycles of neoadjuvant chemotherapy may predict early response in patients with locally advanced ductal breast carcinoma and differentiate responder from non-responder patients.

Methodology: This is an observational, prospective study. Between the years of 2008 and 2013, 32 patients were included with the diagnosis of locally advanced ductal breast carcinoma. All patients underwent 2 whole body 18F-FDG-PET/CT studies utilizing GE Discovery STE 16 equipment, before treatment (baseline PET/CT) and after the second cycle of chemotherapy (interim PET/CT). The 18F-FDG uptake of the lesions was quantified using SUVmax and compared between the two PET/CT studies. Subsequently, all patients underwent surgery and the results were correlated with surgical pathology specimen.

Results: In 11/32 (34.3%) patients a decrease lower than 50% or no change in the SUVmax were observed, either from the primary lesion or the regional nodes involvement, all of them showing gross residual disease in the surgical specimens and 3 (27.2%) of them also presented distant progression disease in the interim PET/CT. In 18/32 (56.2%) cases the SUVmax decreased more than 50%, showing minimal pathologic residual disease or complete pathologic response differentiating responder from non-responder patients with a sensitivity, specificity, positive predictive value (PPV), and negative predictive value (NPV) of 68%, 86%, 94.4%, and 43%, respectively. The average SUVmax decrease in responders and non-responder patients was 65.2% and 24.7% respectively ($p < 0.0005$). Also, in 8 of the 18 responder patients (44.4%) the decrease in SUVmax was greater than 80%; 3/8 (37.5%) of these patients presented smaller than 1cm residual tumours in the surgical specimen and 5/8 (62.5%) of them showed pathological complete response, however only one patient had also pathological complete response with a SUVmax decrease of 68.5% (lower than 80% but greater than 50 %).

Conclusion: In our study, a decrease in the SUV value equal or more than 50 % after 2 cycles of neoadjuvant chemotherapy had a positive correlation with pathological response and allowed to differentiate responder from the non-responder patients. Furthermore, a decrease in SUVmax value equal or more than 80% showed high correlation with complete pathologic response.

IAEA-CN-232/99

Potential Use of 18F-NaF-PET/CT for the Detection of Extra-Skeletal Metastases in Osteosarcoma Comparison with 18F-FDG-PET/CT

F. Jaimez, N. Bustos, G. Bruno, Gabriel, C. Gonzalez, C. Tinetti, S. Traverso

Fundacion Centro Diagnostico Nuclear

Corresponding Author: gbruno.idm@gmail.com

Background: 18F-sodium fluoride (NaF) is often used for the assessment of osteoblastic metastases in different types of tumours since it is a radiotracer whose uptake is directly related to the osteogenic activity, thereby it could be useful for the evaluation of patients with osteosarcoma with high suspicion of extra-osseous disease. The aim of our study is to demonstrate the potential use of 18F-NaF PET/CT for the detection of extra-skeletal metastases in patients with osteosarcoma.

Methodology: We present two patients with histologically confirmed diagnosis of osteosarcoma with suspicion of extra-skeletal metastases in conventional diagnostic methods. Both patients underwent whole-body 18F-NaF and 18F-FDG-PET/CT, and the results were compared.

Case 1: Male patient, 20 years of age with resected osteosarcoma of the left tibia. Six months after surgery, TC control study presented a calcified left pulmonary nodule suggestive of metastases.

Case 2: Female patient aged 70 years with resected primary osteosarcoma of the left breast (radical mastectomy). At diagnosis, calcified pulmonary nodules were seen on chest x-ray and CT scan, suspected malignancy.

Results: There were no differences regarding the number of lesions detected with both radiotracers. 18F-NaF showed higher metabolic activity in all lesions, being most notorious in case 1.

Case 1: The patient had a pulmonary nodule calcification in the left upper lobe showing increased uptake of both radiotracers, as the only manifestation of the disease. Lumpectomy was performed with histologically confirmed diagnosis of metastatic osteosarcoma.

Case 2: The patient presented multiple calcified lesions that showed intense avidity for both radiotracers; such as bilateral pulmonary nodules; mediastinal, right pulmonary hilar and mesenteric lymphadenopathies, and also subcutaneous and muscle nodules.

Conclusion: Both radiotracers might be useful for the evaluation of extra-skeletal metastases of osteosarcoma, since they both detected all the lesions equally. However, 18F-NaF had higher metabolic activity in all the lesions, so it may represent an alternative radiotracer and perhaps the main choice, due to its selective uptake in this type of osteogenic neoplasm. Further validation is needed with a larger number of cases.

IAEA-CN-232/100

Inclusion of PET/CT Scanning and Respiratory Gating in the Radiotherapy Treatment Process of Thoracic Malignancies

J.A. Villalobos¹, A.C. Jiménez²

¹ Centro Médico de Radioterapia Siglo XXI

² Medicina Nuclear, Hospital Rafael Ángel Calderón Guardia

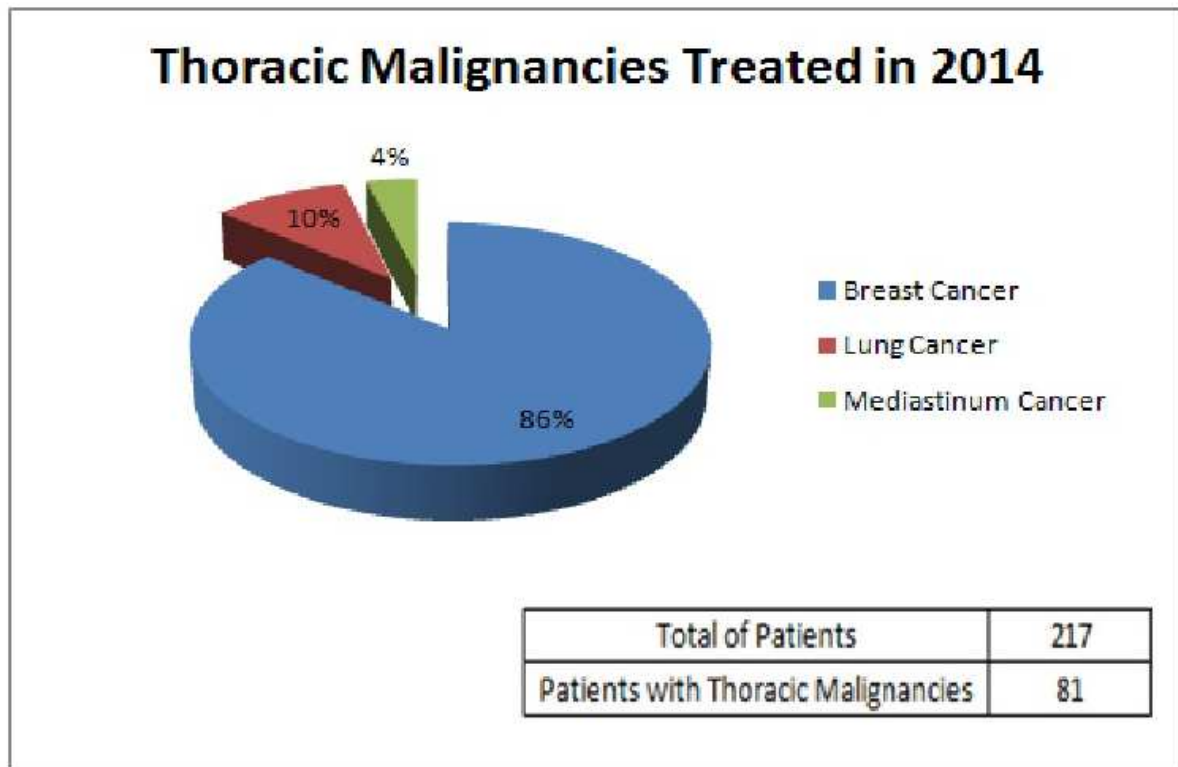
Corresponding Author: jorgevillarosales@hotmail.com

Background: Radiotherapy (RT) is one of the most important treatments used in oncologic patients. Each step in the radiation treatment process (physician consultation, simulation and treatment planning, verification simulation, daily treatments, weekly status checks and follow up after treatment) is crucial and affects directly the effectiveness of this therapy. The inclusion of modalities and procedures like hybrid positron emission tomography with computer tomography (PET/CT) and respiratory gating (RG) technology may help improve the accuracy of radiotherapy. The aim of this study is to determine how useful it could be for our centre to include PET/CT and RG in the thoracic malignancies treatment process.

Methodology: An analysis of our database was performed in order to determine: how many patients were treated in total in 2014, how many of them due to thoracic tumours and its therapeutic approach. Bibliographic research on PET/CT and RG was also done with the objective of learning the impact and benefits of using these technologies in developing countries.

Results: A total of 217 patients were treated in 2014. Around 40% of these patients had malignant neoplasm in the thoracic area (Graph1). All of them were planned with a conventional General Electric CT and treated in a Varian Clinac 1800 without contemplating the thoracic movement due to respiration, although our centre recently established for the first time in Central America, the use of a Varian Trilogy with RG.

Many formal studies indicate that PET/CT changes the actual concept of RT planning process because it not only considers the anatomic aspects (such as the CT), but it also associates metabolic and biologic factors. The inclusion of PET/CT brings a more accurate delineation of the tumour volume, the extent of the disease and has an important role for therapy response. RG is non-invasive; it monitors patient's breathing and movement of the tumour during treatment. It allows a more effective dosage amount, while minimizing unnecessary radiation to normal tissues.



Conclusion: PET/CT gives a more accurate staging and treatment, and an optimal follow up of thoracic malignancies. RG allows for a real time tumour tracking, localization and real time beam adaption, reducing acute and late toxicities. Costa Rica actually does not have PET/CT, but around the country many short term projects (2015-2016) are being developed. A few months ago our centre started using RG during RT; the possibility of starting to use PET/CT during the treatment process also should be taken into account, considering that we treat an important number of patients with thoracic malignancies.

IAEA-CN-232/101

68Ga-DOTANOC PET/CT Imaging in Localizing the Primary Site in Patients Presenting with Metastatic Neuroendocrine Tumours and its Impact on Clinical Decision Making: Experience from a Tertiary Care Centre in India

E.S. Ethel, H. Mahajan, A. Pruthi, P. Pankaj, R. Verma, A. Jain

Department of Nuclear Medicine and PET CT, Mahajan Imaging Centre, and Ganga Ram Institute for Postgraduate Medical Education and Research (GRIPMER), Sir Ganga Ram Hospital, New Delhi- 110060, India.

Corresponding Author: ankur.pruthi2004@gmail.com

Background: Neuroendocrine tumours (NETs) are rare, heterogeneous group of tumours which usually originate from small, occult primary sites and are characterized by over-expression of somatostatin receptors (SSTRs). Positron emission tomography / computed tomography (PET/CT) using 68Ga labeled somatostatin analogues has shown superiority over other modalities for imaging of NETs.

The purpose of this study was to retrospectively evaluate the efficacy of 68Ga-DOTANOC PET/CT imaging in detecting the primary site in patients with metastatic neuroendocrine tumours of unknown origin and its impact on clinical decision making in such patients.

Methodology: Between December 2011 and September 2014, a total of 263 patients underwent 68Ga-DOTANOC PET/CT study in our department for various indications. Out of them, 68 patients (45 males, 23 females, mean age 54.9 +/- 10.7 years, range 31-78 years) with histopathologically proven metastatic neuroendocrine tumours and unknown primary site on conventional imaging underwent 68Ga-DOTANOC PET/CT as part of their staging work-up. Histopathology (wherever available) and/or follow-up imaging with biochemical markers were taken as reference standard. Quantitative estimation of somatostatin receptor (SSTR) expression in the form of maximal standardized uptake value (SUVmax) of detected primary and metastatic sites was calculated. Follow up data of individual patients was collected through careful survey of electronic medical records and telephonic interviews.

Results: Maximum patients presented to our department with hepatic metastasis (50 out of 68 patients) and grade I neuroendocrine tumours (>50%). 68Ga-DOTANOC PET/CT scan identified primary sites in 40 out of these 68 patients, i.e. in approximately 59% patients. Identified primary sites were: Small intestine (19), rectum (8), pancreas (7), stomach (4), lung (1) and one each in rare sites in kidney and prostate. In one patient, 2 primary sites were identified (one each in stomach and duodenum). Mean SUVmax of the detected primary sites was 25.1 +/- 18.0 (median 16.25, range 2.1-150). Significant positive correlation was found between SUVmax of primary tumour and histopathologically proven sites of metastasis ($r = 0.662$; $p < 0.0001$). Based on the findings of the 68Ga-DOTANOC PET/CT scan, 3 out of 40 patients underwent definitive treatment for their primary tumour (1 gastric, 1 ileal and 1 prostatic tumour). 1 patient was being planned for resection of primary rectal lesion. 32 / 68 patients were started on long acting somatostatin analogues or chemotherapy or targeted therapy. 1 patient underwent multiple cycles of peptide receptor radionuclide therapy (PRRT) using 90Y and 177Lu labeled somatostatin analogues.

Conclusion: Our findings indicate that 68Ga-DOTANOC PET/CT is a promising imaging modality in patients with metastatic neuroendocrine tumours of unknown origin for detection of the primary site and

International Conference on Clinical PET-CT and Molecular Imaging (IPET 2015): PET-CT in the Era of Multimodality Imaging and Image-Guided Therapy

in guiding their therapeutic management.

IAEA-CN-232/102

Diagnostic Accuracy of 18F-FDG PET/CT in Differentiated Thyroid Cancer Patients with Elevated Serum Thyroglobulin or Anti-Tg Levels

C. Kaewput¹, P. Pusuwan²

¹ Faculty of Medicine Siriraj Hospital, Mahidol University

² Faculty of Medicine Siriraj Hospital

Corresponding Author: aung_med@hotmail.com

Background: 18F-FDG PET/CT is widely accepted for localizing disease in differentiated thyroid cancer (DTC) patients with high stimulated Tg levels (≥ 10 ng/ml) and negative iodine-131 whole body scan (131I WBS). In Thailand, 18F-FDG PET/CT in DTC is not routinely used due to its high cost and inability of reimbursement. The objective of our study is to evaluate diagnostic accuracy of 18F-FDG PET/CT in detection of recurrence or metastases in DTC patients with elevated stimulated Tg or anti-Tg (Ab) levels.

Methodology: Between January 2007 and December 2014, a total of 38 18F-FDG PET/CT examinations in 36 DTC patients with elevated stimulated Tg levels (n=33) or elevated anti-Tg levels (≥ 40.0 ng/ml, n=5) but negative post-therapeutic 131I WBS or diagnostic 131I WBS were included. All patients underwent total thyroidectomy and radioiodine ablation. A cut-off value of 18F-FDG SUVmax ≥ 3.2 was used to classify as a positive lesion for recurrence or metastasis according to Wong et al. 18F-FDG PET/CT findings were compared with histological (n=16) or clinical follow-up results based on serum Tg/anti-Tg levels or other imaging modalities. Duration of follow-up ranged from 6 months to 7 years (median duration = 30 months).

Results: Thirty-one studies showed true positive lesions of local recurrence (n=23, 60.5%), distant metastases (n=2, 5.3%) and both local recurrence and distant metastases (n=6, 15.8%). Two studies (5.3%) were considered as false positive lesions at cervical nodes which were confirmed by histological results (n=1) and gradual decrease of Tg levels without further treatment for more than one year (n=1). Four studies (10.5%) confirmed true negative results. A patient with no abnormal 18F-FDG avidity in sub-centimeter cervical lymph nodes was clarified as false negative as subsequent follow-up results showed slow rising of Tg levels with suggestion of cervical node metastases demonstrated by neck ultrasonography. Sensitivity, specificity, and accuracy of 18F-FDG PET/CT in this study were 96.9%, 66.7% and 92.1%, respectively. Additional information of previously undiagnosed lesions were found in 4 patients i.e. meningioma and metastatic lesions in brain, bone, liver, muscle, and soft tissue.

Table 1. Validation of ¹⁸F-FDG PET/CT findings and location of recurrence or metastasis

PET/CT results	Validation		Total
	Histology	Clinical follow-up	
True positive			
- LR	13	10	23
- LR + Distant metastasis	2	4	6
- Distant metastasis	0	2	2
False positive			
- LR	1	1	2
True negative			
- LR	0	4	4
False negative			
- LR	0	1	1
Total	16	22	38

LR = Local recurrence

Conclusion: ¹⁸F-FDG PET/CT is useful for detection and localization of recurrence or metastases in DTC patients with negative ¹³¹I WBS but elevated stimulated Tg or anti-Tg levels. This technique also provides useful additional findings for better management of these patients.

IAEA-CN-232/103

**Spectrum of Malignancies Diagnosed on 18F-FDG PET/CT
Presenting as FUO**

P. Gupta, P. Pankaj

Sir Gangaram Hospital, New Delhi

Corresponding Author: parulgupta85@gmail.com

Background: Malignancy forms an important part of the disease burden in modern era. Most of the times individuals present with FUO (fever of unknown origin) along with other non-specific symptoms like low grade fever, weight loss and weakness. At times, the patients may also present with symptoms caused by secondarily involved organs or systems, as in the case of metastases involving skeletal system where the patient presents with pain. At times, the presentation may include paraplegia due to spinal cord involvement. Tumours are particularly common in elderly FUO patients. Many of the tumours, especially Hodgkin's disease, aggressive non-Hodgkin's lymphoma, lung cancer, carcinoma gall bladder, carcinoma stomach, colorectal cancer, pancreatic cancer, and sarcoma, are diseases commonly detected by FDG PET, where clinical symptoms have yet not manifested.

Subjecting such patients to a host of conventional imaging modalities ranging from sonography, regional computed tomography (CT), whole-body CT scan, magnetic resonance imaging, etc. could be mentally and financially agonizing to the patient and the family because the modalities have limited sensitivity and specificity, especially during early stage of the disease when the morphological changes may be either absent or subtle. Also these modalities provide only regional information, hence a comprehensive whole body examination is particularly lacking. 18F-FDG PET is a potential tool that could provide a complete whole body examination, hence clearing the diagnostic dilemma.

Methodology: We studied 20 patients who had presented with non-specific symptoms like low grade fever, weight loss, weakness where ruling out a malignancy was mandatory. The patients were examined by 18F-FDG PET/CT and the results were correlated with standard histopathological reference diagnostic tests.

Results: Amongst the twenty cases studied and followed up, five patients suffered from Hodgkin's lymphoma, four from non-Hodgkin's lymphoma, three from carcinoma lung, two each from renal cell carcinoma and carcinoma gall bladder, and one each from carcinoma pancreas, carcinoma urinary bladder, carcinoma ovary, and neuroblastoma.

Conclusion: Our study demonstrated that 18F-FDG PET/CT is a valuable imaging tool for screening the whole body and ruling out any malignancy in cases presenting with non-specific symptoms. A wide spectrum of malignancies diagnosed on 18F-FDG PET/CT includes lymphoma, carcinoma lung, gall bladder, pancreas, urinary bladder, renal cell carcinoma, neuroblastoma and carcinoma ovary. 18F-FDG PET/CT facilitates a diagnosis not only by indicating the best biopsy site, but also through altering the traditional clinical perspective by providing morphological and functional hybrid imaging of the whole body. Furthermore, 18F-FDG PET/CT not only helped in finding a malignancy but also in staging the disease, hence having a bearing on further treatment planning.

IAEA-CN-232/104

Evaluation of the Role and Incremental Value of 18F-Fluoro Deoxyglucose PET-CT in Diagnosing the Cause of Fever of Unknown Origin

P. Gupta¹, P. Promila²

¹ Sir Gangaram Hospital, Rajinder Nagar, New Delhi

² Ganga Ram Institute for Postgraduate Medical Education and Research (GRIPMER), Sir Ganga Ram Hospital, New Delhi- 110060, India

Corresponding Author: parulgupta85@gmail.com

Background: Fever of unknown origin (FUO) remains a vexing issue consequent to a wide range of possible causes for both patients and physicians. Hence, there is a need for more complex or invasive techniques. Irrespective of the advent of innumerable invasive and non-invasive diagnostic approaches, and imaging techniques, the failure in reaching a diagnosis can vary anything between 7% and 53%. This is mainly because the conventional imaging modalities like CT, USG, MRI, have limited sensitivity and specificity, especially during early stage of the diseases when the morphological changes may be either absent or subtle. This hampers the generalization of these diagnostic approaches. The present study is set to evaluate the diagnostic value of 18F-FDG PET-CT for patients with FUO.

The aim of this study is to evaluate the role and incremental value of 18F-FDG PET-CT in diagnosing the cause of FUO and to correlate findings of 18F-FDG PET-CT scan with various reference standard diagnostic tests.

Methodology: We studied 90 patients with FUO (48 men and 42 women; mean age of 51-year-old with a range between 2 and 88 years old). The patients were examined by 18F-FDG PET-CT and the results were correlated with standard reference diagnostic tests and therapeutic response.

Results: A final diagnosis was established in 69 patients (76.7%). Among them, 27 patients had infectious diseases, 13 patients had non-infectious inflammatory diseases, 12 patients had malignancies, and 2 had miscellaneous causes (like thyroiditis). 44 abnormal 18F-FDG PET-CT results correctly revealed the source of fever (true-positives). Abnormal PET/CT results were considered false-positives for 16 patients without diagnosis. Normal 18F-FDG PET-CT results in 15 patients with no diagnoses were classified as true-negatives. Five patients with normal 18F-FDG PET-CT results with diagnosed cause for FUO were considered false-negatives. Therefore, 18F-FDG PET-CT had a positive predictive value of 77.1%, a negative predictive value of 75%, a sensitivity of 91.5%, and a specificity of 48.4% in patients with FUO.

Conclusion: Our study demonstrated that 18F-FDG PET-CT is a valuable imaging tool for the identification of the etiology in patients with FUO. 18F-FDG PET-CT was found to provide valuable information, facilitating a final diagnosis or ruling out a focal pathology in patients with FUO. 18F-FDG PET-CT facilitates a diagnosis not only by indicating the best biopsy site, but also through altering the traditional clinical perspective by providing morphological and functional hybrid imaging of the whole body. Even a negative 18F-FDG PET-CT was useful in terms of guiding further management strategies.

IAEA-CN-232/105

Role of 18F-FDG PET/CT Imaging in Diagnosis and Therapeutic Response Evaluation in Tuberculosis

P. Gupta¹, P. Promila²

¹Sir Gangaram Hospital, Rajinder Nagar, New Delhi

²Ganga Ram Institute for Postgraduate Medical Education and Research (GRIPMER),
Sir Ganga Ram Hospital, New Delhi- 110060, India

Corresponding Author: parulgupta85@gmail.com

Background: Tuberculosis is a chronic granulomatous inflammation caused by *Mycobacterium tuberculosis*. India accounts for nearly a third of the global burden of tuberculosis, with approximately 1.8 million new cases of tuberculosis reported every year. Sites of disease can include almost every organ including the brain, lungs, lymph nodes, heart, liver, spleen, genitourinary system, skeletal system and even skin. Skeletal disease is one of the most common extra-pulmonary manifestations of TB, affecting 3–5% of patients, half of whom have spinal column involvement.

The conventional imaging has limited sensitivity and specificity during early stage of the disease as morphological changes are absent or subtle. Tuberculous lesions have increased 18F-FDG uptake in the active regions of granulomatous inflammation, with cold areas representing necrosed tissue. 18F-FDG PET/CT determines the activity of lesions, guides biopsy from active sites, assesses disease extent, detects occult distant foci and also evaluates response to therapy.

The study was aimed at evaluating the role of 18F-FDG PET/CT in diagnosis and therapeutic response evaluation in twenty patients in view of symptoms like chronic low grade fever, weight loss, cough, etc., undiagnosed on biochemical and laboratory tests and conventional imaging.

Methodology: The patients underwent 18F-FDG PET/CT and results were correlated with standard histopathological tests and therapeutic response. Fifteen patients were available for follow-up. A follow-up 18F-FDG PET/CT showing resolution of 18F-FDG uptake and size of the lesions equal to or less than 50% was labeled as therapeutic response.

Results: Sixteen abnormal 18F-FDG PET/CT results correctly revealed the source of fever (true-positives). Among these 16 true positive cases, 6 patients had multi-organ involvement (brain/pulmonary/skeletal/hepatic/splenic lesions), 4 had tubercular lymphadenitis, 4 had pulmonary tuberculosis, and 2 patients had abdominal tuberculosis. Abnormal PET/CT results were considered false-positives for 2 patients without diagnoses where histopathological tests came negative. Normal 18F-FDG PET/CT results in 2 patients with no diagnoses were classified as true-negatives. None of the patients with negative findings was diagnosed with disease on any other modality in the follow-up period. So, 18F-FDG PET CT had a PPV of 88.9%, a NPV of 100%, a sensitivity of 100%, and a specificity of 50%.

Conclusion: 18F-FDG PET/CT is a valuable imaging tool for the identification of the sites of involvement in tuberculosis. 18F-FDG PET/CT facilitates diagnosis not only by indicating the best biopsy site, but it also alters the traditional clinical perspective by providing morphological and functional hybrid imaging of the whole body. Another information provided 18F-FDG PET/CT is screening the whole body and ruling out any occult malignancy which clinically may present with non-specific symptoms like weight loss, weakness, low grade fever. Even a negative 18F-FDG PET/CT was useful in terms of guiding further management strategies.

IAEA-CN-232/106

Labelling and Quality Controls of ⁶⁸Ga-PSMA for Prostate Tumours

A. Duran¹, F. Müller², J. Santiñan³, C. Peñaloza⁴, A. Coronel²

¹Comision Nacional de Energia Atomica, Argentina

²Fundacion Centro Diagnostico Nuclear

³Fundacion Centro Diadnostico Nuclear

⁴Comision Nacional de Energia Atomica

Corresponding Author: aduran@fcdn.org.ar

Background: PSMA (prostate specific membrane antigen) is a membrane glycoprotein. It is well established in diagnosis as a highly specific protein in prostate tumour cells surface. Compared to healthy human prostate tissue, in almost all prostate tumours, the expression of PSMA is 10–80 fold higher. We developed a fully automated synthesis of ⁶⁸Ga-PSMA using our experience in labeling other common DOTA peptides such as TOC, TATE and NOC. Radiochemical purity was above 97% assessed by radio HPLC technique.

Methodology: In this paper ⁶⁸Ga-eluate was obtained from different commercial generators (iThemba, Eckert Ziegler, ITG). A Scintomics® module was used for all the labelings. Synthesis routines were written and adapted to achieve an automated labelling. Different labeling strategies, such as elution parameters, pre-purification and final purification methodologies and selection of reaction media (buffers) were evaluated and optimized conditions were developed.

Results: Radiochemical yield above 70% EOS was obtained, with radiochemical purity above 97% using a fractionated elution method, acetate buffer and C-18 post-purification.

Conclusion: In this work we have demonstrated the feasibility of automation to deal with different starting conditions in production of a consistent quality radiopharmaceutical.

IAEA-CN-232/107

Evaluation of PET/CT Role in Diagnosis and Management of Paediatric Malignancies

A. Abaza¹, G. El-Shanshoury²

¹ Ass. Prof. of Safety and Prevention of Oncology in Radiation Protection Department, Nuclear and Radiological Regulatory Authority, Cairo, Egypt

² Ass. Prof. in Radiation Safety Department

Corresponding Author: aya_abaza@hotmail.com

Background: Successful management of solid tumours in children requires imaging tests for accurate disease detection, characterization, and treatment monitoring. 18F-fluorodeoxyglucose positron emission tomography/computed tomography (18F-FDG PET/CT) is a highly sensitive and specific imaging modality for whole-body evaluation of paediatric malignancies. The study aimed to retrospectively evaluate the efficacy of 18F-FDG PET/CT imaging system in the management of some paediatric malignancies and to determine if it provided additional diagnostic information on disease status, during the last 4 years (y).

Methodology: 180 paediatric patients (118 male and 62 female) were included in the study. Their age ranged from 6 month to 19 y at their first PET/CT examination. 78.3% of the patients were below 10 years of age. 100 patients had lymphoma (82 Hodgkin and 18 non-Hodgkin), 26 had soft tissue sarcoma (STS), and 54 had neuroblastoma. The indication, purpose, and findings of each PET/CT examination were reviewed, in addition to other imaging findings as well as clinical information including follow-up results for >1 y from their last PET/CT examination. 720 scans were performed for whole body in all patients for initial diagnosis and staging and restaging of recurrent malignancy. It is also performed to assess cancer response to therapy and after therapy as a routine follow-up procedure or for further evaluation of suspected recurrence or for secondary malignancy. 1080 suspicious sites were evaluated in the studied patients, and those whose reports indicated areas of increased FDG uptake were selected. PET/CT findings were compared with the results of other diagnostic procedures (including CT and ultrasound), biopsy findings and follow-up data.

Results: The current study demonstrates that 18F-FDG PET/CT may influence treatment decision if distant metastases or second primary tumours are detected with regard to staging of the primary tumour. Post chemo-radiotherapy (CRT) PET/CT does aid subsequent management decisions. The overall sensitivities, specificities, and positive and negative predictive values of the imaging system for all the suspicious sites were 98.1%, 97.2%, 97.6% and 97.8% respectively. It was 94.60%, 97.50%, 92.10%, and 98.30% respectively for detecting the local recurrence at the end of treatment; and 96.20%, 98.30%, 92.60%, and 99.10% after 1y of treatment. The sensitivity and specificity of 18F-FDG PET/CT for initial staging of malignant lymphomas is 83.3-100% and 93.75-100% respectively. It ranged from 66.70-100% and from 91.30-100% respectively in sarcoma, and 86.70-100% and 95.80-100% respectively in neuroblastoma.

Conclusion: The study concluded that 18F-FDG PET/CT is the gold standard for non-invasive functional imaging in oncology. Technical developments in PET scanning in cancer management may increase the precision of radiotherapy planning and thus improve tumour control and reduce treatment-related morbidity. PET/CT is recommended in the management of paediatric malignancies to facilitate the

sparing of normal structures and the escalation of dose.

IAEA-CN-232/108

Comparison between PET/CT, SPECT-CT and Planar Bone Scintigraphy in Following and Managing Cancer with Potential Bone Metastases - Bucharest Emergency University Hospital Experience

D. Piroiu¹, R. Vladescu², C. Popescu³

Bucharest Emergency University Hospital, Romania

Corresponding Author: diana_piroiu@yahoo.com

Background: It is known that compared to planar bone scintigraphy and SPECT-CT, PET-CT has a superior image resolution and enables quantification of the uptake of the target lesion. Currently, in Romania there are only a few medical centres which own PET-CT, and all of them are in the private medical system. Because of this, PET-CT examination is not accessible to oncologic patients, only a few of them having the possibility to access it. The purpose of this study is to compare the results of PET-CT investigations with SPECT-CT and planar bone scintigraphy in monitoring cancer with potential bone metastases.

Methodology: The study was retrospective and included 17 oncologic patients, most of them with breast or prostate cancer, who had done a PET-CT in the past - from 8 months to 3 years before, and they were monitored in the nuclear medicine department of the Emergency University Hospital, with SPECT-CT and planar scintigraphy. The PET-CT examinations were done in other medical centres, some in Romania and others abroad.

Results: 5 of the patients had multiple metastases which were detected by all 3 methods of investigation. Other 7 patients who were included in the study didn't have any oncologic bone modifications in PET-CT. In 5 of these 7 patients, there weren't any modifications noted in planar scintigraphy. In the other 2, multiple metastases were noted in whole-body examination. 3 of the patients had a unique equivocal bone lesion found with PET-CT. In 2 of them, no modifications were found with SPECT-CT and in 1, the lesion was interpreted as equivocal as well. In 2 of the patients, PET-CT found certain MTS, and with SPECT-CT, the lesions were interpreted as equivocal.

Conclusion: PET-CT is a superior method compared to SPECT-CT and planar scintigraphy in detecting bone metastases and is useful for monitoring oncologic diseases. However, in the economic context of Romania, SPECT-CT and planar scintigraphy are more accessible.

IAEA-CN-232/109

The Usefulness of ¹¹¹In - Pentetreotide SPECT/CT in the Assessment of Neuroendocrine Tumours

I. Slim, M.F. Ben Slimen

Nuclear Medicine Department, Salah Azaiez Institut, Tunisia

Corresponding Author: ihsen.slim@gmail.com

Background: Hybrid single photon-emission computed tomography (SPECT) and computed tomography (CT) imaging for the investigation of neuroendocrine tumours (NET) allows the fusion of functional and anatomic information in a rapid and efficient method. The aim of this study was to assess the incremental diagnostic value of ¹¹¹In-pentetreotide SPECT/CT imaging compared with traditional planar imaging on study interpretation (lesion localization and characterization and reader confidence).

Methodology: Forty five patients (20 female and 25 male; age range 18-71 y, mean 51 y) with proven or suspected NET were studied with routine planar somatostatin receptor scintigraphy (at 4 and 24 hours) and SPECT/CT (at 24 and optionally 48 hours) after injection of 185-222 MBq ¹¹¹In-pentetreotide. Twenty two patients came for initial diagnosis and detection of metastases, 14 patients for follow up after treatment (gastric tumours n = 8, endocrine pancreatic tumours n = 12, midgut tumours n= 10 and other NETs n= 6) and 9 patients for metastatic NET of unknown primary.

Results: Planar scintigraphy was positive in 23 patients, doubtful in 10 patients and negative in the other 12 cases. Whereas SPECT/CT imaging was positive in 38/40 patients: showed unsuspected foci in 8 negative planar scans, confirmed doubtful foci in 8 patients and showed all 22 pathologic planar lesions with detection of additional lesions in 11 among them. SPECT/CT allowed disease exclusion in site of physiological uptake in five patients. In general, SPECT/CT imaging provided incremental diagnostic value in 60% of cases.

Conclusion: ¹¹¹In-pentetreotide SPECT/CT imaging provides incremental diagnostic value and greater reader confidence over planar imaging, allowing a better therapeutic management of patients with NET.

IAEA-CN-232/110

The Role of Interim 18F-Fluoride PET/CT in Patients Submitted to Radium-223 Therapy

E. Etchebehere, J. Araujo, P. Fox, N. Swanston, H. Macapinlac, E. Rohren

The University of Texas, MD Anderson Cancer Center

Corresponding Author: ecetchebehere@mdanderson.org

Background: Radium-223 dichloride therapy (Ra-223) has improved survival in prostate cancer patients, although a subset does not respond. It would be important to identify this subgroup. Whole-body 18F-sodium fluoride PET/CT (Fluoride PET/CT) is ideal for staging and restaging prostate cancer patients. Interim studies performed with 18F-FDG PET/CT play an important role in the management of patients with a variety of cancers. Similarly, interim fluoride PET/CT may be able to identify patients that will not respond to Ra-223 thus reducing morbidity and unnecessary costs. The purpose of this study is to evaluate the role of interim Fluoride PET/CT performed after the third dose of Radium-223 therapy (Ra-223).

Methodology: This study was approved by the Institutional Review Board (PA14-0848). We retrospectively reviewed 76 histologically confirmed hormone-refractory prostate cancer patients (43-89 y old; mean 71 ± 9 yrs.) with bone metastases submitted to Ra-223 and Fluoride PET/CT.

Eligibility criteria for treatment with Ra-223 consisted of absolute neutrophil counts above 1.5 K/uL and platelet counts > 100 K/uL. All patients completed at least 4 cycles of Ra-223. Treatment was conducted by performing intravenous infusions of 50 kBq/kg (1.4 μ Ci/kg) of Ra223Cl₂.

Images were performed immediately prior to initiation of Ra-223 (baseline Fluoride PET/CT) and immediately before the fourth dose of Ra-223 (interim Fluoride PET/CT). All images were acquired 50-60 minutes after intravenous injection of 158-370 MBq of 18F-sodium fluoride on PET/CT systems. Whole-body non-contrast enhanced CT scans were used for attenuation correction.

Overall survival (OS) was the primary end point. Secondary end points were progression-free survival (PFS) and time to a bone event (TTBE).

Skeletal tumour burden was determined by calculating (on baseline and interim Fluoride PET/CT studies) the total skeletal metastatic lesion with fluoride uptake (TLF10) and the fluoride-avid bone metastases total volume (FTV10). These parameters were obtained after establishing an SUV_{max} >10 as positive for bone disease. To evaluate the performance of interim Fluoride PET/CT, the percent change in skeletal tumour burden between baseline and interim studies was calculated and defined as %TFL10 and %FTV10: ((Interim – Baseline)/ Baseline).

Results: Thirty-four patients underwent both baseline and interim Fluoride PET/CTs prior to Ra-223 and were thus eligible for analysis. Skeletal tumour burden (TLF10 and FTV10) were highly correlated ($\rho=0.95$; $p<.0001$) and thus for subsequent analyses, only %TFL10 was used. %TLF was not able to predict OS ($P=0.6320$; HR = 0.753; 95%CI =0.236- 2.401), PFS ($P=0.5908$; HR = 1.248; 95%CI =0.557- 2.797) nor TTBE ($P=0.5114$; HR = 1.588; 95%CI =0.399- 6.312).

Conclusion: Skeletal tumour burden on interim Fluoride PET/CT, performed after 3 doses of Ra-223 is not able to predict OS, PFS or TTBE.

IAEA-CN-232/111

Local Experience of Using Intravenous ^{99m}Tc Macroaggregated Albumin in the Diagnosis of Hepatopulmonary Syndrome

R. Brown¹, P.S. Chuah², I. Hufton¹, S. Vinjamuri¹

¹ Royal Liverpool University Hospital

² Nuclear Medicine Department, Royal Liverpool University Hospital

Corresponding Author: ruth.brown@doctors.org.uk

Background: This was a review of our local use of intravenous ^{99m}Tc Macroaggregated Albumin (MAA) in the diagnosis of hepatopulmonary syndrome (HPS). When HPS occurs in patients with chronic liver disease it causes intrapulmonary vascular dilatation, small arteriovenous communications and subsequent arterial deoxygenation. Contrast echocardiography is used to detect the presence of intrapulmonary vasodilatation; however, patients with positive contrast echocardiography may have normal arterial blood gases and thus would not fulfil criteria for HPS. Contrast echocardiography is sensitive but it lacks specificity. ^{99m}Tc-MAA can be used as a complementary modality in the detection of HPS in particular in the setting of concomitant lung disease which may also contribute to a patient's hypoxaemia.

Methodology: This was a retrospective data analysis of all patients who received intravenous ^{99m}Tc MAA with the aim of evaluating the shunt fraction in determining the presence of HPS over a 17 month period. Hepatopulmonary shunt quantification was determined by evaluating the geometric mean of counts within the lungs and brain to calculate the extrapulmonary shunt factor. All results were interpreted by an experienced nuclear medicine physician.

Results: 7 patients in total were scanned in which HPS was clinically suspected (M4:F3); 72% were known to have liver cirrhosis, 14% had primary biliary cirrhosis and 14% had hepatitis C without cirrhosis. Of these 7 patients 1 patient with cirrhosis had a ^{99m}Tc MAA scan confirming HPS, 1 had a borderline result and the remaining 5 were negative for HPS.

Conclusion: Intravenous ^{99m}Tc MAA is a valuable and complementary diagnostic tool in determining the cause of hypoxia in patients who have established and advanced hepatic disease, especially in the presence of pre-existing lung disease.

IAEA-CN-232/113

Local Diagnostic Performance Using Serial Brain Imaging with 99mTc-HMPAO and 123I-FP-CIT (DaTSCAN) in the Evaluation of Patients with Dementia when Differentiating Alzheimer's Disease from Lewy Body Dementia

R. Berhane Menghis¹, S. Vinjamuri¹, R. Brown¹, P.S. Chuah²

¹Royal Liverpool University Hospital

²Nuclear Medicine Department, Royal Liverpool University Hospital

Corresponding Author: ruth.brown@doctors.org.uk

Background: This was a review to evaluate local use of serial brain imaging with 99mTc-hexamethylpropyleneamine oxime single photon emission tomography (99mTc-HMPAO SPECT) and 123I-FP-FIT DaTSCAN SPECT in aiding the diagnosis of Alzheimer's Disease (AD) and Lewy Body Dementia (LBD). The global prevalence of AD has increased significantly within the last 20 years; dementia rates are predicted to increase further and with it an associated growing socioeconomic burden. Accurate assessment and diagnosis of dementia and its subtypes is therefore of supreme importance since there are treatment, prognostic and public health implications.

Methodology: This was a 4 year retrospective data analysis of 40 patients who had both HMPAO and DaTSCAN in whom LBD or AD was suspected (15F: 25M, median age 75 years). Visual interpretation was used to evaluate perfusion abnormalities on HMPAO and dopaminergic presynaptic terminal loss on DaTSCAN studies and this was performed by an experienced nuclear medicine physician.

Results: Both studies were abnormal in 25 patients, 13 patients had an abnormal HMPAO only, 1 patient had a normal HMPAO and only 1 patient had no abnormality found. Overall, 38% were diagnosed with LBD, 25% with AD, 15% of patients had mixed vascular and LBD, 10% with mixed vascular and AD, 7% with small vessel vascular dementia, 2.5% with a Parkinson syndrome and 2.5% had no detectable abnormality.

Conclusion: In the age of PET agents for evaluating patients with dementia, the role of SPECT tracers should not be forgotten; combining HMPAO with DaTSCAN improves diagnostic confidence and consequently is a useful clinical tool in patient management.

IAEA-CN-232/114

Significance and Prevalence of Extra-Osseous Findings of Low Dose CT Performed with 18F-Fluoride PET/CT Bone Scans in Patients with Breast Cancer

R. Brown¹, P.S. Chuah², R. Berhane Menghis¹, S. Vinjamuri¹

¹Royal Liverpool University Hospital

²Nuclear Medicine Department, Royal Liverpool University Hospital

Corresponding Author: ruth.brown@doctors.org.uk

Background: The objective of the study is to evaluate the local prevalence of detected extra-osseous findings on reviewing the low dose, unenhanced CT performed in conjunction with 18F-Fluoride PET/CT bone scans in patients with breast cancer. This particular patient group are at risk of other concomitant primary cancers, such as ovarian cancer and as a consequence of their cancer treatment these patients can be immune-compromised and predisposed to infection. Evaluation of the low dose un-enhanced CT therefore provides clinicians with additional information which may change patient management.

Methodology: A retrospective data analysis was performed over a one year period in all patients with breast cancer who underwent a 18F-Fluoride PET/CT bone scan. The scans were either reported by two experienced nuclear medicine physicians or by a nuclear medicine physician and a radiologist.

Results: 343 18F-Fluoride PET/CT bone scans were performed in patients with breast cancer in 2013 with 24% showing incidental extra-osseous findings with 22% of these in the pelvis, which was an area often excluded on diagnostic CT scans. 63% of all the incidental findings were deemed to be potentially significant and examples of these include: suspected second primary cancers, adrenal masses and aortic dilatation.

Conclusion: Evaluating the low dose unenhanced CT provides an additional opportunity to detect previously unknown pathology which has the potential to impact on patient management. Careful and methodical evaluation should be employed to maximise this.

IAEA-CN-232/115

**Contribution of PET-CT in Infection - Moroccan Experience:
Application in Tuberculosis Mimicking a Metastatic Cancer**

N. Ben-Rais¹, R. Aouad², A. Alj³, H. Guerrouj⁴, I. Ghfir⁵, M. Farhati⁶

¹Head of Referral Nuclear Medicine Department IBN Sina Teaching Hospital Rabat Morocco

²Faculty of Medicine Rabat

³Rabat PET Scan

⁴IBN Sina Nuclear Medicine Department

⁵IBN Sina Referral Nuclear Medicine Department

⁶Maternity

Corresponding Author: nouzhanucm@yahoo.fr

Background: Tuberculosis (TB) is a chronic granulomatous inflammation caused by mycobacterium tuberculosis. While performing FDG PET-CT for oncologic workup, we report ten cases of tuberculosis, including three cases of disseminated tuberculosis mimicking metastatic cancer.

Many studies have documented increased FDG uptake in active TB in diverse anatomical locations, mimicking malignant processes.

Due to the high prevalence of TB in Morocco, false positive cases during oncology workup with FDG-PET/CT are commonly encountered in practice.

Although FDG-PET/CT is not specific for tuberculosis it plays an important role in the evaluation of known or suspected TB cases.

FDG-PET/CT can determine the activity of lesions, guide biopsy from active sites, assess disease extent, detect occult distant foci, and evaluate response to therapy.

Methodology: In this study we assessed whether 18F-FDG PET-CT can be used to detect and localize metastatic tuberculosis infections. All studies were performed on an integrated PET-CT "Discovery" GE, PET FDG 3mn/step. A whole body PET/CT study, from the skull base to the mid-thigh level, was performed 1h after intravenous injection of 4MBq/kg of FDG. Non enhanced CT scan images were obtained, using 120kV and 100mAs attenuation correction.

Slice : 3,75mm;

PDL: 828mg/cm.

Results: We report ten cases of tuberculosis, including three cases of disseminated tuberculosis mimicking metastatic cancer.

In general, in patients with high 18F-FDG uptake it is difficult to differentiate between malignancy, HIV infection and TB.

Data on 18F-FDG-PET imaging in patients suffering from tuberculosis are very limited.

Pulmonary TB commonly causes an increase in 18F-FDG uptake, whereas uptake is low in tuberculosis pleural effusion. The site of extrapulmonary TB can be detected with 18F-FDG-PET, in disease involving the central nervous system, and joint and bone TB.

Several authors have shown that 18F-FDG uptake continues to increase over time in malignant lesions, whereas in inflammatory lesions uptake decreases or remains stable.

However, studies conducted to assess the potential impact of double phase 18F-FDG-PET versus routine staging in patients suffering from TB confirmed that it is extremely difficult to distinguish TB from

malignant involvement. ¹⁸F-FDG-PET has a high sensitivity for infection and inflammation but poor specificity. One approach that may increase the diagnostic accuracy of PET for tuberculosis includes the combined use of F-18 FDG and ¹¹C acetate, as the latter accumulates in tumours but not in inflammatory lesions. Thus, ¹¹C acetate may help differentiate inflammation from neoplasms.

Conclusion: Due to the high prevalence of TB in Morocco, false positive cases during oncology workup with ¹⁸F-FDG-PET/CT are commonly encountered in practice.

In future, new more specific radiotracers, like positron emitting labeled anti tuberculosis drugs may help in differentiating TB from cancer and inflammatory process not associated with TB.

IAEA-CN-232/116

**Use of Radium-223 in the Treatment of Bone Metastasis
Secondary to Castration Resistant Prostate Cancer and Initial
Experience in 1 Centre in Mexico**

G. Estrada, J.L. Criales

C.T. Scanner del sur

Corresponding Author: dragiselaus@yahoo.com

Background: Xofigo® is a radiotherapeutic drug indicated for the treatment of patients with castration-resistant prostate cancer, with symptomatic bone metastases.

Radium-223 (dichloride) has a half-life of 11.4 days. The dose regimen of Xofigo is 50 kBq (1.35 microcurie) per kg body weight, given at 4 week intervals for 6 injections.

Radium-223 mimics calcium and forms complexes with the bone mineral hydroxyapatite at areas of increased bone turnover, such as bone metastases. The high linear energy transfer of alpha emitters (80 keV/micrometre) leads to a high frequency of double-strand DNA breaks in adjacent cells, resulting in an anti-tumour effect on bone metastases. The alpha particle range from radium-223 dichloride is less than 100 micrometres (less than 10 cell diameters) which limits damage to the surrounding normal tissue.

Methodology: The efficacy and safety were evaluated in a double-blind, randomized, placebo-controlled phase 3 clinical trial. Patients with visceral metastases and malignant lymphadenopathy exceeding 3 cm were excluded. The primary efficacy endpoint was overall survival.

Results: A statistically significant improvement in patients receiving Xofigo (p-value 0.00185), with a median survival of 14 months, compared to 11 months in patients receiving placebo was revealed.

Before the first administration of Xofigo, the absolute neutrophil count (ANC) should be $\geq 1.5 \times 10^9/L$, the platelet count $\geq 100 \times 10^9/L$ and hemoglobin ≥ 10 g/dL. Before subsequent administrations of Xofigo, the ANC should be $\geq 1 \times 10^9/L$ and the platelet count $\geq 50 \times 10^9/L$. If there is no recovery to these values within 6 to 8 weeks, Xofigo should be discontinued.

The most common adverse reactions ($\geq 10\%$) were nausea, diarrhea, vomiting, and peripheral edema. As an adverse reaction, grade 3-4 thrombocytopenia was reported in 6% of patients. Erythema, pain, and edema at the injection site were reported in 1% of patients.

Radium-223 is not metabolized; fecal excretion is the major route of elimination.

The six-stage-decay of radium-223 to stable lead-207 occurs via short-lived daughters, and is accompanied predominantly by alpha emissions. There are also beta and gamma emissions with different energies and emission probabilities. The fraction of energy emitted from radium-223 and its daughters as alpha-particles is 95.3% (energy range of 5 -7.5 MeV). The fraction emitted as beta-particles is 3.6% (average energies are 0.445 MeV and 0.492 MeV), and the fraction emitted as gamma-radiation is 1.1% (energy range of 0.01 -1.27 MeV). The gamma radiation associated with the decay of radium-223 and its daughters allows for the radioactivity measurement of Xofigo and the detection of contamination with standard instruments.

We will present the first clinical experience with the use of Xofigo in patents with prostate cancer in Mexico. The follow up will be with ^{18}F -NaF PET/CT or bone gammagraphy.

Conclusions: The use of radiotherapeutic drugs for the treatment of symptomatic bone metastases is a new watershed for nuclear medicine physicians.

IAEA-CN-232/117

Analysis of the Usefulness of the Acquisition of PET/CT with 18F-FDG in Dual Time Point

J. Gómez ¹, J. Serna ²

¹Hospital general naval

²Hospital Naval

Corresponding Author: j_r_gg@hotmail.com

Background: The utility of 18F-FDG PET/CT has been demonstrated in tumour pathology. However it is also well known that 18F-FDG is not a radiotracer specific for tumour activity, since the physiological metabolically active tissue and inflammatory and infectious processes can have tracer uptake intense as a tumour lesion, which is a common cause of false positives, decreasing the specificity of the study and its positive predictive value.

There have been many reports about dual images with 18F-FDG PET, the authors have noted that tumours have increased even 12% in SUV between the first and second study. On the contrary, benign lesions show a steady uptake of FDG or a slight decrease as time passes.

However, there are also studies that have shown significant overlap of the FDG uptake patterns between benign and malignant lesions, indicating the low or no use of dual images in time.

The purpose of this study is to summarize our experience in the utility of this modality study, coupled with a review of the literature.

Methodology: Design and general study: prospective, descriptive and cross-sectional. 54 patients were included in this study (30 women, 24 men; mean age 68 years; age range 4-87 years). Patients with suspected or confirmed malignant tumours (newly diagnosed, recurrent or metastatic) were referred to the realization of the PET/CT study with 18F-FDG. Thirty eight patients had confirmed diagnosis of malignant tumours, which included 5 patients with renal cancer, 9 breast cancer, 6 prostate cancer, 6 colorectal cancer, 4 cervical cancer, 3 with gastric cancer, and 5 with ovarian cancer. Of fourteen patients referred with suspected malignancy, seven proved with benign pathology. Of the remaining seven, 2 patients had colorectal cancer, three breast cancer and two cervical cancer.

Results: Diagnostic value of the study in 54 patients with 126 lesions which were suspected malignant disease:

	Semiquantitative evaluation	
	Initial Screen (%)	Late Image (%)
Sensitivity	77.3 (75/97)	95.8 (93/97)
Specificity	68.9 (20/29)	68.9 (20/29)
VPP	91.4 (75/82)	92.0 (93/101)
VPN	55.5 (20/36)	86.9 (20/23)
Accuracy	75.4 (95/126)	89.6 (113/126)

Conclusions: The acquisition of 18F-FDG PET/CT images in dual form shows an increase of SUV and varies according to levels of G6P activity and tumour neovascularization.

According to the data found, rather than recommending dual imaging, a late acquisition of 18F-FDG PET/CT is suggested to increase background-tumour contrast.

Performing only late images facilitates the detection of more lesions and better characterization, which increases the sensitivity of the study avoiding often invasive diagnostic procedures and giving the patient a more opportune diagnosis, which affects their treatment and prognosis.

IAEA-CN-232/118

**Comparison and Correlation of 18f FDG PET/CT,
Operative and Histopathological Findings in Gall Bladder
Cancer - An Initial Experience**

J. Das¹, S. Ray², S. Banerjee³, S. Sinha⁴, P. Roy⁵

¹ Consultant, Nuclear Medicine, Tata Medical Center, Kolkata, India

² Consultant, Nuclear Medicine, Tata Medical Center, Kolkata, India

³ Consultant, Surgical Oncology, Tata Medical Center, Kolkata, India

⁴ Statistician, Tata Medical Center, Kolkata, India

⁵ Consultant, Dept of Oncopathology, Tata Medical Center, Kolkata, India

Corresponding Author: drjayantadas@yahoo.co.in

Background: The aim of this study was to evaluate the effectiveness of 18F-FDG PET-CT in pre-operative staging and assessment of the operability in patients with gall bladder cancer.

Methodology: 40 patients (13 males and 27 females, age range between 30 to 74) histopathologically, clinically and radiologically diagnosed with carcinoma of gall bladder had undergone contrast enhanced 18F-FDG PET-CT before curative or explorative surgery, ranging from staging laparotomy to radical cholecystectomy or more extensive partial hepatectomy and multivisceral resection. Meticulous lymph node dissection was carried out in indicated patients with complete clearance of N1 and N2 level nodes. Suspicious lymph node stations were recorded and frozen section analysis was done as required. Mean interval between PET-CT and surgery was 24.6 (0 – 86) days. Median lymph node harvest was 14.87 (1-29). Sensitivity, specificity and accuracy of PET scan and operative findings as compared with histopathology were analysed under separate headings of primary lesion, locoregional lymph node (N1), distant lymph node (N2---celiac, SMA, retropancreatic and para-aortic nodes) and metastatic lesions.

Results: Among the 40 patients, eligible patients available for analysis were 32 for primary lesion, 29 for regional lymph nodes (N1) and distant lymph nodes (N2) and 17 for metastatic lesions. Analysis of data shows good correlation between PET-CT imaging, intraoperative findings and histopathological reports. The results are tabulated below under separate subheadings.

- 18F-FDG PET-CT findings in primary lesions are in agreement with histopathology report in 75% patients and with intraoperative findings in 82% cases.
- 18F-FDG PET-CT findings in regional lymph nodes are in agreement with histopathology report in 72% patients and with intraoperative findings in 86% cases.
- 18F-FDG PET-CT findings in distant lymph nodes are in agreement with histopathology report in 93% patients and with intraoperative findings in 82% cases.
- 18F-FDG PET-CT findings in metastatic lesions are in agreement with histopathology report in 53% patients and with intraoperative findings in 58% cases.

The sensitivity, specificity and predictive accuracy of PET-CT scan and the operative findings are as

follows:

	N	Sensitivity (%)		Specificity (%)		Accuracy (%)	
		PET	Operative	PET	Operative	PET	Operative
Primary lesion	32	85	100	68	68	75	81
N1	29	38	63	86	76	72	72
N2	29	100	100	93	79	93	80
Metastasis	17	25	87	78	0	53	41

Conclusion: 18F-FDG PET-CT appears to be a very effective and useful investigation in pre-operative staging and assessment of the operability in patients with gall bladder cancer. High degree of correlation has been observed with intra-operative findings and histopathology report. 18F-FDG PET-CT has high specificity and accuracy for N2 level lymph nodal disease, which has an impact on operative planning and overall outcome. A higher number of studies will help to reach a robust conclusion.

IAEA-CN-232/119

**Asian School of Nuclear Medicine – An Emerging Platform
of Nuclear Medicine Education**

M.M. Hasan, F. Nasreen

National Institute of Nuclear Medicine Allied Sciences, BAEC, Dhaka, Bangladesh

Corresponding Author: drhasan_m@yahoo.com

Background: The history of modern nuclear medicine is considered for the last 75 years only but the actual history may be 2400 years old! Credit for early nuclear medicine may be given to two ancient Greek philosophers, Democritus and Hippocrates who lived between 460 and 370 BC. Democritus made theories that led to the discovery of radioactivity and Hippocrates formulated the basics of practicing medicine according to rules and ethics. The fusion of these two theories may be the first step of nuclear medicine specialty.

We have seen rapid development of nuclear medicine in the last few decades. Many new radiopharmaceuticals have been developed for both diagnostic and therapeutic use in nuclear medicine. A revolution has also occurred in nuclear medicine instrumentation. From Anger camera we have moved to positron emission tomography (PET) with fusion technology like PET-CT or PET-MRI.

Nuclear medicine is unique compared to other specialties or branches of medical science. However, promotion of nuclear medicine is not homogeneous throughout the world. In North America and Europe nuclear medicine is contributing significantly. The growth of nuclear medicine in those countries is also tremendous. But the situation is different in Asia. Except for Japan, other countries in Asia are far behind American or European countries in nuclear medicine activities. Very recently, Republic of Korea and China are coming along, but the rest of Asia has a long way to go.

Methodology: For promotion and development of nuclear medicine practice and scientific activities in developing countries of Asian region, a new organization ‘Asian Regional Cooperative Council for Nuclear Medicine’ (ARCCNM) was formed in February 2001. The newly formed council felt the necessity of educational activities for promotion of nuclear medicine in the region and a school named ‘Asian School of Nuclear Medicine’ (ASNM) was founded in February 2003 in Dhaka with Dr. Felix Sundram as its first Dean.

Result: Like the European School of Nuclear Medicine (ESNM) which was founded in 1997, ASNM also started its activities in organizing or accrediting the national seminars and training programmes in the region. However, in less than 10 years ASNM has emerged as a very vibrant organization when Prof. Gang Huang from China took the office as its 4th Dean. The school, in collaboration with AOFNMB & ARCCNM, organized the first Asian Nuclear Medicine Board (ANMB) examination in November 2014 in Osaka, Japan where 26 young nuclear medicine physicians from different countries of Asia got fellowship of ANMB. ASNM has now three permanent campuses - in Osaka, Shanghai and Seoul.

Conclusion: ASNM is emerging as a new platform for nuclear medicine education. It is hoped that in near future the school will be the centre of attraction not only for Asia but also for other continents of the world.

IAEA-CN-232/120

MICADO - A New Collimator Concept and Device for Clinical Nuclear Medicine Imaging

H. Poláček¹, R. Kaštl², I. Režňák¹, P. Kamencay³, Z. Pšenáková⁴

¹ Klinika nukleárnej medicíny UNM a JLF UK, Martin, Slovakia

² REC Slovakia s.r.o., Žilina, Slovakia

³ Katedra telekomunikácií a multimédií EF ŽU, Žilina, Slovakia

⁴ Katedra teoretickej elektrotechniky a biomedicínskeho inžinierstva EF ŽU, Žilina, Slovakia

Corresponding Author: h.polacek@seznam.cz

Background: Since powerful computers became widely available in medical research, several new collimator designs for single-photon imaging of small organs/regions were developed and implemented into the modern commercially available products, dedicated mostly to myocardial imaging. Multi-pinhole principle is one of the few providing emission scans with very low level of multiplexing of input information.

Methodology: In present study we show the original proposal and first tests of clinical collimator and its accessories. Our "MICADO" (multi-intersectional-controlled-aperture-dynamic-output) concept expands the key principles of multi-pinhole collimation to obtain variable, effective and easily manufactured product, which can be connected to most existing gamma-cameras independent on their detector types. Main components were manufactured in-house from material of the Radiation Oncology Department of our hospital put out of service. Basic optical characteristics were measured using different types of phantoms and compared with the output of commercial parallel-hole system. Monte Carlo simulations were used to verify measured data and optimize both calibration procedures and image reconstruction algorithms.

Results: MICADO device is superior in both sensitivity and resolution parameters compared to routinely used parallel hole collimators. The lack of mechanical motion during SPECT acquisition further reduces the system complexity and many common potential image artefacts typical for rotational techniques.

Conclusions: The main advantages of new imaging concept and the steps leading to its clinical implementation in Slovak nuclear medicine practice are discussed.

IAEA-CN-232/121

**Evaluation of the Role and Incremental Value of
18F-Fluoro Deoxyglucose PET/CT in Diagnosis of
Carcinoma of Unknown Primary**

A. Jain, P. Pankaj

Department of Nuclear Medicine and PET CT, Mahajan Imaging Centre, and
Ganga Ram Institute for Postgraduate Medical Education and Research
(GRIPMER), Sir Ganga Ram Hospital, Old Rajinder Nagar, New Delhi-
110060, India

Corresponding Author: dr.anjalimittal@yahoo.co.in

Background: Carcinoma of unknown primary (CUPs) ranks as the seventh most frequent type of cancer in the world and the fourth most common cause of cancer deaths which represents both a diagnostic and management challenge. While histopathologic analysis frequently provides hints as to the location of the primary site, not all tumours are identified despite a comprehensive diagnostic workup. Through imaging with CT/MRI and tumour markers the primary can be detected only in 20-27% and even at autopsy the primary site is detected in only 30-62% of patients. The present study is planned to evaluate the efficacy of 18F-FDG PET/CT scans in detecting occult primaries in patients with CUPs.

Methodology: We studied 62 patients with CUPs (35 men and 27 women; mean age of 51-years with a range 32-85 years). The patients were examined by 18F-FDG PET/CT and the results were correlated with standard reference, diagnostic tests and therapeutic response.

Results: Overall detection rate of primary tumour in CUPs by PET/CT was found to be 29 (47%) patients out of which 20 (32%) were found to be true positive on subsequent biopsy and targeted treatment response.

In our study, 9 out of 62 (14%) cases show false positive results; 3 cases were in the head and neck region, 3 in gastro-intestinal region, two were in the breast and one in the bladder. There were two false negative cases; one in which a thickening in the right **aryepiglottic fold** was not picked up by PET/CT, and in the other HCC was diagnosed later on high clinical suspicion and raised AFP levels but was not picked up by PET/CT. These two cases out of 62 form about 3% and review of other studies revealed a false negative rate between 5 to 8 %.

Sensitivity of the PET-CT in our study was 91%, while review of other studies revealed sensitivity ranging from 67 to 100%. Specificity of PET-CT in our study was 78% and review of studies by other authors showed specificity of PET-CT ranging from 56 to 79%.

The positive predictive value (PPV) and negative predictive value (NPV) of our study was 69 % and 94 % respectively, while it ranged between 33 to 88% and 50 to 100% respectively.

Conclusions: In our study, 18F-FDG PET-CT has proved to be a valuable diagnostic tool in patients with CUPs, because it detected the unknown primary tumour in about one third of all patients investigated, and it has a high sensitivity and specificity in detecting primary tumours. In addition, it assists in both guiding biopsies for histologic evaluation and selecting the appropriate treatment protocols and targeted approach in these patients.

IAEA-CN-232/122

Semiquantitative Analysis of Early 18F-FDG PET/CT in Patients with Diffuse Large B-cell Lymphoma, Mantle Cell Lymphoma and Follicular Lymphoma

L. Henzlová¹, J. Marcinková¹, Z. Kapitáňová², P. Koranda¹, M. Mysliveček¹, T. Papajík², E. Buriánková¹

¹Department of Nuclear Medicine, University Hospital Olomouc

²Department of Haematology, University Hospital Olomouc

Corresponding Author: henzlova.lenka@centrum.cz

Background: Diffuse large B-cell lymphoma (DLBCL), mantle cell lymphoma (MCL) and follicular lymphoma (FL) belong to a group of non-Hodgkin's lymphomas which is highly curable nowadays. Nevertheless, a part of the patients does not respond to the therapy or relapse soon after its completion. Many studies suggest that interim 18F-FDG PET/CT performed after 2 or 3 cycles of chemotherapy is a valuable tool for early therapy response monitoring.

Methodology: We studied a group of 86 patients, 43 men and 43 women, median age 57 years (range 22 – 76) with newly diagnosed and histologically proven DLBCL (62), FL (14) and MCL (10). All patients underwent contrast enhanced 18F-FDG PET/CT examination before and after 2 cycles of chemotherapy. Deauville criteria and percentual change of SUVmax overtime between the two scans (Δ SUVmax) were used for evaluation. Disease-free survival (DFS) was chosen as an endpoint and data were censored if the patients were free of progression or relapse at the last follow-up. To assess significance of the above mentioned criteria for DFS prediction, Kaplan-Meier analysis and Cox regression analysis were used.

Results: During a follow-up period 70 patients (81,4%) were in complete remission, whereas the remaining 16 patients (18,6%) relapsed or progressed. Mean DFS in a group with score 1-3 according to Deauville criteria was significantly longer - 5,1 years vs. mean DFS in a group with score 4-5 which was 3,6 years ($p=0,013$). Cox regression analysis showed that Δ SUVmax is significant for DFS prediction with $p=0,001$.

Conclusion: Our findings indicate that both methods – Deauville criteria and Δ SUVmax - seem to have good prognostic value and can be useful in predicting the risk of relapse or progressive disease during the follow-up with sufficient reliability in patients with non-Hodgkin's lymphomas. Refinement by taking different histologic subtypes or treatment regimes distributively may be required.

IAEA-CN-232/123

**RhTSH Stimulated 18F-FDG PET/CT in Patients
with Thyroid Carcinoma**

J. Marcinkova, H. Polzerová, L. Henzlová, P. Koranda

University Hospital in Olomouc

Corresponding Author: jana.marcinkova@fnol.cz

Background: 18F-FDG uptake by differentiated thyroid carcinoma has been confirmed to be stimulated by TSH since GLUT-1 expression and glucose transport is affected, and therefore 18F-FDG PET under TSH stimulation is more accurate than under TSH suppression. In our study we used rhTSH (thyrotropin alfa) to stimulate either thyroid cancer remnants or metastatic foci before 18F-FDG PET/CT in patients with thyroid cancer who had undergone thyroidectomy previously. In patients with positive PET/CT scans we monitored the change of therapeutic strategy based on these findings.

Methodology: A total of 17 patients (10 females and 7 males) with suspicion of recurrence or metastases of thyroid carcinoma and with negative, or in 3 cases positive, 131I whole-body scans underwent rhTSH stimulated contrast enhanced 18F-FDG PET/CT (400 MBq 18F-FDG/70 kg body weight). The suspicion was based on elevated thyroglobulin (Tg) level (9 patients), T4 (TNM) stage (4 patients) or elevated antithyroglobulin antibodies (anti-TG) level (4 patients). Patients were divided into 3 subgroups according to the level of Tg: 1. Tg < 10 µg/L but with elevated anti-TG or T4 stage (8 patients), 2. 10 µg/L < Tg < 50 µg/L (4 patients), 3. Tg > 50 µg/L (5 patients).

Results: Among the whole group of 17 patients, rhTSH-stimulated contrast-enhanced 18F-FDG PET/CT scan was positive in 10 patients – in all 5 patients in the group of Tg > 50 µg/L, in 3 out of 4 patients with 10 µg/L < Tg < 50 µg/L and in 2 out of 8 patients with elevated anti-TG or T4 stage. There was a direct impact on therapeutic strategy in all PET/CT positive patients. The surgical removal of tumour tissue was performed in 5 cases (recurrence of thyroid carcinoma was histologically confirmed in all cases), 4 patients were considered as inoperable due to a previously unknown metastatic spread and 1 patient underwent rhTSH-stimulated 131I therapy subsequently (non-radioiodine avid lesions were excluded).

Conclusion: This study shows that 18F-FDG PET/CT under rhTSH stimulation identified recurrence or metastases of thyroid carcinoma in combination with elevation of Tg levels efficiently. Frequency of positive PET/CT findings depends on elevation of Tg level; nevertheless the number of positive findings in the subgroup of patients with low Tg is not negligible. It could be concluded that rhTSH-stimulated 18F-FDG PET/CT can be an efficient diagnostic tool in patients with thyroid carcinoma and has a significant impact on therapy.

IAEA-CN-232/125

**Association of Biological and Technical Factors with
Extreme Values of SUV in 18F-NaF PET/CT Studies**

**R. Moreira, P. Schiavom Duarte, G. Barberio Coura Filho,
George, G. Carvalho, M. Tatit Sapienza, C.A. Buchpiguel**

Hospital das Clínicas da Faculdade de Medicina da Universidade de São Paulo
- HCFMUSP

Corresponding Author: r.moreira@hc.fm.usp.br

Background: The objective of this study was to evaluate the association of biological and technical factors with extreme standardized uptake value (SUV) on 18F-NaF PET/CT studies.

Methodology: SUVs were obtained in volumes of interest (VOIs) in proximal diaphyseal regions of the right humeral diaphysis (HD) and right femoral diaphysis (FD) in 705 18F-NaF PET/CT studies. Only regions classified as normal by visual examination of PET and CT and presenting SUVs higher than one standard deviation above the mean or lower than one standard deviation below the mean were included in the analysis (n = 104 and 110, respectively, for HD) (n = 103 and 96, respectively, for FD). Using multivariate logistic regression the association of some anthropometric variables (weight and height), technical parameters of the study (injected activity, mAs and injection-image interval) and the age and sex of patients with the two categories of SUV was evaluated.

Results: Weight and injection-image interval presented a statistically significant positive association (p <0.01) with higher SUVs for the HD and FD VOIs. Male sex and the injected activity presented statistically significant association with higher values of SUV in VOIs in the FD (p <0.01), but no association in the VOIs in the HD.

Conclusions: The statistical analysis showed that some biological and technical factors are associated with higher values of SUV on 18F-NaF PET/CT studies. This association should be considered when the SUVs normal range is defined and is also fundamental to classify the values as normal or abnormal.

IAEA-CN-232/126

**Value of FDG PET/CT in Staging and Prognosis of
Primary Esophageal Cancer**

L. Nguyen

Cho Ray hospital

Corresponding Author: nguyenhoangaily225@gmail.com

Background: 18F-FDG PET/CT has been extensively used in diagnosis and follow-up of variety of cancers. The aim of this study was to assess the role of 18F-FDG PET/CT imaging in initial staging and prognosis of primary esophageal cancer.

Methodology: A retrospective study included consecutive patients with primary esophageal cancer who underwent 18F-FDG PET/CT imaging from March 2011 to Dec 2014. Staging was classified on PET/CT images. Overall survival time was analysed with various factors, such as age, lymph node metastasis and overall stage.

Results: Forty eight patients with esophageal cancer were enrolled. One female and 47 male patients had mean age of 58.0 years (range from 42 to 76). The histologic subtype was squamous cell carcinoma in 47 patients and adenocarcinoma in 1 patient. 18F-FDG PET/CT showed 7 patients with stage IA-IIA, 20 with stage IIB-IIIC, and 21 with stage IV according to stage definition by AJCC 7th edition. The common distant metastases included distant lymph nodes (15 cases), lung (5 cases), bone (4 cases), liver (3 cases) and adrenal (1 case).

Thirty eight of 48 patients were followed-up for survival status. Twenty one patients died during a median follow-up time of 6 months (range, 1 - 18 months) and 17 patients were alive with a median follow-up time of 10 months (range, 2 - 27 months). Kaplan-Meier analysis revealed that overall survival was only correlated with overall stage (stage IV vs. stage I-III) significantly ($p=0.047$). Median survival time was 7 months for patients with stage IV compared to 18 months for those with stage I-III. Age and lymph node metastasis were not correlated with overall survival with p value of 0.41 and 0.34, respectively.

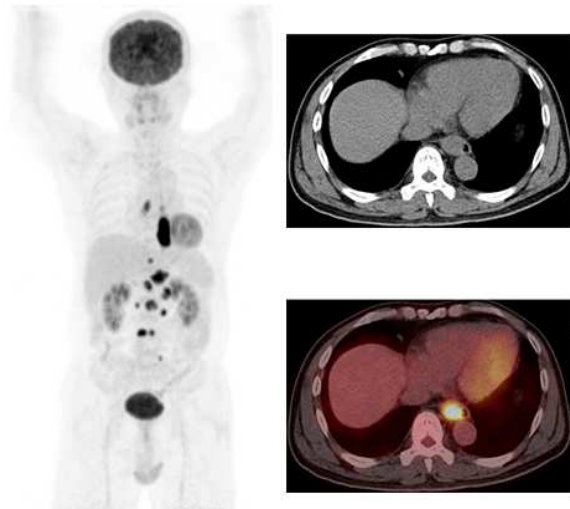


Figure 1. Esophageal cancer with metastasis to the mediastinal and abdominal lymph nodes.

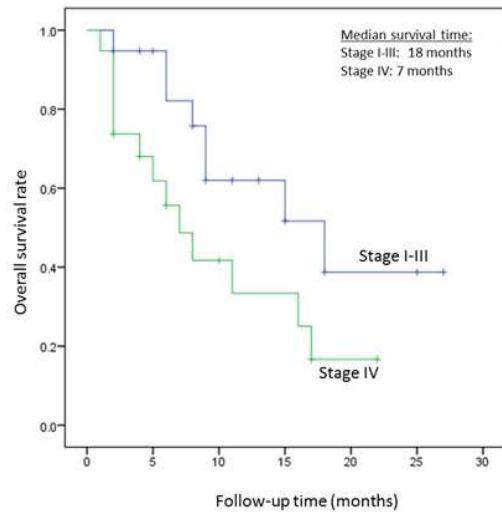


Figure 2. Overall survival curves based on stage

Conclusion: 18F-FDG PET/CT may be valuable in initial staging and provide significant prognosis in primary esophageal cancer.

IAEA-CN-232/127

Nuclear Medicine Education in Pakistan - Past, Present and Future

S. Saeed

Pakistan Institute of Engg Applied Sciences, PAEC

Corresponding Author: shabana_saeed@yahoo.com

Background: Nuclear Medicine (NM) services in Pakistan started in 1962 with the establishment of nuclear medicinal centre in Karachi by the Pakistan Atomic Energy Commission (PAEC). Over the years, more NM centres were established throughout Pakistan. Presently there are 49 NM facilities working under PAEC and other public and private sectors.

In order to fulfil the demand of highly trained manpower for these nuclear medical centres, initially, doctors were sent abroad for training. With the expansion of nuclear medicine services in Pakistan, the demand for nuclear physicians increased. To overcome the dearth of nuclear physicians, two years masters (MS NM) programme was initiated at Pakistan Institute of Engineering & Applied Sciences (PIEAS) in 1988. PIEAS is a multidimensional public sector university working under the umbrella of PAEC. Academic programmes are being conducted at the highest level in a broad spectrum of disciplines, providing major human resource for different programmes of PAEC since 1967.

Methodology: The MS(NM) is designed to provide medical doctors with a thorough grounding in the principles and applications of nuclear medicine. It also equips them with the necessary tools for carrying out meaningful research in this field. MS(NM) is divided into two major segments of one year each. The first year is devoted primarily to course work at PIEAS. During the second year, students do clinical training and research projects at various NM centres. Because of the very close association and involvement of several of the leading international experts in the design and implementation, it has a high degree of visibility and acceptance in the international academic domain. Until now, 151 nuclear physicians have graduated. Among the graduates there were students from the Middle East, South East Asia and Africa. Some of the students were sponsored by IAEA.

In 1996, College of Physicians and Surgeons Pakistan (CPSP) started a fellowship in NM (FCPS). This is a 4 years training programme with no course work. Until now, 25 MSc (NM) graduates from PIEAS, along with 5 other doctors have passed FCPS (NM).

Results: Over the past few years, nuclear medicine is under transition throughout the world. With the advent of hybrid imaging (PET/CT, SPECT/CT etc.), training in cross-sectional imaging has become of utmost importance to the nuclear medicine physicians. Realizing this fact, Department of Medical Sciences, PIEAS is in the process of launching a 4 years MD programme in Nuclear Medicine and Molecular Imaging. The main objectives of this programme are 1) To provide the doctors with extensive clinical, research and communication skills in nuclear medicine and molecular medicine. 2) To keep the nuclear physicians abreast with the latest developments in various fields of molecular imaging 3) To provide a multidisciplinary approach to the nuclear physicians to diagnose a disease by training in various fields of cross-sectional medical imaging. It is expected that this programme will be launched very soon. This will not only meet the future needs of Pakistan but will be able to help in meeting the regional demands.

Conclusion: Nuclear medicine has advanced a lot in Pakistan over the past 50 years, owing to educational efforts undertaken in this discipline.

IAEA-CN-232/129

**Yttrium-90 Radioembolization as an Emerging
Locoregional Therapy for Unresectable Hepatocellular
Carcinoma and Hepatic Metastases from Various Solid
Tumours: a Single-Centre Experience of 30 Patients**

K. Vankadari, P. Pankaj

Sir Gangaram hospital, old rajendar nagar, New Delhi-110060

Corresponding Author: kousik43@gmail.com

Background: Hepatocellular carcinoma (HCC) is the sixth most common cancer and third leading cause of cancer-related death in the world. The management of unresectable, chemorefractory HCC and hepatic metastases from various solid tumours is a clinical dilemma. There is paucity of data on the treatment of unresectable, chemoresistant HCC and hepatic metastases with yttrium-90 (Y90) radioembolization.

Methodology: Thirty patients comprising 21 patients with HCC (12 patients had cirrhosis of which 3 patients belonged to Child-Pugh class A and 9 patients belonged to Child-Pugh class B), 7 patients with metastasis from colorectal cancer, 1 patient with metastasis from melanoma and 1 patient with metastasis from ovarian carcinoma underwent resin-based Y90 radioembolization between 2012 and 2014 in a single institution. In all the patients after embolization of non-target vasculature, SPECT and plain scintigraphy were done with the injection of 5–6 mCi (185–222 MBq) of ^{99m}Tc-labeled MAA into the hepatic artery. Then lung shunt fraction was assessed and dose was calculated based on BSA method for sir spheres. Side effects following therapy were noted in all the patients. All patients were followed up with triphasic CT of the liver 3 months following therapy. Radiologic response was evaluated with the necrosis criteria used for therapy response assessment in solid tumours. Then survival time following therapy was assessed in all the patients telephonically.

Results: On follow-up, twelve patients (40%) developed minor side effects following treatment and resolved without active intervention. The most common side effects include mild abdominal pain (38%), nausea (28%), and fatigue (22%). On follow-up imaging at 3 months following treatment, a complete response was observed in two patients (7 %), partial response in 7 patients (23 %), stable disease in 15 patients (50 %), and progressive disease in 6 patients (20 %). A total of 17 patients have died till date due to tumour related cause.

Conclusion: This study provides supportive evidence of the safety and efficacy of Y90 radioembolization for the treatment of unresectable, HCC and hepatic metastases. Thus Y90 radioembolization is proving to be promising treatment with average disease control rates around 80%.

IAEA-CN-232/130

Status of PET CT in Romania

M.R. Mititelu, V.C. Mazilu

Central University Emergency Military Hospital

Corresponding Author: ralunuclear@yahoo.com

Background: With a population of 22 million people Romania is one of the largest countries in Eastern Europe. Nuclear medicine was introduced as diagnostic and therapeutic technique in Romania in the late 1950s and has evolved as independent specialty in 1992. Introduction of PET-CT in Romania was a difficult process, mainly because of the cost of equipment, lack of medical cyclotrons at the beginning and reimbursement issues.

Methodology: In this paper we have reviewed the main steps that were made in Romania with implementing PET-CT in the medical system and in the management of oncologic patients. Data were collected from websites of each PET-CT centre, from the Romanian Society of Nuclear Medicine and from the National Insurance Company website.

Results: First PET-CT scanners were installed in the private sector in 2008, in Bucharest and Oradea. The number of procedures and requests increased continuously.

The installation of a cyclotron and a unit of ¹⁸F-FDG production in a private facility were followed by an increase in PET-CT projects both in private but also in public hospitals. At present there are 5 PET/CT scanners installed in the private sector (2 in Bucharest, 1 in Oradea, 1 in Cluj-Napoca and 1 in Constanta) and 2 in public hospitals (one in Bucharest and one in Craiova). On the other side, this year there are at least 3 more projects where PET-CT scanners are expected to be installed.

First cyclotron in public system was installed in Horia Hulubei IFIN Institute in Magurele, near Bucharest, which has developed many projects with the IAEA. At this facility production is expected to start soon, the main advantage being the possibility of obtaining more radiopharmaceutical compounds beyond ¹⁸F-FDG.

In May 2010 National Insurance Company approved reimbursement of PET-CT procedures for many oncologic indications. Since 2010 there was an increase in number of indications for reimbursement. There was also a continuous increase in the budget and number of investigations approved for reimbursement on an annual basis.

At present only oncologic indications are included on the list of procedures. None of the centres is performing other studies such as cardiology or neurology. However there are several projects which include installation of PET-CT scanners in some university-related hospitals where new procedures including cardiology, neurology and inflammation will be introduced.

Conclusions: Increased use and widening of PET-CT applications in Romania will require a larger number of nuclear medicine specialists to increase their skills by accessing dedicated courses/trainings. Efforts should be made in this respect, to ensure high quality investigations and improve diagnostic management.

IAEA-CN-232/131

**Diagnostic Accuracy of 18F-FDG and 68Ga-DOTATATE
PET/CT in Detection of Neuroendocrine Tumour: A Meta-
Analysis**

I. Bandong¹, J.R. Bandong²

¹ Philippine Society of Nuclear Medicine

² Faculty of Pharmacy, University of Santo Tomas, Philippines

Corresponding Author: isbandong_md@yahoo.com

Background: Neuroendocrine tumor (NET) is a rare neoplasm with an incidence of about 35 cases per 100,000 people in the United States. The prevalence of NET in the Philippines is 0.8%. NET has different somatostatin receptors.

With recent developments in hybrid and molecular imaging, the detection and localization as well as staging of NET are important in the treatment and management.

The objective of this study was to determine the diagnostic accuracy of 18F-FDG and 68Ga-DOTATATE PET/CT in the lesion detection among patients with neuroendocrine tumor.

Methodology: We searched the Medline for literature from January 2005 to December 2014. Articles meeting the eligibility criteria were collected and reviewed by two independent reviewers. Data were extracted independently. Pooled sensitivity, specificity, positive and negative likelihood ratios were obtained.

Results: From 88 citations identified, 10 relevant articles were selected. Only 2 fulfilled all the inclusion criteria and presented data on the lesion based analysis. The overall pooled sensitivity of 18F-FDG PET/CT and 68Ga-DOTATATE PET/CT was 64.3% (95% CI: 50.36 to 76.64%) and 82.14% (95% CI: 69.60% to 91.08%) respectively. Positive likelihood ratio of 18F-FDG PET/CT and 68Ga-DOTATATE PET/CT was 0.64 and 0.82 respectively. The sensitivity and likelihood ratio of 18F-FDG PET/CT combined with 68Ga-DOTATATE PET/CT was 91.11% and 0.92 respectively.

Conclusion: 68Ga-DOTATATE PET/CT is more sensitive than 18F-FDG PET/CT in detecting neuroendocrine tumors. However, a combination of these 2 molecular imaging modalities has more utility in the evaluation and staging of NET.

IAEA-CN-232/133

**Focal Increased Activity in the Pancreas on
111In Octreotide scan – could 18 FDOPA PET Scan be
Helpful?**

Z. Kováčová¹, J. Kubinyi², D. Zogala², A. Pudlač³

¹ UNM 1.LF UK Praha

² UNM 1.LF UK a VFN Praha

³ RDG klinika 1.LF UK a VFN Praha

Corresponding Author: zuz.kovac@gmail.com

Background: By using retrospective analysis we tried to determine whether 18F-DOPA PET scan could be helpful in finding the etiology of focal increased activity in the pancreas on 111In Octreotide scan.

Methodology: By analysing 306 111In Octreotide scans and all available clinical data we gained the exact number of the phenomenon of focal increased activity in the pancreas for which there was no explanation. Then we evaluated all available 18F-DOPA PET scans that six of these patients underwent.

Results: Out of 306 111In Octreotide scans there were 73 cases with focal increased activity within the region of pancreas. 40 cases were located within the head of pancreas. For 28 cases there was no explanation identified for the high uptake in the pancreas even after the clinical research. 6 patients out of those 28 underwent 18F-DOPA PET scan as well. Unfortunately, 18F-DOPA PET scan did not provide us with any additional information regarding the pathology within the pancreas.

Conclusion: 18F-DOPA PET scan was not helpful in explaining the etiology of focal increased activity in the pancreas on 111In Octreotide scan. However, it is essential to widen the study group to confirm or disprove our conclusion.

IAEA-CN-232/134

**Present Status of PET-CT and Cyclotron Facilities in
Bangladesh - A Developing Country Profile and Experience**

**M. A. Azim¹, N. Islam², N. Hossain¹, K.A. Quadir², F. Begum³,
T.A. Biman¹**

¹ Senior Scientific Officer

² Chief Scientific Officer

³ Principal Scientific Officer

Corresponding Author: nahidhssn@yahoo.com

Positron emission tomography (PET) combined with computed tomography (CT) is a powerful and very sensitive diagnostic tool that integrates functional and anatomical imaging into one combined scanning system. Nuclear medicine in Bangladesh is a dynamic field where new procedures and techniques are continuously being introduced with the help of the Government and technology transfer obtained through training and workshops in relevant fields and also through technical cooperation with the International Atomic Energy Agency (IAEA).

The first medical cyclotron was installed in Bangladesh in 2011 at the United Hospital, Dhaka. The cyclotron was used mainly for production of PET tracers such as F-18. It is an around 9.6 MeV cyclotron. The first PET-CT was installed in the same hospital that same year. At present, the United Hospital routinely operates the cyclotron two days per week and does the PET-CT study in the same days. At the end of 2011 another PET-CT machine was installed in a different hospital named Medinova Medical Services Ltd (MMSL) and this is the second PET-CT machine in the country. MMSL purchases the PET tracers from United Hospital and they are also doing PET-CT studies regularly.

In Bangladesh, cancer poses a serious health problem and is the leading cause of mortality, and the establishment of a PET-CT facility in government sector has been well-justified. Attempts and efforts to justify and convince the Government regarding its essentiality were successful. But it took a few years for clarifications and settling other issues. The main application of PET-CT is in oncology, and the ideal location for this equipment should be a tertiary level institution dealing with cancer patients. It is critical for the cyclotron to be set up assuring availability of positron-emitters of shorter half-lives beyond F-18. We faced difficulties in selecting the appropriate site for cyclotron. At last the Government decided to establish a cyclotron in the hospital campus. Selection of the type of cyclotron to set-up is also crucial. Initially, we planned to establish a high energy 30MeV cyclotron to produce not only positron-emitters but also SPECT isotopes, but when we faced the reality regarding the expenditure and time for such establishment from vendors and also the IAEA, the decision was revised finally to have a cyclotron of around 16-20 MeV.

At present, one PET-CT was installed in our institute and another PET-CT is going to be installed in another institute within very short time under the Government project. The PET-CT studies are still not regularly conducted due to lacking of ¹⁸F-FDG. Now we are planning to purchase ¹⁸F-FDG from the private cyclotron which was installed in United Hospital.

The site of our cyclotron was prepared and the building is now under construction. The procedure for purchasing cyclotron has been started. The tender has been offered and we expect that we can successfully get our own cyclotron within next year.

IAEA-CN-232/135

SPECT/CT 99mTc-EDDA/ HYNIC-TOC in the Management of Neuroendocrine Tumours

S.E. Bouyoucef, M. Habbeche

Department of Nuclear Medicine CHU Bab El Oued, Algiers Algeria

Corresponding Author: salaedine@yahoo.fr

Background: Incidence of neuroendocrine tumors (NET) is increasing due to the development of diagnostic tools including nuclear medicine techniques, conventional and PET imaging. SPECT/CT 99mTc-EDDA/HYNIC-TOC could be available everywhere and have a great potential in the management of NET.

The objective of this study was to assess the role of SPECT/CT 99mTc-EDDA/HYNIC-TOC in the management of NET.

Methodology: A retrospective study of 110 patients with suspected or confirmed NET was done from 2010 to 2014 in the Department of Nuclear Medicine. Clinical indications were: search of the primary (35%), contribution to the strategy and assessment of therapy (48%), location of the primary site (13%) and search for relapse after surgery (4%). SPECT/CT used was a dual head gamma camera with a diagnostic CT. Double reading of reporting was done systematically for all patients.

Results: In the suspected NET, SPECT/CT 99mTc-EDDA/HYNIC-TOC enabled finding the primary in 14/37 (37%) and confirmed the diagnosis in 12 out of 15 patients. All paragangliomas and pancreatic tumors were positive on SPECT/CT 99mTc-EDDA/HYNIC-TOC. For therapy assessment, SPECT/CT 99mTc-EDDA/HYNIC-TOC contributed to the therapeutic strategy in 80% of patients and showed a poor response to targeted therapy in 3 patients.

Conclusion: Despite the lack of Gallium peptide PET, SPECT/CT 99mTc-EDDA/HYNIC-TOC was determinant with a great clinical impact in the management of neuroendocrine tumors.

IAEA-CN-232/136

Scintimetric Characterization of Skeletal Hot Spots in Carcinoma Prostate

V. Sivasubramaniyan¹, K. Venkataramaniah²

¹ Sri Sathya Sai Institute of Higher Medical Sciences Prasanthigram

² SSSIHL

Corresponding Author: sivasubramaniyan.v@sssihms.org.in

Background: The incidence of skeletal metastasis is very high in patients suffering from carcinoma prostate. The presence of skeletal metastasis is inferred by the presence of multiple lesions, asymmetric distribution and increased tracer concentration. The etiology could be ascertained only by invasive biopsy procedure. A non-invasive scintimetric characterization and evaluation of skeletal hot spots in bone scans of carcinoma prostate patients is highlighted.

Methodology: The bone scan is done 4 and 24 hours after intravenous injection of 15 to 25 mCi of Tc99m Methylene Di-Phosphonate with adequate hydration using the e-cam Siemens dual head gamma camera with e-cam whole body acquisition protocol in 75 patients with biopsy proven carcinoma prostate. Metastatic involvement is seen in 53 patients and is negative in 22. 101 focal hotspots in various sites in 16 patients are characterized using the temporal scintimetric method. Both the 4 and 24 hr bone scan images are selected using the general display protocol. Then with the help of the region ratio processing protocol the 4 and 24 hr anterior and posterior images are selected separately. Maximum counts in the selected regions are then tabulated. Then the 4/24 hr Dr. V. Siva's retention ratio is derived by dividing the 4 hr counts with 24 hr counts along with the Israel's 24/4 hr ratio as well. The results are compared and analysed.

Results: The mean of 4/24 hr Dr. V. Siva's retention ratio is found to be 11.5 +/- 2.8 and that of 24/4 hr Israel's ratio to be 0.08 +/- 0.02. The whole body count ratios of 4/24 hr and 24/4 hr also showed correspondingly similar values.

Conclusion: Scintimetric characterization of the skeletal hot spots provides a non-invasive means for identifying the underlying pathology so as to enable proper management decisions. The 4/24 hr Dr. V. Siva's retention ratio is proved to be useful clinically because of its whole integer value, while the Israel's 24/4 hr ratio is a decimal value. The utility is established by the confirmation of the metastatic nature of the lesion as predicted by the scintimetric characterization and histopathological examination through biopsy of the same.

IAEA-CN-232/137

Prognostic Value of 18F-FDG PET-CT Metabolic Parameters in Small Cell Lung Cancer: A Retrospective Study

C. Pieters, V. Lannoy, D. Hoton, F.X. Hanin

Cliniques Universitaires Saint Luc

Corresponding Author: fx.hanin@uclouvain.be

Background: SUVmax is a common metabolic parameter used as prognostic value in FDG-PET/CT for several cancers in clinical routine. In small cell lung cancer (SCLC), we investigated the prognostic value of SUV, and more complex metabolic parameters such as total lesion glycolysis (TLG) and metabolic tumor volume (MTV) in comparison with several clinical parameters.

Methods: We retrospectively computed SUVmax, SUVmean, TLG, and MTV in 71 consecutive patients with SCLC at initial FDG PET-CT imaging procedure performed in our institution between 2007 and 2014. These parameters were compared with clinical parameters (extended disease, ECOG performance status, weight loss, paraneoplastic syndrome, comorbidities, age, treatment delay, neuron-specific enolase [NSE] level, lactate dehydrogenase [LDH] level) for overall survival (OS) and progression-free survival (PFS) in univariate and multivariate analysis. MTV and TLG were computed using thresholding segmentation with SUV values of 3 (TLG3 and MTV3) and 5 (TLG5 and MTV5).

Results: In univariate analysis, MTV3, TLG3, extended disease, ECOG status, weight loss, age, cardiovascular comorbidities, paraneoplastic syndrome, NSE, LDH, treatment delay were significant predictors of OS. In multivariate analysis, ECOG status ($p < 0.001$, HR 3.103, 95%CI [1.966-4.896]) and TLG3 ($p = 0.001$, HR 3.316, 95%CI [1.607-6.841]) were the only independent predictors of OS. For PFS, ECOG status, extended disease, paraneoplastic syndrome, NSE, treatment delay, and MTV3 were significant predictors in univariate analysis. Multivariate analysis showed that paraneoplastic syndrome ($p < 0.001$, HR 8.245, 95%CI [2.660-25.555]) and MTV3 ($p = 0.002$, HR 3.604, 95%CI [1.586-8.186]) were the only independent predictors of PFS.

Conclusion: TLG3 and MTV3 computed at initial FDG PET-CT in addition to clinical parameters are independent predictors of OS and PFS in SCLC. Interestingly, SUVmax and SUVmean, however used in daily routine, were not predictors of OS nor PFS.

IAEA-CN-232/138

**An Example of a Standardization Methodology Applied to
Bone Imaging, within the Auspices of the Quality
Management System**

**E. Lemos Pereira, M. Fernandes, A. García, L. Oliveira, P.
Colarinha**

NuclearMed

Corresponding Author: edgar.lemos.pereira@gmail.com

Background: As a quality management system certificated department for nuclear medicine examinations, it is of our interest to optimize and systematize procedures. Bone scintigraphy represents more than 20% of our examinations.

According to EANM guidelines, the whole body (WB) scan speed should be adjusted so that anterior and posterior views contain at least 1,5MCts each.

In 2008, we found a very easy method for adjusting the WB bone scan speed according to the counts rate measured in the posterior view of the scan's starting position.

The aim of this work was to evaluate the long-term impact of this methodology, regarding dose reduction and scan speed optimization.

Methodology: We used a sample of 260 patients undergoing bone scintigraphy, injected with 730+/-40MBq of 99mTc-MDP. We found a positive and very high correlation between the counts rate on WB posterior view starting image and the WB scan total counts. Then, we constructed a graphical representation that correlates the posterior view counts rate of the WB starting image with the scan speed, in order to obtain at least 1,5MCts.

For this work, we used 106 consecutive patients and compared data with 2008 results: WB starting position counts rate and total counts. We also compared administered activity, scan speed and the number of scans per hour. Data was statistically analysed by EXCEL and SPSS.

Results: Although injected activity and average scan speed was similar in 2008 and 2014, the productivity (number of scans/hour) has significantly increased after the 2008 study: from 2.2 to 3.2 scans/hour.

There was no significant difference between both counts rate and total counts form 2008 and 2014.

Conclusion: Quality management system enables moving towards procedures standardization. Nevertheless, it is very important to note that standardization does not mean overgeneralization. When dealing with health care, especially within radiation area, it is crucial to optimize and adjust procedures to individual patient's requirements and characteristics.

Since 2008, we are using an easy and fast method to adjust scan speed to patient's counts rate, aiming to obtain a quality acquisition, according to European guidelines.

This work allowed us to state the advantages of implementing an optimization policy, because it permits incrementing cost-effectiveness and can enable dose reduction.

IAEA-CN-232/140

**Ablation Rate and Thyroglobulin Decrease after Low-Dose
131I in Differentiated Thyroid Carcinoma Post-Total
Thyroidectomy**

B. Duong Duc, N. Takahito, H. Tetsuya

Department of Radiology and Nuclear Medicine

Corresponding Author: ddbintm@gmail.com

Background: The aim of this study is to evaluate the therapeutic success rate and serum thyroglobulin change after 131I ablation therapy in patients with differentiated thyroid carcinoma post-total thyroidectomy.

Methodology: Thirty four patients with differentiated thyroid carcinoma post-total thyroidectomy treated with low-dose 131I ablation therapy (32 patients with 30 mCi and 2 patients with 60 mCi) between March 2011 and April 2014 were involved in this retrospective study. The imaging results of 131I whole body scintigraphy and the change of serum thyroglobulin before and six months after therapy were analysed.

Results: Twenty seven (79%) out of 34 patients were found to have no thyroid uptake on their 131I whole body scintigraphy image after 131I ablation therapy and six months later. 7 patients (21%) were found to have thyroid uptake on their WBS.

Serum thyroglobulin had significantly decreased from the time of treatment to six months follow up (Wilcoxon Signed Rank Test $P < 0.001$). Serum thyroglobulin was significantly decreased in successful cases ($N = 27$, Wilcoxon Signed Rank Test $P < 0.01$). There was no significant decrease of serum thyroglobulin in unsuccessful cases ($N=7$, Wilcoxon Signed Rank Test $P=0.612$)

Conclusion: Our findings suggest that low therapeutic dose of 131I is useful for the ablation of differentiated thyroid carcinoma post-total thyroidectomy, with the success rate of 79%. High serum thyroglobulin level group is unlikely to be successful and needs a higher dose of 131I.

IAEA-CN-232/141

Diagnostic Performance of PET/CT in Malignant Melanoma

C.A. Stan¹, C.V. Mazlu²

¹ Fundeni Clinical Institute, Euromedic Fundeni

² Euromedic, Fundeni

Corresponding Author: claudiuadrianstan@gmail.com

Background: Numerous studies have already demonstrated the utility of SLNB (sentinel lymph node biopsy) in early stages (I and II) of malignant melanoma (MM), whereas fluorodeoxyglucose positron emission tomography/computed tomography (18F-FDG PET/CT) is indicated in advanced stages (III and IV) of the disease. In addition, metabolic imaging with 18F-FDG should be the technique of choice for the therapeutic evaluation of patients with MM. We evaluated the diagnostic performance of 18F-FDG PET/CT using full-body acquisition, in staging and restaging of patients with MM.

Methodology: This retrospective study included 192 patients with operated MM - 105 females (54%), and 87 male (46%), who were referred between Jan 2013 and Dec 2014 to our centre. The patients were between 39 and 63 years old (mean age 51 +/- 12 years). Full body PET/CT was performed for staging and restaging of the disease. The protocol for PET/CT examination included scanning from vertex to plantar level at 60 minutes following injection of 0,1mCi/kg 18F-FDG, using a GE DISCOVERY ST 16 slices scanner. We calculated sensibility, specificity, positive and negative predictive values. Diagnostic accuracy was calculated for PET/CT, correlated with histopathology.

Results: Diagnostic accuracy of 18F-FDG PET/CT was 92%, and negative predictive value was more than 94%. Changing in treatment occurred in 74 patients (38.5%). We classified the frequency localization of metastases according to PET/CT findings: lymphatic 97%, lung 29%, bone 26%, skin 24%, liver 11%, muscle 8%, digestive 4%, brain 3% and adrenal 3%. PET-CT also revealed digestive lesions in 7/192 (3.62%) patients who were confirmed at histopathology as: primary origin of melanoma (1/7), metastases of melanoma (3/7), or secondary malignancies (3/7).

Conclusion: 18F-FDG PET/CT imaging was useful to evaluate patients for whole-body tumor staging, in particular in detection or exclusion of distant metastases. The technique findings included some associated malignancies, and led to changes in therapy.

IAEA-CN-232/142

Hybrid Optical-Gamma Camera for Intraoperative Imaging: A Flexible Phantom to Assess System Performances for Sentinel Node Detection

A.H. Ng¹, S.L. Bugby²; L.K. Jambi², M.S.M. Alqahtani², D. Clay³, P.E. Blackshaw⁴, P.S. Morgan⁴, J.E. Lees², A.C. Perkins⁴

¹ Ministry of Health Malaysia

² Space Research Centre, University of Leicester

³ Medical Physics and Clinical Engineering, Nottingham University Hospitals NHS Trust

⁴ Radiological Sciences, School of Medicine, University of Nottingham

Corresponding Author: hao06051982@yahoo.co.uk

Background: There is an increasing interest in the applications of handheld gamma cameras in sentinel lymph node biopsy (SLNB) in a broad range of cancers. A prototype hybrid optical-gamma camera has been developed through collaboration between the Space Research Centre at the University of Leicester and Medical Physics at the University of Nottingham. The camera system provides real-time, high resolution fused optical-gamma images highly suited to intraoperative procedures. We have also developed standard methods for assessing the performance of the camera system prior to any surgical applications.

Methodology: A sentinel node phantom was developed to simulate the localisation of nodes in the presence of high injection site activity. The phantom was fabricated using polymethyl-methacrylate (PMMA) and assembled in a cube shape measuring 120 x 130 x 110mm. Syringes with small volumes of ^{99m}Tc were used to simulate activity in the injection site (approx. 3ml) and node (approx. 0.1ml) at node-to-injection site ratio of 1:100. These were placed at different separations and depths to simulate the uptake at different anatomical sites in the body. Image acquisitions were carried out using the prototype camera system consisting of CsI(Tl) columnar scintillator coupled to a charge-coupled device (CCD), 1 mm-diameter tungsten pinhole collimator and compared with a portable gamma camera (Crystal Photonics GmbH, Germany).

Results: Phantom studies simulating the SLNB procedures have showed that the camera system could detect low-activity in nodes up to the depth of 45 mm from the phantom surface by visual examination of images. Profile analysis demonstrated the limits of node detection over a range of depths and node-to-injection site separations. Further comparisons have been made between images captured by both imaging devices.

Conclusion: The phantom was a useful tool to assess the performances of camera systems in a simulated clinical environment. The results show that the system would be suitable for use in intraoperative procedures, included but not limited to SLNB for example in patients with breast cancer. In addition, the co-aligned hybrid images provided good evidence of localisation of radiopharmaceutical distribution and its anatomical features, thus providing added value in intraoperative procedures.

IAEA-CN-232/143

Low Activity of ^{99m}Tc -Tetrofosmin for Reducing Effective Radiation Dose in Patients Undergoing Myocardial Scintigraphy

E. Avila Ramirez ¹, L.E. Veloza Salcedo ², G. Villalobos Benitez ³

¹Hospital Daline

²Universidad Nacional De Colombia, Bogota

³Hospita Dalinde

Corresponding Author: estrellaar@hotmail.com

Background: Myocardial perfusion imaging (MPI) is an established method for assessing the severity of coronary artery disease, which requires the administration of two doses of ^{99m}Tc -Tetrofosmin for diagnosis protocol. Optimization of the activity should be performed as a function of several acquisition parameters for adequate image quality with the lowest radiation exposure. The currently recommended activities have remained unchanged for many years (370/740 MBq rest/stress). A new protocol reducing the activity to be administered has been evaluated with regard to its potential for radiation dose reduction while preserving diagnostic image quality.

Methodology: In our protocol for MPI with ^{99m}Tc -tetrofosmin®, an activity of 296/629 MBq at rest/stress was applied to 99 patients (36 female, 63 male). A second set of 49 patients (14 female, 35 male) with 259/555 MBq at rest/stress was included in the study. The SPECT scans were acquired with M.GE® dual-head with the standard protocol for MPI. The biodistribution of ^{99m}Tc -Tetrofosmin reported by Higley was used in an internal dose calculation program called OLINDA/EXM-1.0® to estimate absorbed radiation doses (mGy) and effective radiation doses (mSv), in our total of patients (female 50 – 100kg / male 43 – 105 kg body mass). Two nuclear medicine physicians have evaluated with visual and quantitative analysis the acceptability of the image quality for clinical interpretation without increasing imaging time.

Results: In total there were 148 patients (50 f/ 98 m, age 32 – 88 y). The mean effective dose in females estimated by internal dosimetry was 3.25 and 5.56 mSv at rest/stress respectively. In males the mean effective dose estimated by dosimetry was 2.65 and 4.51 mGy at rest/stress. For male and female patients of the same weight the dosimetry showed that the women's effective doses are about 17% higher than for men as result of less body muscle mass in women. According to physician's evaluation, 100 % of the total images were deemed acceptable for interpretation.

Conclusion: The international community has been considering the need of decreasing the effective radiation dose as far as possible in patients who require medical imaging involving radiation in order to reduce the associated risks. Recent papers demonstrate progress made in reducing the radiation dose. In this new protocol for reducing the activity to be administered, our results show a radiation dose reduction of 20% at rest and 15% at stress. This study presents new information about the internal dose assessment, concluding that the women's mean absorbed dose in organs and effective dose is higher than in men. The difference in the effective dose is about 20%. The results of the image quality evaluation suggest that interpretable MPI images can be obtained in adults with a reduction in the administered activity of 20% at rest and 15% at stress. Protocols with high activity of ^{99m}Tc -Tetrofosmin should be re-evaluated in favour of those with lower activity, such as the one evaluated here, in order to reduce patients' absorbed and effective dose.

IAEA-CN-232/144

PET/CT: An Evolving Area in Paediatrics

R. Delgado¹, H. Vera²

¹ Hospital Infantil de Mexico

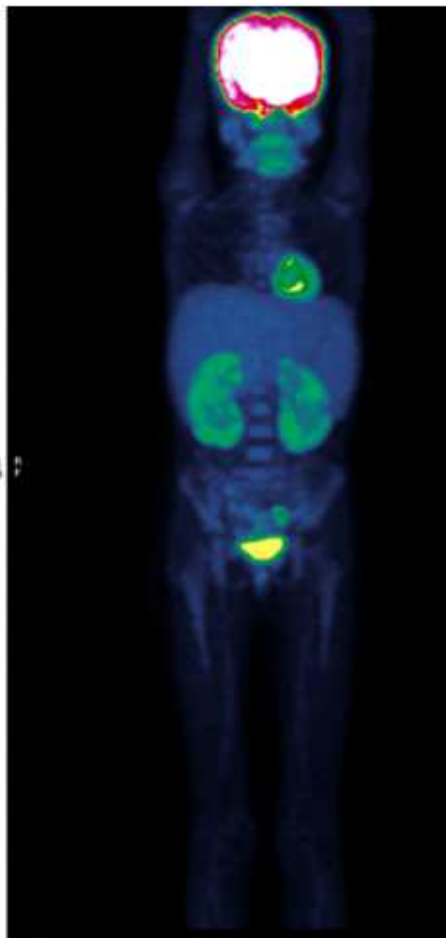
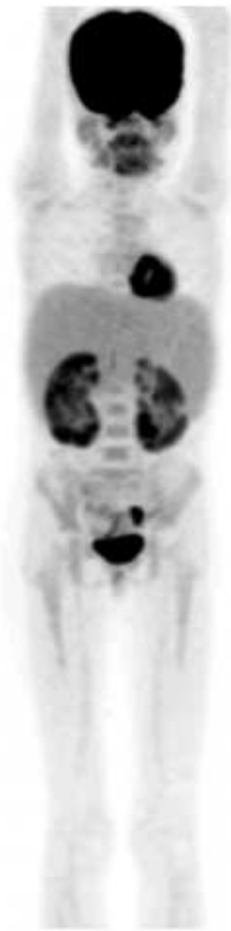² Hospital Infantil de México Federico Gomez

Corresponding Author: fang49@hotmail.com

Background: The use of PET-CT in children is an unexplored and controversial area. Currently, PET-CT plays a role in paediatric oncology – F18-FDG is used particularly in lymphoma, osteosarcoma and rhabdomyosarcoma, but is also used in neurology for epileptogenic foci; 68Ga-DOTATOC is used in cases of neuroendocrine tumors and F18-FLT in brain tumors. PET-CT aids physicians in the staging, therapy planning and treatment of many paediatric oncology patients. As new technology becomes available, scanners will continue to evolve and PET-CT will play a key role in paediatric imaging. The purpose of this paper is to present our experience with paediatric PET-CT which could be helpful to the nuclear medicine community in daily practice. This paper contains information related to staging, re-staging, recurrence, response to therapy and changes in therapy according to PET results.

Methodology: Forty three paediatric patients - twenty cases of lymphoma (13 Hodgkin lymphoma, 6 non-Hodgkin lymphoma and 1 cutaneous T-cell lymphoma), four rhabdomyosarcoma, three medulloblastoma, two primitive neuroectodermal tumors, two germinal tumors, two astrocytoma, two osteosarcoma, one hepatoblastoma, one cortical dysplasia, one glioma, one melanoma, one Ewing's sarcoma, one follicular sarcoma, one nasopharyngeal carcinoma and one case of probable lymphoma from July 2014 to January 2015 were included in the study.

Results: PET-CT results were in good correlation with successful management, staging and treatment monitoring, particularly in lymphomas. In our experience, PET-CT is relevant in staging as well as in monitoring the response to treatment, where it is performed after completing half of treatment. In rhabdomyosarcomas the degree of uptake has a prognostic value. In medulloblastoma, 68Ga-DOTATOC is preferred in the first instance; however in our experience this tumor shows an avid uptake of F18-thymidine, similar to high-grade gliomas. In staging, estimating the recurrence, assessing systematic disease and locoregional sites in sarcomas, neuroectodermal and germinal tumors, melanoma, hepatoblastoma and nasopharyngeal carcinoma PET-CT has a very important role, especially in detecting new lesions and changing the therapeutic management. The metabolic changes occur earlier than anatomic. In cases of refractory epilepsy, PET-CT plays a role in identifying hypometabolic sites in cortical dysplasia in children.



Bilateral hypermetabolic nephromegaly in a 14 year old girl suggestive of being in relation to infiltrative process secondary to lymphoproliferative disease (cutaneous lymphoma)

Conclusion: In paediatrics, PET-CT should be used as a diagnostic tool in staging, monitoring for recurrence and evaluating response to treatment as it change the treatment strategy. In this context, like in adults but considering lower doses, PET-CT should be used in paediatric patients because the method can produce functional information before morphological changes.

IAEA-CN-232/146

**An Optimal Clinical Use of 18-FDG PET-CT for the
Evaluation of Myocardial Viability in Diabetic
Patients**

M.A. Pineda Tovar, J.A. Ortega Ramírez

IMSS

Corresponding Author: pamparo27@yahoo.com.mx

Background: Cardiovascular disease (CVD) is a major cause of morbidity and mortality in patients with diabetes mellitus (DM). In Mexico, DM is the second most common cause of mortality. 9.17% of adults > 20 years of age were diagnosed with DM and 4.47% had a myocardial infarction (MI). Recent publications found that intensive glucose control in patients with DM does not reduce CVD outcomes. Patients with DM are 2-8 times more likely to experience future cardiovascular events like heart failure, MI, and cardiac death than age-matched and ethnically matched individuals without DM. An early detection of coronary artery diseases (CAD) in diabetic patients allows optimal therapeutic management. Nuclear cardiology is one of the most commonly performed non-invasive cardiac imaging investigations of choice. The 18-FDG PET/CT is a cardiac imaging fusion modality that assesses anatomy and biology of CAD, as it detects and localizes cardiac cell survival and viability. 18-FDG competes with glucose uptake in metabolically active cells. However, in an era of rapidly escalating health-care costs, tests can only be justified if the results are capable of improving treatment outcomes and functional recovering. The objective of this investigation is to show the key test for the optimal use of integrated imaging technologies to identify which patients will benefit from such combined approaches, as well as to understand which individuals do not require such testing.

Methodology: A 40 years old diabetic male patient with a recent MI was referred for viability evaluation. A SPECT-gated myocardial perfusion test was done. The images were acquired with a gamma camera after the injection of 10 mCi (stress) and 20 mCi (rest) of 99mTc-Tetrofosmin. Images were reconstructed using Emory toolbox. A week later, the patient was referred for an 18-FDG PET/CT image. The patient was intravenously injected with 10 mCi of 18-FDG after maintaining blood levels of glucose and administrating insulin using the standard protocols. PET/CT images were compared with SPECT myocardial perfusion images. The left ventricular wall was divided into 18 regions, and uptake was evaluated using a five-grade defect score (0 = normal; 1 = low; 2-3=moderate; 4 = defect).

Results: A SPECT gated myocardial perfusion image showed a fixed defect in anterior and septal walls without ischemia and without viability. However, the 18-FDG PET/CT image showed a big defect in anterior, apical and septal walls of the left ventricle with severe reversibility ischemia, which was suggestive of viability.

Conclusion: Considering the age of the patient and knowing the advantages of a molecular image to assess viability with 18-FDG PET/CT, this result suggests that in a young diabetic patient with a MI, 18-FDG PET/CT is the optimal test for evaluating myocardial viability. The young diabetic patient may benefit from a coronary revascularization to improve his functional recovery and prognostic outcome.

IAEA-CN-232/147

The Added Value of FDG PET/CT in the Diagnosis of Chronic Osteomyelitis

S. Alenezi¹, N. Alnafisi², S. Asaad², S. Salem²

¹ Faculty of Medicine-Kuwait University

² Jaber Al-Ahmad Nuclear Medicine and Molecular Imaging Center

Corresponding Author: soud1@hotmail.com

Background: The clinical role of 18F-FDG PET/CT imaging shows incremental value in detecting chronic musculoskeletal infections. Multiple studies revealed higher sensitivity, specificity and accuracy of 18F-FDG-PET/CT modality in the assessment of chronic bone infection and overlying soft tissue.

Methodology: A fifty year old male patient had a remote history of road traffic accident in 1981. He had left tibia fracture that was treated with multiple surgeries including bone grafting until complete recovery in 1987.

One and half year ago, he got an episode of high grade fever, tenderness and swelling at the old surgical site, treated conservatively with antibiotics and recovered. Three weeks ago he relapsed again with the same clinical symptoms.

A three phase bone scan was obtained following the intravenous administration of 99m-Tc MDP. As well, SPECT/CT images of the leg were obtained. On the next day, Leukoscan was performed and early and delayed images were obtained. 18F-FDG PET/CT study was also performed.

Results: The bone scan showed increased uptake at the left tibial shaft. SPECT/CT images revealed a corresponding small osteolytic lesion with sclerotic margin as well as increased cortical thickening. As well, there is increased soft tissue uptake with corresponding fatty stranding on the CT images.

The leukoscan showed mild soft tissue uptake at the left leg with no abnormal bone uptake to suggest acute osteomyelitis.

18F-FDG PET/CT study demonstrated 18F-FDG uptake at the osteolytic lesion suggesting active chronic osteomyelitis and sequestrum formation. There is increased soft tissue uptake with fatty stranding on CT images as well.

Multiple ipsilateral enlarged inguinal lymph nodes were also seen with increased 18F-FDG uptake suggesting reactive process.

Conclusion: Combined radionuclide bone scan and leukoscan studies are the imaging method of choice in cases of post-traumatic and implanted musculoskeletal infection. 18F-FDG PET/CT showed an added value in the diagnosis of active chronic osteomyelitis which was not detected by leukoscan.

IAEA-CN-232/148

Radionuclide Therapy with ^{153}Sm -EDTMP in Painful Bone Metastasis

S. Rahabi, S.E. Bouyoucef

Department of Nuclear Medicine CHU Bab El Oued 16000 Algiers Algeria

Corresponding Author: salaedine@yahoo.fr

Background: Radionuclide therapy has become an important tool in the management of painful bone metastasis. However, the strategy of its use is dependent on certain parameters including local medical protocols of chemotherapy.

The objective of this study was to determine the best response to radionuclide therapy according to the stage of cancer disease and the extension to the bone.

Methodology: 70 patients with prostate or breast cancer and bone metastases have been referred to the department of nuclear medicine for radionuclide therapy of painful bone metastasis from 2009 to 2012. All patients have had multiple lesions on bone scan and normal blood and kidney tests. Incontinent patients, patients with medullar compression and fractures have been excluded from the study. Average activity of ^{153}Sm -EDTMP used was 37MBq/kg for all patients and injection was done slowly during 3 minutes with glucose line. Assessment of response was done each 6 weeks according to clinical symptoms, dose of morphine and Eva and Karnofsky score.

Results: Clinical improvement was observed in 85% of patients including a decrease of the dose of morphine or drugs. The drugs and morphine were totally stopped in 13% of cases after 3 months of radionuclide therapy. The response to treatment was much better when the number of lesions was limited and widespread. The rate of response was slightly higher in patients with prostate cancer. Only one patient experienced bone marrow suppression after 6 months. 15% of patients relapsed and needed a second or a third cycle of radionuclide therapy. Most patients (89%) survived at 3 months and 13% at 2 years.

Conclusion: Radionuclide therapy of painful bone metastasis of prostate and breast is efficient in most cases. However, selection of patients is absolutely required to avoid bone marrow complications and better efficiency of treatment. Despite the new alpha therapeutic agent (Radium 223), ^{153}Sm -EDTMP will remain an excellent alternative for controlling pain in metastatic cancer patients.

IAEA-CN-232/149

The Hydration Behaviour of Hydrophilic Material in Biological Samples Using Ratio of 3-to-2 Photon Annihilation

H. Aldousari

Jaber Al-Ahamad Nuclear Medicine and Molecular Imaging Center

Corresponding Author: hanan3d@hotmail.com

Background: In 2004, the idea of exploiting the unique characteristics of 3γ annihilation as a new PET imaging modality (3γ PET) was introduced by Kacperski and Spyrou and opened a new scientific field that aims to investigate the 3γ yield in hypoxic/normoxic/hyperoxic conditions in tissues for application to oncology. 3γ annihilation is considerably higher in a hypoxic environment.

Methodology: The hydration behaviour in biological samples (blood and serum) of two types of hydrophilic materials, potential candidates for the construction of radiation phantoms, was evaluated. Type A is a HEMA/VP of EWC=38% while type B is an MMA/VP of EWC=75%. The hydrophilic materials dimensions were recorded after 1, 4, 9, 21, 33, 52, 70, and 97 hours of immersion in blood and serum (at room temperature) in order to observe the changes in shape and level of hydration.

Results: The results indicate that the hydration rate is generally higher in serum. The hydration rates for blood and serum were quite similar for sample A; the diffusion coefficients were found to be 0.018 g/h in blood and 0.019 g/h in serum. For sample B, the hydration rate was different for blood and serum; the diffusion coefficients were found to be 0.055 g/h in blood and 0.061 g/h in serum.

Conclusion: Hydrophilic materials are potentially suitable materials for the construction of hypoxic phantoms as they are tissue equivalent structures in which the hydration level and type of liquid content can be controlled. The peak-to-peak method was applied, by using hydrophilic material as a hypoxic phantom, to study the formation and quenching process of positronium that affect the relative yield of 3-to-2 photon annihilation.

IAEA-CN-232/150

Can Self-Shielded Radiosynthesis Box be Routinely Used for a Fully Automated Small Scale Preparation of Radiopharmaceuticals?

M. Krošelj¹, A. Sočan¹, T. Dreger²; R. Knopp², P. Kolenc Peitl¹

¹Department for Nuclear Medicine, UMC Ljubljana, Slovenia

²Eckert, Berlin, Germany

Corresponding Author: marko.kroselj@kclj.si

Background: A self-shielded modular system (MicroCell®), suitable especially for smaller nuclear medicine departments, was recently developed. All the modules to actuate valves, syringes and other moving parts are located outside the shielding and thus the size and the weight of radiosynthesis box are reduced to high extent (total weight of app. 450 kg). Recently published EANM guidance on small scale preparation of radiopharmaceuticals using automated modules covers different aspects of using these systems in clinical settings (installation, validation, routine runs, radiation protection). The self-shielded radiosynthesis box was set up and tested in accordance to EANM guidance. Here we describe radiation protection characteristics of the system, introduction of different labeling procedures and their validation for routine use.

Methodology: Sterile and single use cassettes were specially designed for MicroCell®. Dose rates were measured at surface and at 1m distance from the shielded unit. 68Ge/68Ga generator (IGG100, Eckert&Ziegler) was eluted with 0.1M HCl. Three methods for 68Ga generator eluate pre-purification and concentration were used. 177Lu n.c.a. and 90Y were purchased from ITG and Perkin Elmer. Reaction conditions such as buffers, pH range, reaction temperature and time and volume of reaction solution were optimized for labelling DOTA-Tyr3-octreotate (DOTATATE). Quality testing of the final products was done in concordance to pharmacopoeial requirements.

Results: Dose rates at surface were maximum 1,5 µSv/h and at 1m distance normal background rates were seen. 40 µg of peptide (27,8 nmol) were successfully labeled with 68Ga (max. 450 MBq) with radiochemical purities >96%. Overall reaction yields ranged from 60% to 80%. In case of 68Ga radiolabeling 68Ge breakthrough, half time, ethanol content, bacterial endotoxins and sterility conform to PhEur requirements. 177Lu-DOTATATE (3GBq) and 90Y-DOTATATE were synthesised reproducibly with radiochemical purity of > 99% and > 97%, respectively.

Conclusion: With the rapid development of 68Ga radiopharmaceuticals the self-shielded radiosynthesis box is a novel approach to modular synthesis systems. Its weight and size are suitable also for small(er) nuclear medicine departments. Newly designed single-use cassettes enable the same range of synthesis as previously developed cassette systems. Process validation of different radiosynthesis was performed with a series of three successful validation runs. When the box is placed in a controlled environment and with the use of sterile cassettes the products are ready for human application. With adequate 68Ge/68Ga generator shielding, MicroCell provides sufficient shielding for both PET and β- radioisotopes.

IAEA-CN-232/151

18F-Choline-PET-CT (PET) in N Stage and Radiation Treatment Planning (RTP) of Prostate Cancer Patients (PCap) at High or Unfavorable/Intermediate Risk (HUIR)

A. Magli¹, M. Rensi², E. Moretti³, F. Giacomuzzi⁴, F. Titone¹, S. Fongione¹, M.R. Malisan⁵, O. Geatti²

¹ Department Radiotherapy, University-Hospital, Udine, Italy.

² Department Nuclear Medicine, University-Hospital, Udine, Italy.

³ Department Medical Physics University-Hospital, Udine, Italy.

⁴ Department Nuclear Medicine University-Hospital, Udine, Italy.

⁵ Department Medical Physics, University-Hospital, Udine, Italy.

Corresponding Author: magli.alessandro@aoud.sanita.fvg.it

Background: Prophylactic whole pelvic radiotherapy (WPRT) is often given for HUIR PCap in addition to hormonal therapy. However, the outcome is variable, potentially due to different patient selection, variability in the estimated risk of lymph node (LN) involvement or RTP. Using more accurate imaging techniques could improve patient selection for WPRT, so we tried to evaluate if PET imaging can be helpful in pelvic lymph nodes staging of patients with > 17% probability of pelvic lymph node involvement (Roach Index) and establish if PET positivity relates to PSA concentration and Gleason score.

Methodology: 15 HUIR PCap, naive for hormonal treatment, underwent PET and in those where a LN involvement was diagnosed, radiation treatment was delivered by intensity-modulated radiotherapy (IMRT) with simultaneous integrated boost (SIB) (6MV photons from a Varian 2300iX linac). IMRT-SIB plans were designed to deliver 67.5 Gy in 25 fractions (2.7 Gy/fraction) to the prostate, 62.5 Gy (2.5 Gy/fraction) to the positive LN and 50 Gy (2 Gy/fraction) to the pelvic LN. The image-guided radiation therapy (IGRT) protocol is based on 3 intra-prostatic fiducial markers, with daily online checks by CBCT (Cone-beam CT).

Results: In 33% of patients, PET identified LN involvement which was always inside the pelvic target volume as defined by Radiation Therapy Oncology Group (RTOG). Basal PSA was > 10ng/ml with primary Gleason ≥ 4 and was positively correlated with PET nodal stage. High dose WPRT, together with an on-line IGRT resulted to be safe, as no patients developed acute genitourinary (GU) and gastrointestinal (GI) toxicities ≥ 2 in according to the RTOG grading system

Conclusion: Pelvic IMRT with hypofractionated SIB to positive LN was well tolerated. The early evidence from our study on the correlation between basal PSA and positive lymph nodes on CT/PET are in line with those of the literature. The ability to detect early-stage positive LN shows a potential impact on RTP that could yield a better control of the disease.

IAEA-CN-232/152

Breast Cancer Evaluation: Role of Image Fusion between 18F-FDG PET/CT in Prone Position and Magnetic Resonance

D. Grigolato¹, G. Pollini², F. Pellini², M. Cucca¹, M. Zuffante¹, M. Barillari³, E. Zivelonghi⁴; R. Pozzi Mucelli³, C. Cavedon⁴, M. Ferdeghini¹

¹Nuclear Medicine Unit, Azienda Ospedaliera Universitaria Integrata Verona

²Department of Surgery,

³Department of Radiology

⁴Department of Physics

Corresponding Author: daniela.grigolato@ospedaleuniverona.it

Background: The purpose of this study was to assess the role of fusion of two methods of imaging in the evaluation of patients with breast cancer: prone 18F-FDG PET/CT and MR of the breast.

Methodology: We consecutively recruited 85 women with newly diagnosed breast cancer (cT1- cT3) from August 2012 to October 2013. After confirmation of malignancy, patients underwent dynamic contrast-enhanced MR of the breast and 18F-FDG PET/CT within 10 days. Patients performed PET/CT for initial staging, acquired as standard whole body PET/CT scan in supine position followed by a delayed prone acquisition 2 hours post-injection with a dedicated breast device, the same as the one used in MR. Three groups were created: patients with single lesions (n= 38), patients with multifocal lesions (n=16 women with 48 lesions) and with multicentric lesions (n= 31 patients and a total of 71 lesions). There were 13 suspected bilateral malignant lesions and 40 benign neoformations. The image interpretation in PET/CT was visual and semiquantitative with calculation of SUVmax of the lesions. On MR all lesions were classified as mass or nonmass-like according to the Breast Imaging Reporting Data System (BI-RADS). In the fusion the only criterion for suspicious lesion was any increase in tracer uptake corresponding to the site of the enhancing lesion detected on MR.

Results: By pathology, 161 lesions were malignant and 53 were benign. The sensitivity, specificity, PPV, NPV and accuracy were: for MR 100%, 75%, 93%, 100% and 94%; for PET/CT 90%, 98%, 99%, 76% and 92%; in fused PET/MR 94%, 100%, 100%, 85% and 96%. PET/CT had a great number of FN in multifocal/multicentric groups, whereas MR had a consistent number of FP in the contralateral breasts. Both results greatly improved using fusion PET/MR.

Conclusion: Integrated information between PET and MR images increased the sensitivity and accuracy of PET, and the specificity, PPV and accuracy of MR in diagnostic work-up of breast cancer.

IAEA-CN-232/153

The Utility of 18F-FDG PET/CT in Left Ventricular Assist Device Infection

D. Grigolato¹, **M. Cucca**², **M. Zuffante**³, **M. Merighi**⁴, **A. FORNI**⁵, **E. Concia**⁴, **M. Ferdeghini**³

¹Nuclear Medicine Unit Azienda Ospedaliera Universitaria Integrata di Verona

²Nuclear Medicine Unit

³Nuclear Medicine Unit

⁴Infection Disease Department

⁵Cardiosurgery Department

Corresponding Author: daniela.grigolato@ospedaleuniverona.it

Background: The accuracy of 18F-FDG PET/CT in the diagnosis of prosthetic graft and pacemaker related infections is high and well described in the literature, but the information regarding the application of metabolic imaging in left ventricular assist device infection (LVADI) is poorer. We evaluated the role of 18F-FDG PET/CT for LVSDI: confirming or excluding the presence of infection, defining the extent of the device involvement and helping in the decision whether to change treatment therapy or to remove the device.

Methodology: Between 2013 and 2014 nine consecutive patients, all males (age 51-69, mean 60.8), with Heartmate II and infections of the exit of the driveline, underwent 18F-FDG PET/CT. A complete whole body scan was performed after 1 hour from FDG injection in fasting condition. At FDG imaging, LVADI was classified into four sites: driveline (DL), prosthetic device (PD), inflow valve housing (IV) and outflow valve housing (OV); for each site of infection it was distinguished between focal and extended tracer uptake and the grade of involvement according to SUVmax values and SUVratio between infection site and liver (mild, moderate and severe). FDG uptake was also checked in non-attenuation corrected images (NAC).

Results: Microbiology cultures from percutaneous DL and blood mainly isolated *Staphylococcus Aureus*, coagulase-negative staphylococci and *Burkholderia Cepacia* only in one case.

Twelve PET scans were positive and infectious sites were attributed to the DL in 11, IV in 7, PD in 4, OV in 7. The grade of infection was mild in 7 PET, moderate in 2 and severe in 3 scans. All patients were treated with the most suitable antibiotic according to the pathogens and the extension of the LVADI. Among the two patients with severe involvement at PET and uptake in the PD, one patient underwent transplantation after 3 months of antibiotic therapy while the other one is still on a high dose antibiotic treatment and a continuous worsening of his health condition. All patients with mild grade and focal uptake of LVADI had their personalized antibiotic treatments and at follow-up they were in good condition. One patient with moderate involvement of the PD was transplanted with confirmation of the infection also in the PD. One patient died from a non-infectious cause. In our study we did not see any changes in the OV tracer uptake during different antibiotic treatments, the SUV values and the extension of the uptake were always mild and focal respectively, suggesting a chronic inflammatory response to the prosthetic graft material rather than a site of infection.

Presence of septic embolism at PET imaging was not revealed in any these patients.

Conclusion: In this small sample of patients, 18F-FDG PET/CT was helpful to the clinicians in

recognizing the sites, the extension and grade of LVADI, which had important implications on patient management.

IAEA-CN-232/154

**Prevalence of PET/CT Indications According to
Diagnosis in a Medical Centre in the Province of Santa
Fe, Argentina. Treatment Decisions Based on Results**

F. Faccio, L. Ríos, A. Vazquez, Andrés, M. Fleurquin

PET/CT San Gerónimo

Corresponding Author: ferfaccio@gmail.com

Background: Important medical centres around the world have analysed the different indications to carry out PET/CT studies. Our new centre has been carrying out PET/CT studies on patients with different diagnoses for more than one year now.

The objective of this study was to find the prevalence of indications according to different pathologies in PET/CT studies at a medical centre in the city of Santa Fe, Province of Santa Fe, Argentina. The impact on medical decisions according to PET/CT for solitary pulmonary nodule (SPN) is also reported.

Methodology: We included 743 patients (p) in prospective form, with PET/CT studies, from August 1, 2013 to December 31, 2014. All patients had indication prescribed by their physician in charge. Philips GXL 16 PET/CT was used. Patients were injected with 0.9 to 0.11 mCi of 18F-FDG per kilogram body weight. The images were obtained after one hour at rest after a 6-hour fast and blood glucose check. Patients whose glucose level was over 160 mg/dl were not injected. CTs were low-dose except for those patients requiring diagnostic CT scans.

Results: An average of 44 PET/CT studies per month were carried out over the first 17 months of work. The prevalence of indications was as follows:

1. Lung 158 p (21,3%): 111 p with solitary pulmonary nodule (SPN) (14.9%) and 47 p with lung cancer (6.3%)
2. Digestive tumours 182 p (24.5%)
3. Lymphoma and oncohaematology patients 118 p (16%)
4. Gynaecological tumours 49 p (6.6%)
5. Breast cancer 41 p (5.5%)
6. Head and neck 35 p (4.7%)
7. Melanoma 57 p (7.7%)
8. Nephro-urologic 53 p (7.1%)
9. Unknown primary site 19 p (2.5%)
10. Cardiac 4 p (0.5%)
11. Others 27 p (3.6%).

Medical decisions for patients with SPN based on PET/CT scans were analysed and the determination was reached that the scan established the decisions to be taken in 97% of these patients.

Conclusion: Our medical centre is new and is growing in terms of number of studies and caseload, but the indications fall within the general averages. We had an important number of indications for SPN, for which the PET/CT scan has proved very useful in taking medical decisions.

IAEA-CN-232/155

Clinical Utility of SPECT/CT Versus Planar Bone Scintigraphy in the Daily Practice of the Nuclear Medicine Department of the Salah Azaiez Institute

M.F. Ben Slimene, I. Elbez

Nuclear Medicine Department, Salah Azaiez Institut,

Corresponding Author: mf.benslimene@planet.tn

Background: Bone scintigraphy with single photon-emission computed tomography and CT (SPECT-CT) is an imaging modality which combines highly detailed CT with the functional information from the scintigraphy.

The purpose of our study was to evaluate the diagnostic performance of SPECT coupled to computed axial tomography (SPECT-CT) in our daily practice of bone scintigraphy.

Methodology: A retrospective study involving 50 patients was conducted between March 2012 and December 2014. SPECT-CT scans obtained as a complement to the planar bone scintigraphy in 50 patients were studied. In this population of patients, 35 patients were addressed in an oncologic setting. The other 15 patients were addressed for pain of indeterminate origin without neoplastic context.

Results: In 30 % of the cases, SPECT-CT specified the precise location of increased uptake foci seen on planar bone scintigraphy. In 45 % of cases, SPECT-CT confirmed the diagnosis suspected by the planar bone scintigraphy. In 15% of cases, SPECT-CT established a diagnosis that was uncertain with planar bone scintigraphy. In 10 % of cases, SPECT-CT brought no additional information.

Conclusion: Our study demonstrates the utility of SPECT-CT in the daily practice of bone scintigraphy; this complementary imaging study benefited to 90 % of our patients.

IAEA-CN-232/156

Interest of Hybrid SPECT/CT Imaging in the Localization of Ectopic Parathyroid Glands

M.F. Ben Slimène, I. Elbez

Nuclear Medicine Department, Salah Azaiez Institut

Corresponding Author: mf.benslimene@planet.tn

Background: Hyperparathyroidism due to an ectopic parathyroid is a rare disease; ectopic parathyroid it is the most common cause of persistent or recurrent hyperparathyroidism. Its treatment is exclusively surgical and the results of the surgery benefit from the contribution of preoperative imaging techniques. The aim of this work is to illustrate the contribution of the single photon emission computed tomography/computed tomography (SPECT/CT) in the detection and treatment of ectopic parathyroid orientation, compared to planar scintigraphy and ultrasounds.

Methodology: We compared, in 53 patients with hyperparathyroidism, a planar scan of neck and mediastinum to a subtraction ($^{99m}\text{Tc} / ^{99m}\text{Tc}$ -MIBI) SPECT scan of neck and mediastinum fused with CT. Surgical and histopathologic findings were used as the standard of truth.

Results: Subtraction SPECT/CT appeared to be more sensitive and specific than planar protocol to diagnose and to accurately localize pathologic parathyroid. Sensitivity was 77% and 63%; specificity was 100% and 85% for hybrid SPECT/CT and planar protocol respectively. The SPECT-CT protocol was typically more efficient to diagnose pathologic parathyroid derived from upper gland and for patients with concomitant nodular goiter.

Conclusion: SPECT/CT has an important role in the management of patients with persistent or recurrent hyperparathyroidism. It can usually visualize ectopic parathyroid injury; specify its size and anatomic relationships to optimize surgical management.

IAEA-CN-232/157

Philips Gemini TF64 PET/CT Acceptance Testing

J.J. González González¹, C.F. Calderón Marín¹, C. Varela Corona², A. Machado Tejada³, H.J. González Correa⁴

¹ Institute of Oncology and Radiobiology

² Center for State Control of Medical Equipments and Devices

³ Center for State Control of Medical Equipments and Devices

⁴ National Electromedical Center

Corresponding Author: jgg@infomed.sld.cu

Background: The Philips Gemini TF64 is the first PET/CT scanner installed in Cuba at the Institute of Oncology and Radiobiology in 2014. It is a third generation fully tridimensional whole body PET scanner with time-of-flight (TOF) technology combined with a 64-slice Brilliance CT scanner. The CT detector module contains 672x64 solid state detector, incorporating GOS scintillators, optical diodes and electronic signal channels arranged in 64 side by side arcs, with 672 detectors in each arc. There are sixteen 0.75 mm individual detector elements around the center and four 1.5 mm elements at each end, resulting in a 24 mm total detection length. The PET detector consists of 28 pixelar modules of a 23x44 array of 4x4x22 mm³ of LYSO crystals arranged in an Anger-logic detector design. The hardware coincidence-timing window for this scanner is set at 4 ns and delayed coincidence window technique is used to estimate the random coincidences in collected data. In this study the performance characteristics of PET/CT scanner were measured as part of the program tests of acceptance for clinical use.

Methodology: The performance characteristics of CT scanner were evaluated by manufacturer protocol using Philips system performance phantom. Some additional geometrical tests were performed by the user. The intrinsic measurements of energy resolution as well as timing resolution, which define the TOF performance of PET scanner, were performed following the recommendations of manufacturer using 18F. Spatial resolution, sensitivity, scatter fraction, counting rate performance, image quality and accuracy were measured according to the NEMA NU-2 2007 procedures. Additionally, to characterize the effect of TOF reconstruction on lesion contrast and noise, the standard NEMA torso phantom was reconstructed with and without TOF capability. The accuracy of PET/CT image registration was tested according to the manufacturer protocol using an image alignment calibration holder with 6 point sources of ²²Na.

Results: The manufacturer protocol for CT scanner passed all performed tests for head and body phantom such as image artefacts, mean CT number, CT uniformity, image noise, spatial resolution and slices thickness. The performed geometrical tests were within specifications.

For PET scanner, the energy resolution and the system coincidence timing resolution was 12.03 % and 516.2 ps respectively. The measured values of transversal and axial resolutions near the center, absolute sensitivity at the center and at 10 cm off-center, scatter fraction, counting rate performance, accuracy for correction of count losses and random as well as image quality measurements of lesions contrast and background variability were within manufacturer specifications. A modest improvement of lesion detectability was observed when quality image phantom was reconstructed using TOF capability.

The measured (X, Y, Z, Z rotation) offset values in mm of PET/CT images alignment with gantry in closed and open positions were (-3.22, 3.46, 1.61, -0.44) and (-1.2, 3.25, 3.28, -0.58) respectively.

Conclusion: The measurement of performance characteristics of the Philips Gemini TF64 PET/CT

International Conference on Clinical PET-CT and Molecular Imaging (IPET 2015): PET-CT in the Era of Multimodality Imaging and Image-Guided Therapy

scanner satisfies the manufacturer specification.

IAEA-CN-232/158

**Comparisons of Intratumoral Distribution of ^{64}Cu -ATSM
at Dual Time Point PET Scan and ^{18}F -FDG PET Scan;
Preliminary Results in Patients with Cervix Cancer**

B.I. Kim¹, B.H. Byun², K.C. Lee³, K.M. Kim⁴, I. Lim², M.H. Kim⁵, B.J. Kim⁵, S.Y. Ryu⁵, S.M. Lim²

¹ Department of Nuclear Medicine, Korea Cancer Center Hospital, Korea Institute of Radiological Medical Sciences (KIRAMS)

² Department of Nuclear Medicine, KIRAMS

³ Molecular Imaging Research Center

⁴ Molecular Imaging Research Center, KIRAMS

⁵ Departments of Obstetrics Gynecology, KIRAMS

Corresponding Author: kimbi@kirams.re.kr

Background: The purpose of the study was to compare the intratumoral hypoxic status and metabolic status; we compared the intratumoral distributions of ^{64}Cu -ATSM at dual time point PET scan and ^{18}F -FDG PET scan in patients with pre-treatment cervix cancer.

Methodology: A total of 5 female patients (mean ages, 61.8 ± 10.6 y) with pre-treatment cervix cancer were prospectively enrolled in the current study. All patients underwent PET/CT scan covering the skull base to the upper thigh after the intravenous administration of $370 \text{ MBq} \pm 37 \text{ MBq}$ ($10 \text{ mCi} \pm \text{mCi}$) of ^{18}F -FDG (FDG-PET) and contrast-enhanced pelvic MRI. Within 2 weeks after FDG-PET, all patients underwent PET/CT scan covering the pelvis 30 min (ATSM-PET1) and 17 hrs (ATSM-PET2) after the intravenous administration of $555 \text{ MBq} \pm 55 \text{ MBq}$ ($15 \text{ mCi} \pm 1.5 \text{ mCi}$) of ^{64}Cu -ATSM. The maximal tumor diameters (MTDs) were measured in the enhanced axial T1-weighted MR images (TR/TE 752/10 ms; field of view 450 mm, matrix size 279×448 ; slice thickness 5 mm; 2 average; acquisition time, 3 min 53 s). For visual analysis, we compared the intratumoral locations of pixel with the highest standardized uptake value (SUV) on FDG-PET, ATSM-PET1 and ATSM-PET2, respectively. For semi-quantitative analysis, we selected 1 transverse slice including the pixel with the highest SUV of the primary tumor and placed a 15.0-mm-diameter circular region of interest (ROI) in the highest-uptake region on each PET data set. Then, the average value of SUV within this ROI was denoted as peak SUV (SUV_{peak}).

Results: The histologic subtype of cervix cancer was squamous cell carcinoma in all patients of this study and the mean MTDs were 7.6 ± 1.5 cm. In 3 patients (60%), the intratumoral locations of pixel with the highest SUV were identical between FDG-PET and ATSM-PET1. However, no patients (0%) showed identical intratumoral locations of pixel with the highest SUV between ATSM-PET1 and ATSM-PET2, and only 1 patient (20%) showed identical intratumoral locations of pixel with the highest SUV between FDG-PET and ATSM-PET2. The mean SUV_{peak} of cervix tumor measured on FDG-PET, ATSM-PET1 and ATSM-PET2 were 11.46 ± 4.50 , 3.04 ± 0.86 and 3.06 ± 0.87 , respectively.

Conclusion: In the current preliminary study, intratumoral distributions of ^{64}Cu -ATSM on ATSM-PET1 were similar with those of ^{18}F -FDG in more than half of patients. On the contrary, intratumoral distributions of ^{64}Cu -ATSM on ATSM-PET2 were significantly different with those of ^{18}F -FDG or ^{64}Cu -ATSM on ATSM-PET1 in almost all patients.

IAEA-CN-232/159

PET/CT in the Diagnosis and Treatment of Nasopharyngeal Cancer: Bach Mai Hospital Experiences

T.K. Mai¹, T.T. Ngo², H.B. Tran³, D.H. Tran⁴, C.D. Le⁵

¹ The Nuclear Medicine and Oncology Center, Bach Mai hospital

² The Nuclear Medicine and Oncology Center

³ The Nuclear Medicine Department, Hanoi Medical University

⁴ The Nuclear Medicine and Oncology Center, Bach Mai Hospital

⁵ Department of Oncology, Hanoi Medical University

Corresponding Author: trang_ngothuy0201@yahoo.com

Background: Nasopharyngeal cancer (NPC) is one of the most common cancers in Vietnam and worldwide. PET/CT has been used in NPC patients (pts) not only for diagnostic purposes but also for staging and simulation for radiotherapy planning in Bach Mai Hospital since 2009.

Aims: (1) To evaluate the diagnostic value of PET/CT for staging of NPC. (2) To study the value of PET/CT simulation in radiotherapy planning for NPC.

Methodology: Prospective study on 60 pts newly diagnosed with NPC (histopathology confirmed). PET/CT for staging and simulation was performed and they were then treated with linear accelerator at the Nuclear Medicine and Oncology Center, Bach Mai Hospital, Hanoi, from October 2009 to October 2013.

Results: Average age was 54.1 ± 14.0 years, the most common group was 40-60 years. Male/female ratio was 2.5. Histopathological types: non differentiated carcinoma (96.7%), squamous cell carcinoma (3.3%). Cervical lymph node involvement was present in 68.3% of pts. Primary tumours, metastases were FDG avid and mean SUV of primary tumour was 11.08 ± 5.15 ; in lymph nodes: 9.07 ± 5.81 . There was a correlation between the FDG uptake and the size of tumours and the stages of disease ($p < 0.05$). PET/CT changed the stage in 25% of pts.

PET/CT simulation for radiation therapy: median BTV-PET/CT (54,64 cm³) was less than GTV-CT (102,58 cm³). 100% of pts had complete response (based on RECIST 1.1 criteria) at the end of treatment. Radiation early adverse events were all low grade (1, 2), such as: radiation dermatitis, xerostomia, oral mucositis, vomiting, diarrhea, hair loss. Late adverse events were reported as grade I (in 5-20%) and grade II (5-15%).

Conclusion: PET/CT scan has additional diagnostic value for staging cancer accurately. It therefore helps in choosing the most appropriate treatment. PET/CT simulation for radiation therapy planning has some significant advantages: defining accurate radiation volume, high dose focus in tumour while separating the normal surrounding tissue, which results in minimizing the side effects and improving the treatment outcomes.

IAEA-CN-232/160

Efficacy of 18F-FDG PET/CT in the Detection of Recurrent Gynaecological Malignancies

S. Chandran, S. Simon, I. Elangovan

Apollo Hospitals

Corresponding Author: dracsuresh06@gmail.com

Background: To evaluate the efficacy of 18F-FDG PET-CT for detection of recurrent gynaecological malignancies in correlation with tumour markers, histopathology and MR findings.

Methodology: Seventy five gynaecological malignancy patients with suspected recurrence or as a regular follow-up were included. All imaging and data acquisitions were performed with an integrated PET/CT system (Gemini TF; Phillips) consisting of a PET scanner and a 64 slice multi-detector CT scanner that permits the acquisition of coregistered CT and PET images for the same patient in one session. The images were evaluated by a review team which consisted of a radiology physician and a nuclear medicine physician, who interpreted the PET/CT findings by consensus. Statistical analysis was performed.

Results: Of the 75 patients, 31 patients (41%) had primary ovarian malignancy and 44 patients (59%) had non ovarian malignancies. PET/CT was able to detect recurrence in 49 (65.3%) patients. Among the 31 ovarian cancer patients, recurrence was detected in 17 patients (55%) with elevated CA-125 and 6 (19%) with normal CA-125. The overall sensitivity, specificity, accuracy and positive and negative predictive values in the detection of recurrent gynaecological carcinoma were 96%, 100%, 97%, 100% and 93% respectively. The sensitivity, specificity, diagnostic accuracy and positive and negative predictive values of 18F-FDG PET/CT in the recurrence detection of ovarian carcinomas were 96%, 100%, 97%, 100 % and 89% respectively, but for CA-125 the value was 74%,87.5%,77%,94% and 54% respectively.

Conclusion: 18F-FDG PET/CT is safe, non-invasive and has a high sensitivity, specificity and accuracy in post therapy surveillance for the detection of recurrence even with normal tumour markers. The capability of PET/CT to detect recurrences enables non-invasive prognostication and follow-up of patients by means of a single procedure.

IAEA-CN-232/161

GMP Manufacturing of Multiple Radiopharmaceuticals in the Same System: IBA Synthera Synthesizer

C. Gameiro-Paris¹, V. Kramer², A. Abrunhosa³, G. Casale⁴, I. Oxley¹

¹ IBA S.A.

² PositronPharma S.A.

³ ICNAS

⁴ Laboratorios Bacon SAIC

Corresponding Author: cristiana.gameiro@iba-group.com

Background: Radiopharmaceutical (RP) facilities range from mono-product to multi-tracer facilities for commercial, clinical and/or research applications. Progressively, mono-product facilities turn to multi-product sites to cope with decreasing prices of radiopharmaceuticals and to support R&D programs. Our aim is to demonstrate that in the same facility and equipment, a busy research program can be safely integrated into routine commercial production.

Methodology: In order to be able to combine both activities in a safe way a risk-assessment approach should be designed to identify key control points. The use of a fully automated platform (e.g. IBA Synthera) and disposable cassettes (e.g. IFP™- integrated fluidic processor) can prevent human errors, reduce risk of cross-contamination and improve reliability. Additionally, a production schedule, training and labeling procedures should also be considered. In this paper, three different facilities handling both commercial and R&D activities are described.

Results: Positronpharma S.A. in Chile delivers on daily basis to more than seven nuclear medicine facilities since 2011 including 18F-FDG, 68Ga-DOTA-peptides daily and also other 18F-compounds: FCH (weekly), NaF, FET and FLT (monthly) and will extend for F-DOPA and F-MISO. The facility also supports clinical trials and translational R&D with the investigational PET tracers (18F-DMFP and 18F-PR04MZ) for neuroimaging. Using the IBA Synthera platform production of FDG and complex neurotracers is possible even sharing the same batch 18F. ICNAS is a research unit of the University of Coimbra in Portugal that hosts a GMP PET production facility which supports clinical and pre-clinical R&D programs and supplies RPs to nearby hospitals. The unit is in operation for distribution since 2012 and currently has four radiopharmaceuticals authorized in the market (18F-: FDG, FCH, NaF and 68Ga-DOTA-NOC). All are produced on a single Synthera platform and together represent a combined production of over 2000 cycles. An extensive R&D program is in place with plans for production of other 18F-tracers (F-DOPA nucleophilic route, FLT, FES), 68Ga (PSMA, DOTA-TOC) and 64Cu (ATSM). Laboratorios BACON SAIC in Argentina is a private radiopharmaceutical laboratory with 35 years of experience in radiopharmaceuticals. The facility uses Synthera system to produce 18F-FDG (two daily batches); 18F-FCH (twice/week) and amyloid plaque imaging agent (AV-45) from Avid-Eli Lilly which is produced once a week for clinical trials. Lyophilized kits of Trodat-1 and 18F-FDOPA nucleophilic have also been developed on Synthera. In more than 6 years of operation, 4953 Ci of 18F-radiopharmaceuticals (>95% FDG) in 2023 runs have been produced with only <0.25 % failure runs due to the synthesizer.

Conclusion: As a conclusion, the sites described have been functioning for several years and are able

International Conference on Clinical PET-CT and Molecular Imaging (IPET 2015): PET-CT in the Era of Multimodality Imaging and Image-Guided Therapy

with the same system to safely combine commercial daily production while keeping a highly active R&D program with more than ten different tracers developed for pre-clinical and clinical applications.

IAEA-CN-232/162

18F-FDG, 11C-MET, and 11C-CHO PET/CT in the Preoperative Evaluation of Suspected Adult Gliomas

L. Cai, S. Gao, Y. Li, Y. Wang, H. Yang

PET/CT Center, Tianjin General Hospital of Tianjin Medical University, P.R.China

Corresponding Author: xcl242004@126.com

Background: In recent years, it is a critical challenge to make an exact preoperative evaluation of biological behaviours in gliomas through imaging.

The objective of this study was to assess the metabolic activity of adult gliomas using 18F-FDG, 11C-MET, and 11C-CHO PET/CT and to explore the correlation between tumor metabolic activity and contrast-enhanced MRI, and histopathologic features, such as size, subtype, grade, and cellular proliferation.

Methodology: All consecutive 159 patients with suspected primary gliomas underwent PET/CT scanning in our center. PET/CT examination was performed on 107 patients with both MET and FDG, on 44 patients with both CHO and FDG, on 8 patients with three tracers. Contrast-enhanced MRI was performed within 2 weeks before PET examination. Pathologic diagnosis was obtained by biopsy or open surgery in all patients with suspected tumors. The lesions included 108 gliomas (3 WHO I tumors, 42 II tumors, 42 III tumors and 21 IV tumors), 18 other tumors and 33 non-neoplasm lesions. PET/CT images were analysed visually and semi-quantitatively. The L/WM ratios (tumor to normal white matter ratios) were calculated. To analyse the relations among the tracer uptake, tumor size, subtype, grade, Gd-DTPA enhancement and Ki67 LI, ANCOVAs, one-way ANOVA, ROC curve and Spearman's test were performed.

Results: Visual analysis: The diagnostic accuracy of individual FDG, MET, CHO PET/CT in brain tumor was 71.0%, 92.6%, and 61.4%, respectively. The accuracy of combined two or three tracers PET/CT is no more than that of MET PET/CT alone.

Semi-quantitative analysis: 1. The size of gliomas did not affect FDG, MET and CHO uptake; the grade affected the uptake of all three tracers; and gliomas subtype affected FDG and MET uptake only. The L/WM FDG and L/WM MET of oligodendroglial tumor was significantly higher than that of astrocytic tumor in the same grade. 2. There were significant differences between high-grade tumors and non-neoplasm lesions for the three tracers, but there was a difference between low-grade tumors and non-neoplasm lesions only for MET. 3. There were significant positive correlations between L/WM ratio of each tracer and Ki67 LI and Gd-DTPA enhancement in astrocytic tumors. The correlation between increased CHO uptake and Ki67 LI was more profound than with FDG and MET. However, for oligodendroglial tumors and oligoastrocytic tumors, the correlations were not shown for the three tracers.

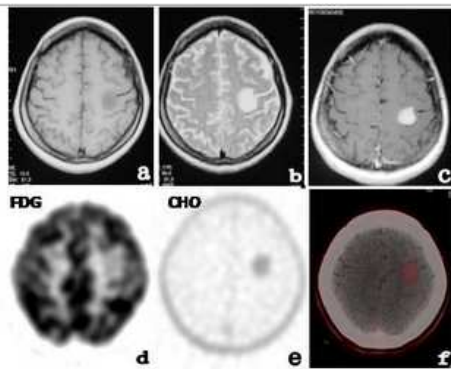


FIGURE 1: A 48-year old woman with cerebral infarction.

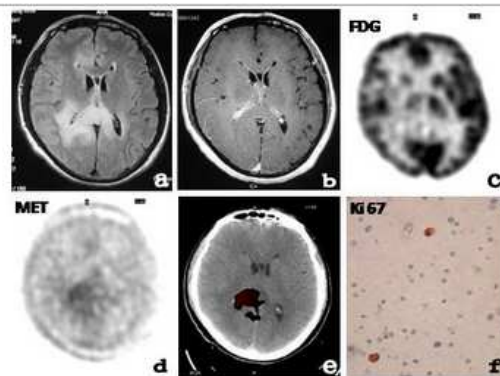


FIGURE 2: A 56-year old men with astrocytoma (WHO grade II).

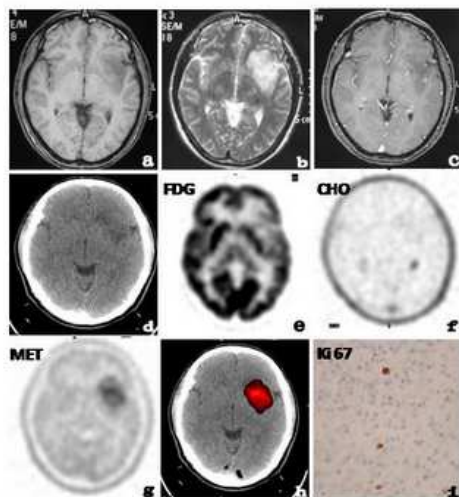


FIGURE 3: A 49-year old men with oligodendroglioma (WHO grade II).

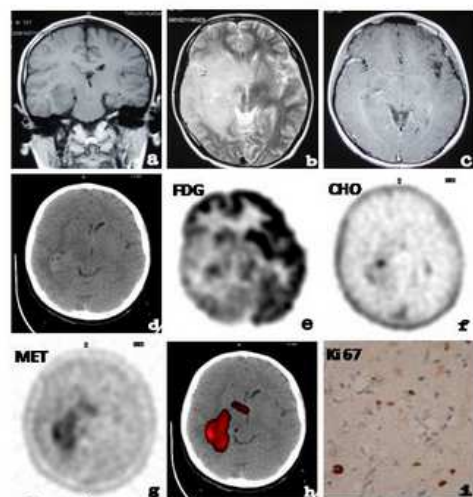


FIGURE 4: A 63-year old men with anaplastic astrocytoma (WHO grade III).

Conclusion: PET/CT with different tracers can provide complementary metabolic data that are independent of the anatomical MR information. Though ^{18}F -FDG exhibits limited utility in brain tumor imaging, it is still an initial and essential tracer for gliomas detection and grading. ^{11}C -MET is superior to ^{18}F -FDG and ^{11}C -CHO in detecting and delineating gliomas, especially low-grade gliomas and small lesions present in grey matter, but its role in grading is affected by gliomas subtype. ^{11}C -CHO can more effectively reflect the integrity of the blood brain barrier and proliferative activity than ^{18}F -FDG and ^{11}C -MET.

IAEA-CN-232/163

Integrated PET-CT for Evaluation of Mediastinal Lymph Node Staging of Non-Small Cell Lung Cancer in a Tuberculosis-Endemic Area: A Five Year Prospective Observational Study

J. Shaw, E. Irusen, F. Von Groote-Bidlingmaier, J. Warwick 1, B. Jeremic, R. Du Toit, C. Koegelenberg

Stellenbosch University

Corresponding Author: jw@sun.ac.za

Background: Integrated positron emission tomography/computed tomography (PET-CT) is a well-validated modality for assessing mediastinal lymph node metastasis in non-small cell lung cancer (NSCLC), which determines management and predicts survival. Tuberculosis (TB) is known to lead to false positive PET-CT findings.

Objectives: To assess the diagnostic accuracy of PET-CT in identifying mediastinal lymph node involvement of NSCLC in a highly TB-endemic area.

Methodology: Patients who underwent both PET-CT and lymph node tissue sampling for the investigation of suspected NSCLC were prospectively included in this observational study. Results were analysed per-patient and per-lymph node stage. A post-hoc analysis was performed to test the validity of a maximum standardised uptake value (SUVmax) cut-off for lymph node positivity.

Results: PET-CT had a sensitivity of 92.6%, a specificity of 48.6%, a positive predictive value (PPV) of 56.8% and a negative predictive value (NPV) of 90% in the per-patient analysis. Diagnostic accuracy was 67.2%. Similar values were obtained in the per-lymph node stage analysis. TB was responsible for 21% of false positive results. A SUVmax cut-off of 4.5 yielded an improvement in diagnostic accuracy from 64.0% to 84.7% compared to a cut-off of 2.5, but at the cost of decreasing the NPV from 90.6% to 83.5%.

Conclusion: In a highly TB-endemic area, PET-CT remains a valuable method for excluding mediastinal lymph node involvement in NSCLC. Patients with a negative PET-CT may proceed to definitive management without further invasive procedures. However, PET-CT positive lymph nodes require pathological confirmation, and the possibility of TB must be considered.

IAEA-CN-232/164

Role of Liver MRI and 18F-FDG PET/CT in Atypical Pattern of Metastatic Liver Melanoma

J. Sejoniene

Vilnius University hospital Santariškių klinikos

Corresponding Author: jurgita.sejoniene@santa.lt

Background: Annual melanoma morbidity rate is increasing in Lithuania like in the whole world. In cases of metastatic liver melanoma, it is usually not difficult to depict and define metastatic lesions neither in MRI scan (because of quite typical appearance, enhancement pattern, signs of aggression) nor in 18F-FDG PET/CT scan (because of evident focal hypermetabolism).

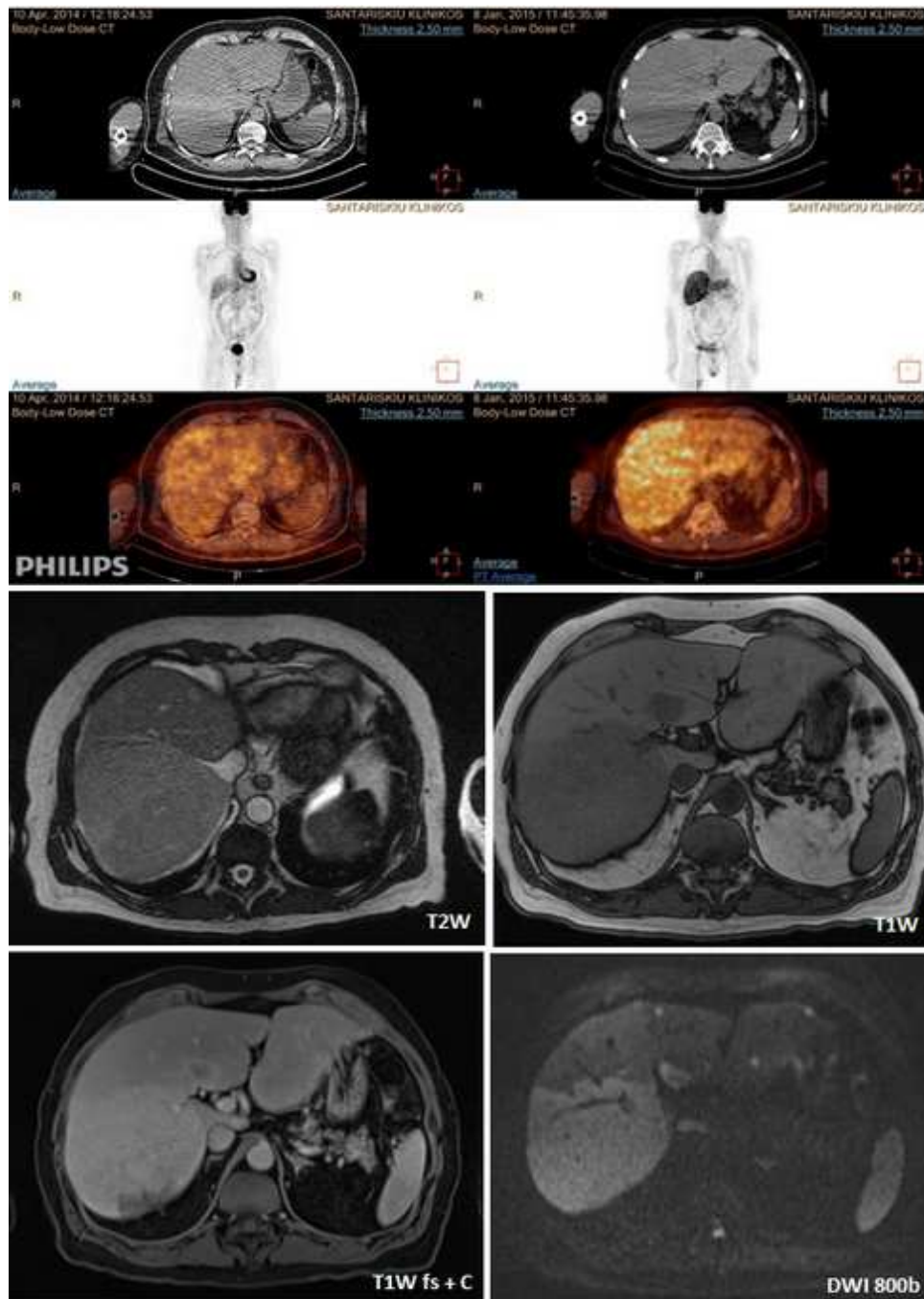
Methodology: We investigated a middle-aged male patient, who underwent primary head skin melanoma resection and subsequent total one side neck lymph node with sentinel lymph node dissection in March 2013. Lymph node histology discovered separate melanoma cells. The patient was assigned for further scrupulous exploration and treatment. Treatment with PEG-interferon and follow-up with CT, US and 18F-FDG PET/CT were assigned. The patient did not have disease progression until January 2015. In January 2015 whole body 18F-FDG PET/CT (Philips Ingenuity TF PET/CT) and liver MRI (Siemens MAGNETOM Avanto 1,5T) were performed due to clinical signs of potential liver impairment, and suspicion of disease progression.

Results: 18F-FDG PET/CT revealed a diffusely increased 18F-FDG uptake in the right hemiliver. No focal extrahepatic lesions with increased FDG uptake on whole body scan were found.

Polymorphic changes were found in the MRI scan. There was a bulky lesion in the right liver lobe involving the entire lobe. It looked unevenly hyperintense on T2W and hypointense on T1W; exhibited a moderate uneven diffusion restriction and inhomogeneous contrast material uptake (inhomogeneous worse uptake in lower subcapsular area), with compression (not invasion!) of hepatic veins. A similar, 3 cm size lesion was seen in the S4b segment. Also, MRI revealed multiple small foci in the left liver lobe, which were hyperintense on T2W, hypointense on T1W, bright on DWI images and exhibited medium intense contrast material enhancement. No focal 18F-FDG uptake was found in the left liver lobe on PET/CT.

As we did not find any clear information about focal liver hypermetabolism in non-specific hepatitis in the former literature, we treated the right lobe hypermetabolism as a huge solitary liver metastasis. The bigger lesions seen on MRI were treated as non-specific hepatitis like changes and the smaller ones were recognised as metastases.

Core needle biopsy of the metabolically active liver mass confirmed the melanoma metastases in the liver.



Conclusion: To our knowledge this is the first time to report the unusual pattern of metastatic melanoma using multimodality imaging. We think that the course of the disease and pattern of the latest findings in the liver is instructive and worth noticing, especially because very sensitive and/or specific research methods (FDG–PET/CT or MRI) alone could not assess the findings precisely.

IAEA-CN-232/165

**Occupational Radiation Doses to Personnel from 18F-FDG
PET/CT Procedures for Tumour Imaging in Ramathibodi
Hospital**

**M. Tuntawiroon, T. Donmoon, W. Chamroonrat, W. Changmuang, S.
Amnuaywattakorn, C. Sritara**

Mahidol University

Corresponding Author: wichana.cha@mahidol.edu

Background: The aims of this study are to evaluate the whole-body and finger radiation doses to radiopharmacists, nurses and technologists while performing duties with 18F-FDG PET/CT procedures for tumor imaging, and then to compare these results with the maximum admissible radiation doses prescribed by the ICRP.

Methods: The whole body radiation doses [Hp(10)] were measured with the digital semiconductor pocket dosimeter (ALOKA model PDM-112). The dosimeter was placed on the upper left side of white coat. The doses received by each medical staff were read directly from the dosimeter and recorded at the end of each procedure. The radiopharmacists, nurses and technologists performed procedures with 18F-FDG preparation, 18F-FDG administration and PET/CT imaging, respectively. The fingers radiation doses [Hp(0.07)] were measured by the new Optically Stimulated Luminescence Ring Type Dosimeter (OSLRD). Two OSLRDs were placed on the base of index finger of both hands. The exposed OSLRDs were read by using an OSL reader called MicroStar. The time spent for procedures of each staff was recorded. This study was conducted over a 4-month period.

Results: The results show that the mean whole body dose per study was 1.01 ± 0.03 (mean \pm SD), not detectable and 1.80 ± 0.48 μ Sv, for radiopharmacist, nurse and technologist, respectively. The mean finger doses per study were 265.89 ± 107.05 , 19.43 ± 2.67 and 4.59 ± 1.13 μ Sv, for radiopharmacist, nurse and technologist, respectively. These results were obtained from a sample of 65 studies. The mean spent times per study were 5.86 ± 0.05 , 1.20 ± 0.03 and 39.23 ± 2.03 minutes, for radiopharmacist, nurse and technologist, respectively. The technologists received the highest mean effective whole body dose per study and the radiopharmacists received the highest finger dose per study. Subsequently, we compared these exposure results with ICRP doses limit; we found that each staff could continue to work with 1200 18F-FDG PET/CT studies for a whole year without exceeding the limit.

Conclusion: This study proved that our staff could work safely within recommended safety levels of occupational radiation doses to which they are routinely exposed.

IAEA-CN-232/166

Role of [F-18] FDG PET-CT vis-à-vis [I-131] MIBG in Evaluation of Pheochromocytomas and Paragangliomas

N.S. Shah¹, M.G.R. Rajan², G. Malhotra², R. Kasiliwal¹,
A. Lila¹, R.V.Asopa²

¹Department of Endocrinology, KEM Hospital, Mumbai

²Radiation Medicine Centre, Bhabha Atomic Research Centre, Mumbai

Corresponding Author: maloounucmed@yahoo.com

Background: Pheochromocytomas and paragangliomas (Phaeo PGL) are mostly sporadic. Even though, functional imaging is essential during their workup, the role of F-18 FDG PET/CT imaging as compared to I-131 MIBG scans has been less studied. The aim of this study was to compare F-18 FDG PET findings with those of I-131 MIBG in patients with known Phaeo PGL.

Methodology: The study group comprised 47 consecutive patients of Phaeo PGL; 22 males [M] (mean \pm S.D = 36.7 ± 15.3 years) and 25 females [F] (mean \pm S.D = 32.8 ± 11.9 years). All patients underwent diagnostic I-131 MIBG and F-18 FDG PET-CT as per the institution protocol. Only those patients whose lesions showed uptake in at least one of the scans were included for analysis.

Results: 31 patients (16 M, 15 F) showed both I-131 MIBG and F-18 FDG avidity in the primary lesion (MIBG+ FDG+ group). 6 patients (3 M, 3 F) showed I-131 MIBG uptake in primary lesions but no significant F-18 FDG uptake (MIBG+ FDG- group). 10 patients (3 M, 7 F) had no I-131 MIBG uptake but significant F-18 FDG uptake (MIBG- FDG+ group). Average SUVmax \pm S.D in MIBG+ FDG+, MIBG+ FDG- and MIBG- FDG+ group was 9.7 ± 4.1 , 2.6 ± 0.76 and 22.4 ± 19.7 respectively in the three groups. SUVmax was significantly higher in MIBG- FDG+ group as compared to MIBG+ FDG+ group.

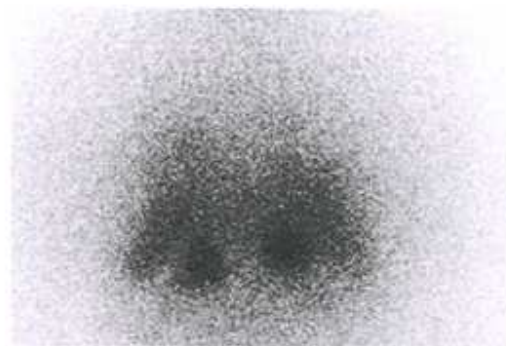
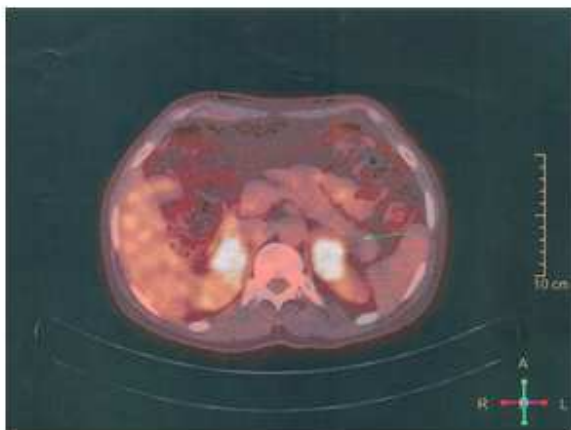


Fig 1. PET-CT of bilateral pheochromocytoma in a patient Fig 2. MIBG image of the same patient

Conclusion: F-18 FDG PET-CT should be included in the diagnostic protocol of all patients with pheochromocytomas and paragangliomas. F-18 FDG uptake is a molecular marker that correlates with

aggressiveness of the lesions which could be due to presence of dedifferentiated clones within the lesions.

The lesions with no or minimal F-18 FDG uptake are the least aggressive.

IAEA-CN-232/167

Evaluation of Efficacies and Clinical Impact of 68Ga-DOTATATE PET/CT and 18F-FDG PET/CT in the Diagnosis of Recurrent or Metastatic Medullary Thyroid Carcinoma: A Comparative Study in Patient with a Raised Calcitonin Level

**B.R Mittal¹, R.V. Parghane², R.K. Phulsunga², A. Bhattacharya²
J.Shukla²**

¹ Postgraduate Institute of Medical Education & Research, Chandigarh, India

² PGIMER, Chandigarh

Corresponding Author: brmittal@yahoo.com

Background: Among thyroid cancers, medullary thyroid carcinoma (MTC) has more specific features, such as the production and secretion of large amounts of peptides leading to high levels of calcitonin in the serum, which acts as tumor marker for the presence of persistent or metastatic MTC. Therefore, an imaging modality is required that can detect persistent or metastatic disease in MTC patients with raised calcitonin levels. The aim of this study was to evaluate and compare the effectiveness and clinical impact of 68Ga-DOTATATE PET/CT and 18F-FDG PET/CT in the detection of recurrent or metastatic disease in MTC patients with raised calcitonin levels.

Methodology: We retrospectively evaluated 29 histologically diagnosed MTC patients (12 men, 17 women, median age: 43 years) with raised calcitonin levels who underwent 68Ga-DOTATATE and 18F-FDG PET/CT within intervals of 2 weeks. Eight patients underwent PET scan before complete thyroidectomy with two having multiple endocrine neoplasia 2 (MEN II) syndrome. Both visual and quantitative analyses were performed in 68Ga-DOTATATE and 18 F-FDG PET/CT studies and tracer avid lesions were recorded. The lesions verification was done by tissue diagnosis in 8 patients, follow up PET scan in 9 patients; further imaging and clinical follow-up in 12 patients.

Results: The mean serum calcitonin level was 1715.4 pg/ml (range of 300-5000 pg/ml). The mean value of SUVmax was 6.9 (range of 4.1-10.0) and 6.3 (range of 3.1 -13) for 68Ga-DOTATATE and 18F-FDG respectively. 68Ga-DOTATATE PET/CT was true positive in 15 patients with a sensitivity of 78.9% [95% confidence interval (CI) 54.4% -93.8%] and a specificity of 100% [95% (CI) 68.9%-100%], whereas 18F-FDG PET/CT was true positive only in 8 patients with a sensitivity of 42.1% [95% (CI) 20.3%-66.4%] and a specificity of 50.0% [95% (CI) 18.8%-81.1%] for diagnosing recurrent metastatic MTC. 68Ga-DOTATATE PET/CT detected extra lesions over 18F-FDG PET/CT in 7 patients (cervical lymph nodes in 3 patients, bone lesion in 3 patients, lung lesion in 1 patient). 18F-FDG PET/CT was false positive in 5 patients mainly due to inflammatory changes involving axillary and mediastinal lymph nodes. Based on 68Ga-DOTATATE PET/CT finding, 2 patients received peptide receptor radionuclide therapy (PRRNT) and 3 patients received chemotherapy.

Conclusion: 68Ga-DOTATATE PET/CT is more sensitive and specific as compared to 18F-FDG PET/CT imaging for detection of recurrent or metastatic disease in MTC patients with a raised calcitonin level. It can be a used as imaging tool to identify MTC patients suitable for PRRNT therapy.

IAEA-CN-232/168

Clinical Role of 18F-Fluorodeoxyglucose Positron Emission Tomography/ Computed Tomography (18F-FDG PET/CT) for Detecting Recurrence in Follow up Cases Of Gastric Cancer after Surgery

R. Parghane¹, B. Mittal², A. Bhattacharya³

Department of Nuclear Medicine & PET center, PGIMER Chandigarh

Corresponding Author: rahul_parghane@yahoo.co.in

Background: Gastric cancer is a leading cause of cancer death worldwide. Complete resection offers the only chance for permanent control and evaluation of treatment response is crucial for appropriate management. The aim of this study was to evaluate the role of 18F-FDG PET/CT scan in detection of recurrence in gastric cancer patients after surgery.

Methodology: We retrospectively evaluated 26 patients (F=5, M=21, age range between 34 to 74yr) with gastric cancer. All patients underwent 18F-FDG PET/CT scan for detection of recurrence after surgery; the scan was performed using standard protocol with quantitative PET analysis, using the standardized uptake value (SUVmax). CECT (regional) of the abdomen and chest was acquired before the PET scan and after surgery with maximum interval between CECT and PET scan of 4 weeks (1-4 week). The lesions verification was done by tissue diagnosis in 4 patients, follow up PET scan in 10 patients; further imaging and clinical follow-up in 12 patients. Follow up was done in all patients with minimum duration of 1 year after surgery.

Results: All patients were subjected to surgical intervention (subtotal or total gastrectomy). 18F-FDG PET/CT scan showed recurrence in 14 patients, including 3 patients with FDG avid lytic bony lesions, 3 patients with FDG avid lesion in pancreas, 2 patients with FDG avid omental deposits, 1 patient each with FDG avid supraclavicular lymph node and liver lesion. Out of 14 patients, 12 patients showed FDG uptake in anastomotic site and 5 patients showed FDG uptake in regional lymph nodes. 1 patient showed false positive FDG uptake due to post-operative changes, and on follow up scan showed no FDG uptake in anastomotic site, and 2 patients showed false negative results due to non FDG avid nodules in the lung. 18F-FDG PET/CT scan detected recurrence in (14/26) patients with sensitivity of 87.5% and accuracy of 88% with mean SUVmax of 6.0 (range, 0.5 –16.8), whereas CECT (regional) showed lower sensitivity (68%) and accuracy (65%) for detection of recurrence. The survival rate for patients with high FDG uptake (SUV>4) was significantly lower than for those with low FDG uptake (SUV<4) (p<0.05).

Conclusion: 18F-FDG PET/CT provides useful information in differentiating true recurrence in postoperative patients of gastric cancer with high sensitivity and accuracy and has a significant impact on clinical management of these patients.

IAEA-CN-232/169

**Indication Appropriateness of 18F-FDG PET/CT
Examination in the Dharmais National Cancer Hospital**

S. Hikmawati, K. Kardinah

Dharmais National Cancer Hospital

Corresponding Author: hsariningsih@yahoo.co.id

Background: In the last decade the use of PET/CT, especially in the field of oncology, is growing rapidly. 18 F-FDG is the most widely and commonly used radiopharmaceutical. Although there are several other radiopharmaceutical agents, they are yet not used as widely. In oncology, there are indications that compared to conventional imaging, PET/CT is more sensitive and specific, so as to change the management of patients such as with respect to diagnosis, staging, response to therapy, and patient treatment.

PET/CT is a high-tech modality. Although it is expected to provide optimal impact on the patient treatment, it is costly, and therefore requires a careful evaluation of utilization. In view of this, the IAEA has produced guidance on the use of PET/CT in oncology that can be used as a reference. In the IAEA publication, the use of PET indications is divided into: appropriate, potentially appropriate, possibly appropriate or inappropriate. Appropriate in this case is proven to improve the diagnosis with high sensitivity and specificity.

The purpose of this study was to determine the accuracy of the indication of 18F-FDG-PET/CT scan in The Dharmais National Cancer Hospital.

Methodology: Retrospective study on 537 patients undergoing examination from May 2012 to March 2013. The results revealed 5 most common cancers examined with 18F-FDG PET/CT: 150 patients with breast cancer, 55 malignant lymphoma, 37 lung cancer, 35 colon cancer and 31 with cervix cancer. Indication was evaluated in accordance with the recommendations of the IAEA, i.e. diagnosis, staging, evaluation of response to therapy and recurrence.

Result: The percentage of 18F-FDG PET/CT scans with indication to determine the diagnosis was 17.3%. Staging was indicated in 8.0%, the largest group being lung cancer with 3.0 %. Therapeutic response evaluation was indicated in 49.9%, the largest group being breast cancer with 18 %. 22.3% scans were performed for evaluation of recurrence, the largest group being breast cancer with 7,8 %. Unknown primary was 2.4%.

Conclusion: 18F-FDG PET/CT is a modality that has a high sensitivity and specificity when used in accordance with appropriate and obvious indications. In this study, 18F-FDG PET/CT was shown to be more widely used for the evaluation of therapeutic response and evaluation of recurrences.

IAEA-CN-232/174

**Challenges in Setting up a Nuclear Medicine and PET Training
Programme: Triumphs and Tribulations, the Malaysian Experience**

M.A. Abdul Khader¹ I.L. Shuib², A. Khoo³

¹ PET Imaging Center, Mount Miriam Cancer Hospital

² Advanced Medical Dental Institute, Science University of Malaysia

³ Department of Nuclear Medicine PET CT Center, Penang Hospital, Malaysia

Corresponding Author: dr mali31@hotmail.com

Background: The nuclear medicine service in Malaysia had its humble beginning in the early 1960s with the first facility as a unit under the Department of Radiotherapy based in Kuala Lumpur Hospital. Progress and expansion was slow with the presence of 4 facilities setup from 1960 to 1990. In 2002 through the collaboration with the IAEA and other stakeholders utilising radiation and spearheaded by the Ministry of Health Malaysia a roadmap for the future expansion of nuclear medicine service was chartered. Major decisions regarding the administration, service, infrastructure, finance, manpower and training were discussed and subsequently implemented incrementally over the years. From four facilities in 1990, in the year 2014 there are sixteen nuclear medicine centres, ten PET-CT scanners and four cyclotrons in Malaysia. The service provided has expanded from diagnostic work in the early 1960s to the present service having diagnostic and therapeutic services and from having just planar camera to having SPECT/CT and PET/CT hybrid imaging cameras.

In terms of training, the MOH together with a local university has embarked on a 4 years Masters in nuclear medicine training programme.

Methodology: Before approval and implementation of the training programme, certain procedures had to be undertaken to convince the approving authorities with regard to the cost effectiveness and sustainability of the programme and how it will benefit the nation.

The following tasks were carried out:

- a. Nationwide survey as to the requirements of the training programme
- b. Data collection from 10 countries
- c. Syllabus formulation
- d. Entry criteria
- e. Programme structure
- f. Candidate assessment throughout programme
- g. Graduation
- h. Recognition of graduates and placement in workplace

Results: Being implemented from 2008, this year saw the 8th batch of intake. A total of 16 nuclear medicine specialists have graduated from this training programme. Graduates from this training programme have to further undergo six months of practicing period in a recognised nuclear medicine setup before they are placed in regional hospitals to function as nuclear medicine specialists throughout the country.

Before the training programme there were four nuclear medicine specialists in the country. As a result of this training programme, currently there are 22 nuclear medicine specialists in total serving in the Ministry of Health hospitals, universities and private hospitals. With this ongoing training programme the

shortage of current nuclear medicine specialists can be overcome and the future requirement can be met.

Conclusion: Here, we describe the progress and development of nuclear medicine service in Malaysia from the 1960s to the present. The collaboration with and assistance of IAEA has helped charter the expansion of nuclear medicine from the era of planar imaging to clinical PET-CT and molecular imaging in the era of multimodality imaging in Malaysia and also in the training of categories of personnel in the nuclear medicine setup. In the poster, we will outline the triumphs and tribulations encountered during the transformation and will also present plans for future development of nuclear medicine in the country.

IAEA-CN-232/175

The Role 18F-FDG PET/CT in Rare Disseminated Pelvic Yolk

Sac Tumour: A Case Report

D. Jocius¹, D. Vajauskas²

¹ Vilnius University Hospital Santariskiu Clinics

² Vilnius University hospital Santariskiu clinics

Corresponding Author: jocius.donatas@gmail.com

Background: Yolk sac tumour (YST) is a rare, fast growing germ cell malignancy mostly affecting children and young adults. Although YST mostly occurs in gonads, 10-20% may arise in extra gonadal sites along the path of natural way in which gonads descend during embryogenesis from cranial cavity to pelvis. Although there are no particular data prescribing the use of 18F-FDG PET/CT in YST nor direct evidence of metabolic activity of YST, several case reports refer the usefulness of 18F-FDG PET/CT in initial staging and response evaluation showing promising results.

Methodology: We present a case of a 22 year old woman presenting at emergency department complaining with right lower abdomen pain, febrile fever, intermittent rectal bleeding and palpable mass in pelvis. Initial laboratory tests showed leucocytosis and elevated CRP. On ultrasound huge inhomogeneous masses were found in pelvis and abdomen with metastatic liver nodules.

On the next day diagnostic laparotomy and pelvic tumor biopsy was performed. During the procedure uterus and ovaries appeared macroscopically normal. Extended laboratory tests showed extremely elevated α -fetoprotein (AFP), a finding suggesting germ cell tumor.

Initial whole body contrast enhanced computed tomography (CECT) performed for staging showed multiple heterogeneous vascularized tumor masses throughout peritoneal cavity with multiple hepatic metastases.

Pathologic examination of tissue sampled during diagnostic laparoscopy revealed yolk sac tumor. Due to advanced tumor stage (cT3NxM1) initial chemotherapy with four BEP (bleomycin, etoposide, cisplatin) cycles was initiated.

After initial treatment (4 BEP cycles) whole body CT revealed 70% decrease of tumor size showing all masses as necrotic, AFP at that time was within normal limits. For assessment of residual metabolic disease 18F-FDG PET/CT was performed from skull base to mid thighs.

Results: On 18F-FDG PET/CT scan one omental and two pelvic masses with increased 18F-FDG uptake were depicted. No other focal lesions of increased FDG uptake on body scan were found.

The 18F-FDG PET/CT imaging results did not match the clinical data of the disease - normal AFP values and diminished anatomical tumor size on CECT.

Patient was operated laparoscopically; left salpingo-oophorectomy was performed in addition to excision of residual "vital tumor" masses from abdomen and pelvis. YST was histologically confirmed.

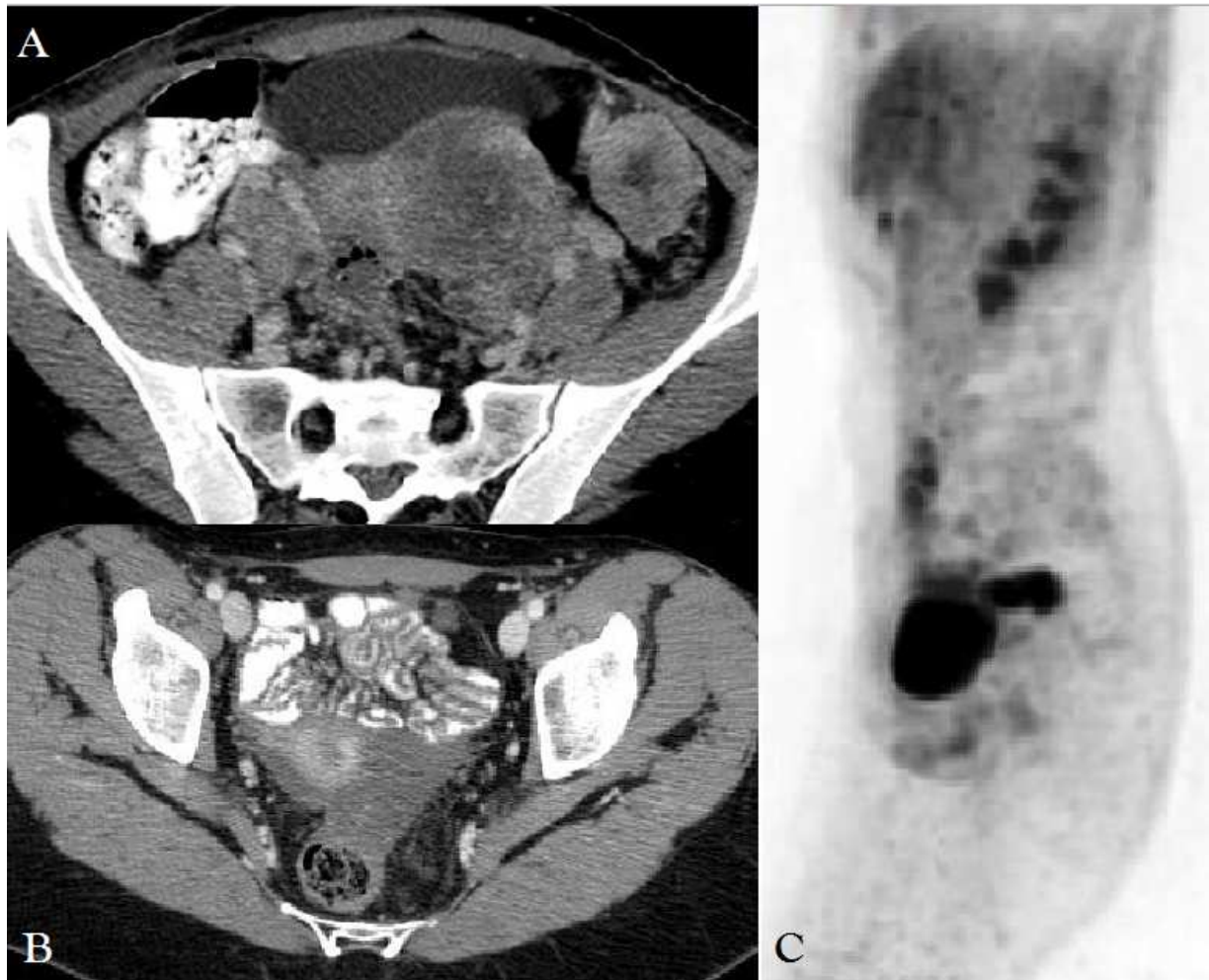


Figure 1. A – pre-treatment CT: heterogeneous vascular tumor in pelvis ; B – post-treatment CT: diminished tumor masses; C – post-treatment FDG PET/CT: showing same masses as in B with elevated FDG uptake.

Conclusion: Our case of YST showed that ^{18}F -FDG PET/CT is a valuable tool to evaluate residual YST tumor cells after first line chemotherapy. This also supports the usage of ^{18}F -FDG PET/CT for initial staging of YST, assuming that it is an ^{18}F -FDG avid tumor.

Moreover, ^{18}F -FDG PET/CT as tumor viability marker may have benefits over AFP measurement as normal result can be false-negative, thus leading to treatment delay and probably worse prognosis.

IAEA-CN-232/177

Prognostic Utility of Quantitative Metabolic Parameters Derived from Sequential FDG PET/CT Imaging in Patients with Oesophageal Squamous Cell Carcinoma

A. Gorla¹, B.R. Mittal², R. Guptha³, A. SOOD⁴, R. Kumar⁵, A. Bhattacharya³

¹ Senior Resident

² Postgraduate Institute of Medical Education & Research, Chandigarh, India

³ Professor

⁴ PGIMER

⁵ Post Graduate Institute of Medical Education and Research Chandigarh, India

Corresponding Author: arunreddy2004@gmail.com

Background: The aim of this study was to evaluate the utility of quantitative metabolic parameters derived from sequential (pre and post treatment) F18-fluorodeoxy glucose positron emission tomography / computed tomography (FDG PET/CT) imaging in predicting the survival of patients with esophageal squamous cell carcinoma treated with chemo-radiotherapy.

Methodology: In this study, we evaluated a total of 48 biopsy proven cases of esophageal squamous cell carcinoma treated with chemo-radiotherapy. Pre-treatment F-18 FDG PET/CT (PREPET) was performed before the initiation of treatment and post-treatment F-18 FDG PET/CT (POSTPET) was performed at least 3-6 weeks after last day of chemo-radiotherapy (4 cycles of chemotherapy + local radiotherapy). All the patients were fasted for a minimum duration of 4-6 hours and F-18 FDG PET/CT was acquired 45 min after the injection of 370 - 440 MBq of F-18 FDG. Blood glucose levels were < 110 mg/dl in all the patients prior to the injection. PREPET and POSTPET studies were analysed for quantitative parameters including maximal standardized uptake value (SUV_{max}), metabolic tumor volume (MTV), total lesion glycolysis (TLG) individually using PET VCAR software (GE Healthcare, USA) and percentage change in parameters was calculated as the difference Δ PRE-POST/PRE. Semi-automated isoactivity contour VOI generation using gradient threshold segmentation algorithm was utilized to obtain these parameters. Primary outcome variable was survival from the time of completion of treatment.

ROC analysis was utilized to determine the cut-off and Cox Proportional Hazard Regression Model was used for statistical analysis. A p value <0.05 was considered statistically significant.

Results: A total 48 patients (28 males, 20 females; Age range 38-85 yrs; mean 53.2 yrs) were evaluated. Mean duration of follow up was 26 +/- 9 months; range 13-54 months. 17 patients died from the disease on follow up (mean survival 8 +/- 2 months, range 1 -18 months). MTV_{PRE}, TLG_{PRE}, MTV_{POST}, Δ MTV and Δ SUV_{max} exhibited greater accuracy than rest of the parameters on ROC analysis (area under curve AUC 0.846, 0.723, 0.796, 0.816 and 0.712 respectively) for prediction of overall survival. Kaplan Meier curves were drawn utilizing the cut-offs derived from the ROC AUC data. On univariate analysis, MTV_{PRE}, TLG_{PRE}, MTV_{POST}, Δ MTV and Δ SUV_{max} had strong statistical significance on overall survival with a negative regression coefficient of 2.24, 1.93, 1.97, 2.21 and 1.99 respectively. No significant statistical association was found with

SUVPRE, SUVPOST, TLGPOST and % Δ TLG.

Conclusion: Quantitative parameters derived from F-18 FDG PET/CT are adjunctive tools readily available for assessment of the metabolic tumor burden. Our study showed that some of these have significant role in the prediction of overall survival of patients with esophageal squamous cell carcinoma. We conclude that the utilization of these parameters may have a role in tailoring therapeutic interventions and thus affect overall outcome of the patient.

IAEA-CN-232/178

Radiochemical Characterization of a ⁶⁸Ga-Labelled PSMA Inhibitor for Prostate Cancer Imaging

V. Trindade ¹, N. Bentancor ², H. Balter ², H. Engler ²

¹ Uruguayan Centre of Molecular Imaging (CUDIM)

² Uruguayan Center of Molecular Imaging (CUDIM)

Corresponding Author: victoria.trindade@tudim.org

Background: Prostate-specific membrane antigen (PSMA) is a membrane associated zinc protease, expressed in nearly all prostate cancers with increased expression in poorly differentiated, metastatic and hormone-refractory carcinomas.

The urea-based inhibitors of PSMA exhibiting Glu-NH-CO-NH-Lys are excellent pharmacophores to bind PSMA. Its labelling with ⁶⁸Ga is an attractive generator-based alternative to cyclotron PET radiopharmaceuticals.

N,N'-bis[2-hydroxy-5-(carboxyethyl)benzyl]ethylenediamine-N,N'-diacetic acid (HBED-CC) is an acyclic complexing agent that allows efficient radiolabeling with ⁶⁸Ga, even at room temperature. This chelator attached to Glu-NH-CO-NH-Lys has an improved binding to PSMA due to the interaction of their aromatic groups with a lipophilic part of the binding site, which is different from that interacting with urea-based inhibitors.

Our aim was the radiolabeling optimization of Glu-NH-CO-NH-Lys(Ahx)-HBED-CC with ⁶⁸Ga and the stability evaluation at room temperature (RT) of different incubation conditions. Also the radiochemical purity (RP) determination was optimized in order to separate different diastereomers as well as potential impurities.

Methodology: ⁶⁸Ga was available from a ⁶⁸Ge/⁶⁸Ga generator. Labelling of Glu-NH-CO-NH-Lys(Ahx)-HBED-CC with ⁶⁸Ga (360MBq in 1000μL HCl 0.05M) was optimized varying the amount of the precursor from 0.04 to 1.25μg (0.04-1.32nmol). Reaction pH 4.0 was adjusted with 250μL NaOAc 0.25M. Incubation was done at RT or 100°C.

The reaction was stopped at different incubation times (1 to 5min) by addition of an excess of gallium nitrate in order to study the kinetics.

Stability studies for each of these conditions were done.

RP was controlled by RP-HPLC, Chromolith® C18 column, 100x4.6mm, testing different solvent gradients of A (0.1% TFA in water) and B (0.1% TFA in acetonitrile) and flow (1 to 4 mL/min). The presence of ⁶⁸Ga-colloid was analysed by Instant Thin-Layer Chromatography Silica Gel impregnated glass fibre (ITLC-SG) in MeOH:NH₄OAc.

Results: ⁶⁸Ga was totally bound to the precursor from amounts of 0.32nmol, giving a maximum specific activity of 1171MBq/nmol. There was evidence that the ⁶⁸Ga incorporation to the precursor formed two diastereomers, which were isolated with the solvent gradient optimized from the fifteen systems tested.

The reaction conditions were optimal when incubation was done at 100°C for at least 5min.

We observed a conversion of the more lipophilic diastereomer into the more hydrophilic one. Rate of conversion was positively correlated with the temperature and time of incubation, as well as with the time elapsed after labelling. Radiochemical impurities with higher retention times than the diastereomers in our RP-HPLC system were revealed and maintained in less than 10% for all conditions.

Conclusion: Two diastereomers were isolated from the radiochemical impurities and from free ^{68}Ga with the optimized HPLC system. More research is required to determine the molecular recognition of each diastereomer. The high specific activities required for the clinical application of this promising agent for diagnosis of prostate cancer, require careful control of the ratio activity/ precursor as well as incubation temperature and time.

IAEA-CN-232/180

Quality Management System in the Production of Radiopharmaceuticals at the Uruguayan Centre of Molecular Imaging

A. Rey, H. Engler, J. Giglio, I. Sanz, H. Balter, E. Savio

Centro Uruguayo de Imagenología Molecular, Uruguay

Corresponding Author: arey@fq.edu.uy

The Uruguayan Centre of Molecular Imaging (CUDIM) is a unique centre in the country performing molecular imaging studies of oncological, neurological and cardiovascular diseases. CUDIM started with activities in 2010 and is currently producing 13 different radiopharmaceuticals for clinical applications (18F labeled: FDG, FLT, FMISO, Fluorine; 11C labeled: Choline, Methionine, PIB, Deuterodeprenyl; 68Ga labeled: DOTA-TATE, Gallgas, PSMA; 15O labeled: H2O; 13N labeled: NH3). Due to the short half-lives of the radionuclides, aseptic processing, parametric release of the product batch and the radiation protection requirements, special handling during their manufacturing is required.

With the objective to fulfil all these requirements, a quality assurance programme has been established in our facility. Radiopharmaceuticals are manufactured according to Good Manufacturing Practices (GMP). This requires the application of validated processes and procedures for production and tests. GMP guidelines are the basis for manufacturing radiopharmaceuticals. Quality management of the finished products and the integration with the internal policies and procedures of the Centre have been achieved through a well-defined and executed quality management system (QMS). The implementation and supervision of the system are responsibility of the internal Quality Committee of CUDIM, which is integrated by representatives of each working area and lead by an external responsible. In Uruguay, quality control of radiopharmaceuticals is performed according to the specifications of either the United States or the European Pharmacopeia (USP or EP). Both are officially accepted in the country.

Our QMS has established the specifications according to published references when the radiopharmaceutical is not included in USP and EP. Documentation is one of the key issues to achieve a good quality assurance programme. Consequently the following documents have been created and are used as a tool of the GMP system:

- a) Site Master File (SMF), including information about the quality management policies and all the activities of CUDIM.
- b) Manuals (Radioprotection Manual, Emergency Manual)
- c) Standard operation procedures (SOP) for production and QC of each radiopharmaceutical
- d) Guidelines for operation and maintenance of each equipment used for this purposes
- e) Batch reports
- f) Reports of working conditions (environmental, equipment, staff, etc.)
- g) A validation plan is under development, including production, quality control and staff management.

Having highly educated personnel is another challenge for a QMS system. Specific training has also been provided to implement a continuous education programme. These high standards have been achieved with the support of the IAEA cooperation that provided fellowships and expert missions.

In conclusion, GMP production of radiopharmaceuticals in CUDIM has been of fundamental importance for the realization of 11.000 studies in the last 4 years performed with high quality and safe radiopharmaceuticals.

IAEA-CN-232/181

Implementation of a Flexible Radiopharmacy Postgraduate Programme in Uruguay for the Region: Acting Locally, Thinking Globally

A. Rey, M. Terán, A. León, E. Savio

Cátedra de Radioquímica, Facultad de Química, Uruguay

Corresponding Author: arey@fq.edu.uy

Radiopharmacy education at university level is not easily accessible and most professionals in this area have been trained in the working place. However, increasing complexity of the field and requirements of regulatory authorities demand deeper knowledge. In Uruguay there is a long history of education in radiopharmacy at pregraduate level developed in the Faculty of Chemistry and in the Faculty of Science. Both institutions also offer the possibility to obtain Masters and PhD degrees in the area of radiopharmacy. However, radiopharmacy practice in hospitals requires specific training which can be achieved through a more focused postgraduate programme.

With the objective to offer specific education to professionals working in hospital radiopharmacy, the Faculty of Chemistry is offering a new postgraduate programme in radiopharmacy, designed to cover these needs that will start in the second semester of 2015.

The programme is open for university graduates in chemistry, pharmacy and biochemistry. A special commission will study applications of students from other areas and decide if their previous education is adequate. Students from other countries can also be accepted after evaluation of their application by the same commission. The programme includes approximately 300 hours of lessons, both theoretical and practical and 300 hours of a supervised professional practice in an accredited radiopharmacy. The courses will be organized by the Faculty or by other accredited institutions, both from Uruguay or other countries. E-learning courses can also be part of the curricula. The syllabus includes basic compulsory areas (radiopharmacy, clinical applications of radiopharmaceuticals, radiation protection, quality assurance, GMP, legislation and research, and development in radiopharmacy) and elective areas (depending on the previous education of the applicant) in pharmacology, pharmaceutical technology, coordination chemistry, organic chemistry and analytical chemistry. A maximum of half of the required theoretical credits could be validated if the applicant has previously attended courses relevant to the field, in universities or institutions of adequate academic level and they had an appropriate evaluation. The supervised professional practice can be performed in public or private radiopharmacies in Uruguay or other countries, provided they have adequate infrastructure and are under the responsibility of a radiopharmacy professional. Both the radiopharmacy and the tutor have to be previously accredited by the Faculty for this purpose.

In conclusion, the radiopharmacy postgraduate programme in Uruguay offers specialized education to professionals who want to practice hospital radiopharmacy in Uruguay or in other countries. It is flexible, not only because it recognizes previous education of candidates, but also allows the possibility to perform the professional practice in the country of origin under the supervision of the University of Uruguay. It also encourages the cooperation and complementation of capacities and experience between different institutions and professionals from Uruguay and other countries in the region.

IAEA-CN-232/182

18F-FDG PET/CT in Detecting Carcinoma Unknown Primary

Y. Tuti

RS Kanker Dharmais

Corresponding Author: use_tia@yahoo.co.id

Background: Carcinoma of unknown primary (CUP) is one of the ten most common types of cancer worldwide. This disease is pathologically proven as metastatic malignant disease without an identifiable primary site. These tumors are categorized by pathology into well and moderately differentiated adenocarcinoma, poorly differentiated carcinomas (including poorly differentiated adenocarcinomas), squamous cell carcinomas, undifferentiated neoplasms, and carcinomas with neuroendocrine differentiation. Detecting the primary site in CUP can improve and optimize patient treatment and prognosis. F-18 FDG PET/CT shows high sensitivity in detecting the primary site. The aim of this study is to evaluate the ability of F-18 FDG PET/CT to detect primary tumors in patients presenting with CUP.

Methodology: Sixty one patients presenting with metastatic malignancy identified pathologically underwent F-18 FDG PET/CT imaging at the Dharmais Cancer Hospital in Jakarta between June 2012 and December 2014. Patients with metastasis of lymphadenopathy colli (38), inguinal (2), axilla (1), pleural effusion (11), pericardial effusion (1), abdominal mass (2), ascites (1) and bone (5) were included. The findings were compared to histology, laboratory and other imaging studies.

Results: Thirty seven patients were excluded; F-18 FDG PET/CT showed a primary tumor site, but this was not confirmed by histology. Twenty four patients were eligible for analysis. F-18 FDG PET/CT imaging accurately identified the primary site in 16 patients (66.6%) with diagnosis confirmed by histology. The primary tumor sites were lung (7), nasopharynx (2), thyroid (1), breast (1), ovaries (1), cervix (1) and prostate (1). Two patients had an inflammation process of the tractus intestinalis and lymphadenitis colli. No primary tumor was found on F-18 FDG PET/CT imaging in the other 5 patients (20.8%). In the remaining three patients (12.5%), F-18 FDG PET/CT identified the primary of the CUP, but histological results showed benign thyroid, chronic inflammatory and fungal infection process in the lungs.

Conclusion: This study has demonstrated that F-18 FDG PET/CT imaging is an appropriate diagnostic tool to detect the primary tumor in cases of CUP, with a detection rate of 66%. Lung carcinoma was the most frequently reported primary tumor.

IAEA-CN-232/183

Design of Inexpensive, Robust and Non-Interactive Waste Water Retention Tanks for Diagnostic and Therapeutic Nuclear Medicine Facilities

H. Speckter

CEDIMAT

Corresponding Author: hspeckter@cedimat.net

Background: A large amount of the administered radioisotopes in nuclear medicine are excreted to urine. According to the literature, 55% of administered activity of I-131 is excreted in the first 24 hours and 85% of the administered activity is discharged in the sewer over a typical patient-stay period of 5 days. Radioactive waste water from nuclear medicine procedures can be dealt by simply storing the wastes safely until radioactive decay reduces the activity to a safe level before releasing it into the general sewage system. Several designs for waste water retention tanks for diagnostic and/or therapeutic nuclear medicine facilities have been proposed. Generally, these retention systems involve more or less professional attention on a regular base for correct operation and compliance with safety regulations. Especially in developing countries there is a need for inexpensive solutions and for systems that do not require particular professional attention.

Methodology: Commonly, diagnostic nuclear medicine facilities produce a relatively high volume of short life isotope waste water from imaging procedures, especially technetium Tc-99m; meanwhile therapeutic nuclear medicine applications, especially iodine therapy with I-131, contribute a relatively smaller volume of longer active waste water. For this reason we completely separated toilets for diagnostic nuclear medicine patients, from toilets and showers for therapeutic patients and additionally from any other hospital waste water system. 2 different waste water retention tanks were designed: a 4 septa tank of 2m³ volume (size at CEDIMAT) for the waste water from diagnostic imaging and a 6 septa tank of 20m³ volume (size at CEDIMAT) for waste water from therapy patients. Both tanks are designed to comply with the following objectives: comply with exposure limits close to the tanks, comply with discharge limits for radioactive liquids, to be virtually non-interactive, to be inexpensive to construct and to operate, to resist minor earthquakes and hurricanes, scalable design according to expected patient volume.

Results: Since installation in April 2011 the function and compliance of both tanks were monitored on a regular basis. Both tanks are fully functional and comply with both exposure limits and discharge limits. The average monthly maximum limit of discharge for I-131 is 22.2 MBq/m³. Exposure rates close to the systems were measured and always found to be less than 0.2 µSv/h, which is close to natural background. Discharge activity was monitored and calculated to be constantly less than 10 MBq/m³ per month. Patients in nuclear medicine have to cooperate, not tossing solid materials into the toilet and are asked not to use the shower for more than 10 minutes.

Conclusion: So far 2 systems of this design have been installed; one in the Centro Nacional de Radioterapia CNR, Managua, Nicaragua (under IAEA project NIC6010), and another system at CEDIMAT, Santo Domingo, Dominican Republic. Both systems are fully functional and comply with all above mentioned objectives. The design may be of great benefit for nuclear medicine facilities, not only in developing countries.

IAEA-CN-232/184

**Low Diagnostic Value of Invasive Coronary Anatomical
Imaging Performed after ECG-stress Test in Patients with
Supposed Ischemic Heart Disease**

N. Maroz-Vadalazhskaya¹, E. Slobina²

¹ ASNC

² National Center of Psychyc Health of Belarus

Corresponding Author: n_moroz@mail.ru

Background: Low availability of nuclear imaging in cardiology correlates strongly with a high rate using of invasive anatomical imaging, which could be performed in patients with minor or atypical signs of ischemic heart disease immediately after an ECG test. The direct cost of invasive coronary angiography (CAG) as well as radiation exposure (RE) during the procedure is higher than with myocardial perfusion tests with nuclear tracers. Nevertheless, hospitals with low acceptance of functional myocardial imaging demonstrate a relatively high rate of invasive anatomical imaging of coronary arteries (CA) with low rate of subsequent coronary stenting procedure.

The aim of this study was to estimate the total diagnostic score of invasive CAG in stable patients after an ECG test. The data of CAG (CA obstruction and following stenting) were analysed.

Methodology: The study cohort included 275 stable patients with angina class II and mild or atypical angina symptoms, who were admitted to the Cardiology Department with a catheterization laboratory unit directly for CAG. Data of patients were collected during a 12-month period. Patients with acute coronary syndrome and patients planned to undergo a heart valve replacement were excluded. Before CAG all patients underwent bicycle ECG-test, which was stopped due to hypertensive response (32%), atypical chest pain (17%), breathlessness (8%), non-significant depressed ST segment (14%), inversion of T wave (19%), arrhythmia (6%) and A-V block (4%). Left ventricular hypertrophy (from mild to significant) was revealed in 53% of patients, mitral valve prolapse in 32%.

Results: Significant (>75%) coronary artery stenosis was found in 16 patients (6%). Regression analysis showed no link between the significance of Canadian Cardiovascular Society Grading of angina (I or II) and the grade of coronary artery stenosis in analysed patients ($r=0.02$, $p=0.88$). None of the ECG-stress test discontinuing criteria was correlated with the percentage of epicardial coronary artery stenosis in the cohort.

Conclusion: Low diagnostic accuracy of the ECG-stress test in conditions of low availability of myocardial perfusion imaging is followed by an increased rate of invasive coronary artery imaging, and increases diagnostic and treatment costs.

IAEA-CN-232/185

**Radiopharmaceutical Production of ⁶⁸GaDOTATOC at the
National Cancer Institute, Colombia**

**N.E Delgado Lopez, J. Rada, F. Lopez, C. Sanchez, L. De la Rosa, J.
Otalora, A. Llamas, A. De los Reyes**

Instituto Nacional De Cancerologia

Corresponding Author: ndelgado@cancer.gov.co

Background: An advantage of the ⁶⁸Ga is its commercial availability through a ⁶⁸Ge/⁶⁸Ga-generator. A fractionation method was described to process the generator-derived ⁶⁸Ga(III), in which 60-70% of the activity is eluted within 1-1.8ml. The aim of this work was to standardize an efficient method to obtain the radiopharmaceutical ⁶⁸GaDOTATOC for PET diagnosis of neuroendocrine tumors.

Methodology: We employed [DOTA0-Tyr3]Octreotide peptide-GMP (DOTATOC) (piChem); a 740MBq Eckert & Ziegler ⁶⁸Ge/⁶⁸Ga-generator, HEPES (Calbiochem); HCl Ultrapur and EtOH (Merck).

A manual system was installed in a shielded laminar flow cell. The ⁶⁸Ga solution was eluted with 0.1M HCl/5mL (2.5mL/min). The first 1.8 ml which contained 65% of the total ⁶⁸Ga-activity (405MBq), were transferred into the reaction vessel containing 40µgDOTATOC dissolved in HEPES 1M/0.5mL, and heated to 92°C/10min. To purify the product, C18-cartridges (30mg StrataX-tubes) were used. ⁶⁸GaDOTATOC was retained and the unreacted ⁶⁸Ga was rejected. The cartridges were then washed with water/4mL and the ⁶⁸GaDOTATOC recovered with 0.5mL/EtOH followed by 0.9%saline/4mL. Finally the product was sterile-filtered through 0.22µm membrane filter (Milex-GV) and the activity was measured.

The radiochemical purity and identity of the ⁶⁸GaDOTATOC was assessed by HPLC. A Lichospher100 column, C18 (5µm) was used and the mobile phase were Eluent B: 60% AcCN and eluent A: 40% trifluoroacetic acid 0.1%/water, (flow rate 1ml/min). Retention times were 2-3min for free ⁶⁸Ga(III) and 12-13min for ⁶⁸GaDOTATOC.

An indicator strip was used for the pH analysis of the ⁶⁸GaDOTATOC, limit-values were within 4.0-8.0. Sterile filter integrity test was performed with a limit value >50psi. Radionuclide identity and purity tests were performed by gamma-ray spectrometry and the peaks of 511 and 1077Kev were allowed. The physical half-life was measured 3 times and must be 62-74min.

⁶⁸Ge-contamination was detected and quantified using a gamma counter. The sample was retained 48h allowing ⁶⁸Ga to decay. The total radioactivity due to ⁶⁸Ge must not be >0.001%.

Endotoxin content was analysed using the LAL test (Endosafe®-system). Limit values must be <175/IU/ml. Sterility tests were performed according to the US-Pharmacopoeia.

Results: The synthesis parameters were optimized as described. The procedure led to the development of an injectable preparation of ⁶⁸GaDOTATOC within 20min +/-1min. Over 25 manual radiolabelling procedures of ⁶⁸GaDOTATOC were made, with overall yields of 58-60% (decay-corrected). Radiochemical purity was always >99.7% and pH between 6-6.5. The ⁶⁸Ge content was <0.0010 in the radiolabeled compounds and the ⁶⁸Ga half-life 67.9 min. All samples passed the endotoxin test at values <1.5UI/mL and the sterility test. 5 patients were injected and the primary tumor was found in two of them.

Conclusion: We have standardized manual radiolabeling method to obtain ^{68}Ga DOTATOC ensuring radiopharmaceutical quality, radiochemical yields and radiochemical purity >99.7%.

IAEA-CN-232/186

Contribution of Hybrid Image in the Diagnosis of Multiple Myeloma: A Case Report

A.Q. Buitrago-Gomez¹, L.K. Anzola Fuentes², A. Llamas-Olier²

¹ Fundacion Universitaria Sanitas

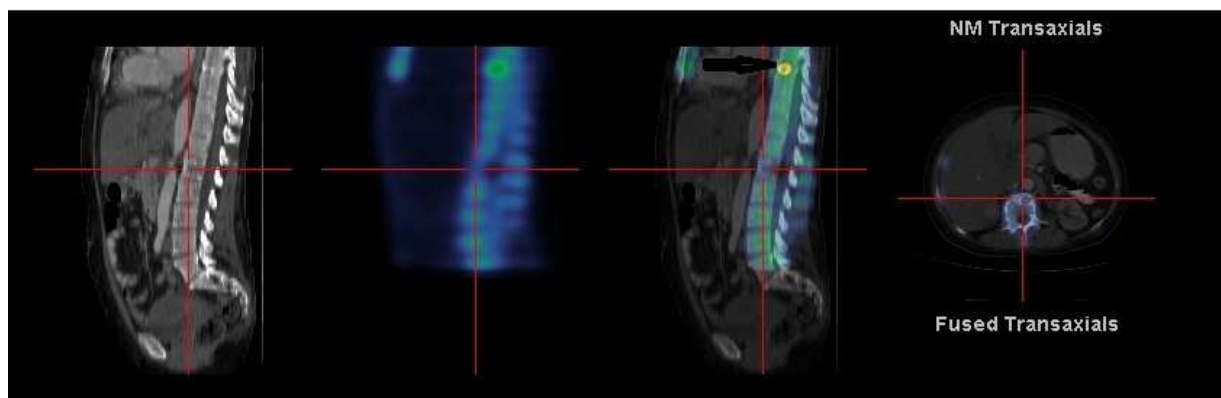
² Clinica Reina Sofia

Corresponding Author: quiteriago@gmail.com

Background: Multiple myeloma (MM) is a hematologic malignancy representing 1% of all neoplastic diseases. For a diagnosis it is essential to look for: 10% of monoclonal plasma cells on a bone marrow biopsy and evidence of end-organ damage (hypercalcemia, anaemia, bone lesion, renal insufficiency). The signs and symptoms can vary and include: bone pain, especially low-back chronic pain, fatigue, constipation, loss of appetite, frequent infections and others. We present the contribution of hybrid imaging SPECT/CT in a patient with MM.

Methodology: A 56 year-old woman with untreatable back pain and history of renal insufficiency of unknown cause was studied with conventional X-ray imaging of the thoracic spine interpreted as normal. As part of the pain evaluation, a bone scintigraphy was ordered.

Results: The bone scintigraphy revealed a photopenic defect in the first lumbar vertebra and abnormal tracer uptake in the left arch of the seventh thoracic vertebra and in the body of the eighth thoracic vertebra. The SPECT images were then coregistered with a previously performed abdominal CT scan. A lytic lesion was found in the first lumbar vertebra. Differential diagnosis included haemangioma or neoplastic lesion (Figure 1). A bone biopsy was then performed by the Hematology Group and found monoclonal plasma cells consistent with a plasmacytoma. Finally, MRI images of the cervical, thoracic and lumbar spine were taken that matched the abnormal uptake pattern described at the seventh and eighth thoracic vertebrae. It was concluded that they all were infiltrative lesions. A nephrologist analysed the results and considered that the patient's renal disease was consistent with a myeloma kidney.



Conclusion: This clinical case illustrates the contribution of hybrid imaging to the diagnostic approach of difficult MM.

IAEA-CN-232/187

Characterization and Clinical Significance of ⁶⁸Ga-DOTA-Peptides in Uncinate Process of Pancreas

X. Yan, A. Kasat

Singapore General Hospital

Corresponding Author: sean.yan.x.x@sgh.com.sg

Background: ⁶⁸Ga-DOTA-peptides are somatostatin analogues tracers used for imaging neuroendocrine tumours (NET). A number of organs demonstrate normal physiological uptake of which the uncinata process of pancreas is of particular concern not only because pancreas itself is a common site for NET but also the great variability of the tracer uptake that may make the interpretation difficult. Thus the aim of the study is to define the characteristics of normal distribution of ⁶⁸Ga-DOTA-peptides in uncinata process and its usefulness in distinguishing pathology versus normal.

Methodology: 66 (⁶⁸Ga-DOTATATE 58, ⁶⁸Ga-DOTATOC 8) PET/CT scans from 20 patients done between May 2009 and Oct 2014 were reviewed retrospectively. Tumor involvement of the uncinata process was excluded based on clinical and radiological evaluation including at least 1 year follow-up. Visual inspection is used to determine the pattern of tracer distribution in the uncinata by two nuclear medicine physicians. The reconstructed axial PET images were used to determine the SUV in uncinata process, rest of the pancreas, spleen, pituitary and aorta. Statistical analyses including Univariable Generalized Estimating Equations (GEE) was carried out.

Results: There are 3 types of distribution in the uncinata process, diffuse (most common), focal and multifocal. The distribution pattern has nothing to do with uptake intensity. There is dramatic intrapatient and interpatients variability of the uptake: The distribution pattern changes even in different scans of the same patient; the average SUV_{max} for uncinata process is 5.88 +/- 3.34, range 1.29-14.88. There is strong positive correlation between the uptake intensity in uncinata process and in pituitary and spleen (both P < 0.0001). The uptake SUV is also negatively influenced by dose of ⁶⁸Ga-DOTA-peptide (p=0.0002). Other factors such as patient age, gender, renal function, tracer type (DOTATATE vs DOTATOC), and uptake time are not noted to have effect on uncinata uptake pattern or intensity.

Conclusion: The distribution pattern and intensity of uptake in uncinata process varies greatly between patients and between scans; the pattern and intensity have no value in differentiating tumor from normal or benign tissue. Pituitary and spleen uptake may serve as a reference in judging the nature of uncinata process uptake. Calling tumor involvement in uncinata process of the pancreas must be very cautious and can only be based on other imaging correlations and/or biopsy results, not the presentation on PET scan.

IAEA-CN-232/189

Incidental Thyroid Uptake on 18F-FDG PET/CT Scans in Mexican Population and Correlation with Pathologic Results

G. Moreno, G. Manlio

Hospital General Naval de Alta Especialidad

Corresponding Author: manliogama@yahoo.com

Background: The objective of this study was to investigate the prevalence and significance of incidental thyroid uptake on whole body PET/CT scans.

Methodology: Retrospective review of 4,908 PET/CT scans performed between 2005 and 2010. Histopathological and cytopathological data was sought on those subjects who showed incidental thyroid uptake.

Results: 275 of the 4,908 patients (5.6%) had increased 18F-FDG thyroid uptake: focal in 119 (43.3%), diffuse in 135 (49%) and mixed (focal-diffuse) in 21 (7.7%). Thyroid uptake was more frequent among women regardless of age. Of these 275 patients with thyroid uptake, 29 has cyto/hystopathological information available (20 with focal, 5 with diffuse and 4 with mixed). 50% of the patients with focal uptake had a final malignant diagnosis, usually papillary carcinoma, whereas 90% of those with diffuse or mixed uptake ended up having a benign condition, usually nodular goiter or thyroiditis. SUVmax, age and gender did not correlate with malignant diagnosis.

Conclusions: Focal thyroid uptake on PET/CT is associated with a high likelihood of cancer. These patients need to be carefully evaluated with thyroid ultrasound and even aspiration biopsy.

IAEA-CN-232/190

Role of Gallium 68 -Labelled Antimicrobial Peptide Ubiquicidin (29-41) in Staphylococcus Aureus Infection Imaging in Animal Model

D. Boddeti¹, **V. Kumar**²

¹ Nuclear Medicine PET, the Children's Hospital at Westmead, Sydney, NSW Australia

² Nuclear Medicine PET, Westmead Hospital, Sydney, NSW Australia

Corresponding Author: dilipk.boddeti@health.nsw.gov.au

Background: Infection imaging has been challenging over the past four decades and the quest continues to find an ideal imaging agent. ^{99m}Tc-Ubiquicidin (29-41), targets bacterial and fungal infections, but not sterile inflammatory processes in experimental animals. The current study is to determine the advantage of using a positron emission tomography (PET) agent, ⁶⁸Ga-DOTA-UBI, for detecting Staphylococcal Aureus (Staph A) infection in an animal model.

Methodology: All chemicals were obtained from Sigma-Aldrich, St. Louis, MO, USA. Antimicrobial peptide DOTA-UBI (29-41) was purchased from Aussep, Melbourne Australia with purity >90%. The ⁶⁸Ge/⁶⁸Ga generator (IGG) was obtained from Eckhart & Ziegler, USA. ⁶⁸Ga-UBI is prepared by mixing pure ⁶⁸GaCl₃ (200MBq) with 50ug of DOTA-UBI (29-41) in 2mL of Millipore water and incubated for 15min at 90°C, after cooling, 1mL of Sodium Acetate buffer (0.1M) was added to raise the pH to 7.0. The RCP of ⁶⁸Ga-UBI was determined by TLC/alumina chromatography, using sodium citrate (0.1 M) as the solvent (free ⁶⁸Ga, R_f=1.0 and bound ⁶⁸Ga, R_f=0.0). The radiochemical purity of the product was >97% and therefore no further purification is required.

Results: The preliminary results clearly indicated an avid uptake of the agent at the infection lesions within 6min post-injection, which increased dramatically at 20 and 60min post-injection. The target to background ratio (T/B) increased significantly over the same time period of study (1.6, 4.2 and 6.1 respectively). The images indicated fast clearance from liver and soft-tissues within 6min post-injection and the delayed images clearly showed low activity in the blood pool, but very high activity associated with only the kidneys and bladder. Control rats showed similar biodistribution of activity.

Conclusions: The avid uptake of ⁶⁸Ga-DOTA-UBI at Staph-A infection lesion and very fast kinetics of clearance from the blood pool and soft-tissues suggested a very high clinical potential for this agent.

IAEA-CN-232/192

PET Quantification as a Function of the Total Acquisition Time in PET/CT

J. Cal-Gonzalez, I. Rausch, T. Beyer

Center for Medical Physics and Biomedical Engineering, Medical University of Vienna

Corresponding Author: jacobo.calgonzalez@meduniwien.ac.at

Background: Combined PET/CT has become a standard tool for the diagnosis and staging of oncology patients before and during/after therapy. Typically, PET quantification is performed using Standardized Uptake Values (SUV) in patients and Recovery Coefficients (RC) in phantoms, respectively. The accuracy of SUV and RC values depends on several factors, such as the patient status, the scan protocol, data processing and data analysis. In this work we evaluate the impact of reduced emission acquisition times and PET image reconstruction algorithms on the RC accuracy for phantom studies.

Methodology: We evaluated a 20 min list mode acquisition of a NEMA NU-2 image quality phantom, filled with ^{18}F -FDG, in the Biograph True Point True View (TPTV) PET/CT system. This list mode data was split into different time frames (from 1 min to 10 min per frame in steps of 1 min) and reconstructed using iterative reconstruction (OSEM) and resolution recovery (PSF) tools from the vendor. We used the RC values for the six hot spheres of the phantom (diameter: 10 mm to 37 mm) as figure-of-merit for the quantification accuracy. The Volumes of Interest (VOIs) for the calculation of the RC values were the maximum pixel value (RC_{max}) and the 3D isocontours at 50% adapted for background correction (RCA50).

Results: RC_{max} increase significantly when reducing acquisition time. This increase is more pronounced for bigger spheres and PSF reconstruction. In the worst case (1 min frame, 37 mm sphere and PSF reconstruction), the RC_{max} values are overestimated by 50%. The dependence of RCA50 on the acquisition time is less significant, and noticeable only for big spheres and acquisition times below 2 min.

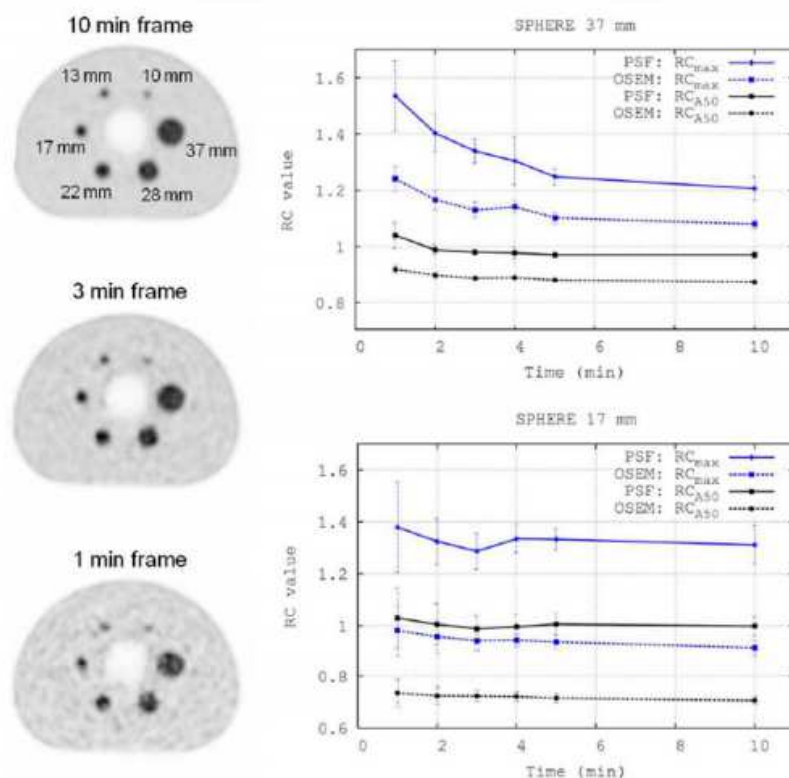


Figure 1. Left – from top to bottom: Transaxial slices, at the center of the spheres, of the NEMA phantom reconstructed with the PSF method and 10 min, 3 min and 1 min per frame. Right, top - RC_{max} and RC_{A50} values for the 37 mm sphere and OSEM, PSF reconstruction methods. Right, bottom - RC_{max} and RC_{A50} values for the 17 mm sphere.

Conclusion: Quantification accuracy in PET is related directly to image noise. As noise increases with shorter acquisition times, quantification is degraded. In general RC_{max} is more sensitive to noise. Therefore, RC_{A50} is more adequate to compare studies at different levels of noise. Phantom data and patient brain-studies with ^{11}C are under evaluation; the results will be presented at the conference.

IAEA-CN-232/193

**Variability in 18F-FDG Uptake of Primary Tumor
According to Acquisition Position Measured on 18F-FDG
PET/CT of Breast Cancer Patients**

T.J. Jeon¹, J. Jeong², J.H. Lee¹, Y.H. Ryu³

¹ Department of Nuclear Medicine, Gangnam Severance Hospital, Yonsei University College of Medicine

² Department of Surgery, Yonsei University College of Medicine

³ Department of Nuclear Medicine, Yonsei University College of Medicine

Corresponding Author: docnuke@yuhs.ac

Background: The purpose of this study was to evaluate the variability in SUVmax, MTV, and TLG of primary tumour according to acquisition position on 18F-FDG PET/CT of breast cancer patients.

Methodology: We retrospectively enrolled patients with pathologically confirmed breast cancer who underwent PET/CT for initial staging workup. PET/CT was acquired as standard whole body imaging in supine position followed by a prone acquisition for additional regional imaging with a mean interval of 18.2 min. For measurement of MTV and TLG, two different common thresholds were used for segmentation: 50% of SUVmax (MTV50, TLG50) and a fixed threshold of SUV 2.5 (MTV2.5 and TLG2.5). All PET/CT parameters were measured on prone images (pSUVmax, pMTV50, pMTV2.5, pTLG50, pTLG2.5). Finally we had 100 sets of SUVmax, MTV50, and TLG50 from each supine and prone image, and 76 sets of SUVmax, MTV2.5, and TLG2.5. Histopathological data were also evaluated and compared with PET/CT parameters. Group correlation and differences were analysed with Spearman correlation coefficient, Mann-Whitney u test, and Wilcoxon signed-rank test. Concordance of changes in PET parameters according to position was also evaluated with Cohen's kappa statistic.

Results: PET/CT parameters measured on supine images showed strong correlation with those measured on prone images ($r > 0.95$ and $p < 0.01$, all). SUVmax was 6.08 ± 3.95 and decreased significantly to 5.72 ± 4.01 in prone position ($p < 0.001$). MTV50 and pMTV50 were 6.06 ± 17.38 and 6.23 ± 16.73 ($p = 0.036$), MTV2.5 and pMTV2.5 were 7.72 ± 14.09 and 6.39 ± 18.53 ($p < 0.001$), TLG50 and pTLG50 were 22.90 ± 46.22 and 21.50 ± 44.11 ($p = 0.034$), TLG2.5 and pTLG2.5 were 36.65 ± 78.06 and 33.76 ± 75.63 ($p < 0.01$), respectively. For concordance of changes according to position, significant number of tumours showed a decrease in SUVmax but an increase in MTV50 or TLG50, or vice versa ($\kappa = -0.143$, $p = 0.067$ for MTV50, and for $\kappa = 0.003$, $p = 0.973$ for TLG50) while MTV2.5 and TLG2.5 showed concordant changes with SUVmax ($\kappa = 0.299$, $p = 0.016$, and $\kappa = 0.424$, $p = 0.001$, respectively). Those changes were not correlated with molecular subtype of breast cancer, hormone receptor status, TNM stage, nuclear grade, and histologic grade, except concordance in change between SUVmax and MTV50 and between SUVmax and TLG50 in triple negative breast cancer.

Conclusion: Our result demonstrated that all analysed parameters except MTV50, i.e. SUVmax, MTV, and TLG decreased on subsequent prone PET images and more importantly, there was significant discordance in change of SUVmax with that of MTV50 or TLG50. When considering that MTV and TLG are being investigated as a correlate with molecular markers or as a prognostic factor, it should be noted that the clinical significance of volumetric parameters is subject to change according to acquisition

position as well as threshold for tumour volume segmentation when using dual position PET/CT protocol.

IAEA-CN-232/194

Importance of the Technical Procedures Manual in Areas of Nuclear Medicine (PET/CT)

C. Arroyo Castela

Hospital of the Federal District of Mexico, Mexico

Corresponding Author: medclaus@terra.com.mx

Background: Due to the need of having guidelines or a standard manual on using PET/CT, it was decided to perform a search of such in the international literature. However, despite being an important diagnostic tool today, we are faced with a lack of information on the subject, and don't have guidelines that allow us to standardize procedures for PET studies.

Having a standard manual will permit an analysis of all procedures involved, making the work supervision easy, and avoiding procedure repetition. It would also serve as part of the introduction and orientation for the new personnel, allowing them to know all the procedures involved in daily practice.

Methodology: General guidelines for the manual elaboration: It should be prepared according to the guidelines and formats established by the local and international institutions and organizations that support it. The Operation Procedures of each institution are necessary to identify the basic elements and basic criteria.

- **Diagnosis:** determines the dynamics and process characteristics through which it will be able to detect the relevant aspects, deficiencies or deviations in the actions development, causes or trend.
- **Organic structure:** systematic disposition of the organs that integrate a unity, according to the criteria of hierarchy and specialization, sorted and coded in a way that will be possible to visualize the hierarchical levels the relations in the institution.
- **Contents of the manual:** It should contain detailed information concerning the history, legal-administrative framework, legislation, organization, hierarchical levels, institutional and organizational structure, functional organization chart, institutional objectives, analysis of the post and directory.
- **The name of the procedure** should give a clear idea of its content. The manual should be drafted in a common, clear and easy language. It should be started with a verb in present time, in the third person of the singular. For example: elaborates, receives, etc.

Elements that integrate the manual:

Classification:

1. Identification:

Title page - Cover of the manual, it will contain the next information:

- 1) Name and logotype of the institutions in the top left side, organization or entity in the top right side
- 2) Place and date of elaboration
- 3) Document key or I.D. code

2. Content:

Introduction and the chapters that constitute the manual.

The first part should include: cover, index, introduction, objective of the manual, legal framework, administrative framework, institutional chart, directory, procedures control and changes control. The second part should include: name, description and flowchart, general and specific objectives, responsibilities, frequency, policy and guidelines, references, description of activities, glossary and changes control.

Results: Through optimization of the material resources, the manual of procedures should reduce the time to develop the tasks, monitor and evaluate daily activities with.

Conclusion: A manual of procedures increases performance of the personal and the service quality provided in the institutions.

IAEA-CN-232/195

**Impact of 18F-FDG PET/CT Scan on Treatment Decision
in Non-Small Cell Lung Cancer**

A. Teyateeti, A. Teyateeti, P. Pusuwan

Faculty of Medicine, Siriraj Hospital, Mahidol University

Corresponding Author: dbsgtvxq@hotmail.com

Background: 18F-FDG PET/CT scan (PET) for initial staging (INS), post-treatment evaluation (PTE) and restaging of recurrent or progressive disease (RS) in non-small cell lung cancer (NSCLC) has been repeatedly proved to provide additional information on disease extension. However, the role as a guide to clinical decision was not extensively evaluated. This study, therefore, purposed to assess the impact of PET on multidisciplinary treatment approach of NSCLC.

Methodology: PET and conventional imaging (i.e. chest CT scan) of 120 pathologically diagnosed NSCLC patients performed between January 2010 and December 2014 were independently reviewed and identified the additional information gained from PET. Changes of initial staging were recorded and impacts on clinical decision were categorized into 6 aspects – (1) triggered major change in treatment in patients with available proposed treatment plan, (2) triggered change from curative to palliative intent in patients without known distant metastasis (DM), (3) triggered suspicion or exclusion of residual/recurrent primary tumor, metastatic lymph node (LN) or DM, (4) triggered changes in radiation field, (5) triggered suspicion of other malignancy and (6) triggered further procedure for pathological diagnosis (fine-needle aspiration/biopsy).

Results: Of 120 NSCLC patients, PET was performed for initial staging in 60 patients, post-treatment evaluation in 41 patients and restaging at time of recurrence or progression in 19 patients. Initial staging PET lead to up-stage and down-stage in 17/60 (28.3%) and 2/60 (3.3%) patients, respectively. Of 83 patients with proposed treatment plans prior to PET, major changes in treatment modality were found in 19 patients (22.9%) - 14 patients (5 INS, 7 PTE and 2 RS) changed from surgery or radiation to chemotherapy due to DM, 4 patients (3 PTE and 1 RS) changed from surgery or radiation to observation due to negative PET and 1 patient (PTE) changed from surgery to concurrent chemoradiation due to mediastinal LN metastasis. Of 106 patients without known DM, changes from curative to palliative intent were found in 29 patients (27.3%). PET triggered suspicion of residual/recurrent primary tumor in 2/120 (1.7%), metastatic LN in 28/120 (23.3%) and DM in 39/120 (32.5%) patients and exclusion of residual/recurrent primary tumor in 5/120 (4.2%), metastatic LN in 18/120 (15%) and DM in 21/120 (17.5%) patients. Of 44 patients receiving radiation, suspicion or exclusion of NSCLC lesions influenced the radiation field in 18 patients (40.9%). PET detected possible other malignancy in 7/120 (5.8%) patients; 2 patients had proven colon cancer and thyroid cancer. Overall, additional information gained from PET had an impact on clinical decision in 85/120 (70.8%) patients and elicited the pathological studies in 12/85 patients (14.1%); true positive, false positive and true negative in 4, 7 and 1 patients, respectively.

Conclusion: Performing PET in setting of initial staging, post-treatment evaluation and restaging of recurrent or progressive disease had considerable impact on clinical decision in treatment of NSCLC.

IAEA-CN-232/196

**A Comparison of Whole Body CT Scan and Whole Body
18F-FDG PET/CT Scan in Evaluation of Non-Small Cell
Lung Cancer**

A. Teyateeti, A. Teyateeti, P. Pusuwan

Faculty of Medicine, Siriraj Hospital, Mahidol University

Corresponding Author: littlecreammy@gmail.com

Background: In Thailand, conventional imaging i.e. CT scan is routinely used as a major tool in evaluation of non-small cell lung cancer (NSCLC) while advanced imaging like 18F-FDG PET/CT scan is preserved for patients with curative intent. However, additional findings such as distant metastases could be gained from whole body imaging. Thus, a comparison between whole body CT scan (WBCT) and 18F-FDG PET/CT scan may help in revealing the actual benefit of 18F-FDG PET/CT scan.

Methodology: Retrospective review of WBCT and whole body 18F-FDG PET/CT scan (fused images) were done in 120 pathologically diagnosed NSCLC patients between January 2010 and December 2014. Interpretation of each lesion on both imaging modalities were based on consensus of a nuclear medicine physician and a radiation oncologist without information of previous conventional imaging. Discordant findings between WBCT and fused images were compared to pathological reports or radiological follow-up for at least 6 months to confirm the diagnosis.

Results: Among 18F-FDG PET/CT scans of 120 patients, 65 patients (54.2%) had discordant findings between fused images and WBCT. Most of these lesions were mediastinal lymph nodes (35/120 patients; 29.2%), followed by early metastatic bone lesions with no demonstrable abnormality on WBCT (17/120 patients; 14.2%). Forty-eight discordant lesions in 34 patients with follow-up information were included. Among 48 lesions, fused images and WBCT correctly diagnosed 45 lesions (93.8%) and 3 lesions (6.2%), respectively. Of 38 false negative (FN) lesions on WBCT, 24 lesions (63.2%) were early metastatic bone lesions and 8 lesions (21%) were subcentimeter mediastinal lymph nodes. There were 7 false positive (FP) lesions on WBCT; 3 enlarged mediastinal lymph nodes, 2 non-FDG avid pulmonary nodules, 1 adrenal adenoma and 1 pleural effusion. Fused images correctly upstaged 5/8 patients due to detection of distant metastases and down-staged 1/8 patient by exclusion of contralateral paratracheal LN. Incorrect staging of fused images in 2/8 patients resulted from FP and FN mediastinal LNs. In evaluation of post-treatment and recurrence (n=20), fused images correctly evaluated disease status in 19/20 patients. One patient showed a FN recurrent tumor, sized 1.5 cm. Fused images demonstrated additional sites of distant metastases in 4 patients and LN metastases in 3 patients.

Conclusion: The benefit of fused images in evaluation of NSCLC is promising as compared to the WBCT. The greatest advantage of 18F-FDG PET/CT is the ability to evaluate subcentimeter mediastinal lymph nodes and detect early bone metastatic lesions.

IAEA-CN-232/198

Synthesis and Evaluation of 1-(2-[¹⁸F] Fluoroethyl)-2-Nitroimidazole for Hypoxia Imaging

S. Nandy¹, M.G.R. Rajan²

¹ Radiation Medicine Centre, Bhabha Atomic Research Centre, C/O T.M.C. Annexe, Parel, Mumbai-400012, India

² Radiation Medicine Centre, Bhabha Atomic Research Centre, T.M.C. Annexe, Parel, Mumbai-400012, India

Corresponding Author: mgr_rajana@hotmail.com

Background: PET imaging of hypoxia is important in oncology and cardiology and radiotracers used have a nitroimidazole moiety. [¹⁸F]FMISO, [¹⁸F]FAZA, [¹⁸F]EF5 are reported but FMISO is the most used radiotracer. However, it has low accumulation in hypoxic tissue and requires 2-4 h waiting to achieve acceptable target-background (T/B) ratio. Further, the precursor is patent protected and adds to the cost of tracer production. Here, we report a novel hypoxia tracer, 1-(2-[¹⁸F]Fluoroethyl)-2-Nitroimidazole, produced by direct radiofluoroethylation of 2-nitroimidazole followed by SEP-PAK® cartridge purification, and compared with [¹⁸F]FMISO.

Methodology: The radio-synthesis of 1-(2-[¹⁸F]Fluoroethyl)-2-Nitroimidazole is fully automated using an adapted general purpose synthesis module which in principle is similar to GE TRACERlab FXFDG and based on three steps: (i) Radiosynthesis of [¹⁸F]Fluoroethyl tosylate (ii) Coupling of [¹⁸F]Fluoroethyl tosylate with 2-Nitroimidazole and (iii) Purification by solid phase extraction. Lipophilicity of the compound was determined by “logP” (Octanol/Water) calculation. Pharmacokinetics were evaluated by PET/CT imaging in a rabbit at various time points and compared with [¹⁸F]FMISO. Bio-distribution study was carried out in tumour (B16F10) bearing mice (C57BL6). Retention of the tracer in tumour was confirmed by autoradiography. Presence of hypoxic regions in the tumours was confirmed by histopathology and immunohistochemistry.

Results: The non-decay corrected radiochemical yield is around (40±1.5) % (n = 10) within 45±2 min. The radiochemical purity is > 95 % as confirmed by radio-TLC and radio-HPLC coupled with UV (λ=254nm). Calculation of the “partition coefficient” predicts that 1-(2-[¹⁸F]Fluoroethyl)-2-Nitroimidazole is hydrophilic in nature in comparison to MISO and FMISO (MISO: - 0.39, FMISO: - 0.40 and 1-(2-[¹⁸F]Fluoroethyl)-2-Nitroimidazole: -0.60). Biodistribution study showed high tumor to muscle and tumour to blood ratio at one (T/M: 3.11, T/B: 3.45) and two hours (T/M:2.6, T/B: 4.1) and retained up to four hour (T/B: 3.9) post injection. The same was compared with [¹⁸F]FMISO (at one hour: T/M: 1.3, T/B: 0.9, at two hour: T/M: 1.9, T/B: 3.2 and at four hour: T/B:2.9).The presence of necrosis and vascularization was confirmed by histopathology with HE staining. Presence of hypoxia was confirmed by immunohistochemistry using pimonidazole based hypoxia detection kit. PET/CT imaging study in rabbit showed initial high uptake in liver, guts and excretory organs but no uptake in brain as well as in the blood. With the progress of time, the tracer cleared out from liver and gut. No bone uptake was observed up to four hours post injection confirming in vivo stability.

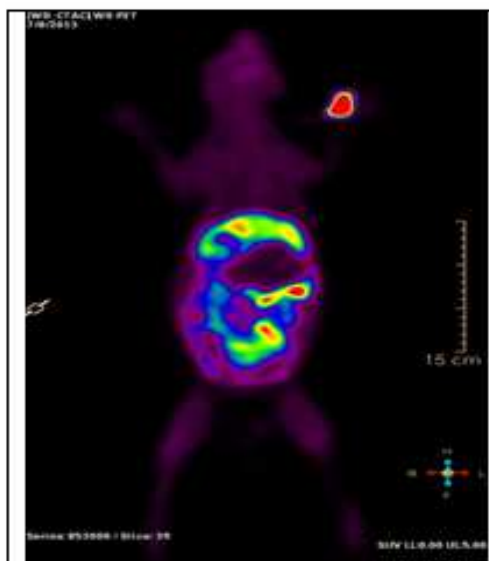


Fig 1 PET/CT Image of rabbit
Two hours post injection with
1-(2-[¹⁸F] Fluoroethyl)-2-Nitroimidazole

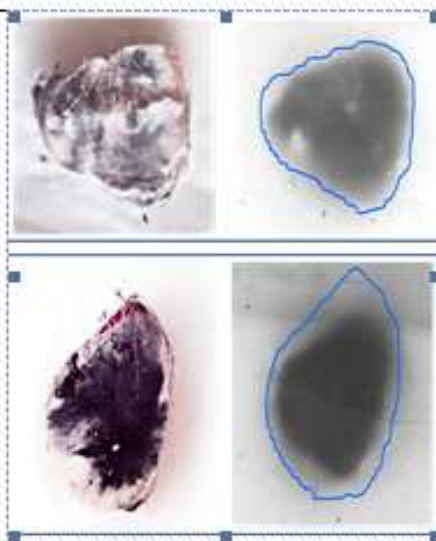


Fig 2. Autoradiography of tumor sections
(B16F10 cell line) developed in C57 BL6
mice. Animal was sacrificed 2 hrs post
injected and frozen sections of tumor were
exposed on X-ray film for 1Hr.

Conclusion: 1-(2-[¹⁸F] Fluoroethyl)-2-Nitroimidazole is synthesized by direct [¹⁸F] fluoroethylation of 2-Nitromidazole. The localization of the tracer in hypoxic region of the animal tumour model suggests further evaluation as a promising PET imaging agent for detecting tumour hypoxia.

IAEA-CN-232/200

Design and Development of a Low Cost Fully Automated Synthesis Module for the Production of Pharmacopeia Grade $[^{18}\text{F}]\text{NaF}$

Y.R. Nitin, S. Nandy, M.G.R. Rajan

Radiation Medicine Centre, Bhabha Atomic Research Centre, TMH Annexe, Parel Mumbai, India

Corresponding Author: mgr_rajan@hotmail.com

Background: Skeletal imaging by PET-CT using $[^{18}\text{F}]\text{NaF}$ is gaining importance over SPECT using $[^{99\text{m}}\text{Tc}]\text{MDP}$ in identifying bone metastasis. The demand for $[^{18}\text{F}]\text{NaF}$ is increasing, with some nuclear medicine centres preferring $[^{18}\text{F}]\text{NaF}$ over $[^{99\text{m}}\text{Tc}]\text{MDP}$. Cyclotron centres isolate $[^{18}\text{F}]\text{NaF}$ from the irradiated ^{18}O -water following $^{18}\text{O}(\text{p},\text{n})\text{-}^{18}\text{F}$ in standard $[^{18}\text{F}]\text{FDG}$ synthesis modules (bypassing the remaining steps) or, manually in a lead cave. The former under-utilizes and wastes the expensive FDG-synthesis cassettes resulting in $[^{18}\text{F}]\text{NaF}$ to be as expensive as $[^{18}\text{F}]\text{FDG}$. Manual methods increase personnel exposure to radiation. Hence, we have developed a low cost automated system for preparing $[^{18}\text{F}]\text{NaF}$ following good manufacturing practice (GMP) and fulfilling International Pharmacopeia specifications.

Methodology: a) Hardware: The control system for the automated Na^{18}F module, (see Fig 1) is based on an Atmel-Mega-328P based non-proprietary microcontroller board, operated by HMI software that commands the hardware controller that drives relays to switch on/off solenoid valves, vacuum pump etc., through a Darlington amplifier array ULN2008, as per the time-list of the programmable steps required.

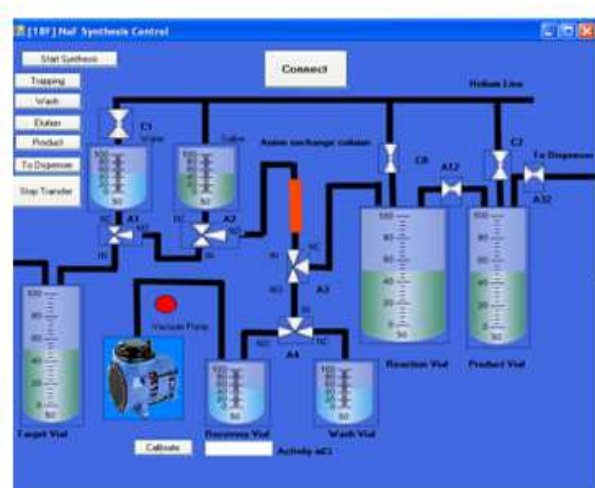


Figure 1: HMI Software for the Na^{18}F synthesis module Figure 2: Na^{18}F synthesis module inside the hot-cell

b) Radiation detector: A single detector, high range LND 715 GM-tube, strategically positioned close to the anion column and product vial to monitor the movement of radioactivity during the $[^{18}\text{F}]\text{NaF}$ production steps: a) Trapping of ^{18}F - on the anion exchange column, b) washing of the column by water

to remove non ^{18}F - impurities, c) elution of ^{18}F - in the form of Na^{18}F with isotonic saline d) Transfer of activity to the dispenser. The detector is small, and has a sensitivity of one cps per $20\mu\text{Sievert/h}$. This is sufficient to monitor $\sim 37\text{ GBq}$ of ^{18}F NaF production.

c) Software: The Visual Studio .NET based custom Human Machine Interface (HMI) software has been used for the automated synthesis with provision for manual over-ride. The software also features report generation and printing required as a part of good manufacturing practice. The software performs moving average filtering of the GM readings and has provision to calibrate the GM tube.

d) GMP: The reaction vial is of glass with a radiation resistant PEEK closure with inlets for reagents, vacuum and compressed air (2 bar) to facilitate fluid transfer. Prior to the production of ^{18}F NaF, the module is thoroughly cleaned/sanitized using ethanol and water followed by elaborate drying. This is automated through a programmed time-list with manual over-ride if special cleaning is required.

Results: The ^{18}F NaF production module has been extensively tested and product validated. It is housed in a 70mm thick lead hot-cell, and has been used for producing over 250 batches of injectable ^{18}F NaF with batch sizes of 2 – 10 GBq.

Conclusion: The automated module is easy to operate and serves the purpose for producing Pharmacopoeia grade ^{18}F NaF. The module costs about INR 160,000 to make and can be used in a mini or micro shielded hot-cell.

IAEA-CN-232/201

**Predisposing Sites of Single Bone Metastasis in Patients
with Primary Breast Cancer Detected on 18F-FDG PET/CT**

**H. Budiawan¹, G.J. Cheon², H.J. Seo², J.K. Chung², J.C. Paeng²,
K.W. Kang², D.S. Lee²**

¹MRCCC - Siloam Hospitals, Jakarta, Indonesia

²Department of Nuclear Medicine, Seoul National University College of Medicine

Corresponding Author: dvn_b@yahoo.com

Background: Breast cancer is the most common primary site of origin of metastatic deposits in the skeleton. Metastatic bone disease is commonly found in multiple patterns. Nevertheless, single bone lesion can also represent metastasis. Understanding the pathway of the cancer spread to bones may be helpful in detecting single bone metastasis.

Methodology: All breast cancer patients who underwent 18F-FDG PET/CT scan in 2011 and were revealed to have bone metastasis were selected. Patients with single bone metastasis confirmed by other modalities were included, while others with multiple bone metastases were further analysed retrospectively to find the first single lesions. The baseline breast imaging including 18F-FDG PET, MR, or CT was also analysed.

Results: Twenty-seven patients were found to have single bone metastatic lesion at sternum (9), rib (7), spine (6), pelvic bone (4), and femoral head (1). Most of the baseline breast imaging of patients with sternal and rib lesions showed that the primary breast lesions were close/attached to the pectoralis major muscle. Most of the baseline breast imaging of patients with spine and pelvic lesions showed that the primary breast lesions were located at the subareolar area.

Conclusion: Single bone metastasis is not uncommon and can be found in the sternum, rib, spine, pelvic bone, or extremity. Primary breast lesions located close or attached to the pectoralis major muscle have higher tendency to spread to the sternum or rib, while subareolar primary breast lesions have higher tendency for haematogenous spread to distant sites. From clinical practice point of view, knowing how breast cancer cells spread to the bones is helpful in detecting single bone metastasis with higher accuracy and giving additional important clinical information.

IAEA-CN-232/202

18F-FDG PET/CT in the Follow Up of Pulmonary Carcinoma Treated by Cyberknife

**K. Chatti¹, J.M. Ouvrier², D. Benisvy², C. Zwarthoed²,
J. Darcourt²**

¹Nuclear medicine department, Sahloul Hospital, Sousse, Tunisia

²Nuclear medicine department, Antoine Lacassagne Center, Nice, France

Corresponding Author: kaouthar.chatti@gmail.com

Background: 18F-FDG PET/CT complete metabolic response is defined as the complete resolution of 18F-FDG uptake within measurable target lesion. In our study we report serial 18F-FDG PET/CT tumour response following CyberKnife radiosurgery (CK) in primary lung carcinoma.

Methodology: We retrospectively reviewed patients with primary pulmonary carcinoma treated by CK from 2011 to 2013 and followed for at least two years. Patients included in this review had had at least two 18F-FDG PET/CT scans in the follow up of the CK treatment.

Results: Eleven women and 14 men with a mean age of 72yrs (46-90) were included. The primary lung carcinoma was a non-small cell carcinoma in 16 cases, an endocrine tumour in one and undifferentiated tumour in one case. There was no histologic diagnosis in 7 cases. All patients had initial Karnofsky score of 100 or 90. Lesions were localised in the left lung in 14 cases, nine in the upper lobe, and in 11 cases in the right lung with nine in the upper lobe. Mean tumour size was 34mm (15-70mm). Initial 18F-FDG PET/CT showed isolated high SUV pulmonary lesion. CK consisted of 3 fractionated high doses of 20Gy in 19 cases and 5 fractionated high doses of 11Gy in 6 cases. The mean interval of six months separated initial 18F-FDG and CK (2-9). Nine patients had more than three PET controls. In 21 patients, SUV of the irradiated lesion was 2.9 ± 0.6 in the first control. In only two cases it increased slightly, to 4.5 and 5.9. All the other cases showed no increase. In five patients, initial control showed a SUV of more than 7.5 (7.5 - 16.4). It increased in the second and third control in all cases and it was associated to the appearance of other specific lesions in two cases.

Conclusion: Our data showed that an SUV of 3 in the first 18F-FDG PET/CT follow-up after CK treatment of a primary lung carcinoma was a good predictive value of the complete metabolic response of the lesion.

IAEA-CN-232/203

Initial Experience with 18F-FDG - Positrons Emission Tomography in Paraguay

C. Laterza, E. Yanagida, J. Cudas Thompson

Instituto Radiologico Cudas Thompson, Asuncion, Paraguay

Corresponding Author: carlos_laterza@yahoo.com

Background: PET/CT is currently considered as an almost indispensable resource in clinical management, mainly of cancer patients. This diagnostic tool is being increasingly used, and nowadays, it is considered imperative to use this type of technology in the staging and monitoring of neoplastic diseases. In Paraguay, PET/CT is available only in the last 28 months, being one of the last countries in the region to offer this diagnostic technology to cancer patients.

As a country with limited resources and without the possibility to produce radiopharmaceuticals locally to date, the implementation of this hybrid imaging technique has been a challenge, due to the need to transport the 18F-FDG from other countries in the region.

Methodology: We studied patients retrospectively, since the beginning of the implementation of this technique to date, evaluating the first 399 consecutive cases.

Results: Mean age of the studied population was 48 years; 57% were older than 50 years old and 51.6% were female. Of the total population, 13% were paediatric cases, and sedation was required only in two patients. Before the injection of 18F-FDG, mean fasting glucose was 111.95 mg/dl.

Of the total population, 98.7% of patients had oncological diseases; lymphoma (25.30%), breast (13%) and lung (12.78%) cancer were the most common ones. Among the non-cancer diseases, only patients with prolonged fever (1.25%) were included. Interestingly, PET/CT was requested by a variety of specialists. Requests from oncologists (32.10%) and surgeons (19.27%) were the most frequent ones.

Of all cancer patients, most of them (72.18%) showed pathological hypermetabolic findings in the study.

We observed no complications during the performance of studies in these 28 months of operation of PET/CT.

Conclusion: Despite being an innovative method and the inherent difficulties of the country, we experienced an increase in the frequency of requests, in the diversity of pathologies studied, and in the number of medical specialties that use this hybrid imaging technology.

The installation of a cyclotron, which will operate in the country in a few months, will facilitate the availability of radiopharmaceuticals, and therefore, will presumably cause an increase in the use of this nuclear technique in oncology. We are also confident about the future use of this method in other areas, such as cardiology and neurology, in which the experience is limited so far.

IAEA-CN-232/204

18F-FDG PET/CT for the Detection of Recurrence in Asymptomatic Patients with Increased Serum CA 15-3 Levels

A. Damian, M. Rodriguez-Taroco, O. Alonso, H. Engler

Uruguayan Centre of Molecular Imaging (CUDIM), Uruguay

Corresponding Author: andres.damian@tudim.org

Background: Although F-18 fluorodeoxyglucose positron emission tomography/computed tomography (18F-FDG PET/CT) has been reported to be useful in the initial staging, the evaluation of therapy response, and in assessing recurrent disease in breast cancer patients, the standard use of this modality for the detection of recurrence in asymptomatic patients with increased serum CA 15-3 levels is still debated.

Methodology: We studied retrospectively 36 women (32-77 years old) with increased CA 15-3 levels and without clinical evidence and conventional imaging findings of recurrent disease. All patients were studied with 18F-FDG PET/CT in the period 2012-2014. Patients with previously known stage IV disease were excluded.

Results: Nineteen of the patients presented localized disease and 17 loco-regional advanced breast cancer at the time of diagnosis. One of the patients had bilateral loco-regional advanced breast cancer. The mean CA 15-3 value at the time of the study was 61.1 ± 25.7 (SD). 18F-FDG PET/CT showed relapse compatible findings in 19 of the patients (52.7%). Seven of these patients presented loco-regional lesions and 12 distant metastases. The percentage of detection was not significantly different compared to patients with localized or loco-regionally advanced disease at the time of diagnosis.

Conclusion: 18F-FDG PET/CT may be a useful tracer to detect recurrence in asymptomatic patients with increased serum CA 15-3 levels, providing additional information to conventional structural imaging to localize the site of recurrence.

IAEA-CN-232/205

18F-FLT PET/CT for Early Assessment of Chemotherapy Response in Advanced Breast Cancer Patients

A. Damian¹; C. Espalter², N. Silveyra², L. Delgado², O. Alonso¹, H. Engler¹

¹ Uruguayan Centre of Molecular Imaging (CUDIM), Uruguay

² Department of Oncology, Clinical Hospital, University of the Republic, Uruguay

Corresponding Author: andres.damian@tudim.org

Background: Even though information is still limited, recent studies have shown that [F-18] fluoro-30-deoxythymidine (FLT) PET/CT might be useful in monitoring chemotherapy response in patients with breast cancer. Therefore, the purpose of this study is to prospectively evaluate the performance of 18F-FLT PET/CT in monitoring early chemotherapy response in advanced breast cancer patients.

Methodology: We studied nine patients (35-82 years old, one male) with metastatic (n=5) or loco-regionally advanced (n=4) breast cancer. All patients were studied with 18F-FLT and 18F-FDG PET/CT before treatment, and six of them were also studied with an interim 18F-FLT PET/CT 15-30 days after the beginning of systemic treatment. SUVmax of assessable lesions was compared with therapy response according to UICC criteria.

Results: Before treatment, 18F-FDG and 18F-FLT SUVmax analysis of non-osseous lesions showed a significant correlation ($P = 0.023$, $n=22$). 18F-FLT and 18F-FDG SUVmax absolute values were not significantly different. With the exception of one patient, those studied with an interim 18F-FLT PET/CT exhibited a significantly decreased uptake after treatment (7.69 ± 3.9 vs. 4.49 ± 2.9 , mean \pm SD of pre and post treatment SUVmax values respectively, $n=22$, $P=0.00028$). Four of the patients were categorized as responders, while 5 showed stable disease ($n=3$) or progression ($n=2$).

Conclusion: 18F-FLT PET/CT might perform well in monitoring early response to systemic chemotherapy. Comparison with pathological and biochemical markers of the disease is mandatory to establish the potential use of 18F-FLT PET/CT in the evaluation of systemic treatment response.

IAEA-CN-232/206

Prognostic Value of Volumetric and Metabolic Tumour Parameters in Head and Neck Malignancy

A.V. Ramachandran Nair¹, V.H. Somasundaram²; S.S. Palaniswamy¹, P. Subramanyam,¹

¹ Amrita University

² Amrita Institute of Medical Sciences & Research Center

Corresponding Author: arunvr19254@aims.amrita.edu

Background: Head and neck cancer (HNC) comprises malignancies involving the oral cavity, oropharynx, hypopharynx, larynx, sino-nasal tract, and nasopharynx. Metabolic parameters are not included under the American Joint Committee on Head and Neck Cancer staging, which is now commonly used to estimate the prognosis and treatment planning. We attempted to study whether volumetric and metabolic tumour markers had a prognostic value in HNC.

Methodology: 33 patients (pts) with proven HNC and treated with surgery/chemoradiation, M:F 31:2, age 41-75 yrs (mean 56yrs), referred for follow up 18F-FDG PET/CT scan between Jan 2013 – Dec 2014, with suspected recurrence were retrospectively analysed. Metabolically active tumour regions were delineated on pre-treatment PET scans semi-automatically using PET/VCAR software. Metabolic tumour volume (MTV) and total lesion glycolysis (TLG) using 40% of SUVmax as threshold were calculated for the primary tumour and involved nodes. The prognostic value of MTV and TLG in predicting recurrence was analysed.

Results: Receiver operating characteristics (ROC) was plotted for MTV and TLG. Patients were divided in two groups: high and low, based on ROC cut-off values (MTV – 41.8 cm³, TLG – 225.2). Out of 16 pts with high MTV and TLG values, 14 pts had recurrence (87.5%) and 2 pts (12.5%) had no recurrence. 13 (76.4%) out of the 17 pts with low MTV and TLG values, had no documented recurrence, whereas 4 pts (23.6%) in this group had recurrence (p value < 0.001). Results show significant association of higher MTV and TLG values with recurrence. Therefore high volumetric and metabolic tumour parameters in pre-treatment 18F-FDG PET/CT were significant variables in predicting a worse prognosis.

Conclusion: MTV and TLG values in pre-treatment 18F-FDG PET/CT are independent prognostic indicators in patients with clinically heterogeneous HNC. Therefore, aggressive clinical management could be carried out in these patients.

IAEA-CN-232/207

Performance Evaluation of the Biograph mCT-Flow PET/CT System According to NEMA NU2-2012 Standards

I. Rausch¹, J. Cal-Gonzalez², T. Beyer³, G. Minear⁴

¹ Center for Medical Physics and Biomedical Engineering, MUW, Vienna

² Center for Medical Physics and Biomedical Engineering, Medical University of Vienna

³ Center for Medical Physics and Biomedical Engineering, Medical University of Vienna, Austria

⁴ Dept of Nuclear Medicine, Landesklinikum St. Pölten, Austria

Corresponding Author: ivo.rausch@meduniwien.ac.at

Background: The evaluation of Positron Emission Tomographs (PET) requires reproducible and reliable methods to allow the comparison of different systems using accepted measurement standards. The National Electrical Manufacturers Association (NEMA) has published a series of procedures to evaluate the physical performance of PET systems. In this work we evaluate the physical performance of a Biograph mCT Flow PET/CT system with continuous and standard, sequential motion of the patient table.

Methodology: We evaluated a new Biograph mCT Flow 64-4R PET/CT system (Siemens Medical Solutions USA, Inc.). We measured the spatial resolution, sensitivity, count rate curves and physical image quality (IQ) parameters following the NEMA NU2-2012 protocols. For resolution measurements we used an ¹⁸F point source inside a glass capillary tube (inner diameter: 0.9-1.0 mm; wall thickness 0.4 mm). For the sensitivity we used a 70 cm long polyethylene tube, filled with 4.5 MBq of ¹⁸F-FDG, and for the scatter fraction and count rates we used a 70 cm long polyethylene cylinder with a diameter of 20 cm, with a line source (1.04 GBq of ¹⁸F-FDG) inserted axially into the cylinder 4.5 cm off-centered. A NEMA IQ phantom containing 6 spheres (internal diameters: 10, 13, 17, 22, 28 and 37 mm) was used for the evaluation of the IQ. Acquisitions were done following the NEMA NU2 section 7 protocol. Additionally, we acquired a 2 bed scan (4 min each) of the IQ phantom with the image plane containing the spheres centered in the overlap of the two bed positions and a scan of the same region in Continuous Table Motion (CTM) mode with a table speed of 0.6 mm/s. We compared the contrast for the six spheres in sequential and CTM acquisitions.

Results: Full Width Half Maximum (FWHM) values of the spatial resolution varied from 4.3 mm (at 1 cm) to 7.8 mm (at 20 cm). The measured sensitivity was 9.4 kcps/MBq, both at the center of the FOV and 10 cm off-centered. The measured NEC peak was 185 kcps at 29.0 kBq/mL and the scatter fraction was 33.5%. Contrast recovery values (sphere-to-background of 8:1) ranged from 42% (smallest sphere) to 78% (biggest sphere). The background variability was between 2.1 and 4.9 (sequential mode) and between 2.4 and 6.3 (CTM mode).

Table 1. Image quality comparison for sequential and CTM acquisition modes. The sphere-to-background ratio is 8:1. The CTM acquisition followed the sequential subsequently.

Sphere diameter (mm)	Contrast recovery (%)		Background variability (%)	
	Sequential	CTM	Sequential	CTM
10	43.7	41.9	4.9	6.3
13	54.2	49.6	4.1	5.4
17	66.6	68.1	3.3	4.4
22	75.5	76.6	2.8	3.6
28	70.7	71.3	2.5	3.0
37	77.5	77.7	2.1	2.4
Lung residual (%) (σ)			12.3 (0.9)	12.1 (0.6)

Conclusion: The spatial resolution, sensitivity, scatter fraction and count rates measured values are in concordance with the published values for the previous system, the Biograph mCT. Contrast recovery values in CTM and sequential acquisition mode were similar.

IAEA-CN-232/208

Is the Application of PET Studies Resilient to Recession?

S. Nazarenko, A. Samarin, L. Karusoo, R. Brand, M. Paris, M. Talk

North Estonia Medical Centre

Corresponding Author: sergei.nazarenko@regionaalhaigla.ee

Background: Nuclear medicine in general, and positron emission tomography (PET) in particular, plays an important role in modern evidence based medicine. Clinical utilization of PET is supported by several pillars: the body of scientific evidence, availability of economic resources, psychological factors, level of training and sets of skills, compliance of clinical partners etc.

The aim of the study was to analyse whether the utilization of PET was influenced by psychological factors and compliance of clinical partners during the outbreak of the economic recession in 2009, and if so, what lessons could be learned in order to make medical practice more resilient to recession in the future.

Methodology: The study focused on the number of PET studies performed at the North Estonia Medical Centre during 2008-2012, i.e. from just before the recession to the recovery, and analysed the influence of factors, including psychological, on the utilization of PET studies.

Result: Perception of the ongoing global economic crisis hit Estonia in autumn 2009 with dramatic results. Profound austerity measures were implemented also in health care sector: the goal was to keep the number of treated cases constant, reducing simultaneously their reimbursement by six percent. In reality, at our institution this caused a reduction of the total payroll of every department and every category of staff by approximately twelve percent, while other costs were kept without drastic changes. In our hospital the number of inpatients decreased by 7,13% and the number of outpatient visits decreased by 4,81% in 2009 in comparison with 2008. Simultaneously, the number of requests for PET and performed studies dropped by 37%.

A clear decrease in requesting and performing PET studies occurred during Q3-Q4 of 2009 and Q1-Q3 of 2010 with a trend to recovery from Q4 2010. With other variables remaining constant: no reduction of the number of treated cases, no reduction of the budget for the utilization of PET equipment, no decrease in the budget for radiopharmaceuticals, and no reduction of staff, the most influential factor for the decrease of utilization of PET studies must be psychological. This was confirmed by frequent statements of our clinical partners that PET studies were too expensive despite the fact that the budget for nuclear medicine was not cut, except for the payroll of the staff. As underutilization of PET studies must have badly influenced the treatment quality, this observation confirms the detrimental psychological impact of uncertainty during a serious crisis, as proven by other studies and in other areas.

Conclusion: Our study demonstrates that detrimental psychological impact of the economic crisis may strongly influence the utilization and availability of PET and, consecutively, may alter the quality of treatment. This impact manifested independently from other detrimental factors, and could be alleviated by decreasing the amount of uncertainty, namely through additional training and confidence building for the situations of crisis and difficulty. These activities should cover not only nuclear medicine staff, but should also aim at supporting positive compliance of clinical partners.

IAEA-CN-232/210

**Some Results of a Seven Years Cooperative Venture between
the PET/CT-Unit of the Radiological Center Franken-
Hohenlohe and Pulmonary Clinical Center Löwenstein
Germany**

J. Witt¹, T. Graeter², A.Schmidt³

¹ Radiologie Franken-Hohenlohe

² Klinik Löwenstein

³ BRD

Corresponding Author: anca.schmidt@gmx.de

Background: Our presentation is based on seven years PET-CT experience in our PET-CT-Unit in the Lung Disease Clinic Löwenstein Germany. Between 2007-2013 we investigated around 3500 patients from the clinic and from other clinics.

Methodology: We investigated mostly patients with known lung cancer of different types in order to perform the first staging evaluation, the evaluation of the treatment and to assess the evolution and the outcome. Additionally we also performed diagnostic and evaluation investigations for patients with other unclear or complex cancer diseases. In most cases the patients were outhouse patients, meaning they presented their diagnosis- and investigation-specific tests before. We performed the PET-CT investigations with a SiemensBiograph PET-CT Camera.

Results: The role of PET-CT in the diagnosis, staging, treatment and follow-up of the patients with a specific lung cancer is well known. Consequently we chose to select and present 39 of our most challenging patients. We will further present special cases of false negative PET-diagnosis, cases of special tumor entities, special evaluation situations in some entities, complex tumor situations, and special evaluation forms. In all these situations PET-CT proved to be a very useful tool in diagnosis, treatment and evaluation in conjunction with the lab tests, physiological, pathological, and clinical investigations.

Conclusions: The PET-CT investigations proved to be not only a useful tool in the management of the patients who matched the classical lung cancer patterns, but also in that of our "special cases". It led to a more specific and therefore better treatment. Good cooperation with the surgical and oncological departments brings feedback in question of diagnosis, further improving the accuracy of the investigation and interpretation of the results. Many times it changed the further treatment and is of course vital for the treatment response and further outcome of the patients.

IAEA-CN-232/213

Audit of 18F-FDG PET/CT in the Assessment of Cancer of Unknown Primary in South Africa

N. Malan, N.N. Mkhize, D. Mpanya, K. Mokoala, M.T. Vangu

University of the Witwatersrand

Corresponding Author: nico.malan@wits.ac.za

Background: Cancer of unknown primary is reported to be one of the ten most frequent cancers (accounting for 3 – 5% of all malignancies) and is the fourth most common cause of cancer-related deaths. Failure to detect the primary tumour impedes optimization of treatment planning, which may negatively influence patient prognosis. 18F-fluoro-2-deoxyglucose (18F-FDG) positron emission tomography is a non-invasive, sensitive, whole body technique, which assists in the detection of the primary tumour with a reported pooled detection rate, sensitivity and specificity of 37%, 84% and 84% respectively. Data is currently lacking in how 18F-FDG PET/CT performs locally for the detection and localization of an unknown primary site of cancer.

Methodology: We performed a retrospective audit of all 18F-FDG PET/CT scans that were performed for patients that were referred for assessment of cancer of unknown primary between 2008 and 2014 to the PET/CT centre in Charlotte Maxeke Johannesburg Academic Hospital, Johannesburg, South Africa. Cases that demonstrated focal, increased, extra-nodal 18F-FDG uptake ($SUV_{max} > 2.5$) were considered as positive of a possible primary site. The audit further assessed in which cases subsequent histological correlation was performed following the PET/CT scan by reviewing histology results from the pathology database.

Results: A total number of 54 patients (mean age = 54.5 years (14 – 83 years); 32 males and 22 females) were referred for assessment of cancer of unknown primary. Fourteen cases demonstrated focal abnormal increased 18F-FDG-uptake (26%), which may suggest a site of unknown primary tumour. These were localized to: duodenum / gastric area: 2, nasopharyngeal: 2, thyroid: 2, cervical soft tissue masses: 2, lung: 2, abdominal soft tissue mass: 1, pancreas: 1, musculoskeletal: 1, and bowel: 2 (one study revealed two possible primary sites: musculoskeletal and lung). The mean SUV_{max} of the possible primary sites were 8.2 (range 2.8 – 28.6). Of the 14 patients, two passed away before any further investigations were done. In 10 cases there were no further follow ups or biopsies performed as indicated by the hospital notes and in 2 cases biopsies were performed on sites that were suggested by PET/CT scan: one revealing follicular thyroid carcinoma and the other was performed in the patient that had two possible primary sites. The biopsy was performed on the musculoskeletal area, which showed metastatic squamous cell carcinoma, so the lesion in the lung was assumed to be the primary site.

Conclusion: Our audit revealed a lower detection rate (26%) for localizing a site of possible primary cancer in our institution than the reported rate in meta-analysis of literature (37%). Although there was a significant number of cases that did not receive further histological correlation, 18F-FDG PET/CT remains a valuable non-invasive tool for assisting clinicians in localising a possible primary site of malignancy.

IAEA-CN-232/214

PET/CT Significance in Primary Thyroid Lymphoma: A Case Report

N. Beslic¹, S. Ceric¹, R. Milardovic¹, A. Sadija¹, B. Hadžihasanović²

¹ Nuclear Medicine, Clinical University Centre Sarajevo

² Radiology, Clinical University Centre Sarajevo

Corresponding Author: milardovic2001@yahoo.com

Background: Primary thyroid lymphoma (PTL) is a rare type of thyroid malignancy affecting mainly elderly females. It accounts for 1-5 % of all thyroid malignancies and 1-5 % of all lymphomas. Of all extra-nodal lymphomas, PTL accounts for only 2%, and the majority of these are non-Hodgkin lymphomas (NHL). Hashimoto thyroiditis is detected in 27-100% of thyroid lymphoma cases. In this case study we evaluate the significance of PET-CT in this rare haematological condition.

Methodology: We present a case of a 58-year-old female with a long-standing medical history of benign thyroid disease - Hashimoto thyroiditis with hypothyroidism. The patient was presented to the multidisciplinary team because of the rapid thyroid enlargement, and was consequently referred to surgery. Histopathology revealed marginal zone lymphoma. Baseline 18F-FDG whole-body PET-CT was recommended six weeks after surgery, and upon its findings, chemotherapy was applied. Follow-up 18-FDG whole-body PET-CT was performed upon the completion of chemotherapy in order to evaluate the response.

Results: Upon total thyroidectomy of the rapidly enlarging thyroid with Hashimoto disease, marginal zone lymphoma was confirmed. Marginal zone lymphoma belongs to the group of indolent (slow-growing) NHL B-cell lymphomas. Baseline 18F-FDG whole-body PET-CT scan depicted only one avid lymph node in the right side of the neck. Based on the results of the baseline scan, chemotherapy was applied. Follow-up 18F-FDG whole-body PET-CT performed upon the completion of chemotherapy and within months from the initial one, showed a complete response with no signs of pathological metabolic activity in the body.

Conclusion: The frequent association of Hashimoto thyroiditis with primary thyroid lymphoma, and overlapping of their clinical and pathologic findings pose a significant diagnostic challenge. While other imaging techniques are helpful in evaluating anatomic local and regional extent of primary thyroid lymphoma, 18F-FDG whole-body PET-CT can be of an added value in evaluating its metabolic activity and detecting regional and distant disease as well as in assessing response to treatment. In this case, PET-CT had a significant role in postoperative restaging and decision making in the therapeutic approach.

IAEA-CN-232/216

68Ga-DOTATATE PET/CT in the Guidance of Surgical Management in Neonatal Hyperinsulinism: A Case Report

L. Salazar Vargas, P. Orellana Briones, D. Vicentini Harboe, J.C. Pattillo, C. Godoy, F. de Barbieri

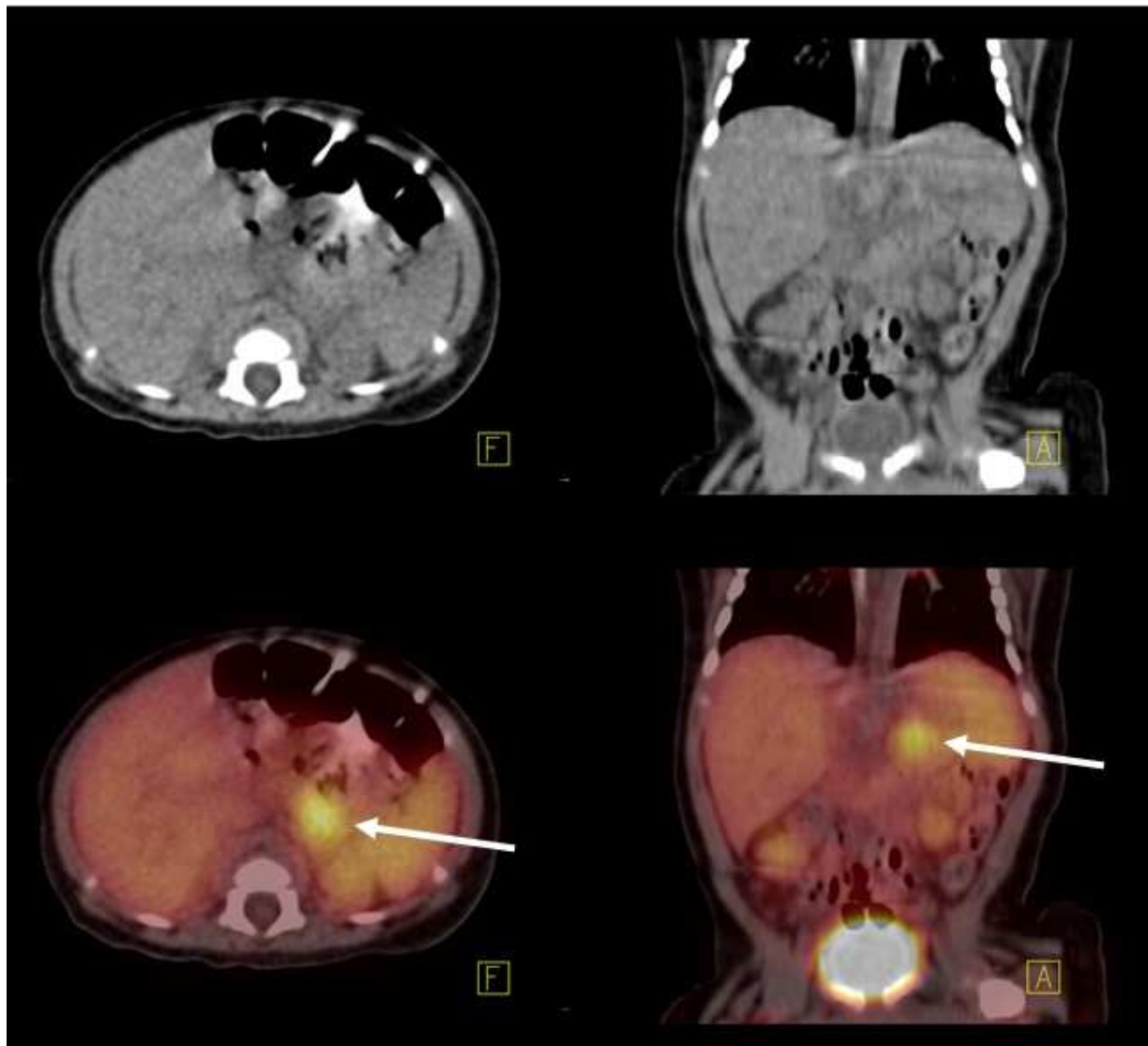
Pontificia Universidad Catolica de Chile

Corresponding Author: lsalazarv@gmail.com

Background: Congenital hyperinsulinism (CHI) is an uncommon disease characterized by severe and persistent hypoglycaemia due to inappropriate insulin secretion by the pancreatic B-cells, which can cause irreversible brain damage. Because of poor response to medical treatment, pancreatectomy is often needed. Two main subtypes are described: diffuse and focal. These subtypes share most of the clinical features, but require different surgical approaches. Some genetic mutations may suggest focal or diffuse subtype of CHI, but genetic testing is currently not available worldwide. The incorporation of imaging studies in the evaluation of patients with CHI has changed the surgical management. 18F-DOPA PET/CT has proven highly accurate in distinguishing between focal and diffuse subtypes of CHI. A recent meta-analysis showed a sensitivity of 88% and specificity of 79%. Currently, 18F-DOPA PET/CT is recommended as the first choice imaging modality. Unfortunately, this radiopharmaceutical is not available in most developing countries. 68Ga-labeled peptide somatostatin analogues strongly bind to type II somatostatin receptors, which are highly concentrated in the neuroendocrine pancreatic islet cells. For this reason, these radiotracers may be a good alternative to 18F-DOPA in the distinction between focal or diffuse subtype of CHI.

Methodology: We present a case of a newborn with persistent hyperinsulinemic hypoglycaemia, with poor response to medical management. Abdominal ultrasonography and magnetic resonance imaging did not demonstrate any remarkable findings. PET/CT was performed 35 minutes after intravenous administration of 1 mCi (37 MBq) of 68Ga-DOTATATE. The study was acquired in a Siemens Biograph 64 True Point camera, with a single PET bed position and low-dose CT for attenuation correction and anatomical correlation. Images were reviewed in a dedicated Siemens Workstation with multiplanar reconstruction and PET/CT fusion.

Results: 68Ga-DOTATATE PET/CT showed focal tracer uptake in the distal pancreatic body (white arrow). After this result, the patient underwent partial pancreatectomy. Histopathological analysis demonstrated focal histologic alteration on Langerhans islets architecture that was confirmed with neuroendocrine markers through immunohistochemistry, consistent with clinical diagnosis of focal CHI. After surgery, medical treatment requirements of the patient progressively decreased, with no further episodes of hypoglycaemia.



Conclusion: To our knowledge, only two cases using ^{68}Ga -labeled peptide somatostatin analogues in CHI have been reported. In the first case, PET/CT showed focal pancreatic uptake but histopathology reported diffuse islet cell hyperplasia. In the second case, PET/CT demonstrated diffuse pancreatic tracer accumulation, surgery was not performed. In our case, both ^{68}Ga -DOTATATE PET/CT and histopathology showed focal subtype of CHI, with favorable clinical response to surgical treatment. This is the first report of a case where ^{68}Ga -labeled peptide somatostatin analogue PET/CT successfully guided surgery in a patient with CHI. We conclude that PET/CT with ^{68}Ga -labeled peptide somatostatin analogues is a reasonable alternative to ^{18}F -DOPA in guiding surgical approach in patients with CHI if the latter radiopharmaceutical is not available.

IAEA-CN-232/217

Assessment of Myocardial Contractile Reserve Added to Perfusion/Metabolism (SPECT-CT/PET-CT) Viability Study

M. Štalc¹, B. Simonič², B. Gužič Salobir³, B. Vrtovec³, L. Ležaić⁴

Department for nuclear medicine, University Medical Centre, Ljubljana, Slovenia

Corresponding Author: monika.stalc@gmail.com

Background: Assessment of hibernating, viable myocardium is important in evaluation and management of patients with ischemic left ventricular dysfunction. Various non-invasive imaging techniques are available for assessment of viable myocardium and prediction of functional recovery after revascularization.

Demonstration of preserved glucose metabolism with 18F-fluorodeoxyglucose (18F-FDG) positron emission tomography (PET) imaging in hypoperfused segments (perfusion/metabolism mismatch) is considered the most reliable viability marker. Stress echocardiography using dobutamine, assessing myocardial contractile reserve, provides similar diagnostic accuracy. While 18F-FDG PET is highly sensitive, dobutamine echocardiography, on the other hand, is highly specific in predicting functional recovery.

The objective of this study was to determine the technical feasibility of evaluation of myocardial contractile reserve concurrently with perfusion/metabolism viability study.

Methodology: We studied nine patients with ischemic dilated cardiomyopathy (left ventricular ejection fraction <30%, New York Heart Association functional class III-IV) who were planned for intracoronary transplantation of CD34(+) cells.

Resting myocardial perfusion imaging was performed with SPECT-CT 99m Technetium (99mTc) tetrofosmin electrocardiography (ECG)-gated study. Metabolism/viability study was performed using ECG-gated 18F-FDG PET/CT. ECG-gated 18F-FDG acquisition was repeated on low dose dobutamine (10µg/kg/min) infusion. Global and segmental left ventricular motion (Mot) and thickening (Thk) (using 0-4 and 0-3 score, respectively), ejection fraction (EF), end-diastolic and end-systolic volumes (EDV, ESV) were compared between the studies using a standard 17-segment model. In segments with significant amount of hibernating myocardium (>10% metabolism/perfusion difference in segmental uptake normalized to maximal myocardial uptake) changes in motion and thickening were also assessed.

Results: The amount of hibernating myocardium in the left ventricle amounted on average to 5.9±5.3%. Significant amount of hibernating myocardium was found in 29/153 evaluated segments. On dobutamine stimulation, on average a small increase in EF (2.1±4.9%) and a small decrease in ESV (4.8±21 mL) were found, while average change in EDV was minimal (0.4±18.4 mL). Overall, LV motion and thickening both improved with decrease in defect scores (Thk and Mot, 1.1±5.1 and 1.9±5.1, respectively). In hibernating segments, we found segmental thickening to increase in 10/29 (34%) and decrease in 4/29 (14%), while no change was observed in the remaining 15/29 segments (52%). Similarly, we found an increase in segmental motion in 9/29 (31%) segments, decrease in 5/29 (17%) and no change in 15/29 (52%) segments; in most segments, there was concordance in segmental change in motion and thickening.

Conclusion: Assessment of myocardial contractile reserve added to perfusion/metabolism (SPECT-CT/PET-CT) viability study is technically feasible. In order to assess the potential added predictive value of this method for segmental and global functional improvement after revascularisation, further studies

and comparison to clinical outcome are needed.

IAEA-CN-232/219

Tuberculous Spondylitis: Detection on PET/CT and Correlation with MRI

Z. Ozcan, Y. Ceylan; M. Argin, S. Bayraktaroglu, A. Oral, A. Akgun

Ege University

Corresponding Author: zehra.ozcan@yahoo.com

Background: In developing countries where tuberculosis (TB) is still an endemic disease, pitfalls or false-positive findings related to TB commonly lead to diagnostic difficulties in F18-FDG PET oncologic surveys. While pulmonary TB findings have been well-defined in the relevant literature, extra-pulmonary findings on PET/CT images are less emphasized partly due to its lower frequency. We aim to present PET/CT findings in a case with reactivated TB and focus on the correlative MRI findings of tuberculous spondylitis.

Methodology: A 58 years old man with a previous history of surgery for sigmoid colon carcinoma referred for PET/CT due to severe back pain and increased levels of Ca-19.9. His history was unremarkable except treatment for pulmonary TB.

Results: Whole-body F-18 FDG PET/CT imaging revealed no significant abnormality in colonic segments and regional lymph nodes. However, on lung parenchyma images, a cavitary lesion in right upper lobe was noted. There were multiple F18-FDG avid (SUVmax: 3.8-6.7) tiny nodules and acinar infiltrations in the upper zones. In the left upper lobe multiple calcified granulomas were detected. These pulmonary findings were consistent with reactivation tuberculosis. Additional F18-FDG avid foci were noted in the mid thoracic (SUVmax: 6.3) and lumbosacral (SUV max: 8.5) regions mimicking vertebral metastases. MRI was requested for delineation of vertebral involvement and differential diagnosis. On MRI images, vertebral compression and gibbus deformity at the level of T6-7 was noted. Contrast enhanced images also showed paravertebral abscess at the level of L5-S1 suggesting spinal TB involvement. Combined evaluation of clinical and imaging findings was supporting TB spondylitis at the levels of T6-7 and L5-S1 which is the most common musculoskeletal manifestation of TB infection.

Conclusion: TB is still one of the most important diseases which may lead to diagnostic challenges in imaging practice. As the disease is multi-systemic it may present either with pulmonary or various extra-pulmonary features. Therefore it is advised to be aware about the F18-FDG PET/CT findings in TB for physicians both in developing countries and also in the western world where most of the patients are immigrants from endemic TB regions.

IAEA-CN-232/220

**Radiolabeling of Nimotuzumab Fab' Fragment with 68Ga
and 90Y: A Potential Theranostic Agent for EGFR
Overexpressing Tumors**

A. Xiques Castillo¹, **R. Leyva Montana**², **M. Zamora Barrabi**²; **A.M. Rodriguez Sanchez**², **M. Gongora Bravo**², **Y. Manresa Sanchez**², **L.M. Alonso Martinez**³, **M. Perez-Malo Cruz**²

¹ Jubilant DraxImage-Canada

² Center of Isotopes

³ Department of Radiopharmacy, Center of Isotopes

Corresponding Author: lmichel@centis.edu.cu

Background: Antibody-based targeted delivery of radioisotopes to malignant tissues is a promising approach in cancer diagnostics and therapy. However, intact antibody molecules are large glycoproteins (~150 kDa) that have significantly slower kinetics of distribution and severely limited tissue penetration properties as compared to small molecules like enzymatically produced Fab' fragments. Nimotuzumab is a genetically engineered humanized monoclonal antibody (IgG₁) that recognizes an epitope located in the extracellular domain of human EGFR. Intact nimotuzumab has been extensively studied and has proved to be a promising agent for radioimmunodiagnostics and radioimmunotherapy. Taking this into account, a small vector based on nimotuzumab can become a promising drug for future applications in immuno-PET and radioimmunotherapy of EGFR overexpressing tumours.

Methodology: The ability to get labeled with 68Ga and 90Y from "in-house" generators of a Fab' fragment against the EGFR was studied. In order to obtain the Fab' fragment the intact antibody was cleaved with pepsin in molar excess. After separating the reaction mixture in two steps using affinity and ion-exchange chromatography, the Fab' fragment was finally obtained by reduction of the F(ab)₂ with a molar excess of 2-mercaptoethanol. The Fab' fragment was derivatized with DOTA-NHS ester and the number of DOTA groups linked to Fab' was determined by tracer method. The conjugate was characterized by SE-HPLC, SDS-PAGE and flow cytometry.

Results: The reported procedure to obtain nimotuzumab Fab' fragment was feasible with high levels of purity and integrity. It was successfully derivatized through introduced DOTA-NHS-ester functionalities with an average of nine DOTA groups per molecule of Fab'. Binding assay in epidermoid carcinoma cell line A431 indicated that receptor recognition of the fragment was not considerably compromised by the conjugation process.

Conclusion: The labeling of nimotuzumab Fab' fragment with 68Ga and 90Y yielded radiochemically pure vectors that can become a suitable theranostic agent in near future.

IAEA-CN-232/221

**Accuracy of Combined Breast Ultrasound and
Mammography Versus Breast Ultrasound alone: Not All
Mammography Examinations in Young Women are Justified**

D. Salama¹, H. Gewefel²

¹ Egyptian Atomic Energy Authority

² Women and fetal imaging center

Corresponding Author: drdinahusseiny@yahoo.com

Background: Diagnosing breast cancer in young women (below 40 years of age) is more difficult because their breast tissue is generally denser than the breast tissue in older women. There is a significant level of consistent and inappropriate use of mammography in young women and thereby many examinations are not justified in terms of radiation exposure. The objective of this study was to compare the accuracy of combined breast ultrasound and mammography (ionizing radiation) versus breast ultrasound alone (non-ionizing radiation) in diagnosing breast cancer in young women.

Methodology: We retrospectively analysed all electronic breast ultrasound and mammographic reports of young women from May 2010 to January 2013. Records were reviewed and divided into two groups (whether they came for screening purpose or diagnostic purpose): The first group were those who underwent both breast ultrasound and mammography and the second group were those who underwent breast ultrasound alone. Breast Imaging and Reporting Data System (BIRADS), breast density and histopathological results were assessed for both groups. Examinations rated as BIRADS categories; 1, 2, and 3 were considered negative for malignancy, while 4 and 5 were considered positive and our gold standard was based on either performing biopsy or follow up results for more than 12 months.

Results: A total of 256 patients were included in the study. 158 patients (61.7%) were evaluated using both breast ultrasound and mammography, while 98 patients (38.3%) were evaluated using breast ultrasound alone. Palpable mass was the presenting symptom in 111 (43.4 %) of the cases. Biopsies were performed for 36 (14.1%) patients, while follow up for one year or more was done in 220 (85.9%) patients. 22 patients were malignant (8.6%) while 234 (91.4%) were benign cases. For the 158 cases who were evaluated with breast ultrasound and mammography (the first group), the sensitivity, specificity, positive predictive value (PPV), negative predictive value (NPV) and over-all accuracy were 92.9% , 98.6% , 86.7% , 99.3% and 98.1 % respectively; while for the 98 cases who were evaluated with breast ultrasound only (the second group), the results were 87.5%, 100%, 100 % 98.9% and 89.8% respectively.

Conclusion: In young women (below 40 years of age), breast ultrasound alone can accurately and independently reveal malignant cases, however performing combined breast ultrasound and mammography could be restricted to suspicious cases only. This is ethically required for the justification of radiation exposure.

IAEA-CN-232/222

Importance of 18F-FDG PET/CT Findings in Primary Staging and Clinical Management of Patients with Breast Cancer

B. Gunalp, S. Ince, N. Arslan

Gulhane Military Medical Academy and Faculty, Department of Nuclear Medicine

Corresponding Author: bgunalp@yahoo.com

Background: Breast cancer is the most frequently diagnosed cancer and the most common cause of cancer death among women worldwide. Accurate initial staging is important for therapy selection and prognostication.

Aim: We retrospectively compared 18F-Fluorodeoxyglucose (18F-FDG) Positron Emission Tomography/Computed Tomography (PET/CT) findings in breast cancer patients with available conventional imaging modalities (CIM) results and tried to determine the added benefits of PET/CT on primary staging and clinical management of patients with breast cancer.

Methodology: Between January 2010 and August 2014, 150 consecutive newly diagnosed invasive breast cancer patients with tumors >2cm and referred to 18F-FDG-PET/CT for primary staging were included in this retrospective study. Clinical evaluation for staging had been made by CIM before PET/CT. The clinical benefits of PET/CT were determined by taking into account the importance of additional PET/CT findings on initial staging and patient management.

Results: PET/CT detected additional tumor foci in 22 patients (15 %), extra-axillary lymph nodes in 15 patients (10%), distant metastases in 30 patients (20%) and synchronous malignancy in three patients (2%) which were not detected by CIM before PET/CT scan. According to PET/CT findings, 57 patients (38%) were upstaged and six patients (4%) down staged. 18F-FDG PET/CT was found to be very useful for evaluating equivocal or suspicious findings on CIMs. 18F-FDG PET/CT findings led to changed therapy plans in 22 of patients (15%). 18F-FDG PET/CT was found to be cost-effective for primary staging of breast carcinoma, since it decreased the total number of imaging studies used for staging to rule out distant metastatic disease. Axillary lymph node positive patients (39, 26%) underwent direct axillary lymph node dissection; and time and cost of sentinel lymph node biopsy procedure was saved. In 30 (20%) patients, distant metastases were detected only by 18F-FDG-PET/CT and unnecessary operation costs, and morbidity were prevented. Initial 18F-FDG PET/CT scan also served as the baseline study for therapy response evaluation.

Conclusion: We have shown that PET/CT is a powerful diagnostic modality in the detection of multifocality, extra-axillary nodal and distant metastases, which were mostly missed or not imaged with CIM. It is concluded that the added benefits of PET/CT have a high impact on primary staging and management in patients with invasive breast carcinoma, especially in high-grade tumors.

IAEA-CN-232/223

**Optimization of Radio-Iodine 131 Dose in Treatment of
Children with Diffuse Lung Metastasis from Thyroid
Carcinoma- Local Experience at Al-Assad University
Hospital, Damascus**

M. Zein

Al-Assad University Hospital

Corresponding Author: majdizein@yahoo.com

Background: Children with diffuse lung metastasis are considered to be a challenge for radioiodine treatment, due to the critical difference in the effective treatment dose and side effects expected after long-term treatment with several radioiodine 131 doses.

Methodology: 11 children (five males and six females) suffering from diffuse lung metastasis from thyroid carcinoma were admitted to the department of nuclear medicine at Al-Assad University Hospital, Damascus in the period between May 2010 and March 2012.

The age of the patients ranged from 7 to 14 years.

General medical evaluation, both physical and psychiatric, was done for all patients. Also, whole blood count (WBC), renal function, thyroglobulin levels, ultrasound of the anterior neck and chest x-ray were obtained.

After discontinuation of thyroid hormone therapy for 3-4 weeks and withdrawing foods containing iodine for sufficient time, a dose of radioactive iodine between 30-60 mCi (depending on the patient age and weight) was given at the department; admission was prolonged to 3-5 days according to residual activity in the body.

Whole body scans were performed on the 5th day after radioiodine treatment.

Results: Six months after radioiodine treatment, a second total evaluation was done for all patients.

All patients showed residual metastasis in the lungs, without any residual tissue in the neck.

According to initial results all patients were given a second radioactive iodine dose of 50-60 mCi.

Another repeated dose was given according to the results of general evaluation until total remission of the disease in 5 children was reached.

No significant side effects or respiratory symptoms were noted, except for dyspnoea in 3 children.

Conclusion: Diffuse lung metastasis from thyroid cancer can be treated safely using a radioactive iodine dose of 30-60 mCi without significant side effects, with overall acceptable treatment results.

IAEA-CN-232/224

Improving the Management of Cancer Diseases in Senegal

R. S. Senghor, O. Diop

Service de Médecine Nucléaire, Hôpital Général de Grand Yoff, Dakar, Sénégal

Corresponding Author: rssenghor@yahoo.fr

Background: Nuclear medicine imaging is dependent on metabolic function. Each explored function has a metabolic tracer - the radiopharmaceutical. Among Senegalese population, important clinical applications include breast and prostate cancer. Bone is the most common site of metastatic disease associated with breast and prostate cancer.

The purpose of this project is to evaluate an approach to strengthen diagnosis and monitoring of cancer in Senegal.

Methodology: Preliminary studies carried out in our nuclear medicine service demonstrate the role of bone scintigraphy for staging metastatic breast and prostate cancers in Senegal. The equipment used is a single photon emission computed tomography NUCLINE-SPECT. The radiopharmaceutical used for bone imaging is methylene diphosphonate labeled with Technetium-99m (^{99m}Tc -MDP), which is obtained in situ from a molybdenum-99 ($^{99}\text{Mo}/^{99m}\text{Tc}$) generator. The patients have received intravenously a mean dose of 740 MBq (20 mCi) of ^{99m}Tc -MDP. Patients were put in the lying position, planar and dynamic images were obtained 3 hours after injection with a gamma camera, SPECT-MEDISO, with a low-energy high resolution collimator. However, bone imaging sometimes had to be confirmed with CT or MRI.

Results: It is essential for Senegal to upgrade nuclear medicine procedures. The hybrid molecular imaging acquisition (PET and SPECT) and morphological (CT and MRI) imaging take an important place in the diagnosis, staging and monitoring of various malignancies. The use of PET relies on isotopes produced in a cyclotron. The isotopes are short-lived, such as fluorine-18 (^{18}F), with a half-life of 110 min. ^{18}F -FDG, a form of glucose labeled with the radionuclide, is the most commonly used PET radiopharmaceutical for diagnostic purposes. ^{18}F -FDG is readily incorporated into the cell without being broken down, and is a good indicator of cell metabolism.

^{18}F -FDG-PET acquisitions give more precision in the diagnosis of cancer diseases. The whole-body technique provides an improved spatial resolution and with ^{18}F -FDG a quantification of tissue glucose metabolism. PET is more specific than bone scintigraphy.

Conclusion: Introducing PET procedures will develop nuclear medicine activities and increase the level of radiopharmacy practice. A training programme will provide the principles of molecular imaging, production of PET radionuclides and radiopharmaceuticals, regulations and specific uses of PET radiopharmaceuticals, generators used in PET imaging, their characteristics and quality control.

To improve health care in Senegal, the Nuclear Medicine Department should strongly suggest to the Ministries of Health, Education and Research to provide a PET camera and cyclotron.

Provision of small cyclotrons to supply the nuclear medicine center with desired radiopharmaceuticals, mainly ^{18}F -FDG, is crucially important.

IAEA-CN-232/225

Preliminary Feasibility Study for the Implementation of a PET-CT Equipment in Senegal

S. Seck Gassama, R. Senghor

Hospital General Grand Yoff (Hoggy) Senegal

Corresponding Author: ssgassama@yahoo.fr

Background: In Senegal, infectious diseases are still the leading cause of death (47%), whereas non-communicable diseases account for 34 % of deaths; cardiovascular diseases (10%) and cancers (5%) are the leading NCDs. The situation is however changing due to lifestyle changes. According to prognosis by the WHO, 28 million people in the region will die of a chronic disease over the next ten years. Introduction of new imaging techniques such as PET-CT should be discussed regarding expected benefits, and consequently there is a need to sensitize clinicians and decision makers on this matter.

Methodology: The study reviewed statistic data on cardiovascular diseases and cancer in Senegal, referred patients with cardiovascular diseases and cancer to the nuclear medicine center of Hoggy in Dakar, and the technical, medical, financial and organizational aspects related to the implementation of PET-CT equipment.

Results: In Senegal, cardiovascular diseases are the second cause of death after malaria, and the leading cause of death in adults. Hypertension is the main cardiovascular disease with a prevalence of about 40%. Cancer comes after cardiovascular diseases with 6800 cases recorded each year, causing 4.900 deaths among people aged 50 to 60 years. Among Senegalese females, cervical cancer is the most frequently diagnosed cancer and the leading cause of cancer death, accounting for 29.3% of the total cancer burden, followed by breast cancer (20.9%). Liver cancer is the leading cancer type in males (27.8%), followed by prostate cancer (14%). Scintigraphy in cardiovascular diseases and cancers represents 62% of nuclear medicine activities.

The infrastructure plans should take into account both installation of a cyclotron and PET. Medical studies tend to show an improvement in sensitivity and specificity of PET, as well as its great contribution to the diagnostics, the prognostic evaluation and the long-term monitoring of patients with cardiovascular disease and cancer, and its potentially high clinical impact; multidisciplinary consultation meetings between nuclear physicians and radiologists allow for better care of patients. The high cost of the machine hinders the development of this new technology. Indeed, the device has a cost of € 2.5 million, the installation costs amount to € 800.000 and the operating budget to € 2 million per year.

Conclusion: In Senegal, the overall cardiovascular and cancer mortality rates are high, most likely because of a combination of late stage of the disease at diagnosis and limited access to timely and standard treatment. This could be improved through a good management of risk factors, and early detection and treatment. 18F-FDG PET-CT is a non-invasive metabolic imaging modality which has demonstrated usefulness in cardiovascular diseases and cancers. In the West African region, to minimize the costs and enhance effectiveness, it could be considered to share human resources and the use of such equipment acquired as part of a multi-partnership.

IAEA-CN-232/226

Substance P – A Possible PET Diagnostic Agent

K. Smilkov¹, **D.G. Ackova**¹, **A. Duatti**³, **G. Di Domenico**³, **R. Guerrini**², **E. I. Janevik**¹

¹ Faculty of Medical Sciences, Goce Delcev University, Stip, Macedonia

² Department of Chemical and Pharmaceutical Sciences, University of Ferrara, 44121 Ferrara, Italy

³ Laboratory of Nuclear Medicine, Department of Experimental Medicine, University of Ferrara, Via L. Borsari, 46, 44121 Ferrara, Italy

Corresponding Author: ksmilkov@gmail.com

Background: Tachykinins are excitatory neuropeptides synthesized in neuronal and glial cells of the human central and peripheral nervous system. These peptides act as excitatory neurotransmitters and/or neuromodulators and induce DNA synthesis leading to stimulation of cell division and proliferation. As their most prominent member, substance P (SP) has been known to trigger biological responses by linking to (mostly) NK1 receptors. The presence of functional NK1 receptors has already been documented in malignant brain tumors of glial origin, medullary thyroid cancer, non-small cell lung cancer and pancreatic carcinoma.

Methodology: ^{99m}Tc and ¹⁸⁸Re radiolabeled SP was tested for cell surface binding after incubation with NK1 receptor expressing U-87 MG cells, and negative control cell line L-929. Further preliminary whole-body biodistribution studies were carried out with ^{99m}Tc labeled SP using a hybrid SPECT/CT YAP(S)PET small-animal tomography scanner.

Results: Our results using ^{99m}Tc and ¹⁸⁸Re radiolabeled SP, demonstrated the affinity of these radioconjugates for NK1 receptor expressing cells, showing pronounced cell surface binding after incubation with U-87 MG cells, compared to the negative control cell line L-929. Further preliminary whole-body biodistribution studies with ^{99m}Tc labeled SP using a hybrid SPECT/CT YAP(S)PET small-animal tomography scanner, showed a predominant kidney elimination 60 min post injection, which is expected for peptides, and an uptake in a region associated with the thymus. Although cardiac uptake was suspected in this region, it was excluded with ex-vivo measurement of the thymus gland, which after 60 min showed high, detectable uptake of 0.0132%IA/g. This finding confirmed previous ones about the localization of specific SP binding sites.

Conclusion: Following the success of ⁶⁸Ga-DOTATOC, and knowing that receptor targeted imaging may provide better diagnostic outcomes in comparison with registering a high glucose uptake in the affected area using ¹⁸F-FDG, we believe that it would be interesting to consider new radiochemistry approaches of radiolabeling SP with ⁶⁸Ga. ⁶⁸Ga (or other PET radionuclides) may provide better screening and possible detection of malignant brain tumors of glial origin, but also other diseases known to express NK1 receptors.

IAEA-CN-232/227

Development of Rituximab Radioimmunoconjugates as PET-Radiopharmaceuticals

D. Gjorgieva Ackova¹, **K. Smilkov**¹, **P. Makreski**², **T. Stafilov**²,
E. Janevik-Ivanovska¹

¹ Department of Pharmacy, Faculty of Medical Sciences, University Goce Delcev - Stip, FYR Macedonia

² Department of Chemistry, Faculty of Natural Sciences and Mathematics, University "Ss. Cyril and Methodius"- Skopje, FYR Macedonia

Corresponding Author: darinka.gorgieva@ugd.edu.mk

Background: Positron emission tomography (PET) has a growing use in medical decision making and management of patients. To further apply the unique properties of PET, more clinically validated PET-radiopharmaceuticals are required and subsequently new and better radiochemical preparation methods are under development. With respect to radiochemistry development, most efforts have been made with the use of ¹¹C and ¹⁸F as radionuclides. Also, labeling methods development stimulates the use of different radiometals as ⁶⁸Ga, ⁸⁹Zr and ⁶⁴Cu for clinical use. These radionuclides have their specific characteristics with respect to half-life, positron energy (resolution), positron abundance and availability. Depending on the biological target of interest and the properties of the PET-radiopharmaceutical the proper radionuclide should be selected.

For the treatment and diagnosis of malignancies, various radiolabeled monoclonal antibodies have also been developed. Rituximab selectively binds with high affinity to the CD20 antigen (human B-lymphocyte restricted differentiation antigen, Bp35), which is expressed on B-lymphocytes and on >90 % of B cell non-Hodgkin lymphomas (NHL). These properties make the CD20 receptor a suitable target for radiotherapy/diagnostic purposes.

Methodology: After promising results (in vitro and in vivo studies) that we obtained in an investigation performed with ¹⁷⁷Lu-rituximab immunoconjugates intended for NHL therapy, in order to obtain ⁶⁸Ga anti-CD20 radioimmunoconjugates for use in PET studies, different bifunctional chelating agents-anti-CD20 conjugates (BFCA-rituximab) were assessed for preliminary chemical characterization. Rituximab, conjugated with three different BFCA, p-SCN-Bn-DOTA, p-SCN-Bn-DTPA and 1B4M-DTPA in form of freeze-dried preparation, was subjected to characterization and determination of secondary structure (which is mandatory for protein-based radiopharmaceuticals), quality parameters (purity, integrity, fragmentation and aggregation of the antibody), and average number of BFCA attached with employment of different analytical techniques such as Matrix-Assisted Laser Desorption Ionization Time-of-Flight Mass Spectrometry (MALDI-TOF-MS), Sodium Dodecyl Sulphate-Polyacrylamide Gel Electrophoresis (SDS-PAGE), Fourier Transform Infrared (FT-IR) and Raman Spectroscopy.

Results: The results demonstrate that after lyophilisation, diluted rituximab immunoconjugates remain stable. No modification of its chemo-physical characteristics, no aggregation, and preservation of antibody secondary structure were observed. Binding of an average 6.1 (p-SCN-Bn-DOTA), 8.8 (p-SCN-Bn-DTPA) and 8.3 (1B4M-DTPA) molecules per antibody was determined.

Conclusion: The results indicate that the time frame for the practical use of rituximab immunoconjugates can be safely extended using lyophilisation, enabling, for example, safe and longer storage and supporting

the possibility of developing a “ready-to-label” rituximab immunoconjugates for imaging/therapy. Further experiments are still needed in order to demonstrate biological and pharmacological properties. ^{68}Ga -labeled rituximab immunoconjugates may provide PET screening of the therapeutic outcomes following ^{177}Lu therapy. Therefore, developing a kit containing this antibody, intended for ^{68}Ga labeling, will be a part of our future investigation.

IAEA-CN-232/228

**Incidental Hypermetabolic Thyroid Abnormalities on
18F-FDG PET/CT and Correlation with Histological
Findings: A Retrospective Analysis**

P. Almeida-Filho, L. Vieira De Carvalho, C. Almeida

Real Hospital Português de Pernambuco

Corresponding Author: pauloalmeidafilho.nuclear@gmail.com

Background: Normal thyroid gland usually does not show significant 18F-FDG uptake. Therefore, any increase of glucose metabolism is considered abnormal. Incidental thyroid 18F-FDG uptake on routine 18F-FDG PET/CT (PET/CT) is found on 2% of the cases, representing inflammatory or tumoral disease.

Methodology: We retrospectively identified 100 patients (22 male, 78 female, age from 29 to 91, mean 64.2 years) in a total of 4562 patients submitted to 18F-FDG PET/CT in our institution from 2009 to 2015, with incidental findings in the thyroid classified into two categories: diffuse uptake and focal uptake.

Results: Patients with incidental findings in the thyroid represented 2.2% of the total number of patients studied in our institution.

All 38 patients with diffuse uptake had clinical and laboratorial diagnosis of thyroiditis.

Among the 62 patients with focal uptake, 38 (61%) had detectable nodules on CT and 24 (39%) had no anatomic correlation on non-contrast CT. In this group, 18 (29%) had thyroiditis, 21 (34%) had confirmed diagnosis of differentiated thyroid cancer (DTC) as a second primary malignancy and in 23 (37%), benign thyroid nodules were identified. None of the patients had metastatic tumor or diffuse neoplastic infiltration of the thyroid.

Conclusion: We conclude that incidental focal hypermetabolic foci in the thyroid should be investigated due to the relatively high incidence of second primary malignancy.

IAEA-CN-232/229

**Correlation between Recombinant Human TSH Stimulated
18F-FDG PET/CT Findings and Thyroglobulin Levels on
Patients with Differentiated Thyroid Cancer**

P. Almeida-Filho, L. Vieira De Carvalho, C. Almeida

Real Hospital Português de Pernambuco

Corresponding Author: lucasvieira3107@gmail.com

Background: Whole body 18F-FDG PET/CT (PET/CT) is an accepted tool for investigation of differentiated thyroid cancer (DTC) with high thyroglobulin (Tg) levels and negative whole body iodine scan (IWS). The rationale is that undifferentiated tumors lose the capacity of iodine uptake, but keep producing Tg that works as a specific tumor marker. At the same time, these tumors tend to be more aggressive and have increased glucose metabolism. Several papers have shown that stimulation with recombinant human TSH (TSHr) may increase the sensibility of the PET/CT scan.

Methodology: We retrospectively studied 25 patients with DTC (23 papillary and 2 follicular carcinoma cases) submitted to TSHr stimulated PET/CT and Tg measurement. All patients had negative IWS and were free of Tg antibodies.

Results: In 24 patients, stimulated Tg levels were elevated (above 1ng/dl). PET/CT showed an uptake at the thyroid bed in 4 patients (14,3%), in cervical lymph nodes in 17 patients (60,7%) and in distant sites in 7 patients (25%). The distant sites of uptake were lymph nodes (4 mediastinal, 1 axillar and 1 abdominal), and bone in 1 individual. None of the PET/CT studies was negative.

Tg levels varied from 0,2 to 965 ng/dl (mean 52,7 ng/dl). The maximum standardized uptake value (SUVmax) in the lesions varied from 1,7 and 4,8 (mean 2,8).

Conclusion: We conclude that TSHr stimulated PET/CT is a valuable tool in finding suspicious lesions in patients with high thyroglobulin levels and negative IWS.

IAEA-CN-232/230

**Initial Experience with PET-CT Guided Biopsy/FNA Using
Automated Robotic Arm**

R. Kumar

All India Institute of Medical Sciences, New Delhi

Corresponding Author: rkphulia@hotmail.com

Background: A precise morphologic diagnosis is essential for the planning of treatment and the prognosis. This can be achieved by tissue sampling, which can be obtained surgically or by image guidance. Ultrasonography (USG), computed tomography (CT) and magnetic resonance imaging (MRI) are commonly used imaging modalities for image guided biopsy. However, many times the tissue obtained is either inadequate or necrotic and histopathology report of the same is not possible. Positron emission tomography-CT (PET-CT) provides both functional and anatomical details and helps to direct the needle to the desired site more accurately and consistently.

Objective: We investigated the feasibility and accuracy of PET-CT guided biopsy / fine needle aspiration cytology (FNAC) using automated robotic arm attached with the PET-CT scanner.

Methodology: A total of 74 patients, 52 male and 22 female with age range of 25-70 years, underwent PET-CT guided biopsy/FNAC using automated robotic arm attached with the PET-CT scanner. All patients were suspected/confirmed cases of cancer, and had abnormal PET-CT scan. In all patients conventional imaging modalities like USG and / or CT were either unable to demonstrate the lesion or repeated biopsy/FNAC was inconclusive. The technique involved PET-CT acquisition of the region for which the biopsy/FNAC is planned. Digital Imaging and Communications in Medicine (DICOM) images were transferred to the computer attached with a robotic arm. Images were displayed and those where the lesion is best seen were selected. The target lesion and point of entry in the image are set. All the calculations regarding depth, angle of entry of the needle were sent to the robotic arm attached with the PET-CT scanner.

Results: Of 74 patients, 66 were positive for malignant pathology and 4 were benign. Two patients with uptake in thigh and neck region had fibrosis; repeated biopsy revealed no cells. Follow-up in both patients showed no recurrence. Only two patients with small peripancreatic and cervical lymph nodes were inconclusive. Of the 66 patients which were positive for malignant pathology, 34 had primary lung cancer, 28 had recurrent malignant disease and 2 had breast cancer, 1 had gall bladder cancer and 1 had colon cancer.

Conclusion: Based on the results of this study we conclude that PET-CT guided biopsy/FNAC using automated robotic arm attached with the PET-CT scanner is a unique, feasible, and easy-to perform method to obtain a tissue sample from viable tumor tissue. The automated robotic arm provides better accuracy, precision and confidence to users.

IAEA-CN-232/231

**Place of the Sentinel Node in Uterine Cancers: Preliminary
Joint study between Nuclear Medicine Departments of the
Hospital St. Antoine of Paris and General Hospital of Grand
Yoff of Dakar**

O. Diop¹, R.S. Senghor², S. Gassama³, B. Ndong⁴ J.Y Devaux⁵

¹ UCAD Sénégal

² Hospital General Grand Yoff Senegal

³ Faculty of Medicine University Cheikh Anta Diop Of Dakar (Ucad)

Hospital General Grand Yoff (Hoggy)

⁴ Service de Médecine Nucléaire HOGG/Dakar

⁵ Hospital of St. Antoine of Paris

Corresponding Author: ousseynou.diop@ucad.edu.sn

Background: Lymph node status is an important prognostic factor and a major decision criterion for adjuvant treatment, making nodal evaluation necessary. Non-surgical nodal evaluation by lymphography, CT or MRI is not satisfactory in terms of sensitivity.

Sentinel lymph node technique seems to be a solution to this problem in cancers of the uterus.

Methodology: 1. Realization of scintigraphy for 27 patients with cervical cancer in the early stage, with a SPECT or SPECT-CT; and 2. Collection and analysis of scintigraphic data, intraoperative and postoperative.

Results: Positive sentinel node on scintigraphy and / or blue dye was found in 25 patients. It was bilateral in 80% and unilateral in 20% of cases. Pelvic localization was found in 85%, and 15% was extrapelvic (paraaortic).

In pelvic localization, hypogastric dissemination was found in 47.06%, presacral dissemination in 29.41%, and lateral dissemination in 23.52% of cases.

Seven patients (26%) underwent node dissection, and 20 (74%) underwent targeted sampling.

No lymph node was positive in frozen section or immunohistochemistry. Survival was better in patients who were not subjected to lymphadenectomy in the first 6 months.

Conclusion: Sentinel node reaction in the uterine cancer is not specific for metastatic lymph node. Lymphadenectomy based solely on sentinel node without histological examination may not be necessary and thus impairs the quality of life of the patient. Although the study of uterine sentinel node in SPECT or SPECT-CT is a very important step, it has limitations.

PET, which has the highest specificity, therefore seems to be the best tool in nodal evaluation of cancer of the uterus.

IAEA-CN-232/232

Well-Differentiated Neuroendocrine Tumors with Aggressive Behavior Frequently Display Predominantly Hyperglycolytic Tumours on 18F-FDG PET/CT

A. Llamas-Olier

Instituto Nacional De Cancerología

Corresponding Author: allamas@cancer.gov.co

Background: The therapeutic algorithm of neuroendocrine tumors (NETs) requires integration of several forms of therapy; therefore it is crucial to identify the more aggressive forms. The histopathological classification of NETs is still limited because the tissue obtained from biopsy of a single site of disease or following surgical excision of a portion of the total tumor burden does not necessarily reflect the behaviour of the whole lesion and in all the sites, and more than one sample is seldom available in routine clinical practice. Although Ki67 staining has been shown to have prognostic significance in gastroenteropancreatic (GEP) NETs, pitfalls such as tumor heterogeneity may mislead the determination of tumor grade. The combination of somatostatin receptor (SSTR) scintigraphy and 18F-FDG PET/CT characterizes receptor expression and glycolytic metabolism, enables visualization of intra-individual tumor heterogeneity, and helps direct appropriate therapy. We sought to determine the rate of F18-FDG uptake in patients with well-differentiated (WD) NETs with clinical or radiologic evidence of advanced or progressive disease.

Methodology: We reviewed the charts of 7 consecutive patients (3 women and 4 men; age range 54-79 y) with histologically proven metastatic or progressive GEP NETs who were examined with Tc-99m EDDA/HYNIC TOC and F-18 FDG PET/CT scans within a 30-day interval. The clinical indications for PET/CT were: initial staging, n=2; primary tumor localization, n=2; suspected recurrence, n=3. All patients had well-differentiated NETs with histologic grade 1 (n= 3) or 2 (n=4). Patients were grouped according to their Ki67: group A (Ki67 \leq 2%, n=3), group B (Ki67=3-9%, n=2) and group C (Ki67=10-20%, n=2). Tc-99m HYNIC TOC and PET/CT scans were sequentially reviewed by two experienced nuclear medicine specialists. A positive scan finding was defined by significant tracer uptake based on visual assessment. Abnormal tumor findings were compared between both types of scans and further described as predominant SSTR-overexpression (SSTR+) vs hyperglycolytic activity (FDG+), or balanced predominance (same lesions with equal intensity of uptake of both tracers).

Results: Primary tumors were localized in pancreas (n=3), duodenum (n=1), ileum (n=1), or unknown (n=2). Only one patient had a negative Tc-99m HYNIC TOC scintigraphy; another had a negative PET/CT scan. The 3 patients in group A were SSTR+. Group B patients were SSTR+ (n=1) and FDG+ (n=1), respectively. Group C patients were FDG+ (n=1) and balanced predominance (n=1).

Conclusion: A significant number of patients with WDNets display predominantly hyperglycolytic tumors, particularly when Ki67 lies between 3% and 20%. The coexistence in the same patient, or even in the same tumor, of well-differentiated and poorly-differentiated tumor clones may explain the variability of tumor behaviour and the sometimes fatal progression of certain patients with a NET who had wrongly been classified as low risk. F-18 FDG PET/CT can help to identify patients with WDNets who could benefit from chemotherapy.

IAEA-CN-232/233

Radiation Protection in Design of PET-CT Facility to Reduce Doses for Occupational Personnel and Patients

N. Sirag, A. Hussein

Egyptian Nuclear and Radiological Regulatory Authority

Corresponding Author: dr_nsirag@yahoo.com

Background: Plans and specifications will require assessment for radiation protection by a certified expert. The radiation protection assessment will specify the type, location and amount of radiation protection required according to the final equipment selection and layout. Radiation protection requirements shall be incorporated into the final specifications and the building plans. Radiation shielding will be required to a number of areas. Radiation protection aspects of PET-CT facilities, NM facility with PET-CT, can result in a shielding requirement. Even modest reductions in the radiation levels at 511 keV require significant amounts of shielding.

Methodology: A ground floor site is preferred but if this cannot be achieved, consideration should be given to units above, below and adjoining the proposed location with regard to radiation shielding requirements, the weight of equipment and associated shielding and access for equipment and radioactive isotopes. The Unit should not act as a thoroughfare to other units of the healthcare facility.

Waiting areas should allow separation of dosed and undosed patients. Some patients may need to wait for 45 minutes after dosing for uptake. It is also preferable to separate dosed patients from relatives. Dosed patients should have access to drinking water and toilet facilities without having to access general waiting areas.

Results: The Nuclear Medicine Unit should be located with ready access to the Medical Imaging Unit, PET Unit if provided, Emergency Unit, Operating Unit and Critical Care areas. It requires easy access for ambulant patients and beds/ stretchers.

Design

Construction Standards:

- Flooring shall be adequate to meet load requirements for patients and personnel.
- Floors and walls should be constructed of materials that are easily contaminated.
- Walls should contain necessary support systems for either built- in or mobile oxygen and vents for radioactive gases.
- Ceiling height should be a minimum of 3 meters in procedure or scanning rooms.
- Natural light is desirable in all patient areas. Lighting level in reporting rooms needs to be adjustable. Safety and Security

- Floor finishes and junctions should be smooth, impervious and non-absorbent in case of radiation spills. Building Service Requirements

Conclusion: PET-CT facilities involve somewhat different design requirements than conventional NM facilities and are more likely to require additional shielding. By providing good handling facilities and following good work practices, radiation dose to the staff, public, and environment can be maintained well below the acceptable limit.

To reduce exposure to operating personnel in the PET-CT facility and to improve instrument performance, the type of work and the radionuclides and their activities intended to be used should be taken into consideration. The concept of ‘categorization of hazard’ should be used in order to determine the special needs concerning ventilation, plumbing, materials used in walls, floors and work benches, signs, labels and records, shielding, floors, impervious material, and curved to the walls glued to the floor No carpet!

IAEA-CN-232/234

**18F-Fluorodeoxyglucose Positron Emission
Tomography/Computer Tomography (18F-FDG PET/CT) in
Early Treatment Response Assessment in B-Cell Non-
Hodgkin Lymphoma Patients: A Preliminary Result**

N.H. Le, H.S. Mai

Tran Hung Dao Hospital

Corresponding Author: lengochal08@yahoo.com

Background: The aim of our study was to differentiate between responders and non-responders B-cell non-Hodgkin lymphoma patients to standard treatment based on early 18F-FDG PET/CT.

Methodology: In our center, a total of 22 consecutive B-cell non- Hodgkin lymphoma patients were newly diagnosed between July to December 2014. All the patients underwent 18F-FDG PET/CT scan before treatment, after 3 cycles and 6 cycles of chemotherapy using the CHOP or R-CHOP regimen. Modified Ann Arbor assessment criteria for staging, and Cheson BD for treatment response were applied.

Results: After 3 cycles of chemotherapy, 45.5% (10 patients) of those 22 patients had a complete response (CR), 50% (11 patients) had a partial response (PR). Meanwhile, one patient (4.5%) who had a positive PET scan received an alternative chemotherapy regime. After 6 cycles of chemotherapy, all patients in the CR group had no evidence of relapse on PET/CT. In the PR group, 2/11 (18%) patients had a complete response, 7/11 patients (64%) permanently remained in partial remission, and 2 patients (18%) had a relapse afterwards.

Conclusion: 18F-FDG PET/CT has a high potential in helping oncologist in decision making for further treatment of B-cell lymphoma patients.

IAEA-CN-232/235

**Value of 18F-Fluorodeoxyglucose Positron Emission
Tomography/Computer Tomography (18F-FDG PET/CT) in
Detection of Recurrence in Colorectal Cancer Patients**

N.H. Le, H.S. Mai

Tran Hung Dao Hospital

Corresponding Author: lengocha108@yahoo.com

Background: This study assesses the role of 18F-FDG PET/CT in detection and management of colorectal cancer patients with suspected recurrence and metastases.

Methodology: 30 patients suspicious for colorectal cancer recurrence based on clinical symptoms or serum carcinoembryonic antigen (CEA) levels were recruited to the study. All patients underwent conventional scan (abdominal CT, ultrasound, chest X-ray) and PET/CT. Sensitivity (SEN), specificity (SPEC), positive predictive value (PPV) and negative predictive value (NPV) were calculated using either histopathology or follow-up imaging as the standard of reference and compared to the ability of CEA level (CEA level higher than 5 ng/ml was considered positive).

Results: Regarding the detection of local recurrence, PET/CT has shown a SEN of 100%; SPEC of 67%; PPV of 88%; NPV of 100%. The SEN, SPEC, PPV, NPV of conventional imaging was 43%, 100%, 100%, 43%, respectively. The value of CEA level was 64%, 67%, 44%, 81% in SEN, SPEC, PPV and NPV, respectively. PET/CT found 9 of 30 colorectal cancer patients who had positive regional lymph node metastases, however, conventional imaging identified only 4 of 30 these patients. Similarly, in detection of distant metastases, 4 of 30 cases had liver and lung metastases on PET/CT, while only 2 of 30 cases were shown on CT and chest X-ray.

Conclusion: 18F-FDG PET/CT has high accuracy in the assessment of local recurrences and metastases, impacting significantly on colorectal cancer patient management.

IAEA-CN-232/236

Utility of 18F-Fluorodeoxyglucose Positron Emission Tomography/Computer Tomography (18F-FDG PET/CT) in Initial Diagnosis and Staging of Patients with Primary Colorectal Cancer

N.H. Le, H.S. Mai

Tran Hung Dao Hospital

Corresponding Author: lengocha108@yahoo.com

Background: In pre-operative colorectal cancer staging there is an emphasis on techniques that might change the treatment plan. Conventional imaging modalities such as CT, MRI, and ultrasound have lower accuracy in detecting regional lymph node and distant metastases. This study aimed to evaluate the important role of 18F-FDG PET/CT in the initial diagnosis and staging of patients with primary colorectal cancer.

Methodology: A total of 60 patients suspicious for colorectal tumor detected by colorectal endoscopy (including 55 patients with adenocarcinoma lesions proven by pathological histology) were enrolled in the study. The patients underwent both PET/CT and conventional diagnostic imaging (abdominal CT and/or pelvic MRI).

Results: 18F-FDG PET/CT and conventional imaging detected correctly primary tumors in all colorectal cancer patients. Regarding regional metastatic lymph node detection, PET/CT showed higher sensitivity (78%) and specificity (84%) compared to conventional imaging (61% and 69%, respectively). For distant metastases assessment, the sensitivity and specificity of PET/CT was 100% in all cancer patients with liver and pulmonary lesions. 18F-FDG PET/CT findings were important in restaging of 50% of patients, and modified the therapeutic approach in 25% of patients.

Conclusion: 18F-FDG PET/CT is superior to conventional imaging in pre-surgical staging of colorectal cancer and has a considerable impact on management of colorectal cancer patients.

IAEA-CN-232/237

**Value of 18F-FDG-PET/CT in Detecting
Recurrent/Metastatic Lesions in Post-Surgical Differentiated
Thyroid Carcinoma Patients with High Serum
Thyroglobulin and Negative 131I Whole Body Scan**

N.H. Le, Q.B. Bui

Tran Hung Dao Hospital

Corresponding Author: lengocha108@yahoo.com

Background: In clinical practice, there are approximately 20 – 30% of post-surgical differentiated thyroid carcinoma (DTC) patients treated with 131I therapy who have recurrent/metastatic lesions, which cannot be detected by 131I whole body scan. The purpose of our study was to evaluate the value of 18F-FDG-PET/CT in patients with high serum thyroglobulin (Tg) level and negative 131I whole body scan.

Methodology: We studied 69 post-surgical DTC patients with high serum Tg level and negative 131I whole body scan after therapeutic dose in the Department of Nuclear Medicine, Tran Hung Dao Hospital.

Results: 92 lesions were detected in 43/69 patients (62.3%) with positive 18F-FDG-PET/CT scan compared to only 39 lesions in 26/69 patients (37.7%) detected on CT scan. The sensitivity, accuracy and negative predictive value of 18F-FDG-PET/CT was 87%, 88% and 76% respectively; and was higher than with CT (54.3%, 67.2% and 48.8%, respectively). Specificity and positive predictive value of 18F-FDG-PET/CT (90.5% and 95.2% respectively) was similar to those of CT (95.2% and 96.2%, respectively). SUVmax threshold with good diagnostic value was 4.5 (sensitivity 92.3%, specificity 100%). 18F-FDG-PET/CT led to changes in the treatment plan in 33/69 patients (47.8%).

Conclusion: 18F-FDG-PET/CT plays an important role in detecting recurrent/metastatic lesions in post-surgical DTC patients with high serum Tg level and negative 131I whole body scan.

IAEA-CN-232/239

Quality Control of PET/CT Radiopharmaceuticals

N. Garg¹, J. Shukla², B.R. Mittal², B. Singh²

¹ Fortis Hospital Ludhiana

² PGIMER CHANDIGARH

Corresponding Author: nitashagarg89@yahoo.com

Background: PET is a medical imaging modality in which a patient is injected with a radiopharmaceutical. Quality control of the radiopharmaceutical is an important aspect in order to ensure its purity, potency, product identity, biologic safety and efficacy. The aim of our study was to assess radionuclide purity, radiochemical purity, apyrogenicity and sterility of PET radiopharmaceuticals 18F-FDG, 13N-NH₃ and 68Ga-DOTATATE.

Methodology: Samples of 18F-FDG, 68Ga-DOTATATE (n=25 each) and 13N-NH₃ (n=10) were randomly selected. Radionuclide purity was assessed through half-life (t_{1/2}) determination by recording activity after every 10 min for F-18, Ga-68 and after every 10 sec for N-13. N-13 impurity in 18F-FDG was assessed by recording multichannel analyser (MCA) spectra of 18F-FDG and t_{1/2} of N-13. Instant thin layer chromatography (ITLC) of 18F-FDG and 68Ga-DOTATATE was done by using acetonitrile:water (85:15) and sodium citrate as mobile phase, to assess radiochemical purity. The chemical purity was checked by gas chromatography using ethanol (4000 ppm) and acetonitrile (400 ppm) as standards. Kryptofix impurity was determined by colour chromatography using methanol: ammonium hydroxide (90:10) as mobile phase and I₂ vapours as colour developer. All the samples were incubated in RCM broth at 37°C for 3-4 days to determine the sterility. Bacterial endotoxin test was performed by Limulus amoebocyte lysate (LAL) reagents with positive and negative.

Results: The half-lives of radionuclides in 18F-FDG, 68Ga-DOTATATE and 13N-NH₃ samples were 110 minutes, 68 minutes and 10 minutes, respectively. The prepared 18F-FDG was free from N-13 impurity as N-13 peak was not observed in 18F-FDG spectrum. Retention factor (Rf) of 18F-FDG and 68Ga-DOTATATE samples was in the range of 0.39 to 0.48 and 0.11 to 0.243, respectively. The radiochemical purity of 18F-FDG and 68Ga-DOTATATE was 100% as single peak was observed in TLC scan. The concentration of ethanol and acetonitrile in 18F-FDG was 7-1385 ppm and 1.23 - 41.02 ppm, respectively. The concentration of ethanol in 68Ga-DOTATATE was between 1.9 - 294ppm. The 18F-FDG samples did not show purple/brown colour, an indicator of kryptofix. The samples did not show any gel formation indicating apyrogenicity of the samples. The samples were sterile as no growth was observed even after seven days of incubation in RCM at 37 °C.

Test	Method	¹⁸ F-FDG	⁶⁸ Ga-DOTATATE	¹³ N-NH ₃
pH	pH Check	4.5-8.8	4.5-8.5	4.5-8.5
Radionuclidic Purity	Half –Life	105-110 minutes	68 minutes	10 minutes
	Gamma-Spectrum	Photon Energy (PE) of 0.511-1.022 keV	PE0.511-1.022 keV	PE0.511-1.022 keV
Radiochemical Purity	TLC	Rf 0.4-0.45	Rf 16-2.2	NOT APPLICABLE (NA)
Chemical Purity	Kryptofix test	Sample spot lighter than reference spot	NA	NA
Residual solvent	Ethanol	>4000ppm	>4000 ppm	NA
	Acetonitrile	>400 ppl	NA	NA
Sterility	Standard sterility test	No bacterial growth (NBG)	NBG	NBG
Bacterial Endotoxin Test	GelClot Method	No gel formation (NGF)	NGF	NGF

Conclusion: ¹⁸F-FDG, ⁶⁸Ga-DOTATATE and ¹³N-NH₃ conformed to various quality attributes of purity, efficacy and safety in the randomized samples and are safe for patient use.

IAEA-CN-232/240

Synthesis of Radioiodine Labelled Functional Magnetic Nanoparticles: L-PHA Lectin Conjugated MNPs and in Vitro Bioaffinities on Cancer Cells

A.Y. Kilcar, C.A. Ichedef, P. Unak, O. Kozgus Guldu, E.I. Medine, F.Z.B. Muftuler

Ege University

Corresponding Author: perihan.unak@gmail.com

Background: Magnetic radioactive nanoparticles have the advantage of being able to deliver high concentrations of radioactivity to the target area, without damaging normal surrounding tissue. Phytohemagglutinin-L (PHA-L) which is obtained from red kidney bean is one of the major types of lectins due to its cell recognition property. PHA-L has strong effects on cell agglutination and mutagenic activities. It can bind to the cell membranes by interacting with monosaccharides and oligosaccharides. For that purpose, it was aimed to investigate magnetic nanoparticles (MNPs) conjugation with PHA-L and radiolabel them to obtain an effective agent for the diagnosis of breast cancer in this report.

Methodology: Magnetic nanoparticles, Fe₃O₄, were prepared by the co-precipitation method from ferrous and ferric ion solutions with a molecular ratio of 1:2 and they were coated with tetraethyl orthosilicate (TEOS). The obtained silica-coated magnetic particles were coated with aminosilane. Finally L-PHA was conjugated to the NPs through the cross-linker glutaraldehyde. Magnetic nanoparticles were characterized through Zeta potential, atomic force microscopy (AFM), scanning electron microscopy (SEM), and Fourier Transform Infrared Spectroscopy (FTIR). Finally, L-PHA conjugated magnetic nanoparticles (MNP-L-PHA) were radiolabeled with ¹³¹I by iodogen method. Incorporation studies were carried out in breast cancer cell line (MCF-7) and Human alveolar adenocarcinoma cell line (A-549). Cytotoxicity studies were carried out in MCF-7, A-549 and Vero cell lines for 24, 48 and 72 hours through the MTT method. Wound healing studies were carried out in MCF-7 cells. For fluorescence imaging studies, MCF-7, A-549 and Vero cells were used.

Results: The size of the magnetic nanoparticles was 40-60 nm. L-PHA lectin was conjugated to nanoparticles in 10 minutes with a yield over 99% and 30 minutes with 99.9%, binding was determined as optimum immobilization time. Radiolabeling yields of ¹³¹I labeled L-PHA conjugated silane magnetite nanoparticles and ¹³¹I labeled L-PHA were 97.96 ± 1.98 % and 94.43 ± 4.28 %, respectively. Radiolabeled compounds (¹³¹I-MNP and ¹³¹I-MNP-L-PHA) could be separated with electrophoresis method and they were positively charged. Experimental lipophilicity of the ¹³¹I-L-PHA was determined to be -0.35 ± 0.11 . This value shows that the radiolabeled biomolecule is hydrophilic. Serum stability studies showed that the stability until 24 hours was over 90 %.

In vitro bioaffinities of ¹²⁵I-MNP-L-PHA and ¹³¹I-L-PHA were performed in A549 and MCF-7 cells. Cell uptake studies showed that the conjugation with magnetic nanoparticles increased the uptake of radiolabeled compound by the cells. Also, applying external magnetic field increased the cell uptake. There was no toxicity in both MCF-7 and Vero cells up to 200µg/ml concentration limit within 48 hours.

Conclusion: Radioiodinated lectin conjugated radiolabeled magnetic nanoparticles could have a potential as hybrid imaging agent in SPECT-MR imaging systems. Also, using this molecule under external magnetic field can increase its affinity for therapeutic purposes.

IAEA-CN-232/241

Histologic Correlation between 18F-FDG PET/CT and Lumboartic Lymphadenectomy in Cervix Carcinoma

R. Pruzzo, H. Amaral, E. Hernández, H. Lavados, B. Morales, D. Acuña

Fundación Lopez Perez

Corresponding Author: bmoralesk@gmail.com

Background: The nodal status in uterine cervix carcinoma (UCC) can significantly influence disease outcome. In patients with small tumors and negative lymph nodes the overall survival at 5 years is 90%. This figure falls to near 50% in patients with positive pelvic lymph nodes and to 20-30% in patients with positive lumboartic lymph nodes.

In locally advanced cervical cancer 18F-FDG PET/CT is highly recommended for staging. Although MRI is the preferred method to evaluate local extension, PET/CT is superior for the evaluation of nodal involvement. In advanced stage, specificity to detect paraaortic lymph node involvement increases to 75% and specificity to 95%.

Since unnecessary extended field radiotherapy to paraaortic lymph nodes has a high morbidity, the precise evaluation of nodal status could have a tremendous impact in the radiotherapy planning. So, an accurate evaluation of retroperitoneal nodal involvement might be of great impact in treatment choice.

The objective of this study was to evaluate the lumboartic nodal status with 18F-FDG PET/CT and to determine the definitive therapy.

Methodology: PET/CT with 18F-FDG was performed in 21 patients with UCC (FIGO \geq IB1), average age 47.8 years old (range 30-78). 17 cases were referred for staging and 4 for suspected recurrence. The histology of the primary tumor was squamous carcinoma in 16 and adenocarcinoma in 5 patients.

Sixty minutes after the i.v. injection of 277 MBq of 18F-FDG, PET/CT images were acquired in a Biograph mCT20 (Siemens). A nuclear physician and a radiologist reviewed all images simultaneously.

Laparoscopic lumboartic lymphadenectomy was performed in all patients, with a total of 284 lymph nodes resected. The 18F-FDG PET/CT results were correlated with the nodal histology in each case.

Results: All primary tumors showed intense metabolism; average SUVmax was 19.4 (range 11-33). Hypermetabolic paraaortic lymph nodes were present in 4/21 patients (19%), the size of lymph nodes ranged between 9-15 mm in the short axis and the SUVmax from 3.9 to 11.2.

Metastasis was demonstrated in 3 patients with 6 lymph nodes involved. One patient was a false positive due to inflammation in the context of recto-vaginal fistula.

In 17/18 patients PET/CT ruled out lumboartic involvement. 278 lymph nodes had negative histology.

Sensitivity of 18F-FDG PET/CT per patient to detect paraaortic lymph node metastases was 100%, specificity 94%, PPV = 75% and NPV 100%.

Conclusion: There is an excellent correlation between 18F-FDG PET/CT results and paraaortic lymph node histology. PET/CT has a high negative predictive value in lumboartic region and could avoid extended field radiotherapy.

IAEA-CN-232/242

PET/CT and MRI in the Relapse of Cervical Cancer Followed Up in the Same Centre

J. Arma, A. Mollerach, I. Hume, Isabel, C. Collaud, C. Cianciarelli,
L. Paganini, V. Jager

Hospital Italiano de Buenos Aires, Argentina

Corresponding Author: irenearma@yahoo.com.ar

Background: Estimated recurrence rates in cervical cancer have been reported to range as high as 28-35%. The objective of this study was to assess the usefulness of PET/CT and MRI in the follow-up of patients diagnosed with cervical cancer.

Methodology: All patients diagnosed with cervical cancer treated between January 2012 and December 2013 with PET/CT and MRI studies performed within 2 months were assessed.

13 patients were enrolled: 8 squamous-cell carcinomas, 4 adenocarcinomas and 1 leiomyosarcoma.

Results: PET/CT findings: 8 positive results, 5 negative results for relapse/recurrence.
MRI findings: 10 positive results, 3 negative results for relapse/recurrence.

PELVIC LESIONS

	PET (+)	PET (-)
MRI (+)	7	3
MRI (-)	1	2

ADENOPATHIES

	PET (+)	PET (-)
MRI (+)	3	0
MRI (-)	2	8

OVERALL RESULTS

	PET (+)	PET (-)
MRI (+)	7	3
MRI (-)	1	2

Both PET/CT and MRI detected a peritoneal implant in different patients.

The mean SUV was 10.2 (range 3.3-19.5) for pelvic injuries, and 11.1 (range 3.2-22) for retroperitoneal adenopathy.

Conclusion: Although MRI detected recurrence in a greater number of patients due to its capacity to detect pelvic lesions, PET/CT proved more useful in detecting both loco-regional and distant lymph nodes.

IAEA-CN-232/243

Determining the Most Frequent SUVmax Value Related to Non-Small Cell Lung Carcinoma in Our Center of Nuclear Medicine

M. Agolti, M.S. Cosarinsky

CNEA Argentina

Corresponding Author: marielsmednuc@hotmail.com

Background: Lung carcinoma is one of the most common types of cancer in the world, and 18F-FDG PET is one of the most important tools for its diagnosis. It is very important to have quantitative parameters for each centre to obtain the best value from the technique.

Methodology: Our objective was to determine the most frequent value of SUV maximum (SUVmax) associated with non-small cell lung carcinoma both in treated and non-treated patients. We also analysed the SUVmax related to the nodule size. We analysed all 54 patients presenting with lung carcinoma in our centre in the period 31 January 2013 – 31 January 2015. We divided the population into two groups - patients treated with chemotherapy, radiotherapy, both or surgery (n=18), and patients without treatments (n=36).

Results: We made a histogram and determined the most frequent SUVmax value for each group. The value was 4 to 6 for non-treated patients and 2 to 4 for treated patients. In both groups we also analysed the size of nodules dividing the patients into two groups, 3 cm being the cut-off value. In non-treated patients, the most frequent SUVmax value was 4 to 6 in patients who had a nodule size of at least 3 cm, and 2 and 4 in patients who had a nodule size of less than 3 cm. In patients who were already treated, the SUVmax value was 2 to 4 regardless of the size of the nodule. It is important to note that only 1 patient had a SUVmax value of less than 1, but he had a complete and successful excisional biopsy. None of the patients that had not received treatment had a SUVmax value of less than 2, and only 2 patients in this group had a SUVmax of less than 3.

Conclusion: In our centre, in patients without treatment a SUVmax value of 2 to 4 can be more frequently related to lung carcinoma if the size of the nodule is less than 3 cm, and in only 7.2 % of these patients a SUVmax of less than 3 was observed. It can therefore be concluded that with a SUVmax value of 3, whilst not considering false-positives, the sensibility of diagnosing lung cancer is 93%. In patients with nodule size of at least 3 cm, a SUVmax value of 4 to 6 was most frequently found and is most probably associated with lung carcinoma. In patients who had undergone treatment, the nodule size did not correlate with the SUVmax value.

IAEA-CN-232/244

Contribution of Nuclear Medicine Services to the Medical Care in Yemen, the Challenges and Impact on Patient Care Management

F. Mohammed

Nuclear Medicine Center, Al-Thawra General Hospital, Sana'a, Yemen

Corresponding Author: dr.fairoz@gmail.com

Background: The Nuclear Medicine Centre at Al-Thawra General Hospital in Sana'a, Yemen, is the only public institution that provides nuclear medicine (NM) services (diagnostic and therapeutic), to about 25 million people. The centre was the first to be established in Yemen with the assistance of the IAEA Technical Cooperation Programme leading to increased number of patients receiving NM services over time; it became operational in 2008. It is equipped with two gamma cameras (SPECT), hot lab and 131-I therapy rooms. Isotopes in use include Tc-99m, Ga-67, TI-201 and I-131.

Many challenges continue to limit the service to the needy patients especially those living outside the capital city. Such challenges are:

- Lack of awareness of medical professionals on the role of nuclear medicine in patient care
- Patient confidence and radiation phobia
- Centralized service at the capital and incurred cost
- Lack of interest by the private sector in nuclear medicine
- Limited numbers of radiopharmaceuticals vendors willing to export to Yemen
- Limited number of international couriers for radiopharmaceuticals - one courier
- Limited number of qualified nuclear medicine physicians
- Lack of quick maintenance services for gamma cameras

Methodology: Efforts have been made to the extent possible and with the available limited resources. However, most efforts were limited in scope due to the difficulty in receiving international experts in order to have a close look at the work to conduct advice at the site. Nevertheless, collective efforts by the staff of the centre, which used the IAEA regional training courses as well as networking with their peers in the region, contributed to the improvement of the situation, widening its scope and the quality of the service provided.

The focus of the work:

- A system for data collection was established and has been continuously improved since 2008
- Patient archiving system making it easy to retrieve patient information
- Gamma camera DICOM files since the establishment of the centre

- Establishment of a separate out-patient clinic filing system

A lot of work still needs to be done in order to address the challenges cited above, requiring strong commitment of all relevant stakeholders.

Results: Statistics on the number of examinations since July 2008:

Patent Case Type	Beginning of the Service - Cases per month	Current - Cases per month
Bone	30-40	60-75
Renal	43-55	60-83
Cardiac	10	15-34
Thyroid	15-25	25-35
Parathyroid	1-2	1-2

Thyroid cancer was managed only by surgery earlier, but now radioactive iodine therapy is also practiced. Renal evaluation before nephrectomy or donation contributed to informed and proper decision. Performing bone scans impacted on staging leading to different management. A private hospital was encouraged to run its NM unit. In South Yemen, another NM facility is on its way to become functional.

Conclusion: NM services were made available to Yemeni patients for the first time in 2008. Access to this service has contributed to the improvement of health care especially in cancer care and control. However, this service is still limited in its scope and needs to be further strengthened to introduce more radioisotopes both for diagnosis and therapy.

IAEA-CN-232/245

**Use of 18F-FDG PET/CT for Peritoneal Carcinomatosis
before Hyperthermic Intraperitoneal Chemotherapy:
A Clinic Case**

C.A. De Los Reyes Victoria ¹, Y. Herrera ², F. Bastidas ²

Instituto Nacional de Cancerologia, Colombia

Corresponding Author: ameliadelosreyes@gmail.com

Background: Complete cytoreductive surgery combined with hyperthermic intraperitoneal chemotherapy has been shown to improve survival rates of peritoneal carcinomatosis (PC). However, this treatment is beneficial for patients only if the complete cytoreductive surgery is macroscopically completed before implementing hyperthermic intraperitoneal chemotherapy. Even so, a strict selection of patients is of fundamental importance because of the invasive nature of the intervention. Several reports have confirmed that 18F-FDG PET/CT outperforms contrast-enhanced CT (CECT) in the diagnosis of nodal, peritoneal and liver sub-capsular disease in patients with ovarian cancer with a reported accuracy of 72-95% (vs 38-88% for CECT). It can induce treatment changes in up to 60% of cases. We present a clinical case to illustrate depiction of peritoneal implants by 18F-FDG PET/CT compared to CECT and post-surgical pathology findings.

Methodology: A patient diagnosed with stage IIIC papillary serous cystadenocarcinoma of the ovary underwent 18F-FDG PET/CT and CECT scanning before complete cytoreductive surgery and hyperthermic intraperitoneal chemotherapy. The results were compared to histological and intraoperative findings. The extent of PC was assessed precisely using the results of 18F-FDG PET/CT, surgery and histology.

Results: 18F-FDG PET/CT showed hypermetabolic implants in the round ligament of the liver and the hepatorenal space. Also, a 44 x 39 x 40 mm mass with hypermetabolic borders was described at the splenic hilum. Histopathologic analysis of the surgical specimen reported tumor involvement in the round ligament, peripancreatic soft tissues, splenic capsule, right diaphragm, peritoneum, perirectal soft tissues, and colonic serosa. Proximal and distal tumor-free resection margins were obtained.

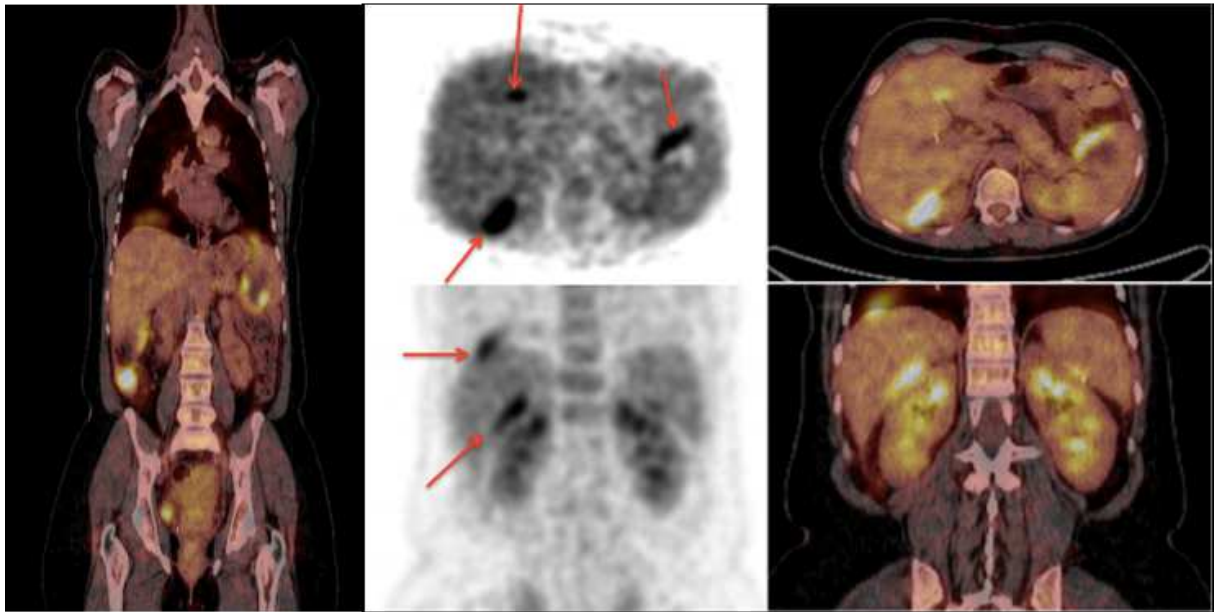


Figure 1: ^{18}F -FDG PET/CT showed hypermetabolic implants in the round ligament of the liver and the hepatorenal space

Conclusion: Even if the extent of PC was underestimated by PET, there was a good correlation when compared with histology and intraoperative results. CECT only showed the splenic hilar mass. ^{18}F -FDG PET/CT is useful to avoid unnecessary surgery.

IAEA-CN-232/246

Role of 18F-FDG PET/CT Scan for Evaluating Newly Diagnosed Lung Cancer - Experience in Bangladesh

S. Biswas¹, Z. Hossain²

¹ Bangladesh Atomic Energy Commission

² Medinova Medical Services Ltd. Dhaka

Corresponding Author: drsbiswas09@yahoo.com

Background: Proper diagnosis and staging is very important for managing lung cancer. Initial staging is usually performed with computed tomography (CT) but functional imaging using integrated positron emission tomography and CT (PET-CT) is being increasingly used to provide more accurate staging, guide biopsies, assess therapeutic response and identify recurrent disease. This study was designed to unravel the impact of PET-CT scan for evaluating newly diagnosed primary lung cancer.

Methodology: Seventeen patients (age 63±8 years, male 13, female 4) were enrolled into the study during the period of September 2012 through September 2014. All of them underwent CT guided fine needle aspiration cytology (FNAC) for diagnosing lung cancer. Whole body 18F-FDG PET-CT scan was performed from vertex to mid-thigh in a whole body PET-CT scanner (128 Slice GE Discovery VCT) one hour after intravenous injection of the tracer. High resolution contrast CT of the same area was obtained. Oral contrast was administered for bowel opacification 2 hours before the scan. Images were reconstructed using VUE point HD algorithm and slices were reformatted into transaxial, coronal and sagittal views. Semi-quantitative estimation of 18F-FDG uptake was performed by calculating SUVmax value, corrected for dose administered and body weight (g/ml).

Results: Aspiration cytology revealed 6 cases of adenocarcinoma, 5 squamous cell carcinoma, 3 non-small cell lung carcinoma (NSCLC) and 3 cases showed features of small cell carcinoma. Mean diameter of the primary lung lesion was 6.5 ± 3 cm with a SUVmax of 15.79 ± 6.59. Thirteen cases showed locoregional lymph node metastasis with a SUVmax of 10 ± 4.87. Four cases showed distant lymph node metastasis (cervical and axillary) with a SUVmax of 10.12 ± 4.69. Distant bone metastasis was observed in 3 cases (ribs, vertebrae and ischium) and malignant pleural effusion was detected in 2 cases only. Pericardial disease involvement and metastasis in the pharyngeal wall were present in one patient. More interestingly, one case showed contralateral 18F-FDG avid metastatic nodule without any morphological changes in contrast enhanced CT.

Conclusion: 18F-FDG PET-CT scan is now a well-established method for staging lung cancer. This sophisticated imaging modality provided additional information compared to conventional X-ray or CT imaging. PET-CT scan played a pivotal role in treatment planning and also provided prognostic information in newly diagnosed cases of lung cancer. Cost-effective implementation of more PET-CT scanners is needed to combat the high cancer burden in the country.

IAEA-CN-232/247

**177Lu-DOTATATE Peptide Receptor Radionuclide
Therapy in Patients with Inoperable and Metastatic
Neuroendocrine Tumours: Experience with First 100 Cases
from India**

C. Bal¹, G. Arora², S. Ballal³, M.P. Yadav³

AIIMS, New Delhi, India

Corresponding Author: csbal@hotmail.com

Background: We evaluated the role of 177Lu-DOTATATE peptide receptor radionuclide therapy (PRRT) in patients with inoperable and metastatic neuroendocrine tumors (NET). In this study we report the efficacy of this treatment performed in 100 patients.

Methodology: Hundred 68Ga-DOTANOC scan positive patients with known NET were included in the study since 2008 to 2012. Among 100 patients, 20 who had < 4 cycles of PRRT were excluded. Interestingly, seven 68Ga –DOTANOC positive patients had no significant uptake on 177Lu-DOTATATE post-therapy scan, thus no further therapy cycles were contemplated. Finally, 73 patients (47 males and 26 females), who completed at least 4-6 cycles of 177Lu-DOTATATE therapy (Mean cumulative activity = 20,720 ± 1,147 MBq), were available for analysis and were included in the study. A kidney protection protocol was performed by co-infusion of Gelofusine, arginine and lysine (800 – 1000 ml). 177Lu-DOTATATE post-therapy scan was performed 24 hr post-administration of the tracer. Follow-up 68Ga-DOTANOC scans were performed for response evaluation at the end of the study. Primary outcome endpoints - Overall survival (OS) and secondary outcome endpoints - event-free survival (EFS) were calculated using the Kaplan-Meier analysis.

Results: Total mean follow-up duration was 60 months ± 12 (SEM). Event was defined as progression, recurrence or death. Among the 73 patients (mean age - 47.75 years ± 1.8), no patient showed complete response (CR), 5 (6.8%) showed partial response (PR) and 31 (42.5%) had stable disease (SD). The total objective response in this series was 36/73 (49.3%). 37/73 had progressive disease of which 25 died and 12 still survive albeit with progressive disease. None of the patients showed grade 3 or 4 haematological or renal toxicity. Mean OS was 52.83 months (95% Confidence interval (CI): 45.47 to 60.20). Median OS was not reached. Mean and median EFS was 37.32 months (95% CI: 30.59 to 44.05) and 35 months (95% CI: 21 to 45), respectively.

Table 1: Comparison of overall survival and progression-free survival in ¹⁷⁷Lu-DOTATATE treated NET patients

Author	Year	Total No of patients	Overall survival (OS) (months)	Progression Free Survival(PFS) (months)
<u>Paganelli G et al</u>	2014	43		Median - 36
<u>Dantala M et al</u>	2014	40		Mean - 45.6
<u>Bodei L et al</u>	2011	51	Mean - 36	
<u>Kwekkeboom DJ et al</u>	2008	310	Median - 46	Median - 32
Present Study	2015	73	Mean - 52.83 Median–Not Reached	Mean - 37.2 Median - 35

Conclusion: With a mean follow-up of 60 months, the median EFS was 35 months. However, the median OS has not yet been reached. The results are similar to previously published literature.

IAEA-CN-232/248

**Retrospective Review of Clinical Experience with Ga-68
DOTANOC at the Western Cape Academic PET/CT Centre**

A. Ellmann, A. Doruyter, S. Rubow

Western Cape Academic PET/CT Centre, Stellenbosch University and Tygerberg
Hospital

Corresponding Author: ael@sun.ac.za

Background: Ga-68 DOTANOC PET/CT is a sensitive molecular imaging modality for imaging somatostatin receptors, with highest affinity for SS2R. Ga-68 DOTANOC PET/CT is generally regarded as superior to alternative (single photon emission) scintigraphic techniques for the imaging of neuroendocrine tumours (NETS). Although the normal biodistribution of Ga-68 DOTANOC is similar to other somatostatin receptor imaging agents, differences are described. In September 2013 the Western Cape Academic PET/CT Centre began Ga-68 labeling of DOTA-compounds. We report our clinical experience with these compounds thus far, including indications for investigation; discussion of normal variants and pathology; as well as pitfalls in interpretation.

Methodology: Referral patterns, imaging results, and laboratory and clinical data were collated for patients referred for Ga-68 DOTANOC PET/CT since September 2013. Normal biodistribution of Ga-68-DOTANOC was compared to experience with single photon emission agents. Clinical follow-up allowed us to identify any interpretative pitfalls in initial reporting.

Results: Scans of 53 patients were reviewed. The majority of patients were referred for staging procedures. Several differences between the normal biodistribution of Ga-68 DOTANOC and In-111 Octreoscan and Tc-99m Tektrotyd were identified. Correlative clinical information was available in 44 of the patients, which allowed us to identify 7 false negative and 2 false positive studies. Two of the false negative studies were due to tumour dedifferentiation, and in one case the recurrent lesions were smaller than the resolution limit of the camera. In one patient an insulinoma was not detected. The reasons for the false negativity were not clear in the other 3 cases. The two false positive studies were identified after clinical follow-up and subsequent literature review, which identified an important pitfall in interpretation, namely physiological DOTANOC uptake in the uncinate process of the pancreas.

Conclusion: Ga-68 DOTANOC PET/CT offers several advantages over traditional somatostatin receptor imaging methods, including improved sensitivity and shorter total scan duration. While both methods image predominantly SS2R, several notable differences exist in biodistribution. It is important that nuclear physicians be mindful of these differences as well as potential pitfalls in the interpretation of these studies. Interpreter knowledge of normal variants is important for accurate reporting. Ga-68 DOTANOC PET offers significant benefit in terms of directing clinical intervention and subsequent follow-up.

IAEA-CN-232/249

**Effects of Reconstruction Parameters on SUV with NEMA
2007 IQ Phantom**

**A. Skopljak-Beganović¹, A. Beganović¹, M. Gazdić-Šantić¹, N. Salkica²,
A. Drljević¹**

¹ University Clinical Center Sarajevo, Department of Medical Physics and Radiation Safety

² University Clinical Center Sarajevo, Clinic of Nuclear Medicine

Corresponding Author: amraskopljak@gmail.com

Background: The aim of this study was to examine the effects of reconstruction parameters on image quality and SUV values.

Methodology: For this study we used the NEMA 2007 IQ Phantom with 6 fillable spheres with diameters of 10 mm, 13 mm, 17 mm, 22 mm, 28 mm and 37 mm. Activity concentration of the solution used for filling of spheres was 20 MBq/l. As opposite to NEMA specifications for IQ phantom, all spheres were filled with F-18 FDG. Initial background activity of phantom was set to be 20 MBq. Images were obtained using the Discovery 600 PET/CT. PET scans were acquired with 2 bed positions, 10 minutes each, and CT was included for attenuation correction purposes. Reconstructions were performed with attenuation, scatter, normalization, decay and dead time corrections, following the EANM recommendations. Images were retro-reconstructed using different numbers of iterations (from 1 to 5 iterations), subsets (from 2 to 32 subsets) and cut-off filters (from 1 to 5 cut-offs). The ROIs of spheres were drawn to the acquired and reconstructed images. Maximum, average and standard deviation of activity concentration of all 6 spheres were measured.

Results: Values of the maxima varied from 9.6 kBq/ml to 15.5 kBq/ml for the sphere 1 (the smallest sphere); from 3.8 kBq/ml to 31.7 kBq/ml for sphere 2; from 4.7 kBq/ml to 33.9 kBq/ml for sphere 3; from 6.3 kBq/ml to 41.5 kBq/ml for sphere 4; from 8.2 kBq/ml to 40.7 kBq/ml for sphere 5; and from 9.9 kBq/ml to 39.8 kBq/ml for the sphere 6 (the largest sphere). The results of this study show how SUV determination is a semiquantitative method that highly depends on reconstruction parameters.

Conclusion: After the analysis we concluded that these parameters affect the accuracy of quantification in reconstructed PET images. The cut-off filter has the greatest impact on assessed concentration values; more than the number of iterations and subsets have.

IAEA-CN-232/250

PET-MR in Radiation Oncology – How to Correct for Attenuation Caused by Flat Table Top?

S. Witoszynskyj¹, P. Andrzejewski², B. Knäusl², M. Hacker³, D. Georg²

¹ Div. of Nuclear Medicine, Dept. of Biomedical Imaging and Image-guided Therapy, Vienna General Hospital, Austria

² Dept. of Radiation Oncology, Comprehensive Cancer Center, Medical University Vienna, Austria and Christian Doppler Laboratory for Medical Radiation Research for Radiation Oncology, Vienna, Austria

³ Div. of Nuclear Medicine, Dept. of Biomedical Imaging and Image-guided Therapy, Medical University Vienna, Austria

Corresponding Author: piotr.andrzejewski@meduniwien.ac.at

Background: Positron emission tomography (PET) and multi-parametric magnetic resonance imaging (MRI) are increasingly explored in radiation oncology research. Clinical implementation of these complementary imaging modalities was hampered by the need of PET-MR image registration and therefore impaired accuracy of geometric information. Introduction of hybrid PET/MRI scanners solves this issue but introduces new challenges. To assure similar patient positioning during imaging and therapy, specially manufactured flat table tops (FTT) are used. However, additional attenuation and scatter caused by the FTTs in PET is not accounted for during image reconstruction. Thus, PET image quality (IQ) is significantly degraded. The goal of this phantom study was to evaluate the impact of a FTT on PET IQ and to investigate possible correction methods.

Methodology: PET images of a ¹²⁵I canister filled with ~40 MBq ¹⁸F-FDG in an aqueous solution (0.9% NaCl and ~0.2mmol/l Gd-DO3A-butrol) were acquired on a Siemens Biograph TrueV PET/CT and a Siemens Biograph mMR PET/MR. Measurements with the canister positioned on the MR-compatible FTT and without FTT were performed. A transmission scan (PET-TS) of the FTT was performed on a GE Advance PET. MR markers visible also on PET were used for co-registration between modalities. An attenuation map (μ Map) was derived from PET-TS and used to modify the MR- μ Map for an additional reconstruction. All images were evaluated visually and by estimating the uniformity using a sliding window approach with a 5x5 voxel ROI (volume of 0.8ml) on a slice-by-slice basis. The non-uniformity was averaged over 20 central slices.

Results: The best IQ was found in PET/CT without FTT (non-uniformity: 17%, figure 1a). Compared to these images, PET/MR images were degraded (non-uniformity: 25%, figure 1c). PET/CT with FTT exhibited attenuation artefacts (non-uniformity: 22%, figure 1b), while scatter and attenuation artefacts were observed in PET/MR (non-uniformity: 46%, figure 1d). However, IQ can be improved significantly by the FTT's PET-TS μ map (non-uniformity: 26%, figure 1e).




Figure 1. PET/CT images without (a) and with FTT (b). PET/MR images without FTT (c) and with FTT, without (d) and with (e) a PET-TS derived μ Map.

Conclusion: Although the non-uniformity measure provides an indication for IQ, it is of limited use for evaluating systematic artefacts caused by incorrect corrections. The incorrect attenuation visible in PET/CT images is caused by the transformation from CT attenuation to PET attenuation that is not valid for materials used in the FTT. A PET-TS can be used to derive a μ Map and to reduce artefacts in PET/MR. Further improvements are currently explored by improving the quality of the PET-TS μ Map and by its better integration into the reconstruction.

IAEA-CN-232/251

Validation Approach for a New PET Radiopharmaceuticals GMP Facility

R. Smith, F. Aigbirhio, I. Boros

Wolfson Brain Imaging Centre, University of Cambridge

Corresponding Author: ib297@wbic.cam.ac.uk

Background: The Wolfson Brain Imaging Centre (WBIC) is part of the Department of Clinical Neurosciences, University of Cambridge and is licensed by the UK Medicines and Healthcare Products Regulatory Authority (MHRA) for manufacturing short-lived radiopharmaceuticals for clinical PET imaging studies.

A grant award has permitted the WBIC Radiochemistry Team to prepare plans for a two-floor extension of the WBIC Radiopharmaceutical Unit.

Here we present the commissioning and validation methodology of the new facility.

Methodology: The new Radiopharmaceutical GMP Facility consists of a single Grade C Aseptic Room for PET radiopharmaceutical manufacturing, accessed via a First Stage, Grade D, Lobby, and a Second Stage, Grade C, Change Room. During the whole construction phase it has been necessary to keep the existing licensed manufacturing facility fully operational. The overall validation project was divided into five sub-projects:

- Risk Assessment of the GMP Operation in the GMP Facility;
- Qualification of the New GMP Facility;
- Qualification of the HVAC system;
- Qualification of the New Hot-Cells; and
- Qualification of the New Operational Equipment.

For each sub-project a systematic validation approach has been applied:

- System definitions;
- User Requirement Specifications;
- Design Reviews (DQ);
- Validation/Qualification Plans (IQ-OQ-PQ, including Factory Acceptance Tests where applicable);
- Protocols and reports.

Results: This systematic validation methodology offered an easier pathway to the commissioning process as all stakeholders were kept involved. Furthermore the adoption of this streamlined validation approach significantly reduced the overall project costs and scheduled duration, and provided real value-added benefits in the start-up of the facility.

On completion of the qualification report the facility will be subject to a Medicines and Healthcare Products Regulatory Agency (MHRA) inspection in order to prove conformance with the cleanroom regulations and GMP requirements.

Conclusion: The effective implementation of such a design proved that the presented approach could be used as a template for other PET units.

IAEA-CN-232/252

Experience with ¹⁷⁷Lu-DOTATE in Fundacion Valle de Lili of Cali, Colombia

L. Pabon Castilla, A. Alvarez Paez, E. Manzi

Fundacion Valle de Lili, Cali

Corresponding Author: lpabon@yahoo.com.co

Background: The aim of the study is to describe our experience with using peptide receptor radionuclide therapy (PRRT) in patients with functioning neuroendocrine tumours (FNTs) and to determine survival rates and symptoms-free probability after the therapy.

Methodology: Twelve patients with FNTs referred to PRRT (administration of 150 mCi of ¹⁷⁷Lu-DOTATE with an interval of 6-9 weeks, maximum 4 cycles of therapy) based on positive SRS (somatostatin receptor scintigraphy) between 01 August 2009 and 30 September 2013 were included. Follow up was performed three years later. There were 5 men and 7 women, with Karnofsky index > 50%. Kaplan-Meier plot was used for survival analysis.

Results: Four cycles were done in 9 patients, two cycles in one patient and one cycle in two patients. Mean age was 51 years (range: 37-68). Median time between diagnosis of the disease and first cycle of therapy was 20 months (RIQ: 4 – 64). Three years patient survival was 48%, progression-free probability after PRRT was 52% and symptoms-free probability was 83%. The median time-free of symptoms was 28 months (RIQ: 10 – 51). At the present time, 6/12 patients are alive; stabilization of the disease was observed in 3/6, complete remission in 1/6 and progression of the disease in 2/6 patients, 5/6 patients are being treated with Sandostatin. Median observation time was 14 months (RIQ: 4 – 29). Six patients died; 4 of them due to progression of the disease, 1 due to sepsis and 1 due to bleeding. After PRRT we observed the following adverse effects: abdominal pain (n=4), renal dysfunction (n=2) and hair loss (n=3).

Conclusion: Therapy with ¹⁷⁷Lu-DOTATE is a treatment option in patients with FNTs, leading to stabilization or reduction of the symptoms and slowing down disease progression. Studies with more patients are necessary to identify risk factors for disease progression and death.

IAEA-CN-232/254

**68Ga-PSMA PET/CT in Patients with Prostate Cancer.
Initial Experience at the Tel Aviv Medical Center**

E. Even-Sapi¹, V. Kulikov²

¹ MD, PhD Dept of Nuclear Medicine Tel Aviv Medical Center, Tel Aviv Israel

² MD, Dept of Nuclear Medicine, Dept of Nuclear Medicine Tel Aviv Medical Center

Corresponding Author: evensap@tlvmc.gov.il

Background: 18F-FDG PET/CT has been shown to be of limited value in patients with prostate cancer. Recently, a novel PET tracer, 68Ga-PSMA (Prostate- Specific Membrane Antigen), which accumulates in malignant prostatic tissue, has been introduced in clinical practice. The current study summarizes our initial experience with 68Ga-PSMA PET/CT.

Methodology: 68Ga-PSMA PET/CT study has been performed in 173 patients with prostate cancer, 57-85 years of age (mean 70+/- 7.6 years). Indications were staging of newly diagnosed high-risk cancer (n=43), rising PSA levels (biochemical failure n=106), monitoring response to therapy in patients with metastatic disease (n=17) and characterization of unclear lesions seen on CT (n=7). Among patients with rising PSA levels, 74 had previous radical prostatectomy. Sixty seven of the 106 patients with biochemical failure received hormonal therapy with (n=34) or without (n=33) radiotherapy, 7 had radiotherapy alone and 34 were not treated after surgery.

Results: 37 of 43 patients with newly diagnosed cancer had increased 68Ga-PSMA uptake at the primary tumour site, 15 patient had also nodal uptake and 7 had nodal and skeletal sites of disease. Abnormal sites of 68Ga-PSMA uptake were identified in 97 of the 106 patients with biochemical failure; local active disease in the prostate gland or prostate bed and its vicinity (n=50), nodal disease (n=41), bone metastasis (n=42). Four patients had disease at the liver, pleura and peritoneum. When performed for monitoring response to therapy, 68Ga-PSMA data separated active skeletal disease and responsive non-active metastases. In one patient with unclear CT lesion at the periportal region that accumulated 68Ga-PSMA, biopsy validated the diagnosis of prostate cancer metastasis and in another patient with unclear CT lung lesion that did not accumulate the tracer unknown colon cancer with liver and lung metastasis was eventually the final diagnosis. The latter findings were suggested on the CT data of the PET/CT with no 68Ga-PSMA increased uptake.

Conclusion: Our initial experience suggests promising role of 68Ga-PSMA PET/CT in imaging patients with prostate cancer. These results raise a potential use of 177Lu-PSMA for treatment of patients with 68Ga-PSMA –avid metastatic disease.

IAEA-CN-232/255

Quantitative Deauville Scale (qPET) in Assessment of Interim 18F-FDG PET in Non-Hodgkin Lymphoma

V.H. Somasundaram, S. Palaniswamy

Amrita Institute of Medical Sciences Research Center

Corresponding Author: vijayharishs@aims.amrita.edu

Background: Deauville 5-point response assessment scale for interim 18F-fluorodeoxyglucose (18F-FDG) PET/CT has now become a routine in tailoring treatment strategy among lymphoma patients. Since PET response is a continuum and its visual assessment may be biased, a quantitative extension of Deauville scale (qPET) was recently proposed and its utility demonstrated in paediatric Hodgkin lymphoma. Here, we have applied the principles of qPET to assess response in patients with diffuse large B cell (DLBC) lymphoma.

Methodology: Data of 68 DLBC lymphoma patients undergoing interim 18F-FDG PET after 4 cycles of R-CHOP chemotherapy was analysed. Standardized volumes of interest were manually drawn. qPET value was measured as the ratio between SUV_{peak} of residual tumours and average uptake in the liver.

Results: Kruskal-Wallis test revealed a significant difference between the mean (median in categories 3 and 4) qPET values in each category. Categories 2, 3, 4 and 5 corresponded to qPET threshold values of 0.6, 0.9, 1.5 and 2.5 respectively. Threshold value of 1.5 proved to be a sensitive and specific indicator of poor metabolic response to chemotherapy.

Conclusion: The qPET method of interim 18F-FDG PET response analysis can be utilized for DLBC lymphomas. In our patients, a good metabolic response of disease to chemotherapy was indicated with qPET values < 1.5.

IAEA-CN-232/256

Is the Biology of Prostate Cancer Related to 18F-Choline Uptake on PET/CT Scans? A Correlation with PSA Values and Gleason Score

L. Maffioli, L. Dellavedova, M. Carletto

A.O. Ospedale Civile di Legnano

Corresponding Author: lorenzo.maffioli@ao-legnano.it

Background: In order to choose the best therapeutic option, it is mandatory to know the exact site of recurrence (local, regional, systemic) in prostate cancer (PC) patients who had undergone radical therapy (prostatectomy and/or radiotherapy) and show biochemical relapse of the disease. Similarly, an accurate evaluation of the extent of the disease in patients recently diagnosed with PC cancer, especially when features of high-aggressiveness are present, could sometimes influence and change the therapeutic plan, suggesting the opportunity of systemic therapy rather than surgical approach. In this setting, the use of 18F-choline (FCH) PET/CT has been showing interesting results. Nonetheless, a better comprehension of the correlation between PET/CT findings and the biological features of PC (i.e. Gleason score, PSA levels) seems necessary, in order to employ properly this effective but expensive diagnostic tool. The aim of the study was to evaluate how Gleason score and PSA levels are related to FCH PET/CT findings in prostate cancer staging and restaging.

Methodology: 80 patients affected by prostate adenocarcinoma were studied with FCH PET/CT (16 staging, 64 restaging). The results of FCH PET/CT were compared with clinical examination and findings of pelvic CT and/or pelvic MRI, to evaluate the diagnostic accuracy, and correlated with PSA values and Gleason score. A ROC analysis was performed to find a threshold in PSA values predicting positive FCH scans.

Results: FCH PET/CT was pathologic in 40/80 (50%) patients (14/16 staging, 26/64 restaging) and showed an overall sensitivity of 90% and a specificity of 86%. The diagnostic accuracy was 88%. The median PSA value in staging patients was 17.10 ng/ml: 18.45 ng/ml in patients with a positive FCH scan, 9.45 ng/ml in negative ones. The median PSA value in restaging patients was 1.21 ng/ml: 3.76 ng/ml in positive, 0.77 ng/ml in negative ($p < 0.05$ in both cases). No clear relationships were found between Gleason score and PET results. A PSA threshold level of 1.65 ng/ml emerged as a good predictor of recurrent prostate cancer lesions in patients who had undergone PET/CT for restaging (AUC 0.81, 73% sensitivity, 81% specificity). Good results in positivity-prediction could be also obtained with lower PSA values, i.e. 1.32 ng/ml (sensitivity 77%, specificity 76%).

Conclusion: The results of our study underline the accuracy of FCH PET/CT in the evaluation of patients with prostate carcinoma, both during staging procedures and restaging after biochemical relapse. They also highlight the close relation between FCH findings and PSA levels and indicate that FCH scans could be useful in localizing recurrences even in patients with quite low PSA values (1.32-1.65 ng/ml), independently from initial biopsy Gleason score. FCH PET/CT emerges as a single, non-invasive and accurate diagnostic procedure for the in-vivo evaluation of the biological behaviour of prostate adenocarcinoma at different time points.

IAEA-CN-232/257

18F-FDG PET/CT Imaging Has a Place in Patients with Germ Cell Tumours

L. Louw¹, S. Sa'id², M.T. Vangu²

¹ WITS

² Nuclear medicine and Molecular imaging, CM Johannesburg Academic Hospital, University of the Witwatersrand

Corresponding Author: lizettelouw@hotmail.com

Background: Germ cell tumour (GCT) is the most common malignancy in men aged 20 – 40 years and has an excellent prognosis. GCTs are categorized as seminomatous or non-seminomatous, with metastases more common in the latter. Initial staging, chemotherapy response and early recurrence diagnosis are of utmost importance in optimizing treatment. Apart from mature teratoma, all GCTs are FDG-avid. Currently, the role of 18F-FDG PET/CT in patients with GCTs is recognized, but not established.

Methodology: We retrospectively reviewed imaging of patients with GCTs referred from June 2008 to December 2014 for 18F-FDG PET/CT for staging, chemotherapy response, restaging and surveillance after equivocal findings on a previous 18F-FDG PET/CT study. We analysed data from 62 patients, 7 were females (11.3%) and 55 were males (88.7%) with an age ranging from 18 to 52 years old (mean: 33). Positive findings were assessed in consideration of the indication for study, clinical suspicion of disease as well as tumour type and origin.

Results: The indications for referral were grouped as follows: Staging = G1 (9 patients), chemotherapy response = G2 (29 patients), restaging = G3 (16 patients) and surveillance = G4 (8 patients). Positive 18F-FDG PET/CT findings were seen in 26 (41.9%) patients: 3 in G1, 18 in G2, 4 in G3, and only 1 in G4. There was no statistical difference on the 18F-FDG PET/CT findings between patients with seminomatous and non-seminomatous GCT (Pearson Chi-square $p = 0.426$). Despite the absence of a clinical suspicion of disease, 18F-FDG PET/CT for surveillance was done in 7 of the patients in G4 due to equivocal findings on a preceding PET/CT study. All of these repeated studies were negative. The single patient with a positive result in G4, however, had a previous positive PET/CT study, but was not treated. As expected, the repeated 18F-FDG PET/CT was positive, with disease progression. Out of the 34 patients with clinically suspected disease (based on raised biomarkers and/or suspicious CT findings and/or clinical symptoms), 18F-FDG PET/CT was positive in only 14 (41.2%)

Conclusion: 18F-FDG PET/CT imaging appears to be a good metabolic imaging modality in patients with known GCTs for staging, assessing response to chemotherapy and restaging. It is however not a cost-effective choice for surveillance of patients with previous equivocal findings, yet no clinical suspicion of disease. Contrary to some literature, this modality performs equally well for seminomatous and non-seminomatous GCTs. Clinically suspected disease based on raised biomarkers, CT findings or clinical symptoms was a poor predictive factor for positive findings on 18F-FDG PET/CT in this review.

IAEA-CN-232/258

18F-FDG PET/CT Imaging in Differentiated Thyroid Carcinoma Patients Who Present with ‘Truncated Expression of Sodium Iodide Symporter’ Syndrome

K. Purbhoo, O. Evbuomwan, O.A. Ayeni, M.D.T. Vangu

Department of Nuclear Medicine and Molecular Imaging, University of the Witwatersrand, Johannesburg, South Africa

Corresponding Author: khushica.purbhoo@wits.ac.za

Background: Differentiated thyroid cancer (DTC) is the most frequent endocrine cancer, representing 1% of all malignant tumours. Whole-body 131I scintigraphy (WBS) and serial thyroglobulin measurement (Tg) are standard methods for detecting thyroid cancer recurrence after total thyroidectomy and 131I ablation. Some patients develop elevated Tg or there is clinical suspicion of recurrence, but WBS is negative. This may reflect non-iodine-avid recurrence or metastasis. This subset of patients poses a diagnostic and therapeutic challenge because disease localization can be difficult. As DTC cells dedifferentiate, their radioiodine uptake generally decreases and their glucose metabolism generally increases. This alternating pattern of 131I uptake to 18F-FDG uptake has been described as a “flip-flop” uptake pattern. 18F-FDG PET/CT plays a valuable role in the post thyroidectomy workup of patients with DTC who have elevated Tg levels and a negative 131I-WBS or the so called ‘Truncated Expression of Sodium Iodide Symporter (TENIS)’ syndrome. In daily practice, the decision regarding when to perform 18F-FDG PET/CT in patients with DTC should be tailored for each patient, considering not only Tg levels and radioiodine WBS findings, but also the individual risk on the basis of clinical and histopathologic features.

Methodology: We retrospectively reviewed data of 28 patients followed up in our clinic. All patients who underwent 18F-FDG-PET/CT from January 2009 to December 2014 were evaluated for possible analysis. Patients were WBS-negative but were suspected to have recurrence based on Tg levels, anti Tg levels or on clinical grounds. Suspected 18F-FDG-PET/CT abnormalities were reported as positive, negative or uncertain for disease. Lesions were ultimately declared benign or malignant by surgical pathology, fine needle aspiration (FNA), other modalities, ie. ultrasound, bone scan, MRI etc, or based on clinical outcome (disease progression).

Results: There were 23 females (82.14%) and 5 males (17.85%). The patients’ age ranged from 30 to 75 years (mean: 51.08 +/-12.68). The primary histological types were as follows: Follicular variant of papillary carcinoma - 8 (28.57%), Papillary - 14 (50%), Follicular - 3 (10.71%), hurtle cell variant - 2 (7.14%). Positive PET/CT imaging findings were seen in 11 patients (40%), negative findings in 14 patients (50%) and equivocal findings were seen in 3 of the patients (10%). Of the 11 patients that had positive PET findings, 3 patients (27%) had localized disease, 4 patients (36%) had distant disease only, and 4 patients (36%) had both local and distant disease. A significant difference was found in PET findings between the patients that were done during TSH stimulation (63%) versus only 30% during TSH suppression ($p < 0.05$).

Conclusion: 18F-FDG PET/CT imaging is essential in the management of patients with TENIS syndrome. Surgery may be indicated in patients with localised disease found on PET imaging. The TSH stimulated PET was superior to PET imaging done on TSH suppression.

IAEA-CN-232/259

Using Hybrid Imaging (SPECT-CT) to Identify a Particular Reason of Single HMDP- 99mTc Uptake in the Context of Breast Cancer

F. Mansouri ¹, H. Mahtout ²

¹ Nuclear Medicine Department. University Hospital Dr Benbadis Constantine Algeria

² Nuclear medicine department. HMRU Constantine Algeria

Corresponding Author: farouk.mansouri@gmail.com

Background: Planar bone scan is one of the most prescribed examinations in nuclear medicine relating to the increasing prevalence of cancer in the world, especially before (staging) and after (evaluation) specific treatments (surgery, chemotherapy +/- radiation).

Increased diphosphonates-99mTc bone uptake is very common, but reaching etiologic diagnosis is often difficult, especially when staging a cancer disease.

The introduction of hybrid SPECT-CT imaging has enabled a diagnostic resolution of a large number of cases, including ours.

Methodology: We present a case of a 40 years old female patient with recent history of a malignant tumour discovered after breast biopsy. She was referred to conventional bone scan for pre-treatment investigation, and in addition a SPECT-CT was performed.

Results: In the conventional bone scan, a single focal increased uptake was seen, next to the fronto-temporal junction, without other associated lesions.

The SPECT-CT revealed the anatomical characteristics of the bone lesion and an associated brain disease. The bone lesion was an erosion of the internal table of the skull caused by meningioma.

Meningiomas are often benign tumours arising from the meningeal layer of the central nervous system. Most meningiomas are non-cancerous and are slow-growing; they also can grow outwards toward the skull, causing it to thicken. Some meningiomas have receptors that interact with hormones, including progesterone, androgen and less commonly estrogen. Researchers observed that meningiomas occasionally grow faster during pregnancy.

They represent about one-third of all primary brain tumours and occur most frequently in middle-aged women. They occur about twice as often in women as in men.

They are most likely to be found in adults older than 60; the incidence appears to increase with age. Rarely are meningiomas found in children.

Risk factors for meningiomas include:

- Previous radiation to the head
- History of breast cancer
- Neurofibromatosis type 2

Surgery and radiation are the most common forms of treatment.

Although surgery is the primary treatment, some tumours may not be removed this way.

Radiation therapy may be used for:

- Tumours not or incompletely removed with surgery
- Malignant meningiomas or anaplastic tumours

- Recurrent tumours

Conclusion: HMDP-99mTc planar bone scan and multimodality imaging using SPECT-CT helped in reaching the correct diagnosis in this patient (no breast cancer metastasis to the bone) and revealed a second pathology (meningioma) which requires special management (surgery +/- radiation).

IAEA-CN-232/260

**A Novel SUV-Based Quantification of ^{99m}Tc -MDP
SPECT/CT Uptake and ^{18}F -FDG PET/CT Metabolism in
Patients with Lumbar Disc Herniation**

W. Zhai, W. He

Huadong Hospital

Corresponding Author: weihaozhai@hotmail.com

Background: The objective of this study was to investigate the clinical value of SUV measurements in ^{99m}Tc -MDP SPECT/CT and ^{18}F -FDG PET/CT in lumbar disc herniation and its correlation with glucose metabolism of the lower extremity muscles.

Methodology: 75 patients with diagnosed single level unilateral lumbar disc herniation were enrolled in this study. Each patient underwent both ^{99m}Tc -MDP SPECT/CT and ^{18}F -FDG PET/CT. SPECT/CT SUV and PET/CT SUV of involved lumbar vertebral and normal lumbar vertebral uptake were calculated using the quantification tools 'SUV-SPECT' and 'Hybrid Viewer' on a HERMES Workstation. Meanwhile SUVmax of their different lower extremities' muscles were detected by ^{18}F -FDG PET/CT and the results were compared with contralateral healthy muscle. The correlations between SUVmax, Oswestry disability index and visual analogue pain scale (VAPS) were analysed.

Results: The measured SPECT/CT SUVmax (body weight) of involved lumbar vertebrae in 75 patients was 15.4 ± 3.1 . SPECT/CT SUVmax of normal vertebral uptake in 300 patients was 8.3 ± 1.2 . Meanwhile, PET/CT SUVmax of referred muscle was 2.25 ± 0.34 and 2.03 ± 0.14 for ipsilateral and contralateral uptake respectively. The involved vertebral SPECT/CT SUV values were significantly higher than those of the normal vertebrae ($P < 0.01$), but PET/CT SUV showed no significant difference between them ($P > 0.05$). The differences between ipsilateral and contralateral PET/CT SUVmax were significantly lower than those of contralateral muscle (1.05 ± 0.03 vs 1.29 ± 0.13 , 1.06 ± 1.03 vs 1.23 ± 0.18 ; $P < 0.01$). The difference between ipsilateral and contralateral SUVmax were positively correlated with Oswestry disability index ($R^2 = 0.974$, $P < 0.01$) and negatively correlated with JOA score ($R^2 = -0.774$; $P > 0.01$).

Conclusion: SPECT/CT SUV is a cost-effective absolute quantification tool to evaluate lumbar disc herniation. ^{18}F -FDG PET/CT can detect glucose metabolism changes in the involved extremity muscles.

IAEA-CN-232/261

Patients with Normal Exercise Stress Myocardial Perfusion Studies Who Achieve Less Than 75 Percent of Maximum Predicted Heart Rate Are at Increased Risk for Cardiac Events

W. Zhai, W. He

Huadong Hospital

Corresponding Author: weihaozhai@hotmail.com

Background: The objective of this study was to investigate whether patients with normal stress myocardial perfusion imaging (MPI) who achieve < 75% maximal predicted heart rate (MPHR) with the Bruce protocol are at higher risk for cardiac events compared to those who achieve higher levels of MPHR.

Methodology: 1000 patients (614 male, 386 female; mean age 60 ± 12 y) with normal MPI in whom Bruce protocol stress MPI was performed were enrolled. The patients were divided into two groups based on MPHR; 116 patients with MPHR < 75% were placed in the Group 1 and 884 patients with MPHR \geq 75% were placed in Group 2. Follow-up data over $\sim 2 \pm 0.3$ year were obtained from hospital records. Associated cardiac risk factors, medications and prior cardiovascular medical history were compared in these two groups, and prognostic value of exercise treadmill stress variables analysed.

Results: There were a total of 30 adverse cardiac events. In Group 1 there were 16 events (16 / 116=14.0%). In Group 2 there were 14 events (14/ 884=1.5%). The difference in the number of events in the two groups was highly significant ($p < 0.001$). Group 1 patients were more likely to have a history of MI, PTCA, diagnosed CAD, symptoms of typical angina, smoking history, hypertension, or treatment with β -blockers. Resting HR, peak HR, peak SBP, METS, frequency of ST depression ≥ 1 mm and EF were significantly higher in Group 2 patients; the Duke score was significantly lower in the Group 2 patients. Stepwise regression analysis demonstrated that the variables most likely to be related to cardiac events were MPHR, followed by ischemic ECG changes, and METS. Duke score and systolic blood pressure did not have a strong influence on adverse cardiac events.

Conclusion: Patients with normal exercise MPI with MPHR below 75% should be evaluated with pharmacological stress testing or other appropriate procedures to prevent future adverse cardiac events.

IAEA-CN-232/262

Standardized Uptake Values of ^{99m}Tc -MDP SPECT Bone Scans - a Novel Method for Absolute SPECT/CT Quantification

W. Zhai, W. He

Huadong Hospital


Corresponding Author: weihaozhai@hotmail.com

Background: The objective of this study was to investigate the variation of SUV values in ^{99m}Tc -MDP bone scans using SUV SPECT hybrid reconstruction based quantitative methods.

Methodology: 430 patients (mean age 63.07) were enrolled and were divided into three groups: Group 1 was 298 patients without vertebral disease, Group 2 was 51 patients with degenerative changes, and Group 3 was 81 patients with bone metastases. To generate SUV-calibrated images, the raw SPECT data was reconstructed using the software 'SUV-SPECT'. Corrections were applied for CT attenuation, Monte Carlo-modelled scatter correction, resolution recovery, scaling for injected dose and radioactive decay. The units of counts-per-voxel were scaled to activity per unit volume (Bq/cc) based on previously performed phantom calibration work to allow for SUV measurements. The reconstructed images were analysed using a constrained threshold-based volume of interest approach to automatically calculate the uptake in the bony structures. SUVmax by body weight was recorded in the derived volume. All the values were measured twice to verify consistency.

Results: The mean SUVmax for Group 1 was 7.09 ± 1.6 (cervical vertebra), 6.54 ± 1.19 (thoracic vertebra), 7.79 ± 1.41 (lumbar vertebra) and 7.93 ± 2.91 (pelvis). For Group 2 the mean SUVmax was 11.46 ± 4.09 . For Group 3 it was 25.23 ± 1.97 (cervical vertebra), 40.73 ± 32.66 (thoracic vertebra), 52.43 ± 18.96 (lumbar vertebra) and 53.24 ± 38.79 (pelvis). There were significant differences between Group 3 and 1 ($P < 0.01$). The mean SUVmax between the degenerative and the normal results (Groups 1 and 2) had no statistical difference. The repeated results were consistent.

International Conference on Clinical PET-CT and Molecular Imaging (IPET 2015): PET-CT in the Era of Multimodality Imaging and Image-Guided Therapy



Conclusion: This method is accurate, easy-to-use and robust, providing absolute quantification in SPECT/CT, which promises to be widely used in primary diagnosis and evaluation of therapy response. Furthermore, multi-centre data are planned to be acquired to build up SUV variation in bone scan through cloud-based solutions.

IAEA-CN-232/263

**The Clinical Application of Absolute Quantification SUV SPECT
99mTc-MIBI Myocardial Perfusion Imaging to Translate
Myocardial Viability - A Pilot Study**

W. Zhai, W. He

Huadong Hospital

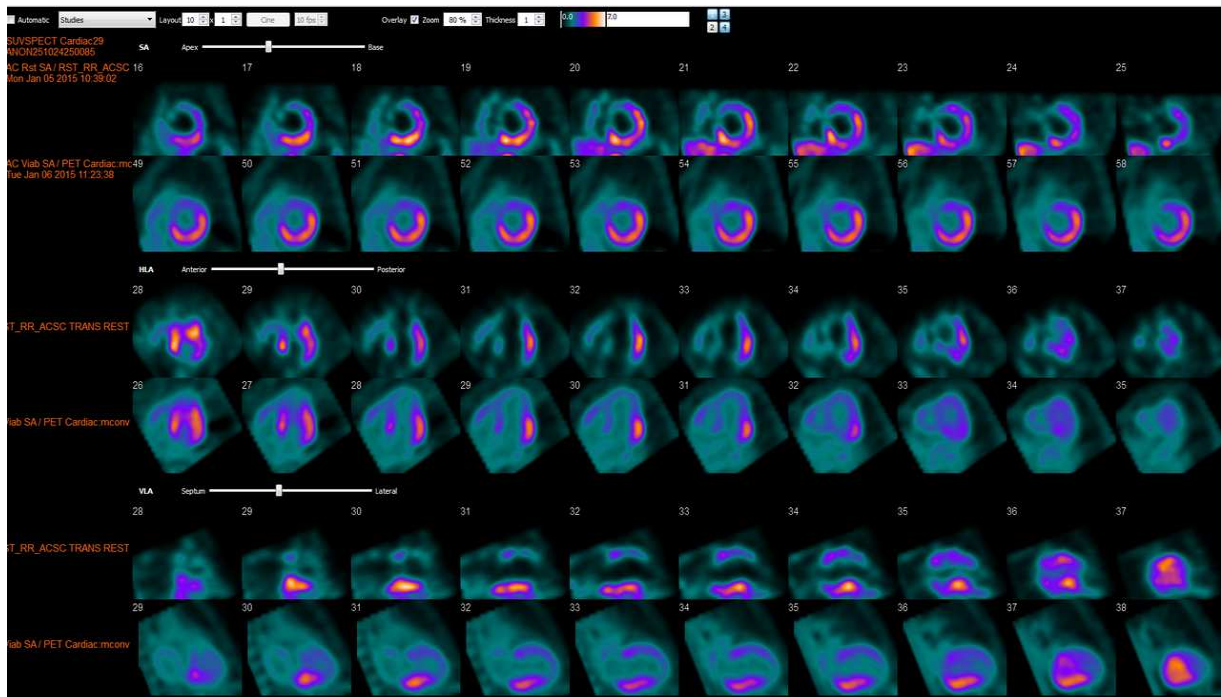
Corresponding Author: weihaozhai@hotmail.com

Background: The objective of this study was to investigate the relation of SUV values between 99mTc-MIBI and PET/CT in cardiac imaging to evaluate myocardial viability.

Methodology: 15 consecutive patients with previous MI and left ventricular (LV) dysfunction ($35 \pm 6\%$), who underwent 99mTc-MIBI SPECT and 18F-FDG PET/CT were enrolled. Results of the two studies were divided into two types: myocardial perfusion match (group 1 MM) and myocardial perfusion mismatch (group 2 M). The SPECT/CT images were acquired using the standard clinical acquisition protocol (1800 scan arc, 64 frames in step-and-shoot mode, 25s per frame). The raw projection data was reconstructed using the software 'SUV-SPECT™'. The reconstruction parameters were set to 16 subsets and 5 iterations. Corrections were applied for CT attenuation correction, Monte Carlo-modelled scatter correction, resolution recovery, scaling for injected dose and radioactive decay. The units of counts-per-voxel were scaled to activity per unit volume (Bq/cc) based on previously performed phantom calibration work to allow for SUV measurements and scaling of different myocardial segments and compare with 18F-FDG PET/CT SUV.

Results: 9 patients were mismatch, while 6 were match. The value of SUV 99mTc-MIBI myocardial perfusion was 4.1 ± 0.3 (inferior), 2.8 ± 0.4 (septum), 4.3 ± 0.3 (anterior), 3.9 ± 0.2 (lateral), and 2.3 ± 0.1 (apex). There was no statistical difference between SUV in 30 mismatch segments in SPECT/CT and PET/CT, but SUV in 15 match segments was 20- 55 % different, with statistical difference.

International Conference on Clinical PET-CT and Molecular Imaging (IPET 2015): PET-CT in the Era of Multimodality Imaging and Image-Guided Therapy



Conclusion: Absolute quantification SUV SPECT ^{99m}Tc -MIBI myocardial perfusion imaging can be used as a translator to evaluate myocardial viability. A multi-centre study is planned to explore SUV cut-off in ^{99m}Tc -MIBI myocardial perfusion imaging to evaluate viable myocardium.

IAEA-CN-232/264

**The Clinical Value of Novel Hybrid 3D Lobar
Quantification SPECT Lung Ventilation/Perfusion Scan in
Predicting Remaining Lung Function for Lobectomy Lung
Cancer Patients**

W. Zhai, W. He

Huadong Hospital

Corresponding Author: weihaozhai@hotmail.com

Background: The objective of this study was to investigate the clinical value of hybrid 3D lobar quantification SPECT lung ventilation / perfusion scan in predicting the remaining lung function, compared with clinical routine respiratory function test. Pre- and post-lobectomy hybrid 3D lobar quantification results were also compared.

Methodology: 115 patients with suspected lung cancer were enrolled. All the patients underwent an independent diagnostic CT and SPECT lung V/Q scan before and after lobectomy. Diagnostic CT was co-registered with attenuation corrected SPECT V/Q images. A 3D segmentation algorithm was used to automatically extract the left and right lung from the diagnostic CT. The lung regions were further split into lobar regions by semi-automatically placing points along the lobar boundaries (fissures). Once the lobar regions were accepted, they were added to the SPECT V/Q images and the relative percentage contribution of each lobe was computed for both ventilation and perfusion. All the results were compared with clinical routine respiratory function test criterion (FEV1, VC, FEV1%, MVV). Pre and post-surgery hybrid 3D lobar quantification lung V/Q results were compared. The difference between the two methods and two point time scan were tested for significance using non-parametric test or χ^2 test.

Results: The agreement rate of predicting the remaining lung function between lung V/Q hybrid 3D quantification and clinical routine function test was 97.8% (101/115; $\chi^2=0.158$, $P>0.05$), while pre and post-lobectomy lung V/Q hybrid 3D quantification results were not significantly different - remaining perfusion: $75.8 \pm 8.71\%$, $78.3 \pm 5.39\%$, $\chi^2=1.14$, $P>0.05$ respectively; remaining ventilation: $83.1 \pm 3.42\%$, $81.2 \pm 5.1\%$, $\chi^2=1.23$, $P>0.05$ respectively.


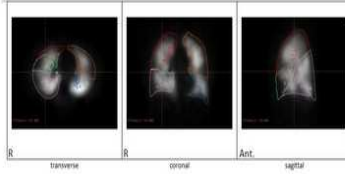
International Conference on Clinical PET-CT and Molecular Imaging (IPET 2015): PET-CT in the Era of Multimodality Imaging and Image-Guided Therapy

Hybrid3D - Lobar Quantification

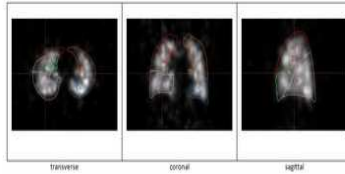


Name: LUNGS WHY ID: ANCON104155041072
 Date of Birth: 01/01/1967 Sex: F
 Study Date: 26/12/2013

Perfusion:



Ventilation:

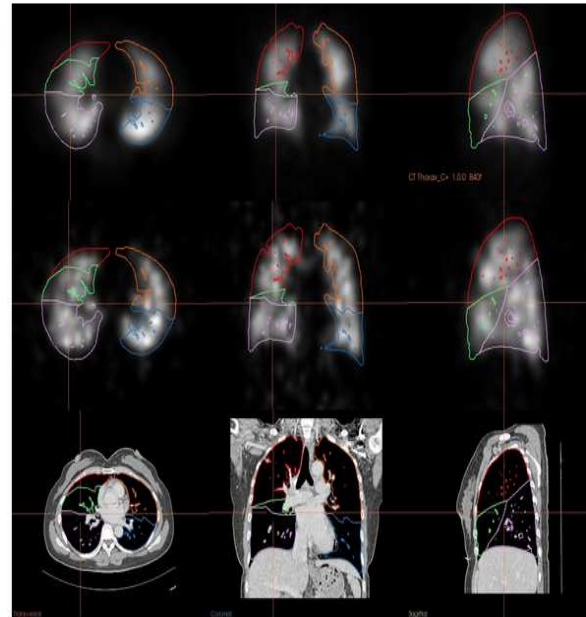


Results:

	Perfusion (%)		Ventilation (%)	
	Right	Left	Right	Left
Upper	19.7	25.9	19.9	22
Middle	5.49	N/A	7.46	N/A
Lower	25.2	23.7	25.9	24.8
Total	50.4	49.6	53.2	46.8

Predicted Remaining Function:

	Perfusion (%)	Ventilation (%)
Right	30.69	33.36
Left	49.6	46.8
Total	80.29	80.16



Conclusion: Hybrid 3D lobar quantification of lung V/Q method can predict accurate postoperative pulmonary function in patients undergoing lobectomy.

IAEA-CN-232/265

**The Clinical Value of SUV Measurements in ^{99m}Tc-MDP
SPECT/CT Bone Scans in the Evaluation of Therapy
Response in Prostate Cancer Patients with Bone Metastases**

W. Zhai, W. He

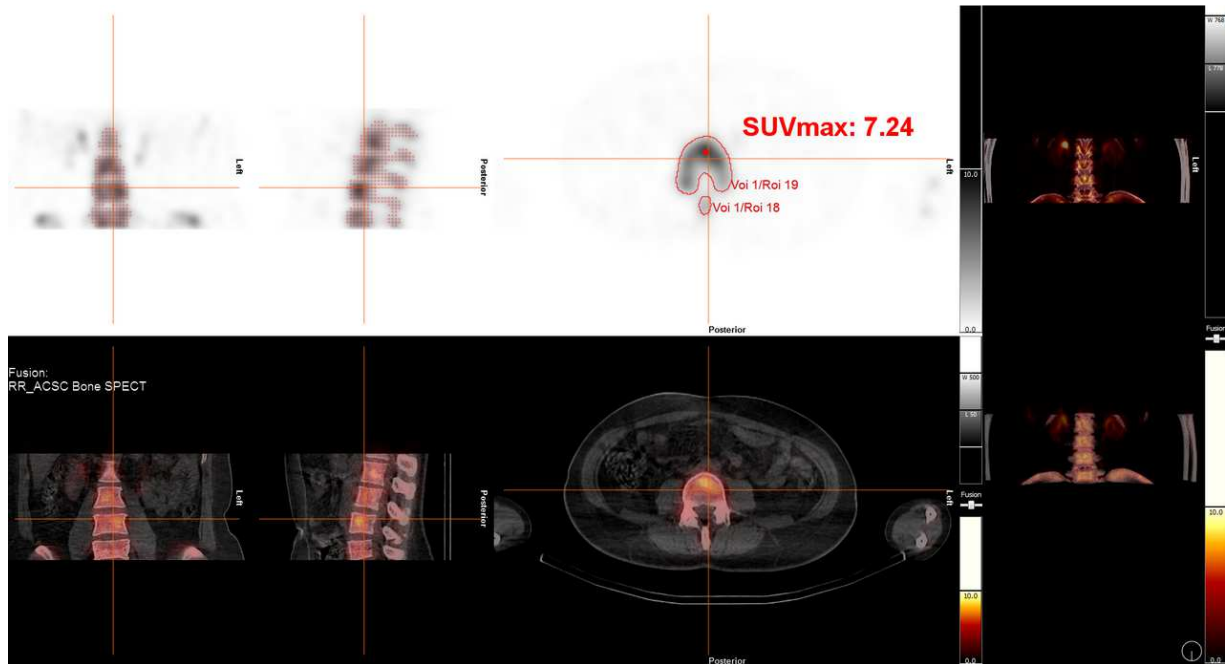
Huadong Hospital

Corresponding Author: weihaozhai@hotmail.com

Background: The objective of this study was to evaluate the clinical value of SUV measurements in ^{99m}Tc methylene diphosphonate (^{99m}Tc MDP) SPECT/CT bone scans for assessing therapy response in prostate cancer and to investigate its relation with serum prostate-specific antigen (PSA), alkaline phosphatase (ALP), bone-specific alkaline phosphatase (BAP) and Gleason scores.

Methodology: 312 patients with diagnosed prostate cancer were enrolled. All patients showed lumbar spine metastases based on the corresponding appearance on MRI. A ^{99m}Tc-MDP SPECT/CT bone scan, serum test of PSA, ALP, BAP and Gleason score were performed pre- and post- therapy. The SUV uptake in the bone scan was generated using the novel software 'HERMES SUV-SPECT'. The quantitative results for pre- and post- therapy were divided into two groups according to PSA, ALP, BAP and Gleason score. The SPECT/CT SUV values (SUVmax by body weight) were compared with these two groups using multivariate analysis.

Results: The measured SUV values were 35.1 ± 6.80 for 435 lumbar vertebral lesions in the pre-therapy scans. 625 patients with normal lumbar vertebrae were had an SUV value of 8.50 ± 1.80 . The difference was statistically significant ($P < 0.001$). Multivariate analysis suggested that the difference in pre- and post- therapy SUV lesion measurements was statistically significant in the group of PSA > 50 ng/ml, ALP > 1000 ng/L, BAP > 20.1 ng/L and Gleason score 7-10 points. There was no statistically significant difference ($P > 0.05$) between pre- and post-therapy SUV values in the group whose PSA < 25 ng/ml, ALP > 350 ng/L, BAP < 20 ng/L, and with a Gleason score of less than 7 points.



Conclusion: The software ‘SUV-SPECT’ is a user-friendly, reliable and robust quantification tool. SUV measurements of SPECT/CT bone scans can serve as an absolute quantification to follow-up prostate cancer patients with bone metastases in daily clinical practice.

IAEA-CN-232/266

Is Cardiac PET Imaging for Viability Assessment an Unnecessary Luxury in Developing Countries?

D. Mpanya, A.B. Rahmani, E. Hammond, M.T. Vangu

University of Witwatersrand

Corresponding Author: dineompanya@gmail.com

Background: In patients with confirmed infarction on myocardial perfusion imaging (MPI) studies, a reliable assessment of the amount of viable myocardium is crucial to guide the selection of patients who would benefit from revascularisation. The amount of viable myocardium assessed preoperatively is the best indicator of long-term cardiac event-free survival after cardiac intervention. Various diagnostic modalities are utilised for the assessment of myocardial viability, e.g. echocardiography, cardiac molecular imaging techniques (PET, SPECT), cardiovascular MR or cardiovascular CT. PET imaging with 18F-FDG is highly accurate and reproducible in this setting. Despite its accuracy and reproducibility, 18F-FDG PET is an expensive imaging modality that requires appropriate indications, particularly in developing countries where cardiothoracic services are limited.

Methodology: We retrospectively reviewed the data of cardiac patients referred for the assessment of myocardial viability. All these patients had confirmed myocardial infarction on the resting 99mTc-Sestamibi MPI images and the electrocardiogram (ECG). All patients referred for PET-CT imaging from January 2009 to July 2014 were reviewed. Specific attention was given to the number of patients with viable myocardium and to the number of patients that eventually underwent revascularisation.

Results: A total of 175 patients were included in the study. There were 116 males (66%) and 44 females (25%). Fifteen patients (9%) were left undefined. Ninety-two patients (53%) demonstrated myocardial viability on the 18F-FDG PET-CT images. Of these, in 86 patients (93%) viability was visualised in more than 10% of the myocardium. There was a correlation between the rest ejection fraction (rest EF) and the extent of the infarcted area ($r=0.37$; $p<0.05$). For multiple varying reasons only 15 of the 86 patients with visualised myocardial viability (17%) actually underwent revascularisation. The post-revascularisation rest EF was inconsistently measured rendering this variable of limited value in the few patients who benefited from cardiac intervention.

Conclusion: 18F-FDG PET-CT imaging for the assessment of myocardial viability seems to be over-utilised in our clinical settings. While a detailed analysis of the factors that limit revascularisation is needed, a rigorous set of appropriate use criteria is required in current health economics to render the use of this modality cost effective in an environment with limited resources.

IAEA-CN-232/267

The Role of SUV SPECT Perfusion Defect Quantification of the Lung as a Predictor of Severe Cardiovascular Events in a Cohort of Patients with Congestive Heart Failure

W. Zhai, W. He

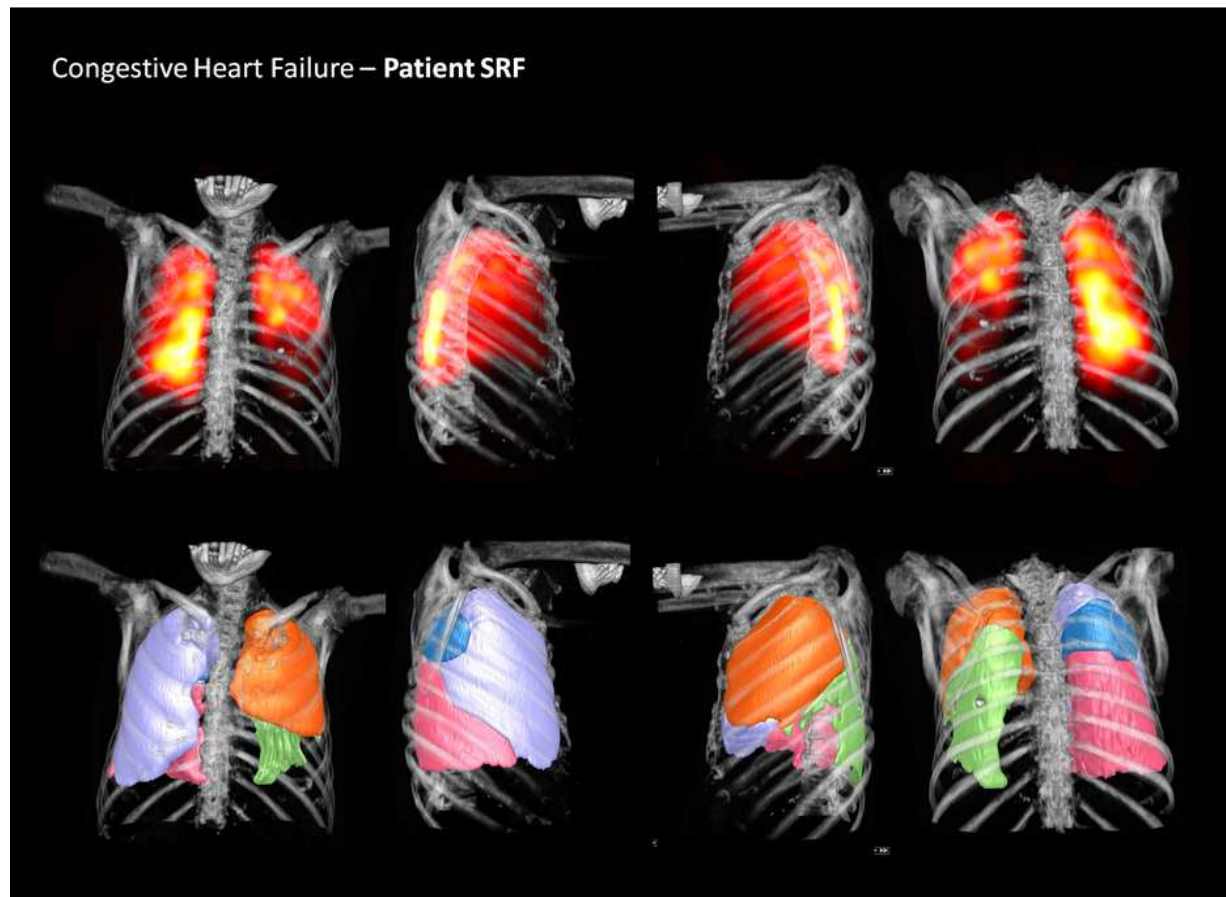Huadong Hospital

Corresponding Author: weihaozhai@hotmail.com

Background: The aim of this study was to investigate the use of SUV SPECT to quantify lung perfusion defects in both non-congestive heart failure (CHF) patients and CHF patients and to explore its correlation index as an outcome predictor for CHF patients.

Methodology: 30 patients were enrolled in the study. 17 CHF patients were followed for 16 ± 5 months (mean \pm SD) and 13 patients were a non-CHF control group. All patients underwent a lung perfusion scan, an independent diagnostic CT plus echocardiography. The lung perfusion scan was reconstructed using the software to convert the recorded counts per voxel into activity per unit volume to allow for SUV calculations. The diagnostic CT was co-registered with the SPECT perfusion scan in order to relate the perfusion function to anatomy. Using the software 'Hybrid 3D Lung Lobe Finder', the lungs were further split semi-automatically into individual lobes by placing 10 to 15 points along each fissure. Using the computed anatomical volumes it was possible to record the total SUV and volume of each lung and lobe. The difference in SUV between the CHF group and the control group was compared. Cardiac death, acute MI, unstable angina, and late revascularization (>3 months) experienced by the patients during follow-up were defined as cardiac events. Multivariate Cox regression analysis was applied for cardiovascular events patients and different SUV index.

Results: Preliminary results showed that there was no significant difference between the total lung SUV in the two groups. There were 10 patients (33.3%) who had cardiac events, including 2 cases of acute MI, 3 late coronary artery bypass grafting, and 5 unstable angina pectoris during the follow-up. Upon completion of the study, a differential SUV analysis between the CHF group and the control group will be presented.



Conclusion: SUV SPECT perfusion defect quantification of the lung is a promising method for assessing pathology, physiology state and the rate of severe cardiovascular events in CHF patients.

IAEA-CN-232/268

The Utility of Automatic Dispenser in Nuclear Medicine

W. Zhai, W. He

Huadong Hospital

Corresponding Author: weihaozhai@hotmail.com

Background: Radionuclides are widely applied in nuclear medicine. Previously, staff in nuclear medicine department dispensed and diluted the radiopharmaceutical manually, leading to low dispensing accuracy and poor radiation protection. The aim of this study was to find a solution to improve the dispensing accuracy and lower the radiation exposure.

Methodology: Four staff members were involved in this study using the same radiopharmaceutical (¹⁸F-FDG), and they injected the same number of patients (80 every month) with the same dose (10mCi). Data from 8 months (June 2013 to January 2014) before using automatic dispenser were placed in Group 1 and data from 8 months (February 2014 to September 2014) after using automatic dispenser were placed in Group 2. Individual exposure dose was recorded every 2 months. The actual injected radioisotope dose of each patient was measured and the dispensing deviation was calculated.

Results: The individual radiation dose in Group 1 was 353.55 μSv, 365.9 μSv, 348.58 μSv and 384.93 μSv, respectively, while the dose in Group 2 was 71.78 μSv, 83.68 μSv, 79.35 μSv and 72.7μSv, respectively. Group 2 has received much lower, statistically different radiation dose than Group 1. The mean dispensing deviation in Group 1 was 3.986% and in Group 2 1.211%, the difference being statistically significant.

Conclusion: Automatic dispenser can be a good solution to lower the radiation exposure. Also, it is easy to operate and has a high dispensing speed. It should therefore be integrated in more nuclear medicine departments.

IAEA-CN-232/269

To Investigate the Nuclear Medicine PET/CT Standardized Training Model

S. Chen; H. Shi

Fu Dan University ZhongShan hospital, China

Corresponding Author: tc99m@sina.com

Background: Molecular imaging is developing very quickly in China in the past 10 years. Two hundred sets of PET/CT are installed in medical institutions in China as of 2013, providing medical services to approximately 240000 patients each year. A training programme is being implemented to ensure the standardization of PET/CT technology and procedure, and explore the efficient establishment of new PET/CT is being explored.

Methodology: In the period 2010 - 2013, 10 technicians from the Department of Nuclear Medicine of the Zhongshan Hospital Fudan University underwent training for clinical application of PET/CT. The trainees were divided into two groups, according to the way of training – traditional versus standardized training model. After going through the same period of training, by the 3 physicians-in-charge practice of attending PET/CT based on basic knowledge, technology and advanced proficiency in three areas, to assess the results.

Results: No significant difference between the two groups of people in the basic knowledge in PET/CT scores, the technical operation of two groups score normalization training group was significantly higher than that of the traditional training group, advanced application ability training group is superior to the traditional grades standardized training group. Group A of non - standard training mode - trained technicians, did not meet uniform technical operating standard, in terms of software for advanced application has some advantages, but each application level is different, so pet/ct operation in practice not achieve uniform technical standard, cannot be applied to achieve standardization of PET/CT. Group B of the standardized training of technicians reached technology standard in the provision of training time required for the operation.

Conclusions: PET/CT standardized approach is to ensure the application of image acquisition and processing the need to ensure the correct, but a single training model cannot give full play to individual characteristics. Training should be based on clinical need to develop PET/CT application mode ,you can improve efficiency, reduce the practice of application of new technologies.

IAEA-CN-232/270

PET/CT in Latin America - Brazilian Experience

C. Mesquita¹, F. Silva²

¹ Hospital Universitario Antonio Pedro

² INTO - BRAZIL

Corresponding Author: claudiotinocomesquita@gmail.com

Background: Worldwide PET/CT utilization will grow 22% over the next five years and 55% over the next ten years. The reasons include: (1) more clinical confidence; (2) falling prices of the equipment that used to span from \$1.8 million-3 million and now is close to \$1.2 million-2.3 million, and (3) increase in non-communicable chronic diseases prevalence, especially cancer and cardiovascular diseases. Latin American and Caribbean countries are struggling to respond to increasing morbidity and death from advanced cancer. PET/CT was recently included (2014) in the global government public coverage health system in Brazil. We analyse Brazilian experience with this technique to offer a perspective from Latin American where PET/CT is being incorporated in a country with a universal health system.

Objective: To analyse Brazilian experience with PET/CT: distribution of services, number of nuclear physicians, training centres, and resources involved.

Methodology: We performed a search on positron emission tomography services authorized to operate and nuclear physicians authorized in Brazil on the official site of the Brazilian National Committee of Nuclear Energy and Brazilian demographics in the site of National Institute of Geography and Statistics.

Results: The first 18F-FDG study in Brazil was done in a SPECT/PET hybrid machine in 1998 and the first PET scanner was installed in 2003. In 11 years the number of PET services increased to 101, corresponding to 23% of the number of all nuclear medicine services in Brazil (433). PET scanners are mostly concentrated in the Southeast region (51 services = 50.3%). Brazilian population is estimated to 203.894.000 inhabitants giving the ratio of 2 million inhabitants per equipment. There are five Brazilian states that do not have PET/CT scanners, mostly in the Amazonia region. Patients in these areas need to cross more 1.000 km to have access to PET/CT. This is approximately 50% of the number of PET/CT machines adjusted for the population of US. The main radiotracer used in Brazil is 18F-FDG used in all services, followed by 68Ga (7 services), 11C (2 services) and I124 (2 services). The mean activity per week of 18F-FDG allowed for these services is 1200 mCi, most of them using 1000 mCi or less per week. In Brazil there are 11 cyclotrons producing 18F-FDG. There are 600 nuclear medicine specialists in Brazil, most of them in the Southeast region (55%). Nuclear medicine specialists comprise only 0.25% of all physicians in Brazil. There are 23 training centres for nuclear medicine physicians, mostly in the Southeast region.

Conclusion: Brazilian experience with PET/CT is evolving and the growth observed in the last decade is impressive. At present, there is an asymmetrical distribution of resources that creates difficulties for part of the Brazilian population to have access to this technology. Efforts to provide a more equal distribution of resources and specialists must be considered in order to strength the care of patients with non-communicable chronic diseases, especially cancer and cardiovascular diseases.

IAEA-CN-232/271

18F-FDG PET in the Differential Diagnosis of Parkinsonism on an Individual Basis

D. Volterrani¹, G. Puccini¹, D. Frosini¹, F. Guidoccio¹, A. Accorroni¹,
E. Filidei², A. Giorgetti², G. Manca³, R. Ceravolo¹, G. Mariani¹

¹ University of Pisa

² Fondazione Gabriele Monasterio

⁵ Regional Center of Nuclear Medicine, Pisa

Corresponding Author: duccio.volterrani@med.unipi.it

Background: Although the clinical diagnosis of Parkinson's disease (PD) and atypical parkinsonism (AP) is based on standardized and reproducible clinical diagnostic criteria established by several consensus conferences, distinguishing between AP and PD in early stages may be quite difficult. Molecular imaging techniques play a fundamental role in the diagnosis and classification of patients with movement disorders. It has been reported that PET with 18F-FDG can identify patterns of regional glucose metabolism that are characteristic for PD or AP. However, most previous studies were based on a group-comparison approach.

The aim of this study was to evaluate the diagnostic accuracy of PET with 18F-FDG in parkinsonism on an individual basis in order to aid in the identification of the different forms of parkinsonism.

Methodology: We retrospectively analysed 101 PET scans of patients with parkinsonism who underwent in their diagnostic work-up a PET scan with 18F-FDG at baseline (within 1 year since onset of the symptoms) and at clinical follow-up of at least 5 years.

The scans were processed by a fully automatic analysis software of 18F-FDG data PMOD (PMOD Technologies v.3.408), and the parametric maps obtained that way were independently evaluated by two readers blind as to the final diagnosis.

Results: At the 5-year follow up patients were classified as follows: 17 PD (mean age 65), 23 multiple system atrophy (MSA) (mean age 72), 30 progressive supranuclear palsy (PSP) (mean age 74), 16 cortico-basal degeneration (CBD) (mean age 72), 15 Lewy body dementia (LBD) (mean age 75). Sensitivity and specificity of PET with 18F-FDG for the diagnosis of AP were 94% and 88% respectively. The inter-rater agreement was 0.60 to 0.86 by Kappa Cohen.

Conclusion: Our data demonstrate the usefulness of a computer-supported 18F-FDG PET analysis to help the clinicians in the early differential diagnosis of PD, PSP, MSA, CBD and LBD on a single case basis.

IAEA-CN-232/272

Effect of Radiotherapy on Salivary Gland in Head and Neck Cancer

S.A Khan ¹, A. Sood ², S. Sharma ²

¹ Anand Mri, New Delhi

² PGIMER

Corresponding Author: shahnawaz_alam46@yahoo.com

Background: The aim of this study was to evaluate the effect of radiotherapy in patients with head and neck cancer pre and post therapy through salivary gland scintigraphy using 99mTc-pertechnetate.

Methodology: A total of 8 patients (4 males and 4 females) with head and neck cancer aged 38-66 years were enrolled in this prospective study. Patients were positioned in supine position with chin up and neck extended, with the detector positioned anteriorly. All patients were intravenously injected with 15-20 mCi of 99mTc-pertechnetate and dynamic images were acquired for 30 min. Patients were given 5 ml of lemon juice at 40th frame. Static images were acquired. Mean, standard deviation and data descriptive values were calculated for the uptake ratio, percentage max accumulation, and percentage excretion for parotid and submandibular gland individually in both pre and post therapy salivary scintigraphy image.

Results: For both the parotid and submandibular glands there was a significant reduction in mean uptake ratio, mean percentage, maximum accumulation and mean percentage excretion post radiotherapy suggesting a reduction in the parotid gland uptake capability.

PAROTID					
	Mean value Pre-therapy	Mean value Post-therapy	T TEST	T value at df 7 and P=0.01	Result
LEFT					
Uptake Ratio	18	15.74	0.418	3.499	Sig
%Max Accum	77.61	75.83	0.830	3.499	Sig
% Excretion	80.87	55.15	0.06793	3.499	Sig
RIGHT					
Uptake Ratio	17.66	16.52	0.802	3.499	Sig
%Max Accum	77.63	80.16	0.572	3.499	Sig
% Excretion	48.54	40.81	0.0082	3.499	Sig

TABLE 1: showing the Mean value of Uptake, Max Accumulation and Excretion in pre and post therapy scan of left and right parotid gland

SUBMANDIBULAR					
LEFT					
	Mean value Pre-therapy	Mean value Post-therapy	T TEST	T value at df 7 and P=0.01	Result
Uptake Ratio	13.28	15.55	0.313902	3.499	Sig
%Max Accum	67.38	56.17	0.343732	3.499	Sig
% Excretion	60.1	35.97	0.015576	3.499	Sig
RIGHT					
Uptake Ratio	12.16	13.56	0.63931	3.499	Sig
%Max Accum	57.42	56.48	0.901866	3.499	Sig
% Excretion	53.85	34.36	0.029044	3.499	Sig

TABLE 2: showing the Mean value of Uptake, Max Accumulation and Excretion in pre and post therapy scan of left and right submandibular.

Conclusion: The uptake capability of salivary glands is reduced in head and neck cancer post radiotherapy.

IAEA-CN-232/273

MCID: A Software Tool to Provide Monte Carlo Driven Dosimetric Calculations Using Multimodality NM Images

A. Vergara Gil¹, L.A. Torres Aroches¹, M.A. Coca Perez¹, M. Pacilio²,
F. Botta³, M. Cremonesi³

¹ Division of Clinical Research, CENTIS, Havana, Cuba

² Department of Medical Physics, Azienda Ospedaliera S. Camillo Forlanini, Rome, Italy

³ Division of Medical Physics, European Institute of Oncology (IEO), Milan, Italy

Corresponding Author: alexvergaragil@gmail.com

Background: We present a new software tool (named MCID) to calculate patient specific absorbed dose in molecular radiotherapy, based on Monte Carlo simulation.

Methodology: The inputs for MCID are two co-registered medical images containing anatomical (CT) and functional (PET or SPECT) information of the patient. The anatomical image is converted to a density map, and tissues segmentation is provided considering compositions and densities from ICRU 44 and ICRP; the functional image provides the cumulative activity map at voxel level. MCID creates an input file for Monte Carlo (MC) codes such as MCNP and GATE, and converts the MC outputs into an absorbed dose image.

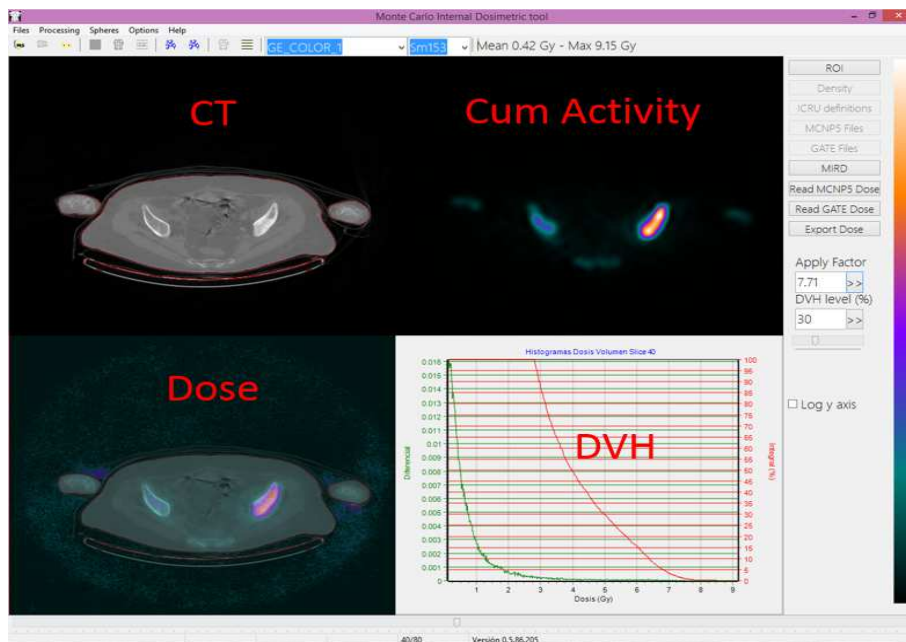


Fig 1. MCID, dose study stage, left-top CT image, right-top SPECT image, left-bottom dose image, right-bottom dose-volume histograms

Results: The developed tool allows to estimate dose distributions for non-uniform activities distributions and non-homogeneous tissues. It includes tools for delineation of volumes of interest, and dosimetric data analysis. Procedures to decrease the calculation time are implemented in order to allow its use in clinical settings. Dose–volume histograms are computed and presented from the obtained dosimetric maps as well as dose statistics such as mean, minimum and maximum dose values; the results can be saved in common medical image formats (Interfile, DICOM, Analyze, MetaImage). The MCID was validated by comparing estimated dose values versus reference data, such as gold standard phantoms (OLINDA’s spheres) and other MC simulations of non-homogeneous phantoms. A good agreement was obtained in spheres ranging from 1g to 1kg of mass and in non-homogeneous phantoms. Clinical studies were also examined. Dosimetric evaluations in patients undergoing ^{153}Sm -EDTMP therapy for osseous metastases showed non-significant differences with calculations performed by traditional methods. The possibility of creating input files to perform the simulations using the Gate Code has increased the MCID applications and improved its functionality. Different clinical situations including PET and SPECT images can be considered and evaluated using the developed tool.

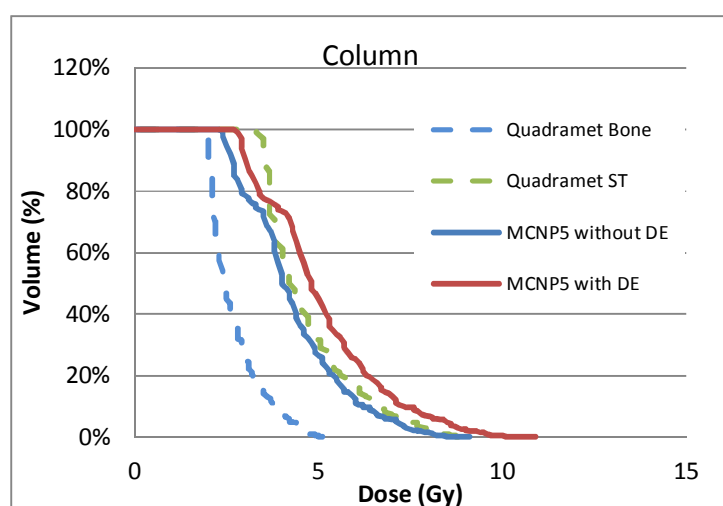


Fig 2. Comparison result for Column ROI using MCID with MCNP5 and a VSV methodology

Conclusion: MCID allows calculating accurately with acceptable running time, the patient specific 3D absorbed dose distributions during the radionuclide therapy of malignant diseases. The processed data showed encouraging results as to the potential use of MCID in the clinical practice.

IAEA-CN-232/274

Glomerular Filtration Rate (GFR) in Patients Taking Nephrotoxic Therapy

A.O. Osman

Nuclear Medicine Department, National Cancer Institute University of Gezira, Wad Medani, SUDAN

Corresponding Author: ahmedabdelbagio@yahoo.com

Background: An adequate method is important in assessing renal function in patients with renal disorder or taking nephrotoxic therapy. Glomerular filtration rate (GFR) is generally accepted as the most representative parameter of renal function. It is relatively constant under standard conditions. GFR is reduced prior to the onset of symptoms of renal failure, its assessment thus enables earlier diagnosis and therapeutic interventions in patients at risk.

The aims of this study were to evaluate the accuracy of different single plasma sample methods (SPSM) ^{99m}Tc-DTPA clearances, and to test if the SPSM can replace the dual plasma samples method (DPSM), in measurement of GFR.

Methodology: Four hundred and thirty subjects were included in this study, including renal patients and donors for renal transplantation (240 male, 190 female; mean age 43.40 ± 16.30 years). All subjects underwent dynamic renal scintigraphy after injection of ^{99m}Tc-DTPA. Three blood samples were taken; the GFR was calculated by seven SPSMs, in addition to DPSM as a reference. Each of SPSM clearances was compared with DPSM measurement. Mean \pm SD, the mean difference (bias), standard error, limits of agreements and correlation coefficient were calculated.

Results: There was a high correlation between all SPSMs and the DPSM; however, there is relatively low correlation coefficient (0.84) when comparing Ham and Piepsz's method (one of SPSMs). The limits of agreement (95%) were found between DPSM and all the SPSMs. Overall, the best method among SPSMs, which is closest to the DPSM, is Fleming's single method as it has statistically significant lowest mean difference (bias), lowest standard error, close mean \pm SD to the reference method, best limits of agreement and high correlation coefficient.

Conclusion: This study concludes that, among the SPSMs, Fleming's method can reflect GFR more accurately than other methods, particularly when the expected serum creatinine is normal. Standardized protocol for GFR measurement was done as a recommendation.

IAEA-CN-232/276

Surveillance of Papillary Thyroid Cancer Patients Who Received Empiric I-131 Therapy: Can Posttherapy Scanning Predict Response to Therapy and Final Outcome?

S. Caro¹, **A. Llamas-Olier**¹, **S. Menendez**²

¹ Instituto Nacional de Cancerologia

² Fundacion Santafe de Bogota

Corresponding Author: smcpmn@gmail.com

Background: Oftentimes patients with differentiated thyroid cancer will be diagnosed with persistently high thyroglobulin (Tg) levels after total thyroidectomy and I-131 ablation with no structural correlates. High Tg levels could be explained by residual or recurrent tumour, but could also be produced by already irradiated normal or tumour thyroid tissue destined to disappear in time without further treatment. If treated with empiric doses of I-131, the lack of abnormal uptake on post-therapy I-131 whole-body scans (pWBS) could further signify tumour dedifferentiation and predict disease progression, or small volume disease of debatable clinical significance. We evaluated if post empiric therapy whole-body scan (pWBS) results could predict the clinical outcome of patients with biochemical evidence of disease that had been empirically treated with I-131.

Methodology: The clinical charts of patients with papillary thyroid cancer (PTC) who received empiric I-131 therapy in our institution between 2003 and 2009 were reviewed. All patients had been treated with total thyroidectomy and I-131 ablation. The clinical indication for empiric I-131 therapy was a stimulated Tg ≥ 10 ng/ml obtained at some point during follow-up, more than 1 year after initial treatment, in the absence of structural disease on neck ultrasound, chest CT scan and other imaging methods freely ordered by treating physicians. We analysed pWBS results and compared them to the final outcome.

Results: 38 patients (84% women, 15% men; mean age, 42 years) were included. Mean stimulated Tg levels at the time of empiric therapy were 40.1 ng/ml \pm 51.39 ng/ml. The patients were divided into positive and negative pWBS for comparative analysis. Out of 23 patients (61%) with a positive pWBS, 8.7% evolved into a complete remission after treatment (stimulated Tg < 1 ng/ml and no structural correlates); 17.4% had biochemical persistence (stimulated Tg > 10 ng/ml and suppressed Tg > 1 ng/ml, no structural correlates); 69.6% had structural recurrence; 4.3% could not be classified. Fifteen patients (39%) had a negative pWBS: 20% evolved into a complete remission after treatment; 26.6% had biochemical persistence; 46.6% had structural recurrence; 6.6% could not be classified. Outcomes were not significantly different between groups ($p=0.54$). The time-to-final outcome was between 1 and 5 years (mean, 2.17 \pm 1.19 years) for patients with positive pWBS and between 1 and 8 years (mean, 1.86 \pm 1.8 years) for patients with negative pWBS. Complete remission took more time to develop than structural recurrence but there was no significant difference (mean, 3 \pm 2.8 vs 1.97 \pm 1.1, $p=0.12$).

Conclusion: We found no relation between pWBS results and final outcome. More than half of the patients eventually developed structural recurrence regardless of their pWBS results. Predictive factors to identify patients that could benefit from empiric I-131 therapy are still needed before recommending its use.

IAEA-CN-232/277

Case Report of an Extensive Neurolymphomatosis Highlighted by an 18F-FDG-PET/CT Imaging

L. Zaabar¹, N. Willems², C. Garcia²

¹ Institut Salah Azeiz. Tunis. Tunisia

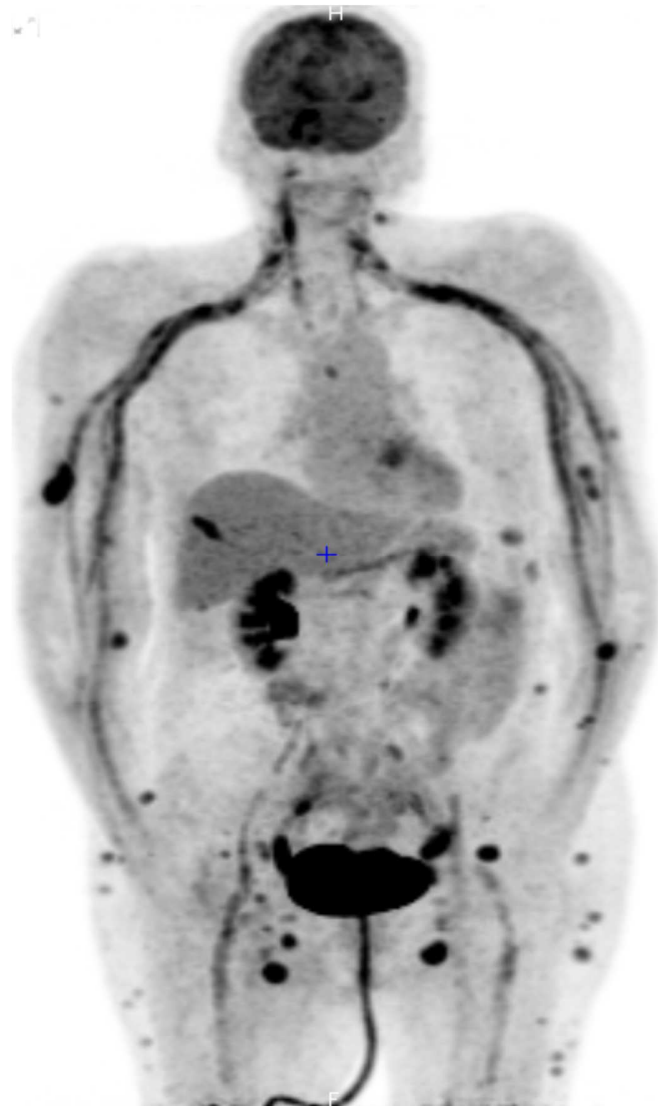
² Institut Jules Bordet. Brussels. Belgium

Corresponding Author: lamia_zaabar@yahoo.fr

Background: Neurolymphomatosis is a unique clinico-pathological entity, consisting of nerve infiltration by neurotropic neoplastic cells as part of unknown or known haematological malignancy. Nerve invasion may be unique or multiple, and can include cranial nerves, peripheral nerves or nerve roots. The main differential diagnosis remains sciatic nerve tumour. Functional imaging modalities including positron emission tomography/computed tomography are the key to accurate diagnosis. This report illustrates a spectacular case of neurolymphomatosis shown on an 18F-FDG PET/CT examination.

Methodology: We present a case of a 76-year-old woman, who was admitted for a rapidly progressive weakness associated with severe neuropathic pain. She was treated 7 years earlier with splenectomy and chemotherapy (cyclophosphamide) for a splenic marginal zone lymphoma. Six years after treatment, a recurrence of lymphoma (blastoid mantle cell lymphoma) was diagnosed. She received R-CHOP as well as intrathecal chemotherapy with cytarabine and methotrexate. After four months, she was in complete remission with no residual disease detected on 18F-FDG-PET/CT control examination. Four months later, she complained about progressive weakness in the left arm, followed within 3 to 4 weeks, by an important loss of strength in all four limbs, making self-care and unassisted walking impossible. At the admission, muscular strength was 0/5 in arms and 2/5 in legs. No positive muscle reflexes were objectified and all types of sensitivity were also affected, decreasing mainly in the upper extremities. Neuropathic pain was severe, refractory to usual pharmacologic treatment and required several medications, including high doses of morphine. Further biological and imaging investigations were to be performed.

Results: Brain MRI was normal as well as cerebral spinal fluid, but electromyography study demonstrated acute abnormal polyneuropathy. Anti-Hu, Ro and Ri auto-antibodies were not detected. An 18F-FDG-PET/CT was performed and showed bilateral uptake along brachial plexus and both sciatic nerves, in addition to diffuse hypermetabolic foci matching with few adjacent cutaneous nodules and small lymph nodes (supra and infra diaphragmatic), all compatible with lymphoma relapse and a very suspicious peripheral nerve tumoural involvement (neurolymphomatosis). Based on 18F-FDG-PET/CT findings, MRI of the brachial plexus showed marked thickening of whole nerve structure with enhancement after gadolinium injection. All these imaging findings were suggestive of an extensive neurolymphomatosis associated with recurrent systemic lymphoma. The patient was treated with etoposide, carboplatin, cytarabine and corticoids, with no significant response. Unfortunately, her neurological status further deteriorated and she died 2 months after the onset of her neurological symptoms (less than 10 month-median overall survival reported in literature), with a complete loss of muscular strength and sensitivity in the limbs and the upper body.



Conclusion: ^{18}F -FDG-PET/CT imaging is a reliable and strong tool in the detection of neurolymphomatosis. It resulted to be the most sensitive exam for this diagnosis. Early detection could contribute to prognosis enhancement.

IAEA-CN-232/278

18F-FDG PET/CT in Differentiated Thyroid Cancer, Usefulness in Clinical Decision Making

M.C. Martínez¹, C.A. De Los Reyes Victoria²

¹ Instituto Nacional de Cancerología Bogota Colombia

² Nuclear Medicine Physician Instituto Nacional Cancerología

Corresponding Author: mcris.martinez@gmail.com

Background: The aim of this study was to evaluate the clinical role of 18F-FDG PET-CT in detecting recurrent or metastatic lesions in patients with well-differentiated thyroid cancer who have elevated serum thyroglobulin level, and its usefulness in clinical decision making.

Methodology: A retrospective study was performed in National Cancer Institute, Bogota, Colombia in 27 patients with recurrent well-differentiated thyroid cancer, who underwent 18F-FDG PET-CT in our institute, from January 2012 to January 2015. These patients were previously treated with total thyroidectomy and iodine-131 therapy.

Results: 18F-FDG PET-CT was positive in 88% of patients evaluated. All these patients presented elevated serum thyroglobulin, but only 10 patients had negative I-131 body scans. The results of 18F-FDG PET-CT were correlated with conventional images, histopathological findings and clinical follow-up. The most common sites of metastases were in order: 1. neck, 2. mediastinum, 3. lung, 4. bone, 5. other. 18F-FDG PET-CT led to change in management, with different treatments such as surgery, radiation therapy and tyrosine kinase inhibitors.

Conclusion: 18F-FDG PET-CT is a valuable diagnostic tool for detecting recurrence in patients with differentiated thyroid cancer who have increased thyroglobulin levels and negative 131I whole body scan. 18F-FDG PET-CT assists in the clinical decision making process for therapy - either localized or systemic therapy.

IAEA-CN-232/279

PET Research in Brazil: How Are We So Far?

C. Wiefels¹, C. Mesquita²

¹ Universidade Federal Fluminense

² Hospital Universitario Antonio Pedro

Corresponding Author: chriswreis@gmail.com

Background: Positron emission tomography (PET) was introduced in Brazil in 1995, in São Paulo (Heart Institute-InCor). Currently, we have 433 nuclear medicine services, and amongst them, 101 PET machines. However, this technology is distributed unevenly across the country, with the highest concentration in the Southeast (most developed region). Although quantitative data on the distribution of nuclear medicine centres are available, little is known about the Brazilian scientific production.

Objective: To develop and evaluate a quali-quantitative matrix on the current landscape of the Brazilian scientific production in PET.

Methodology: We performed article searches in Pubmed, Scielo and Google Scholar databases, using the keywords "Positron Emission Tomography", "Tomografia por emissão de positrons" and "PET", which were crossed with "Brazil" or "Brasil". As inclusion criteria, publications should use PET, at least one of the authors being Brazilian and the research conducted in Brazil. Initially 418 articles were found, but only 100 met all the criteria. These were classified according to the region and State where the research was conducted, whether it was done in a public or private institution, whether it was an international cooperation, the radiopharmaceutical used and the journal's impact factor, according to ISI Web of Knowledge classification.

Results: Southeast region is responsible for the most part of the scientific production in PET field (87%), with São Paulo state having the largest share (65%), followed by Rio de Janeiro (32%). Sixty percent of the research was conducted in public hospitals, most of them university hospitals. Sixty different journals published the papers, 47 being non-Brazilian. Several magazines had no impact factor defined on the ISI. The highest impact factor was 17.96 (J Clin Oncol), and the second largest 5.80 (Eur J Surg Oncol). Amongst all magazines, the average impact factor was 1.80, and when considering only ISI classified magazines, 3.27. The main radiotracer used was F-18 FDG, in 87 articles, followed by F-18 NaF (n=5) and 11C-choline (n=2). Only one study employed Ga-68. The main areas of expertise were oncology (n=59), neurology (n=11), physics (n=7), cardiology (n=6) and rheumatology (n=5). Most articles were published in the last five years. Eleven articles were part of international cooperation research. The two main partner countries were the United States and Italy, with 5 and 3 publications respectively. Brazil has participated in International Atomic Energy Agency research on PET on three occasions.

Conclusion: The Brazilian scientific production in PET has been growing in recent years. However, the nuclear medicine sectors involved, especially public services, are concentrated in a restricted geographic region of the country. Oncology remains the main research field, reflecting the current world trends. Brazilian publications still have little visibility in the international scientific community, with few publications in relevant journals. However, the cooperation with other countries, although they are few, strengthens the image of Brazilian nuclear medicine in the area of PET around the world.

IAEA-CN-232/280

**Prognostic Value of $\alpha v\beta 3$ Integrin Ligand
[⁶⁸Ga] DOTA-E- [c (RGDfK)] 2 in Patients with
Non-Small Cell Lung Cancer**

**F.O. Garcia Perez, O. Arrieta, J.J. Del Real Rivas, Q. Pitalua,
I. Soldevilla Gallardo**

Instituto Nacional de Cancerologia

Corresponding Author: fosvaldogarcia@gmail.com

Background: Lung cancer is the main cause of cancer-related mortality worldwide, accounting for 1.38 million deaths (18.2% of all cancer-related deaths). One of the main characteristics of this disease is genetic and epigenetic alterations which induce an overgrowth of blood vessels and therefore an increased risk of progression of the disease. It has recently been shown that expression of adhesion molecules such as alpha (v) beta3 integrin, has a well-characterized involvement in tumour angiogenesis and invasiveness. The use of [⁶⁸Ga] DOTA-E- [c (RGDfK)] 2 to perform PET/CT scans, can identify global expression of these adhesion molecules.

The objective of this research was to correlate the progression-free period with integrin expression in patients with non-metastatic non-small cell lung cancer through the use of PET /CT with [⁶⁸Ga] DOTA-E- [c (RGDfK)].

Methodology: We included 24 patients (14 women, 10 men, average age 59.1 ± 12.3 years), all with stage IV non-small cell lung cancer. We evaluated progression-free survival after treatment with angiokinase inhibitors, during a follow-up period of 6 months. 20 patients had EGFR mutations (wild-type), 3 had exon 19 deletion, and one mutation in exon 21. Statistical methods included Kaplan-Meier curves and ROC curves.

Results: We analysed 28 pulmonary lesions, 20 nodes and 18 metastatic lesions in 24 patients. The mean maximum diameter of primary lesions was 54 mm +/- 12.3 mm, 12 mm +/- 0.43 mm in the lymph nodes and 26 mm +/- 0.8 mm in metastatic lesions. SUVmax values of the patient group with poor prognosis (progression) showed significant differences (3.24 ± 0.24) when compared with the patient group with stable disease or partial response (1.94 ± 0.22) with statistical differences ($p = 0.0002$).

The analysis of Kaplan-Meier curves showed a reduction in the progression-free period in patients with a SUVmax of the primary lesion larger than 1.8 ($P = 0.027$). There were no significant differences between SUVmax values of lymphadenopathy and metastatic lesions in both groups.

Survival proportions: Survival of Two groups

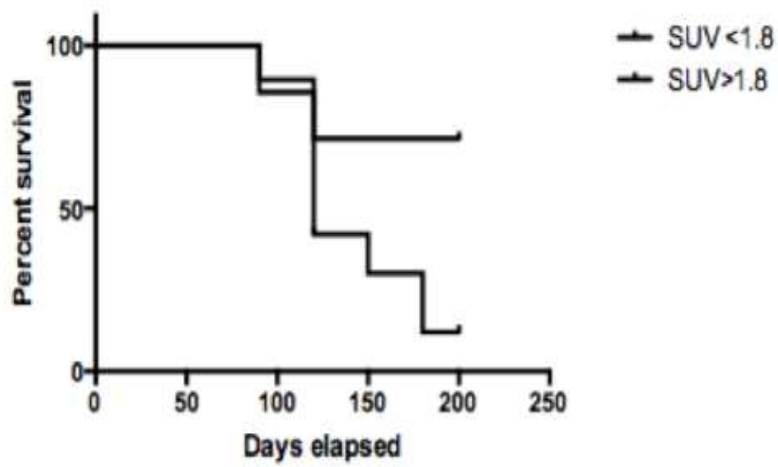


Figure 1: Kaplan Meier Curve Data

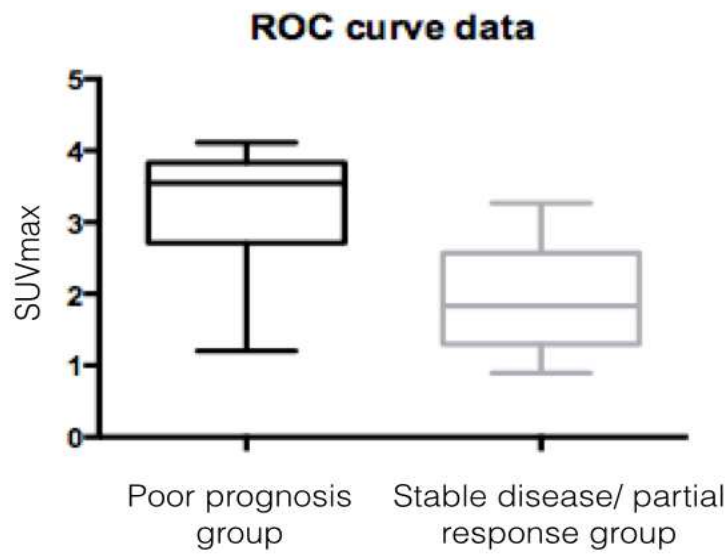
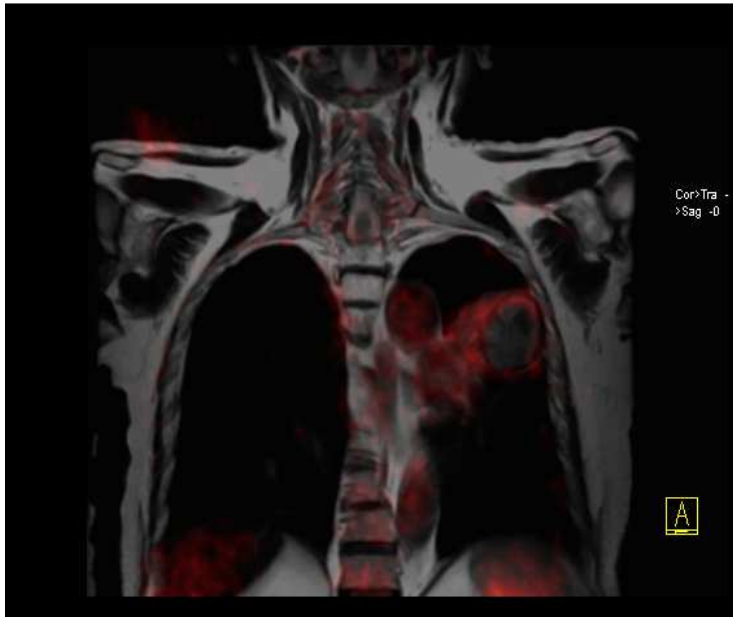


Figure 2: ROC Curve Data



Conclusion: The results of this study demonstrate that increased integrin expression quantified by the uptake of [68Ga] DOTA-E- [c (RGDfK)] 2 in the primary lesion, can predict the risk of subsequent progression after treatment with angiokinase inhibitors.

IAEA-CN-232/281

Developing ⁶⁸Ga-Labelled Neuropeptide Y (NPY) Nanoconstructs as Potential PET Imaging Radiopharmaceuticals

I.U. Khan¹, A. Shahid²; F. Ahmad², F. Iram³, M.S. Iqbal⁴

¹ Radiopharmacy and PET Radiochemistry Division, Institute of Nuclear Medicine and Oncology (INMOL), P. O. Box 10068, New Campus Road, Lahore-54600, Pakistan

² Institute of Nuclear Medicine and Oncology (INMOL), P. O. Box 10068, New Campus Road, Lahore-54600, Pakistan

³ Lahore College for Women University (LCWU), Jail Road, Lahore-54590, Pakistan

⁴ Forman Christian (FC) College, Canal Road, Lahore-54590, Pakistan

Corresponding Author: drirfankhan69@gmail.com

Background: The over-expression of neuropeptide Y1-receptors in human breast cancer leads to a potential application of selective neuropeptide Y (NPY) Y1-receptor ligands as a new generation of agents for cancer diagnosis and therapy. NPY-derived Y1-receptor ligands, e.g., ^{99m}Tc(core)³⁺-(N α His-ac)-labeled-[Phe⁷,Pro³⁴]NPY have been previously developed and investigated in vitro and in vivo. The preclinical and first clinical data of these ligands clearly indicate that the overexpression of the Y1 receptor in human breast cancer offers a unique possibility for tumour targeting by using NPY-derived Y1-receptor ligands and prompted us to develop peptide-based gold and silver nanoparticles, thus ultimately, resulting in highly specific radiolabeled nanoconstructs decorated with DOTA-NPY.

Methodology: For this purpose, we produced highly stable gold and silver nanoparticles (NPs) using arabinoxylan (AX) from ispaghula (*Plantago ovata*) seed husk. The NPs were synthesized by stirring a mixture of AX and HAuCl₄•H₂O or AgNO₃, separately, below 100°C for less than an hour, where AX worked as the reducing and the stabilizing agent. The synthesized NPs were characterized by surface plasmon resonance (SPR) spectroscopy, transmission electron microscopy (TEM), atomic force microscopy (AFM), and X-ray diffraction (XRD). In order to simulate the effect on binding towards Y1 receptors of ⁶⁸Ga- Lys(Ga-DOTA)₄,Phe⁷,Pro³⁴]NPY labeled nanoconstructs, we labeled [Lys(Ga-DOTA)₄,Phe⁷,Pro³⁴]NPY analog with nonradioactive gallium, e.g., ⁶⁹Ga and tested for binding to SK-N-MC cells. In vivo uptake of radiolabeled peptides was studied in various organs of normal rabbits after regular time intervals.

Results: The NPs were synthesized by stirring a mixture of AX and HAuCl₄•H₂O or AgNO₃. The particle size as determined by TEM (for silver: 5-20 nm and gold: 8-30 nm) was found to be dependent on pH, temperature, reaction time, concentration of AX and the metal salts used. The peptides were produced with the different labels as N α His-ac, or DOTA. The labels were introduced manually to the resin-bound peptides either at the N-terminus or at selectively de-protected Lys₄ side chain while peptides were still bound to the resin. The binding affinity in terms of pK_i value of [Lys(Ga-DOTA)₄,Phe⁷,Pro³⁴]NPY, to the NPY-Y1 receptors was 8.8 \pm 0.1. The biodistribution data showed a slower uptake with a significantly higher retention time, thus leading to sufficient renal excretion to allow absorption of the labeled compound into the tumour, with ultimately fast body clearance to avoid unspecific peptide accumulation.

Conclusion: In summary, this approach might be further extended to a tumour-specific targeting by using NPY derivatives for carrier of chemotherapeutic agents and might not be limited to breast cancer, because Y-receptor expression has been identified in other tumours, such as neuroblastoma, glioblastoma, ovarian adenocarcinoma, gastrointestinal stromal tumour, neuroblastomas, renal cell carcinoma, and pheochromocytoma; thus ultimately, could be used as a future tool for peptide receptor radionuclide therapy (PRRNT).

IAEA-CN-232/282

**18F- FDG PET-CT Imaging of Patients with Extra-Cranial
Primary Cancer: Routine or Elective Inclusion of Brain in the
“Whole Body” Protocol?**

N. Mkhize, M.T. Vangu, N. Muambadzi, N. Malan

University of the Witwatersrand

Corresponding Author: ntombifikile.mkhize@wits.ac.za

Background: Positron emission tomography–computed tomography (PET-CT) with F-18 fluorodeoxyglucose (FDG) has been shown to be a useful tool in the management of a wide variety of malignancies. Routinely whole-body PET-CT refers to the area between the base of skull and mid-thigh. The inclusion of brain varies from centre to centre and from malignancy to malignancy. In our department, brain imaging is included in melanoma and malignancies of the breast, lung and colon. Magnetic resonance imaging (MRI) is the imaging modality of choice for brain metastases detection and CT scan is an alternative. F-18 FDG PET is not ideal for this purpose, mainly because the grey matter is highly FDG avid due to the cerebral glucose metabolism. However with hybrid PET-CT this limitation may be overcome. The aim of this retrospective study is to determine the prevalence of unknown brain metastases that were detected by F-18 FDG PET-CT in patients imaged for staging, restaging and therapy assessment of melanoma, breast, lung and colorectal cancers.

Methodology: We retrospectively reviewed data of 381 patients with melanoma, breast, lung and colorectal cancers referred from November 2008 to January 2015. We included all patients who underwent the protocol that included brain imaging for the above-mentioned malignancies. The presence of brain metastases was diagnosed on the abnormal PET findings and confirmed on CT findings, or CT findings alone. The prevalence of detection of previously known and unknown brain metastases was determined. The clinical impact and change in management was evaluated by reviewing the clinical files of patients with brain metastases on 18F-FDG PET-CT.

Results: Patients' ages ranged from 16 to 87 years (mean age: 56.5). There were 144 males and 237 females. The overall detection rate of brain metastases was 13 patients out of 381 (3.4%). When excluding the cerebral metastases that were known prior to PET-CT imaging, the detection rate became 8 out of 376 (2.1%); for individual malignancies: melanoma 3.7%, colorectal 0%, lung 8% and breast 2%. All patients with brain metastases also had distant metastatic disease; either nodal, visceral or skeletal. There was obvious change in management in only two patients who underwent surgical resection and external beam radiation of the metastatic brain lesions, respectively. The rest had systemic chemotherapy, demised or lost to follow-up.

Conclusion: The findings discourage the routine inclusion of brain imaging in patients with colorectal cancer who are referred for 18F-FDG PET-CT imaging in our institution. The overall detection rate of unknown brain metastases was low (2%). Concomitant distant disease should raise the suspicion of presence of brain metastases, thus elective inclusion of brain images should be considered on a case per case merit in melanoma, breast and lung cancer.

IAEA-CN-232/283

PET/CT Imaging in Takayasu's Arteritis – Should It Be the Standard of Reference?

A.K Lawal, M.T.H. Vangu, A.B. Rahmani

Nuclear medicine and Molecular imaging, CM Johannesburg Academic Hospital, University of the Witwatersrand

Corresponding Author: dr.rahmani247@gmail.com

Background: Takayasu's arteritis (TA) is a chronic non-specific granulomatous vasculitis, commonly affecting the aorta and its main branches. It has a predilection for young females. The associated significant morbidity necessitates early diagnosis and aggressive treatment. Early diagnosis, however, is challenging as damage from previous episodes of vasculitis can produce symptoms that may be difficult to distinguish from symptoms of active vasculitis.

Laboratory investigations also have their own drawbacks especially because most markers do not appear to have the same predictive value as they do prior to treatment.

Biopsies have limited sensitivity due to sampling error and often have inconclusive findings. Thus, rapid, easy to perform, non-invasive tools with better sensitivity and specificity are becoming more popular in confirming disease activity in TA. These include angiography, computer tomography angiography (CTA), magnetic resonance angiography (MRA), all with inherent limitations.

18F-fluorodeoxyglucose positron emission tomography (18F-FDG-PET) is increasingly being utilised in the early diagnosis of TA, in monitoring of disease activity, as well as assessing response to treatment. The aim of this review was to assess the utility of 18F-FDG-PET in patients with Takayasu's arteritis, and to correlate the results with inflammatory markers.

Methodology: We retrospectively reviewed the data from 2008 to 2014 of patients referred for 18F-FDG-PET for either suspected Takayasu's arteritis or to confirm disease activity. A total of 37 scans were performed in 28 patients. The majority of our patient population had type IIb disease (9 patients); the rest having either type I disease (2 patients), type IIa (1 patient) or type V disease (4 patients). The 18F-FDG-PET results were also correlated with inflammatory markers. To our knowledge, this is the largest review to date.

Results: The youngest patient was merely 5 years of age, whilst the oldest was 72 years (median age 14 years). The vast majority of the scans were requested to assess disease activity (32 scans – 86%). For the other 5 scans (14%), the indication was to confirm the diagnosis of TA. Overall, 16/37 scans (43%) were positive for inflammation.

Of the total 37 18F-FDG-PET scans that were performed, only 10 patients had inflammatory markers tested within 6 months of the 18F-FDG-PET scans. This may suggest that clinicians are currently relying mainly on 18F-FDG-PET to assess the disease activity.

Furthermore, in the 10 patients with inflammatory markers, only in 2 patients the results correlated with the 18F-FDG-PET scan. In 3 patients whose 18F-FDG-PET scans were clearly positive for active disease, the inflammatory markers were normal. In half of the patients (5 patients) with negative 18F-FDG-PET findings, the inflammatory markers were raised.

Conclusion: 18F-FDG PET imaging plays a crucial role in the diagnosis and assessment of disease activity in Takayasu's arteritis. This modality should be used for effective management when it is available.

IAEA-CN-232/284

Integrated Modern Neuroimaging (NI) and Image-Guided Stereotactic Thermo/Radio Destruction in the Neurological Clinic of Metastatic Breast Cancer

E. Slobina, T. Dokukina

National Center for Mental Health

Corresponding Author: e.slobina@gmail.com

Background: The aim of this study is to report the results of clinical application of combined modern neuroimaging (NI) and linear accelerator (LINAC)-based stereotactic radiosurgery (SRS) vs. stereotactic thermodestruction (ST) in the neurological clinic of metastatic breast cancer and to evaluate the feasibility and tolerance of this type of local treatment.

Methodology: From March 2005 till February 2012, 7 female patients (pts), median age 54 years old, with generalized seizures were maintained on anticonvulsant therapy (enkorat chrono, valproat 600 mg/day), which led to a decrease in seizure frequency from 1 to 3 months up to 1 year. Four pts with undifferentiated scirrhus cancer of the breast, pT2N0M0, stage II, were treated by Madden mastectomy without further special cancer treatment. Due to frequent seizures of up to 2 per month, electroencephalogram (EEG) was prescribed and showed epileptiform activity (pointy alpha waves complexes sharp - slow wave bilaterally synchronous). Computer processing of files of 6 pts revealed abnormal EEG beta-focus and teta 2 index exceeding the limit value in the fronto-central lead (38.2 - 41.4). Consecutive MRI of the brain showed reduced metabolic activity (average V 10mm³) in the basal media department of the right (1 patient) and left (3 pts) temporal lobe anterior to the temporal horn of the lateral ventricle and the head of the hippocampus due to SRS exposure. SRS was performed on a system of stereotactic irradiation with conical collimators, mounted on a linear accelerator. The prescribed dose was 30Gy at the isocentre, in 1 fraction. 3 pts underwent ST of deep structures of the temporal lobes on both sides with an average temperature of 38.9 °C.

Results: The follow-up was 105 months. No signs of local tumour recurrence were found. After the SRS seizures stopped after 2-3 months. Brain MRI results – no tumour found - 3 pts, partial tumour regression - 1 patient, MR signs of post-treatment changes. Within 3 months, a reduction of pathological EEG pattern (beta focus disappeared; teta2 index fell to 23.6-18.4). Persistent clinical remission was achieved, and in 1 patient valproat dose was reduced, in 3 pts anticonvulsant therapy was stopped. ST seizures stopped after 3-5 months, and clinical neurological remission was present for 8 months when a resumption of seizures was noted.

Conclusion: Integrating modern methods of NI for LINAC-based SRS of solitary brain metastatic lesion within combined treatment of neurological pathology is an adequate management. LINAC-SRS can be used in certain clinical situations, especially in the absence of functional diagnostic methods such as PET/CT or PET/MRI, adequate surgical treatment, or ineffectiveness of other therapies. The proposed dose for SRS of a single brain metastatic lesion with a background of existing status epilepticus in a linear accelerator is feasible, well tolerated and can achieve local control of both the tumor and the neurological status and leads to persistent clinical neurological remission better and longer than ST.

IAEA-CN-232/285

**The Role of ⁶⁸Ga- DOTATATE PET/CT Imaging in Patients with
'Known' vs 'Suspected to Have' Neuroendocrine Tumours**

M.D.T.H. Vangu, K. Purbhoo, N.N. Mkhize, L. Louw, N. Malan, S. Dhooth

Nuclear Medicine and Molecular Imaging, CM Johannesburg Academic Hospital,
University of the Witwatersrand

Corresponding Author: mboyo-di-tamba.vangu@wits.ac.za

Background: Neuroendocrine tumours (NETs) constitute a heterogeneous group of tumours that arise from neuroendocrine cells. The diagnosis of these tumours is enhanced by the presence of some neuroendocrine markers, and the presence of chromogranin A seems to be at the centre of biochemical diagnosis. Functional imaging also plays an important role in the management of patients with NETs. Currently, the role of PET tracers for functional imaging in patients with NETs is well recognized. ⁶⁸Ga-DOTATATE is one of the most prominent radiopharmaceuticals used in imaging neuroendocrine lesions that may overexpress somatostatin receptors.

Methodology: We retrospectively reviewed patients referred from September 2010 to October 2014 for PET/CT imaging with ⁶⁸Ga-DOTATATE for the diagnosis, staging or restaging of NETs. All images were evaluated visually and the maximum standardized uptake value (SUVmax) was used for quantification of the tumour activity.

Results: There were 133 patients, 85 were females (63.91%) and 48 were males (36.09%), and their ages ranged from 4 to 85 years old (mean: 53.32 +/-15.03). The indications for referral were as follows: diagnosis (36%), staging (22%) and restaging (42%). Positive imaging findings were seen in 56% of patients, negative findings in 42% and equivocal findings were seen in 2% of patients. No significant correlation but only a trend (p=0.06) was found between positive biomarkers and positive imaging findings (Chi-Square and Fisher's Exact Test). A significant difference was noted in positive imaging findings between patients with NETs (79%) and those with suspected NETs (20%), [p<0.001].

Conclusion: ⁶⁸Ga-DOTATATE PET/CT imaging appears to be a good metabolic imaging modality in patients with known NETs. In this review, the imaging modality did not perform well when there was only a suspicion of NET.

IAEA-CN-232/286

Biological Target Volume Segmentation for Gamma Knife Treatment

C. D'arrigo¹, M. Ippolito¹, A. Stefano²; G. Russo³, S. Vitabile⁴, F. Marletta¹

¹ Cannizzaro Hospital, Catania

² IBFM-CNR; DICGIM University of Palermo

³ IBFM-CNR

⁴ DIBIMEF, University of Palermo

Corresponding Author: alessandro.stefano@ibfm.cnr.it

Background: The Leksell Gamma Knife is a radio-surgical device used to treat brain disorders. The stereotactic radio-surgery allows in a single session accurate external irradiations with high dose and a sharp dose gradient to minimize radiation doses given to adjacent critical brain structures.

Nowadays, the target for the treatment is identified on magnetic resonance imaging (MRI), without providing the biological and molecular characteristics of tumor tissue. For this reason, the metabolic imaging, as positron emission tomography (PET), has to be considered to improve treatment planning for high precision radiotherapy. Nevertheless, lesion volume delineation of ¹¹C-labelled methionine (MET) PET images is challenging because of the low spatial resolution, and high noise level. To date, the biological target volume (BTV) is manually contoured: a slice-by-slice manual segmentation is a time expensive and operator-dependent approach. Aim of this work was the development of an automatic operator independent (OI) method for the BTV delineation to Gamma-Knife treatment.

Methodology: An algorithm based on random walks (RW) on graphs has been adapted for PET image delineation. This method represents an image as a graph in which the voxels are its nodes and the edges are defined by a cost function which maps a change in image intensity to edge weights. Then, RW partitions the nodes into lesion and background subsets. To create an OI method starting from previous work, the algorithm identifies the PET slice with the highest standardized uptake value (SUV_{max}) and a maximum of 10 target and 8 background seeds for each volume slice. The voxels with a SUV > 95% of SUV_{max} are marked as target seeds. Then, the method explores the hottest voxel neighborhood through searching in 8 directions to identify the voxels with a SUV < 30% of SUV_{max} (background seeds). Once the foreground and background seeds are localized, RW performs a 3D lesion delineation. The segmentation performance of the proposed method was evaluated making a comparison with manual BTV delineation by the dice similarity coefficient (DSC) and median Hausdorff distance (HD). Ten patients underwent a MET-PET examination: an expert radiation oncologist included the tumour area with an intense tracer uptake respect to background MET activity level.

Results: The BTV delineation was not subject to either intra or inter-operator variability. The DSC range of PET delineation using the RW algorithm was found to be from 84.9% up to 92.6% with a mean of $89.13 \pm 2.64\%$. The HD range was found to be from 1.00 mm up to 2.84 mm with a mean of 1.81 ± 0.55 mm.

<i>Patients</i>	<i>DSC(%)</i>	<i>HD(mm)</i>
#1	87.0	2.84
#2	84.9	2.46
#3	92.6	1.82
#4	90.1	1.55
#5	92.1	1.00
#6	91.3	1.92
#7	87.0	1.49
#8	90.7	1.76
#9	89.1	1.17
#10	86.5	2.05
Mean±STD	89.13±2.64	1.81±0.55

Conclusion: Results show that our algorithm is an OI method, satisfying a critical requirement in clinical environment. In addition, high DSC and low HD values confirmed the accuracy of delineation method.

IAEA-CN-232/287

Diagnostic Possibilities of Multimodality Imaging in Cardiological and Neurological Clinic of Metastatic Colon Cancer

E. Slobina¹, N. Maroz-Vadalazhskaya²

¹ National Center of Mental Health of Belarus

² ASNC

Corresponding Author: e.slobina@gmail.com

Background: Due to lack of PET/CT in our country the use of fusion EEG, US, MRI or CT is of particular importance, especially in multiple tumour cases.

Methodology: Here we present a case report. Since November 2010 a 37-year-old female patient underwent: 1) surgical treatment for thyroid cancer, pT2N0M0, I stage; 2) complex treatment for colorectal cancer, pT3N2M1, IV stage and session of stereotactic radiosurgery (SRS) due to multiple brain metastases; 3) setting of pacemaker for concomitant diagnosis as myocardial dystrophy of complex genesis, transient AV block III stage in syncope. There was severe pain syndrome due to brain metastasis near the VII nerve treated by narcotic analgesia and generalized seizures treated by anticonvulsant therapy.

Results: Due to frequent seizures of up to 2 per month, an electroencephalogram (EEG) was prescribed and showed epileptiform activity (pointy alpha waves complexes sharp - slow wave bilaterally synchronous). Computer processing of the file revealed abnormal EEG beta-focus and index teta2 activity exceeding the limit value in the fronto-central lead - 38.6. Consecutive MRI of the brain revealed metabolic activity (average V 14 mm³) in the basal media department in both the temporal lobe anterior to the temporal horn of the lateral ventricle as well as the head of the hippocampus due to SRS exposure. Transthoracic echocardiography in 2D with 3D reconstruction was applied using an ultrasound machine with 1-5 MHz probes. Ventricular wall was composed of normal myocardium (anterior wall and antero-lateral segments of left ventricle and anterior wall of right ventricle) and tissue of higher density, abnormal structure, postero-lateral spreading and intracavitary growth with extremely decreased right ventricle volume. Echo signs of neotissue capsule or extracardiac growth were not found.

MRI investigation with gadolinium enhancement was performed. Large intramural masses in area of intraventricular septum, posterior wall of both ventricles with abnormal shape and small volume of the right ventricle cavity were revealed. These data corresponded to the data of US investigation and have clearly shown a tumour of myocardium with intramural and intracavitary growth, which could not be operated by open-heart techniques.

Conclusion: Multimodality imaging plays an increasingly important role in delivering personalized care to cancer patient. In cases of multiple tumour lesions of various organs and tissues, they are particularly important methods of functional diagnostics, such as PET/CT and PET/MRI, because they can be used to assess whole body status. Combined EEG/MRI and US/MRI imaging for cancer patients are useful diagnostic option for brain metastasis and heart tumor in the absence of PET/CT.

IAEA-CN-232/288

Influence of 18F-FDG-PET/CT on Radiation Therapy Planning in Patients with Non-Small Cell Lung Cancer

P. Povinec¹, A. Masaryková², D. Šćepanović², M. Pobjíáková², A. Masaryk¹

¹ BIONT PET Center, Bratislava, Slovakia

² Dept. of Radiation Oncology, National Oncology Center, Bratislava, Slovakia

Corresponding Author: povinec@biont.sk

Background: Radiotherapy (RT) is an important treatment modality in locally advanced or inoperable non-small cell lung cancer (NSCLC). The immediate vicinity of the target volumes and radiosensitive organs endangers patients with acute and chronic toxicity. 18F-FDG-PET/CT can be used for imaging of the viable tumour tissue with the potential for better targeted treatment.

The primary goal of the study was to compare the definition of delineation of irradiation target volumes using CT and PET/CT in patients with NSCLC. The secondary goal was to determine the influence of the PET/CT planning on the radiation dose delivered to the surrounding lung tissue.

Methodology: There were 25 patients with histologically confirmed NSCLC scheduled for treatment with definitive RT. The patients were scanned in the same therapeutic position on the localisation CT and on the PET/CT. All patients underwent 3D conformal RT, the mean total dose was 66 Gy. In all patients we compared 2 treatment plans (CT and PET/CT) in regard to gross tumour volume (GTV), planned target volume (PTV), mean lung dose (MLD) and the volume of lung tissue with dose ≥ 20 Gy (V20).

Results: The influence of PET on the observed parameters was as follows: GTV reduction in 10/25 (40%), increase in 13/25 (52%), no change in 2/25 (8%), PTV reduction in 68%, increase in 28%, no change 4%, MLD reduction in 64%, increase in 20%, no change in 16%, V20 reduction in 68%, increase in 20%, no change in 12%. In 4 patients PET/CT changed the treatment strategy from radical to palliative due to previously unknown distant metastases.

Conclusion: PET/CT demonstrated influence on the radiation treatment planning with more precise delineation of irradiation volumes (increase in for example inclusion of infiltrated lymph nodes, decrease in exclusion of atelectatic tissue). In a significant number of patients there was a reduction of the volume of irradiated lung tissue, with the supposed decrease of treatment complications. The combined 18F-FDG-PET/CT examination can be used in place of the stand-alone planning localisation CT in the RT planning of patients with NSCLC.

IAEA-CN-232/289

68-Ga-DOTATATE PET/CT in Insulinoma Detection

A. Banchemo, J. Gaudiano

CUDIM

Corresponding Author: [javier.gaudiano@cudim.org](mailto:javier.gaudiano@ cudim.org)

Background: Insulinoma is the most common cause of endogenous hypoglycemia in non-diabetic patients, being also the most prevalent pancreatic endocrine tumour.

Due to their small size, the localization with imaging methods is very limited and has been controversial. Most of them are histo-pathologically “benign” but physio-pathologically very aggressive due to the abnormal hormone production. Surgical resection is the only curative treatment, accurate detection and anatomic localization being extremely important for surgical strategy planning.

The aim of this work was to determine the sensitivity of 68Ga-DOTATATE in preoperative diagnosis of suspected insulinomas at CUDIM (Uruguayan Centre of Molecular Imaging).

Methodology: We retrospectively analysed the data of patients with suspected insulinoma between July 2010 and July 2014. Ten patients (5 women, 5 men) with a mean age of 50 years (19-76y) were studied. PET/CT was performed 30 minutes after the radiotracer injection.

Results: Positive diagnosis for definite insulinoma was performed in 4/10 patients, probable insulinoma in 4/10 patients and a negative result was observed in 2/10 patients. The mean clinical follow up was 23 months (7-49m). Positive confirmation for insulinoma was found in 100% of the patients reported as positive or probable. Surgical resection was made in all of them, with the exception of one patient who died and another who is scheduled for surgery. All patients who underwent surgery have remained asymptomatic, euglycemic and currently free from recurrence.

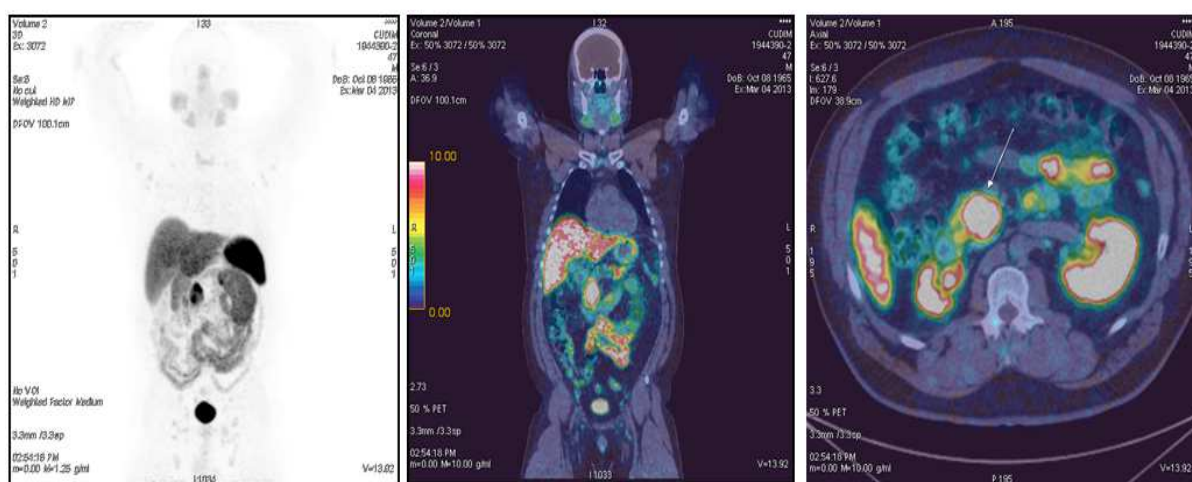


Figure 1: Coronal and axial views of pancreatic tumour (insulinoma) with 68Ga-DOTATATE

Conclusion: We can conclude that ^{68}Ga -DOTATATE PET/CT imaging is a helpful non-invasive diagnostic tool for the diagnosis and preoperative localization of insulinomas contributing to successful surgical treatment.

IAEA-CN-232/290

11C-Methionine and 18 F-FMISO in the Diagnosis, Surgery and Radiotherapy Planning of Patients with Glioblastomas

C. Bentancourt, G. Lago, A. Quagliata, Adriana, R. Castro, Richard, A. Damian, H. Engler

CUDIM

Corresponding Author: [cecilia.bentancourt@cudim.org](mailto:cecilia.bentancourt@ cudim.org)

Background: Glioblastomas have increased capacity of proliferation and high invasive potential. Molecular imaging helps to detect and localize the lesions, define target areas for biopsies, plan surgical and radiation interventions and assess tumour progression and treatment outcome.

The use of the multi-tracer concept takes a central role in the diagnosis, treatment and follow up of these tumours providing new specific information to guide the clinical management.

It has been shown that:

1. In the brain, 11 C-methionine (11C-MET) is more sensitive and precise than 18F-FDG to quantify tumour metabolism in proliferative cells compared to non-proliferative cells.
2. 11C-MET also differentiates viable or recurrent brain tumour from fibrotic post-radiation changes.
3. 18F-Fluoromixonidazole (18F-FMISO) detects hypoxic areas in the tumour that indicates treatment resistance leading to tumour progression. If the tumour does not have a hypoxic component the response to radiotherapy is better. The detection of hypoxic areas may guide the surgical approach as well as the radiotherapy treatment. This information is not provided by other imaging techniques.

The objective of this study is to report the first case studies in our centre using multi-tracer neuroimaging for assessing glioblastomas after surgery.

Methodology: Two patients with glioblastoma were studied after surgery after suspected recurrence.

The first study was performed after injection of 3MBq/Kg of 11C-MET. A PET/CT scan in dynamic mode for 35 minutes was performed immediately after the i.v injection. The "hot spot" including the 4 pixels with higher uptake was compared with the contralateral normal cortex.

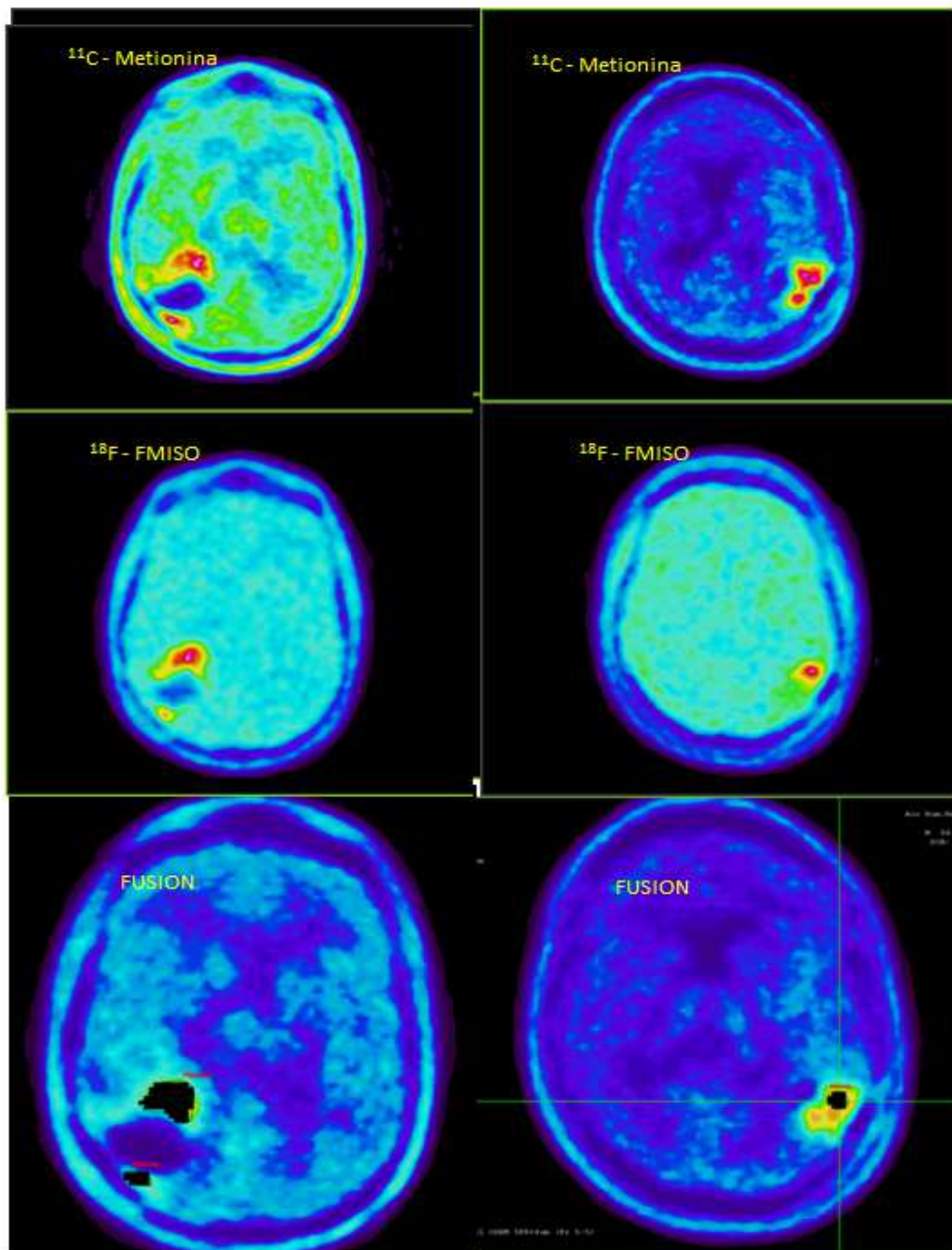
Estimation of the physiological volume of the tumour was done using a method described in the Uppsala PET Centre (Ribom, Engler).

On the second day, 6 MBq-Kg 18F-FMISO were injected to the patients i.v and a scan was performed 3 hours post injection.

The same methodology as described above was used for the determination of the 18F-FMISO volumes.

Overlapping of the two images obtained resulted in compiled information of the tumour characteristics provided separately by each tracer.

Results: Comparison of two patients studied with 11C-MET (images above) and 18F-FMISO (below). In case 1, a poor response to radiotherapy due to the extensive hypoxic area is predicted and in the second case an acceptable response due to the smaller area.



Conclusion: We report our preliminary experience in 2 adult patients with glioblastomas assessed with a multi-tracer approach after surgery. The overlapping of multi-tracers images allows for a better understanding of the biology of the tumour and helps clinicians to better plan surgery and radiotherapy.

IAEA-CN-232/291

The Role of 68Ga-DOTATATE PET/CT Imaging in Treatment Plan Change in Patients with Neuroendocrine Tumours

E. Skoura¹, E. Panagiotidis¹, O. Almukhailed¹, M.E Caplin²; I. Kayani¹, R. Syed¹, S. Michopoulou¹, A. Alshammari¹, J. Bomanji¹

¹ Nuclear Medicine Department, University College Hospital, London

² Neuroendocrine Tumour Unit, Royal Free Hospital, London

Corresponding Author: lskoura@yahoo.gr

Background: 68Ga-DOTATATE PET/CT is a well-known imaging modality for neuroendocrine tumors' (NET) staging, restaging and follow-up. This study evaluates the role of 68Ga-DOTATATE PET/CT scan to influence management decisions in patients with NETs.

Methodology: Data from NET multidisciplinary team (MDT) minutes, patient discharge summaries and correspondence was reviewed to evaluate the influence of 68Ga-DOTATATE PET/CT scan on patients' treatment plan.

Results: 980 68Ga-DOTATATE PET/CT scans were performed in 651 patients with NETs, for initial staging, restaging, recurrence detection or follow-up. The findings of 68Ga-DOTATATE PET/CT scans changed the patients' treatment plan in 393 cases (40%). The change in therapeutic management consisted mainly of resection of a previously unknown primary tumour, curative lymph node or solitary metastasis resection, initiation of chemotherapy or PRRT due to recurrence, change to chemotherapy instead of surgery due to progressive or systemic disease, change in PRRT instead of chemotherapy due to intense tracer avidity or use of additional treatment such as radiotherapy. The most frequent management change was observed in lung NET, 45.2%. The percentage of management decision change was also 41.4% for midgut tumours, 42.2% for pancreatic NET, and 42.5% for thyroid primary. In patients with unknown primary malignancy the change in treatment plan was quite low, 37.3%.

Conclusion: This study shows that 68Ga-DOTATATE PET/CT scan can change the patients' treatment plan in a significant percentage, irrespectively of the location of the primary.

IAEA-CN-232/292

**Added Advantages of New Nuclear Medicine
Radiopharmaceuticals – A Short Neuroendocrine Tumor Series**

**T.N. Silva¹, J.P. Teixeira², C. Oliveira³, J. Castanheira³,
H. Duarte², D. Costa³, J. Portugal¹, A.I. Santos⁴, J.G. Santos⁴**

¹ Serviço de Endocrinologia; Hospital Garcia de Orta, E.P.E.

² Serviço de Medicina Nuclear, IPO Porto, E.P.E.

³ Champalimaud Centre for the unknown, Champalimaud Foundation

⁴ Serviço de Medicina Nuclear, Hospital Garcia de Orta, E.P.E.

Corresponding Author: foss.jakomo@gmail.com

Background: Neuroendocrine tumours (NET) are a distinctive group of neoplasms originating from endocrine cells situated in multiple anatomical locations. These tumours have the unique characteristic of expressing somatostatin receptors, which provide a very convenient target for tumour detection. Functional imaging has been essential for the evaluation of patients with NET by means of the somatostatin receptor scintigraphy, performed with somatostatin analogues labeled with either Indium-111 or Technetium-99m. However, despite its advantages there was a need to improve the method, both in sensitivity and in resolution. Somatostatin receptor PET/CT, using ligands with higher affinity for somatostatin receptors labeled with Gallium-68 is expected to bring improvements in both sensitivity and resolution.

Methodology: We present a short series of six patients diagnosed with NET, who were evaluated with a multitude of both anatomical and functional methods, namely both somatostatin receptor scintigraphy and somatostatin receptor PET/CT. We compare the diagnostic yield of both methods and discuss the possible clinical impact of added somatostatin receptor PET/CT findings.

Results: We present the clinical cases of six patients, two with jejuno-ileal NET, two with ectopic Cushing syndrome (presumably due to a pancreatic NET), one with a pancreatic NET in the context of MEN1 syndrome and one with a poorly differentiated neuroendocrine carcinoma. Anatomical tests (abdominal CT and MRI and pancreatic CT, MRI and endoscopic ultrasound) were negative in four patients, identified isolated hepatic metastases in one and documented extensive secondary involvement in another. Both functional methods were negative in two patients. In the other four, namely enteropancreatic NET, somatostatin receptor scintigraphy detected possible primary lesions in two patients, which were confirmed by somatostatin receptor PET/CT. Somatostatin receptor PET/CT identified more lesions than somatostatin receptor scintigraphy in three patients, especially small tumours in unsuspected anatomical locations. It was also the only method to document the primary lesion in the terminal ileum in one patient with hepatic metastases (Figure 1). The patient with poorly differentiated neuroendocrine carcinoma also underwent 18F-FDG-PET/CT which demonstrated hypermetabolism in some secondary lesions while somatostatin receptor scintigraphy and PET/CT identified somatostatin receptors in others; a fact demonstrating significant heterogeneity in the tumoural cell population and the complementary nature of these methods.

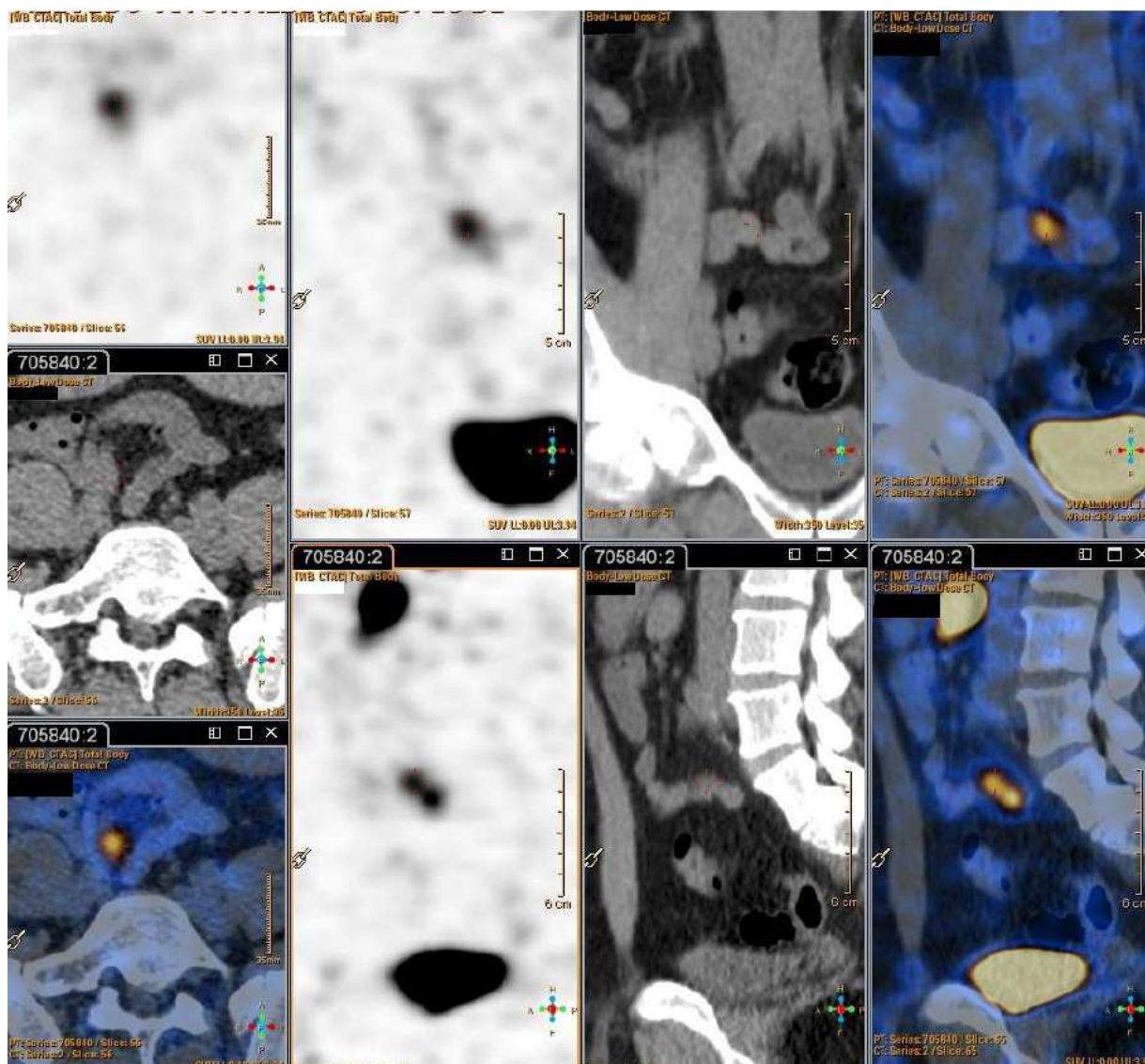


Figure 1: A previously elusive primary lesion detected by somatostatin receptor PET/CT in the terminal ileum in a patient with NET hepatic metastases

Conclusion: Functional imaging is the cornerstone for the evaluation of patients with NET. However, traditional somatostatin receptor scintigraphy is still lacking in both sensitivity and anatomical resolution. Somatostatin receptor PET/CT addresses these shortcomings. Even considering the small size of this series, it helped stage more accurately half of the patients, both by detecting more lesions in multiple anatomical locations and by identifying a previously elusive primary lesion. This information is helpful not only in staging the disease but also for programming further therapeutic actions. Therefore, somatostatin receptor PET/CT should be given special consideration in the evaluation of patients with clinically complex NET.

IAEA-CN-232/293

Combined Multimodality Modern Neuroimaging (NI) and Image-Guided Thermo/Radio Destruction in the Treatment of Epilepsy

T. Dokukina, E. Slobina

National Center for Mental Health

Corresponding Author: e.slobina@gmail.com

Background: We report the results of clinical application of combined modern neuroimaging (NI) and linear accelerator (LINAC)-based stereotactic radiosurgery (SRS) vs. stereotactic thermal destruction (STD) in the treatment of epilepsy and evaluate the feasibility and tolerance of this type of local treatment.

Methodology: Since March 2003 till February 2014, 14 patients (pts), 1:4 ratio female/male, median age 45 years old, with generalized seizures were being treated with anticonvulsant therapy (enkorat chrono, valproat 600 mg/day), which led to a decrease in seizure frequency from 1 to 5 months up to 1 year; 4 pts with brain trauma in the past were treated by neurosurgery. Due to frequent seizures of up to 2-4 per month, an electroencephalogram (EEG) was prescribed and showed epileptiform activity (pointy alpha waves complexes sharp - slow wave bilaterally synchronous). Computer processing of the files all of pts revealed abnormal EEG beta-focus and index teta2 activity exceeding the limit value in the fronto-central lead (38.6- 41.8). Consecutive MRI+MR spectroscopy of the brain revealed metabolic activity (average V 10mm3) in the basal media department of the right (3 pts) and left (11 pts) temporal lobe anterior to the temporal horn of the lateral ventricle and the head of the hippocampus due to SRS (7 pts – 1 group) or thermal destruction (7 pts – 2 group). SRS was performed on a system of stereotactic irradiation with conical collimators, mounted on a linear accelerator. The prescribed dose was 24-30Gy at the isocentre, in 1 fraction. 7 pts underwent STD of deep structures of the temporal lobes on both sides with average temperature of 39.1 degrees celcius.

Results: The follow-up was 126 months. After the SRS seizures stopped after 2-3 months. Brain MRI results: MR signs of post-treatment changes. Within 3 months: reduction of pathological EEG pattern (beta focus disappeared, teta2 index fell to 23.2-18.1). Persistent clinical remission was present. 1 group: 4 patients - dose reduction of enkorat chrono, 3 pts - anticonvulsant therapy taken out. After STD in 6/7 pts seizures stopped after 3-6 months, clinical neurological remission was achieved for an average of 9 months with a higher resumption of seizures.

Conclusion: The proposed dose level SRS in a linear accelerator or STD of epileptic lesions with a background of the existing status epilepticus is feasible, well tolerated and can achieve local control of the neurological status using the combined data of NI. Persistent clinical neurology remission is longer and better after SRS in comparison with STD, with a higher resumption of seizures after treatment with STD. In the absence of the possibility of functional diagnostic methods as PET/CT or PET/MRI and ineffectiveness of other therapies, combining modern methods of NI for treatment of epilepsy by SRS or STD within the context of combined neuropathological treatment supports diagnostic and treatment planning purposes. LINAC-SRS can be used in certain clinical situations.

IAEA-CN-232/294

Influence of 68Ga-DOTATATE PET/CT Imaging in the Decision of Peptide Receptor Radionuclide Therapy (PRRT) Administration

E. Skoura¹, E. Panagiotidis¹, O. Almukhailed¹, M.E Caplin²; I. Kayani¹, R. Syed¹, S. Michopoulou¹, A. Alshammari¹, J. Bomanji¹

¹ Nuclear Medicine Department, University College Hospital, London

² Neuroendocrine Tumour Unit, Royal Free Hospital, London

Corresponding Author: lskoura@yahoo.gr

Background: Peptide receptor radionuclide therapy (PRRT) consists of the systemic administration of a synthetic peptide, labeled with a suitable β -emitting radionuclide, able to irradiate tumours and their metastases. PRRT, with either 90Y-octreotide or 177Lu-octreotate, has established to be an efficient and effective therapeutic modality that provides objective responses in neuroendocrine tumours (NET), and is well tolerated with moderate toxicity. This study was performed to reveal if 68Ga-DOTATATE PET/CT can influence the decision of PRRT administration in NET patients.

Methodology: Data from patients with NET who received PRRT or were candidate for PRRT were analysed.

Results: Between 25/5/2005 and 19/8/2013, 1246 68Ga-DOTATATE PET/CT scans were performed in patients with confirmed or suspected NET. In 13.4% of these cases (in 167 cases, from 122 patients), radioisotope therapy, either as PRRT- 177Lutetium (177Lu)-DOTATATE/ 90Yttrium (90Y)-DOTATOC or 131MIBG was received after 68Ga-DOTATATE PET/CT scans. In this patient group, PRRT was decided as new treatment in 85 cases (6.8% of the total cases). In these 85 cases, 68Ga-DOTATATE PET/CT imaging showed extensive unresectable and/or metastasized disease with intense 68Ga-DOTATATE uptake. On contrary, in two cases (0.2%) the PRRT was rejected as treatment because of the low tracer uptake. In detail, 177Lu-DOTATATE was administrated in 44 cases, 90Y-DOTATOC in 23 cases, while in 18 cases the given radiopharmaceutical for PRRT is not known to us (177Lu-DOTATATE or 90Y-DOTATOC). Finally, in 4 cases 131MIBG was administered, as the MIBG uptake in diagnostic 123I-MIBG scan, was more intense than the 68Ga-DOTATATE uptake in 68Ga-DOTATATE PET/CT scan.

Conclusion: PRRT is an established treatment in patients with advanced and/or progressive NET. It is known that the 68Ga-DOTATATE PET/CT imaging is necessary prior to PRRT in order to target the somatostatin receptors. Our study reveals that PRRT could be decided as a new treatment in a significant percentage of NET patients, when 68Ga-DOTATATE PET/CT scan shows extensive unresectable and/or metastasized disease with intense uptake.

IAEA-CN-232/296

A Novel Brain Imaging Agent for Diagnosis of Alzheimer's Disease; ^{99m}Tc -BH

**F.Z.B. Muftuler¹; A. Kilcar¹, V. Evren¹, E.I. Medine¹, V. Tekin²;
P. Unak¹**

Ege University, Institute of Nuclear Sciences, Department of Nuclear Applications, Izmir, Turkey

Corresponding Author: fazilet.zumrut.biber@gmail.com

Background: Recently, development of novel brain imaging agents for assessing the blood-brain barrier (BBB) has attracted much interest due to the limited number of brain imaging agents and the lack of Alzheimer's disease (AD) diagnostic agents. Despite the fact that this chronic and progressively neurodegenerative disorder affects a wide audience, definitive diagnosis of AD still requires post-mortem examination of the brain through histological staining of amyloid plaques and neurofibrillary tangles, which are two hallmarks of AD pathology. Early recognition of the condition has important benefits in planning treatment strategies and yet, early stage dementia is often unrecognized or misdiagnosed. Scans using conventional imaging techniques and nuclear medicine brain imaging techniques are not specific yet. We sought to elucidate the diagnosis of AD by designing amyloid probes that could be used to measure brain amyloid noninvasively by single photon emission computed tomography (SPECT). In addition, deficiency of AD diagnostic agents and limitation of assessing the BBB are the main reasons of the current research focusing on brain agents with plaque or tangle imaging potential. Metal-protein attenuating compounds (MPACs) such as clioquinol and cloxyquin have a great increasing potential for amyloid plaques.

Methodology: A novel radiolabeled agent, ^{99m}Tc -Bioquin-HMPAO (^{99m}Tc -BH), that overcomes impositions of the BBB was synthesized. BH was characterized utilizing FTIR and LC-MS methods. BH was radiolabeled with ^{99m}Tc and quality control of radiolabeled compound is carried out with solvent extraction method. Additionally, in vitro stability and lipophilicity of ^{99m}Tc -BH was performed. In accordance with the objectives of the study, animal model of AD created in healthy male Sprague Dawley rats with intra-hippocampal stereotaxic injection of amyloid beta 1-42 ($\text{A}\beta$ 1-42). Nissl staining for animal model of AD was performed. All animal experiments were carried out under the approval of the relevant Institutional Animal Review Committee of Ege University, (Number: 2010-155) Izmir, Turkey.

Results: The radiolabeling yield and the radiochemical purity (RCP) of ^{99m}Tc -BH were over 95 %. Stability of the complex was appropriate for imaging period. Bioaffinity of the complex, ^{99m}Tc -BH, was investigated on male Balb/c mice at various time points post-injection. Regions of the brain had uptakes over 4 % ID/g following intravenous (iv) injection. Furthermore, hippocampus had an uptake of approximately 10 % ID/g.

Conclusion: Higher uptakes in hippocampus were observed at $\text{A}\beta$ 1-42 injected side in animal model of AD when compared with the control and naïve groups. Saturated studies with Bioquin-7-carboxylic acid compound showed that ^{99m}Tc labeled Bioquin-HMPAO compound has specificity towards amyloid plaques. It is suggested that ^{99m}Tc -BH has a potential to be used as a novel brain imaging agent including a diagnostic potential for AD due to its chemical structure and uptake in hippocampus.

IAEA-CN-232/300

Improvements in the Identification of the Maximum Skin Exposure and the Position of its Maximum on the Surface of Hands of Workers Handling Selected Radiopharmaceuticals

J. Hudzietzová¹, M. Fulop², P. Ragan³, J. Sabol⁴

¹ Faculty of Biomedical Engineering of CTU in Prague

² Slovak Medical University, Bratislava

³ Slovak Centre of Scientific and Technical Information, Bratislava

⁴ Crisis Management Department of PACR in Prague

Corresponding Author: j.sabol44@gmail.com

Background: In the process of handling radiopharmaceuticals, the local skin exposure of workers, according to the ICRP recommendations as an average over 1 cm², constitutes some restrictions. This exposure shows some inhomogeneity and, therefore, the position of the maximum exposure cannot be easily determined. Conventionally, this is established experimentally using TLDs placed at various locations on the surface of the skin of hands of workers where the maximum exposure is presumed. In fact, however, the positions identified as a result of such measurements may not always coincide with the real position corresponding to the maximum exposure. This means that there are some unspecified uncertainties in confronting the exposure monitored with relevant dose limit.

Methodology: We describe a method for a more accurate assessment of the position of the maximum skin exposure of hands of workers engaged in operations involving radiopharmaceuticals which could significantly contribute to their exposure. The selection of specific operations characterized with a dominant exposure has been made using a de-convolution of spatial distribution of doses following the administration of FDG radiopharmaceuticals to patients. The phantoms of hands at typical operations were scanned by a CT scanner and then converted to voxel phantoms for the calculation of the maximum exposure by means of the MCNP5 code. This method allows identifying the position of maximum dose with sufficient accuracy.

Results: Three phantoms of hands using the Epoxy resin with the density of 1.3 g.cm⁻³ were produced. The material chosen was a good approximation of the soft tissue and bone of a finger. Two of these phantoms are used for simulations of techniques of how a syringe can be held in the hand and the third one simulates holding pincers with a radionuclide, dripping cannula or other accessories. The shapes of such phantoms allowed a required variability for modeling of specific operations used in the handling of radiopharmaceuticals. Based on this simulation method, the position of the maximal skin exposure in terms of HP (0.07) was calculated. A good agreement between the exposure obtained from MC simulations and experimental results based on the use of TLDs of the MCP-Ns type has been confirmed.

The comparison made showed that the difference between the maximum exposure predicted position and the actual position at the point with the maximum dose to skin on the surface of the pad of the index finger or thumb may exceed 40%.

Conclusion: A method has been proposed aimed at the quantification of inaccuracies in the experimental assessment of the position of the maximum exposure of the skin of hands of the nuclear medicine personnel based on TLDs placed at predicted positions.

The suggested method for improved assessment of the maximum exposure and its position can serve for a more accurate evaluation of the exposure of the skin of hands applied especially in the case when this exposure exceeds the reference level set by relevant national authorities.

Acknowledgements: This work was supported under projects SGS15/114/OHK4/1T/17 and APVV-0241-011.

IAEA-CN-232/306

**Added Value of Positron Emission Mammography with
Fluorine-18 Fluorodeoxyglucose in the Management of Locally
Advanced Breast Cancer**

**I. Soldevilla Gallardo, F.O. Garcia perez, J.J. Del Real Rivas, E. Estrada
Lobato**

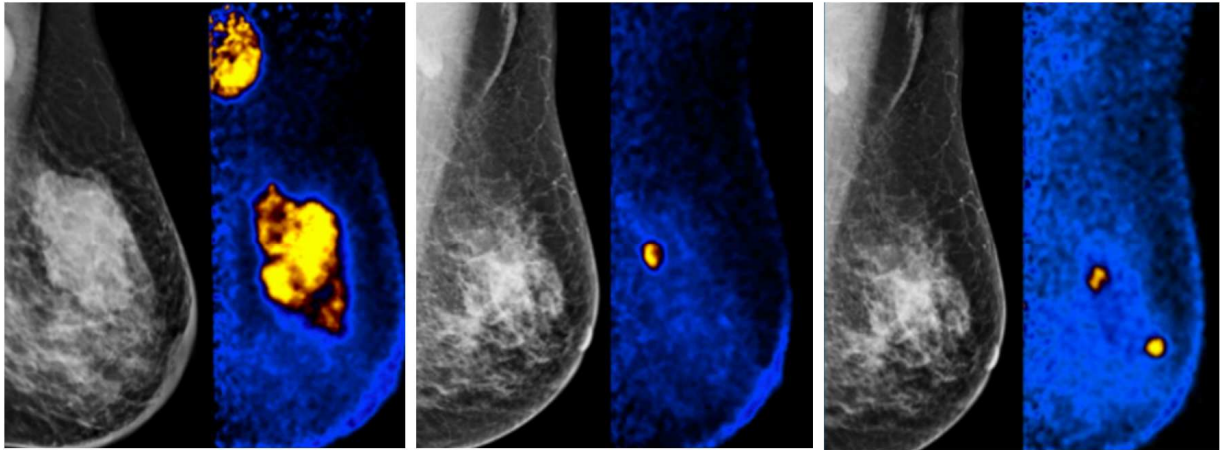
Instituto Nacional de Cancerologia

Corresponding Author: irmasoldevilla81@hotmail.com

Background: Locally advanced breast cancer represents the main presentation form in our population. An adequate staging is essential for optimal treatment. For this reason novel technologies such as the positron emission mammography (PEM) have been developed, and are capable of detecting diverse molecular processes with high resolution.

Methodology: 295 PEM studies were performed in 195 women with an average age of 49.5 years +/-10.1 with diagnosis of locally advanced breast cancer with histo-pathologic correlation (127 hormone-sensitive, 51 HER2neu positive and 17 triple negative) over a period between August 1 2012 and May 1 2014. In 50 patients the response to therapy was evaluated with initial interim and final PEM for each patient. Mammography (MG) was performed along with PEM, supplementary ultrasound and histo-pathological report after mastectomy following the end of neoadjuvant therapy.

Results: Of the 195 patients with initial diagnosis, PEM found synchronicity in 5 cases and multifocality in 33, 10 of them not seen by MG. Both methods identified multi-centricity in 13 cases, PEM discarded 7 lesions suspicious of synchronicity, 6 of multi-centricity and confirmed the presence of 2 lesions seen by mammography. The maximum PEM uptake value (PUVmax) of the malignant lesion was 2.34 +/- 0.54 (range 1.63 - 3.64). In 34/50 patients with positive histo-pathological report, PEM identified 3/34 (8.8%) with complete response (CR), 13/34 (38.2%) with partial response (PR), 16/34 (47%) with stable disease (SD) and 2/34 (5.8%) with progressive disease (PD); while in the remaining 16 patients with negative pathology PEM identified 12/16 CR (75%), 2/16 PR (12.5%) and 2/16 SD (12.5%); giving a sensitivity, specificity and negative predictive value of 91%, 75%, of 80% respectively. In 34/50 patients with positive histo-pathological report, MG identified 4 CR, 20 PR, 7 SD and 3 PD, whereas in patients with negative histopathology it found 5 CR, 10 PR and 1 SD, resulting in a sensitivity, specificity and negative predictive value of 88%, 33% and 55% respectively.



a) January 2013

b) March 2013

c) June 2013

- a) PEM baseline study showing a hypermetabolic lesion which extends in all four quadrants, there is also a hypermetabolic axillary adenopathy; b) Study performed after the 2nd cycle of chemotherapy based on FEC + Trastuzumab shows significant reduction in tumour burden in relation to partial response, similar findings are reported by mammography; c) Mammography at the end of treatment shows no significant changes from the previous study, but PEM shows the presence of an additional lesion not observed in previous study, neither in current mammography.

Conclusion: PEM is a tool with higher diagnostic accuracy than MG in the detection of suspicious and additional lesions as well as discarding synchronicity and multicentricity.

PEM also corroborated multifocality suspected by other imaging methods. The additional value of PEM over conventional imaging and clinical findings is associated with an increased sensitivity, specificity and negative predictive value, impacting on an early and efficient diagnosis, leading to change in surgical management and directly impacting prognosis.

IAEA-CN-232/307

**Physical Characterization of the New PET/CT Scanner
Discovery IQ (D-IQ)**

E. De Ponti¹, S. Morzenti¹, A. Zorz¹, L. Guerra², C. Landoni³, C. Spadavecchia¹, A. Crespi¹

¹ Medical Physics Department AO San Gerardo

² Nuclear Medicine Department AO San Gerardo

³ University of Milano Bicocca

Corresponding Author: e.deponti@hsgerardo.org

Background: The new GE Discovery IQ PET/CT scanner combines high stopping power BGO crystals with a dual energy integration channel acquisition to reduce dead time losses and pileup at high count-rates. Moreover 3D Q.Clear regularized iterative reconstruction available on D-IQ computing platform provides accurate quantitative measurements with predetermined high iteration number without degrading image quality or increasing noise.

Methodology: NEMA_NU2-2012 were applied to assess D-IQ physical performance. IEC body phantom was acquired. Contrast, background variability, residual lung error, spheres volume and SUV were analysed as a function of spheres diameter (10-13-17-22mm), activity in the phantom (52 and 26 MBq), spheres to background (S/B) concentration ratio (4:1-8:1-2:1), iterative reconstruction algorithms (VPHD, VPHD-S with resolution recovery and Q.Clear) and reconstruction parameters (n° of iteration for VPHD and VPHD-S and beta factor for Q.Clear). Contrast, background variability and residual lung error were calculated according to NEMA definition. Spheres volumes were calculated with segmentation method (42% fixed threshold); SUVmax was analyzed.

Results: Table 1 (below) summarizes NEMA measurements.

GE D-IQ NEMA NU2-2012 performance						
Spatial Resolution (mm)			1 cm FWHM	10cm FWHM	20cm FWHM	
	Axial		4.47	5.55	8.01	
	Radial		4.72	5.00	4.61	
	Tangential		4.80	5.18	5.67	
Sensitivity	0cm 23.3cps/kBq			10cm 19.3cps/kBq		
SF	37.4%					
NECR peak Activity peak	132.8kcps 9.8kBq/ml					
Hot Sphere recovery coeff.	10mm	13mm	17mm	22mm	28mm	37mm
	30.7%	53.0%	63.6%	68.9%		
Cold Sphere contrast					68.5%	75.0%
Background Variability	7.5%	6.5%	5.7%	4.9%	3.8%	2.8%
Average Residual over "lung" insert	16.6%					

Table 1 NEMA results

Results for the smallest IEC sphere are described.

Considering acquisition with 52 MBq of activity and S/B concentration ratio of 4:1, contrast increases according to n° of iteration in both VPHD and VPHD-S from 36.1% and 34.4% (6 iter) to 45.3% and 62.9% (25 iter). Background variability passes from 7.1% and 5.6% to 12.8% and 12.9% and lung error changes from 19.3% and 20.0% to 9.9% and 9.9%. Regularized reconstruction shows a contrast of 63.3%, 53.8% and 34.8% for $\beta=5$, $\beta=25$ and $\beta=100$ respectively, while the corresponding background values are 12.3%, 8.8% and 5.3%; and lung error 9.5%, 9.5% and 9.8%. Analysis of acquisition with half activity gives very similar results while increasing activity concentration ratio, contrast increases as expected and differences between reconstruction algorithms decrease.

Smallest sphere volumes from VPHS-6iter and VPHD-S-6iter reconstruction are 6.88 and 7.05 cm³, respectively, 13.1 and 13.5 times bigger than the real value (0.52cm³); increasing iterations to 25 we obtain more defined volumes of 1.74 and 1.21 cm³. Volumes from Q.clear are closer to the real value within a range of β starting from 5 (GE value for IEC phantom) up to 50. The SUV_{max} values are 2.5 and 2.4 for VPHD-6iter and VPHD-S-6iter, 4.2 and 3.9 for VPHD-25iter and VPHD-S-25iter and 4.2, 3.7 and 2.7 for Q.Clear and β values 5 – 25 and 100, respectively.

Conclusion: D-IQ is a very high sensitivity PET/CT scanner allowing fast scan acquisition or low dose tracer injection in clinical applications. Regularized reconstruction with fixed 25 iterations improves contrast, lesion definition and SUV quantification without image quality degradation.

IAEA-CN-232/308

Assessing Utility of 99mTc-MDP Bone Scan in Symptomatic Versus Non-Symptomatic Cases of Cancer at Nuclear Medicine Unit, at Mulago National Referral Hospital

R. Andropi Kuru Embati

Nuclear Medicine Unit, Mulago National Referral Hospital

Corresponding Author: embatirichard@yahoo.co.uk

Background: Uganda has one Nuclear Medicine unit, and it is only equipped with a single head SPECT gamma camera. With increasing prevalence of cancer diseases the number of patients referred for cancer screening at the Nuclear Medicine unit has increased considerably. For optimal patient evaluation there is a need to use both SPECT and PET/CT imaging. Unfortunately in our setting, there is no PET/CT, therefore we only use SPECT gamma camera with 99mTc-MDP as a first line diagnostic tool for the exclusion of metastasis to different parts of the body as part of the investigation strategy in cancer patient referred for radionuclide imaging.

The aims of the study were to assess the utility of 99mTc-MDP bone scan in symptomatic and asymptomatic cases of high risk cancer patients in Nuclear Medicine Unit, Mulago Hospital.

Methodology: All referred patients were assessed by the nuclear medicine physician, then scheduled for bone scan. The patients were divided into three groups namely - before treatment, after surgery and three years following the treatment (both radiotherapy and chemotherapy).

A total of 1575 patients who presented with symptomatic and asymptomatic pains were evaluated and a dose of 20-30mCi was administered to the patients dependent on the weight of the patients.

The patients were then rehydrated with 2000ml of saline, hence imaged 3 hours post injection.

Whole body anterior and posterior images were acquired for each patient using a Siemens E.Cam Single Head SPECT Gamma camera with a scan speed of 15cm/minute, 15% energy window and low energy high resolution collimator. In 543 asymptomatic patients whole body planar bone scan was followed by single field of view (FOV) SPECT of the axial skeleton.

The bone scans were then evaluated for possible metastasis by the physicians.

Results: A total of 1575 patients were evaluated with 99mTc-MDP of which 1008 (64%) were females and 567 (36%) were males (female to male ratio of 1.8:1).

The age distribution of the respondents was 0 as minimum with 99 years as the maximum whereas mean average age was 50.13 years with standard deviation of 19.34.

The symptomatic and asymptomatic patients were 616 (39%) and 959 (61%) respectively.

Of the symptomatic patients, 503 were positive for cancer (81.6%) and the remaining 113 (18.4%) negative. Conversely, of the asymptomatic patients 853 (88.9%) were positive whereas 106 (11.1%) were negative. Categorizing equivocal and malignant interpretation as suggestive for malignancy, the sensitivity and specificity of the study were 37.09% and 48.4% respectively whereas the positive predictive value (PPV) and negative predictive value (NPV) were 81.66% and 11.05% respectively.

Conclusion: From our findings, 99mTc-MDP bone scan is an important investigation because it has been able to identify asymptomatic patients who tested positive for cancer and these were the majority in the study. Therefore it is recommended that it should be used for evaluating asymptomatic patients who are at high risk for cancer in the absence of advanced nuclear medicine modalities such as PET/CT.

IAEA-CN-232/310

18F-FDG PET/CT in the Evaluation of Vascular Disease

G. Marcenaro, P. Orellana Briones, J.C. Quintana, D. Vicentini

Corresponding Author: porellana@med.puc.cl

Background: In the evaluation of vascular disease, conventional imaging methods such as computed tomography (CT), magnetic resonance imaging (MRI), and ultrasound (US) are excellent tools for evaluating morphologic changes. Positron emission tomography (PET) with fluorine-18-fluorodeoxyglucose (18F-FDG) has several advantages for the assessment of patients with infection and inflammation, but specially, it has the ability to noninvasively detect molecular and cellular processes and identify diseases in an early phase. It has shown the capacity to detect inflammatory processes with high sensitivity. The goal of this study is to show our experience using PET-CT with 18F-FDG in the assessment of some vascular diseases.

Methodology: We retrospectively reviewed the clinical data and 18F-FDG PET-CT findings in 21 patients suspected to have vascular disease such as vasculitis in 7 patients, endograft infection in 10 patients and mycotic aneurysm in 4 patients. The final diagnosis was obtained by clinical follow-up and laboratory tests.

Results: 18F-FDG PET/CT was abnormal in 6 of 10 cases with suspected endograft infection. In five of these patients findings were consistent with infection and in one patient the study showed a perforated urinoma. PET/CT was considered abnormal in 4 of the 7 patients with suspected vasculitis, showing diffusely increased metabolic activity involving the whole extension of compromised vessels (Fig. 1). CT was positive in only 2 of these 5 patients. Among the 4 cases of suspected mycotic aneurysm, 2 were considered positive showing heterogeneously increased FDG uptake in the aneurism wall.

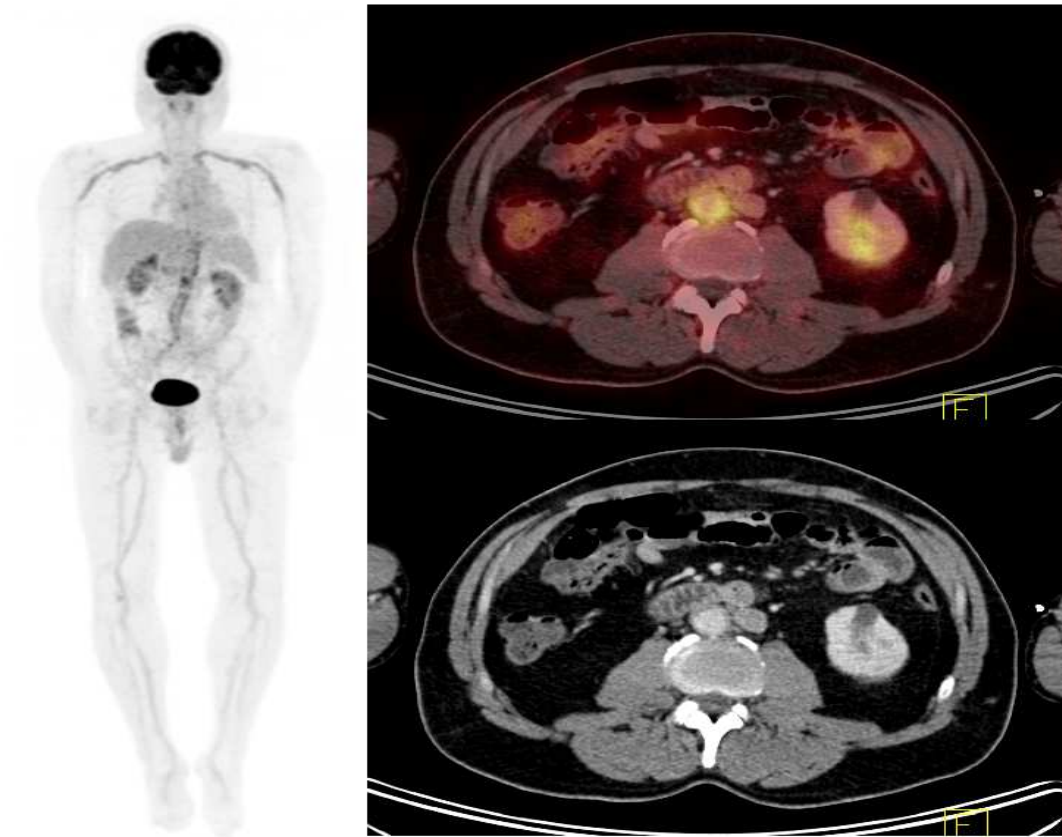


Figure 1

Conclusion: ^{18}F -FDG PET/CT is a useful diagnostic modality in the evaluation of vascular inflammatory and/or infectious processes with high diagnostic accuracy, providing both anatomic and functional information, which is important in clinical management of this group of patients.

IAEA-CN-232/311

Imaging Co-Registration: Clinical Applications and Daily Practice

I. Berrocal-Gamboa, E. Mora-Ramirez, M. Torres Gonzalez, C. Fonseca Zamora,

Caja Costarricense del Seguro Social, Hospital San Juan de Dios

Corresponding Author: isaberro@gmail.com

Background: The hybrid-high energy technologies in molecular medicine are currently prevalent in the daily practice of clinical diagnosis and treatment of patients in nuclear medicine around the world.

We are interested in knowing the value and feasibility of fused images with protocols and software applications to develop image fusion and co-registration, because it can provide valuable information during the analysis of clinical decision.

According to diagnostic modality used, the image fusion can be performed as follows; those resulting from the co-registered functional and molecular studies with morphological images, nuclear medicine and computed tomography and nuclear medicine and magnetic resonance, and those from co-registration of functional images with other functional images or intra-modality intra-subject, that represents the comparison of serial studies of the same modality but with different molecular or metabolic mechanism, using relatively simple algorithms that fit well and allow to determine disease progression and evaluate new lesions or relative intensity and spatial distribution of the alterations in serial studies for therapeutic intervention or control restaging.

Methodology: We employed fusion image in the category of inter-subject inter-modality in 4 cases, corresponding to: SPECT with I-131 tomography study and F-18 FDG PET, Gallium 67 citrate and 99mTc-HDP in osteomyelitis, 99mTc-DTPA for cerebrospinal fluid fistula in soft tissues with CT, 99mTc-octreotide to parathyroid adenoma and insulinoma.

Results: In our experience the registration and fusion images are used for special cases; both planar and tomographic modalities, as well as nuclear medicine with morphological studies can be used. The co-registration allows anatomical localization, attenuation correction using attenuation maps, correction scatter and partial volume, and provides additional diagnostic information.

Conclusion: Fusion technique is likely to be helpful for decision making in nuclear medicine patients. Fusion applications software depends on algorithms for the correct spatial registration of images. This is important and should therefore not be overlooked to ensure the quality of the studies. However, this approach can be improved in our daily practice.

IAEA-CN-232/312

**Radiation Protection Recommendations for
Releasing Patients Treated with ¹³¹I for Thyroid Cancer:
Theoretical Considerations for Specific Patient Approach**

E. Mora-Ramirez¹, M. Salas-Ramirez², I. Berrocal-Gamboa¹, C. Fonseca Zamora¹

¹ Caja Costarricense del Seguro Social, Hospital San Juan de Dios

² Caja Costarricense del Seguro Social, Hospital Mexico

Corresponding Author: erick.mora.ramirez@gmail.com

Background: The Nuclear Medicine Department at the San Juan de Dios Hospital has considered radiation protection guidelines given by the IAEA for releasing patients after ¹³¹I treatments for thyroid cancer, in the Safety Report Series No. 63, “Release of patients after radionuclide therapy”, published in 2009. This report has taken into account information published from different authors that considered measurements from released patients interacting with their relatives. However, IAEA guidelines are based on the administrated activity and do not take into account bio-kinetics of the ¹³¹I in the patient body, distance between patients and their relatives, which means they are not patient specific.

Methodology: We have studied considerations from USNRC document called “Consolidated Guidance About, Materials Licenses, Program-Specific Guidance About Medical Use Licenses, Final Report: NUREG-1556, Revision 2, appendix U”. Considering its mathematical formulism we do believe that patient specific approach can be done, taking into account the “EANM Dosimetry Committee Series on Standard Operational Procedures for Pre-Therapeutic Dosimetry II. Dosimetry Prior to Radioiodine Therapy of Benign Thyroid Diseases” and “EANM Guideline for Radioiodine Therapy of Differentiated Thyroid Cancer”, because estimation of bio-kinetics of thyroid and extra-thyroid compartments and of the effective half-life for thyroid and extra-thyroid compartments have been estimated. On the other hand definition of other parameters such as, occupation factor, distance and effective dose can be defined.

Results: Three female patients who underwent treatment for thyroid cancer were analysed. Two of them received 100 mCi (3700 MBq) for ablation and the other 150 mCi (5550 MBq) for treatment of metastatic recurrence disease. Establishment of occupation factor, distance and effective dose was defined under agreement of local medical physicist. Data showed good agreement with IAEA guidelines for ablation patients in restrictions for children under 2 years of age, time off work and sleep apart, however, restrictions for children from 2 to 11 years old are not similar. On the other hand, results for patients treated for recurrent disease are very different from the IAEA guidelines for all restrictions.

Conclusion: A method to establish patient specific radiation protection recommendations can be applied in a Nuclear Medicine Department taking into account bio-kinetics of ¹³¹I.

IAEA-CN-232/313

**Nuclear Medicine in Burkina Faso Three Years Later:
Difficulties and Prospects**

**F. Ouattara¹, S. Ouedraogo¹, V. Gansore¹, S. Amadou¹, T. Tapsoba¹
B. Ouattara², S. Tarbagdo¹, H. Sanon¹**

¹ Centre Hospitalier Universitaire Yalgado Ouedraogo, Ouagadougou,
Burkina Faso

² Institut de Recherche en Environnement, Burkina Faso

Corresponding Author: luis.metello@gmail.com

Background: The first, and currently the only, Nuclear Medicine Department of Burkina Faso was inaugurated on the 9th January 2012, with one dual-head gamma camera and seven health professionals as the starting staff. The scans performed in this department are bone scans, nuclear cardiology scans (myocardial perfusion scintigraphy), thyroid, parathyroid, lung and renal scans. The aim of this study is to present the operation of the service and the balance of these three years.

Methodology: Patient information: During the first contact with the patient, we explain in detail the role of the nuclear medicine to reassure the patient who does not generally have any information about nuclear medicine scans. After getting the patient's confidence, we interrogate the patient about the treatments progress, for example for the female patient, we find out if she is pregnant. The patients are also informed about the different steps of the scan.

Image acquisition: Patients are invited to be at the Nuclear Medicine Department at 7:00am. After the registration of the patient, the radiopharmaceutical is administrated depending on the scan. The waiting time after injection depends on the injected radiopharmaceutical. For example for the bone scan (whole body), patient receives the Tc-99m MDP and waits for 3h to 4h before the scan is performed. The MEDISO gamma camera system is used in Teaching Hospital Yalgado Ouedraogo.

Results: During this period there were some difficulties such as the lack of radioprotection materials (dosimeter, babyline...), and the lack of materials for quality control and training course. Despite these difficulties we got interesting results. The number of patients increased with the time. The number of patients varied between about 500 patients in 2012 to about 700 patients in 2014. During the three years, 7-8% of patients were children aged less than 10 years. Most of the patients were male: 60.2% in 2012, 69% in 2013, and 76.12% in 2014. More than 68% of the patients are interns.

We present the repartition of patients according to the type of exploration in 2013 in the table.

Years	Explorations	number of patient	Percentage
2012	Bone Scintigraphy	119	37.5
	Thyroid scintigraphy	77	24.3
	Myocardia scintigraphy	45	14.2
	Kidney scintigraphy	39	12.3
	Lung scintigraphy	37	11.7
	Total	317	100%
2013	Bone Scintigraphy	220	38.3
	Thyroid scintigraphy	175	30.4
	Myocardia scintigraphy	85	14.8
	Kidney scintigraphy	55	9.5
	Lung scintigraphy	40	7
	Total	575	100%
2014	Bone Scintigraphy	264	41.1
	Thyroid scintigraphy	188	29.3
	Myocardia scintigraphy	89	13.9
	Kidney scintigraphy	65	10.1
	Lung scintigraphy	36	5.6
	Total	642	100%

Conclusion: The practice of nuclear medicine began late in Burkina Faso, but it is making its own way on a steady and robust manner, improving firmly its placement in the range of reliable modalities able to support clinical decision. The next phase, including metabolic therapy with radionuclides should help us to further establish our position, while preparing us for the next phases to come; that is believed to go in the direction of SPECT/CT, before turning our attention to PET/CT.

IAEA-CN-232/314

Optimal Therapeutic Management of Metastatic Pancreatic Neuroendocrine Tumours by Complementary Molecular Imaging (18F-FDG and 68Ga-DOTATATE PET/CT)

T. Kamoun¹, I. Karfis², G. Gebhart², C. Garcia²

¹ Department of Nuclear medicine, Erasme Hospital, Université Libre de Bruxelles, Brussels, Belgium

² Nuclear Medicine Department, Institut Jules Bordet, Université Libre de Bruxelles, Brussels, Belgium

Corresponding Author: kamoun.tarek1982@gmail.com

Background: Gastro-entero-pancreatic neuroendocrine tumours (NETs) are a heterogeneous group of relatively rare neoplasms ranging from well-differentiated tumours over-expressing somatostatin receptors (SSR), to poorly differentiated malignancies with more aggressive behavior. Usually asymptomatic in early stage, these tumours are mainly discovered after their metastatic spread. In case of unresectable disease, palliative treatment is the only option, including peptide receptor radionuclide therapy (PPRT), with ¹⁷⁷Lu- or ⁹⁰Y-labelled peptides.

The tumour grade with the Ki67 index is an important prognostic marker in NETs. Tumour heterogeneity is a common finding in many tumours including NETs. In the setting of multifocal metastatic disease, in which the most aggressive lesions determine the prognosis, a tissue sample may not be representative of the whole tumour burden and may not fully reflect tumour heterogeneity, leading to inaccurate Ki67 values.

The aim of this communication is to emphasize the emerging role of combined molecular imaging (68Ga-DOTATATE and 18FDG) in NETs, assessing intra-tumoural heterogeneity.

Methodology: We present a case of a 59 years old man with grade 3 (Ki67 > 50%) pancreatic NET diagnosed by Fine Needle Aspiration. The disease was discovered incidentally throughout a liver ultrasonography in the follow up of a hemochromatosis. He underwent 18F-FDG PET/CT and 68Ga-DOTA-TATE PET/CT for prognostic and staging purposes as well as for the evaluation of the possibility of a treatment with ¹⁷⁷Lu-DOTATATE.

Results: 18F-FDG PET/CT (reflecting disease aggressiveness) showed multiple hypermetabolic metastatic sites of intense uptake in the liver, retroperitoneal nodes, peritoneum and gastric cardia. 68Ga-DOTATATE PET/CT (reflecting expression of SSR and disease differentiation) showed fewer and less intense sites of uptake only in the liver. The low expression of SSR orientate towards aggressive therapeutic approach, instead of treatment with ¹⁷⁷Lu-DOTATATE.

The patient was treated initially by cisplatin, VP16, FOLFIRI and chemoembolization of liver metastases with no response. Unfortunately, the evolution was pejorative with further progression of the metastasis in the gastric cardia becoming stenotic despite radiotherapy and capecitabine.

Conclusion: Molecular imaging using combined 68Ga-DOTATATE and 18F-FDG PET/CT, may highlight tumoural heterogeneity, identifying the more aggressive parts of the disease and leading to a more optimal therapeutic management in NETs.

IAEA-CN-232/315

18F-FDG-PET/CT: Changing Routine Practice in Evaluation of Bone Marrow Involvement in Hodgkin Lymphoma in North Estonia Medical Centre

A. Samarin, S. Nazarenko, L Karusoo, K. Tomberg

North Estonia Medical Centre

Corresponding Author: sergei.nazarenko@regionaalhaigla.ee

Background: Implementation of hybrid Imaging, and 18F-FDG-PET/CT in particular, plays an important role in evaluation and staging of patients with Hodgkin lymphoma (HL), including assessment of bone marrow involvement (BMI). BMI is present in 4 to 14% of all patients with HL, and it may cause upstaging in HL, with consecutive modification of treatment. Despite the fact that BMI can be easily demonstrated by 18F-FDG-PET/CT, bone marrow biopsy has been traditionally recognized as a golden standard for evaluation of BMI in HL.

Recently, in September 2014 updated recommendations on the use of 18F-FDG-PET/CT for staging and therapy response assessment for FDG-avid lymphomas were published in the Journal of Clinical Oncology. According to these guidelines bone marrow biopsy is no longer required for the routine evaluation of patients with HL if 18F-FDG-PET/CT is performed.

The aim of our single centre retrospective study was to evaluate the correlation between 18F-FDG-PET/CT and bone marrow biopsy findings in patients with HL treated at our institution - North Estonia Medical Centre.

Methodology: We analysed data from last three years (2012-2014) and identified 62 patients with HL in whom both 18F-FDG-PET/CT and bone marrow biopsy were carried out. In our group of patients 26 were male and 36 female, aged 14-78. Out of 62 cases 53 were primary HL patients, 9 patients had recurrent disease.

Results: In our group, in one case both 18F-FDG-PET/CT scan and bone marrow biopsy were positive for BMI. In 12 cases 18F-FDG-PET/CT scan showed BMI, and biopsy was negative. In 49 cases both 18F-FDG-PET/CT findings and bone marrow biopsy were negative for BMI.

Conclusion: As our data are in line with the results of the previous studies presented at the International Conference on Malignant Lymphomas Imaging Working Group, at our centre the Working Group on Haematological Diseases decided to use 18F-FDG-PET/CT as a golden standard for assessment of BMI in HL, and to abandon bone marrow biopsy in routine practice for HL management.

IAEA-CN-232/316

Preparation of ⁶⁸Ga-68 Radiopharmaceuticals in a South African Hospital Radiopharmacy

S. Rubow¹, A. Africander², A. Ellmann¹

¹ Stellenbosch University and Tygerberg Hospital

² Tygerberg Hospital

Corresponding Author: ael@sun.ac.za

Background: Ge-68/Ga-68 generators provide a positron-emitting radionuclide without daily cyclotron production. Radiolabelling with gallium-68 is not as easy as Tc-99m kit labelling. This presentation describes the validation procedure and problems experienced during the initial use of Ga-68 at the Western Cape Academic PET/CT Centre.

Objectives: Our aim was to establish and validate a reliable radiolabelling routine with Ga-68 according to Good Radiopharmacy Practice principles at the Western Cape Academic PET/CT Centre.

Methodology: Ge-68/Ga-68 generators from iThemba LABS, South Africa and Ga-68 peptide kits from ABX, Germany, were used. Protocols for generator elution manually or with a Scintomics automated unit were established. Acceptance criteria for the validation were specified a priori. A manual Ga-68 DOTANOC synthesis routine based on the Scintomics/ABX kit for cationic purification was validated in four trial runs. Quality control included testing for sterility, endotoxins, labelling yield, radiochemical purity by ITLC (all) and HPLC (n=3), half-life determination, and pH of the product. Operator radiation exposure was monitored.

Results: During all validation runs, the final product was sterile, endotoxin free and contained <5% free Ga-68. The average decay corrected labelling yield was 50% (validation), and 63% (successful clinical batches). Ge-68 breakthrough in eluates increased with generator age, but this was not reflected in the labelled product. Of 30 post-validation productions, 3 batches failed due to buffer impurities, and 1 batch failed due to a blocked filter. Procedure and shielding modifications decreased radiation exposure to the operator from 0.08 to 0.02 μ Sv/MBq eluate for manual synthesis. Problems included malfunctioning of the synthesis unit, eluant leakage and chemical impurities in a buffer solution.

Discussion: The synthesis unit uses disposable manifolds and tubing, and sterile consumables and reagents support GRP principles. When we had problems with our synthesis unit, we therefore based our manual procedure on the same kits and method.

Conclusion: Validation showed that Ga-68 DOTANOC suitable for administration to patients can be prepared at our Centre. Careful attention to detail and rigorous quality assurance protocols are essential if complex radiolabelling procedures are to be done in a hospital radiopharmacy.

IAEA-CN-232/317

**PET/CT with 68Ga-DOTA-Peptide Somatostatin Analogue in
Non-Gastro-Entero-Pancreatic (GEP) Neuroendocrine
Tumours (NET) Initial Experience**

R.O. Pinilla Soto, P. Orellana Briones

Pontificia Universidad Católica de Chile

Corresponding Author: rodrigopinilla@gmail.com

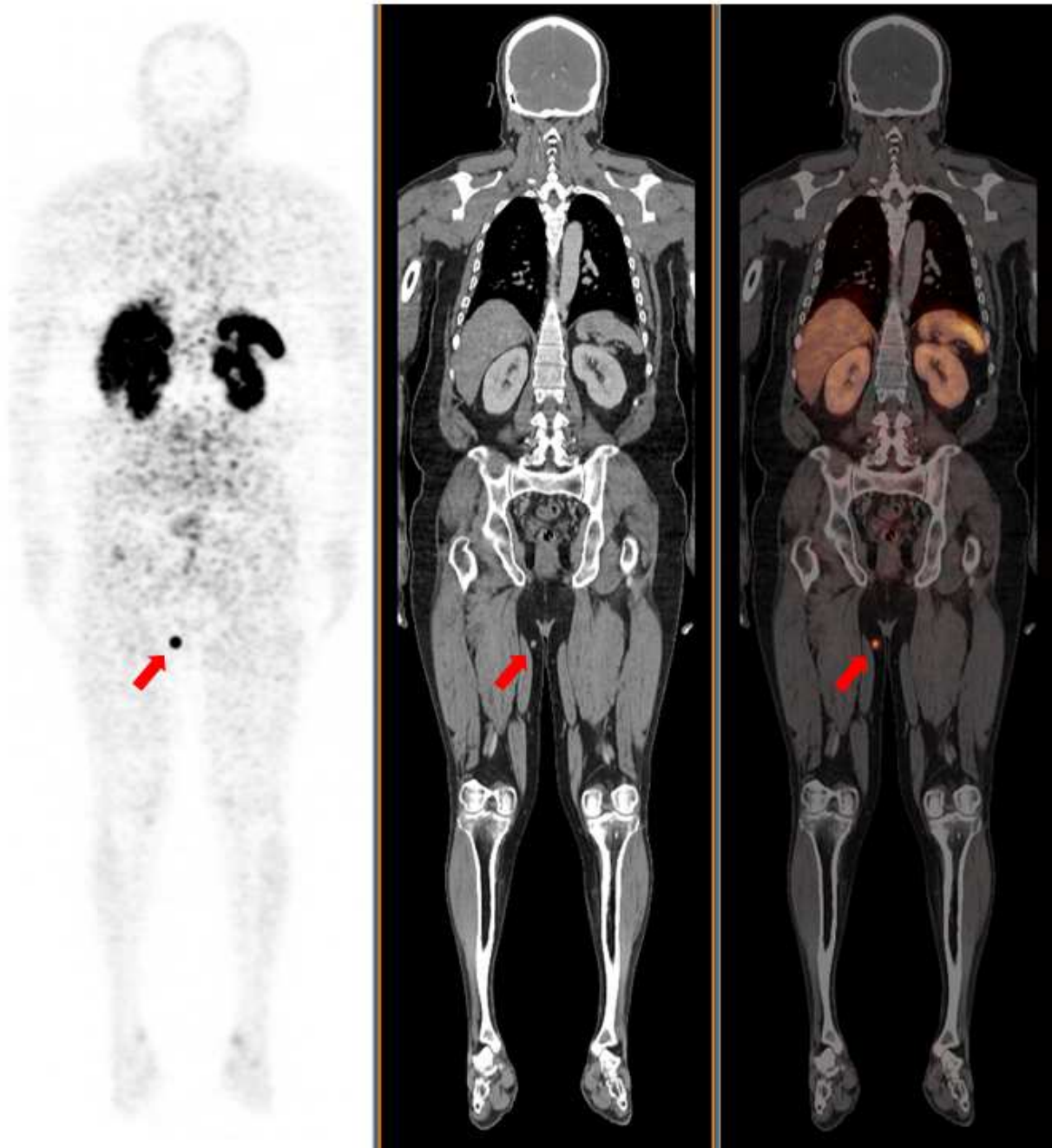
Background: 68Ga-DOTA-peptide somatostatin analogue PET-CT has shown high diagnostic performance in the evaluation of tumours that overexpress somatostatin (SST) receptors and is widely used as first-choice modality in gastroenteropancreatic neuroendocrine tumours (GEP-NETs). However, there are other neoplasms that show SST receptor overexpression. PET-CT with 68Ga-labelled peptides can be useful for diagnosis and evaluation of such tumours, including selection of patients that could benefit from peptide receptor radionuclide therapy (PRRT).

The purpose of this report is to show our experience in the use of PET-CT with 68Ga-DOTA-peptide somatostatin analogue in the evaluation of non GEP-NETs.

Methodology: We retrospectively reviewed clinical data and PET-CT with 68Ga-DOTA-peptide somatostatin analogue in patients suspected to have a non GEP-NET. The final diagnosis was confirmed by histology, laboratory tests and clinical outcome.

PET-CT images were obtained at least 35 min after intravenous injection of 37 to 245 MBq of 68Ga-DOTA-peptides somatostatin analogue. Images were acquired from cranial vertex to mid-thigh with a Siemens Biograph True Point 64 PET-CT camera, with 3 min/bed position and contrast enhanced diagnostic CT 3/3 mm with arterial and venous phases.

Results: Thirty out of 259 (11.6%) PET-CT studies with 68Ga-DOTA-peptide somatostatin analogue performed between 2009 and 2015 were included; corresponding to twenty five patients with non GEP-NETs. There were 13 females and 12 males, between 15 days and 74 years old. Ten patients had medullary thyroid cancer, 6 had pheochromocytoma, 3 had congenital hyperinsulinism, 3 had oncogenic osteomalacia, 2 had ectopic ACTH syndrome and 2 had thymoma. Other diagnoses were differentiated thyroid cancer (n=1), acromegaly (n=1), insulinoma (n=1) and pituitary adenoma (n=1). Among the 30 studies, PET was abnormal in 14 cases and CT was abnormal in 12 of these. PET-CT was abnormal in 50% of patients with medullary thyroid cancer as well as in patients with pheochromocytoma, demonstrating radiotracer uptake in primary tumours and metastases. The study was abnormal in 2 out of 3 patients with oncogenic osteomalacia, showing the presence of a mesenchymal phosphaturic tumour. PET-CT was positive in 2 out of 3 neonates with congenital hyperinsulinism. The study was normal in all 2 patients with ectopic ACTH syndrome and in all 2 cases of thymoma. SST receptor density was different among tumours, with high radiotracer uptake in some lesions and low uptake in others. Two patients underwent further PRRT with 177Lu-DOTATATE, one with malignant pheochromocytoma and one with undifferentiated thyroid cancer.



Conclusion: ^{68}Ga -DOTA-peptides somatostatin analogue PET-CT appears to be a valuable imaging modality in a broad clinical spectrum of non GEP-NETs that express SST receptors, with potential utility for initial diagnosis, follow-up and selection of candidates for PRRT. The expression of various SST receptor subtypes and their density on the tumour cell surface may contribute to the high variability on radiotracer uptake that was observed in this series.

IAEA-CN-232/319

Nuclear Medicine in Mali: Living on a Bad Moment, Having Faith and Highly Committed with the Future

S. Keriba, M.I Diarra, R. Diakite, S. Sidibé

Service de Radiologie et Médecine Nucléaire, Hôpital National du Point G,
Bamako, Mali

Corresponding Author: luis.metello@gmail.com

Background: The first (and only until this moment) Nuclear Medicine Department at Mali has been established in the late 1986, with one single headed gamma-camera, essentially dedicated to thyroid examinations. The situation had been based on that reality for a couple of years, until the moment that, because of successive technical problems, the use of the gamma-camera had been discontinued. Nuclear Medicine had persisted several years after this only based on radioimmunoassays. About the end of 2008, a new double-headed gamma camera, offered by the IAEA, was installed and two generators of $^{99}\text{Mo}/^{99\text{m}}\text{Tc}$ per month started.

During 2009, we had the opportunity to serve around 1.200 –1.300 patients, with a distribution of work based on around 30% of thyroid scans, 20% of bone scans, 15% of nuclear cardiology (myocardial perfusion scintigraphy), 15% of renal scans (with two thirds morphological examinations and one third functional renal scans, essentially with $^{99\text{m}}\text{Tc}$ -DTPA), 10% of parathyroid scans and the remaining percentages concerning lung scans and sentinel node evaluations.

2010 has been a very difficult year, with some economical and logistical problems that had interfered with the availability of the radiopharmaceuticals, since most part of the year generator equipment was compromised. Nevertheless, in the meanwhile, the education and training of some of the staff members continued.

The situation returned to normal in the very beginning of 2011 until September 2013. During this period, around 2.800 to 3.000 patients per year were treated, with around the same distribution already mentioned before. The relevance of Nuclear Medicine has been very well acknowledged because of the good work we have been able to provide to the clinicians that were sending us their patients.

In September 2013 a criminal assault has occurred and the criminals have taken with them the workstation, the acquisition unit and the central server, completely jeopardizing the equipment. A written official report has been sent to the authorities and the IAEA, which has helped and supported our efforts with all the pieces of equipment that had been robbed.

Actually, efforts are being made to create the necessary security conditions to assure that something similar will not happen in the future. Once this security building phase has been finished, all the new pieces received will be installed and we hope to (re)start our activities as soon possible.

Until the present moment, pediatric nuclear medicine is far from becoming reality in Mali's daily practice of nuclear medicine, but a recent participation at a IAEA meeting suggests that, once restarting our activities, we should introduce pediatric nuclear Imaging in our practice.

Conclusion: Nuclear medicine has proven its value and relevance in the recent past and we hope to be able to launch activities again as soon as possible.

IAEA-CN-232/320

**Assessment of Vulnerable Atherosclerotic Plaque Using
18F-FDG PET/CT**

**L. Pabon Castilla, A.M. Alvarez, M. Renjifo, F. Medina, J.C Castro
J.S. Toro, M. Valenzuela, E. Manzi**

Fundacion Valle del Lili

Corresponding Author: lpabon@yahoo.com.co

Background: Atherosclerosis is recognized as a diffuse chronic multisystem inflammatory disease. The determination of the unstable plaque is important for risk stratification for major cardiovascular events. Increased metabolism in an atherosclerotic plaque in PET/CT scan with 18F-FDG is associated with increased angiogenesis and inflammation mechanisms and could be related to unstable plaque. The aim of this paper is to describe the cases with incidental findings of vulnerable atherosclerotic plaque in 18F-FDG PET/CT scan until the date.

Methodology: Out of 1360 18F-FDG PET/CT scans performed between June 2012 to February 2015, incidental findings of vulnerable atherosclerotic plaque was evidenced in a total of six patients. One case was remitted with diagnosis of fever of unknown origin; the rest were oncological patients. The PET/CT studies were performed in a hybrid computer - BIOGRAPH mCT128 SIEMENS (Siemens, Germany) with previous intravenous administration of 18F-FDG, with qualitative and semiquantitative evaluation. We report the most relevant cases with incidental finding of vulnerable atherosclerotic plaque to rupture.

Results: Reviewing the medical literature, major cardiovascular events are associated with plaque rupture. The inflammatory cell content of the plaque is the most important factor for its rupture. The inflammatory cells, especially macrophages, destroy the fibrous layer that protects the atheromatous plaque, exposing the thrombogenic contents to circulation. The macrophages on the atheromas plaques will uptake the 18F-FDG. The proposed theory is that the accumulation of oxidized lipids (necrotic lipid layer) in the vessel wall will trigger an inflammatory response in the intima layer. The balance of inflammatory cells (macrophages and lymphocytes) is crucial to the stability of the plaque; plaque rupture may occur as clinical and subclinical; with a final consequence of cell death - apoptosis.

Conclusion: The 18F-FDG PET/CT scan can identify vulnerable atherosclerotic plaque and quantify the degree of inflammation. A prospective study with a multidisciplinary team is required to validate these results and define risk stratification protocols for cardiovascular events.

IAEA-CN-232/321

**Increased 18F-Fluorodeoxyglucose PET/CT Uptake in Benign
Eccrine Poroma Simulating Melanoma**

K. Maguiña, P. Chávez

Guillermo Almenara Irioyen National Hospital

Corresponding Author: kmaguina1002@hotmail.com

Background: PET/CT imaging plays an important role in tumour diagnosis, staging, evaluation for metastasis, and screening for recurrence. Nevertheless 18F-FDG uptake is not tumour specific, as the tracer also may accumulate in benign processes, the majority of which are of inflammatory nature. Eccrine poroma is a benign tumour which arises from the intraepidermal portion of the eccrine sweat glands. It usually occurs as a solitary lesion in the extremity, with the foot and sole as a common site. It may present as a foot mass, ulcerative lesion, bleeding lesion, or suspected melanoma. Eccrine poroma should be considered in the differential diagnosis of chronic foot lesions. Malignant transformation to porocarcinoma, has been reported, the tumour shows a high FDG uptake, when tumour staging is requested. Many benign or malignant lesions are only differentiated with appropriate workup and histologic evidence.

Methodology: We present a case report. Staging PET/CT was performed in a 43 years old woman with a lesion in the right foot. The lesion biopsy was compatible with undifferentiated malignancy, probably melanoma. Philips GEMINI TF 64 Diagnostic X-ray CT/PET Imaging System was used with standard acquisition protocol. The processing and interpretation of images was performed by an experienced nuclear medicine physician.

Results: PET/CT showed an increased uptake of 18F-FDG in the lesion with SUVmax value of 1.9, and increased 18F-FDG diffuse uptake in the skeleton, especially in both femurs and back bone, without bony injury tomography. The patient did not receive chemotherapy, or any drug that produced medullary hyper-reactivity, and blood count was within normal parameters. It was reported as a primary lesion with suspicious bone involvement. Biopsy was reviewed and the foot lesion was a benign eccrine poroma. The uptake in the skeleton was a benign, non-physiologic uptake.

Conclusion: Benign lesions like benign eccrine poroma show an abnormal uptake of 18F-FDG. The knowledge of these conditions is crucial for accurate PET interpretation in patients, and avoiding false-positive 18F-FDG-PET/CT results.

IAEA-CN-232/322

Diagnostic Utility of 18F-FDG PET/CT in Infectious and Inflammatory Disease: Case Reports

A.M Alvarez, L.M. Pabon, M. Renjifo, M. Valenzuela, F. Medina, J.S. Toro

Fundacion Valle de Lili

Corresponding Author: lpabon@yahoo.com.co

Background: Positron emission tomography (PET) with 18F-FDG is mainly used in oncology. However, in the last years, some publications have shown the potential role in diagnosing infectious or inflammatory diseases and in monitoring response to therapy. The aim of this study is to evaluate the contribution of 18F-FDG PET/CT in the diagnosis of patients with infectious and inflammatory disease in our population.

Methodology: Out of 1360 18F-FDG PET/CT scans performed between June 2012 to February 2015, a total of 28 cases were infectious and inflammatory disease, mainly patients with fever of unknown origin (53%). The PET/CT studies were performed in a hybrid computer - biograph mct128 Siemens (Siemens, Germany), with previous intravenous administration of 18F-FDG. We describe the most relevant cases in this group of patients (7 patients).

Results: In four patients with fever of unknown origin a final diagnosis was established by 18F-FDG PET/CT scan as follows: endocarditis, vasculitis, sarcoidosis (muscle involvement confirmed by biopsy) and sub-diaphragmatic abscess in a patient with liver transplantation (these results were not detected in other imaging tests performed).

There was one patient with invasive aspergillosis and intracranial lesions with a long medical treatment, with brain MRI image non-conclusive for differentiation between active infection and residual post-treatment lesion. In this patient, 18F-FDG PET/CT showed hypometabolism in brain lesions, suggesting residual post-treatment.

In the last two patients with diagnosis of Takayasu arteritis, 18F-FDG PET/CT allowed to evaluate disease extension and response to treatment.

Conclusion: 18F-FDG PET/CT scan is a non-invasive and useful technique for diagnosis in patients with fever of unknown origin to identify infecto/inflammatory disease. It also allows to differentiate between residual post-therapy lesions or active infection and to detect vasculitis disease extension and response to treatment.

IAEA-CN-232/323

Intracavitary Therapy with β Radiation-Emitting Nuclides in Cystic Craniopharyngioma: A Case Report

L.M. Pabon, A. Alvarez

Fundacion Valle de Lili

Corresponding Author: lpabon@yahoo.com.co

Background: Cystic craniopharyngiomas are benign lesions with slow tumour growth. The symptoms are related to space occupation, presenting compression of optical nerve, optic chiasm, hypothalamus and vascular structures. They mostly presented in the first and fifth decade of life, with possible recurrence until 10 years after. Surgical resection is not the best therapeutic alternative in some cases due to the tumour localization and the risks, comorbidities and complications that may occur (endocrine, visual, metabolic and cognitive impairment). In these patients, the therapeutic objective is to provide the best therapy for tumour control with minimal damage and improving quality of life; and intracavitary therapy with β radiation-emitting nuclides is an alternative.

Beta radiation-emitting nuclides (^{32}P , ^{90}Y , ^{188}Re) produce a localized radiation on the cyst wall containing secretory epithelium, with subsequent cystic fibrosis, decreasing the production of fluid with collapse of the lesion.

Methodology: We present our experience from 1994 until 2014 in three patients with five therapies using different emitting radiopharmaceuticals B: ^{32}P , ^{90}Y , ^{188}Re -colloid. Two paediatric patients at the age of 5 and 12 years old and a 35 year old woman, with initial symptoms of space occupation (blindness and diabetes insipidus) were included.

Patients were managed by a multidisciplinary group: nuclear medicine physicians, neurosurgery, endocrinologists, and medical physicist. Confirmation of pathology and lesion characterization (cystic / solid) was performed. Dosimetric calculations depending on the volume of the cyst were performed by medical physicist. All patients signed informed consent.

Ommaya reservoirs were placed under the scalp in the three patients. The administration of the radioisotope was performed in operating room, through the Ommaya reservoir, after draining the cyst, and saline and $^{99\text{m}}\text{Tc}$ wash. A post-therapy SPECT/CT image was acquired. In hospital observation for 24 hours and corticosteroids medication were undertaken. Clinical monitoring was performed every three months of the first year and every year thereafter.

Results: The two paediatric patients obtained excellent results with significant collapse of the cystic lesion, reduction of local symptoms and a normal child development. The adult patient presented cyst reduction, with a partial improvement of symptoms.

Conclusion: Intracavitary therapy with β radiation-emitting nuclides in cystic craniopharyngioma is an effective easy-to-handle alternative therapy, which can reduce compression symptoms and size of the cyst, offering a good quality life post-therapy. Ideally, the patient must be in an early stage of the disease with minimal symptoms, prior to significant compression and brain structures damage.

IAEA-CN-232/324

68Ga-DOTATATE PET/CT in Recurrent Medullary Thyroid Carcinoma: Comparison with 111In-DTPA-Octreotide SPECT-CT and Conventional Imaging

G. Campos Neto¹, J. Yang²; C. Camacho², M. Funari¹, M. Garcia¹, L. Yamaga¹, J. Wagner¹, M. Cunha, Marcelo¹

¹ Hospital Albert Einstein

² UNIFESP

Corresponding Author: itayay@hotmail.com

Background: The objective of this study was to prospectively evaluate the role of 68Ga-DOTATATE PET-CT for recurrent medullary thyroid carcinoma (MTC) and compare its findings with 111In-DTPA-octreotide SPECT-CT and dedicated CT and/or MRI.

Methodology: Fourteen patients with biochemical (raised serum calcitonin) and/or imaging evidence of recurrent MTC underwent 68Ga-DOTATATE PET-CT and 111In-DTPA-octreotide SPECT-CT. The results were compared on a per-patient basis and on a per-lesion basis. Histopathology (when available), correlation with conventional imaging modalities (US/CT/MRI/bone scan) and biochemical/clinical/imaging follow-up were used as reference standard.

Results: PET-CT was positive in 12 and negative in 2 patients. One of the positive PET cases was excluded from this casuistic because of the further diagnosis of lymphoma. PET-CT revealed a total of 99 lesions distributed in the thyroid bed, neck and mediastinal lymph nodes, pulmonary hila, liver, lung and bone. SPECT-CT was positive in 6 patients detecting 16 lesions. PET-CT and SPECT-CT had concordant findings in 3 patients (23.0%): two cases with negative result in both PET-CT and SPECT-CT exams, and 1 patient with positive results in both studies demonstrating the same number of lesion sites. Discrepancies among PET-CT and SPECT-CT results were found in 10 patients (77.0%). In this patient group, 5 patients had positive PET-CT and negative SPECT-CT. Five other patients had positive results in both studies but more lesions were detected by PET-CT than by SPECT-CT. PET-CT was also compared to diagnostic CT and/or MR. In particular, PET-CT detected more bone and mediastinal lymph nodes metastasis than was suspected by clinical and conventional imaging evaluation. On the other hand, false negative PET-CT findings occurred with no 68Ga-DOTATATE uptake in some of the small pulmonary nodules detected by chest CT and in some small neck lymph nodes. The 2 patients with negative PET-CT and SPECT-CT had also negative conventional imaging results. According to these results, the sensitivity of PET-CT and SPECT-CT were calculated as 84.6% and 46.1%, respectively.

Conclusion: In this small series we found that 68Ga-DOTATATE PET-CT was more sensitive than 111In-DTPA-octreotide SPECT-CT in the evaluation of MTC recurrence. PET/CT gives additional information to conventional imaging by detecting additional bone and mediastinal lymph node lesions.

IAEA-CN-232/325

Role of 18F-FDG PET/CT in the Diagnosis of Rasmussen's Encephalitis

A.M. Alvarez, L.M. Pabon

Fundacion Valle de Lili

Corresponding Author: lpabon@yahoo.com.co

Background: Rasmussen's encephalitis is a rare neurological disease, described as a chronic, progressive encephalitis developed in childhood and characterized by intractable focal seizures and progressive multifocal neurological symptoms such as hemiparesis and cognitive impairment. It tends to be localized usually in one hemisphere, although some cases have been described with bilateral affection. Recent reports highlighted the importance of functional imaging studying this pathology. The aim of this paper is to describe the cases with Rasmussen's encephalitis and demonstrate the role of PET/CT with 18F-FDG.

Methodology: Within 1360 18F-FDG PET/CT scans performed in the period June 2012 - February 2015, 4% were done for evaluation of neurological disease. Of these, 44 patients presented with refractory epilepsy (85%) including two adolescent patients with functional hemispherectomy and histological diagnosis of Rasmussen's encephalitis. Due to seizure recurrence, a brain 18F-FDG PET/CT scan was requested to determine the extent of disease prior to new surgery. MRI in both cases only showed cortical atrophy in the remaining cerebral cortex post-hemispherectomy without other significant changes. The PET/CT studies were performed in a hybrid computer - BIOGRAPH mCT128 SIEMENS (Siemens, Germany) after intravenous administration of 18F-FDG, with qualitative and semiquantitative evaluation.

Results: In both cases, the PET scan showed moderate to severe hypometabolism in the remaining cerebral cortex post-hemispherectomy and crossed cerebellar diaschisis, suggesting it to be the epileptic focus. Non-significant alterations were found in CT image.

Conclusion: Brain 18F-FDG PET/CT scan is useful for the evaluation of Rasmussen's encephalitis. Although cerebral MRI is an excellent tool for seizure disorders evaluation, correlation with PET/CT with 18F-FDG increases the pre-surgical diagnostic confidence allowing the exact identification of the cortical area which is functionally affected.

IAEA-CN-232/326

Implementation of a Strategy towards Harmonization of PET/CT Quantification in Different Devices

A.C Fischer¹, A.M. Marques Da Silva²

¹ PUCRS - Pontificia Universidade Católica do Rio Grande do Sul

² PUCRS

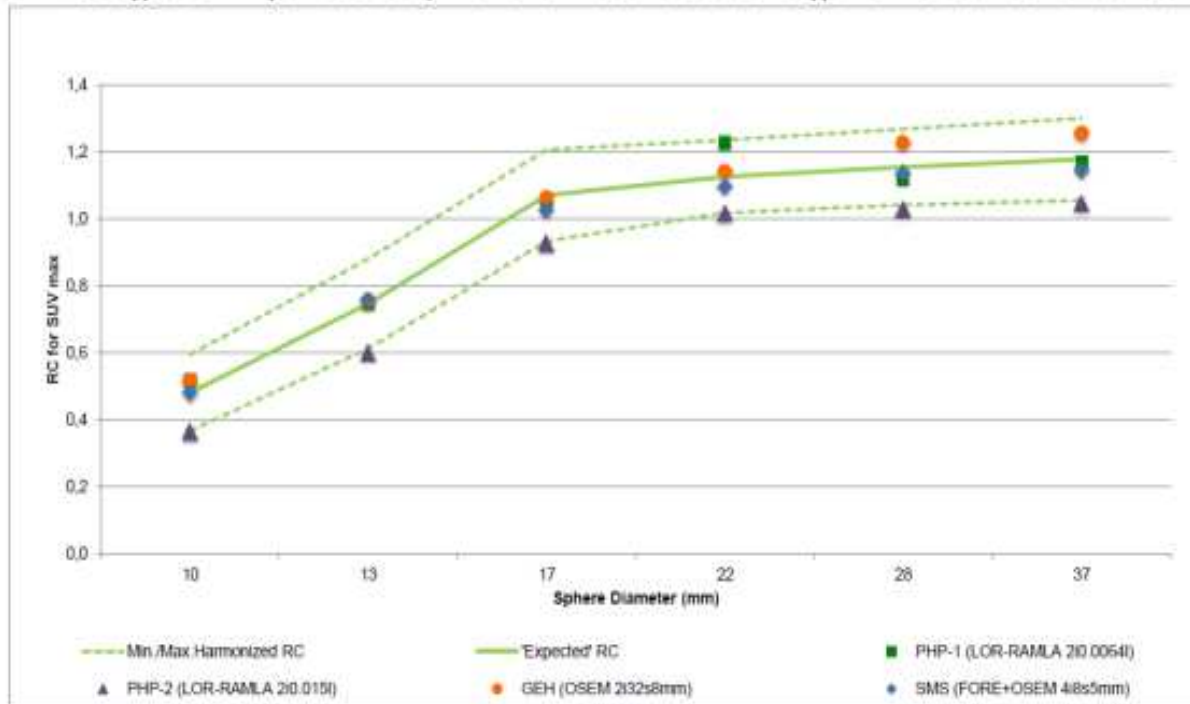
Corresponding Author: andrea.silveira.001@acad.pucrs.br

Background: In clinical practice, PET/CT images are often analysed qualitatively by visual comparison of tumour lesions and normal tissues uptake; and semi-quantitatively using the SUV (standardized uptake values). While the potential of 18F-FDG-PET in oncology has been demonstrated, the reproducibility of SUV measurements is affected by biological and technological factors. To ensure that longitudinal studies acquired on different scanners are interchangeable, it is necessary to establish a strategy to harmonize its quantification. The aim of this study is to present the implementation of a strategy to harmonize quantitative PET image measurements, performed with different scanner models and manufacturers.

Methodology: The strategy was based on Boellaard et al. (2011) and EANM accreditation procedures for 18F-FDG PET/CT devices. A NEMA IEC Body phantom study was performed using four different PET/CT devices: PHP-1 (Gemini TF Base, Philips); PHP-2 (Gemini GXL, Philips); GEH (Discovery 600, General Electric); SMS (Biograph Hi-Rez 16, Siemens). The activity concentration Recovery Coefficient (RC) was calculated using the clinical protocol and other clinically relevant reconstruction parameters. Through the clinical RC values, the harmonized RC curve (minimum, “expected” and maximum RC values) among the evaluated scanners was identified. The most appropriate reconstruction parameters (MARP) for SUV harmonization, in each scanner, are those which achieve that harmonized RC curve. They were identified using the lowest root mean square errors (RMSE). To evaluate the strategy’s effectiveness, the Maximum Differences (MD) between the clinical and MARP RC values were calculated.

Results: The “expected” RC values of the harmonized curve (shown in Figure 1) are overestimated, particularly for objects larger than 17mm. This means that, although a harmonized curve has been identified among the investigated scanners, it is not optimized (close to 1). These results demonstrate the need for further optimization, through the reconstruction parameters modification or even changing the reconstruction algorithm used in each scanner. The reconstructions parameters that obtained the lowest RMSE, identified as the most appropriate reconstruction algorithm for harmonizing PET measurements are: LOR-RAMLA 2i0.0064l (PHP-1); LOR-RAMLA 2i0.0151 (PHP-2); OSEM 2i32s8mm (GEH); and FORE+OSEM 4i8s5mm (SMS). These are the clinical protocols (PHP-2 and SMS) or variations thereof (PHP-1 and GEH). Thus, to ensure that quantitative PET image measurements are interchangeable between the sites included in this study, the images must be reconstructed with the above-mentioned parameters. The MD showed that the strategy was effective in reducing the variability of SUV quantification for small structures (<17mm).

Figure 1 - Recovery coefficients after the implementation of harmonization strategy for all investigated PET/CT devices, with their reconstruction algorithms between brackets.



Conclusion: We concluded that the harmonization strategy of the SUV quantification implemented with these devices was effective in reducing the variability of small structures quantification, minimizing the inter-scanner and inter-institution differences in image quality and quantification. However, for further comparison of SUV quantification between different scanners and institutions, it is essential that, in addition to the harmonization of quantification, the standardization of the methodology of patient preparation must be maintained, in order to minimize the SUV variability due to biological factors.

IAEA-CN-232/327

**The Use of 68-Ga Somatostatin Analog (DOTATOC) PET/CT
in the Initial Workup in Neuroendocrine Tumours with
Somatostatin Receptor Expression: A Four-Year Review of the
Experience in the Instituto Nacional de Cancerología (INCan),
Mexico**

**A. Garcia-Resendez, Q.G. Pitalúa Cortés, D. Arguelles, F.O. Garcia
Perez**

INCan, Mexico

Corresponding Author: garciare@gmail.com

Background: Neuroendocrine tumours (NET) are neoplasms that mostly express somatostatin receptors on the tumour surface. They are considered a rare entity, but the incidence is believed to be higher than reported. The development of somatostatin analogs and their later binding to PET tracers have made the visualization of this expression possible. Different analogs have different affinity towards specific types of receptors which are expressed.

The objective of this review is to share a four-year experience (2010-2014) in the use of 68-Ga DOTATOC PET/CT in the diagnosis, staging, follow-up and treatment response of NET tumours in the INCan Mexico.

Methodology: A retrospective analysis of the patients data in which a 68-Ga DOTATOC PET/CT scan was required as part of their work up for the characterization of neuroendocrine tumours was conducted. In the period between February 2010 and March 2014, a total of 238 patients with an age range of 22-80 years old (mean age of 52.08 years) were studied. They were classified according to the localization of the primary tumour: head and neck tumours, GEP tumours, gynecologic, breast tumours, paragangliomas, central nervous system (CNS) tumours, lung tumours and other neoplasms. They were also classified for their scan indication: primary diagnosis and localization, staging, restaging, recurrence and treatment response.

Results: 68-Ga DOTATOC PET scan was positive in 238 patients. The classification according to the localization of the primary tumour was as follows: 13 head and neck tumours, 96 GEP, 13 gynecologic, 8 breast tumours, 23 paragangliomas, 25 lung tumours, 11 CNS, 28 other neoplasms, including 21 with unknown primary tumour, including 12 cases where the primary was never found. Also, 55 patients had a positive for primary diagnosis, 54 for staging, 59 for restaging, 31 for recurrence and 40 for response to treatment.

Conclusion: 68-Ga DOTATOC PET SCAN has been included in the work up of NET tumours in the INCan Mexico as a powerful tool in the diagnosis, staging, restaging, recurrence, and treatment response evaluation of the disease.

IAEA-CN-232/329

Breast Cancer Immunophenotypic Heterogeneity, Evaluation by Molecular Imaging

Q.G. Pitalúa Cortés, F.O Garcia Perez, D. Arguelles

INCan, Mexico

Corresponding Author: quecho70@hotmail.com

Background: Patients who develop distant metastases usually undergo systemic therapy with chemotherapy, hormonal therapy and/or human epidermal growth factor receptor 2 (HER2) targeted therapy. The choice of therapy is currently personalized on the basis of the immunophenotype of the primary tumour, since distant metastases are often not biopsied. However, previous studies have indicated that receptor status may differ from the primary tumour, generally denoted “receptor conversion”. An alternative for taking biopsies could be molecular imaging methods that are currently being developed to functionally assess immunophenotype of breast cancer metastases.

Published discordance rates between primary and recurrent disease are highly variable and range for example for the oestrogen receptors (ER) between 7.2 and 43.2% and for the HER2 between 0 and 64.3%.

The factor that has been associated with the loss of ER expression with primary tumours expressing ER was endocrine treatment with tamoxifen, which increased the risk of discordance. Treatment with trastuzumab may lead to clonal selection, which results in HER2-negative metastases caused by the eradication of HER2-positive tumour cells. However, these observations might be influenced by other factors like intra-tumoural heterogeneity with different biological features and metastatic potential.

Methodology: Ten patients with locally advanced or metastatic breast cancer were studied with 18F-FDG PET-CT, 18F-FES and 67Ga-DTPA-Trastuzumab. Tissue samples were collected post-imaging studies, and ER and HER2 expression were assessed by IHC. We also correlated 18F-FES uptake (SUVmax) with ER expression measured by H-SCORE (0-210). 67Ga-DTPA-Trastuzumab uptake was measured by a visual analysis based on the hepatic and blood pool uptake (-, +, ++, +++) and was compared with HER2 expression measured by IHC (positive or negative, ordering fluorescence in situ hybridization (FISH) only if the IHC results did not clearly show whether the cells are HER2-positive or negative).

The percentage of receptor change status in the metastases immunophenotype was also evaluated in order to correlate with the primary lesion.

Results: We included 28 lesions in 10 patients. Histology of primary lesion was 9 invasive ductal carcinomas and 1 invasive lobular carcinomas; ER positive=7, PR positive=8, Her2 positive=3. Histology of metastatic disease was 7 ductal carcinoma, 1 lobular carcinoma, 1 neuroendocrine carcinoma, 1 without neoplasm evidence, ER positive=12, PR positive=10 Her2 positive=7; we found receptor discordances in 8 lesions; RE + to - in 1, RE - to + in 1, HER2 + to - in 1, and HER2 - to + 5 lesions.

Final results were 8 receptor discordances in 18 studied metastatic lesions.

18F-FES SUVmax was correlated with ER H-Score (r: 0.7739, p: 0.0003); the uptake value of 67Ga-DTPA-Trastuzumab was correlated with IHC (r: 0.8575, p: 0.0001).

Conclusion: Molecular imaging in breast cancer is highly efficient to assess the receptor expression in metastatic lesions and any unsuspected changes in these receptors, therefore leading to therapeutic change.

IAEA-CN-232/330

Use of SPECT/CT in the Evaluation of Malignant Lesions in the Spine and its Correlation with Histopathology

D. Arguelles, U. Martinez Berry, F.O. Garcia Perez,

INCan Mexico

Corresponding Author: davarguelles@gmail.com

Background: The incidence and prevalence of back pain is very high and has a multifactorial etiology. Metastatic bone lesions may be lytic, blastic and mixed. Diagnosis and early treatment improves results. Combining single photon emission computed tomography (SPECT) and computed tomography (CT) has proven to be useful. Scintigraphy with bisphosphonates and lyophilized methoxy-isobutyl-isonitrile (MIBI) is the most widely used imaging method because of its availability, high sensitivity and cost-effectiveness, but it has low specificity. Hybrid imaging systems such as SPECT/CT in the diagnosis of bone metastases have greater sensitivity, specificity and accuracy. The role of hybrid systems is becoming greater, both in research and in clinical practice and new combinations are developing.

In the Instituto Nacional de Rehabilitacion (Mexico), the number of patients suffering from lumbar pain is very high. Vertebral destruction syndrome, being of multifactorial etiology, is especially highly present, and generates the need to demonstrate or rule out objectively the underlying pathology, in order to undertake the most accurate treatment.

Methodology: To determine the behavior of malignant lesions in spine MIBI and MDP SPECT/CT scans were performed and correlated with the histopathological findings.

Results: 45 studies with MIBI and 36 with MDP were done from January 2013 to December 2014. The patients were divided into two groups:

Group A (MIBI) with 22 patients, 13 men and 9 women (mean age 52.9 years, age range 22-78 years).

Lytic lesions: 5 positive, 5 negative, 2 single, 8 multiple, 3 benign, 7 malignant.

Blastic lesions: 1 positive, 1 negative, 2 multiple, 1 benign and 1 malignant.

Mixed lesions: 1 positive, 1 multiple, 1 malignant.

Vertebral destruction: 4 positive, 5 negative, 7 single, 2 multiple, 6 benign, 3 malignant.

Group B (MDP) with 20 patients, 11 men and 9 women (average age of 56.7 years, age range 36-79 years).

Lytic lesions: 3 positive, 1 negative, 1 single, 3 multiple, 2 benign, 2 malignant.

Blastic lesions: 1 positive, 1 single, 1 benign.

Mixed lesions: 2 positive, 1 single, 1 multiple, 1 benign, 1 malignant. Vertebral destruction: 13 positive, only 5 single, 8 multiple, 11 benign, 2 malignant.

Conclusions: The correlation between SPECT/CT and histopathologic findings when using MIBI was 92% versus 25% with MDP. This difference is expected because MIBI has greater specificity for malignant tumour lesions compared with MDP. Radiologically, the most frequent type of malignant lesions was lytic type, whereas for benign lesions vertebral destruction was most commonly seen; however both pharmaceuticals were not used in every patient studied. We conclude that a more specific tracer should be used in cases of vertebral destruction for malignant lesions, as it would enable proper early management in those patients in which vertebral destruction is due to malignant changes.

IAEA-CN-232/331

**Biodistribution of $^{64}\text{CuCl}_2$ in the Rat: A Potencial Tracer
for Theranostic Applications**

J.C. Manrique Arias¹, M.A. Ávila Rodríguez¹, P.G. Reyes Romero², A. Zarate Morales¹, A. Flores Moreno¹; V. Lara Camacho¹

¹ Unidad PET, Facultad de Medicina, Universidad Nacional Autónoma de México, México D.F., C.P. 04510, Mexico

² Facultad de Ciencias, Universidad Autónoma del Estado de México, Instituto Literario No. 100, C.P. 50000, Toluca Edo de México, Mexico

Corresponding Author: jc.manrique@prodigy.net.mx

Background: Copper plays an essential role in human physiology. It is required for respiration, radical defense, neuronal myelination, angiogenesis, and many other processes. Over the last few years, $^{64}\text{CuCl}_2$ has shown a potential as a theranostic agent. However, there is little information about the normal biodistribution of this radionuclide. The aim of this study was to obtain the biodistribution of $^{64}\text{CuCl}_2$ in healthy rats.

Methodology: Cu-64 was produced in a cyclotron via the $^{64}\text{Ni}(p,n)^{64}\text{Cu}$ reaction with 11 MeV protons using ^{64}Ni electrodeposited on Au backing as target material. Radiochemical separation was performed by ion exchange chromatography, obtaining ^{64}Cu in the chemical form of CuCl_2 (0.1M HCl). The copper fraction was evaporated to dryness and recovered with 0.9% NaCl for final injection. After intravenous administration of $^{64}\text{CuCl}_2$ (37-74 MBq), static scans were acquired at different times (0.5, 1, 3, 5, 24 and 72 hours n=3) using a microPET Focus 120. Whole organs were dissected, weighed and assessed for radioactivity in sodium iodide.

Results: Serial microPET images at 0.5, 1, 3, 5 and 24 h post-injection (Figure 1) revealed a rapid clearance from blood and high uptake in kidneys and liver, which was consistent with biodistribution data. The distribution of ^{64}Cu in whole organs, given as percentage of the injected dose, at various times after injection, is shown in Figure 2. Note the rapid blood clearance, reaching less than 5% of injected dose after 3 hours. At 1 h post-injection, the rat liver and kidneys showed the highest uptake (7.12 ± 0.57 and 3.85 ± 0.57 % ID/organ, respectively), followed by muscle, bone, spleen, brain, heart, lung and bladder (1.74 ± 0.57 , 1.001 ± 0.70 , 0.30 ± 0.12 , 0.39 ± 0.2 , 0.26 ± 0.11 , 0.22 ± 0.05 , 0.3 ± 0.39 % ID/organ, respectively).

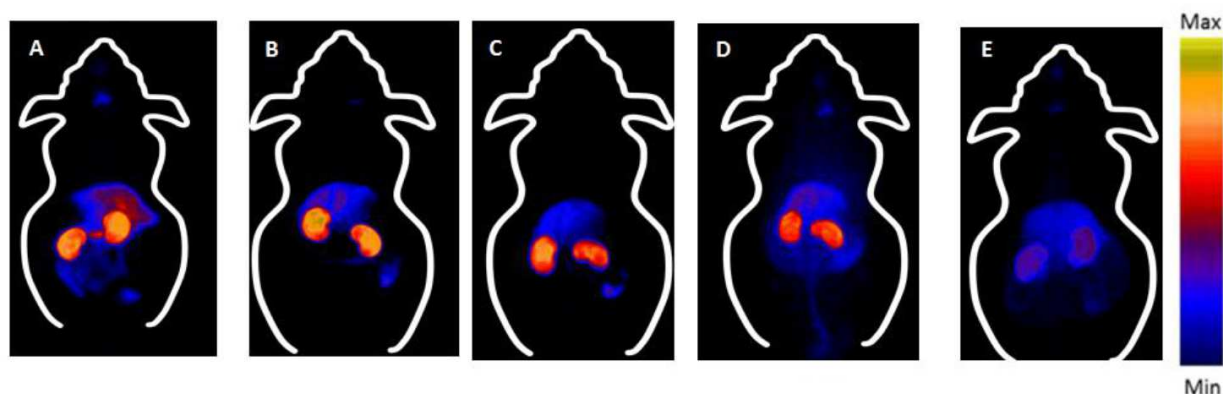


Figure 1. Serial microPET images of $^{64}\text{CuCl}_2$ in rat, at different times after injection: 0.5 h (A), 1 h (B), 3 h (C), 5 h (D) and 24 h (E). Acquisition time was 30 min for A, B, C, D, and 60 min for E.

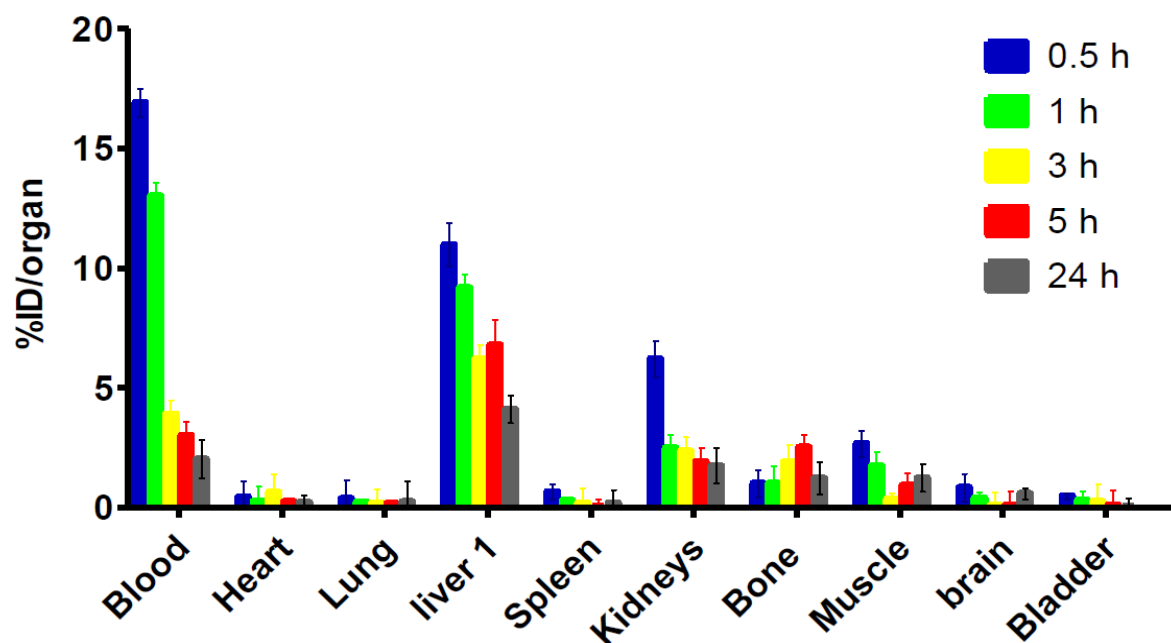


Figure 2. Biodistribution data for $^{64}\text{CuCl}_2$ in rat at 0.5, 1, 3, 5 and 24 h p.i. Results are shown as %ID/organ (mean \pm SD).

Conclusion: Based on the biodistribution results, which are in agreement with the serial microPET images, we conclude that the critical organs for $^{64}\text{CuCl}_2$ in rat are liver and kidneys.

Acknowledgments: The financial support of CONACYT Grant 179218.

IAEA-CN-232/332

Radioguided Parathyroidectomy: A Single Centre Experience in Mexico

S. Medina, F.O Garcia Perez, D. Arguelles, Q.G. Pitalúa Cortés, A. Garcia-Resendez

INCan, Mexico

Corresponding Author: dr.sevastian@outlook.com

Background: Parathyroid adenoma has a prevalence of 1%, with maximum incidence is in the 3rd and 5th decade of life and being more common in women (3:1). Parathyroid adenomas have an ectopic location in 5-10% of cases and the most common location is anterior mediastinum. The conventional surgical approach is bilateral neck exploration; nevertheless the use of ^{99m}Tc-MIBI scintigraphy intraoperatively has made minimally invasive parathyroidectomy possible. Parathyroid adenoma assessment with ^{99m}Tc-MIBI is based on longer retention of the tracer in parathyroid compared with thyroid tissue. The objective of this study was to evaluate the utility of portable gamma-camera at real time intraoperative imaging for assessing localisation of parathyroid adenoma.

Methodology: This was a retrospective analysis of patients with parathyroid adenoma who underwent radioguided surgery at INCan. Planar scintigraphy was performed 15 minutes after intravenous injection of ^{99m}Tc-MIBI, 60-120 min before intervention. The portable gamma-camera was used to identify the adenoma during surgery, as well as to verify if it was removed completely. All surgical specimens were taken for intraoperative histopathological evaluation.

Results: 20 patients were diagnosed with parathyroid adenoma (17 with usual location and 3 with ectopic location). Parathyroid adenoma were localized intraoperatively with a portable gamma-camera in all patients, reducing the time of surgery. All surgical specimens were confirmed as parathyroid adenoma in the intraoperative and definitive histopathological evaluation.

Conclusion: Parathyroid scintigraphy with portable gamma-camera in intraoperative identification of parathyroid adenoma has contributed to the development of minimally invasive parathyroidectomy. Therefore, in our opinion, in addition to the realization of preoperative scintigraphy, radioguided surgery with portable gamma-camera should always be performed, thus reducing complications, hospital stay, surgical and recovery time, with the same therapeutic effectiveness as classical treatment.

IAEA-CN-232/333

Breast Cancer: Role of Molecular Imaging

A. Garcia-Resendez, M. Patino-Zarco, I. Soldevilla Gallardo, F.O Garcia Perez

INCan, Mexico

Corresponding Author: garciare@gmail.com

Background: The purpose of this work is to provide an overview of clinical and biologic considerations in breast cancer, and to review current applications of molecular imaging in breast cancer screening, staging, restaging, response evaluation and guiding therapies.

Methodology: We present:

- Incidence, risk factors, pathology, and classification
- Breast cancer detection and diagnosis: PEM
- Locoregional Staging: PEM, SPECT/CT lymphoscintigraphy, 18F-FDG PET/CT
- Systemic Staging: 18F-FDG PET/CT, bone scan
- Response to therapy assessment: PEM and PET/CT
- Potential role of other PEM and PET/CT radiotracers: Fluorothymidine - FES

Results: The major teaching points of this presentation are:

- Indications for PEM
- Detection in high-risk groups, and cases in which mammography is less effective
- Defining disease extent for surgical planning
- Therapy selection and monitoring
- Indications for lymphoscintigraphy
- Lymphoscintigraphy + SLN sampling is the standard of care for axillary nodal staging; best results with SPECT/CT
- Indications for PET/CT:
 - Emerging role for locoregional staging in advanced disease
 - Assessment of extent of disease in selected patients before therapy.
 - Therapy selection and monitoring (emerging role for FES PET/CT)

Conclusion: Breast cancer is one of the most common forms of cancer and is associated with high mortality. Molecular imaging plays a vital role in proper management of breast cancer. In our poster presentation, we will present crucial points of molecular imaging in this pathology.

IAEA-CN-232/334

The Relationship between Testicular 18F-FDG Uptake and Clinical Parameters

J.H. Lee, S.G Park

DKUH, Rep. of Korea

Corresponding Author: allright73@hanmail.net

Background: The purpose of this study is to assess physiological 18F fluoro-2- deoxy glucose (FDG) uptake of testicles in healthy people and evaluate its relationship with testosterone, age, visual grade, body mass index (BMI), waist hip ratio (WHR) and testicular volume.

Methodology: Among 18F-FDG positron emission tomography/computed tomography (PET/CT) images for health check between March 2009 and February 2011, 236 testes of 118 men with no underlying disease were investigated. We used mean FDG uptake (SUV_{mean}) of both testicles or higher FDG uptake (SUV_{max}) on one side as testicle FDG uptake. Serum testosterone levels of participants in this study were analysed by radioimmunoassay (RIA). We calculated manually the volume of both testicles of each participant. The correlation between 18F-FDG uptake of testicles and testosterone, age, BMI, testicular volume and sexual habit was evaluated.

Results: The mean age of 118 men was 46 ± 8 y (range 29-72) and mean blood glucose level was 94 ± 13 mg/dl (range 52-131). The mean volume of 236 testes of 118 men was 41.2 ± 7.8 cm³ (range 29.5-65.6). The mean SUV_{max} of testes was 3.3 ± 1.1 (range 1.6-3.5) and mean SUV_{mean} was 1.9 ± 0.7 (range 1.0-2.3). The serum testosterone level was 6.9 ± 2.8 (range 0.5-11.3). There was no significant relationship between testicular SUV_{mean} or SUV_{max} and testosterone, volume, age, BMI, visual grade and WHR. Mild negative correlation was noted between testosterone and age ($r=-0.231$, $p<0.05$). Also, the correlation between testicle 18F-FDG uptake and weekly mean sexual activities ($p<0.05$) was statistically significant.

Conclusions: The results of our study demonstrated that there is no significant relationship between testicular 18F-FDG uptake and age, testosterone, volume and other parameters originated from health check, compared to previous reports dealing with physiologic 18F-FDG uptake. However, the significant link between testicular metabolism and sexual habit is found. Further investigation will be warranted to clarify the link between testicular 18F-FDG uptake and various clinical parameters.

IAEA-CN-232/335

PET/CT in Evaluation of Malignant Pleural Mesothelioma

A. Calderón

National Cancer Institute, Bogota

Corresponding Author: acalderom10@yahoo.com.ar

Background: Malignant pleural mesothelioma (MPM) is a rare and aggressive tumour originating from the serosal membranes that line the thoracic and abdominal cavities.

A previous exposure to asbestos and erionite is the main risk factor of mesotheliomas.

Epithelioid mesothelioma is the most common subtype and accounts for about 60% of all mesotheliomas.

Sarcomatoid malignant mesotheliomas represent about 10-20% of mesotheliomas.

Biphasic malignant mesotheliomas contain a mixture of epithelioid and sarcomatoid areas within the same tumour and comprise about 30% of mesothelioma.

Imaging techniques such as CT, MRI and PET/CT have essential pre-and post-treatment roles in detecting tumours and evaluating the extension of MPM.

We set out to describe the findings in PET/CT studies performed in patients diagnosed with mesothelioma during the three years of operation of the Centre's PET/CT (January 2012 to March 2015).

Methodology: We performed 12 18F-FDG-PET/CT studies in 12 patients with MPM (10 males, 2 females, aged 49 to 81 years, 9 at time of initial diagnosis, 3 follow-up studies). We revised 18F-FDG-PET/CT findings of primary tumours, recurrent tumours, lymph nodes and metastases.

Results: Histologically 11 cases of epithelioid and one biphasic mesothelioma were found.

All primary and recurrent tumours were 18F-FDG positive. The uptake patterns at initial diagnosis were: diffuse + multi-nodular uptake pattern in 9/9. One patient had a 18F-FDG positive lymph node in the ipsilateral supraclavicular region confirmed as metastasis (N3). 3 patients had a 18F-FDG positive lymph node in retroperitoneal region. Lung metastases were seen in one patient (M1). Four patients had bone metastases.

At restaging, 2 of 3 patients showed multi-nodular uptake and one patient showed diffuse + multi-nodular uptake.

Conclusion: 18F-FDG-PET/CT is useful for detecting distant metastasis and for evaluating activity of supraclavicular, abdominal lymph nodes and bone metastases. It is also useful for identifying unsuspected disease.

IAEA-CN-232/336

**Diffuse Large B-Cell Lymphomas: Utility of Interim
18F-FDG-PET/CT to Predict Early Treatment Response**

**L. Melillo¹, G. Bruno², S. Traverso², M. Namias², P. Parma¹,
M. Zerga¹, C. Gonzalez², G. De Stefano¹, S. Cugliari¹, M. Miodosky¹,
C. Tinetti², F. Jaimez, Fernando²**

¹ Instituto Oncologico Angel Roffo

² Fundacion Centro Diagnostico Nuclear

Corresponding Author: gbruno.idm@gmail.com

Background: PET/CT is a proven useful tool to evaluate initial staging and assess treatment response in Hodgkin lymphomas, however, in diffuse large B-cell lymphomas (DLBCL) the treatment response is more controversial because of the high incidence of false positives that have been reported in the literature.

Objective: To evaluate the utility of the interim PET/CT (I-PET) to predict early treatment response and its correlation with end of treatment PET/CT (E-PET), in patients with confirmed DLBCL.

Methodology: This is an observational, prospective study. From July 2009 to January 2015, 26 patients with diagnosis of DLBCL before treatment were included. All of them underwent 3 whole body 18F-FDG-PET/CT studies utilizing GE Discovery STE 16 equipment in different stages of the disease:

- Baseline PET/CT
- Interim PET/CT (after 3rd cycle of chemotherapy)
- End of treatment PET/CT (after 6th cycle of chemotherapy)

The FDG uptake of the lesions was evaluated using visual parameters and compared among the 3 PET/CT studies. All patients' treatment remained unchanged after I-PET results. Subsequently, the same patients with positive E-PET underwent histological confirmation.

Results: Of the 26 patients evaluated 10 (38.5%) had complete metabolic response as shown by negative I-PET scans, they were also negative in the E-PET scans and remained free of disease with a mean follow-up of 43 months (NPV = 100%). In the remaining 16 (61.5%) patients a metabolic reduction was observed in the I-PET, and they were considered as partial responders and in the E-PET, 5 of them showed metabolic complete response, 8 continued with partial response and 3 had a progression of disease. In those 8 patients with partial response in the E-PET, only 2 showed complete pathologic response (E-PET false positives) and the remaining 6 patients continued treatment (I-PET PPV = 56.3%, E-PET PPV = 81.8%).

Conclusion: I-PET in DLBCL predicted early treatment response, since all patients with negative I-PET remained free of disease with a mean follow-up of 43 months, indicating a high negative predictive value. However, the I-PET has a low positive predictive value, making it difficult to identify non-responder patients based on interim PET/CT results only.

IAEA-CN-232/337

Preliminary Dose Assessment in Paediatric Patients Undergoing PET/CT in Recife/PE in Brazil

I.V. Batista de Lacerda¹, S.C. Soares Brandão, F.R. de Andrade Lima^{1,3}, M. Liane de Oliveira^{1,3}

¹PhD student from Universidade Federal de Pernambuco - UFPE - Nuclear Energy Department

²Hospital das Clínicas da Universidade Federal de Pernambuco - HC/UFPE

³Centro Regional de Ciências Nucleares do Nordeste - CRCN-NE/CNEN

Corresponding Author: simonecordis@yahoo.com.br

Background: Nuclear medicine use in paediatric patients is beneficial mainly in tumours of the nervous system and lymphoma. The most common imaging technique used for diagnosis, staging and monitoring of lymphomas is PET/CT, which is a hybrid technique involving two simultaneous sources of radiation exposure to the patient. Due to high radiation doses associated with this examination and the possible radiation effects on the human body, it is important to perform dosimetric studies to optimize the radiation levels that children are being exposed to. The aim of this study is to evaluate the effective dose received by paediatric patients with lymphoma in PET/CT exams.

Methodology: The effective dose was estimated for paediatric patients with lymphoma undergoing PET/CT exams (Siemens Biograph 16 PET/CT scanner) in Recife/PE, Brazil. The model proposed by ICRP Publication 106 offers coefficients (Γ) that allow estimating the absorbed dose in organs and the effective dose to the patient as a function of the radioactivity administered, the radionuclide utilized and the patient's age. Regarding the estimate of the external dose due to the CT examination, we used the CTDIvol and DLP values estimated by PET/CT scanner to calculate the effective dose, through the utilization of k coefficients specific to each region analysed which are made available by the National Radiological Protection Board (NRPB) and the European Guidelines. In order to ensure the proper operating condition of the scanner, the quality control tests recommended by the manufacturer were performed.

Results: Six patients were evaluated; four of them males, mean age 14.7 years (age range 11-17 years). The average activity administered in an individual PET study was 4.7 MBq/kg (range: 3.7 to 5.6) and the parameters for the CT technique have been set optimally depending on the patient's body features by CARE Dose4D™ function. The effective doses received were between 6.9 and 17.1 mSv. In Brazil, studies to evaluate the dose in paediatric patients undergoing PET/CT are scarce, especially in relation to dose from CT. According to a 5-year retrospective dosimetric study in children, the average effective dose in PET/CT study was 24.8 mSv (range: 6.2 to 60.7).

Conclusion: The effective doses received by these children from PET-CT studies performed were quite different, but they were within the expected range described in the literature. Procedures that expose children to radiation should be optimized in order to minimize the radiation dose but provide appropriate image quality for diagnostic information. The results reported in literature, reinforced by this work, indicate the need for harmonization and optimization of procedures involving ionizing radiation. This is necessary because during the medical treatment, the patients usually are exposed many times to different radiation sources. However, few nuclear medicine services perform dosimetric control for paediatric

International Conference on Clinical PET-CT and Molecular Imaging (IPET 2015): PET-CT in the Era of Multimodality Imaging and Image-Guided Therapy

patients.

IAEA-CN-232/338

**18F-FDG PET/CT Demonstrates Objective Response to
Alternative Chemotherapy in Breast Cancer**

J.G Rank¹, A.G. Garcia Cainzo¹, M. Hjelt²

¹ CNEA

² SAR

Corresponding Author: gerardorank@hotmail.com

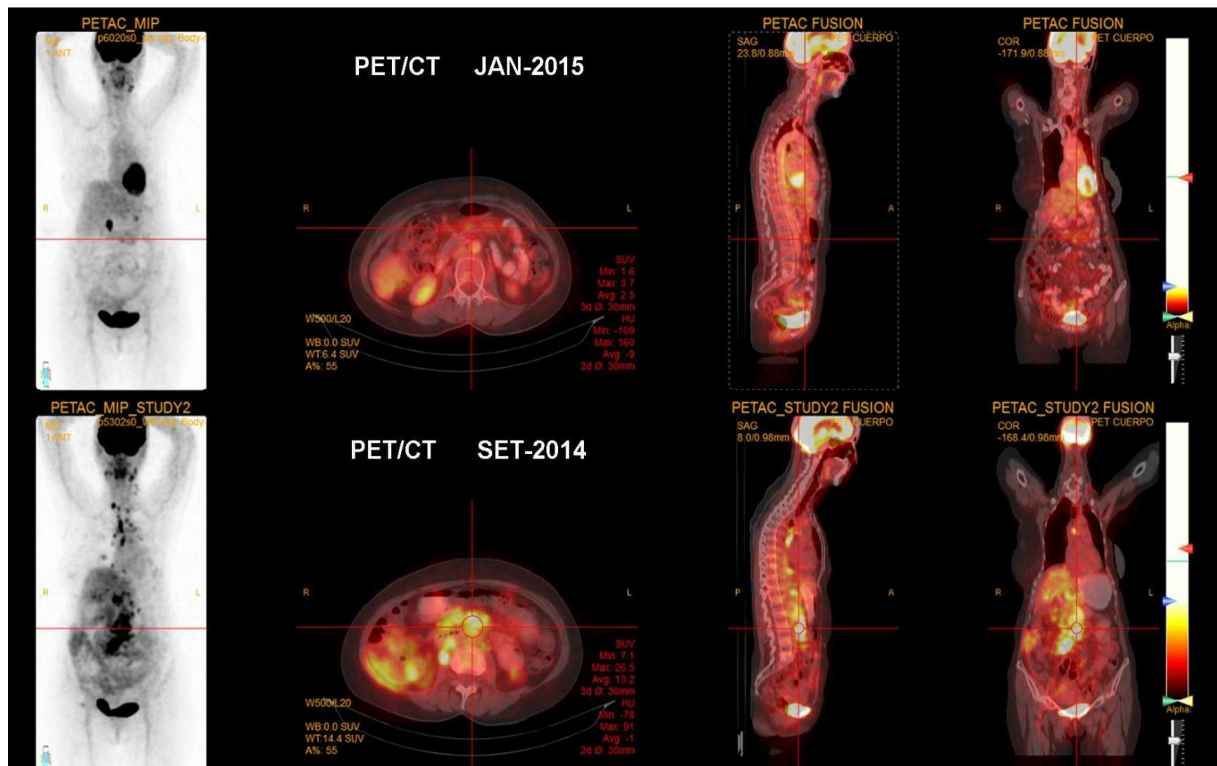
Background: We present a case of a 62 year-old woman with invasive ductal carcinoma of the breast. She completed neoadjuvant chemotherapy (docetaxel 30 mg, 7 cycles 2002-2003) and underwent left total mastectomy in March 2003. She received radiation therapy until September 2003 and tamoxifen for 5 years (2003-2008). PET/CT in February 2014 showed hepatic metastasis and multiple nodal disease in the chest and belly. New chemotherapy plan was installed with paclitaxel (8 cycles from March to August 2014). An interim PET/CT revealed partial response.

18F-FDG PET/CT in September 2014 showed metastasis in the right laterocervical and supraclavicular lymph nodes, mediastinum, mesenterium, hepatic hilum and retroperitoneum demonstrating an increased number of abnormal hypermetabolic foci (progressive disease). See figure 1 (Lower set of images).

The patient received ixabepilone 40 mg/m² plus capecitabine 2,000 mg/m² in four cycles till December 2013 and she was assessed with a new 18F-FDG PET/CT scan to evaluate the tumour response.

Methodology: Every 18F-FDG PET/CT scan was performed in the same centre with a Philips Allegro PET scanner and Marconi MX 8000 CT scanner, under typical 18F-FDG preparation and dosage.

Results: January 2015 PET/CT scan (see figure 1 upper set of images) shows dramatic attenuation of hypermetabolic lesions. Only low persistence is seen in left submandibular region, presenting an SUV_{max} of 3.1. Mediastinal and liver uptake did not exceed an SUV_{max} value of 2.8.



Conclusion: In clinical follow-up, the patient stays asymptomatic. Ixabepilone plus capecitabine is a recently available alternative in patients with metastatic breast cancer resistant to anthracyclines and to taxanes. 18F-FDG PET/CT plays an important role in the work-up and monitoring of metastatic or recurrent breast cancer as demonstrated in this case.

IAEA-CN-232/339

The Advantage of 18F-FDG PET/CT in Staging of Young Population with Breast Cancer

H. Indrawati, H. Budiawan

MRCCC Siloam Hospitals

Corresponding Author: dr.hapsari2011@yahoo.com

Background: Breast cancer is a common disease with a highly variable outcome. Younger age at breast cancer diagnosis confers inferior prognosis compared to older age, therefore indicating that accurate tumour staging is important. The use of 18F-FDG PET/CT in this population is still controversial. There is guidelines that discourage the use of 18F-FDG PET/CT scan in young patients with stage I-II diseases. This study aimed to evaluate the use of 18F-FDG PET/CT for staging of cancer patients younger than 40 years of age with stage T1-T2 in our population.

Methodology: Retrospective study used data of all patients with breast examination from 2011 to 2014. Eligibility criteria included patients with primary tumour sized ≤ 20 mm and > 20 mm but ≤ 50 mm in greatest dimension. Patient aged > 40 years and patients with inflammatory breast carcinoma were excluded. All subjects underwent 18F-FDG PET/CT scan before having any treatment such as surgery, chemotherapy, or radiotherapy.

Results: Between July 2011 and December 2014, there were 545 breast cancer patients. The inclusion criteria were met in 11 of 61 young patients. 18F-FDG PET/CT revealed unexpected regional axillary nodal metastases in 6 patients, and extra-axillary nodal metastases in the other 4 patients. Upstaging to stage IV was found in 4 patients. Of the 4 patients, 3 patients had more than one distant metastatic site.

Conclusion: 18F-FDG PET/CT scan is beneficial in young patients with T1-T2 breast cancer by giving more accurate staging.

IAEA-CN-232/340

Challenges in Implementing Quality Assurance Programme (Qap) In PET Centres in Malaysia – A Regulatory Perspective

S.C. Saifuddin

Radiation Health and Safety Section, Engineering Services Division,
Ministry of Health Malaysia

Corresponding Author: sarene_chu@yahoo.com

Quality Assurance Programme (QAP) in Ministry of Health of Malaysia was launched in 1980s. The objective of the implementation of the QAP is to ensure customers benefit from the services provided at optimal levels with existing resources. Indicators are in place to monitor the quality of various services from the aspects of care, customer management, resources utilization, and customer satisfaction.

In the context of the implementation of the QAP using ionizing radiation for the purpose of diagnosis and therapy, the patient's interests must come first. This can be achieved with the proper and optimum dose of radiation exposure to the patients, as well as controlled radiation exposure to workers and the public, while continuously monitoring the use of ionizing radiation sources involved from the safety and security aspect. QAP implementation is also able to ensure the compliance with regulatory requirements specified under Malaysian Atomic Energy Licensing Act. Through measures such as this, hopefully the objective of implementing a comprehensive and effective QAP will be achieved.

This presentation will describe the challenges encountered in implementing the Quality Assurance Programme (QAP) in PET centres in Malaysia from a regulatory point of view.

Implementation of QAP does not just mean meeting legal requirements but also implies optimum use of equipment, personnel and resources. The Ministry of Health of Malaysia is continuously improving the quality of nuclear medicine services in Malaysia through the implementation of the QAP in Nuclear Medicine Services. The objectives of the QAP implementation are to improve the quality of services in the scope of nuclear medicine, to ensure the production of clinical information required by the optimum use of radioactivity, to make use of existing resources effectively, and to meet and comply with regulatory requirements under the Act. QAP implementation in nuclear medicine includes three elements, namely monitoring indicators, quality control of imaging equipment and related equipment and continuing professional education to all personnel involved. This presentation will discuss the challenges specifically from these three aspects related to the implementation in the PET centres in Malaysia.

IAEA-CN-232/343

The Growth of Nuclear Medicine in Mauritius

A. Naojee, H.S.G. Dustagheer

Ministry of Health

Corresponding Author: asnaojee@yahoo.com

Background: Mauritius is a small island in the Indian Ocean with a population of 1.3 million people with an increasing number of non-communicable diseases like diabetes mellitus, hypertension, cardiac diseases and cancer of breast, prostate and colon. Mauritius has a national cancer registry and a cancer actions plan programme.

The Nuclear Medicine Department was created in Mauritius by the Ministry Of Health and Quality of Life under an IAEA project in 2001. A single head SPECT gamma camera was installed which allowed the first bone scan investigation in early May 2001.

Methodology: Staff from different departments was brought to form a critical group. With the help of several visiting IAEA experts the training of staff started. The initial training of staff was followed later by several short IAEA fellowship trainings at different Nuclear Medicine centres abroad. The initial staff was comprised of two radiologists, one radiotherapist and one radiographer technician. One year later two more radiographers joined the group. The challenge was to have a proper structuring of the Department which is still a problem even today.

A second gamma camera, a Mediso dual head SPECT, was introduced in 2008 to address the increase in number of non-communicable diseases in Mauritius

Much effort has been made to increase the number of referrals for cardiac studies. It was a challenge, since cardiologists prefer to stick to their own methods of investigations.

In 2013 we introduced pharmacological stress test with dipyridamole to perform MPI studies and it was a breakthrough. This has increased the number of referrals to such an extent that we have now an important waiting list.

14-day supply of Technetium generator was rescheduled to weekly supply.

With the increase in certain types of cancer, more patients are subjected to PET/CT investigations abroad as requested by physicians. For better health care management we initiated a national PET/CT project.

Structuring of the Department is in process to enable human capacity building and to add new services.

Results: The steps taken have made the only department to grow slowly and steadily to a well sustainable health service which is well integrated in the existing health system. The number of investigations performed yearly is steadily increasing with a very good investigations to people ratio (0.1%) especially in bone and renal examinations, and even more so in cardiology.

Conclusion: It is with the continuous support of the Ministry of Health that we have achieved good progress and a sustainable service upon which the physicians are very much dependent. The IAEA has a major role in this achievement. The way forward now and a great challenge is the introduction of hybrid imaging PET/CT by 2017 in Mauritius, under the national project MAR 6013 with the IAEA.

IAEA-CN-232/344

Comparison of SUV Lean Body Mass Using TOF and Non-TOF Reconstruction Technique

N. Das, A. Kumar, R. Mishra, J. Cherian, D.C. Pandey, N.D. Joshi

Dr. B L Kapur Memorial Hospital, New Delhi, India

Corresponding Author: nitendradas@gmail.com

Background: Time-of-flight (TOF) PET/CT has been shown to have great potential in oncologic applications, and recent works have demonstrated improvements in visibility of lesions. This study was done to evaluate the differences in standardized uptake value (SUV lean body mass) in TOF vs. non TOF PET reconstruction technique in a time of flight PET/CT scanner using HD mode acquisition.

Methodology: PET/CT was acquired in HD non-TOF mode 50-60 minutes after injection of 370 MBq of ¹⁸F-FDG in 20 patients in a GE discovery 710 PET/CT time of flight scanner. Retro-reconstruction of acquired data was done in time of flight HD (sharp IR) mode (TOF) and compared with non-time of flight HD (sharp IR) mode. Number of iterations, subsets and filter cut-off were kept constant for both modes. SUVlbm values were later calculated on Advantage window 4.6 using volume ROI. The visual comparison of TOF and non-TOF images was performed independently by 2 nuclear medicine physicians with adequate experience.

Results: Total of 88 lesions were analysed quantitatively and qualitatively in 20 patients. SUVlbm max was corrected for lean body mass. In TOF reconstruction the SUVlbm value ranged from 2.6 - 25.22 and in non-TOF reconstruction it ranged from 2.06 to 25.66. Out of total of 88 lesions, 65 lesions showed an increase in SUVlbm value in the range of 0.1 - 2.34 and 22 lesions showed a decrease in SUVlbm value in the range of 0.01 - 1.29 on TOF reconstruction as compared to non-TOF reconstruction. One lesion showed no difference in SUVlbm in both techniques. Positive variation was seen in smaller lesions with maximum diameter of less than 1 cm. Qualitatively the lesions appeared sharper with better defined margins and lesser degree of edge blurring effect. The data was then analysed using T test and the difference was not found to be significant (p value 0.17).

Conclusion: There is no statistically significant difference in SUVlbm values calculated in TOF PET and non TOF PET/CT reconstruction techniques.

IAEA-CN-232/345

Is PET/CT More Sensitive than Bone Marrow Biopsy for Detection of Bone Marrow Involvement in Lymphomas

R. Mishra, A. Kumar, N. Das, J. Cherian, D.C. Pandey, N.D Joshi

Dr.B.L.Kapur Memorial Hospital, Pusa Road, New Delhi-110005

Corresponding Author: drrohini.mishra@gmail.com

Background: Lymphoma is the sixth most common cancer form in both males and females. Hodgkin lymphoma (HL) accounts for approximately 10 % of all lymphomas and approximately 0.6 % of all cancers diagnosed in the developed world annually. Non Hodgkin lymphoma (NHL) accounts for 4% of new cancer cases and 4% of cancer related deaths. Morphologic bone marrow infiltration (BMI) occurs in 30 to 50 % of all patients with NHL, most commonly in the indolent histology. The incidence of BMI is reported to be 4-14 % in HL and 23.8% in NHL as assessed by iliac crest bone marrow biopsy. Hence the bone marrow evaluation is very important in the staging of lymphoma. Bone marrow biopsy (BMB) is the standard for the evaluation of marrow involvement but it has limitations. PET/CT has been recommended in staging of lymphoma, and bone marrow uptake of 18F-FDG correlates with the involvement of lymphoma. The aim of this study was to assess the utility of PET/CT in the detection of BMI in patients of lymphomas and compare the results with BMB.

Methodology: A retrospective study of 88 patients with lymphoma (60 NHL and 28 HL cases) was done. A staging PET/CT and bone marrow biopsy was done for each patient. All the patients were followed up after the treatment with whole body PET/CT.

Results: Bone marrow infiltration was detected in 12 (23.3%) cases of HL and 27 (45%) cases of NHL by PET/CT and in 1 (3.5%) case of HL and 18 (30%) cases of NHL by BMB. Concordance between PET/CT and BMB was observed in total 68 patients (77%), out of which 19 cases had positive PET/CT and BMB results and 49 negative PET/CT and BMB results. Marrow biopsy was performed from iliac bones. Discordant results were observed in 20 patients (22.7%) with positive PET/CT and negative standard bone marrow biopsy results. The sensitivity, specificity, positive and negative predictive values of 18F-FDG-PET/CT were 88%, 90.9%, 88%, and 90.9%, respectively and for bone marrow biopsy they were 32%, 90.9%, 79%, 58% (lower limit of 95% confidence interval). The significance of results was analysed by Z test and they were found to be significant ($p=0.00132$ i.e. <0.05).

Conclusion: PET/CT is more sensitive in detecting BMI in lymphomas as compared to BMB with high positive and negative predictive values.

IAEA-CN-232/347

68Ga-PSMA PET/CT in the Evaluation of Prostate Cancer Patients

**S. Ballal¹, P. Chakraborty², P. Thakral¹, M. Tripathi³, C.J Das⁴,
C. Bal⁵**

AIIMS, New Delhi, India

Corresponding Author: csbal@hotmail.com

Background: Prostate specific membrane antigen (PSMA) is up-regulated in prostate cancer and its metastases. ¹¹¹In-capromab pendetide, a commercially available monoclonal antibody, has been used to target PSMA for prostate cancer imaging. However, it binds to the intracellular domain of PSMA where internal binding occurs mainly in the dead cells. A newer urea-based motif (Glu-NH-CO-NH-Lys) agent, Gallium (III) chelator N,N'-bis [2-hydroxy-5-(carboxyethyl)benzyl] ethylenediamine-N,N'- diacetic acid (HBED-CC) (68Ga-PSMA HBED-CC) has been designed to target the extracellular domain of PSMA. In this on-going study, as a primary objective we present the utility of 68Ga-PSMA HBED-CC for assessing primary tumour, lymph nodal involvement and distant metastasis. As a secondary objective we compared 68Ga-PSMA HBED-CC with ^{99m}Tc- Methylene diphosphonate (^{99m}Tc-MDP) bone scan findings in the detection of skeletal metastasis.

Methodology: A total of 83 patients with high Gleason scores and/or rising PSA levels underwent 68Ga-PSMA PET/CT either for the purpose of pre-operative staging or to look for recurrence of the disease post-operatively. 30 minutes post-injection of 92.5 MBq tracer, scans were acquired in mCT scanner (Siemens, Germany). The scan interpretations were done by two experienced nuclear medicine physicians; both were blinded to the clinical and radiological data of the patients. All lesions with focal increased uptake higher than the background were considered as pathological. In patients with skeletal metastasis 68Ga-PSMA scans were compared with conventional ^{99m}Tc-MDP bone scans to look for concordance by McNemar's test. P value <0.05 was considered significant.

Results: Total of 83 patients (age ranging from 38 to 83 years; mean \pm SD 65 \pm 9years) were recruited. 44 underwent the examination for initial staging while 39 patients for suspected recurrence. The mean serum PSA level was 156.45 ng/mL (range: 0.26 – 2166.45 ng/mL) and the mean Gleason score was 7.1 \pm 1.1. In the 68Ga-PSMA images, local residual/recurrent disease uptake, lymph node, bone, and other soft tissue metastases were detected in 43 (51.8%), 34 (40.9%), 36 (43.3%) 11 (13.2%) patients, respectively. The qualitative comparison of skeletal metastasis between 68Ga-PSMA and ^{99m}Tc-MDP scan revealed, 24 patients had both scans positive, and 41 patients had both scans negative, leading to 65 (78.3%) concordant and 18 (21.7%) discordant results. In analysing discordant results, 68Ga-PSMA scan identified additional lesions in 9 patients which were missed by ^{99m}Tc-MDP scans. Similarly ^{99m}Tc-MDP scans identified additional lesions in 6 patients that were missed by 68Ga-PSMA. However, there was no statistically significant difference (P= 0.237) between the two modalities as far as the skeletal lesion detection is concerned.

Conclusion: 68Ga-PSMA PET/CT appears to be 'one-stop-shop' imaging agent in prostate cancer evaluation with high detection rates of primary/recurrent tumour, lymph nodes, bone and soft tissue metastases. Our results encourage the theranostic approach of PSMA-targeted imaging and therapy in prostate cancer.

IAEA-CN-232/349

The First Year Experience of PET/CT Utilization in a Newly Built Private Hospital

D.N. Prawiro

Corresponding Author: djoko60@yahoo.com

Background: In many countries PET/CT is often utilized by clinical doctors as a diagnostic tool. PET/CT is a useful diagnostic tool in oncology disease management, and also in the fields of neurology and cardiology. In 2010, Indonesia started PET/CT in one hospital. In early 2011, a newly built private hospital, MRCCC Siloam Hospital, installed a second PET/CT with a cyclotron. The PET/CT started to be utilized in April 2011, with two days a week schedule which increased to four days a week.

The purpose of this study was to describe the experience of the first year of PET/CT utilization in the newly built MRCCC hospital.

Methodology: Retrospective descriptive study was performed from April 2011 to December 2011. Number of patients: 243, 107 men and 126 women. Age: 4 - 88 years old. Blood sugar level: 68 - 202 mg/dL. Height: 106 - 184 cm. Weight: 15 - 110 kg. Radiopharmaceutical injection - time to scan: 50 - 122 minutes. Doses of 18F-FDG: 2.9 - 19.5 mCi. The number of cases: April: 7, May: 1, June: 3, July: 22, August: 40, September: 47, October: 32, November: 39 and December: 52.

PET indications in oncology include early detection, staging, restaging, therapy evaluation, evaluation of malignancy, and radiotherapy treatment planning.

Results: Main indications of PET/CT oncology studies in MRCCC were:

1. Post-therapy evaluation in 183 cases: 40 breast carcinoma, 24 lung carcinoma, 19 hepatocellular carcinoma, 17 carcinoma of the colon/rectum, 17 lymphoma, 10 nasopharyngeal carcinoma, 7 prostate carcinoma, 6 ovarian carcinoma, 6 endometrial carcinoma, 5 thyroid carcinoma, 3 cervical carcinoma, 3 carcinoma of tongue, 3 gastric carcinoma, 3 renal cell carcinoma, 2 parotid carcinoma, 2 neuroendocrine tumours, 2 abdominal tumours, and the others: MPNST, palatum durum cell carcinoma, carcinoma of the appendix, pancreatic carcinoma, teratoma, germinoma, carcinoma of the oesophagus, rhabdomyosarcoma, neurofibromatosis, adrenal carcinoma, tumours of the spine, laryngeal carcinoma, gall bladder carcinoma, glioma, and malignant melanoma.

2. Carcinoma of unknown primary in 27 cases: 9 multiple bones metastases, 9 mass of the body, 8 brain metastases, and neurological paraneoplastic caused by tumour.

3. Diagnostic purpose in 8 cases: 4 lung nodules, 3 suspected prostate carcinoma, 1 breast nodule.

4. Early detection in 5 cases: medical check-up with a family history of carcinoma.

5. Weight loss with suspected malignancy in 4 cases.

6. The other 9 cases: FUO and other cases.

Non oncology/neurology study: Brain PET in 3 cases (2 cases of dementia and 1 of epilepsy).

Conclusion: Early phase of 18F-FDG PET utilization showed that oncological studies were more requested compared to neurology/cardiology studies. The main oncological PET/CT studies were post

International Conference on Clinical PET-CT and Molecular Imaging (IPET 2015): PET-CT in the Era of Multimodality Imaging and Image-Guided Therapy

therapy evaluation, carcinoma of unknown primary, diagnostic purpose, and early malignancy detection. No cardiology studies were conducted. Total patient number per month was increasing through time.

IAEA-CN-232/350

Association of 18F-Flouroethylcholine PET/CT with Gleason Score in Prostate Cancer

M. Modiselle, M. Vorster, M. Sathekge

Department of Nuclear Medicine, University of Pretoria & Steve Biko Academic Hospital

Corresponding Author: modisellemoshe@yahoo.co.uk

Background: The Gleason score is well-recognised for predicting prognosis in PC with the score of 7(4+3) being associated with a poorer outcome and when combined with other relevant clinical information it helps in selecting the most appropriate course of therapy. PET/CT imaging plays an important role as a non-invasive modality in the staging, restaging, treatment response monitoring and prognostication of oncology patients

The objectives of this study were to evaluate the potential value of 18F-flouroethylcholine (18F-FECH) PET/CT in the detection of malignant lesions in various stages of histologically proven PC and correlate the image findings with the Gleason score.

Methodology: Thirty patients with biopsy proven PC underwent 18F-FECH PET/CT imaging. The 18F-FECH PET/CT images were evaluated qualitatively and quantitatively and compared to the results of histopathological grading using the Gleason score.

Results: Patients included in the study had an average age of 65 years. Twenty-two patients demonstrated abnormal pelvic- and or extra-pelvic findings on 18F-flouroethylcholine PET/CT, which was consistent with malignant or metastatic involvement. The prostate SUVmax could not be used to predict the presence or absence of metastatic disease. Seventeen patients (56%) had a Gleason score of $\geq 4+3$. Higher Gleason scores were statistically significantly associated with the presence of metastatic disease ($P=0.025$). We also found a significant association between higher scores ($\geq 4+3$) and more uptake and severe metastatic disease.

Conclusion: 18F-flouroethylcholine PET/CT may be useful in patients with high risk prostate cancer (Gleason score $\geq 4+3$) to evaluate for distant metastases, predicting prognosis and in guiding for further management.

IAEA-CN-232/351

4 D-PET/CT for Radiotherapy Planning: How Many Phase-Bins?

C. Cavedon, E. Zivelonghi, P.M. Polloniato, S. Guariglia, M.G. GIRI, M. Zuffante, D. Grigolato, M. Cucca, R. Mazzarotto, M. Ferdeghini

Azienda Ospedaliera Universitaria Integrata - Verona

Corresponding Author: carlo.cavedon@ospedaleuniverona.it

Background: There is no standardization in the number of phase-bins to use in 18F-FDG respiratory-gated PET-CT (4D PET-CT) used in radiotherapy treatment planning. The aim of this study was to find the optimal number of phases as a balance between accuracy of SUV estimation and preservation of the signal-to-noise ratio.

Methodology: 21 patients with tumours in the chest or upper abdomen were studied with 18F-FDG 4D PET-CT. Only patients that showed respiratory-induced tumour motion greater than 5 mm were enrolled. 4D PET-CT was performed by means of a Philips Gemini BigBore TOF scanner and the Varian RPM respiratory gating system. 3.0 MBq/kg, 2 min/bed and retrospective-mode for both PET and CT modalities were used. Images were reconstructed using 1 (no sorting) up to 10 phase bins. SUV_{max} values within the lesion were studied as a function of the number of phase-bins. The smaller number of phase bins that allowed SUV quantification no less than 90% compared to the gold standard (10 phases) was considered as optimal.

Results: Lesions with range of motion greater than 10 mm required at least 5 phase-bins to be used to conform to the criterion given above. Smaller ranges of volume were accurately described by a lower number of phases (typically 4). SUV_{max} measured at max exp. was on average 63.2% higher in the gated acquisition (10 phases) compared to the non-gated case (range 11.5% - 328.3%). The underestimation of SUV in non-gated PET-CT was strongly dependent on lesion volume and location, small lesions in the lower lung region being the most affected. When comparing 4D PET-CT in 5 and 10 phases, the underestimation was 9.5% (range 2.0%-29.2%). The corresponding value for 6 compared to 10 phase bins was 6.9% (range 0.0%-23.3%). Compared to even numbers, the use of an odd number of phases better identified the full-exhale phase, often used in treatment planning because of better reproducibility compared to other respiratory states.

Conclusion: 4D PET-CT offers an advantage in 18F-FDG SUV quantification for tumours that move with respiration compared to 3D techniques. The balance between acquisition/reconstruction time, SNR and accuracy of SUV estimation proved to be achievable with 5 phase-bins. It is also expected that SUV-based volume quantification is less prone to inconsistent results when respiratory gating is used, a result confirmed by a preliminary test with gradient-based segmentation algorithms. 4D PET-CT can improve SUV quantification in tumours that move with respiration. This might be especially useful when metabolic data are used to help delineate reference volumes in radiation oncology. Validation of these findings with a phantom capable of reproducing realistic motion patterns is ongoing.

IAEA-CN-232/352

An Analysis of 46 Thyroglobulin Elevated Non Iodine Secreting (TENIS) Syndrome Patients' Data with Respect to Multiple Risk Factors and 18F-FDG PET/CT Findings

J. Das, S. Ray

Tata Medical Center, New Town, Kolkata, India, 700156

Corresponding Author: drsoumenray@gmail.com

Background: The aim of this study was to explore the correlation of the possible risk factors for developing iodine refractory TENIS syndrome in differentiated thyroid cancer and corroborate them with 18F-FDG PET/CT findings.

Methodology: A total number of 536 differentiated thyroid cancer patients received high dose radioiodine therapy over a period of 3 years. Six months after radioiodine therapy, the patients were evaluated with TSH stimulated thyroglobulin estimation, whole body I-131 scan and chest x-ray. 46 patients had developed TENIS syndrome on follow up. 18F-FDG PET/CT was performed in all patients to decide further management. The follow up data were retrospectively analysed taking into consideration the histopathological findings, focality, extrathyroidal extension, lymph node metastasis, extranodal extension, tumour size and the imaging findings.

Results: 41 out of 46 TENIS syndrome patients had papillary thyroid cancer. Three patients had follicular cancer, one patient had mixed papillary and follicular cancer and the other one had poorly differentiated cancer. In 38 % patients the cancer was multifocal. Extrathyroidal extension was present in 46% of them. 34 out of 46 TENIS patients had undergone lymph node dissection during initial surgery and lymph node metastasis was present in 88% of them. Extranodal extension was noticed in 48 % of patients. 43% patients had either T3 or T4 lesions, and with T2 disease also considered, 68% had larger primary lesion (T2, T3 or T4). On follow-up, whole body I-131 scan was negative in all of them with elevated thyroglobulin (range 11.3 ng/ml to 15355 ng/ml). 18F-FDG PET/CT showed metabolically active lesions in 47 % of patients and in another 28 % CT images of PET/CT showed non-FDG avid findings which might contribute to raised thyroglobulin like cervical lymphadenopathy or lung nodules. 12 out of 22 TENIS patients with FDG avid lesions had undergone lymph node dissection and histopathology was positive for metastatic disease in 11 (91%) of them. Postoperative pre I-131 therapy USG showed residual thyroid disease (0.1 to 1.3 cc) in 6 cases (13%) and apparently involved lymph nodes in 19 (48%) of patients. 13 out of 19 (68%) patients with abnormal nodes in USG did not show any I-131 avidity in those nodes in the post therapy scan. Six of these patients showed FDG avid neck nodes in the follow-up PET scans, though it may not have been exactly the same node which was identified in the initial USG.

Conclusion: 18F-FDG PET-CT could detect lesions possibly leading to elevated thyroglobulin in 76% patients. In the subset of PET positive patients with FDG avid lesions who underwent neck dissection the positive predictive value of PET was found to be very high (91.6%). Postoperative USG is of immense importance to predict transition to iodine refractory state especially if the nodes are non-iodine avid in post therapy scan. Multifocality, extrathyroidal extension and tumour size appear to be important contributing risk factors but more number of cases are to be studied to reach a statistically significant conclusion.

IAEA-CN-232/353

**Building Integrity of Nuclear Medicine into the Cardiology
Field: The Mauritian Experience**

**H. Sonea, L. Savurimuthu, V. Sungkur, C. Ahgun,
H.S. Dustagheer, A. Naojee**

Nuclear medicine Department, J.Nehru Hospital, Rose Belle, Mauritius

Corresponding Author: vhsona@gmail.com

Background: There is a high prevalence of coronary artery disease (CAD) among the Mauritian population. Diagnosis of CAD is traditionally made using conventional methods including ECG, physical stress test, cardiac echography, bio-chemistry and clinical assessment.

Since the setting up of the only Nuclear Medicine Department in Mauritius at J. Nehru Hospital, our attempts to convince cardiologists to adopt nuclear cardiology imaging have not been very successful. Cardiologists were very much conservative in their conventional assessment. This experience strangely shows how physically compromised patients paved the way to a fully developed Nuclear Cardiology Unit and made cardiac molecular imaging a well-accepted modality among cardiologists.

Methodology: Nuclear medicine services started in 2001 at J. Nehru Hospital, at Rose Belle, Mauritius, but almost no examinations in the field of nuclear cardiology were performed, apart from occasional LVEF assessments. Although several presentations were made in different hospitals referrals for cardiac scintigraphy (treadmill method) from medical and cardiac units were rare.

In the beginning of 2014 our Department started implementing pharmacological stress test.

90 cases (from Jan 2014- June 2014) were studied. In January 2014 only 5 cases were performed and the number of cases grew steadily.

From January to March 2014 out of 44 patients, 31 patients were physically handicapped (70%), and 9 patients were referred to us as their physical stress test were inconclusive (20.4%); 4 patients were in good physical condition (9%). All these patients were subjected to pharmacological stress test using dipyridamole.

From April 2014 to June 2014 the profile of the remaining 46 patients needing pharmacological stress test showed some changes. Twenty one patients were physically compromised (45.6%), 7 of them had inconclusive physical stress test (8.7%) and 18 (39.1%) were patients in good physical condition who were under cardiac problem investigations.

Results: Nuclear medicine physician has used a standard template in writing cardiac report. The following critical information was documented in their report: viability of myocardium, vessels involved, ejection fraction, ventricular dilatation and wall motion. It took only 6 to 8 months to notice how the interest from the Cardiac Unit grew. The physically compromised patients were still referred to the Nuclear Medicine Department but the number of patients in good physical condition grew steadily.

Conclusion: Initially cardiologists preferred to stick to their own physical stress test. At the beginning only physically handicapped patients were referred for pharmacological stress test as cardiologist had no choice (otherwise many of these patients would have been planned directly for cardiac angiography). Cardiac scintigraphy reports for these patients have been very promising so that nowadays many patients in good physical condition are referred for pharmacological stress test as well. In fact, cardiac scintigraphy has become a complimentary modality. This is how physically compromised patients have

International Conference on Clinical PET-CT and Molecular Imaging (IPET 2015): PET-CT in the Era of Multimodality Imaging and Image-Guided Therapy

paved the way to a fully-fledged Nuclear Medicine Cardiac Imaging Service. Cardiac imaging is now a well-accepted modality in our institution. At present we have a waiting list of 250 patients needing cardiac scintigraphy. Referrals are from all the 5 major Hospitals of the island.

IAEA-CN-232/354

The Impact of 18F-FDG PET/CT Imaging in the Management of Patients with Iodine Negative Thyroglobulin Positive Thyroid Cancer

M. Urhan, E. Akdemir, S.A. Ay, A.I. Filiz, F. Deniz, Y. Kurt

GATA Haydarpaşa Training Hospital

Corresponding Author: muammerurhan@yahoo.com

Background: Differentiated thyroid carcinoma has a good prognosis compared to other organ malignancies. However, in up to 30% of the patients the recurrent or metastatic lesions lose the ability to take up radioiodine due to dedifferentiation and pose a diagnostic and therapeutic dilemma. Surgical intervention remains the only option for a potential complete cure if thyroid cancer cells are localized accurately. In this study, we investigated the impact of 18F-FDG PET/CT in patients with a clinical suspicion of the recurrent and metastatic disease because of elevated serum thyroglobulin levels and negative radioiodine whole-body imaging.

Methodology: A total of 115 patients with differentiated thyroid carcinoma (85 female, 30 male; age range, 16-93 years) were included in the study. The histology was papillary thyroid cancer in 101, follicular in 8, and poorly differentiated in 6 patients. All patients underwent thyroid surgery with high dose radioablation 2 to 14 years before. In the surveillance period, patients with elevated serum thyroglobulin levels (>2 ng/dl) underwent ultrasound of the neck and diagnostic radioiodine scanning and those with negative whole-body imaging were enrolled for 18F-FDG PET/CT imaging. PET imaging was performed one hour after IV injection of approximately 350 MBq of 18F-FDG and positive scan findings were correlated with those of histology and morphological imaging modalities.

Results: 18F-FDG PET/CT imaging was positive in 65 patients and 57 of them were proved to be true-positive. Malignant lesions were detected in the neck in 44 patients, in the mediastinum in 6, in the lungs in 4, and in the skeleton in 3 patients. In 8 patients, PET findings were false-positive; in 4, lymph nodes with increased FDG uptake detected in the neck delineated reactive/inflammatory changes and in two, with residual thymus in the mediastinum proved by histology. In another two patients focal uptake in the lungs was consistent with inflammation. The sensitivity and positive-predictive value of 18F-FDG PET/CT were 53% and 88%, respectively. In 50 patients PET/CT was false-negative; however in 8 patients, ultrasound of the neck showed metastatic lymph nodes < 1 cm in size in the lateral neck. In the remaining 42, all imaging modalities, including whole-body imaging after high-dose therapeutic radioiodine administration, failed to show any thyroglobulin-producing focus. In this group, serum Tg levels ranged from 2.1 to 22.4 ng/dl (mean: 6.8 ng/dl).

Conclusion: 18F-FDG PET/CT detected the recurrent thyroid cancer with reasonably high positive predictive values and led to surgical intervention for promising complete cure. It also contributed to further management of thyroglobulin positive and whole-body radioiodine scanning negative patients depicting distant organ metastases.

IAEA-CN-232/355

Use of Digital Electronic Personnel Dosimeter to Improve the Staff from Radiation Protection

I.K. Budak, H. Ozpinar, N. B. Akyildiz, M. Urhan

GATA Haydarpasa Training Hospital

Corresponding Author: muammerurhan@yahoo.com

Background: The aim of this study was optimize the radiation exposure, particularly from FDG, to the staff working in a nuclear medicine facility including PET/CT unit from hot lab to the end of imaging procedure.

Methodology: Radiation exposure to the staff was measured using personnel digital electronic dosimeters. A total of 10 staff including 5 technologists, 3 nurses, 1 physicist and 1 physician were enrolled in the study. All staff also carried their own conventional TLD film dosimeters during the survey. For a period of 3 months, the total number of scintigraphic and FDG imaging procedures and daily radiation measures were recorded monthly. In the second set of the measures including the last 3 months, alarm function of the digital dosimeters was set “on” when exposed radiation exceeding a certain level (>70 uSv) to produce an auditory stimulus.

Results: A total of 2 sets of measures from digital electronic dosimeters were analysed with each other for every personnel. Mean radiation dose per working month was 2.8 uSv (range: 1.2 to 6 uSv) for nurses (the highest), followed by technologists (2.2 uSv, range: 1.1 to 2.2). The physicist and the physician values were reasonably low, 0.8 uSv (range: 0.2 to 1.1 uSv). In the second set of measures when the alarm function of the digital dosimeter was “on” those values were 1.8, 1.1, 0.4 and 0.3 respectively.

Conclusion: Using a personnel dosimeter with an auditory stimulus contributed to optimizing radiation exposure significantly urging the staff to work more quickly and reducing the radiation exposure. The overall radiation exposure to the staff measured by the digital dosimeters was reduced up to 50% and minimized exposure to radiation sources.

IAEA-CN-232/356

**Establishing Nuclear Medicine Facility Guided by IAEA
Publication of Nuclear Medicine Resources Manual - Cagayan
de Oro Experience**

A. Quinon

Capitol University Medical City

Corresponding Author: alpaqu@yahoo.com

Background: Nuclear medicine clinic is new to Cagayan de Oro city. The city is situated in an island around 1000 kilometres south of Manila, Philippines. Establishing nuclear medicine outside Manila is confronted with numerous tasks. The IAEA Nuclear Medicine Resources Manual provides practical approach on creating a Nuclear Medicine section.

Methodology: This is a qualitative research based on ethnographic experience. Literature review of the IAEA manual, interviews of the medical staff and results of the previous survey were incorporated. In a span of 6 years, there were 2 nuclear medicine sections that were fully established in the city. The IAEA Nuclear Medicine Resource Manual chapter on establishing nuclear medicine services was used in providing a blueprint as to the categorization of levels of nuclear medicine, socioeconomic consideration, need for personnel training and basic infrastructure. Events such as seminars and conferences were made to educate the clinicians and staff. Attendance was checked and feedback was collected. Marketing and review on the number of referring physicians were done. The patients for treatment were given handouts and asked with regards to the general impression of nuclear medicine.

Results: The first nuclear medicine section established in 2008 became operational after 8 months of conceptualization, personnel training and acquisition of local license. Following the financial viability of the first centre, a second nuclear medicine section in the city was established. It was observed that during seminars, participants grew in number if foreign or non-local experts were invited. Post event survey shows preference on workshop or case discussions with audience participation versus conventional lecture series. Local endocrinologists' preference for RIA procedures boosts non specialist referral versus ELISA method. The use of radioactive safety precaution handouts based on the IAEA resource manual with vernacular translation helps better in understanding but does not lessen the incidence of fear from radiation harm.

Conclusion: Establishing nuclear medicine in southern Philippines presents a hurdle such as infrastructure; staff training; public, referring physician and investors acceptance. IAEA resource manual provides a useful template in starting a section.

IAEA-CN-232/357

**18F-FDG PET/CT for Delineating Intraabdominal Invasion
from Gastrointestinal or Pelvic Malignancies**

M. Urhan, E. Akdemir, I. Succulu, O. Bilgi, B. Karagoz, Y. Kurt

GATA Hayparpasa Training Hospital

Corresponding Author: muammerurhan@yahoo.com

Background: Detection of peritoneal seeding from intraabdominal and pelvic malignancy is important as this clinical situation is a common cause of morbidity and even mortality. In this study, we evaluated the role of 18F-FDG PET/CT for evaluating intraabdominal invasion originating from gastrointestinal and pelvic malignancies and its therapeutic impact on surgical management of patients.

Methodology: A total of 74 patients with a proven diagnosis of colorectal carcinoma in 33, ovarian cancer in 16, gastric carcinoma in 13, cervical cancer in 7, endometrium cancer in 5, were enrolled into the study. Patients with a clinical suspicion of recurrent of metastatic disease because of elevated tumour markers or positive abdominal CT scan findings were referred to 18F-FDG PET/CT imaging. Positive PET findings were correlated with those of cytology from aspiration of the ascites and histology from surgical intervention from either peritoneal biopsy or lesion excision.

Results: The sensitivity and specificity of 18F-FDG PET/CT were 72% and 83% respectively while abdominal CT scan had a sensitivity of 56% and specificity of 52%. More lesions were shown with 18F-FDG PET/CT than with CT scan in 28 of the patients and these findings led to a change in surgical intervention in 22 of them.

Conclusion: 18F-FDG PET/CT imaging has contributed to detecting intraabdominal invasion from gastrointestinal and pelvic malignancies. Additional information obtained from PET/CT imaging over abdominal CT scan led to alteration of therapeutic management in these patients.

IAEA-CN-232/359

A Pilot Comparison of 18F-Fluorocholine PET/CT, Ultrasonography and 123I/99mTc-Sestamibi Dual-Phase Dual-Isotope Scintigraphy in the Preoperative Localisation of Hyperfunctioning Parathyroid Glands in Primary or Secondary Hyperparathyroidism - Influence of Thyroid Anomalies

L. Michaud¹, S. Balogova², S. Perie³, J.N. Talbot¹, A. Burgess⁴; J. Ohnona¹, V. Huchet¹, K. Kerrou⁵, M. Lefrvre⁶, M. Tassart⁷, F. Montravers¹

¹ Nuclear medicine, Hospital Tenon AP-HP Université Pierre et Marie Curie

² Nuclear medicine, Hospital Tenon AP-HP Université Pierre et Marie Curie, Comenius, University, Bratislava, Slovakia

³ Otolaryngology, Hospital Tenon AP-HP Université Pierre et Marie Curie

⁴ Otolaryngology, Hospital Tenon AP-HP

⁵ Nuclear medicine, Hospital Tenon AP-HP

⁶ Pathology, Hospital Tenon AP-HP Université Pierre et Marie Curie

⁷ Radiology, Hospital Tenon AP-HP

Corresponding Author: sona.balogova@tnn.aphp.fr

Background: We compared 18F-fluorocholine (FCH) PET/CT with US and scintigraphy in patients with hyperparathyroidism and discordant or equivocal results of US and 123I/99mTc-sestamibi dual-phase dual-isotope scintigraphy.

Methodology: FCH PET/CT was proposed and performed in 17 patients with either primary (n=11), lithium induced (n=1) or secondary hyperparathyroidism (1 dialysed, 4 grafted). The standard of truth was only based on results of surgical exploration and histopathologic examination. Results of imaging modalities were evaluated, on site and by masked reading, on per-patient and per-lesion bases, lesions being grouped in 3 sites: right and left thyroid beds and ectopic areas.

Results: In a first approach, reported equivocal images/foci were considered as negative. On a per-patient level, the sensitivity (at least one abnormal parathyroid gland detected by imaging in its correct site) was for US 38%, for 99mTc-sestamibi scintigraphy 69% by open reading and 94% by masked reading, for FCH PET/CT 88% by open reading and 94% by masked reading. On a per-lesion level, sensitivity was for US 42%, for 99mTc-sestamibi scintigraphy 58% by open reading and 83% by masked reading, for FCH PET/CT 88% by open reading and 96% by masked reading. Only one ectopic adenoma was missed by the 3 imaging modalities. Considering equivocal images/foci as positive increased the accuracy of open reading of sestamibi and FCH but not of US. FCH PET/CT was significantly superior to US in all approaches, whereas it was more sensitive than scintigraphy only for open reading considering equivocal images/foci as negative (p=0.04). There was a trend that FCH uptake was more intense in adenomas than in hyperplastic parathyroid glands. Thyroid lesions were suspected on imaging in 9 patients. They may induce false-positive results as in one case of oncocytic thyroid adenoma, or false-negative results as in one case of intrathyroidal parathyroid adenoma. Thyroid cancer (4 cases) could be visualised with FCH as well as with sestamibi, but the intensity of uptake was moderate, similar to that of parathyroid

hyperplasia.

Conclusion: This pilot study confirmed that FCH PET/CT is an adequate imaging tool in patients with secondary as well as primary hyperparathyroidism, since both adenomas and hyperplastic parathyroid glands can be detected. Furthermore, the sensitivity of FCH PET/CT was higher than that of US and was not inferior to that of dual phase dual isotope scintigraphy. FCH could replace sestamibi as the functional agent for parathyroid imaging but US would still be useful to identify thyroid lesions.

IAEA-CN-232/360

**Initial Experience of 18F-FDG PET/CT in the Foundation
Clinic Valle Del Lili**

**A.M. Alvarez, L.M. Pabon Castilla, M. Renjifo, J.C. Castro, J.S. Toro ,
M. Valenzuela , F. Medina , E. Manzi**

Fundacion Valle de Lili

Corresponding Author: lpabon@yahoo.com.co

Background: At present, the application of 18F-FDG-PET/CT is widespread in the diagnostic assessment of patients in oncology, neuroimaging, infecto-inflammatory diseases and cardiology. After almost 40 years, it has become an established nuclear imaging modality that has proved its high diagnostic accuracy. The aim of this report is to describe our experience with 18F-FDG PET/CT to date in the Foundation Clinic Valle del Lili in Cali, Colombia.

Methodology: Retrospective observational study. A total of 1360 18F-FDG PET/CT scans were performed between June 2012 and February 2015. The PET/CT studies were performed in a hybrid computer - BIOGRAPH mCT128 SIEMENS (Siemens, Germany) including brain images, with previous intravenous administration of 18F-FDG, with qualitative and semiquantitative evaluation. A descriptive analysis includes demographic information, diagnosis, medical indication and the results of the studies.

Results: 1360 18F-FDG PET/CT scans were performed in a total of 1184 patients (13% had more than one study in our institute). Only 57 were paediatric patients. More than half of patients (55%) were women. The median age was 55 years (IQR: 42-65). A total of 51 patients (3.75%) had diagnosis of two or more tumours (most frequent types were thyroid (19%) and prostate (15%) cancers). Clinical indications for 18F-FDG PET/CT scans were: Oncological 1279 studies (94%), neuroimaging 52 studies (3.8%), infectious-inflammatory diseases 28 studies (2%), and one scan (0.07%) for assessment of myocardial viability with 18F-FDG.

Among the oncological studies, the most common diagnoses were lymphomas (28%, mostly non-Hodgkin lymphoma), followed by gastrointestinal tumours (20% - including the most frequent location in colon) and breast cancer (7.8%). The medical indications for performing oncology PET/CT scans were: Diagnosis (characterization of suspicious lesions) (10%), initial staging (9%), end-of-treatment response (34%), restaging (30.3%), elevated tumour markers (10%), follow up (4.6%), and monitoring response (interim) in 3 studies (0.23%). The studies were positive for malignancy in 775 cases (60.6%), negative in 416 (32.5%) and doubtful in 88 (7%).

Refractory epilepsy was the most frequent indication among neurological studies (44 cases - 84%). Only two patients diagnosed with refractory epilepsy evidenced normal brain metabolism.

Diagnosis of fever of unknown origin was the most common diagnosis among infectious-inflammatory studies (15 cases - 53%). In the group of infectious-inflammatory studies, 21 (75%) were positive and 7 (25%) negative.

A total of 338 18F-FDG-PET/CT incidental findings were identified in 331 (24%) studies (49 patients evidenced two or more incidental findings in the same study). The most common location of incidental findings was thyroid gland (21%) and brain (12%).

Conclusion: Our initial experience indicates that functional information obtained by an 18F-FDG PET/CT scan is unique. Most of the studies were done for oncological purpose, where 18F-FDG PET/CT

provides useful information required to reach a diagnosis and determine an appropriate treatment. In neurological and infectious-inflammatory diseases, ¹⁸F-FDG-PET/CT incidental findings must be further studied to rule out malignancy.

IAEA-CN-232/361

**Utilization of Serum Thyroglobulin and Anti-Thyroglobulin
in the Dose Adjustment of Radioactive Iodine in the
Treatment for Papillary Thyroid Carcinoma**

A. Quinon

Capitol University Medical City

Corresponding Author: alpaqu@yahoo.com

Background: Papillary carcinoma is the most common type of thyroid carcinoma and it is responsive to radioactive iodine (RAI) treatment post-surgery. Serum thyroglobulin (TG) and anti-thyroglobulin (anti-TG) are used to monitor treatment response. Empiric radioactive iodine (RAI) dose treatment shows no overwhelming advantage versus dose-adjusted treatment using remnant thyroid tissue uptake. The objective of this study was to utilize serum TG and/or anti-TG in the selection of patients for RAI dose adjustment.

Methodology: A total of 77 patients (12 male and 55 female) diagnosed with papillary carcinoma post-total thyroidectomy who underwent radioactive treatment from 2002-2014 were included. They were stratified based on the level of cancer aggressiveness: group 1: papillary carcinoma (normal variant), group 2: papillary carcinoma with lymph node metastases, and group 3: papillary carcinoma (follicular variant). Empiric dose was applied with 100 mCi for group 1 and 3 and 150 mCi for group 2. Dose adjustment based on residual tissues was done with serum TG >10 ng/mL and/or >30 IU/mL for anti-TG. The patients were followed-up for 1 year for the presence of the disease (WBS positive or elevated serum TG or anti-TG).

Results: Group 1 consisted of 38 patients with 11 patients who were dose adjustment (29%); empiric dose of 100 mCi of I-131 and the dose adjustment (110-130 mCi; serum TG 10.0-16.8 ng/mL; anti-TG 13-224 IU/mL).

Group 2 consisted of 26 patients with 15 patients who were dose adjusted (57%); empiric dose of 150 mCi and the dose adjustment (160-220 mCi; serum TG 12-1000 ng/mL; anti-TG 13-147 IU/mL).

Group 3 consisted of 16 patients with 5 patients who were dose adjusted (31%); empiric dose of 100 mCi with dose adjustment (120-180 mCi; serum TG 12.6-250 ng/mL; anti-TG 13-170 IU/mL).

There was no recurrence after 1 year seen in groups 1 and 3 for dose adjusted, while 8 patients (30%) in group 1 and 3 patients (27%) in group 3 showed presence of disease.

Group 2 with multiple lymph node metastasis showed a recurrence rate with dose adjustment (2/15 = 13%) and without adjustment (5/11) of 45%.

Conclusion: Serum thyroglobulin and anti-thyroglobulin levels can be used in the selection of patients who will benefit from radioactive iodine dose adjustment in papillary thyroid carcinoma.

IAEA-CN-232/362

18F-Fluorocholine PET/CT for the Detection of Progression of Castration-Resistant Prostate Cancer during Treatment

S. Balogova¹, L. Michaud², M. Tassart³, M. Wartski⁴, J.P. Lotz⁵, J.N. Talbot², A. Estes⁶, V. Nataf⁷, V. Huchet⁴, D. Avenin⁶, C. Dubot⁶, K. Kerrou⁴

¹ Nuclear medicine, Tenon Hospital AP-HP Université Pierre et Marie Curie, Paris, France, Comenius University, Bratislava, Slovakia

² Nuclear medicine, Tenon Hospital AP-HP Université Pierre et Marie Curie, Paris, France

³ Radiology, Tenon Hospital AP-HP

⁴ Nuclear medicine, Tenon Hospital AP-HP

⁵ Oncology, Tenon Hospital AP-HP Université Pierre et Marie Curie, Paris, France

⁶ Oncology, Tenon Hospital AP-HP

⁷ Radiopharmacy, Tenon Hospital AP-HP

Corresponding Author: sona.balogova@tnn.aphp.fr

Background: As various treatment regimens are available for castration-resistant prostate cancer (CRPC), the correct identification of the extent of disease is vital and imaging has a recognized role in this aim. 18F-fluorocholine (FCH) is registered in several EU-states for prostate cancer imaging and, as it can detect prostate cancer in both bone and soft tissue, FCH-PET/CT offers several advantages over anatomic imaging and bone scintigraphy.

Methodology: FCH-PET/CT was used to monitor the effect of treatment in 20 consecutive CRPC patients (mean age 74.3 years, range 66-87 years). Fifty-one tumour assessments were performed, based on changes occurring before and after intravenous (median 4 (range 1-12) cycles) or oral (median 2.5 (range 1.5-5.5) months) therapy, in physical examination, serum prostate-specific antigen levels (PSA) and FCH PET/CT. A visual score and the mean SUVmax (SUVmax-avg) of 5 index lesions defined by a reader blind to clinical information were used to compare pre and post therapy FCH imaging.

Results: Selected index lesions were 63 bone lesions and 21 lymph node lesions; none were measurable according to RECIST-1.1 criteria. Progression was detected more often visually than using the variation of SUVmax-avg, due to appearance of new foci in 20 cases (59%). Bone marrow activation related to administration of stimulating factors could be misleading but false positives can be avoided, even at a masked read. Biochemical progression (PSA increase $\geq 25\%$) was observed in 28/51=55% of cases and visual progression on FCH-PET/CT in 36/51=71% of cases, with a significant co-relationship ($p<0.02$). PSA decreased an average of 51% when no progression was visible on FCH-PET/CT vs. an average 220% increase when the visual score corresponded to disease progression ($p<0.01$). There were 7 cases where there was a progression on FCH-PET/CT but with a decline in PSA, and the reverse was observed in 1 patient who then responded to treatment. Subsequent assessments showed that the change on the FCH-PET/CT scan warning progression was correct in all cases.

Conclusion: This pilot study showed added value of FCH-PET/CT to PSA assay and clinical monitoring for detecting on-treatment progression of CRPC, including regimens targeting endocrine components.

International Conference on Clinical PET-CT and Molecular Imaging (IPET 2015): PET-CT in the Era of Multimodality Imaging and Image-Guided Therapy

Further studies are warranted to compare with criteria of the Prostate Cancer Clinical Trials Working Group-2.

IAEA-CN-232/364

Use of Small External Devices for Location of Oncological Injury with 18F-FDG PET/CT

J. Mullo

Almenara Hospital

Corresponding Author: juanmullo@gmail.com

Background: 18F-FDG PET/CT (PET/CT) standard body study is known as a routine procedure in oncology; however there are situations where image findings of a pathological focal hypermetabolic lesion cannot not be conclusive of its anatomical location. In order to clarify this situation, localized studies of PET/CT in a specific area are made using small external marker on or within the body.

Methodology: PET/CT standard body scans following the acquisition are immediately evidenced by a specialist nuclear medicine physician. In cases of pathological hypermetabolic foci located in accessible body cavities, a second PET/CT scan is performed in this area 30 minutes after completion of the first one, but this time using a small external marker. For example, for vocal cavity injury, an empty syringe can be used to open the mouth and place focus on the jaws; in gynaecological area, using a vaginal tampon leads to vaginal distension to determine the correct location of a lesion on the cervix, vagina or vulva.

Results: PET/CT scan of a certain body part with the use of small external marker in a body cavity, such as the oral cavity or the vaginal cavity, improves anatomical and spatial localization of a pathological hypermetabolic focus when compared with standard PET/CT body scan.

Conclusion: PET/CT studies using small external markers placed into a body cavity allow for a proper localisation of a pathological hypermetabolic focus.

IAEA-CN-232/365

**Nuclear Medicine in the Public Health Service in Madagascar,
Capabilities and Perspectives**

N.R. Rakotondralambo, R.A. Rasata

Service de Médecine Nucléaire CHU d'Andohatpenaka

Corresponding Author: rijandretsa@yahoo.fr

In Madagascar, the practice of nuclear medicine turns 50 this year. The only nuclear medicine service was started in 1965 with the creation of radioisotope laboratory by the Commissariat à l'énergie atomique (CEA). Madagascar, given the duration of services, should be one of the leaders in Africa in the field of nuclear medicine. Unfortunately, the department has not yet reached those standards. The goals of this study are to trace the path and to consider the future of nuclear medicine in Madagascar.

The services provided are under a nuclear physician, assisted by two residents, a general practitioner and a technologist. It has new premises in the University Hospital d'Andohatpenaka, a gamma camera, a laminar flow hood, and two ultrasounds for thyroid diseases.

The service is in close cooperation with the IAEA and numerous donors, both national and international. Therefore, results are expected to satisfy the increasing demand of isotopic examinations for different pathologies, as well as a continuation of the activities, and last but not least, the promotion of new specialists.

According to international standards, a gamma camera should be available per 400,000 inhabitants; but yet, we have only one for the entire population of Madagascar comprising 23 million people. We lag behind our neighbours - in Mauritius, there is a gamma-camera for 1,200,000 people; in La Reunion, there are 3 gamma-cameras for a little less than a million people.

Therefore, one nuclear medicine department is neither sufficient nor satisfying in view of the size of the population of the country. However, while failing to create new services, it is necessary to strengthen the existing one. From that perspective, it is fundamental to reinforce capacities, especially material resources and qualified personnel.

IAEA-CN-232/366

Open Phase II Trial "Protonchorde01": Improvement of Local Control in Skull Base and Spine Chordomas Treated by Surgery and Proton Therapy Targeting Hypoxic Cells Revealed by Nitroimidazole ([18F] FAZA) PET/CT

H. Mammam¹, L. Champion¹, I. Buvat³, N. Fournier-Bidoz¹, F. Goudjil¹, P. Dass³, L. Combe⁴; F. Lokiec¹, J.L. Albérini², R. Belshi², A. Labib², A. Mazal², R. Dendale², A. Fourquet², O. Madar², V. Servois²

¹ Institut Curie

² CEA

³ Advanced Accelerator Application

Corresponding Author: hamid.mammam@curie.fr

Chordomas are notochordal histogenesis tumours representing 1 to 4% of all bone tumours. In most cases, these tumours are low grade, with insidious and destructive growths.

The standard treatment for chordomas of the skull base and spine consists of radical and functional surgery associated with radiotherapy. In addition to a primary surgery, mono-component (protons only) or dual component (protons + X-rays) irradiation delivering a total dose of 67 to 71 CGE [CGE (Cobalt Gray Equivalent) = 1 Gy (Photon) x 1.1 (RBE of Protons)] allows for local control rates of approximately 71% and 54% at 3 years and 4 years respectively with acceptable complication rates. These tumours show different components in CT and MRI scans and also exhibit resistance to cytotoxic, targeted therapies and radiotherapy.

Hypoxia induces an aggressive phenotype, promoting tumour progression and increased metastatic potential, but also resistance to ionizing radiation, cytotoxic agents and can explain the high rate of relapse.

Hypoxia is defined as a decrease in oxygen concentration resulting in a mismatch between the needs and tissue oxygen intake. We have shown evidence of hypoxic cells in chordoma with metabolic imaging using a fluorinated analogue of misonidazole, 18F-fluoromisonidazole ([18F]FMISO).

18F-fluoroazomycin arabinoside [18F]FAZA is another imidazole tracer that shows the presence of hypoxic cells in tumours. [18F]FAZA exhibits a better tumour-to- background contrast in PET images than other tracers because of its faster clearance due to its low lipophilic character. This enhanced contrast facilitates the interpretation and delineation of different target volumes for radiotherapy. [18F]FAZA PET/CT makes it possible to get an accurate and quantitative map of hypoxia.

Proton beam (delivered by a cyclotron installed at Orsay proton therapy center - Institut Curie) is used to increase the dose delivered to the primary site, along with elegant sparing of nearby organs at risk. This is due to the rapid fall-off of the dose at the distal end of the Bragg peak (from 80% of the maximum dose to 20% in less than 4 mm) and at its lateral edges (from 90% of the maximum to 20% in 3.5 to 9 mm, depending on the energy and depth). [18F]FAZA is developed in our institution s/a (Hospital René Huguenin - Institut Curie).

Identifying hypoxia using [18F]FAZA PET/CT to allow for dose painting is a promising concept. By increasing the dose to hypoxic volumes of the tumour a higher tumour control is expected.

For chordomas initially treated by surgery, additional radiotherapy oriented by conventional imaging (CT/MRI) and guided by the [18F]FAZA PET/CT could target the hypoxic areas. Adequate and

intelligent increased doses might thus improve local control while minimizing complications. Our goal is to increase to 10% of the total dose delivered at the GTV (Gross Target Volume) to the hypoxic volume in order to improve local control at 3 years by 15% without increasing the current rate of complications.

IAEA-CN-232/368

18F-FDG PET/CT: Metastatic Pattern in HIV Positive Patients with Recurrent Cervical Cancer

K.O Ololade, N. Mokgoro, M. Modiselle, M. Sathekge

Department of Nuclear Medicine, University of Pretoria & Steve Biko Academic Hospital

Corresponding Author: ololadekehinde@yahoo.com

Background: HIV-positive women with cervical cancer have higher recurrence and death rates with shorter intervals to recurrence and death than do HIV-negative control subjects. The objective of this study was to investigate the recurrence patterns in HIV-positive women with invasive cervical cancer using 18F-FDG PET/CT.

Methodology: This study reviewed 26 HIV-seropositive and 79 HIV-seronegative cases of recurrent invasive cervical carcinoma that were referred for 18F-FDG PET/CT. The PET/CT datasets were rated separately by two readers regarding the lesion uptake, lesion localization and lesion characterization. All available data (histology, prior examinations, PET/CT, follow-up examinations) served as standard of reference.

Results: HIV-positive patients were almost 9 years younger than the HIV-negative patients, i.e., mean age 39 years versus 48 years. There was no significance difference in the distribution of metastatic lesions in the two groups (HIV-positive vs HIV-negative), i.e. the most commonly reported sites include the regional lymph nodes (pelvic and para-aortic nodes) (54% vs 46%), mediastinal and supraclavicular lymph nodes (57% vs 43%), lungs (61% vs 39%), bones (58% vs 42%) and the liver (61% vs 39%). However, some HIV-seropositive patients demonstrated rare metastatic sites in the spleen (2), brain (2) and cutaneous (1).

Conclusion: The disease characteristics of invasive cervical carcinoma take a more aggressive clinical course in HIV-infected women as demonstrated by relatively younger age of presentation. HIV-positive women did not demonstrate significantly different metastatic pattern than do HIV-negative control subjects. However, detection of unusual metastatic sites might contribute to future individualization of the management in HIV positive patients with cervical cancer.

IAEA-CN-232/370

18F-FDG Whole Body PET/CT: Dose Evaluation in Paediatric Patients

F. Zito¹, G. Galetta², L. Rossi², L. Florimonte³, C. Canzi¹, F. Voltini¹,
R. Benti³, E. Orunesu³

¹ Medical Physics Unit - Fondazione IRCCS Cà Granda Ospedale Maggiore Policlinico

² Università degli Studi di Milano

³ Nuclear Medicine Unit - Fondazione IRCCS Cà Granda Ospedale Maggiore Policlinico

Corresponding Author: felicia.zito@policlinico.mi.it

Background: A retrospective analysis of 18F-FDG PET/CT absorbed dose in paediatric patients is presented with the purpose of optimizing CT acquisition parameters and to improve protection of this high-radiation-sensitive young population.

Methodology: Eight paediatric patients (age 1-7 years) were evaluated. For PET examinations 18F-FDG activity was scaled according to PET scanner sensitivity and body weight (on average 5 MBq/kg) but 37 MBq minimum was injected. After 1 h from the administration, whole-body (WB) scans were acquired from head to toe. PET WB were performed with the Biograph TruePoint system (Siemens), 21.6 cm axial FOV (7 cm bed overlap), by setting 3min/bed. Images (3 mm slice thickness) were reconstructed with 2 iterations 8 subsets AWOSEM algorithm and 5 mm FWHM Gauss-post-filter. All CT scans were carried out with:

- automatic control of tube current by setting 90 mAs of reference current,
- pitch 0.8, -24x1.2mm beam collimation and -0.5s rotation speed.

Four patients were scanned at 120 kV and the other four at 100 kV. PET effective dose was assessed by multiplying the injected MBq with the ICRP 80 18F-FDG factors (mSv/MBq) interpolated to each patient age. Based on AAPM report 204, specific-patient-CTDIvol index (CTDIvol_AAPM) was calculated by measuring on CT images the patient effective diameter and correcting the scanner CTDIvol with AAPM factors. By using ImPACT dosimetry calculator the CT effective dose (ImPACT) was estimated. ImPACT values, referred to adult patient, were scaled to paediatric age by linear interpolation of Khursheed's factors. Two expert physicians scored CT image quality, anatomical support for PET image interpretation, based on 1-3 scale, sufficient-good -excellent .

Results: A summary of results is reported in Table 1. The four patients scanned at 100 kV had on average a 40% reduction of CTDIvol with respect to the other four at 120 kV. CT image quality did not lower moving from 120 kV (scores: 3 cases sufficient and 1 case good) to 100 kV (scores: 2 cases sufficient and 2 cases good). CTDIvol_AAPM, based on the patient specific size, doubled CTDIvol which is based on the standard 32 cm phantom size. In 2 patients scanned at 120 kV, CT effective dose, assessed with ImPACT, was comparable with PET dose, for the remaining patients CT dose exposure was 0.3 - 0.6 PET dose. The total (the sum of PET and CT) effective doses ranged from 6.4 to 8.6 mSv.

Table 1: Acquisition parameters and dose measurements

Paz	Age (y)	Injected (MBq)	Tube mAs	CTDIvol (mGy)	D _{eff} (cm)	CTDIvol_AAPM (mGy)	ImPACT (mSv)	PET (mSv)	PET+ImPACT (mSv)	Ratio CT/PET
1	1	41	21	0.86	13.6	1.92	2.5	3.9	6.4	0.6
2	3	60	21	0.83	14.8	1.78	2.4	5.0	7.4	0.5
3	6	128	26	1.06	20.8	1.82	2.6	6.0	8.6	0.4
4	7	134	20	0.81	19.7	1.45	2.0	5.9	7.9	0.3
5*	1	37	22	1.52	13.1	3.48	4.8	3.5	8.3	1.4
6*	3	46	16	1.1	14.9	2.34	3.1	3.3	7.5	1.3
7*	4	90	21	1.48	16.4	2.99	3.0	5.5	8.5	0.6
8*	6	108	20	1.39	15.8	2.88	3.4	5.1	8.5	0.7

Conclusion: Even if assessed only with eight young patients, obtained results confirm the importance to take into consideration the specific patient size to estimate exposure dose for 18F-FDG PET/CT examinations. In our PET/CT Unit for patients with age in the range 1-7 years CT scans are performed at 100 kV.

IAEA-CN-232/373

Study on the Preparation and Quality Control of Labeled Monoclonal Antibody 131I-Rituximab for Non-Hodgkin Lymphoma Therapy

T. Ngo Thuy¹, K. Mai Trong², T. Nguyen Thi³, H. Tran Dinh⁴

¹ The Nuclear Medicine and Oncology Center, Bach Mai hospital

² Hanoi Medical University

³ Nuclear Research Institute 4 Bach Mai Hospital

Corresponding Author: trang_ngothuy0201@yahoo.com

Background: Rituximab, a chimeric monoclonal antibody targeted against the cluster designation (CD20) antigen was labelled with 131I and 90Y for use in the treatment of B cell non-Hodgkin lymphoma.

Aims: In this study, the monoclonal antibody rituximab was labelled with 131I using chloramine T method and was bound to the DTPA chelating agent using Hnatowich method. Labelling with 90Y was then done.

Methodology: Preclinical study. In order to label the antibody with 131I, optimized ChT concentration was used at room temperature. The labelling reaction was stopped by using sodium metabisulfite. Labelling efficacy was controlled by instant thin layer chromatography (ITLC). The reaction mixture was purified through the sephadex G-25, PD10 Pharmacia column. The collected 131I-labelling yield was more than 95%. Radiochemical purity of the radiopharmaceutical after purification was more than 99%. The product was subjected to tests of sterility and bacterial endotoxins, in order for it to be sufficiently stable in vivo and in vitro.

Results: Cyclic anhydride DTPA (cDTPAa, 0.1 mg/ml) was dissolved in chloroform and was degassed with nitrogen for 30 min. 131I-rituximab solution in 0.05M bicarbonate buffer was immediately added and mixed for one minute at room temperature. The antibody 131I -rituximab at different concentration (5 mg/ml and 10 mg/ml) was coupled with the cyclic DTPA anhydride, at molar ratios (cDTPAa : rituximab) of 1:1, 3:1, 5:1, 10:1 and 20:1. Coupling efficiency of cDTPA to 131I -rituximab molar ratios of 1, 3, 5, 10, 20 at concentration of 5mg/ml and 10mg/ml 131I -rituximab was around 85.0 -53.5% and 82.2 – 44.2%, respectively. A 70% coupling efficiency at a 3:1 molar ratio results in an average of 2 groups per molecule. The conjugation mixture was diluted to about 0.2 ml with the bicarbonate buffer and loaded onto a PD-10 column (Sephadex G-25, Pharmacia, Biotech). After purification, the DTPA-131I-rituximab conjugate was collected and labelled with Y-90 in 0.5M acetate buffer, pH 5, at room temperature. The labelling yield was about 99%. The radiochemical purity of 90Y-DTPA-131I -rituximab was determined by ITLC and developed in 0.1M acetate at pH=6 as mobile phase. Radiochemical purity of 90Y-DTPA-131I-rituximab was more than 99%.

Conclusion: The radiopharmaceutical (90Y-I131-rituximab) can be used in a clinical setting after having passed tests for sterility, apyrogenicity and biodistribution.

IAEA-CN-232/374

CA Esophagus: Role of PET/CT on Staging and Management

A.T. Orunmuyi, M. Vorster, M. Sathekge

Department of Nuclear Medicine, Steve Biko Academic
Hospital, Pretoria, South Africa

Corresponding Author: akin2nde@gmail.com

Background: PET/CT plays an important role in the management of oesophageal malignancy in terms of staging, restaging, monitoring of treatment response and in predicting prognosis. This has been well established in other countries. Our aim was to assess the impact of PET/CT on staging and management decisions in oesophagus cancer in the South African setting.

Methodology: We retrospectively analysed whole body 18F-FDG PET-CT studies performed in patients with oesophageal malignancy after institutional review board approval. A total of 54 patients were identified of which 4 were excluded due to unavailability of histology results. In all, 55 PET/CT scans were evaluated (3 patients underwent 2 studies each and one had 3 studies).

Results: Twenty-six males (52%) and 24 females (48%) with a mean age of 48 years (25-73) were included in the study. Racial distribution was as follows: 70% Black, 28% Caucasian and 2% Indian. The majority of patients presented with dysphagia and weight loss and most tumours (65%) were localised to the distal third of the oesophagus. Histology demonstrated squamous cell carcinoma in 78% of cases with adenocarcinoma present in only 22% of cases. Overall, the PET/CT result changed the clinical staging in 93% (43/46) and potentially changed management in 81% of referrals. The greatest impact was noted in N- (nodal) as well as M- (metastatic) staging where results lead to changes of 56% and 52% respectively. Changes in T-(tumour) staging occurred in 21/46 studies (45%).

Conclusion: In our experience, 18F-FDG PET/CT is valuable in the initial staging and restaging of disease. Evaluation of nodal and metastatic involvement impacts therapy planning notably. Further studies are required to assess its impact on prognosis in our settings.

IAEA-CN-232/375

68Ga DOTATATE PET/CT Uptake in Vertebral Hemangioma

A. Haeger, D. Valenzuela, J.C. Quintana, P. Orellana Briones

Pontificia Universidad Catolica de Chile

Corresponding Author: porellana@med.puc.cl

Background: Somatostatin receptor (SSTR) PET/CT is an established modality for imaging well-differentiated neuroendocrine tumours. There are few benign differential diagnoses for accumulation of somatostatin receptor analogs. Derivates of octreotide may accumulate in benign inflammatory diseases (e.g., tuberculosis, sarcoidosis, or rheumatoid arthritis). Here, we show a case of a somatostatin receptor expression in one vertebral hemangioma. Vertebral hemangiomas are often incidental, predominantly show asymptomatic findings in MRI or CT scans, and are most commonly found in the thoracic spine. Although studies outlining the normal distribution of 68Ga DOTATATE exist, only one case of uptake in vertebral hemangioma has been reported.

Methodology: We present a case of a 42-year-old patient with a neuroendocrine tumour of the right lung showing incidental uptake of 68Ga DOTATATE in the third thoracic vertebra that was caused by vertebral hemangioma. PET/CT was performed 35 minutes after intravenous administration of a dose of 68Ga-DOTATATE. The study was acquired in a Siemens Biograph 64 True Point camera. CT was performed for attenuation correction and anatomical correlation. Images were reviewed in a dedicated Siemens Workstation with multiplanar reconstruction and PET/CT fusion.

Results: Coronal and transaxial PET images and PET/CT fusion images show intense SSTR expression of the lung tumour (SUVmax 13.7) and pathologic uptake in the third thoracic vertebrae (SUVmax .39). The vertebral lesion would be suspicious for osseous metastases. However, in our patient, corresponding CT images clearly demonstrated a coarse, vertical trabecular pattern and the classical polka-dot appearance on the axial slices, consistent with hemangioma.

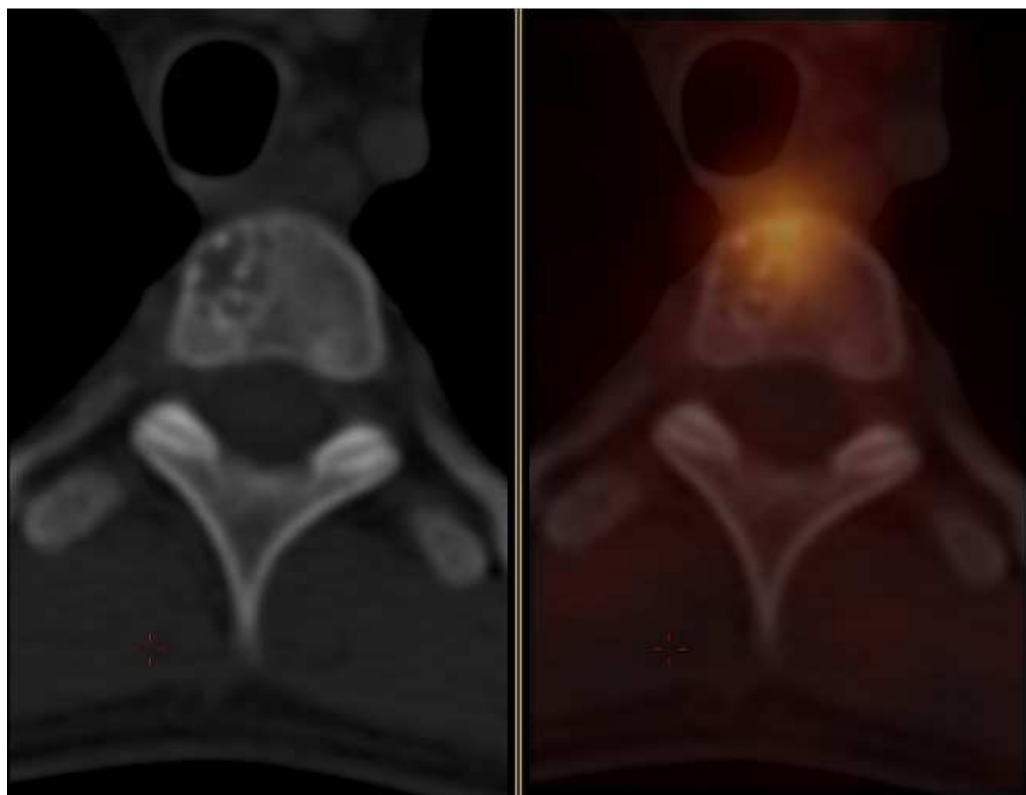


Figure 1: Axial plane

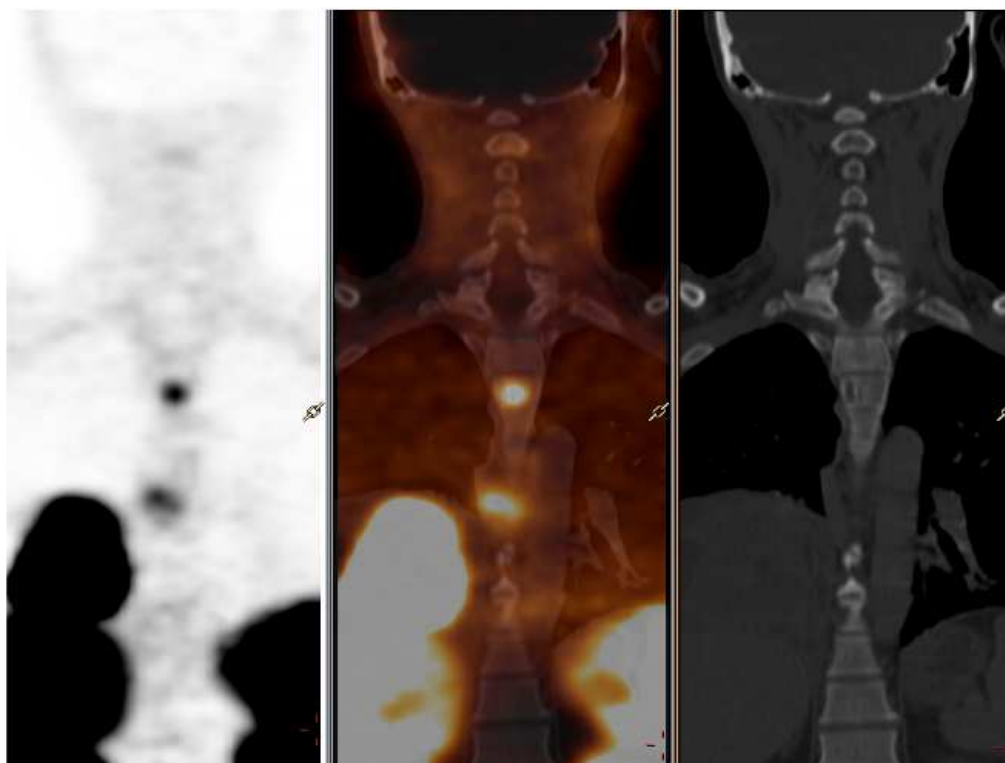


Figure 2: Coronal plane

Conclusion: As the case shows, vertebral hemangiomas should be kept in mind as a benign differential diagnosis.

IAEA-CN-232/376

**Usefulness of Whole Body 18F-Fluoro-2-Deoxyglucose
Positron Emission Tomography/Computed Tomography in the
Detection of Malignant Neoplasm**

D. Valenzuela¹, A. Haeger², P. Orellana Briones², J.C. Quintana²

¹ Hospital Clinico de la Pontificia Universidad Catolica de Chile

² Pontificia Universidad Catolica de Chile

Corresponding Author: porellana@med.puc.cl

Background: The aim of this study was to describe the clinical value of whole body 18F-fluoro-2-deoxyglucose positron emission tomography/computed tomography (18F-FDG PET/CT) in detecting occult primary tumour.

Methodology: A retrospective and descriptive review was conducted on the file records of 94 patients, who were referred to 18F-FDG PET/CT with a diagnosis of unknown primary tumour (UPT) and/or paraneoplastic syndrome. Final diagnosis was based on clinical findings, histology and follow up. The follow up period after 18F-FDG PET/CT scan ranged between 3 and 36 months.

Results: Of the 4507 18F-FDG PET/CT done in our institution, 122 (2,7%) were referred for UPT and/or paraneoplastic syndrome and we included 94 who had follow up; 51 patients were female and 43 male with an age range between 19 and 83 years old, with a mean age of 54 years.

The 3 main reasons of reference were paraneoplastic syndrome with 56.4% of patients, adenopathies with 24.5% and brain metastases with 5,3% of patients.

18F-FDG PET/CT detected a malignant neoplasm in 27 patients (28.7%), lymphoproliferative syndrome being the most frequent with 10 cases. Of these 27 malignant neoplasm detected, 23 were true positive cases.

In our case, almost 30% of the patients had extensive disease on 18F-FDG PET/CT scan.

In our study, the sensitivity and specificity were 63.2% and 94.6% respectively, with a positive predictive value of 88.9% and a negative predictive value of 79.1%.

The accuracy of our 18F-FDG PET/CT scan was 81.9%.

Conclusion: The identification of the UPT in patients with suspected oncological disease is very important to determine a specific treatment to improve the survival time in these patients or to discard other diseases in suspected cases. There are few studies evaluating the clinical value of 18F-FDG PET/CT in detecting UPT, but with similar results.

In our study, 18F-FDG PET/CT scan detected primary tumour in 26% of cases with an accuracy of 80% which is similar to others studies in the literature.

18F-FDG PET/CT is a helpful tool for the identification of the primary tumour in patients with UPT; it is also able to provide an accurate assessment based on the extent of the disease without the need for identification of the primary tumour.

IAEA-CN-232/377

**Evaluating the Percentage of Positive Whole Body Bone Scans
in Patients with Breast Cancer in Different Periods of Disease**

P.K Ramdass

J.Nehru Hospital, Mauritius

Corresponding Author: pratimah2003@yahoo.com

Background: The incidence of breast cancer in the Mauritian female population has increased considerably over the last decades. The parallel advent of nuclear imaging technology since 2001 has allowed confirming or excluding bone metastases at the time of initial diagnosis, in the course of anticancer therapies and also years after completion of initial therapy for the primary lesion.

The objective was to make a comparative study of the positive whole body bone (WBB) scans in 3 groups of patients with breast cancer.

Methodology: Statistical evaluation.

Material: All patients with breast cancer with bone metastases on WBB scan in J. Nehru Hospital from February to September 2014.

Age range was 30-80 years.

Patients were divided into 3 subgroups:

- (a) Newly-diagnosed breast cancer prior to treatment (surgery/radiotherapy/chemotherapy)
- (b) Breast cancer undergoing therapy and presenting symptoms suggestive of bone secondaries
- (c) Breast cancer years after radical treatment of primary lesion in view of onset of symptoms suggestive of bone metastases.

(2) Siemens E-cam & Mediso Nucline gamma camera.

(3) LEHR collimator

(4) 20-30mCi 99m Tc-MDP.

Exclusion criteria: Patients had no other documented oncological co-morbidity at the time of WBB scan.

Results: 29.7% vs 33.4% vs 36.9%.

Conclusions: There was no significant difference in the percentage of positive WBB scan. This indicates the importance of performing this scan in patients with breast cancer in all 3 periods of disease.

IAEA-CN-232/378

**18F-Fluorodeoxyglucose Positron Emission Tomography-
Computed Tomography (FDG PET/CT) Scans in Lung
Lesions: A 3 Case Report**

K. Maguiña Aguedo, S. Rojas, P. Chávez, P. Fernández

Guillermo Almenara Irioyen National Hospital

Corresponding Author: kmaguina1002@hotmail.com

Background: Pulmonary nodules are one of the most common incidental findings in clinical practice. There are wide differential diagnoses of benign and malignant lesions that manifest as solitary pulmonary nodules. 18F-FDG-PET/CT is widely accepted for the clinical diagnosis and staging of lung cancer in patients with suspicious lung nodules. In geographical regions where there are high endemic rates of infectious or granulomatous lung disease, for example infection (histoplasmosis, aspergillosis or tuberculosis chronic/subacute granulomas), abscesses, rheumatoid nodules, sarcoidosis, pneumoconiosis, fibrosis, 18F-FDG PET-CT may have significant limitations because of false-positives. In Peru there is a high prevalence of infectious disease like tuberculosis, thus it is expected that the specificity of 18F-FDG PET/CT will be similar to other areas with high endemic granulomatous disease; however there are not studies because of the recent incorporation of PET/CT in the social health insurance.

Methodology: In the nuclear medicine area of “Guillermo Almenara Irioyen National Hospital” 18F-FDG PET/CT studies were performed for patients referred for lung lesion assessment during the year 2014. Philips GEMINI TF 64 Diagnostic X-ray CT / PET Imaging System was used with standard acquisition protocol. The processing and interpretation of images was performed by an experienced nuclear physician. We present 3 subjects who underwent a PET/CT study for evaluation of the solitary pulmonary lesion. Fine needle aspiration (FNA) or surgical biopsy of solid solitary pulmonary lesions resulting in a definitive pathologic diagnosis was performed.

Results: All lesions had increased 18F-FDG uptake. The first subject, a 78 years old male patient with two pulmonary nodules of 10 and 12 mm in diameter and negative bronchoscopy, had an SUVmax value of 9.7. The second subject was a 59 year old male patient with pulmonary nodule (3 x 3 cm), negative bronchoscopy and PET/CT scan with hypermetabolic lesion and an SUVmax value of 12.6. The last subject was a 71 year old male patient with a hypodense solid tumour and adenopathies of less than 15mm in size; SUVmax value of the pulmonary lesion was 5.7 and of adenopathies 7.9. All lesions were biopsied, and the first two of them were reported as positive for malignant lesions, while the third patient was reported to have granulomatous lung disease, constituting a false positive.

Conclusion: Given the high prevalence of infectious diseases in Peru, which could represent false positives of malignant lesions, the sensitivity and specificity of 18F-FDG PET/CT should be evaluated in further studies with a statistically significant population.

IAEA-CN-232/379

Dose Assessment in Molecular Radiotherapy: Need for Standardization and Harmonization of Nuclear Imaging Procedures

M. D'ariento¹, **M. Capogni**², **V. Smyth**³, **M. Cox**³,
L. Johansson³, **A. Fenwick**³, **J. Solc**⁴, **C. Bobin**⁵, **H. Rabus**⁶, **L. Joulaeizadeh**⁷

¹ National Institute of Ionizing Radiation Metrology, ENEA-INMRI, C.R. Casaccia, 00123 Rome, Italy and Department of Human Anatomy, Histology, Forensic Medicine and Orthopedics, Sapienza University of Rome, Via Borelli 50, 00161 Rome, Italy

² National Institute of Ionizing Radiation Metrology, ENEA-INMRI, C.R. Casaccia, 00123 Rome, Italy

³ National Physical Laboratory NPL, Hampton Road, Teddington, Middlesex, TW11 0LW, UK

⁴ Czech Metrology Institute (CMI), Inspectorate for Ionising Radiation, Radiova 1, CZ-102 00 Prague 10, Czech Republic

⁵ Commissariat a l'Energie Atomique (CEA) Bt 476, Pt Courier 142, CEA-Saclay, FR-91191 Gif-sur-Yvette Cedex, France

⁶ Physikalisch-Technische Bundesanstalt (PTB), Bundesallee 100, D-38116 Braunschweig, Germany

⁷ VSL, Dutch Metrology Institute, Thijsseweg 11, P.O. Box 654, NL-2629, JA Delft, Netherlands

Corresponding Author: marco.dariento@enea.it

Background: The current state of the art for quantitative activity assessment in molecular radiotherapy is the use of single photon emission computed tomography (SPECT) or positron emission tomography (PET). However, absolute activity quantification via tomographic imaging is affected by inherent limitations. Attenuation and scatter of photons degrade the image quality and the accuracy of activity estimates varies with the object size due to the limited spatial resolution, dead time and partial volume effects. Thus proper compensation techniques are required. Finally, from corrected SPECT images the absorbed dose can be calculated by using a number of computational approaches.

Methodology: Despite the growing trend towards developing patient-specific dosimetry models based on quantitative tomographic information, the general consensus is that progress in this area has been hindered by the lack of appropriate standards for calibrating the imaging systems and the lack of validated methodologies for the assessment of absorbed dose to the tissue from therapeutic radionuclides. Further, the clinical implementation of MRT dosimetry procedures is highly demanding. As a consequence, at present, no general clinically accepted dosimetry protocol exists and dosimetry studies are usually performed on individual initiatives. It is generally accepted that quantitative imaging and dosimetry in MRT suffer from a significant degree of inaccuracy and that there is a need for standardization and harmonization of nuclear imaging procedures.

Results: An international three-year project funded under the European Metrology Research Programme,

MetroMRT (<http://projects.npl.co.uk/metromrt/>) addressed this issue, finishing in May 2015. By analogy with external beam radiotherapy, the project formulated MRT dosimetry as a measurement chain that as far as possible is traceable to primary standards with known uncertainty. The links in the dosimetry process are I) measurement of administered activity; II) measurement of activity within a defined tissue volume at a sequence of time points using quantitative imaging; III) integration of the time sequence of measured activity values; IV) calculation of the absorbed dose from the activity-time integral.

Conclusion: The aim of the project was to provide a standardized methodology for calculation of internal dose quantities and associated uncertainties. In the present paper the steps taken towards the standardization and harmonization of nuclear imaging procedures will be presented, along with the major results achieved.

The research leading to these results has received funding from the European Commission (EC), Grant Agreement N° 217257 between the EC and EURAMET under the Seventh Framework Programme.

IAEA-CN-232/380

**Initial Experience at the Instituto Nacional de Cancerologia
(Mexico) of Coregistration of PET / MR Images in Oncological
Diseases**

D.A. Arguelles Perez, F.O. Garcia Perez, Q.G. Pitalúa Cortés, U. Martínez-Berry

INCan, Mexico

Corresponding Author: davarguelles@gmail.com

Background: Hybrid imaging has made significant progress in the management of oncological diseases possible. Oncological advances have allowed fusion of hybrid positron emission tomography / computed tomography (PET/CT), single photon emission computed tomography and computed tomography (SPECT/CT) and more recently magnetic resonance with positron emission tomography (PET/MR). This last modality combines the functional imaging, high spatial resolution of MRI with biological information provided by PET.

Although the limited availability of this dedicated equipment, there are several tools that allow for a coregistration of images acquired in separate devices.

Methodology: Our objective is to demonstrate the feasibility and reproducibility of manual fusion PET/MR performed in our cancer centre using different radiotracers such as ^{18}F -FDG, ^{18}F -FLT, ^{68}Ga -DOTATOC, and ^{11}C -methionine.

16 PET scans were acquired on work station (Siemens Biograph 16) and then they were fused with MRI, which was acquired separately (General Electric), in the PET workstation previously described.

Results: Morphological and functional findings were relevant in 12 cases. In 3 PET studies an increased extent of the tumour was demonstrated and in 1 case the MR allowed for a better assessment of tumour extension, which affected the pre-surgical assessment and radiotherapy planning.

Conclusions: PET/MRI fusion is an effective alternative that brings together the benefits of both imaging methods. Preliminary results observed in our case series match recently published preliminary results that guide towards greater benefit in tumours of central nervous system, head and neck, lung, pelvic and soft tissues. The main difficulty was patient positioning during both studies even if fusion of PET and MRI in separate workstation is feasible.

IAEA-CN-232/381

Safety and Effectiveness in Performing Pharmacological Stress Test Using Dipyridamole

H. Sonea, L. Savurimuthu, V. Sungkur, C. Ahgun, P. Ramdass, H.S. Dustagheer, A. Naojee

Nuclear Medicine Dept, J.Nehru Hospital, Rose Belle, Mauritius

Corresponding Author: vhsona@gmail.com

Background: There is a high prevalence of coronary artery disease (CAD) among the Mauritian population, essentially because of high local prevalence of type 2 Diabetes. Traditionally, patients were diagnosed using ECG, physical stress test, cardiac ultrasound, bio-chemistry and clinical assessment. In early 2014, at the Nuclear Medicine Department of J. Nehru Hospital, Rose Belle, Mauritius, pharmacological cardiac stress test using dipyridamole was introduced and it was a major break-through in the management of patients.

This study aimed to study safety issues related to dipyridamole as pharmacological agent in cardiac stress testing,

Methodology: A group of 151 patients were studied during one year. Only patients with normal vitals were qualified for the test. A resting ECG was performed in all patients prior to stress test.

The pharmacological agent used in the test was Persantine® (dipyridamole), with doses calculated by the formula 0.56mg/kg , and administered intravenously over 4 min, with a maximum of 40 mg. All doses were diluted with normal saline up to a volume of 20 ml.

During administration of dipyridamole patients were encouraged to perform light physical exercise (movement of extremities). Blood pressure was closely monitored.

Whenever side effects (patient referring headaches, experiencing flushing, severe palpitations, pain episodes, etc.) were noticed, aminophylline (with a minimum of 125mg, eventually escalating the dose to 250 mg) was given intravenously 4 minutes after injection of the radiotracer, with a slow administration technique, to reverse the side effects of dipyridamole.

Results: 35 patients corresponding to 23.2% of the total, complained of headache, while 37 patients complained of fatigue (considered as a normal variant), corresponding to 24,5%. Aminophylline was used in 70% of the cases of headache (the most serious complaints) and was never used for the fatigue cases. 52.3% of patients tolerated dipyridamole well.

Conclusion: The study shows that most of the patients tolerated dipyridamole well, with some minor side effects (mostly headache) which resolved completely after being promptly reversed with aminophylline. Moreover, the pharmacological stress test has proven effective in the diagnosis of CAD in patients with physical handicaps who could not have been screened by physical stress test. Gradually the confidence in performing pharmacological stress test grew among all staff members of the Nuclear Medicine Department and eventually this method has gained higher acceptance from the cardiologists.

IAEA-CN-232/382

Neurosurgical Care in Dealing with High-Grade Gliomas that Overexpress the 1p19q Mutation Assessed by Non-Hybrid Fusion of SPECT; CT and MRI; Using Gamma Probe Scanning with 99mTc-Sestamibi

E.A. Serrano Frago

Hospital Mexico, Costa Rica

Corresponding Author: [easfrago@gmail.com](mailto: easfrago@gmail.com)

Background: Gliomas are a type of malignant brain tumour that are classified into high and low grade. They represent a severe health problem. The selection of the appropriate surgical approach is pivotal in order to improve the disease-free survival.

There are clearly defined criteria for the appropriate and comprehensive care of neuro-oncological patients. However, routinely performed studies do not provide sufficient information for an optimal surgical planning. In order to improve the survival rate and quality of life of these patients it is important to have morpho-functional evaluations using diagnostic hybrid imaging modalities. The simultaneous use of SPECT-CT and MRI provides valuable information in patients undergoing surgical treatment and can serve as a tool for the gamma probe guided radiosurgery.

The use of these techniques is aimed at identifying the tumour tissue to be removed, while sparing healthy functional tissue, which is not compromised by tumour, necrosis or edema. Patients with overexpression of 1p19q are characterized by increase in the metabolism in the SPECT-CT studies using 99mTc-Sestamibi, which is a good way to identify those patients with a higher risk of an early tumour relapse which are potential candidates for temozolomide treatment.

These patients have areas with hypermethylation of the MGMT promoter showing higher 99mTc-Sestamibi uptake; this can be semi-quantified before the surgical removal.

Four weeks after surgery a follow up SPECT/CT sestamibi study is performed in order to evaluate the residual areas of increased uptake. Based on the images the radiotherapy treatment is planned as well as the selection of patients that are candidate for chemotherapy in addition to the radiotherapy.

Methodology: All patients were studied with MRI 1.5T, SPECT with 99mTc-Sestamibi and CT to obtain a triple fusion image that provides detailed morpho-functional information for a comprehensive approach and planning for the neurosurgical procedure.

The administration of the radioactive compound (sestamibi) is performed no more than 2 hours before the surgery in order to improve the radioguided surgery and the removal of high uptake areas. Post-surgically, genetic characterization of the removed tissue is performed to determine the over-expression of the mutation 1p19q, to tailor the treatment on individual case basis, which may include chemotherapy, radiotherapy, or both. At four weeks after the surgery a sestamibi SPECT study is performed to assess the residual tissue with increased uptake and define the appropriate treatment. Three months after, another fusion study with SPECT and CT is performed to evaluate the relapse or progression of the disease.

Results: We carried out the study in 5 patients that are currently in follow up. Three showed no uptake in the bed. Out of the two patients which had residual disease, one patient died. So far patients undergone radio-guided surgery have had a better disease-free survival at 7 months follow up.

Conclusions: Interdisciplinary approach plays a crucial role in the surgical treatment of glioma.

IAEA-CN-232/383

**CZT GAMMA Camera Multi-Pinhole and Thyroid Imaging.
Preliminary Experience**

E. Mora-Ramirez, I. Berrocal-Gamboa

Caja Costarricense del Seguro Social

Corresponding Author: erick.mora.ramirez@gmail.com

Background: Cadmium zinc telluride (CZT) detectors have been investigated for a variety of nuclear imaging applications, especially cardiac nuclear and dedicated gamma cameras. Preliminarily, given the characteristics of these detectors configuration and technology, we are interested in evaluating the image quality in small structures, specifically, thyroid studies in order to take advantage of the physical characteristics of the CZT system.

Methodology: Two healthy volunteers, 38 and 36 years old, 1 female, 1 male, with 32 and 24 BMI; both with thyroid hormones and thyroid functionality under reference parameters were studied. Thyroid ultrasound images were taken in order to characterize the glandular morphology and determine the volume.

Thyroid image was acquired using a non-gated heart study with the GE Discovery NM 530c acquisition protocol, activity administrated i.v. was approximately 3 mCi (111 MBq) of $^{99m}\text{TcO}_4^-$; images were acquired 15 minutes after injection. Volunteers were in supine position and detector head was close enough to the cervical region. Generated images were processed under Xeleris workstation using general tomography reconstruction software.

Results: The acquisition and pre-processing software was able to recognize acquisition lower than 180 degrees and generate image reconstruction of the gland. It was capable of generating volumetric images of the thyroid from each volunteer. Images seemed to be well delineated due to the high spatial resolution of the system; activity distribution in the entire gland was seen. The advantage of using these images is that thyroid volume can be determined according to the radioactivity distribution. Segmentation by threshold can be done to compare volume estimation between NM images and US measurements.

Conclusion: This method is not used regularly in our patients; however, imaging in small structures like thyroid seems well delineated. CZT detector advantages have to be taken into account in order to improve the quality of nuclear medicine images. We encourage manufacturers to produce an acquisition and processing software for creating images of small organs, especially of the thyroid gland for use in daily practice.

IAEA-CN-232/384

Challenges in Establishing First PET/CT Centre and Cyclotron Facility in Latvia

M. Kalnina¹, V. Skrivelis²

¹ Pauls Stradins Clinical University Hospital

² PharmIdea

Corresponding Author: marika.kalnina@gmail.com

Background: In the developed world PET/CT has become the standard of care imaging modality for diagnosing, staging, and restaging a variety of cancer types, and has emerged as one of the most accurate non-invasive imaging modalities for monitoring the early response to therapy. Yet in the developing world the setting up of PET/CT and cyclotron facilities has been slower. Attempts and efforts to justify and convince the government ministries several times were not successful because of lack of sufficient funding. Finally in 2011 private companies in cooperation with State education and scientific research institutions founded company with an aim to realize the European Union co-funded project. The aim of the current study is to analyse the key challenges and to suggest potential solutions in establishing first PET/CT and cyclotron facility in our experience.

Methodology: The project implementation is still in progress; however, we tried to analyse the different key challenges we have encountered according to the following implementation stages:

1. Preparatory stage. This stage had different challenges to overcome and major difficulties included choosing appropriate staff, employee's lack of experience in similar projects and public radiation phobia.
2. Designing the construction project for the Centre laboratory's building. At this stage we faced significant increase in costs and were forced to look for additional investors. At the same time the lack of legal framework and restricted legislations were problems we faced.
3. To order, to deliver and to teach personnel skills of using equipment.
4. Start-up of the clinical PET/CT service at full capacity. Referral process will be challenged by lack of awareness from other medical professionals about PET/CT applications.

Results: Installing first PET/CT and cyclotron centre in developing country is a challenging mission, which besides securing the needed funds requires logical robustness in planning process and utilizing the different resources. For any developing country considering having its first PET/CT and cyclotron centre it is suggested to proceed in a logical step of:

1. Preparing a detailed project plan through multidisciplinary task force.
2. Convincing the justification of the project to the authorities.
3. Securing the needed funds based on wise assessment.
4. Seeking and ensuring conformity with regulatory requirements including radiation safety measures in various stages of installing the PET/CT and cyclotron centre facility which include site and layout plan approval, approval for commissioning and routine operation and radiation monitoring measures.
5. Training and appointment of properly qualified staff. In our experience, lack of appropriate experience of staff is partly overcome by training, fundamentally provided in the framework of collaboration with International Atomic Energy Agency (IAEA) and partly provided by vendors.
6. Conducting academic and general activities with medical professionals would overcome lack of awareness of PET/CT applications.

Conclusion: Setting up the first PET/CT and cyclotron facility in a developing country is a great

International Conference on Clinical PET-CT and Molecular Imaging (IPET 2015): PET-CT in the Era of Multimodality Imaging and Image-Guided Therapy

challenge, but it can be adequately overcome by thoughtful planning, targeted solutions and collaboration with International Atomic Energy Agency.

IAEA-CN-232/385

90Y-PET Imaging after Liver Radioembolization for the Assessment of the Absorbed Dose to Lesions

M. D'arianzo¹, **M.L. Cozzella**², **E. Spezi**³, **N. Patterson**³,
P. Chiaramida⁴, **L. Filippi**⁵, **P. Carconi**², **O. Bagni**⁵

¹ National Institute of Ionizing Radiation Metrology, ENEA and Department of Human Anatomy, Histology, Forensic 2 Medicine and Orthopedics, Sapienza University of Rome, Via Borelli 50, 00161 Rome, Italy

² ENEA, National Institute of Ionizing Radiation Metrology, Via Anguillarese 301, 00123 Rome, Italy

³ Department of Medical Physics, Velindre Cancer Centre, Cardiff, United Kingdom

⁴ GE Healthcare Medical Systems, Milano, Italy

⁵ Nuclear Medicine Department, Santa Maria Goretti Hospital, Latina, Italy

Corresponding Author: marco.darianzo@enea.it

Background: Hepatic selective internal radiation therapy (SIRT) using either resin or glass 90Y microspheres is an established catheter-based therapy for the treatment of unresectable primary and metastatic tumours with the potential of delivering a high radiation dose directly to tumour areas meanwhile sparing healthy tissues. In the last 5 years positron emission tomography (PET) has been successfully used to image 90Y in a number of patients and phantom studies. In fact, thanks to its improved spatial resolution 90Y-PET has the potential to provide a superior assessment of the microsphere biodistribution. Further, recent researches showed the possibility of performing dosimetry studies using quantitative 90Y-PET data.

Methodology: The aim of the present work is to describe a calibration procedure of a GE Discovery DST system and to assess absorbed doses from activity maps using the Raydose Monte Carlo code. The proposed calibration procedure was validated on our GE Discovery DST scanner using a reference geometry consisting in cylindrical phantom uniformly filled with a known activity concentration of 90YCl acquired overnight. Absolute quantification of 90Y-PET images was further validated in a non-reference geometry using an anthropomorphic phantom provided with a liver cavity and a cylindrical insert simulating a hepatic lesion. Activity maps obtained in anthropomorphic geometry were converted into dose maps using Raydose, a Geant4-based application for molecular radiotherapy. Finally, dose volume histograms both for the liver insert and the hepatic lesion were produced.

Results: Despite a uniform 90Y solution used for phantom studies, 90Y-PET images showed a non-uniform activity distribution, with focal areas clearly showing scarce 90Y accumulation. Total activity concentration in reference geometry was underestimated by 6%, approximately. Dose calculations performed with Raydose provided an average absorbed dose in anthropomorphic geometry within 10% of the nominal dose (evaluated considering the same uniform activity distribution inside the lesion).

Conclusion: Preliminary results indicate that despite the fact that 90Y-PET provides high resolution images, the 90Y low branch ratio may produce non-uniform activity maps, possibly leading to activity and dose underestimations when a non-optimised image reconstruction protocol for 90Y is used. Additional work is needed towards the development of 90Y specific PET reconstruction protocols to

International Conference on Clinical PET-CT and Molecular Imaging (IPET 2015): PET-CT in the Era of Multimodality Imaging and Image-Guided Therapy

allow proper image quantification for dosimetry.

The research leading to these results has received funding from the European Commission (EC), Grant Agreement N° 217257 between the EC and EURAMET under the Seventh Framework Programme.

IAEA-CN-232/386

18F-FDG PET/CT Interictal Seizure Focus Localization

A. Marti Samper

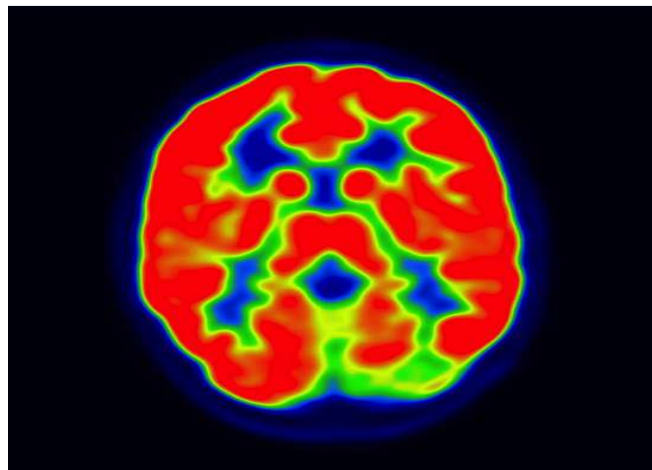
Instituto Nacional de Cancerologia

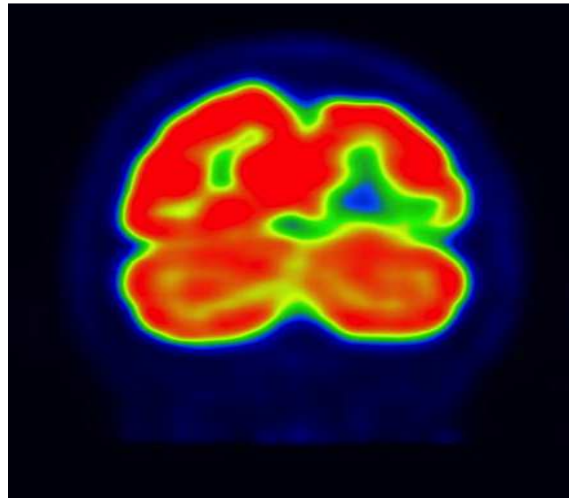
Corresponding Author: amsmarti@hotmail.com

Background: In the process of epileptogenic focus localization patients undergo a variety of tests such as MRI, EEG and 18F-FDG-PET/CT. Seizure free rate ranging from 60 to 80% after temporal lobectomy in cases of mesial temporal epilepsy have been reported, and patients with a positive unilateral PET have excellent post-surgical results.

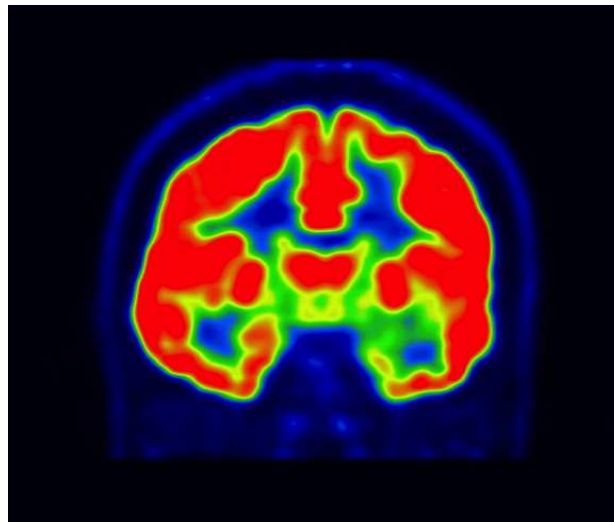
Methodology: Four interictal 18F-FDG- PET/CT case studies of epilepsy are presented. The studies were performed 50 minutes after the radiopharmaceutical intravenous injection (0.14 mCi/kg) and a 10 minute brain image was acquired in a Discovery 600 PET camera. During the uptake time the patient was resting in a dim light and without noise and stimulus, no interventions were done.

Results: A 25 year old male patient having episodes of complex partial seizures characterized by head deviation and focal motor seizures, preceded by visual auras (dyschromatopsia and metamorphopsia) was sent for 18F-FDG PET/CT evaluation. The interictal EEG was non-localizing, as well as MRI. The PET/CT showed a severe hypometabolic left occipital focus lateralizing the disease in a very rare type of epilepsy.

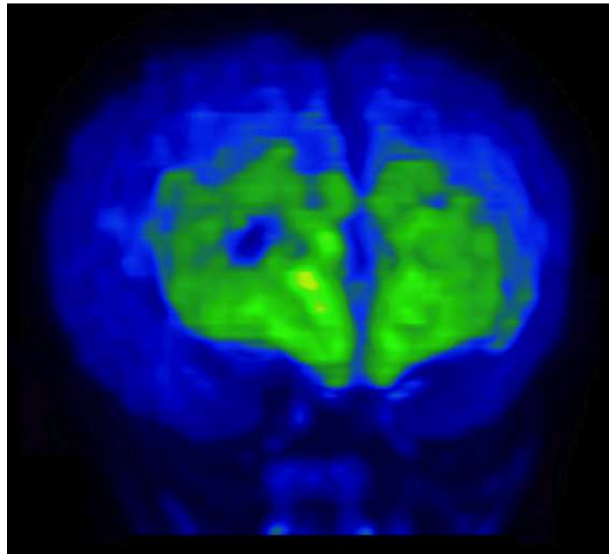




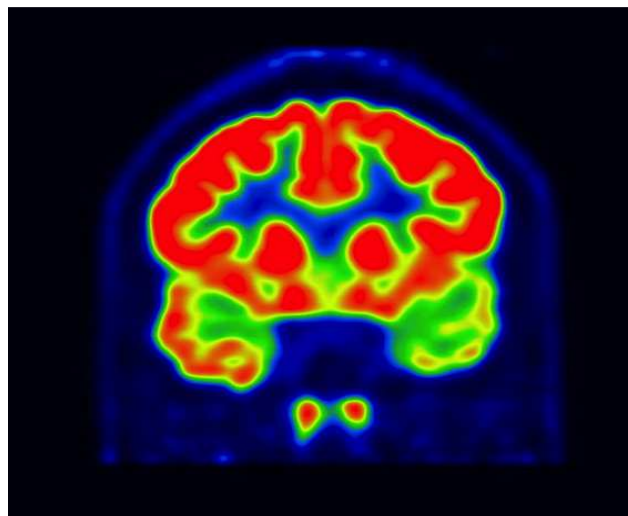
A 17 year old female patient with a history of febrile seizures in her infancy, now referred for partial complex seizures associated with somatosensory auras, lip smacking, anxiety followed by a motionless stare and manual automatisms; this pattern has been increasing in frequency even though she was on several medications. Her MRI was unremarkable, the video electroencephalography was not diagnostic so her neurologist ordered a 18F-FDG PET/CT with 18-fluoro-deoxyglucose that showed a severe hypometabolic focus in the left mesial temporal lobe.



A 17 year old patient had recurrent seizures, prolonged postictal and a misleading EEG, the 18F-FDG PET/CT showed a clear hypometabolic focus in the right frontal lobe.



The last case shows another female, 20 years old, having recurrent seizures with an interictal EEG suspicious of left temporal epilepsy, MRI was unremarkable, the FDG-F18 PET/CT showed hypometabolism in the entire left temporal lobe (mesial and lateral).



Conclusion: Interictal ^{18}F -FDG PET/CT is a very useful imaging modality to lateralize the seizure focus even when primary tests are negative. It provides the treating physicians an anticipated prognosis, taking into account that mesial temporal lobe epilepsy responds very well to surgery, and on the other hand extra temporal epilepsies do not, the outcomes in lateral and severe whole lateral and mesial temporal lobe epilepsy could also be disappointing and cannot provide a seizure free outcome. Finally, surgery in cases of rare occipital lobe epilepsy is difficult because of the risk of visual loss and possible poor result on seizure control, not to mention how hard it can be to make a correct diagnosis and localize the disease.

IAEA-CN-232/389

Papillary Thyroid Carcinoma Metastasis to the Pancreas

A. Marti Samper

Instituto Nacional de Cancerologia

Corresponding Author: amsmarti@hotmail.com

Background: Differentiated thyroid cancer (DTC) is the most frequently found malignant endocrine neoplasia. It usually has a slow development allowing for surgical management and ablative therapy with iodine 131, achieving complete remission in the great majority of cases. However a small percentage of tumours present an aggressive behaviour showing distant metastases in lung, bone and brain and foci of cellular dedifferentiation, which worsens prognosis and limits therapeutic options.

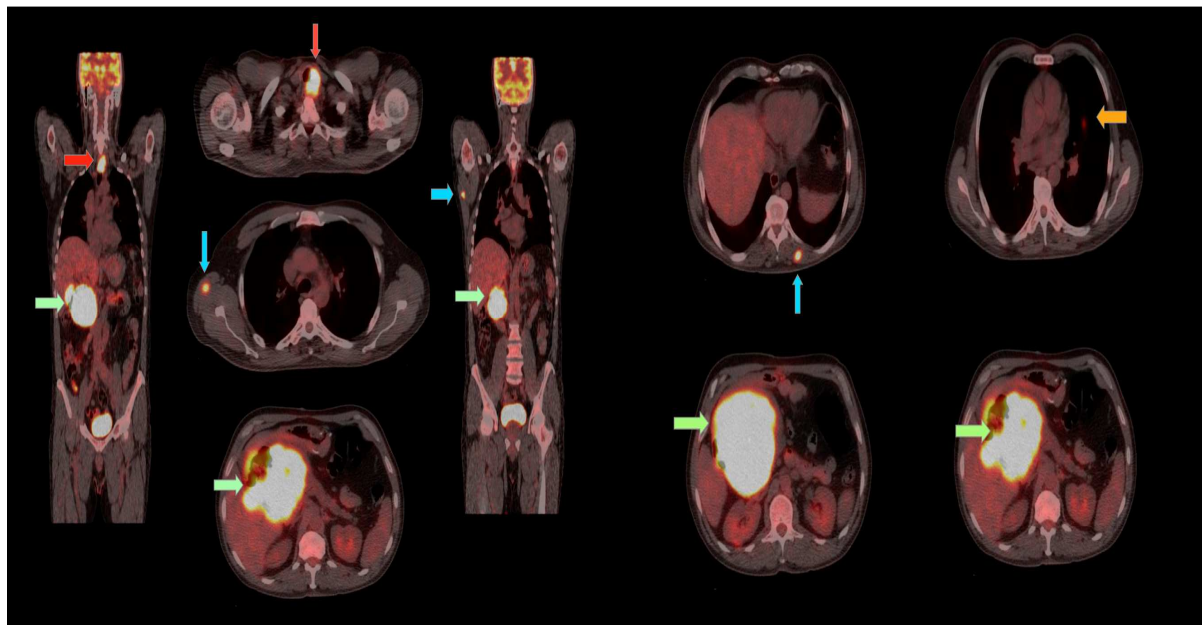
In the monitoring process of the CDT, positron emission tomography with the glucose analogue F-18FDG remains an important diagnostic and prognostic imaging tool. A case of a 50 year old male patient with papillary thyroid cancer, unstimulated thyroglobulin level of 550 ng/dl and very rare metastatic disease to the pancreas is presented.

Methodology: 18F-FDG PET/CT.

Results: PET images: The red arrow shows a hypermetabolic left paratracheal infiltrative mass with tracheoesophageal recess extension and invasion of the trachea.

The green arrow shows intensely hypermetabolic mass that infiltrates pancreatic head, with extension to the hepatic hilum, which is confirmed with pathology and immunohistochemistry as papillary thyroid carcinoma metastasis.

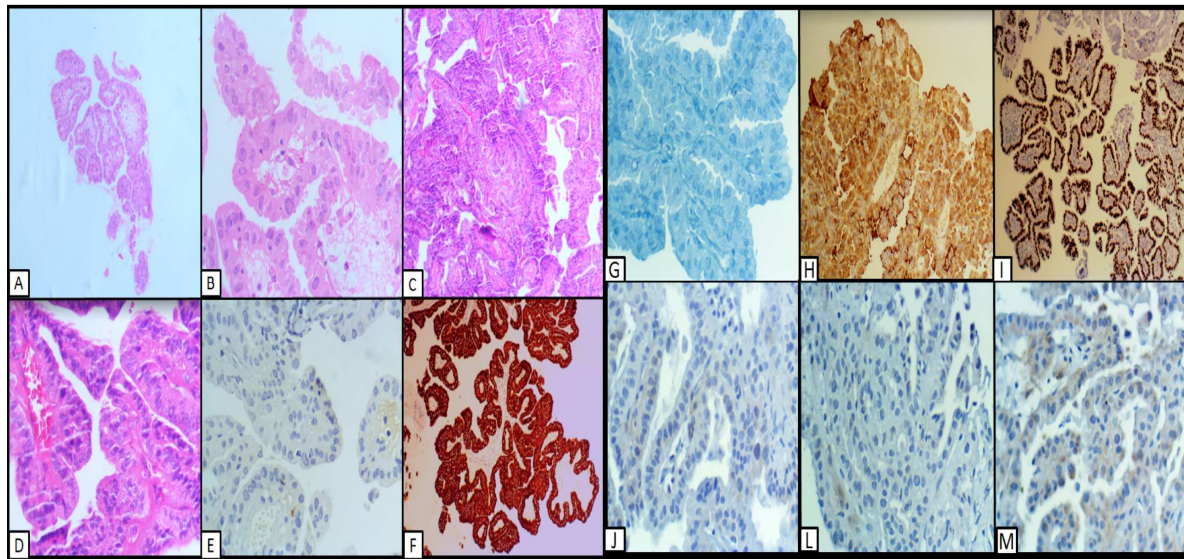
The blue arrows show hypermetabolic metastatic foci in muscle tissue in the right axillary and left dorsal region, the yellow arrow shows a left lung metastatic nodule.



Pathology and immunohistochemical images:

Papillary thyroid carcinoma with pancreatic metastases: loose papillary formations in pancreatic tissue (A) coated by follicular cells with intranuclear inclusions (B) and presence of thyroid tissue papillae (C) and tumour follicles (D). Observed negativity for calretinin (E) and positivity of tumour cells for galectin-3.

Second Set: Immunohistochemical study negative for mesothelial keratin (G), cytoplasmic reactivity for thyroglobulin (H) and nuclear positivity for TTF1 (I). Thrombomodulin (J), WT - 1 (L) and D2-40 (M) were negative.



Conclusion: Some investigators have concluded that the distant papillary thyroid metastases at diagnosis occur in a frequency that ranges from 6 to 20%. Of these, 49% are located in the lungs, 25% in the bone, 15% in both locations and 10 % in other soft tissues. Pancreatic metastases are exceptional, in the year 2013 only 9 cases have been reported in the literature, and in general surgical management is recommended.

IAEA-CN-232/390

**Image Processing for Biological Tumour Volume Definition
Based on 18F-FDG- PET/CT Imaging: Dynamic and
Pharmacokinetic Aspects**

H.A. Amaya Espinosa¹, W. Stiller², L.S. Veloza Salcedo³

¹ Universidad ECCI - Bogota Colombia

² University Hospital Heidelberg

³ Universidad Nacional de Colombia

Corresponding Author: hamayae@eccci.edu.co

Background: Fused positron emission and computed tomography (PET/CT) images have an important role in external beam radiotherapy (RT), especially for target volume delineation, and in spite of it, in Colombia the majority of the RT planning is made without the information provided by PET. For this reason, a computational algorithm based on Canny's edge detection tool was developed for processing PET/CT images.

On the other part, for contouring on PET/CT images, the source background algorithm, and gradient methods are the methods currently used. There are many published studies where the authors evaluate the quality of the delimitation, but they do not give a physical interpretation to the gradients of counts, or to the Laplacians of counts. Therefore, the additional information that could be obtained from the processing of the images is wasted.

Methodology: The image processing was realized with a software developed previously, based on the data analysis framework ROOT (CERN, Geneva, Switzerland) and the Grassroots DICOM GDCM libraries. First, pre-processing by Gaussian smoothing (SD =1.3 pixels) was applied to PET/CT image data. Directional derivatives were computed using a finite difference method and then, the gradient magnitudes and Laplacians were calculated. An image from the PETCETIX DICOM sample image set from OsiriX-viewer software was processed using the cited software.

Results: PETCETIX DICOM image was displayed and processed. Two new images whose voxels now correspond to gradients and Laplacians of counts were obtained.

In theory, there is a proportional relationship between the value of the number of counts and the radiopharmaceutical mass concentration for a constant acquisition time, so the gradient of counts is also proportional to the gradient of mass concentration. Fick's laws could explain the borders present in the processed images if the radiopharmaceutical enters into the cell by diffusion, but the images were obtained with 18F-FDG, a radiopharmaceutical that enters into tumor cells through the glucose transporters (GLUT), a facilitated diffusion that is not described by the Fick laws. However, in agreement with the results, it is necessary to propose experiments to study the variation of gradients and Laplacians of counts with the acquisition time, to establish its correlation with the time-activity curves.

Conclusion: Gradient magnitude and Laplacian images obtained after processing the 18F-FDG PET-CT images could be associated with some diffusion processes explained by Fick's laws, but it is necessary to include pharmacokinetic models to give a correct interpretation of the images. Gradient magnitude and Laplacian images show direct information on diffusive processes when images from radiopharmaceuticals that enter cells by simple diffusion are processed.

IAEA-CN-232/391

**Nuclear Medicine at the Health Sciences Research Institute,
National University of Asuncion: Current State and
Projections**

M. Pedrozo¹, P. Galván², G. Giménez², N. Apuril², B. Grossling²

¹ The Health Sciences Research Institute, National University of Asuncion

² Member State experience with PET, multimodality imaging and newer applications in diagnostic imaging, and related IAEA Projects

Corresponding Author: maglo1982@hotmail.com

Background: In the Paraguayan public sector, the Instituto de Investigaciones en Ciencias de la Salud (IICS) was the pioneer in the implementation of nuclear medicine in the 1980s with the support of the International Atomic Energy Agency (IAEA). The nuclear medicine service of the IICS has acted as support for the low-income patients that attend the Clinics Hospital of the Faculty of Medical Sciences of the National University of Asuncion (UNA in Spanish) and other institutions of the capital and the countryside, performing bone, thyroid, renal and cardiologic studies together with the radioactive iodine therapy for the treatment of thyroid cancer.

Methodology: In 2014, the IICS opened its new facilities in the campus of the UNA in San Lorenzo, with a modern building infrastructure for the new nuclear medicine service, following national and international guidelines for radiological protection. Through several projects of national and regional technical cooperation of IAEA, human resources were trained abroad, and a SPECT gamma chamber, providing 3D images, was donated to replace the first plane gamma chamber which the IICS had.

Results: Many functions of this specialty will be carried out, such as diagnosis, staging, treatment, prognosis and follow-up of diseases prevailing in the country like bone, thyroid, renal, cardiologic, gastric, haematological and oncological metastases.

Conclusion: The future outlook is documented through projects of national and regional public and private institutions with the support of the IAEA with a view to expanding the use of nuclear medicine investment; which are aimed at strengthening the quality of the practice of nuclear medicine, human resources training, equipment purchase and technology application for diagnostic and therapeutic purposes. Of note is the commitment and support of the Institute for Research in Health Sciences of the National University of Asuncion, considering in its new headquarters campus of UNA, a chord physical space to international demands serving in nuclear medicine. Also, it an expansion of the specialty is anticipated with the use of the hybrid specialties: SPECT/CT, positron emission tomography/computed tomography (PET/CT) and the use of radionuclides therapies with labeled monoclonal antibodies and peptides.

IAEA-CN-232/393

Biological Evaluation of a ¹⁸F-FDG-Labeled Small Peptide as an Imaging Agent

A.M. Senisik¹, S. Teksöz², A.Y. Kilcar², C. Ichedef², E. Ucar², K. Ari², D. Göksoy³, Y. Parlak³, B.E.S. Bilgin³

¹Sifa University Vocational School of Health Services, Buca-İzmir

²Institute of Nuclear Sciences, Ege University, Bornova-İzmir

³Nuclear Medicine Department, Celal Bayar University, Manisa

Corresponding Author: steksoz@hotmail.com

Background: In recent years, several radiolabeled molecules such as peptides, proteins, and aptamers have been proposed as highly target-specific PET (positron emission tomography) imaging probes. Overexpression of peptide receptors on tumour cells compared to normal cells is the molecular basis of a number of peptide applications. The use of small peptides is preferred in studies because of their low toxicity and successful radiolabeling. As valuable biological tools, radiolabeled small peptides are under investigation and they are excellent candidates for nuclear medicine applications. Selecting a suitable peptide enables specific imaging or tissue targeted therapy. Glycyl-glycine (Gly-Gly), as a small peptide, has a favourable pharmacokinetic profile and does not accumulate in the blood or non-target tissues due to its rapid clearance properties.

PET is a rapidly developing non-invasive imaging method that uses target specific compounds radiolabeled with positron emitting radionuclides with short half-life. Within the spectrum of available positron emitters, fluorine-18(¹⁸F) is a particularly attractive radionuclide due to its favourable nuclear and chemical properties (low β^+ energy of ¹⁸F, 635 keV). ¹⁸F-fluorodeoxyglucose (¹⁸F-FDG) is the most important imaging radiotracer in nuclear medicine for PET. Tissues that have higher glucose metabolism will accumulate more ¹⁸F-FDG. Therefore, cancer cells can be distinguished from normal tissues through their increased glucose metabolism. Development of peptide-based PET radiotracers is one of the main challenges of PET radiochemists. The aim of the current study was to prepare radiolabeled Gly-Gly with ¹⁸F-FDG and investigate its biological behaviour in vivo.

Methodology: Radiolabeling of Gly-Gly with ¹⁸F-FDG was performed. Quality control studies were performed by thin layer radiochromatography (TLRC) and high performance liquid radiochromatography (HPLRC). Imaging studies on Wistar Albino rats were carried out in accordance with the permit from Local Ethics Committee for Animal Experiments numbered as 2011-082. Radiolabeled compounds were intravenously administered to the tail vein of each rat. The biologic distribution of ¹⁸F-FDG-Gly-Gly was examined by using PET/CT.

Results: The radiolabeling yield was 98.65 ± 0.35 %. It is understood that ¹⁸F-FDG-Gly-Gly complex is rapidly cleared from the blood and excreted through the renal pathway.

Conclusion: We conclude that ¹⁸F-FDG-Gly-Gly could be beneficial as peptide based targeted agent for imaging purposes.

IAEA-CN-232/394

68Ga-Labeled PSMA as a New Tracer for Evaluation of Prostate Cancer: Its Diagnostic Value in Patients with Biochemical Recurrence of Prostate Cancer

S.A. Vöö , F. Mottaghy

Maastricht University Medical Center

Corresponding Author: stefanvoo@yahoo.com

Background: There is an ongoing need for an accurate imaging modality which can be used for staging, metastatic evaluation, predicting biologic aggressiveness, and investigating recurrent disease in prostate cancer. Prostate specific membrane antigen (PSMA), due to its exclusive presence in prostatic tissue and an increased expression in prostate tumour cells, is regarded as an ideal target for prostate cancer. Recently, a new anti-PSMA ligand [68Ga-PSMA] has been introduced for PET imaging of prostate cancer. Despite first promising experimental results, there is still limited data available on 68Ga-PSMA imaging in patients. Hence, the aim of this evaluation was to analyse the diagnostic value of 68Ga-PSMA PET/CT in patients with suspected recurrent prostate cancer and a possible association between different clinical variables and the imaging results.

Methodology: We performed a retrospective analysis on 30 consecutive patients (median age 68 years) with suspected biochemical recurrence of prostate cancer who underwent 68Ga-PSMA PET/CT between January 2013-December 2014. Other clinical factors such as prostate-specific antigen (PSA) level, PSA doubling time (PSA-DT), Gleason score (GSC), androgen deprivation therapy (ADT), age, and amount of injected tracer were evaluated in correlation with the imaging results. Furthermore, multifocal prostate biopsies were taken in all patients following the 68Ga-PSMA PET/CT.

Results: In 83.3% of the patients at least one lesion indicative of prostate cancer recurrence was detected. A total of 45 focal prostatic lesions were considered positive on 68Ga-PSMA PET with an average maximum standardized uptake value (SUV_{max}) of 12 ± 8 (1.1- 25), compared to a low background SUV (median SUV 0.7). All PET-positive lesions were confirmed as true-positive on histology. However, of all prostate biopsy samples taken for verification, 3 samples proved to be positive on histology but false-negative on PET. Tumour detection was positively associated with the PSA levels (>2 ng/ml) and ADT. Other clinical parameters, such as GSC, PSA-DT, age, and dose of injected tracer, showed no association with the PSMA PET findings. A lesion-based analysis revealed a sensitivity, specificity, negative predictive value (NPV), and positive predictive value (PPV) of 93%, 100%, 92%, and 100%, respectively. A patient-based analysis revealed a sensitivity of 96%.

Conclusion: 68Ga-PSMA PET/CT shows a high sensitivity and, importantly, a high specificity in detecting prostate cancer, even in patients with low PSA levels. Therefore, PSMA PET/CT is a promising new imaging approach that could guide the therapy management in patients with suspected recurrence of the disease.

IAEA-CN-232/395

Would the PET/CT with Choline Be Useful for Prostate Cancer Patients in Senegal

B. Ndong, O. Diop

Cheikh Anta Diop University of Dakar

Corresponding Author: ndongboucar73@yahoo.fr

Background: Prostate cancer is the second most common cause of cancer related death in men and the third most frequent cancer type in the world after breast cancer and colorectal cancer, and therefore represents a real health problem. Choline PET/CT represents a very important diagnostic tool in management of prostate cancer.

The objectives of this work were to show:

- The impact of PET-CT with choline in the follow-up of patients after radical prostatectomy and biochemical relapse;
- The fact that PET-CT is not a luxury, but a need in Senegal.

Methodology: The patient was in fasted state for 4 hours. The radiopharmaceutical (18F-choline) was delivered ready-to-use and was administered i.v. to the patient. The radioactivity injected was calculated based on the weight of the patient at a rate of 4 MBq/kg. The duration of the examination was approximately 60 minutes. The acquisition of the PET image was carried out. A dynamic pelvic bed and 7 to 8 beds from the base of the skull to the mid-thigh were performed.

Results: We report the results of the PET-CT of a patient followed in Bichât hospital in Paris where a three months fellowship was done in 2014. The 80 years old patient underwent radical prostatectomy on March 1 2005 for prostate adenocarcinoma with a Gleason score of 7 (4+3), invasion of the left seminal vesicle and involvement of surrounding nerves.

After post-surgical radiotherapy at a rate of 66 Gy, PSA was undetectable until 2009, and then increased from 0.66 ng/ml in 2010 to 1.93 ng/ml in 2013.

The PET-CT with choline showed an intensely hypermetabolic bone lesion localized on the right iliac bone (SUVmax=7.4). PET-CT showed at the right axilla moderately hypermetabolic nodes (SUVmax = 1.9). It also showed a hypermetabolic focus at the level of the fourth thoracic vertebra (SUVmax = 5.4) and a hypermetabolic focus (SUVmax = 7.6) at the right costal rib.

PET-CT allowed to direct the biopsy of these metastatic nodes which are rare even in patients with high PSA values.

Conclusion: This observation underlines the importance of 18F-choline PET-CT after radical prostatectomy. PET-CT imaging during the monitoring of this patient showed the presence of lesions compatible with nodal and bone metastatic relapses. This allowed an early modification of the treatment of this patient.

IAEA-CN-232/396

Prostate Cancer Radiation Therapy Response Assessed with [11C] Acetate PET and MPMRI in the Absence of a Hybrid Scanner

P. Andrzejewski¹, P. Baltzer², J. Knoth¹, P. Kuess¹, S. Polanec², G. Goldner¹, W. Wadsak³, D. Georg¹, T. Helbich²; P. Georg⁴

¹ Department of Radiation Oncology, Medical University Vienna, Christian Doppler Laboratory for Medical Radiation Research for Radiation Oncology, Vienna, Austria

² Department of Biomedical Imaging and Image-guided Therapy, Medical University of Vienna, Christian Doppler Laboratory for Medical Radiation Research for Radiation Oncology, Vienna, Austria

³ Department of Nuclear Medicine, Medical University Vienna, Christian Doppler Laboratory for Medical Radiation Research for Radiation Oncology, Vienna, Austria

⁴ EBG MedAustron GmbH, Wiener Neustadt and Christian Doppler Laboratory for Medical Radiation Research for Radiation Oncology, Vienna, Austria

Corresponding Author: piotr.andrzejewski@meduniwien.ac.at

Background: The objective of the study was to evaluate the feasibility of response assessment during external beam radiotherapy (EBRT) of prostate cancer (PCa) based on [11C]Acetate PET and multiparametric magnetic resonance imaging (mpMRI) in the absence of a hybrid PET/MR scanner. The study aimed at finding the correlation of quantitative parameters changes derived from different imaging modalities during the course of treatment.

Methodology: Five PCa patients were included in this IRB approved prospective study. Patients received a prescribed dose of 78Gy to the prostate and 50.4Gy to elective pelvic nodes. The imaging protocol included [11C]Acetate PET-CT and mpMRI scans at 4 time points of the treatment: at baseline, after 2 and 4 weeks of radiotherapy (at ~20 and 40Gy) and 3 months after EBRT. In the PET-CT protocol patients were injected 740MBq of [11C]Acetate and imaged 20 minutes later. The mpMRI scan consisted of the following sequences: T2-weighted TSE, diffusion weighted single-shot echo-planar imaging (DWI) and dynamic contrast enhanced (DCE) T1-weighted gradient echo. ADC, Ktrans and iAUC maps were generated using the Syngo® software. All images were analysed and registered with the Mirada RTx software using automatic and manual rigid registration with respect to three reference gold markers in the prostate. Series of structures (defined on datasets from all consecutive time points) consisted of: focal lesion visible on particular modality (T2w; ADC-, Ktrans-, iAUC- maps and PET), reference PET structure (gluteal muscle) to calculate tumour to background (TBR) and the dominant intraprostatic lesion (DIL) based on all imaging modalities. DILb defined at the baseline was copied to the remaining time points (DILb2-4) to assess temporal stability of the DIL. The quantitative parameters measured within defined structures were extracted from the respective imaging series.

Results: Mean volume of the DIL structures was 2.1±1.4 cc at baseline and decreased to 0.2 ± 0.2 cc at follow up (with 31.8 ± 35.9% and 55.1 ± 29.6% decrease after 2 and 4 weeks, respectively). Mean values

of the quantitative parameters between DILb and DILb4 differed as follows: ADC increased by $32.3 \pm 8.1\%$, Ktrans decreased by $62.4 \pm 22.3\%$ and iAUC by $50.9 \pm 20.1\%$. Signal intensity on T2w images decreased by $5.7 \pm 6.9\%$ and TBR dropped by $42.1 \pm 20.7\%$. The behavior of these parameters during treatment differed between cases. For instance for one patient the lesion was not visible on the MR images already after 20Gy, whereas for another one it could be recognized even in follow up after 78Gy.

Conclusion: It is feasible to perform PCa EBRT assessment with combined [11C]Acetate PET and mpMRI on separate scanners. Patient positioning and image registration play important roles in the absence of a hybrid PET/MR. Functional parameters from different imaging modalities complement each other and give more comprehensive picture of tumour microenvironment and its changes during treatment, but their predictive power for treatment outcome need further investigation with more patients and longer follow up.

IAEA-CN-232/397

**Continuous Medical Education of Nuclear Medicine
Professionals in Macedonia**

A. Urgrinska, D. Miladinova

Institute of Pathophysiology and Nuclear Medicine, UKIM

Corresponding Author: ugrinskaana@yahoo.com

Background: The field of nuclear medicine has changed dramatically over the past decade in terms of the introduction of multimodality imaging, development of new radiopharmaceuticals and new treatment modalities and protocols.

Therefore the continuous education has become very important for the professionals working in the field of nuclear medicine. However in a small country like R. Macedonia with limited resources and few nuclear medicine departments keeping pace with the new advances in the field can be a challenging task.

Methodology: We reviewed the modes of continuous medical education for nuclear medicine professionals in Macedonia in the past and the new initiatives that emerged in the recent years.

Results: During the past two decades the problem of continuous education was overcome by fellowship visits to departments in other countries through cooperation with the IAEA and with the attendance at the IAEA RTC's. In addition to these activities in the recent years the importance of the nuclear medicine has been recognized by our government as well and several exchanges between professionals were facilitated by the Ministry of Health. The role of the National Society of Nuclear Medicine in the field of continuous education has also emerged. The Society got involved in the cooperation with the EANM and has been a host of CEE Seminar that proved to be very successful. This year the Society is organizer of the 4th Balkan Congress of Nuclear Medicine (BCNM). The Congress is organized with contribution of EANM, WARMTH, Ministry of Health, UKIM and other national and international organizations. Recognizing the necessity of basic education in some areas the Organizing Committee has decided this year for the first time to organize in the frame of BCNM workshops in the field of PET, cross-sectional anatomy and internal dosimetry hoping that this will help the nuclear medicine professionals from the country and from the region.

Conclusion: The Continuous education proved to be essential in the face of fast changing specialty, and the role of National Society and cooperation on regional level and with different international organizations is very important for the development of nuclear medicine in small countries like Macedonia.

IAEA-CN-232/398

Weight Loss in Metastatic Castration Resistant Prostate Cancer (mCRPC) Patients on Radium-223 Dichloride

S. Paknikar¹, S.H. Mehr², J. Paknikar³, L. Nordquist⁴

¹ Nuclear Radiologist, Urology Cancer Center and Genitourinary Research Network Core Faculty, Creighton University School of Medicine, Omaha NE 68124, USA

² Director, Molecular Therapy and Imaging, Urology Cancer Center and Genitourinary Research Network, Omaha NE 68130, USA

³ Core Faculty, Creighton University School of Medicine Staff Physician, CHI Health, Omaha NE 68131, USA

⁴ CEO and Medical Oncologist, Urology Cancer Center and Genitourinary Research Network, Omaha NE 68130, USA

Corresponding Author: JayashreePaknikar@creighton.edu

Background: Patients with metastatic castration resistant prostate cancer are known to lose weight. Amongst other factors this weight loss is mediated through Macrophage Inhibitory Cytokine 1 (MIC1), which is overexpressed in human prostate cancer. The objective of this study was to evaluate the patterns of weight loss in mCRPC patients receiving intravenous Radium-223 Dichloride (Xofigo).

Methodology: Forty patients with mCRPC with metastases exclusively to the bone were included in the study. The Gleason scores, initial BMI, the height, drugs for mCRPC, serial body weight and percentage body weight change at beginning of each cycle were recorded. Demographic data, baseline blood chemistry, CBC, cross sectional body imaging to exclude metastases to other organs were obtained prior to the study enrollment.

A 99m-Tc MDP bone scan was obtained at the beginning and end of the study. Percentage weight changes were plotted against BMI, Gleason score, number of medications and prior chemotherapy. Intravenous Ra-223 dose was calculated at 50 kBq per kilogram body weight.

Results: Twenty-three patients lost weight and 13 gained weight and 4 did neither. The weight loss was more in those with BMI >30 (n=15) and weight gain more in those with BMI <29.9 (n=9). Significant number of patients on 2 drugs for treatment of mCRPC lost weight. Previous chemotherapy history positively correlated to weight loss in a marginal number of patients. No significant relation was seen between Gleason score and weight loss in mCRPC patients.

Conclusion: Although the number of patients in this exploratory study is limited, a few observations can be made. Patients with a higher BMI (30-45) tended to experience a weight loss, while patients with a

lower BMI (19-29.9) tended to experience a weight gain. The reasons for these weight changes may be manifold and may need further study. However these preliminary observations of ours viewed in conjunction with the finding of the ALSYMPCA trial that patients with metastatic prostate cancer (mCRPC) and higher body weight had overall higher survival rate may have implications for management of this cohort of patients.

Keeping in mind these observations, adopting a treatment strategy, which minimizes this weight loss and encourages weight gain, may have a positive bearing on the patient outcome. Furthermore as Ra-223 dose calculation method is weight based a loss in body weight can translate to a smaller calculated therapy dose, which may potentially impact negatively on the disease management.

IAEA-CN-232/400

Establishment and Development of Good Radiopharmacy Practice in Eastern Africa - Tool for Recognized Young Radiopharmacists and Prospective for Nuclear Medicine

D. Mwanza Wanjeh^{1,3}, A. Alemu^{2,3}, J.M. Muchira^{1,3}, E. Janevik-Ivanovska³

¹Ministry of Health, Kenya

²Faculty of Medicine, Addis Ababa, Ethiopia

³Faculty of Medical Sciences, University Goce Delčev – Stip, FYR Macedonia

Corresponding Author: emilija.janevik@ugd.edu.mk

Background: Describing the current status of radiopharmacy practice in Eastern Africa using the current situation of Kenya and Ethiopia is the starting point for creating our vision of perspective of well recognized, qualified professionals in the field.

Non-communicable diseases (NCDs) are the most common cause of mortality in Africa and can be a starting point for radiopharmacist to play an important role in the detection, diagnosis and targeted therapy of NCDs, including also all infectious diseases responding to the unfolding new disease trends in sub-Saharan Africa.

The exact information on the number, status and size of radiopharmacy units, regionally, is still not clearly documented, as well human resources, education, suitable training and local demand for the radiopharmacy and nuclear medicine services. It is the existence of this gap that necessitated the preparation of this presentation.

Methodology: The preparation of radiopharmaceuticals for human use requires that it is carried out in well-defined and controlled conditions to avoid the risk of contamination with microbes, pyrogens and particulate matter as well as cross contamination with other radiopharmaceuticals.

Accordingly, principles of good practices in all levels should be planned, introduced by the planned priority and strictly observed in the production, preparation, testing and the packaging of the final product ready for use.

Results: Most radiopharmaceuticals are parenterally administered and must therefore be prepared in such conditions, and with the use of such techniques and procedures, that guarantee the sterility of the product. Every procedure undertaken should be done according to the clearly defined protocol and under the right conditions so as to build quality into the product.

Radiopharmacy professionals should have adequate training in all aspects of sterile production, quality control, GMP, GLP, radiation safety and radiochemistry to ensure that they are competent to handle radioactive materials and that they can take responsibility for their level of practice.

Conclusion: This paper presents our idea on how to create the network of all professionals and state authorities for establishing and developing good radiopharmacy practice. Qualified personnel and appropriate regulation according to the local and international parameters will be a step forward to have advanced health care system and confidence of the patients.

IAEA-CN-232/401

Unique PET Facility in Skopje - New Perspective for the Health Care of the Patients in the Balkan Region

E. Janevik¹, M. Zdraveska-Kocovska³, M. Velickovska², M. Angeleska³, K. Kolevska¹, M. Atanasova¹, M. Jancovska¹, F. Jolevski¹, Z. Filipovski¹, S. Nikolovski¹, N. Ristevska³, T. Sazdov², Z. Spirkovski², E. Belopeta²

¹Faculty of Medical Sciences, Goce Delcev University Stip, FYR Macedonia

²Project Unit for implementation of Positron Emission Tomography - PET Center Skopje in RM, Ministry of Health, FYR Macedonia

³Institute of Pathophysiology and Nuclear Medicine, Faculty of Medicine, University Ss Cyril and Methodius, Skopje, FYR Macedonia

Corresponding Author: emilija.janevik@ugd.edu.mk

Background: Positron emission tomography has become one of the most promising methods in detecting oncological, cardiological, neurological diseases in the last decade and entered slowly in the other fields showing promising results. As is well confirmed, PET has the key advantage of enabling diagnosis of diseases in the early stages, determining the extent of the disease process and its pathological impact, as well as monitoring the effectiveness of chemotherapy and treatment planning.

Methodology: The University Institute for Positron Emission Tomography is under official establishment as a unique facility in the country and in the Balkan Region. The new facility is result of the Government investment and joint project with IAEA.

The new facility has a Department for Production and Department of Molecular Imaging connected together in the one unique system of Radiation Protection, QA, BMS, Informatics and technical and administrative support connected to the network of the unified Health Care System in the country.

Results: Building includes cyclotron for production of ultra-short-lived isotopes (F-18, C-11, N-13 and option for solid targets), two full GMP production laboratories for PET radiopharmaceuticals, one completely dedicated for FDG production and second includes production of other F-18, C-11, N-13, Ga-68 radiopharmaceuticals, and Cu-64 in the future. The third production laboratory that is part of the same GMP production site is dedicated for small scale production of therapeutical radiopharmaceuticals for clinical trials and investigation. The integrated part are two QC laboratories and one research laboratory for preclinical investigation including toxicological studies of new radiopharmaceuticals.

The Department of Molecular Imaging is located in the second floor with two PET/CT cameras dedicated for clinical investigation and advanced biomedical imaging in humans using extensive suite of state-of-the-art internally produced radiopharmaceuticals as imaging tools.

This institution will be a full partner to the physicians in the patient care not only in the country, but also in the region, as was the most important planned outcome. Providing all an opportunity can be performed only in an institution containing cyclotron and GMP production laboratories

following always the new trends in development of new radiopharmaceuticals.

PET in that condition may serve as a magnet for recruitment in many areas and promote national and international interdisciplinary cooperation, to provide university educational opportunities for master, doctoral and postdoctoral studies, specialties in nuclear medicine, radiopharmacy and medical physics with distinctive strength in education and research and an entrepreneurial dimension.

Conclusion: The University Institute for Positron Emission Tomography in Skopje serves both as a model for future and more widespread use of PET. Unique capabilities of PET may facilitate grant opportunities.

International Conference on Clinical PET-CT and Molecular Imaging (IPET 2015): PET-CT in the Era of Multimodality Imaging and Image-Guided Therapy