

POSTTRAUMATIC SOFT TISSUE IMPINGEMENT OF THE ANKLE: ARTHROSCOPIC FINDINGS AND SURGICAL OUTCOMES

Konstantin Mitev, Saso Mladenovski, Igor Kaftandziev

Filip Vtori Special Hospital for Surgical Diseases, Skopje, R. Macedonia

Corresponding Author: Dr Konstantin Mitev MSc, Filip Vtori Special Hospital for Surgical Diseases, Ilindenska bb, Skopje, R. Macedonia, Mob: +389 (0)2 70 25 24 30; E mail: konstantin.mitev@cardiosurgery.com.mk

Abstract

Painful conditions and limited dorsal flexion of the ankle, which are the result of the friction of joint tissues and also the cause and the effect of altered joint biomechanics, are called ankle impingement syndromes. Post-traumatic ankle injures, like an ankle sprains or ankle fractures, are the main causes of impingement lesions, which result in chronic ankle pain.

Purpose: To evaluate the results for patients treated arthroscopically for anterolateral soft tissue impingement after ankle injury.

Methods: Twelve patients underwent operative arthroscopy for anterolateral impingement between 2010 and 2012, A retrospective study with a mean follow up of 1 year. There were 7 females and 5 males, average age 44.1 years.

Results: Preoperative American ankle and foot score was average, 68 (63–71) points and after the operation 92 (87–95) points.

Conclusion: Soft tissue impingement of the talocrural joint shows painful and limited dorsal flexion and plantar extension, effusion and joint line tenderness especially in the anterolateral gutter. Arthrofibrosis following ankle fractures causes an unfavorable surgical outcome, and arthroscopic debridement of fibrous tissue is an effective means of improving articular function.

Key words: Ankle arthroscopy, soft tissue impingement, AAF score.

Introduction

The ankle's impingement syndromes involve either osseous or soft tissue impingement, which can be anterior, anterolateral or posterior. These syndromes are painful conditions, and limited dorsal flexion of the ankle which are the result of the friction of joint tissues and also the cause and the effect of altered joint biomechanics. Post-traumatic ankle injuries such as ankle sprains or ankle fractures are the main causes of impingement lesions, which result in chronic ankle pain. According to the ISAKOS definition, anterior ankle impingement is a pain syndrome characterized by anterior impingement ankle pain on activity. At the medical investigation, during the palpation,

there is pain at the anterior, anteromedial and anterolateral aspects of the ankle joint. Swelling and limitations of dorsal flexion are present.

Morris, in 1943, first described the impingement of the ankle observing five patients who had what he called athletes ankle. At that period of time, there were three types of intra-articular soft tissue lesions described that lead to these complaints: meniscoid lesions, synovitis and the distal fascicle of the anterior inferior tibiofibular ligament (AITFL). Tibiotalar spurs formation due to repetitive capsule traction is therefore not a plausible reason for anterior ankle impingement.

Anterolateral ankle impingement may be due to hypertrophied soft tissue interposed in

the anterior ankle joint or, on the other hand, proliferation of osteophytes (Fig. 3) that limit the open space between the anterior lip of the tibia and the dorsal talar neck. Different theories have been proposed for describing this condition. One theory is that this impingement often occurs in athletes (soccer players kicking, or dancers), those with forced plantar flexion. Traction on the anterior capsule results in spurs that then impinge, like a single proposed mechanism. Different studies have refuted this theory. In a study of soccer players, Tol et al. found that the spurs typically occur in the location of ball impact without excessive plantar flexion. This suggests that the impact and not traction of the capsule results in the spurring [1].

Van den Bekerom MP also located hypertrophied soft tissue in the anterior joint after ankle trauma, overlying the capsule that was compressed between the tibia and the talus with ankle dorsiflexion [2]. Tol J L's conclusion was that traction could not be responsible for the spurs and that hypertrophied soft tissue in the anterior ankle was likely to be responsible for impingement symptoms [3].

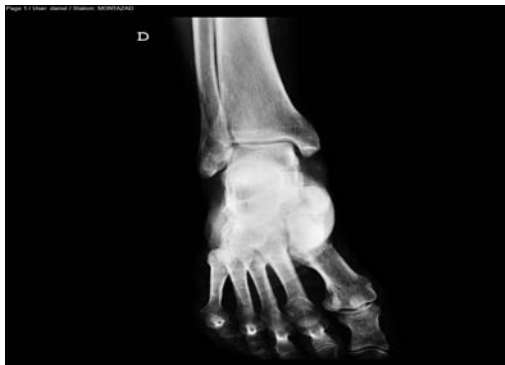

Figure 1 – AP radiography

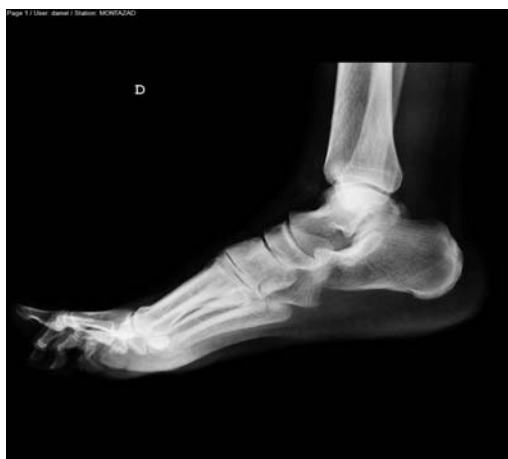

Figure 2 – Profile view

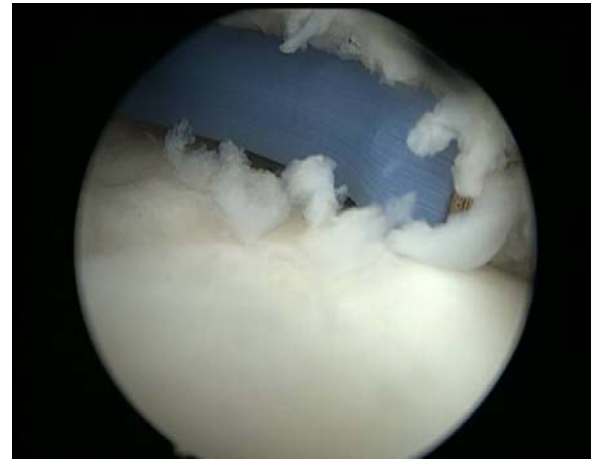


Figure 3 – Debridement

Current opinion is that osteophyte formation is secondary to repetitive ankle sprains or repetitive microtrauma such as one would find with a ball impact or mutual contact between the anterior tibia and talar neck with according repetitive loaded dorsiflexion. Once the osteophytes occur, the space available for ankle dorsiflexion decreases, likely resulting in soft tissue impingement, inflammation, hypertrophy and pain [4].

The presence of osteophytes does not always correlate with impingement, indicating that soft tissue changes must also be necessary. This is supported by the finding that anterior osteophytes are very common, occurring in 59% without symptoms of impingement. This study also demonstrated that talar osteophytes were particularly prominent in the affected patients [5]. It is also widely accepted that soft tissue impingement can occur without the presence of osteophytes. Ankle arthroscopy has demonstrated anterior impingement from the anterior inferior tibiofibular ligament [7] and from a hypertrophied synovium in the absence of significant osteophytosis.

Purpose: To evaluate the results for patients treated arthroscopically for anterolateral soft tissue impingement after ankle injury.

Diagnosis

Patients with anterior impingement often have a history of multiple ankle sprains or old ankle fractures and present complaining of pain and some swelling in the anterior ankle. Patients may not have a history of ankle sprain but complain of increasing pain through training and performance, especially with plié po-

sitions and landing from jumps. Patients are often very sensitive to body position and note a loss of dorsiflexion in the affected ankle usually noted as a loss of ability to plié on the affected side (Figs. 1, 2). The key physical finding is tenderness to palpation along the anterior joint line. Osteophytes at the anterior lateral or anterior medial joint line can often be palpated with the foot in some plantar flexion. Weight-bearing full dorsiflexion of the ankle with the foot flat will often show some limitation on the affected side and reproduce symptoms.

Methods

Twelve patients underwent operative arthroscopy for anterolateral impingement between 2010 and 2012 year this was a retrospective study with a mean follow up of 1 year. There were 7 females and 5 males, average age 44.1 years. All patients reported ankle injury, six of them with operation-treated bimalleolar fractures, four with bimalleolar fractures treated conservatively and two with ankle sprains. Arthroscopy was performed through the antero-medial and antero-lateral portals.

Ankle arthroscopy is a useful tool both for diagnosis and treatment of persistent ankle pain following injury and it may be the only way to definitely diagnose and treat soft tissue impingement from an abnormal fibrous band [7]. Arthroscopy also provides highly effective treatment of bony and anterior soft tissue ankle impingement provided there is no significant associated chondral lesion in the anterior ankle [8].

Surgical treatment is reserved for those in whom conservative measures have failed at least 6 months after the injury or the symptoms appearing. If initial radiographic studies fail to show osseous impingement, then an ankle arthroscopy is performed. Thickened synovial tissue and/or the thickened distal fascicle of the anteroinferior tibiofibular ligament is debrided with a shaver. (Figs. 3, 4, 5) Any articular cartilage damage is addressed with debridement, drilling, and/or microfracture.

For those with osseous impingement, either talar neck or tibial, arthroscopic or open osteotomy can be performed. Any hypertrophied tissue is debrided along with the osteophytes. Open treatment is not recommended when an osteochondral defect is present, but for talar

neck or distal tibial osteophytes without other intra-articular pathology, a small anteromedial arthrotomy can be used effectively.

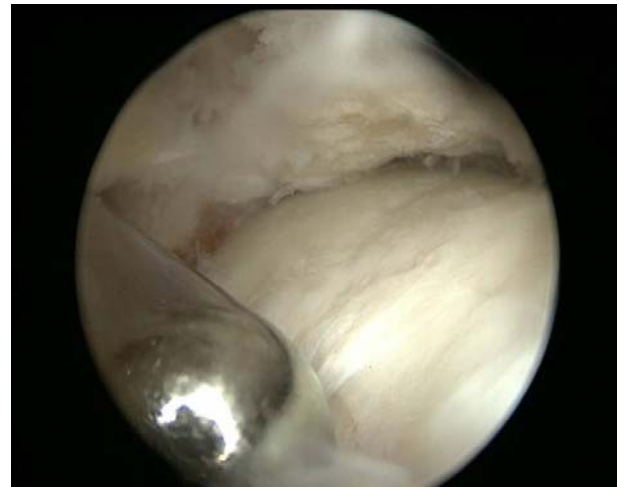


Figure 4 – Ankle debridement

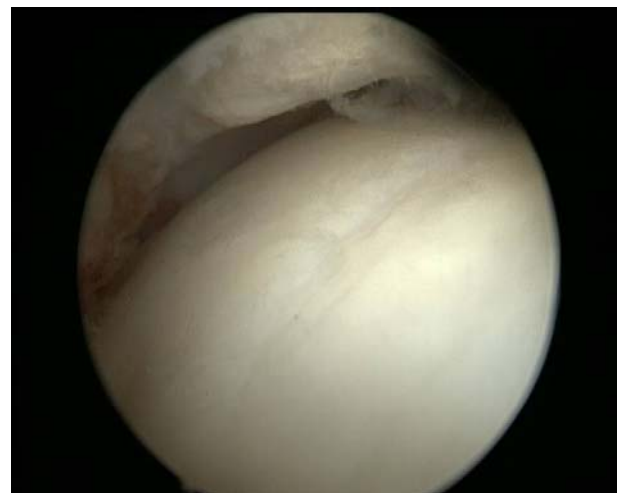
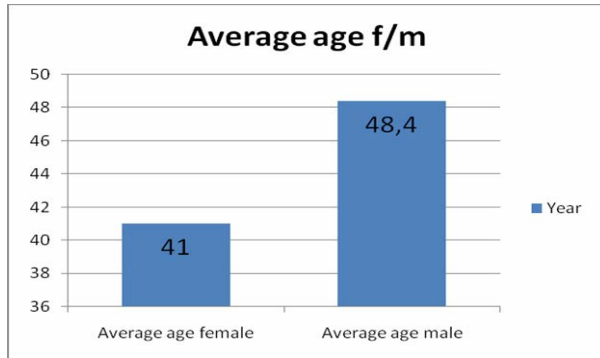


Figure 5 – After debridement of the ankle

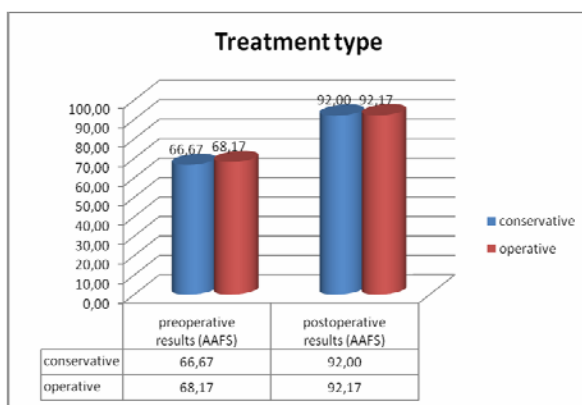
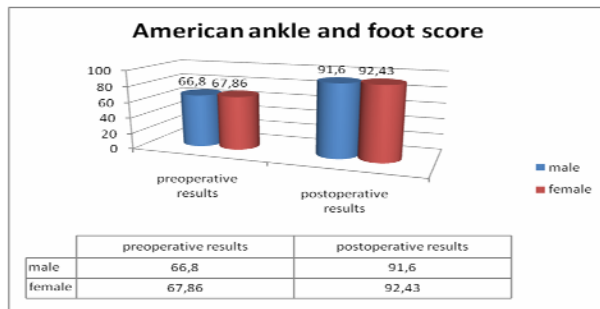
Post-operative care includes use of an ankle cryo-cuff to control edema and pain, alternating with a removable boot for ambulation. Patients are allowed to bear weight as pain allows unless an osteochondral defect has been drilled. In that case, patients are maintained strictly non-weightbearing for 6 weeks. After 10–14 days (for those with simple debridement or osteotomy), the patient is allowed to go without the boot. Physical therapy is begun to gradually increase range of motion and strength, with attention to proprioception exercises. Patients return to everyday activities gradually, as comfort allows. Patients are counseled that a return to full performance may be limited for up to 6 weeks.

Results

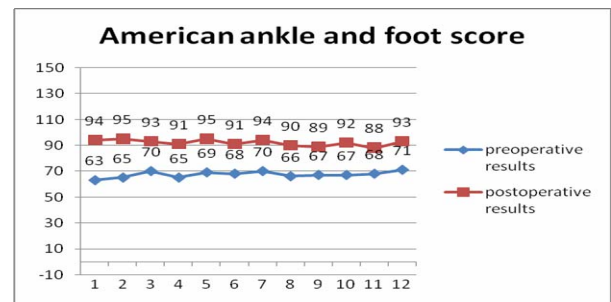
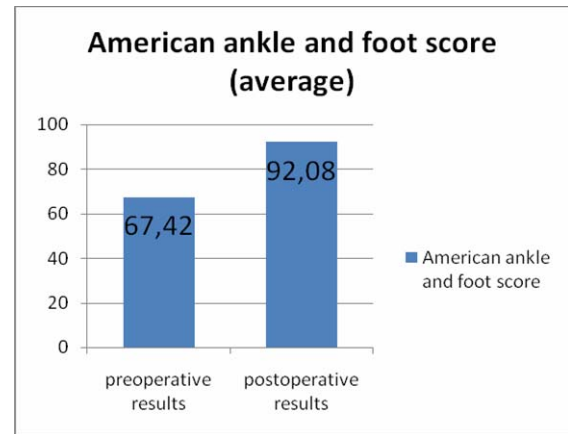
Arthroscopic treatment was successful in all (12) patients who were observed during the period of 1 year follow up. Male versus female were 5/7. Average age 44.1 years.



Six of them were operated due to ankle fractures more than 1 year ago, 4 had ankle fractures older than 6 months which were conservatively treated and 2 had old ankle sprains.



Preoperative American ankle and foot score was average 68 (63–71) points and after the operation 92 (87–95) points with no significant difference in postoperative results between operatively and conservatively treated ankle fractures.



Furthermore, when extensive fibrosis and impingement on the articular surface were present, 88% of patients showed impaired articular function. Arthroscopic debridement of fibrous tissue resulted in improved articular function in 100% of patients with functional deterioration of the ankle joint before arthroscopy (Fig. 6).

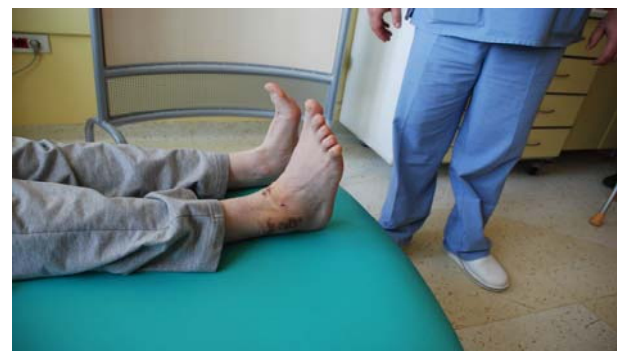

Figure 6 – Postoperative result (1 week)

Discussion

In our study, the first type of treatment of chronic ankle instability was conservative regarding phisycal therapy, relative active limitation and NSAID. After 6 months, if conservative treatment failed, we performed an arthroscopic synovectomy and debridement in twelve patients, according to E. Carlos Rodrigues [6].

Nihall et al. arthroscopically provided a profile of the typical dancer with treated an-

terior ankle impingement [8]. The patients included 7 women and 4 men, all professionals. The women had been for a mean of 18 years and the men 10 years. All reported prior ankle trauma, primary sprains and two fractures. All had tenderness inferiorly or anterior-laterally and all had pain with plié.

Milloy et al. in 2003 found it useful to diagnose synovial soft tissue impingement in the anterior lateral ankle in patients following inversion injury [9]. The retrospective study carried out by Urguden M et al. explains that seventy-three patients underwent ankle arthroscopy. Forty-one had a positive test and 37 of those had synovial hypertrophy in the latter gutter (sensitivity of 94.8%). Of 32 patients with negative symptoms, 2 had synovial hypertrophy (specificity of 88%) [10].

Imaging of suspected anterior impingement starts with plain weight-bearing radiographs of the ankle. According to Moon JS et al. inclusion of talar tilting in grading schemes enhances the assessment of cartilage damage [11]. As discussed above, the diagnosis is primarily clinical but imaging is necessary to rule out other causes of anterior ankle pain and confirm the presence and location of osteophytes that need to be removed to achieve the best surgical results. Plain radiographs including AP and mortise views are less helpful for the diagnosis of impingement, but will demonstrate other causes of ankle pain including fracture, mortise disruption, OCD, and arthritis. The identification of arthritis is important to plan treatment because the surgical results with arthroscopy are significantly worse if arthritis is present [12]. RTG imaging (lateral view) will often demonstrate the tibial and talar osteophytes associated with anterior impingement. An oblique view with the beam 45° craniocaudal and the foot plantar flexed with the leg 30° externally rotated will increase the detection of medially located tibial and talar osteophytes [13]. CT scanning can also be used to identify osteophytes contributing to impingement, and in areas with easy access to CT this is often the preferred method of identifying bony changes in the ankle, especially if plain films are non-diagnostic in the setting of clinical impingement. It is widely accepted that anterior impin-

gement can occur without the formation of osteophytes secondary to entrapment of hypertrophied synovium or torn anterior lateral ligaments [14]. MRI has been studied to evaluate its accuracy in identifying purely soft tissue impingement. T1 and proton density axial views demonstrating thickened synovium in the anterior lateral joint space or hypertrophy of the anterior talo-fibular ligament are the findings most consistently associated with impingement at arthroscopy [15]. The identification of chondral injury to the anterior aspect of the joint is also helpful, as this finding decreases the likelihood that arthroscopic debridement of anterior osteophytes and hypertrophied tissue will result in significant improvement.

Relative activity limitation such as avoiding jumps, avoiding forcing of demi-plié, combined with attention to the correct technique to reduce pronation may improve the symptoms of anterior impingement. Physical therapy with a focus on the entire kinetic chain, joint mobilization, and taping may resolve symptoms in some patients. Use of a night splint or removable walking cast brace can be tried briefly, and a single intra-articular corticosteroid injection may be used in selected cases when other conservative measures prove ineffective. In the study by Kars P. Valkering et al. the term "web impingement" was promoted. He confirmed that anterior ankle arthroscopy is of great value in the diagnostic work-up and treatment [16].

In conclusion soft tissue impingement of the talocrural joint shows rather characteristic clinical symptoms and signs including exertion pain, painful and limited dorsal flexion and plantar extension, effusion and joint line tenderness especially in the anterolateral gutter. Arthrofibrosis following ankle fractures causes an unfavourable surgical outcome, and arthroscopic debridement of fibrous tissue is an effective means of improving articular function so that even in "normal RTG or MRI findings" an arthroscopy should be considered.

REFERENCES

1. Van Dijk CN, Verhagen, ToJJ. Arthroscopy for problems after ankle fracture. *J Bone Joint Surg Br.* 1997; 79: 280–284.
2. Van den Bekerom MP, Raven EE. Post-traumatic anterior impingement of the ankle. *Knee Surg Sports Traumatol Arthrosc.* 2012.
3. Tol JL, Dijk CN. Etiology of the anterior ankle impingement syndrome: a descriptive anatomical study. *Foot Ankle Int.* 2004; 25(6): 382–6 [PubMed].
4. Dijk CN. Anterior and posterior ankle impingement. *Foot Ankle Clin.* 2006; 11(3): 663–83. doi: 10.1016/j.fcl.2006.06.003 [PubMed] [Cross Ref].
5. Stoller SM, Hekmat F, Kleiger B. A comparative study of the frequency of anterior impingement exostoses of the ankle in dancers and nondancers. *Foot Ankle.* 1984; 4(4): 201–3 [PubMed].
6. Carlos Rodrigues-Merchan E. Chronic ankle instability: diagnosis and treatment. *Arch Orthop Trauma Surgery.* 2012; 132: 211–219.
7. Bassett FH, Gates HS, Billys JB, Morris HB, Nikolaou PK. Talar impingement by the anteroinferior tibiofibular ligament. A cause of chronic pain in the ankle after inversion sprain. *J Bone Joint Surg Am.* 1990; 72(1): 55–9 [PubMed].
8. Nihal A, Rose DJ, Trepman E. Arthroscopic treatment of anterior ankle impingement syndrome in dancers. *Foot Ankle Int.* 2005; 26(11): 908–12 [PubMed].
9. Molloy S, Solan MC, Bendall SP. Synovial impingement in the ankle. A new physical sign. *J Bone Joint Surg Br.* 2003; 85(3): 330–3 doi: 10.1302/0301-620X.85B3.12873 [PubMed] [Cross Ref].
10. Urguden M, Soyuncu Y, Ozdemir H, Sekban H, Akyildiz FF, Aydin AT. Arthroscopic treatment of anterolateral soft tissue impingement of the ankle: evaluation of factors affecting outcome. *Arthroscopy.* 2005; 21(3): 317–22 [PubMed].
11. Moon JS, Shim JC, Suh JS, Lee WC. Radiographic predictability of cartilage damage in medial ankle osteoarthritis. *Clin Orthop Relat Res.* 2010; 468(8): 2188–97.
12. Tol JL, Verhagen RA, Krips R, et al. The anterior ankle impingement syndrome: diagnostic value of oblique radiographs. *Foot Ankle Int.* 2004; 25(2): 63–8 [PubMed].
13. Ferkel RD, Karzel RP, Pizzo W, Friedman MJ, Fischer SP. Arthroscopic treatment of anterolateral impingement of the ankle. *Am J Sports Med.* 1991; 19(5): 440–6 doi: 10.1177/036354659101900504 [PubMed] [Cross Ref].
14. Duncan D, Mologne T, Hildebrand H, Stanley M, Schreckengaust R, Sitler D. The usefulness of magnetic resonance imaging in the diagnosis of anterolateral impingement of the ankle. *J Foot Ankle Surg.* 2006; 45(5): 304–7 doi: 10.1053/j.jfas.2006.06.003 [PubMed] [Cross Ref].
15. Meislin RJ, Rose DJ, Parisien S, Springer S. Arthroscopic treatment of synovial impingement of the ankle. *Am J Sports Med.* 1993; 186–189.
16. Kars P, Valkering, Pau Golano, C. Niek van Dijk, Gino M. M. J. Kerkhoffs. "Web impingement" of the

ankle: a case report. *Knee Surg Sports Traumatol Arthrosc.* 2012. DOI 10.1007/s00167-012-2077-4.

Резиме

ПОСТТРАУМАТСКИ МЕКОТКИВЕН ИМПИЦМЕНТ НА СКОЧЕН ЗГЛОБ: АРТРОСКОПСКИ НАОД И КЛИНИЧКИ РЕЗУЛТАТИ

Константин Митев, Сашо Младеновски, Игор Кафтанчиев

Специјална болница за хируршки болести „Филип Втори“, Скопје, Универзитетска клиника за трауматологија, Скопје, Р. Македонија

Вовед: Ограничената дорзална флексија и болната состојба на скочниот зглоб, која е резултат на триењето на зглобните ткива, и причината и ефектот на променетата зглобна биомеханика се познати како импицмент синдром. Посттрауматски повреди, како што се дисторзии и скршеници во пределот на скочниот зглоб, се главни причини за импицмент синдром, кој резултира со хронична болка во скочниот зглоб.

Цел: Цел на трудот е евалуација на клиничките резултати кај пациентите третирани артроскопски поради постоење преднонадворешен мекоткивен импицмент по повреда на скочниот зглоб.

Методи: Клиничките резултати на дваесет пациенти третирани артроскопски поради преднонадворешен импицмент се евалуирани во студијата помеѓу 2010–2012 година.

Ретроспективна студија со просечно време на следење од една година. Испитани се 7 од женски пол и 5 од машки пол со просечна возраст од 43.6 години.

Резултати: Предоперативниот скор (American ankle and foot score) беше просечно 68 (63–71) бода, а по операција 92 (87–95) бода.

Заклучок: Мекоткивен импицмент на скочниот зглоб доведува до болна и ограничена дорзална флексија и плантарна екстензија придружено со ефузија и болна осетливост на палпација посебно во предел на преднонадворешен компартмент. Артроскопскиот дебридман на артрофиброзата е ефикасен метод за подобрување на зглобната функција.

Клучни зборови: артроскопија, импицмент, скочен зглоб.