

LAPAROSCOPIC SURGERY AT THE CHOLECYSTECTOMIA

Irena Trajkovska, S.Jovevska,G.Panova

Faculty of Medical Sciences, University „ Goce Delcev” -Stip, Republic of Macedonia

Apstrakt

Laparoscopic surgery is a type of minimally invasive surgery is performed through a few small holes in the abdomen. Specialized camera optical fiber is passed through one of these holes in order to visualize the interior of the stomach. Through other openings introduced surgical instruments operation is performed.Laparoscopic interventions performed in more surgery but usually applies to cholecystectomy (removal of the gall bladder)

Anatomy of the na gall bladder

Gall bladder (vesica fellea s. Biliaris) collects bile (fel s. bilis) in the period when no digestion, and lies in the eponymous pit (fossa vesicae felleae) localized visceral side of the liver and the border between his lobus dexter and lobus quadratus.

Gall bladder has pear shape. It has different three morphological parts:

a) fundus, b) corpus and c) collum.

a) The fundus of the gall bladder (fundus vesicae felleae) is its extended and blindly closed fundus end. It is coated with visceral peritoneum and fit a shallow incision on the front edge of the liver. Fundus usually does not pass through the edge and normally can not be palpated through the abdominal wall because of its soft and elastic consistency.

b) The corpus of the gall bladder (corpus vesicae felleae) is a medium and longest part (5-6 cm), which lies in the fossa vesicae felleae.

c) The collum of the gall bladder (collum vesicae felleae) is a conical narrowed rear part. It is directed forward, and left with the body form a sharp angle open front.

The colum has pear shape and is long and about 2 cm, contained in the duplicate lig.

hepatoduodenale. His narrow front end continues to pin channel gall bladder (ductus cysticus).

Method of performing of laparoscopic intervention. The surgeon makes a small opening in the abdomen. Normally this opening is located around the navel or lower abdomen. Through this aperture is introduced via a needle which stomach entere carbon dioxide, CO₂, and the stomach is inflated, creating space in which goods can be achieved, and the ability to visualize the operation. Then, through one of the holes in the stomach sets laparoscop (specialized camera). The camera illuminates the inside of the stomach, increases image and system cables transmit to the screen in the operating room. Then inspect - review screen. After surgery, the nurse it checks content cornels, whether the patient breathes good [and better breathing ,keep records na fluid intake, the quantity of urine entered and other fluids. Patient are advised to breathe deeply every hour, checking the airway, bleeding of the wound bleeding

and etc . following vital parameters of the patient. patients are not eat by mouth for several hours to several days and at that time gives infusion. Attention is paid to as to whether whether they contain bile or blood.

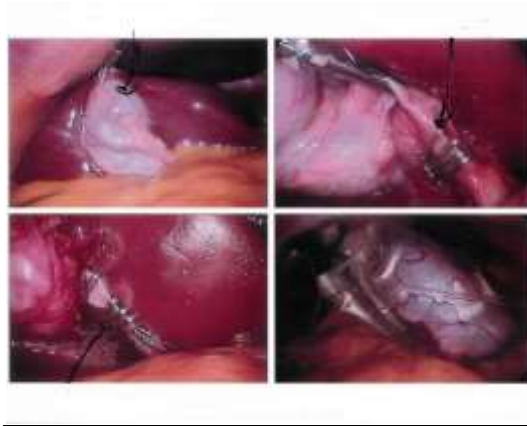


Fig.1 Laparoscopic cholecystectomy

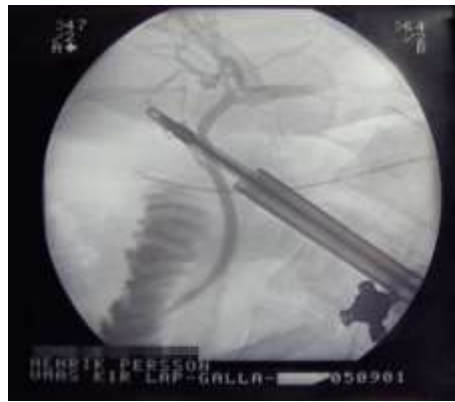

Fig.2 X-ray imaging during cholecystectomy

References

1. Carli F, Charlebois P, Baldini G, Cachero O, Stein B. An integrated multidisciplinary approach to implementation of a fast-track program for laparoscopic colorectal surgery. *Can J Anaesth* 2009; 56(11):838-42
2. Patel GN, Rammos CK, Patel JV, Estes NC. Further reduction of hospital stay for laparoscopic colon resection by modifications of the fast-track care plan. *Am J Surg* 2010; 199(3):391-4
3. Vlug MS, Wind J, Hollmann MW, Ubbink DT, Cense HA, Engel AF, Gerhards MF, van Wagenveld BA, van der Zaag ES, van Geloven AA, Sprangers MA, Cuesta MA, Bemelman WA; LAFA study group. Laparoscopy in combination with fast track multimodal management is the best perioperative strategy in patients undergoing colonic surgery: a randomized clinical trial (LAFA-study). *Ann Surg* 2011; 254(6):868-75

4. Anesteziologija - Predrag Lalevic

5. Anesteziologija so reanimacija - Marija Soljakova so sorabotnicite

6. Vospalenie na zolcno kese - Prof. D-r. Liljana Tevdovska

7. Anatomija na covekot - Prof. dr Anica Kargovska Klisarova

8. Fiziologija - Jolic