



Prevalence and morphological variability of torus palatinus and torus mandibularis

Zlatanovska K. *, Zarkova J. , Radeska-Panovska A. , Papakoca K. , Dimova C.

University of Goce Delcev- Shtip, Faculty of Medical Sciences, Dental Medicine

19th BaSS Congress
April 24 – 27, 2014f
Belgrade, Serbia

Introduction

The oral tori are non-pathological and benign exostosis of the cortical and limited amount of bone marrow, covered with a thin and poorly vascularized mucosa. Because the tori are usually asymptomatic, except in cases of significant growth or in edentulous patients, their finding usually happens accidentally during clinical examination.

The purpose of this study was to determine the prevalence of torus palatinus (TP) and torus mandibularis (TM) and morphological variability in relation to age and gender in the population of Shtip region, Macedonia.

Methods and materials

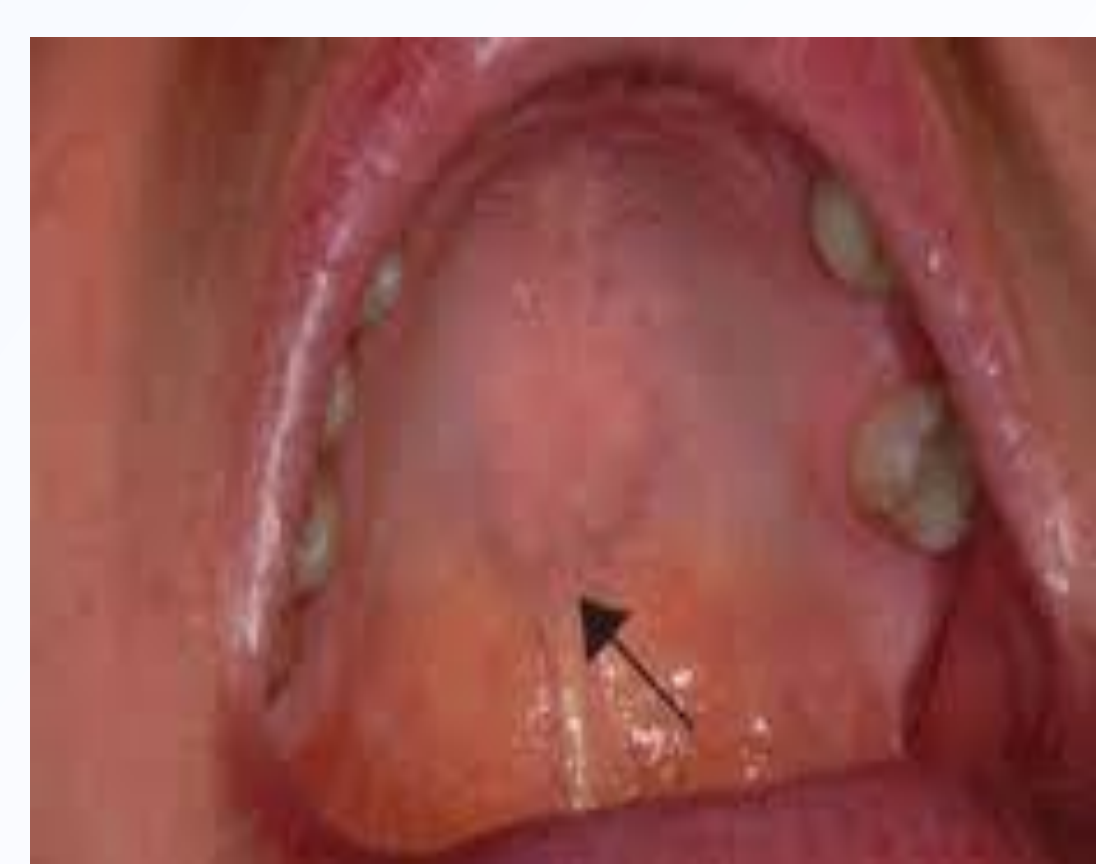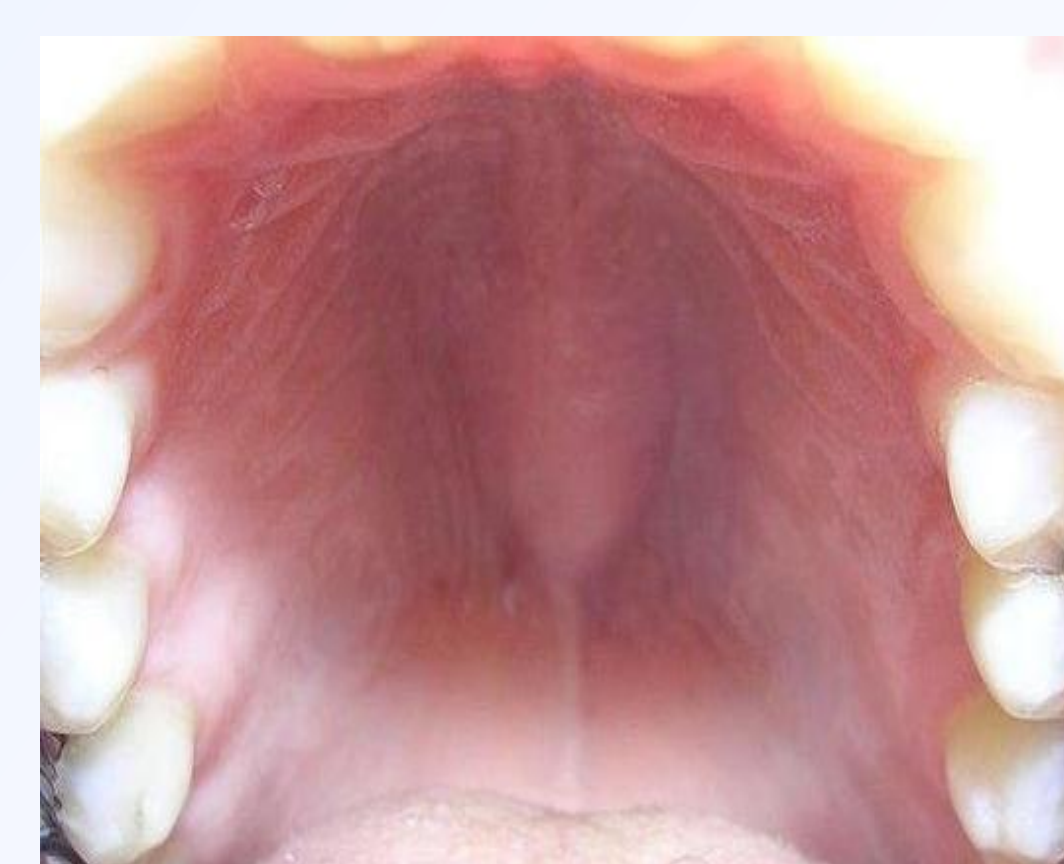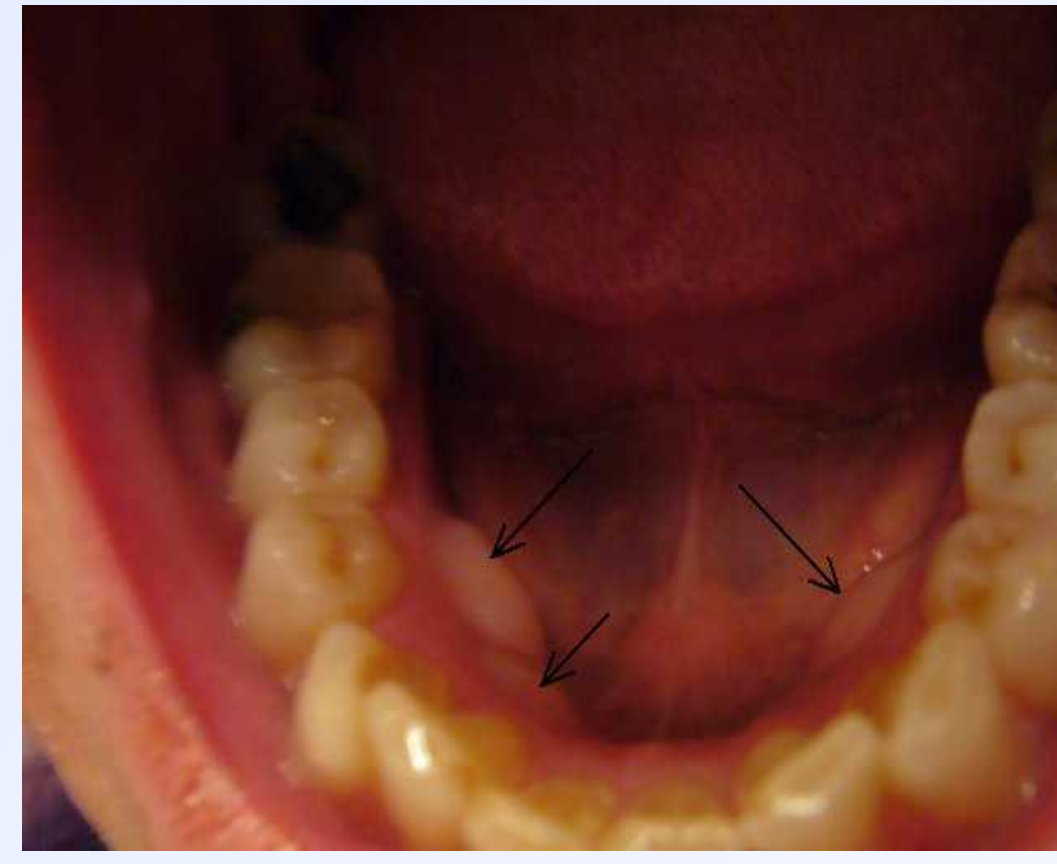
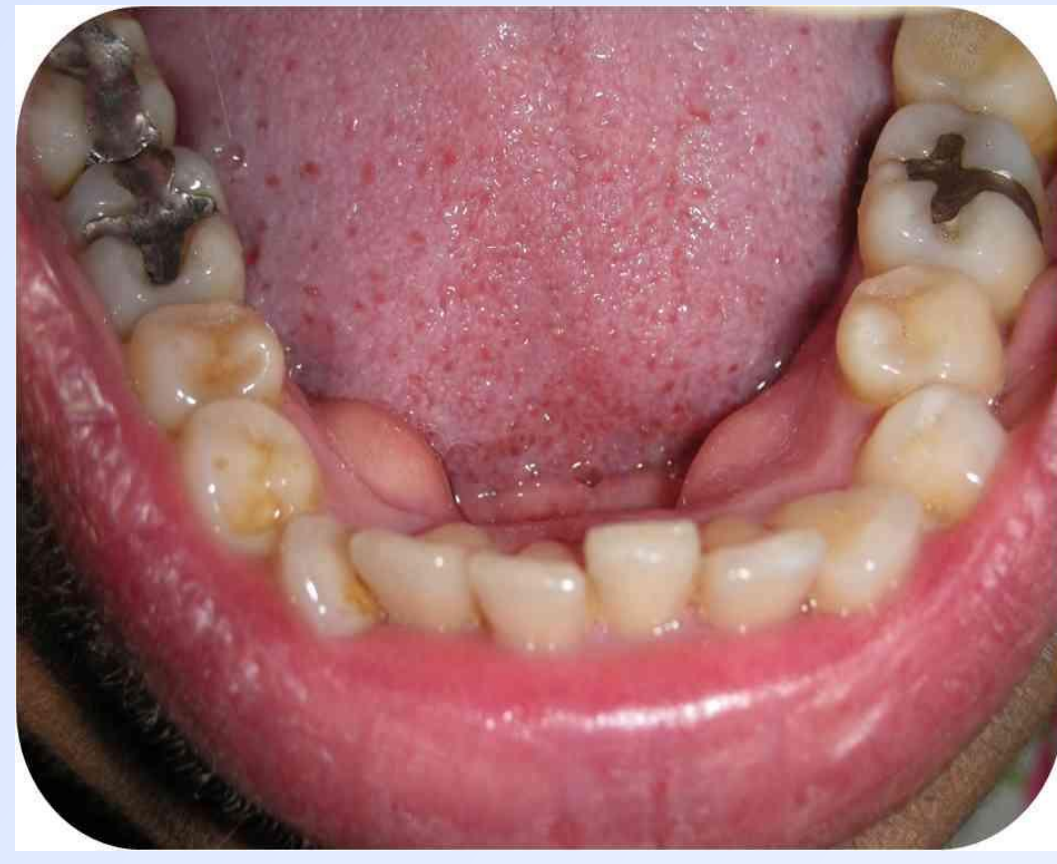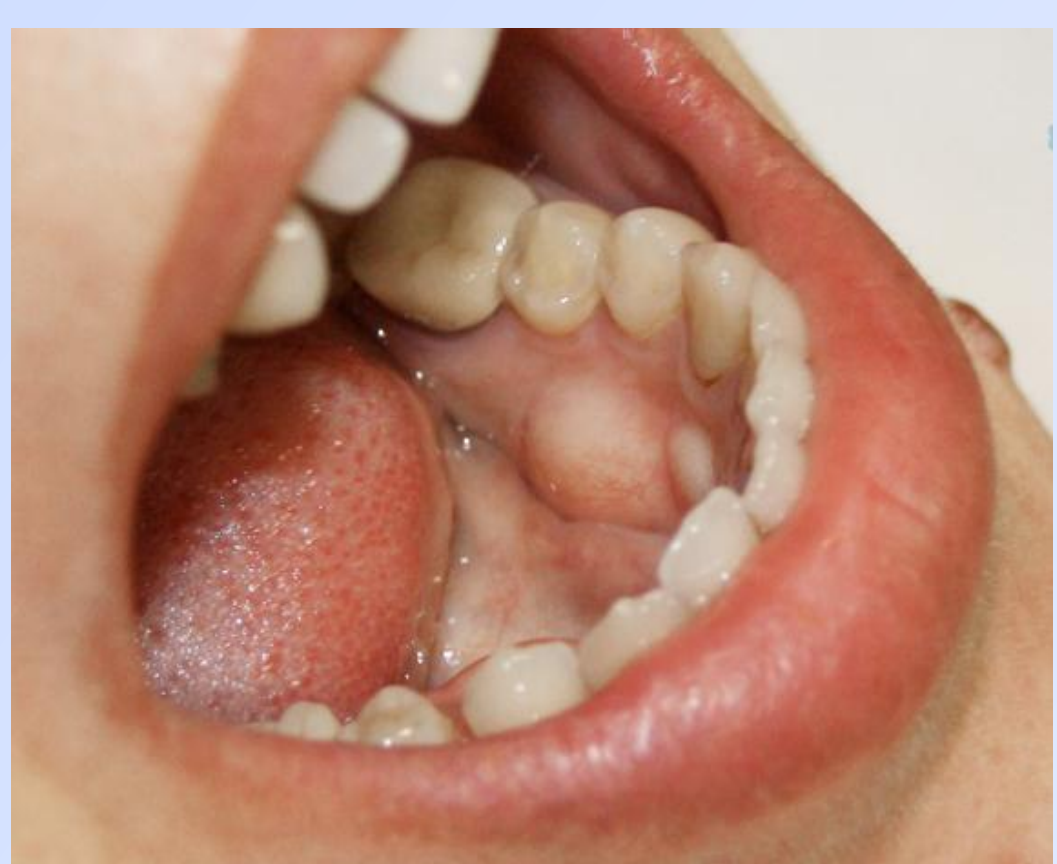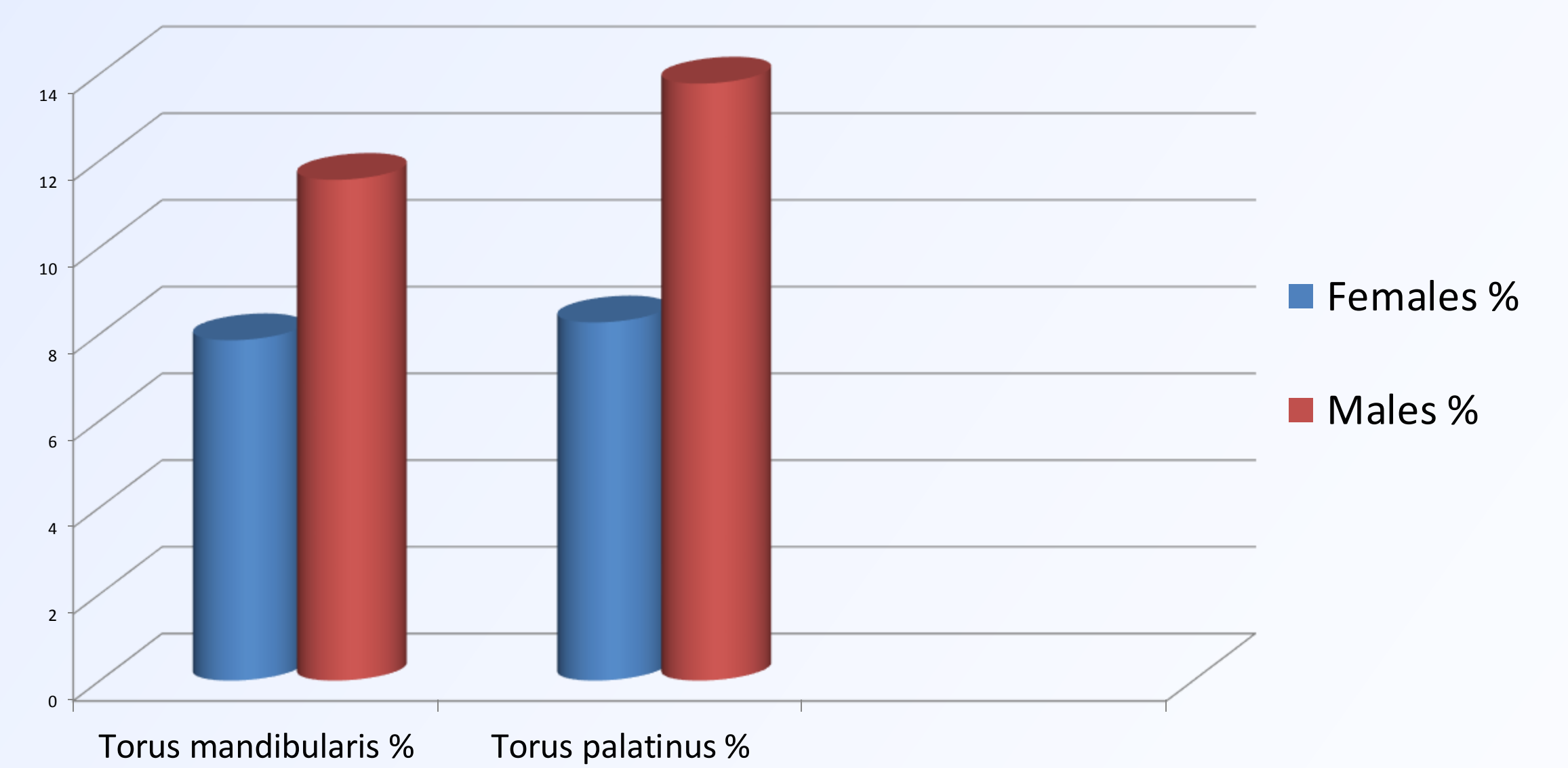
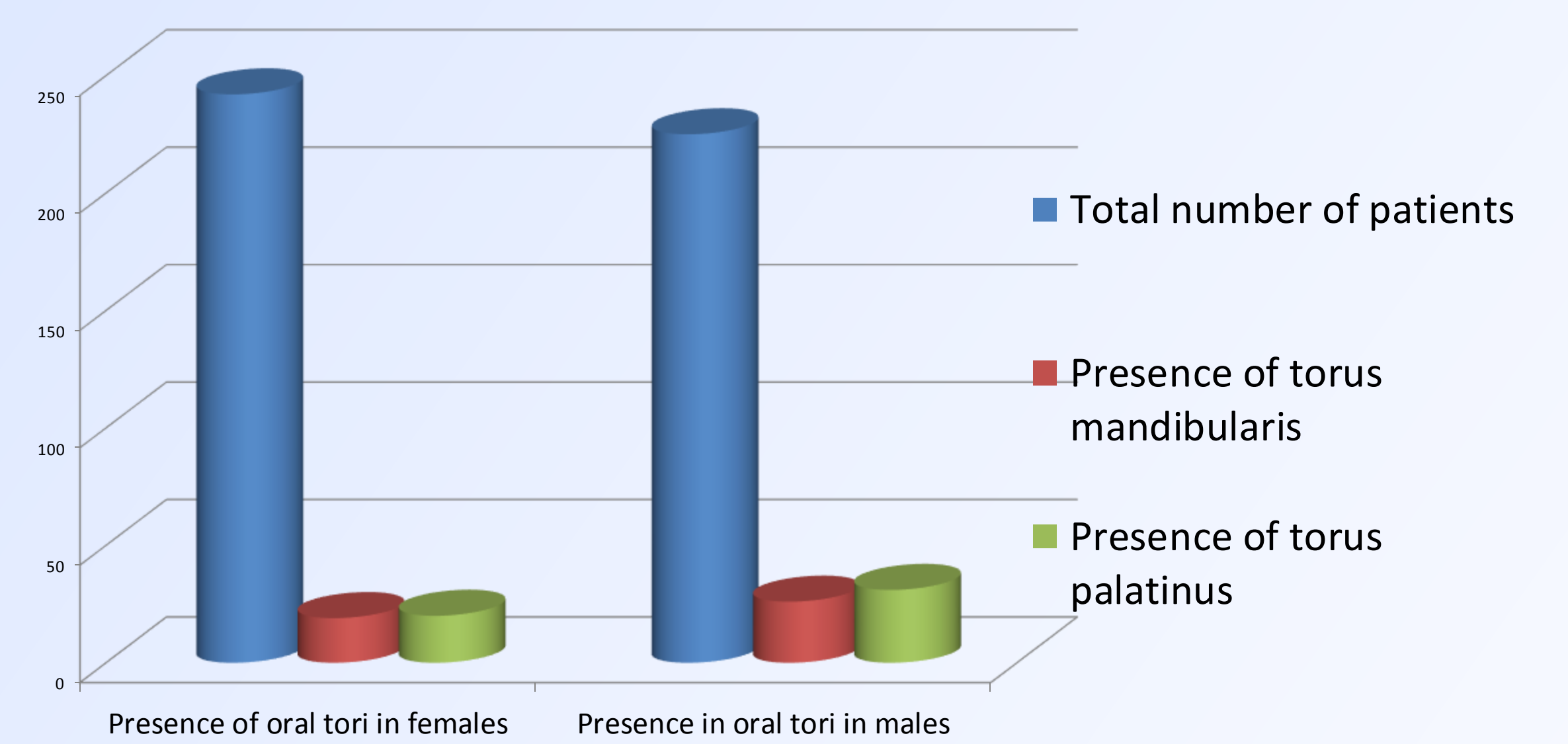
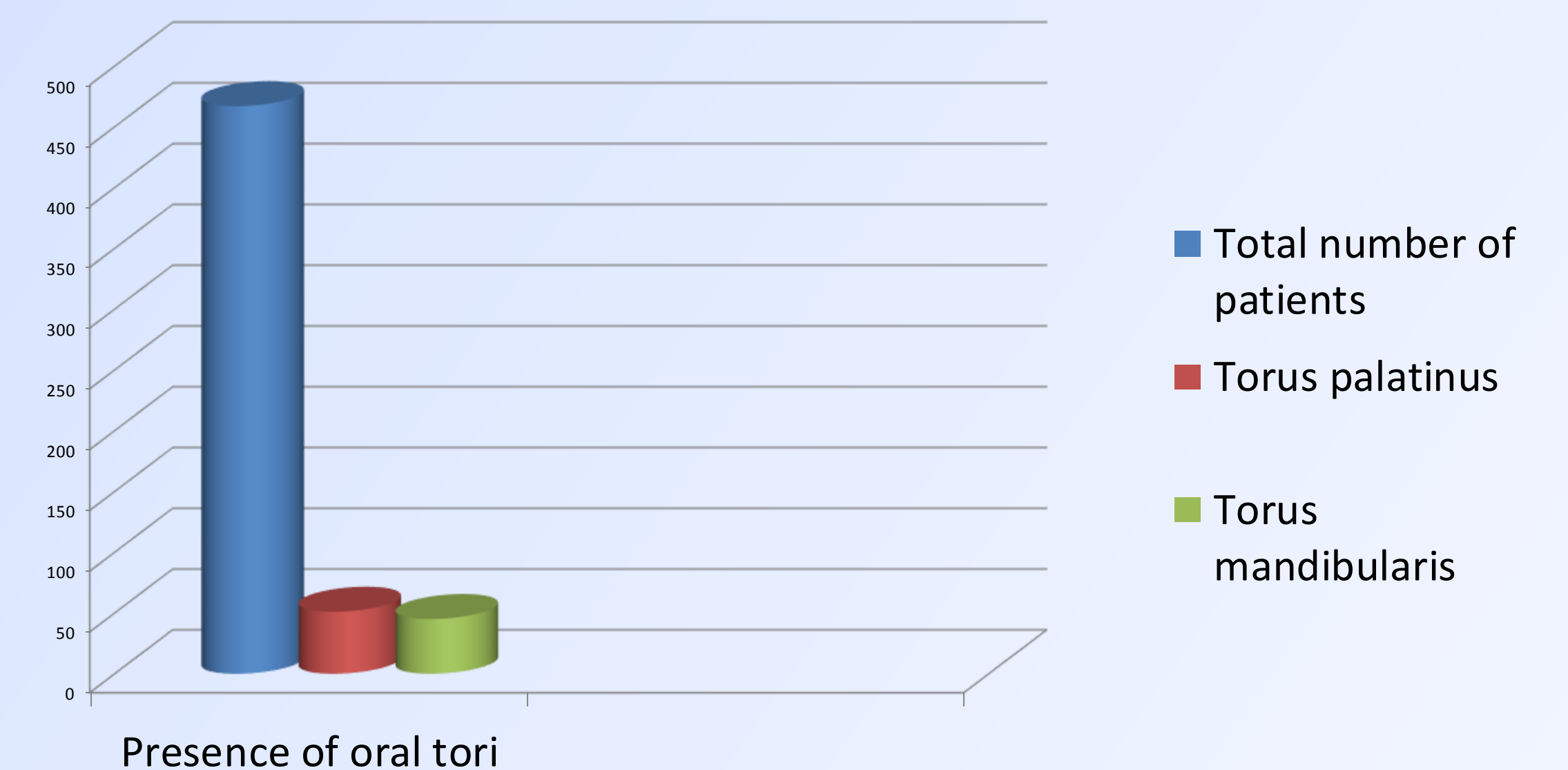
The study comprised of 467 subjects, 242 females and 225 males, who attended four dental offices in Shtip in a period of one year. The subjects were from 20 years old and onwards, divided according to gender and were split into 5 age groups. They were examined for the presence or absence of TP and TM and morphological variability - analysis of form, location and symmetry. The presence of tori were confirmed by clinical examination, palpation and analysis of the plaster casts.

The form of the TP was established as flat, spindle-shaped, nodular and lobular. The forms of the TM take into consideration four categories, solitary bilateral, multiple bilateral, solitary unilateral and multiple unilateral. The symmetry of the TM was analyzed, for both sides, and for each individual.

Results

In the present study the age of the patient with tori ranged from 20 to 70 years, majority (38.0% of female and 36.0% of male patients) were in the age group of 51-60 years. From the total number of 467 subjects, 51 (10.9%) had torus palatinus, whereas torus mandibularis was found in 45 subjects, which is 9.6% of the total population. The torus palatinus was well developed in 48.4 % of the individuals, spindle-shaped form and its more frequent location was in the middle palate. The most frequent type of torus mandibularis was bilateral solitary torus mandibularis (32.4%).

The results of this study show significantly higher prevalence of torus palatinus and torus mandibularis in the male subjects. Torus mandibularis was found in 19 females (7,85% of female population) and in 26 males (11,55% of male population). Torus palatinus was found in 20 females (8,26% of female population) and in 31 males (13,77% of male population).



Conclusion

The results of this study show significantly relationship between the occurrence of tori and gender and although not significant, there is a trend towards higher prevalence of TP and TM with increasing age.