

## **TREATMENT OF NON-METASTATIC HIGH-GRADE OSTEOSARCOMA**

**(STUDY OF 30 CASES TREATED WITH SCANDINAVIAN  
OSTEOSARCOMA PROTOCOL XIV AND SURGERY)**

**Samardziski M.,<sup>1</sup> Zafiroski G.,<sup>1</sup> Tolevska C.,<sup>2</sup>  
Zafirova-Ivanovska B.,<sup>3</sup> Kostadinova-Kunovska S.,<sup>4</sup>  
Kalicanin-Markovska M.<sup>1</sup>**

<sup>1</sup>*Musculoskeletal Tumours Department, University Orthopaedic Surgery Clinic,  
Skopje, R. Macedonia*

<sup>2</sup>*Radiotherapy and Oncology Institute, Skopje, R. Macedonia*

<sup>3</sup>*Epidemiology and Statistics Institute, Skopje, R. Macedonia*

<sup>4</sup>*Pathology Institute, Skopje, R. Macedonia*

**Abstract:** The aim of this study is to improve 3-years survival rates and functional outcome in high-grade osteosarcoma patients treated with amputations and limb-sparing surgery, introducing Scandinavian Sarcoma Group chemotherapy protocol (SSG XVI).

*Patients and methods.* During the period 2000–2005, thirty seven patients with high-grade, non-metastatic osteosarcoma on the extremities were treated at the Clinic for Orthopaedic Surgery in Skopje. Male patients were 21 (57%) and female were 16 (43%). Patients age varied from 8 to 63 years (mean  $18 \pm 13$ ). Seven patients (7/37) did not comply with including criteria and were excluded from the study. The rest 30 patients were introduced to two courses of pre-operative chemotherapy (high doses of Methotrexate, Cisplatin and Adriamycin). Surgical treatment was in 9-th week of the protocol. In 27/30 (90%) of the patients limb-sparing surgery was done, and in 3/30 (10%) amputations were performed. Histopathological assessment of the tumour after the neo-adjuvant chemotherapy divided the patients into group with bad and group with good response. All the patients had 3 more courses of chemotherapy after surgery (same as the preoperative). Patients with bad response were introduced to 3 more cycles of 5 days with high-dose of Ifosfamide. Follow-up was from 2 to 8 years, mean 51 months.

*Results.* Histopathological assessment showed that 57% of the patients had bad response to neo-adjuvant chemotherapy, but there was no statistical significance in the survival time of the groups ( $p = 0.06$ ). Three-years survival time was 40% of the patients with local recurrence in comparison with 80% of the patients with no local recurrence. Three-years survival time was 20% of the patients with distant metastases in comparison with 92% of the patients with no metastases. Overall survival time (OS) was 80%. After 3 years 60% of the patients were disease-free (DFS).

*Conclusion.* High-grade osteosarcoma of the extremities treated with modern chemotherapy protocols enables limb-sparing in the same time with improved survival time of the patients. Introducing high-dose Ifosfamide in treatment of patients with bad response after neo-adjuvant chemotherapy improves their functional results as well as the survival time.

**Key words:** osteosarcoma, neo-adjuvant chemotherapy, limb-sparing.

### *Introduction*

Osteosarcoma is a very rare malignant bone tumour with an incidence of 4–6 cases in 1,000,000 inhabitants and appears mostly in the young and active population aged between 10 and 30. [23] Amputations and disarticulations, the dominant treatment for malignant bone tumours in the beginning of 20<sup>th</sup> century, are rarely and very selectively used now. In spite of aggressive and radical surgery, the 5-year survival was low (10–20%). [18, 19] The introduction of new sophisticated diagnostic methods (CT and MRI) gave the possibility of precise anatomic definition of the tumours and the borders of infiltration in the surrounding tissue. [11] After 1980, improvement of chemotherapeutic protocols with neo-adjuvant chemotherapy, better preoperative planning and modern reconstructive options after the resection of osteosarcoma led to better survival rates of the patients with limb-sparing procedures. [1, 3, 16, 22] Better planning of the biopsy and the definite operative procedure, and fostering better patient selection for specific treatment strategies, have decreased the risk of spreading the osteosarcoma in surrounding tissue and lowered the risk of distant metastases. [6, 18] Currently, 80–85% of the patients with osteosarcoma on the extremities can be treated safely with wide resection and limb preservation. [7] A multidisciplinary approach to diagnosis and treatment, multimodal chemotherapy and a number of options for reconstruction after osteosarcoma resection (especially in chemotherapy-sensitive tumours) have increased long-term survival rates from 60% to 70%. [7, 13, 14, 17]

### *Material and Methods*

In the period from 2000–2005, 37 patients with high-grade, extremities-localized osteosarcoma, were treated at the University Orthopedic Surgery Clinic in Skopje with neo-adjuvant chemotherapy and surgery.

Selection of the patients was done according to the following including criteria:

- histopathologically proven high-grade osteosarcoma (grade III or IV),
- primary localization on the extremities, with no evidence of lung or other metastases,
- patient age between 8 and 65,
- normal hepatic and renal function,
- leukocyte range over  $3.0 \times 10^9/L$  and thrombocyte range over  $100 \times 10^9/L$ ,
- neo-adjuvant chemotherapy introduced no later than 1 month after histological diagnosis of osteosarcoma.

Excluding criteria for the patients were:

- patients with central localization of osteosarcoma (eg. pelvis, vertebra),
- evidence of lymphatic or haematogenous metastases at the time of diagnosis,
- patients younger than 8 or older than 65 years,
- pregnant or nursing women.

Diagnosis was made by clinical examination, plane x-rays, CT, MRI and histopathologically (with open biopsy). Staging was done with Tc 99m bone scans, x-ray of lungs and CT. For preoperative planning MRI and arteriography were obtained. After completion of the chemotherapy protocol, clinical and radiographic evaluation of patients was done every 3 months in the first year and twice a year after that.

Male patients were 21 (57%), and female were 16 (43%). Patients were aged from 8 to 63 (mean  $18.3 \pm 13.4$ ). In 5 (14%) patients osteosarcoma was localized on the upper limb and in 32 (86%) it was localized on the lower limb. According to the criteria, 7/37 patients were excluded from the study. Twenty-seven patients were treated with limb-sparing surgery, and 3 patients were treated with ablative surgery. Patients' characteristics, due to many clinical attributes, are shown in Table 1.

All patients were introduced to the Scandinavian Sarcoma Group XIV neo-adjuvant chemotherapy protocol (SSG XIV). Patients received 2 cycles of preoperative chemotherapy (high dose Methotrexate  $1200\text{mg}/\text{m}^2$ , Cisplatin  $45\text{mg}/\text{m}^2$ , Adriamycin  $75\text{mg}/\text{m}^2$ ).

Table 1 – Табела 1

*Clinical attributes of patients with high-grade osteosarcoma localised on extremities, treated with chemotherapy and surgery*

*Клинички карактеристики на пациенти со осстеосаркоми со висок степен на малигнијетет, локализирани на екстремитетите, а лекувани со хемотерапија и хируршко остврачување*

No	Age	Gender	Complications	Recurrence (months)	Metastases (months)	Follow-up (months)	Exitus (months)	Respond to chemo.*	MSTSS (%)**
<i>Patients with limb preservation</i>									
1	25	m	0	0	22	30	30	B	83.3
2	13	m	haematoma	0	20	25	0	B	60.0
3	23	m	transitor.parez	0	0	46	0	B	80.0
4	16	f	0	0	0	41	0	G	56.7
5	15	f	infection	0	63	68	68	B	46.7
6	14	m	0	0	0	56	0	G	70.0
7	13	m	0	0	0	41	0	G	83.3
8	16	f	seroma	0	0	60	0	G	73.3
9	17	f	skin necrosis	6	15	25	25	B	86.7
10	54	f	0	0	0	43	0	B	63.3
11	14	f	0	0	0	100	0	G	80.0
12	63	m	0	0	0	101	0	G	96.7
13	17	m	loosening	0	0	60	0	B	66.7
14	16	m	0	0	0	64	0	G	96.7
15	20	f	0	0	51	54	54	B	80.0
16	20	f	0	0	0	40	0	G	73.3
17	23	m	0	4	0	42	0	B	33.3
18	39	f	skin necrosis	53	0	66	0	B	83.3
19	14	m	0	0	0	101	0	G	70.0
20	8	m	0	0	0	33	0	B	73.3
21	44	f	haematoma	0	0	53	0	B	90.0
22	14	m	0	0	35	40	40	B	83.3
23	44	f	0	0	0	70	0	G	63.3
24	15	f	0	0	0	100	0	G	93.3
25	15	m	loosening	2	19	27	27	B	76.7
26	24	f	infection	18	0	28	0	G	56.7
27	34	m	0	31	0	32	0	B	33.3

Patients with amputations									
28	24	m	0	0	0	34	0	G	40.0
29	13	m	seroma	0	0	25	0	B	46.7
30	15	m	seroma	35	43	45	0	B	36.7

\*G – good response after neo-adjuvant chemotherapy (more than 90% of the tumour); B – bad response after neo-adjuvant chemotherapy (more than 10% viable tumour)

\*\* MSTSS – Musculoskeletal Tumour Society score

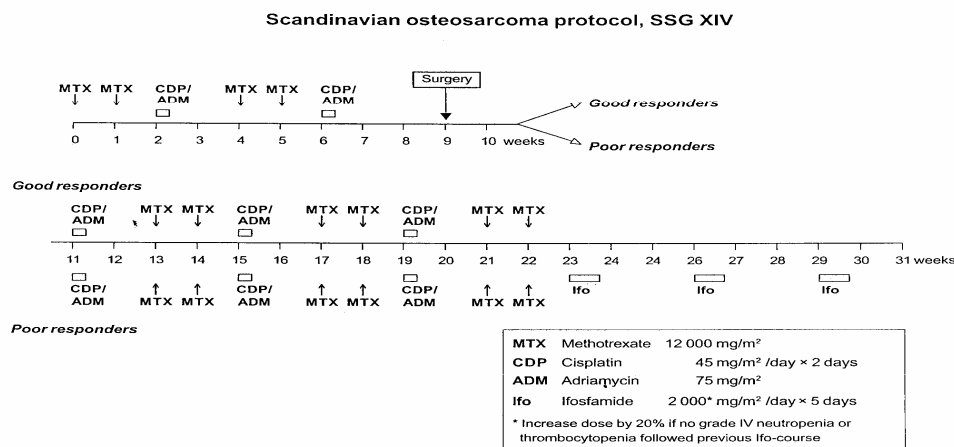


Figure 1 – Scandinavian Sarcoma Group protocol (SSG XIV) for treatment of osteosarcoma

Слика 1 – Проїєколойї на скандинавскаїя ґруїа за їреїман на осїеосаркоми (SSG XIV)

Surgical resection of the osteosarcoma was made 9 weeks after the beginning of neo-adjuvant chemotherapy, as shown in Figure 1. After resection, a detailed histopathological assessment of the specimen was done to determine the extent of necrosis of the tumour tissue. Patients were grouped according to the percentage of necrotic tumour tissue. The first group had a good response to chemotherapy (> 90% necrosis of the tumour). The second group had a bad response to chemotherapy (> 10% viable tumour). According to the "good or bad response" of the tumour to chemotherapy, patients were subjected to a different "branch" of the protocol (Figure 1). All 30 patients received 3 courses of postoperative chemotherapy (the same as preoperative). Patients with bad responses received 3 more cycles of chemotherapy with high doses of Ifosfamide (Ifosfamide 2000 mg/m<sup>2</sup> and × 5 days in the cycle).

Table 2 – Табела 2

*Enneking's surgical resection margins**Enneking-oviiie хирурџики ѓраници ѓри оџсџранување на тумор*

<i>Margins of resection</i>	<i>Explanation</i>
Radical resection	Resection of the whole anatomical compartment
Wide borders of resection	Resection of the tumour with 1 to 1.5 cm of surrounding tissue
Marginal borders of resection	Resection is in the vicinity of the tumour, but pseudocapsule is not disrupted
Intratumoural resection	Excision is made through tumour pseudocapsule, (no tumour sterility and radicality achieved)

The histopathological assessment of the specimen did not give only the extent of tumour necrosis, but also information on tumour-free margins. The primary goal was to achieve tumour-free margins. Intralesional resections or marginal resections were unacceptable. If this goal was not reached, the extremity was amputated. (Table 2). [9]

We followed the four basic principles of limb-sparing procedures: 1) local recurrence should be no greater and survival no worse than by amputation; 2) the procedure, or treatment of its complications, should not delay adjuvant therapy; 3) reconstruction should be enduring and not associated with a large number of local complications requiring secondary procedures and frequent hospitalization; 4) function of the limb should approach that obtained by amputation, although body image, patients' preference and life-style may influence the decision. [21]

When "negative" tumour margins were obtained, a large skeletal defect was often present, requiring reconstruction of the bone, muscles, other soft tissues, and the skin. Patients' age, tumour location and extent of resection narrowed the list of appropriate surgical alternatives. The extent of the disease, anatomical location of the tumour and the patient's age defined the most appropriate surgical procedures.

Several options for limb-sparing were available:

- resection arthrodesis and other techniques with special indications (Figure 2a, b, c), [2, 4, 8]
- modular or special expanding endoprostheses (Figure 2d, e, f), [11, 13, 17]
- cortico-spongy or bulk auto-graft (Figure 2g, h, i). [2, 8, 14]

For the patients who could not satisfy the principles of limb preservation, ablative surgery was taken into consideration. For these patients disarticulation of the hip or shoulder girdle, femoral or below knee, humeral or other amputations were more appropriate. [4]

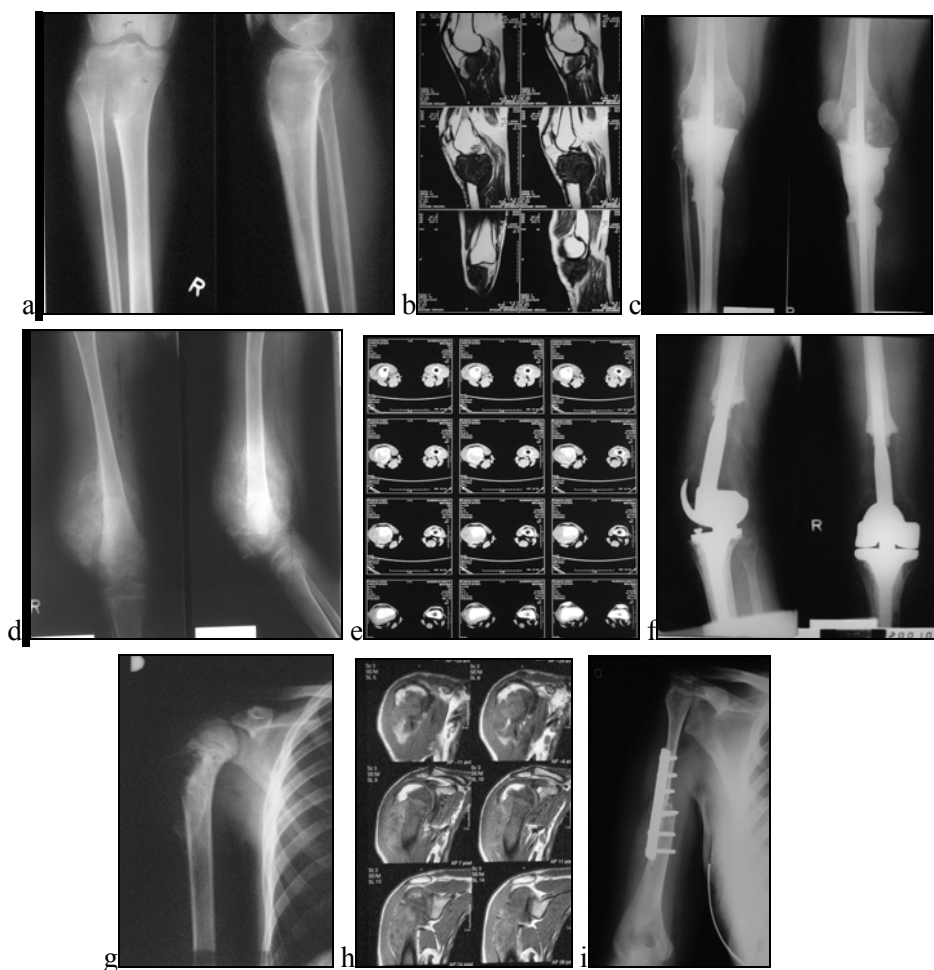

Figure 2 – Various surgical options for limb-sparing: **a, b, c** x-rays and MRI of tibial osteosarcoma treated with resection arthrodesis (temporary or first stage procedure); **d, e, f** x-rays and CT of osteosarcoma patient with distal femur and knee special endoprosthesis reconstruction (Link); **g, h, i** x-rays and MRI of proximal humerus osteosarcoma treated with vascularised cortico-spongious graft (fibula) and osteosynthesis

Слика 2 – Различни хируршки техники за зачувување на екстремитетите: **a, b, c** радиографија и магнетна резонанса на тибисјален остеокарком иреширан со ресекција и артиродеза на коленото (како привремена или процедура во прв акти); **d, e, f** радиографија и компјутерска томографија на пациенти со остеокарком, кај кој е направена реконструкција на долниот дел од бујината коска и коленото со специјална туморска ендопротеза (Link); **g, h, i** радиографија и магнетна резонанса на остеокарком локализиран на горниот дел од надлактината коска, која е хируршки отстранување е реконструирана со васкуларизиран кортико-спонгиозен пресадок (од фибула) и остеоинтеграција

A Musculoskeletal Tumour Society score (MSTSS), based on Enneking's system for functional evaluation of reconstructive procedures, was used to determine the functional results. [10] This score system evaluates: pain, function, patient's emotional acceptance (pertinent to the patient as a whole) and specific factors for evaluating upper limb (range of motion, manual dexterity and lifting ability) or lower limb (need of support with orthopaedic accessories, ability to walk, and gait). For each of six factors, values from 0 to 5 are assigned, with a total of 30 (or 100% function of the limb). For each factor, values 1, 3 and 5 are equated with criteria levels of achievement or performance. Intermediate values of 2 or 4 are assigned, based on the examiner's judgment, when achievement or performance falls between the specified values. It is recommended that results be reported numerically in percentages of normal function (Table 1).

The cumulative prospect of 3 years overall survival (OS) was calculated using the Kaplan-Meier method. [15] The statistical significance of the differences between the survival curves was evaluated using the Log-Rank test and the generalised Wilcoxon test, with the criteria of probability being less than 0.05.

Follow-up was 2 to 8 years, mean 51.7 ( $\pm$  23.6) months. Results were updated in December 2007.

### Results

Thirty patients (30/37) included in the study were divided into two groups: 27 with limb-sparing and 3 with ablative surgery (Table 2).

Histopathological assessment showed a bad response to neo-adjuvant chemotherapy in 57% of the patients (17/30). In the group of patients with a bad response, 75% survived for 36 months, and in the group with a good response 100% of the patients survived 36 months (as shown in Figure 3). Statistical analysis showed *no significance* between the groups (*Log-Rank test* = 1.87 *p* = 0.06).

Five patients (5/30) or 16.7% developed local recurrence between 2 and 36 months after surgery. In the group of patients with local recurrence 40% survived for 36 months, and in the group without local recurrence 88% of the patients survived 36 months (as shown in Figure 4). Statistical analysis showed a high significance (*Log-Rank test* = -2.48 *p* = 0.013).

Five patients (5/30), or 16.7%, developed distant metastases from between 15 to 36 months after surgical treatment. Only 20% survived for 36 months in the group of patients with metastases, compared to the group of patients without metastases, where 92% of the patients survived 36 months (as shown in Figure 5). Statistical analysis showed high significance (*Log-Rank test* = 3.7 *p* = 0.0002).



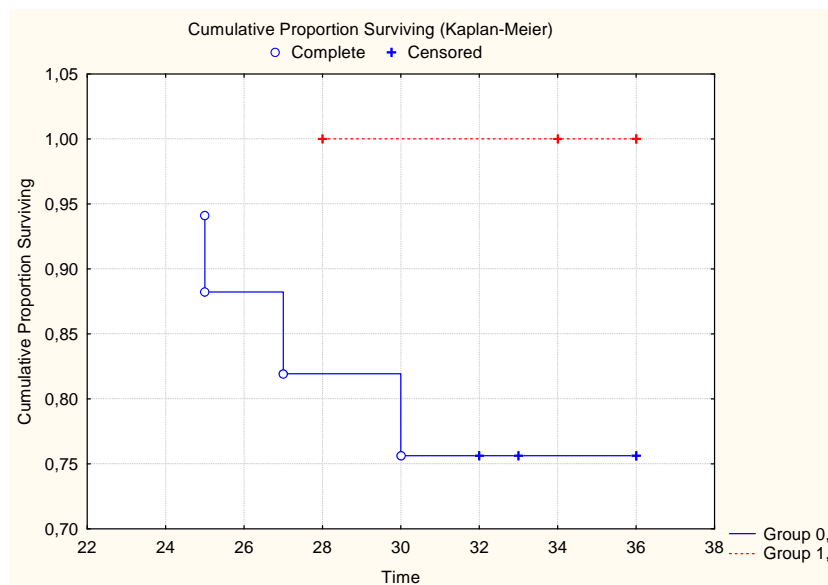


Figure 3 – Cumulative proportion surviving according to response after neo-adjuvant chemotherapy. (Group 0 – patients with bad response, group 1 – patients with good response)

Слика 3 – Вкујно преживување на пациенти според одговорот на нео-адјувантната хемотерапија. (Група 0 – пациенти со лош одговор на хемотерапијата, група 1 – пациенти со добар одговор)

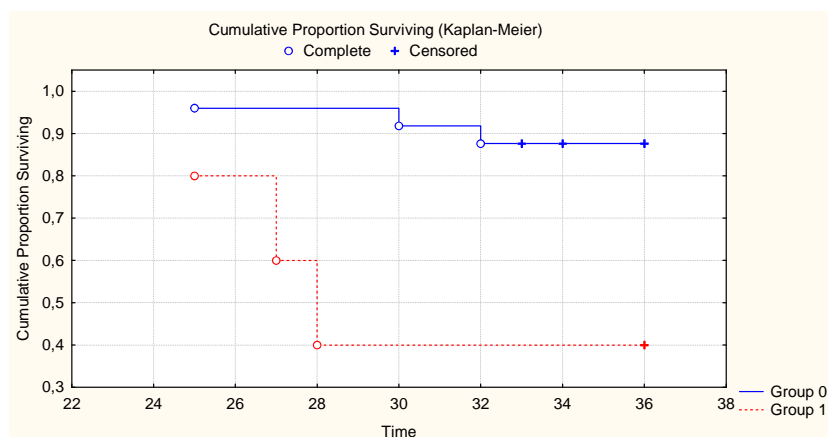


Figure 4 – Cumulative proportion of surviving according local recurrence (Group 0 – patients without local recurrence, group 1 – patients with local recurrence)

Слика 4 – Вкујно преживување на пациенти според појавата на локални рецидиви. (Група 0 – пациенти без локален рецидив, група 1 – пациенти со локален рецидив)

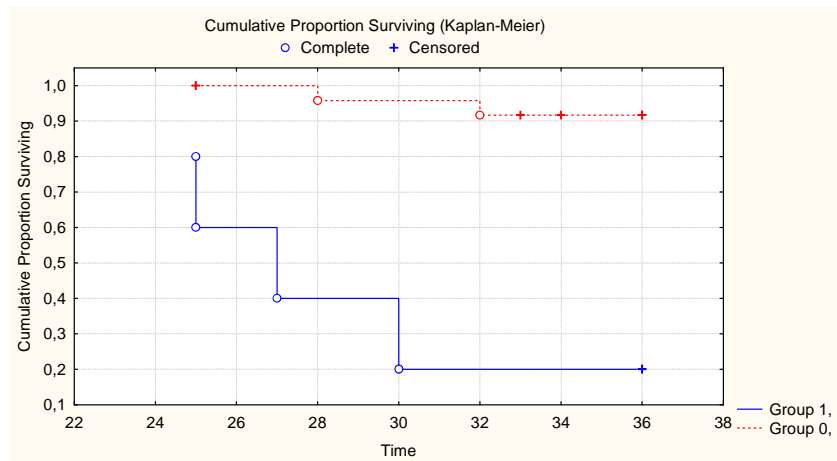


Figure 5 – Cumulative proportion surviving according to distant metastases. (Group 0 – patients without metastases, group 1 – patients with metastases)

Слика 5 – Вкујно преживување на пациентиите според појавата на оддалечени метастази. (Група 0 – без оддалечени метастази, група 1 – со оддалечени метастази)

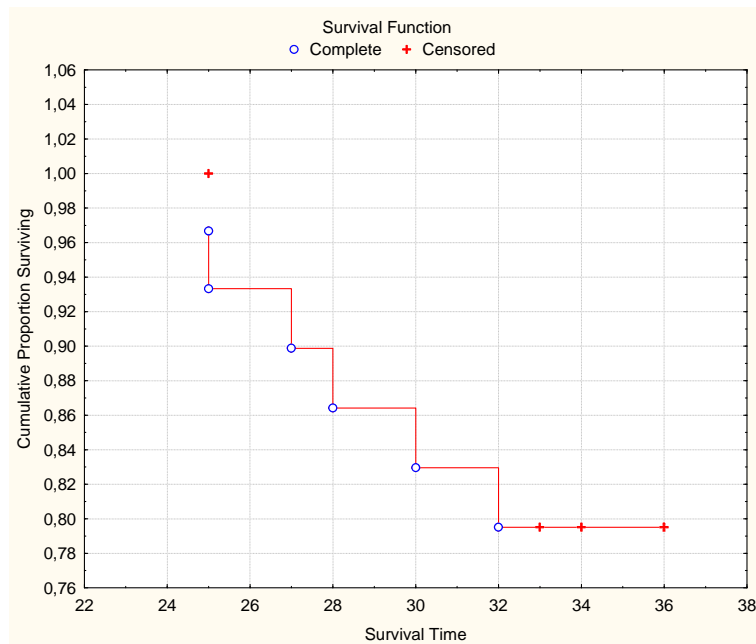


Figure 6 – Kaplan-Meier survival curve

Слика 6 – Kaplan-Meier-овата крива на преживување на пациентиите

Ten patients (10/27) with limb-preserving surgery (37.0%) had complications. In 3 patients (3/27) with limb-sparing (11%), complications or local recurrence led to secondary ablative surgery. All three patients (10%) with primary amputations were male. One of them had prolonged seroma and another one, due to local recurrence, was reamputated.

The three-year overall survival was 80% (Figure 6). In our study, 18 patients (18/30) are disease-free after 3 years (60%), with no significant statistical difference between good or bad responders (*Log-Rank test* = 1.87 *p* = 0.06).

Functional results (MSTS score) after rehabilitation showed approximately 65% function of the spared upper limbs and 76% function of the spared lower limbs (Table 2).

### Discussion

Amputations, once a dominant treatment for malignant bone tumours, are rarely and very selectively used now. Most patients with extremity-localized osteosarcoma are candidates for limb-sparing procedures because of effective chemotherapeutic agents and regimens, improved imaging modalities and advances in reconstructive surgery. Various options for skeletal reconstructions include modular endoprostheses, osteoarticular or bulk allografts, arthrodeses, expandable endoprostheses, rotationplasty and limb-lengthening techniques. Two primary goals must always be considered: survival rates should be no worse than those associated with amputation and the reconstructed limb must provide satisfactory function. [1, 7, 10, 11, 13]

However, surgical treatment associated with limb-sparing procedures is also associated with significant complications and requires extensive rehabilitation [7].

Before consideration of limb preservation, the patient needs to be appropriately staged and assessed through a multidisciplinary approach [9]. Some elements of the disease may warrant concern, including relative contraindications to such procedures [6]. During the past few decades neo-adjuvant chemotherapy has made dramatic advances in the treatment of nonmetastatic osteosarcoma of the extremities [1]. Multidrug neoadjuvant therapy, popularized for patients with osteosarcoma by Rosen in the late 1970s, is usually initiated as appropriate after pathohistological diagnosis and staging. Neoadjuvant chemotherapy dramatically improves long-term survival rates in patients with osteosarcoma sensitive to chemotherapy. [1, 3, 18, 22] Introducing the Scandinavian Sarcoma Group XIV chemotherapy protocol equalizes survival rates between "good" and "bad" responders. [1, 3, 21] Patients considered operable at diagnosis or following neo-adjuvant chemotherapy (9 weeks after beginning of the

neoadjuvant chemotherapy) must undergo "wide margins" resection of the osteosarcoma. Patients with a bad response received 3 more cycles of chemotherapy with a high dose of Ifosfamide (Ifosfamide 2000 mg/m<sup>2</sup> and × 5 days in the cycle). The main risk of limb-salvage procedures is that complications may sometimes cause a delay in the chemotherapy regimen. If the basic principles of limb-sparing surgery and "tumour sterility and radicality" are not to be achieved, amputation is a better choice than limb preservation at any cost [18].

The three-year overall survival (OS), disease-free survival (DFS) and functional results (MSTS score) of the patients in our study are comparable to the results published in the literature [1, 7, 12, 13, 17]. There was no significant difference in 3-year overall survival between the groups of "bad" and "good" responders to chemotherapy ( $p = 0.06$ ). A comparison of results of patients with limb-sparing and amputations in our study with the results of patients with surgery at our Clinic in the period prior to 2000 comes out in favour of the group treated with neo-adjuvant chemotherapy.

### *Conclusion*

The application of neo-adjuvant chemotherapy followed by limb-salvage surgery calls for responsible, trained and highly engaged medical staff. Introducing a high dose of Ifosfamide for "bad responders" to preoperative chemotherapy improves the results and overall survival of the patients. If treatment and management principles of high-grade osteosarcoma are followed, limb-sparing with 60–70% survival rates and improved functional results could be achieved. Our preliminary results are promising and encouraging.

### *Acknowledgment*

Special thanks to Mrs. Maria Tanevska-Pulios for English language editing of the paper.

### REFERENCES

1. Bacci G., Picci P., Ferrari S., Ruggieri P., Casadei R., Tienghi A., Brach del Prever A., Gherlinzoni F., Mercuri M., Monty C. (1993): Primary Chemotherapy and Delayed Surgery for Non-metastatic Osteosarcoma of the Extremities. *Cancer*; Vol. 72, No. 11: 3227–3238.
2. Bonardelli S., Nodari., Maffei R., Ippolito V., Saccalani M., Lussardi L., Guilini M.S. (2000): Limb Salvage in Lower-Extremity Sarcomas and Technical Details about Vascular Reconstruction, *J Orthop Sci*; 5: 555–560.

3. Bruland OS., Phil A. (1999): On the current management of osteosarcoma. A critical evaluation and a proposal for modified treatment surgery. *Eur. J. Cancer*; 33: 1725–1731.
4. Campanacci M. (1999): Errori nella diagnosi e terapia dei tumori muscolo-scheletrici: cio' che non si deve fare, *Chir. Organi Mov*; LXXXIV, 1–17.
5. Chao E.Y.S., Frassica F. J., Sim F. (1998): Biology, Biomaterials and Mechanics of Prosthetic Implants, In: Surgery for Bone and Soft-Tissue Tumours, M.A. Simon, D. Springfield, Lippincott-Raven Publ., Philadelphia, 34: 453–465.
6. Choong PFM., O'Conor MI., Sim FH. (1996): Surgical management of malignant pelvic tumours: The 1990s, *J Orthop Sci*; 1: 64–69.
7. Di Caprio MR., Friedlander GE. (2003): Malignant Bone Tumours: Limb Sparing Versus Amputation, *Jour Amer Acad Ort Surg*; Vol. 11, No 1.
8. Donati D., Capanna R., Casadei R., Ercolani C., Aluigi P., Masetti C., Mercuri M. (1995): L'artrodesi di ginocchio dopo resezione per tumore: innesti autoplastici ed omoplastici a confronto, *Chir. Org. Mov*; LXXX, 29–37.
9. Enneking WF., Spanier SS., Goodman MA. (1980): A surgical staging of musculoskeletal sarcomas, *J Bone Joint Surg Am*; 62: 1027–30.
10. Enneking WF., Dunham W., Gephardt MC., Malabar M., Prichard DJ. (1993): A system for functional evaluation of reconstructive procedures after surgical treatment of tumours of the musculoskeletal system, *Clin. Orthop*; 286: 241–246.
11. Gerrard CH., Currie D., Grigoris P., Reid R., Hambien DL. (1999): Prosthetic reconstruction of the femur for primary bone sarcoma, *International Orthopedics*; (SICOT), 23: 286–290.
12. Getty P., Peabody TD. (1999): Complications and Functional Outcomes of Resection with an Osteoarticular Allograft after Intra-Articular Resection of the Proximal Aspect of the Humerus. *J. Bone Joint Surg*; 81: 1138–46.
13. Gushier G., Gebert C., Ahrens H., Streitbuerger A., Winkelmann W., Haddes J. (2006): Endoprosthetic Reconstruction in 250 Patients with Sarcoma. *Clin. Orthop and Rel. Reser*; No. 450: 164–171.
14. Ghert M., Colterjohn N., Manfrini M. (2007): The Use of Free Vascularised Grafts in Skeletal Reconstruction for Bone Tumours in Children. *J. A. A. Orthop. Surg*; Vol. 15. No. 10: 577–587.
15. Kaplan EL., Meier P. (1958): Nonparametric estimation for incomplete observation. *J Am Stat Assoc*; 53: 457–481.
16. Kivioja A. (2004): Limb Salvage Tehniques, ([http://www.findarticles.com/p/articles\\_mi\\_qa376/is\\_200401/ai\\_n9372737](http://www.findarticles.com/p/articles_mi_qa376/is_200401/ai_n9372737)), Journal of Bone and Joint Surgery on line.
17. Kotz R., Dominkus M., Zettl T., Ritschl P., Windhager R., Gadner H., Zielinski C., Salcer-Kuntschik M. (2002): Advances in bone tumour treatment in 30 years with respect to survival and limb salvage. A single institution experience, *Inter. Orthoped.* 26, N. 4: 197–206.
18. Nagarajan R., Neglia PJ., Clohisy DR., Robinson LL. (2002): Limb Salvage and Amputation in Survivors of Pediatric Lower-Extremity Bone Tumours: What

are Long Term Implications?, *Jour Clin Oncology*; Vol.22, Issue 22 (November), 4493–4501.

19. Rozen G., Murphy M.L., Huvos A. G., Guterez M., Marcove R. C., (1975): Chemotherapy, En Block Resection and Prosthetic Bone Replacement in the Treatment of Osteogenic Sarcoma, 28<sup>th</sup> Annual Meeting of the James Ewing Society, New Orleans, March 25–29, No. 1: 1–11.

20. Samek V., Kotrz R., Engel A., Petsching Szendrői M. (2002): Advances in Orthopaedic Oncology, *International Orthopedics* 26: 195–196.

21. Simon M. A. (1988): Current Concepts Review Limb Salvage for Osteosarcoma, *Journal for Bone and Joint Surgery*; Vol. 70–A No. 2: 307–310.

22. Sutov W.W., Sullivan M.P., Fernbach D. J., Cngir A., George S.L. (1975): Adjuvant Chemotherapy in Primary Treatment of Osteogenic Sarcoma, A Southwest Oncology Group Study, *Cancer*, Vol. 36: 1598–1602.

23. Зафировски Ѓ. (1986): Малигни коскени тумори, МИО „Сџудениски збор“ – Скопје, (1): 9–32.

#### Резиме

### ТРЕТМАН НА ОСТЕОСАРКОМ СО ВИСОК СТЕПЕН НА МАЛИГНИТЕТ

(СТУДИЈА НА 30 СЛУЧАИ ТРЕТИРАНИ СО СКАНДИНАВСКАТА САРКОМА  
ПРОТОКОЛ БРОЈ XIV И ОПЕРАТИВНА ИНТЕРВЕНЦИЈА)

Самарциски М.,<sup>1</sup> Зафировски Ѓ.,<sup>1</sup> Толевска Ц.,<sup>2</sup>  
Зафирова-Ивановска Б.,<sup>3</sup> Костадинова-Куновска С.,<sup>4</sup>  
Каличанин-Марковска М.<sup>1</sup>

<sup>1</sup>Оддел за мускулоскелетни тумори, Универзитетска клиника  
за ортопедски болести, Скопје, Р. Македонија

<sup>2</sup>Институт за радиотерапија и онкологија, Скопје, Р. Македонија

<sup>3</sup>Институт за епидемиологија и статистика, Скопје, Р. Македонија

<sup>4</sup>Институт за патиологија, Скопје, Р. Македонија

**Апстракт:** Целта на овој труд е зголемување на тригодишното време на преживување и подобрување на функционалните резултати, кај пациентите со остеосарком со висок степен на малигнитет на екстремитетите, третирани со хемотерапискиот протокол на скандинавската саркома група број XIV и оперативна интервенција.

**Пациенти и методи:** Во овој труд беа анализирани 37 пациенти со остеосарком на екстремитетите, со висок степен на малигнитет, третирани во периодот од 2000 до 2005 година на Клиниката за ортопедски болести во Скопје. Од нив 21 (57%) беа мажи и 16 (43%) беа жени. Возраста се дви-

жеше од 8 до 63 години (средно  $18,3 \pm 13,4$ ). Седум пациенти (7/37) беа исклучени од анализата, бидејќи не ги исполнуваа потребните критериуми. Останатите 30 пациенти примија два циклуси на предоперативна хемотерапија (високи дози на Methotrexat, Cisplatin, Adriamycin). Хируршкото лекување се извршуваше во деветтата недела од протоколот. Кај 27 (90%) пациенти се извршија операции за спасување на екстремитетите, а кај 3 (10%) ампутации. Патохистолошката анализа на извадениот тумор ги подели пациентите во 2 групи: пациенти со добар одговор на хемотерапијата и пациенти со лош одговор. Сите пациенти имаа уште 3 циклуси на постоперативна хемотерапија (иста како и предоперативната). Пациентите со лош одговор на хемотерапијата добија уште 3 циклуси од по 5 дена со висока доза Ifosfamide. Следењето на пациентите беше од 2 до 8 години или средно 51 месец.

*Резултати:* Патохистолошката анализа откри лош одговор на неoadjuvantната хемотерапија кај 57% од пациентите, но немаше статистички значителна разлика во преживувањето на групите ( $p = 0,06$ ). Тригодишното преживување на пациентите со локален рецидив беше 40% во споредба со 88% на тие без рецидив. Тригодишното преживување на пациентите со оддалечени метастази беше 20% во споредба со 92% на тие без метастази. Вкупното тригодишно преживување (OS) беше 80%. По три години од лекувањето (DFS), 60% од пациентите беа без метастази и локални рецидиви.

*Заклучок:* Модерната хемотерапија кај пациентите со остеосарком со висок степен на малигнитет, локализиран на екстремитетите, дава можност за зачувување на екстремитетот и истовремено го продолжува времето на преживување. Вклучувањето на високи дози на Ifosfamide кај пациентите со лош одговор на предоперативната хемотерапија, ги подобрува резултатите и го продолжува времето на преживување. Нашите почетни резултати се охрабрувачки.

**Клучни зборови:** остеосарком, неoadjuvantна хемотерапија, спасување на екстремитети.

**Corresponding Author:**

**Milan Samardziski MD, MSc,**  
**Chief of Musculoskeletal Tumours Department,**  
**University Orthopaedic Surgery Clinic,**  
**Ss. Cyril and Methodius University,**  
**Vodnjanska 17,**  
**1000 Skopje, R. Macedonia,**  
**Tel. /fax: ++ 389 2 3147 626**

**E-mail: milan\_samardziski @ yahoo.com**