


Provided for non-commercial research and education use.
Not for reproduction, distribution or commercial use.



This article appeared in a journal published by Elsevier. The attached copy is furnished to the author for internal non-commercial research and education use, including for instruction at the authors institution and sharing with colleagues.

Other uses, including reproduction and distribution, or selling or licensing copies, or posting to personal, institutional or third party websites are prohibited.

In most cases authors are permitted to post their version of the article (e.g. in Word or Tex form) to their personal website or institutional repository. Authors requiring further information regarding Elsevier's archiving and manuscript policies are encouraged to visit:

<http://www.elsevier.com/copyright>



Images in cardio-thoracic surgery

**Cardiac silhouette following a mitral valve replacement,
tricuspid annuloplasty and atrioplasty of both atria**

Zan Mitrev, Nikola Hristov *

Special Hospital for Cardiac Surgery, PZU "Filip Vtori", Skopje, Macedonia

Received 26 March 2008; received in revised form 13 June 2008; accepted 19 June 2008; Available online 3 August 2008

Keywords: Cardiac silhouette; Neglected mitral stenosis

Preoperative X-ray (Fig. 1) of 37-year-old woman with neglected mitral stenosis, severe pulmonary hypertension, tricuspid regurgitation and dilatation of both atria. Her mitral valve was replaced with mechanical prosthesis,

tricuspid suture annuloplasty and reduction atrioplasty was performed. Her first postoperative X-ray (Fig. 2) showed normal cardiac silhouette.

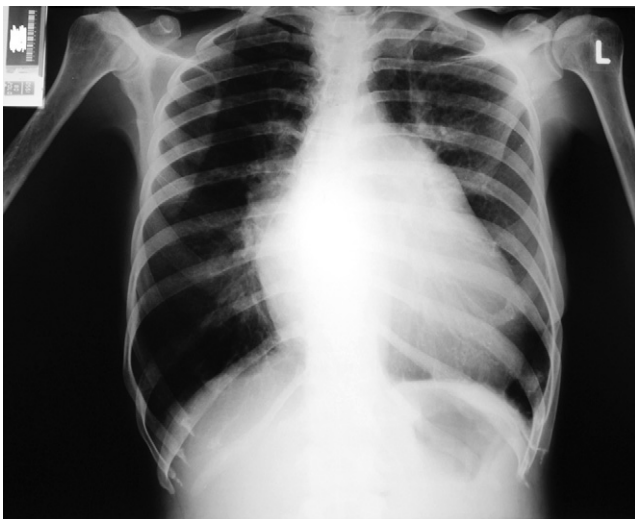

Fig. 1. Preoperative postero-anterior projection X-ray.

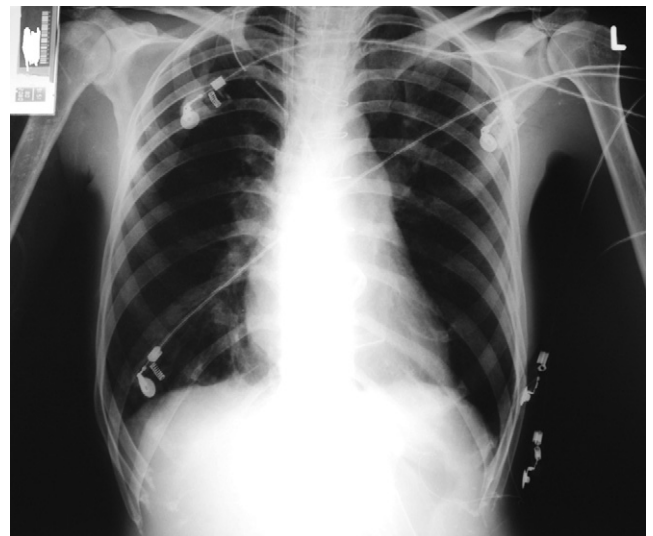

Fig. 2. Postoperative antero-posterior projection X-ray.

* Corresponding author. Tel.: +389 2 3091500; fax: +389 2 3091499.
E-mail address: hristov@cardiosurgery.com.mk (N. Hristov).