

64 MSCT ANGIOGRAPHY & 64 Cardiac MSCT

Lidija Veljanovska, MD

Special hospital for surgery diseases

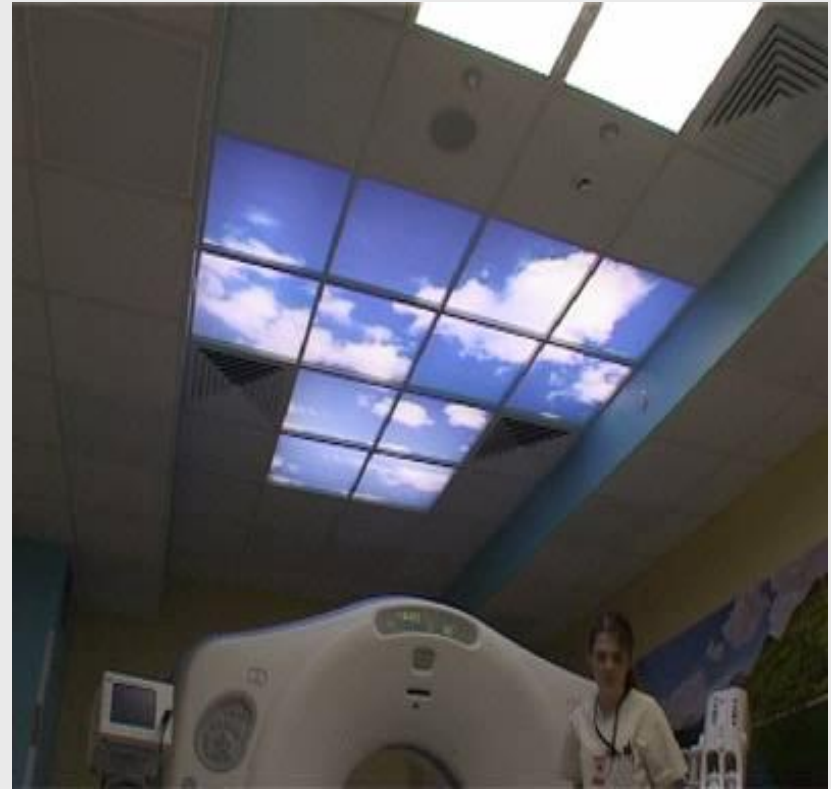“Filip II”

May, 2009



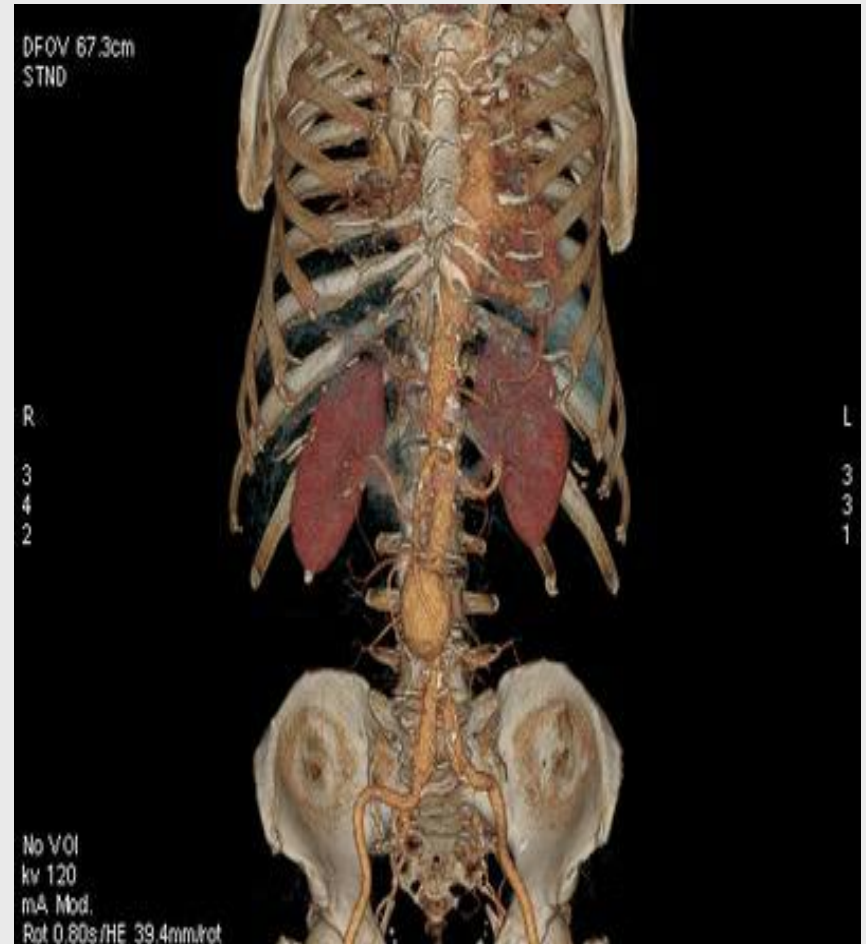
64 MSCT ANGIOGRAPHY

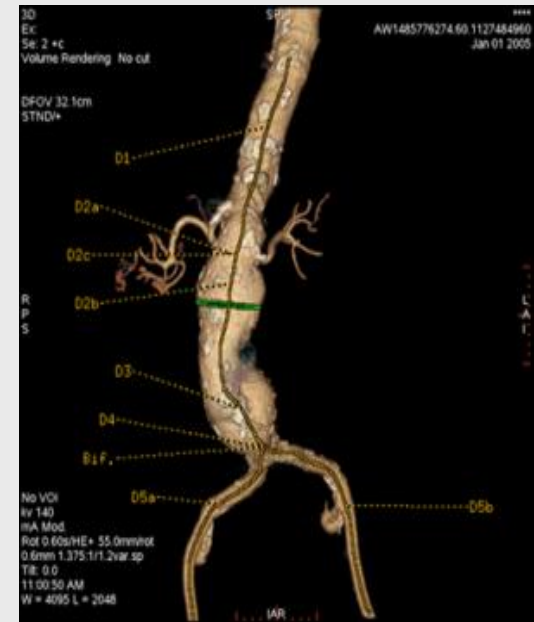
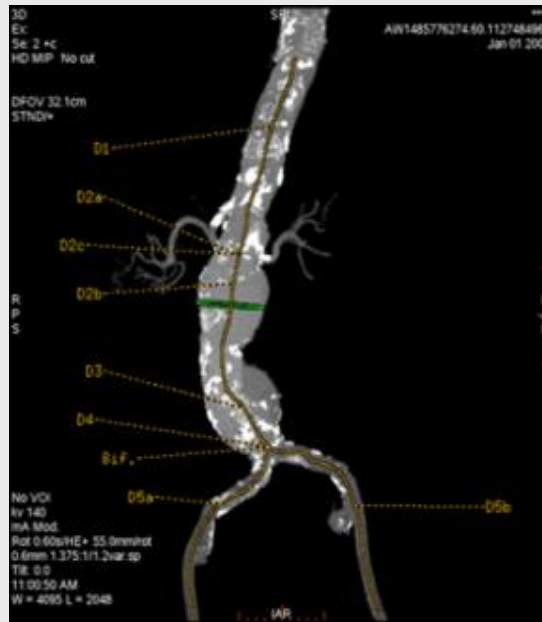
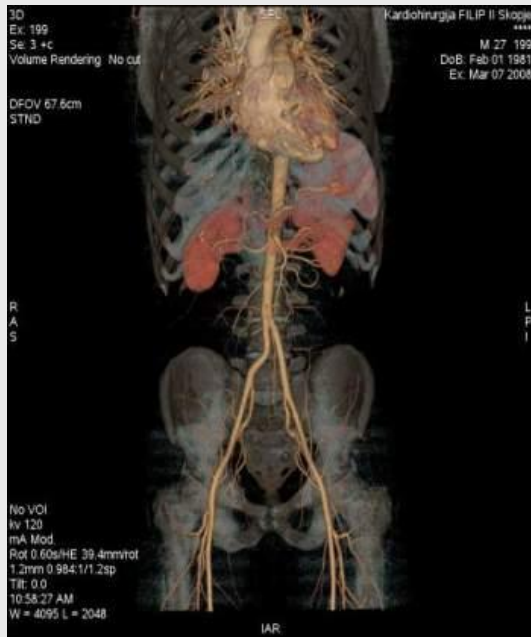
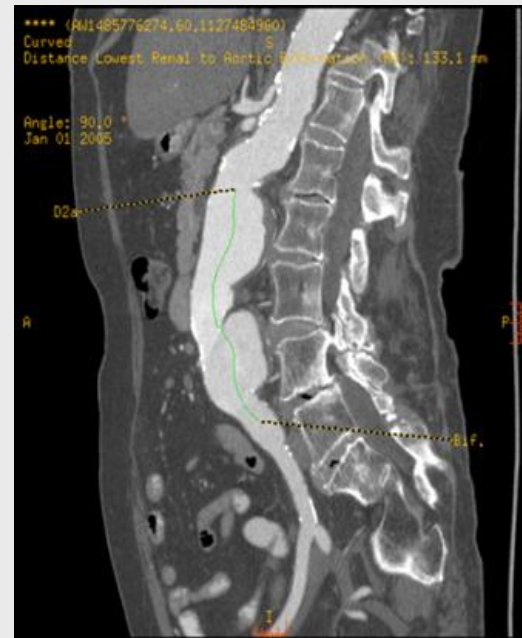
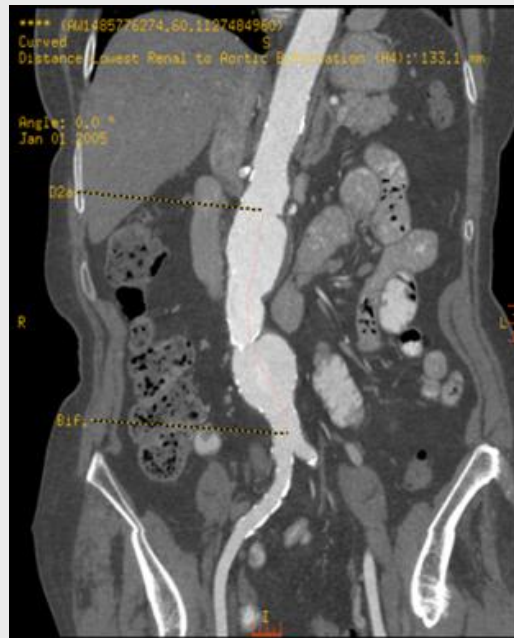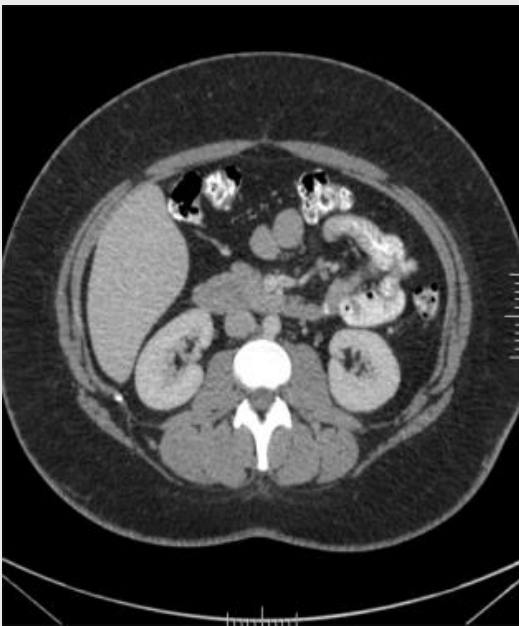
- Non invasive procedure, comfortable for the patient
- Great spatial and temporal resolution, slice thickness - 0,625 mm (provide excellent details that allow identification of vascular anomalies and different pathological entities)
- 3D post-processing
- Method of choice for emergency cases (dissection, trauma)



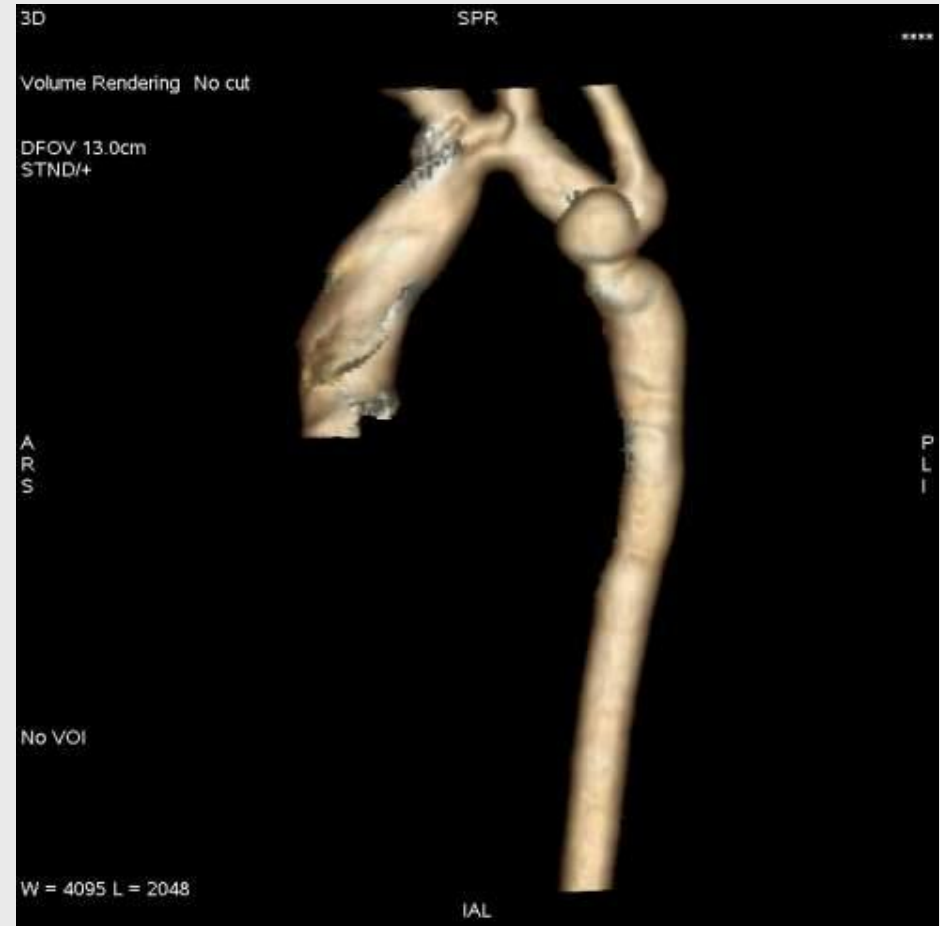
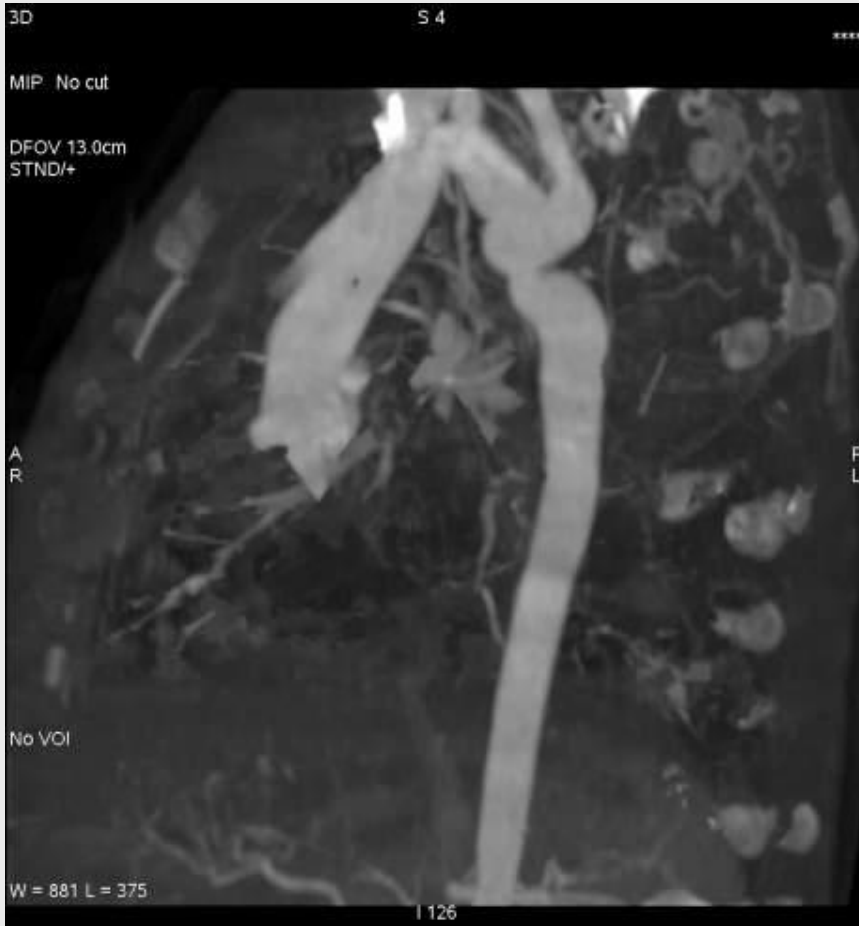64 MSCT ANGIOGRAPHY - INDICATIONS

- Vascular anomalies
- Trauma-rupture, stenosis, occlusion
- Pathological vascularisation of the tumors
- Aneurysmatal disease and dissection of the aorta
- Aneurysmatal disease of intracranial vessels
- Planing - interventions, stenting or vascular surgery
- Postinterventional follow up (grafts, stents)

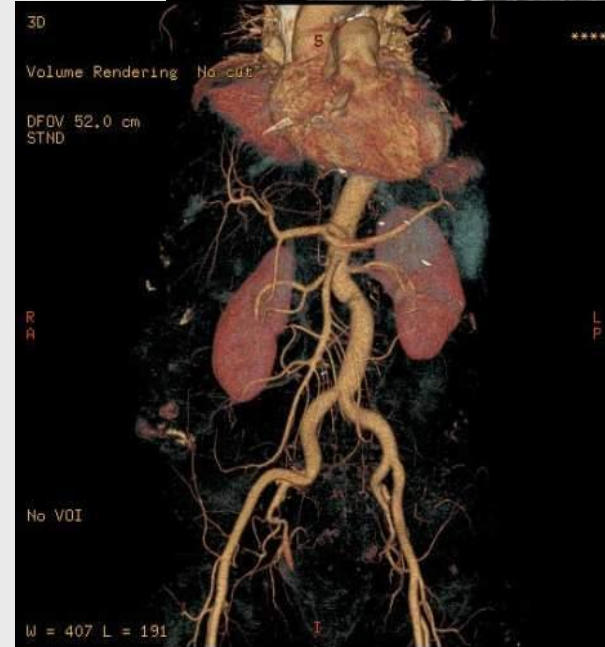
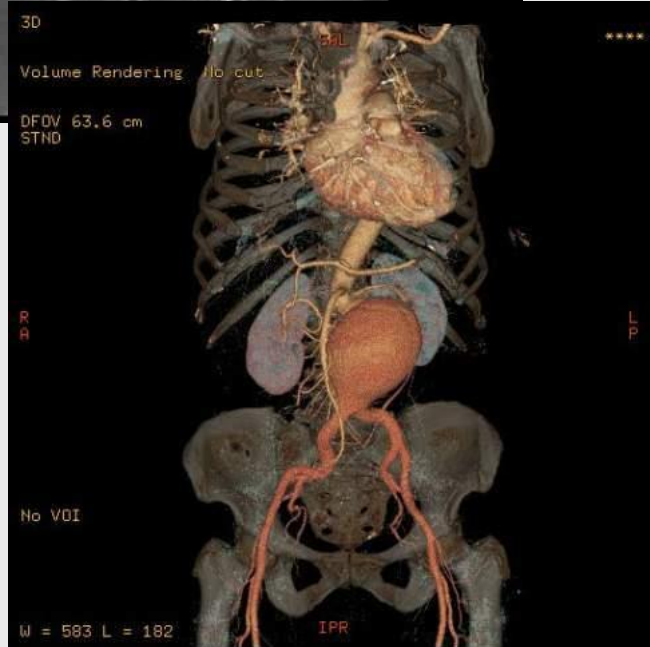
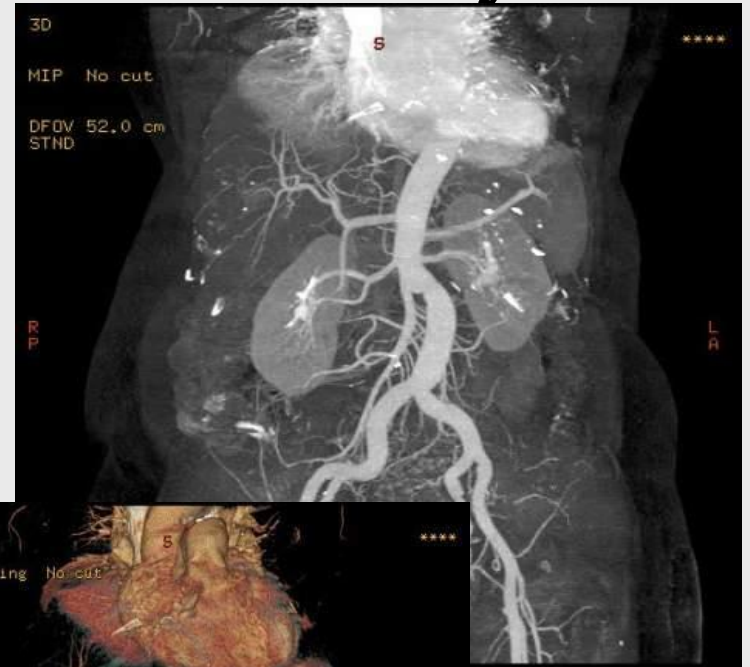
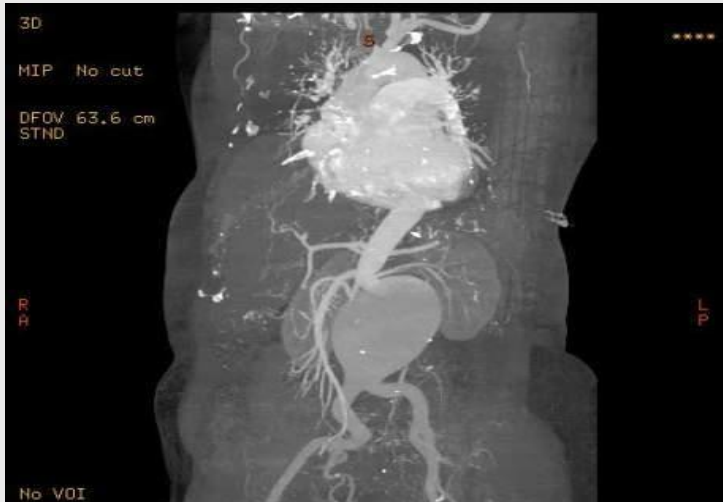


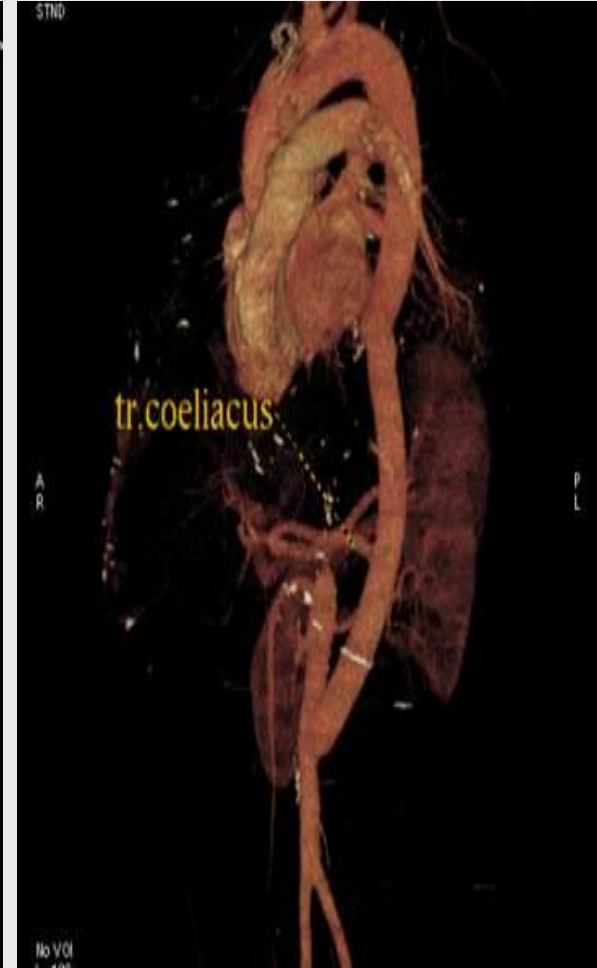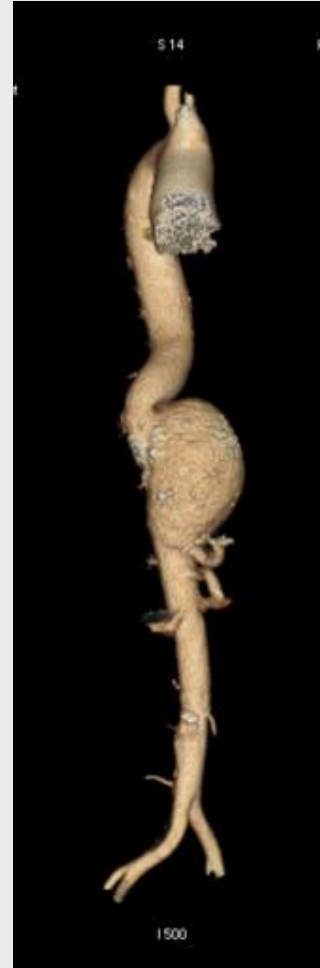
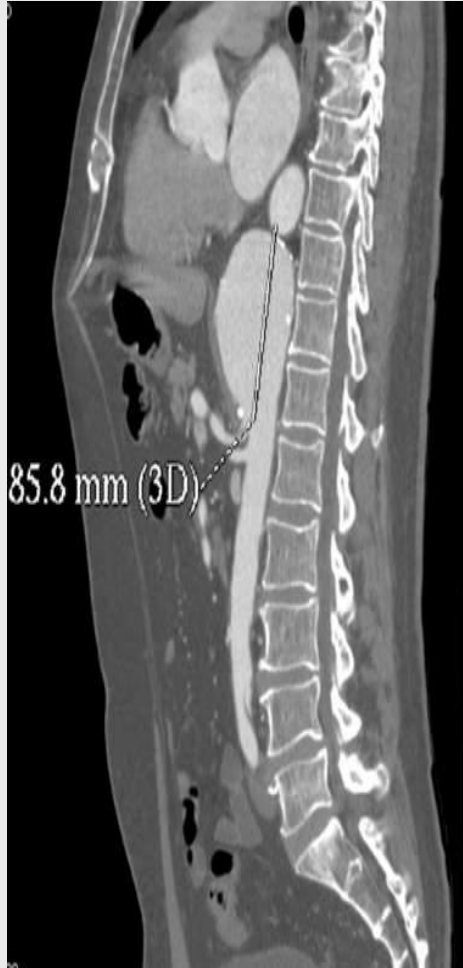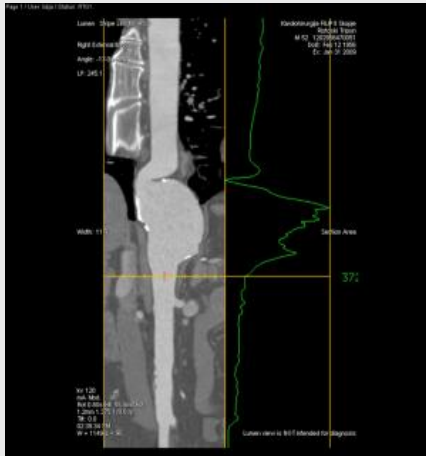
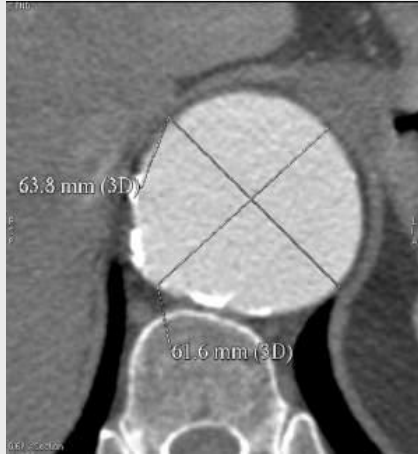Congenital anomalies, coarctation

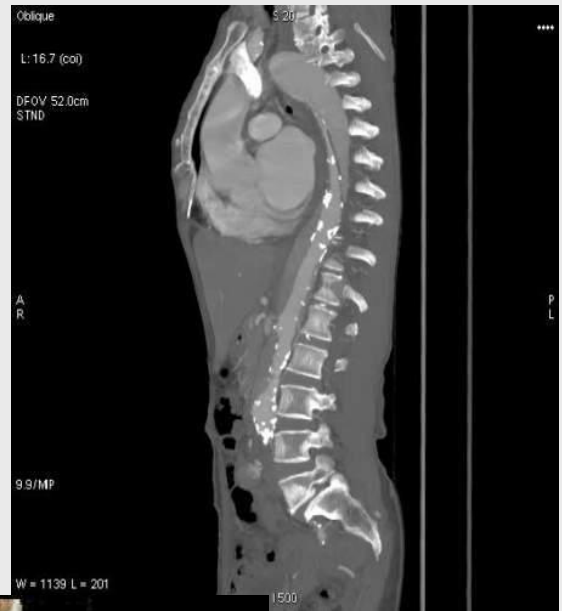
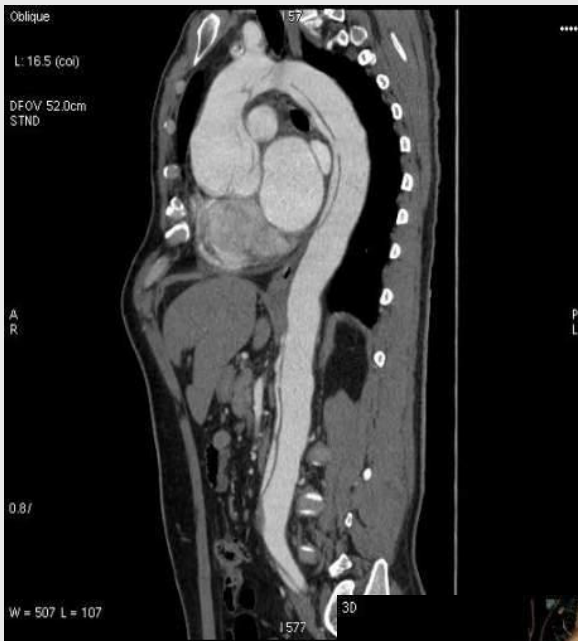


Abdominal Aorta – Infrarenal Aneurysm

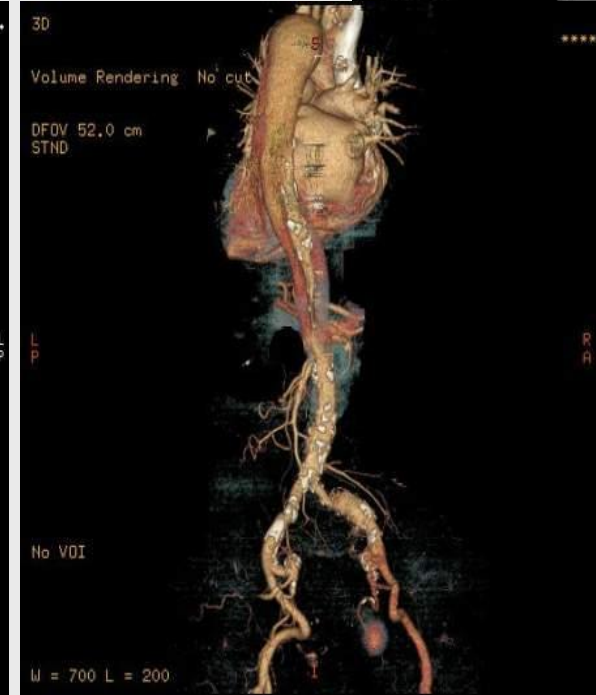
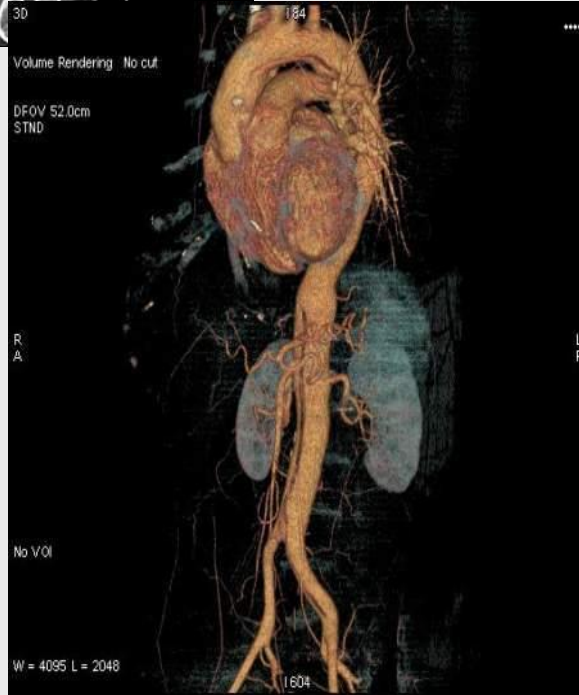


Thoracoabdominal aneurysm



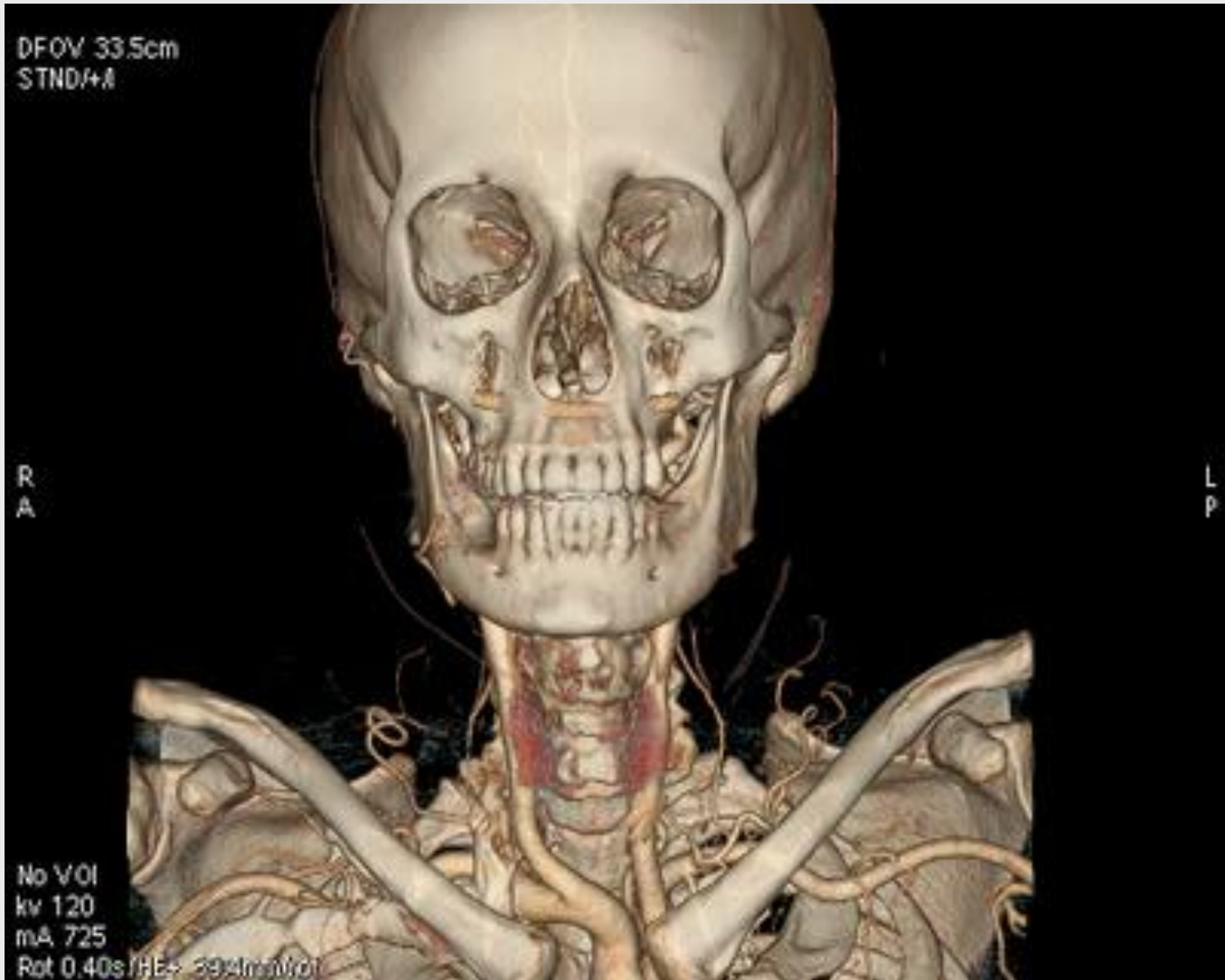


**Dissection
Stanford A**

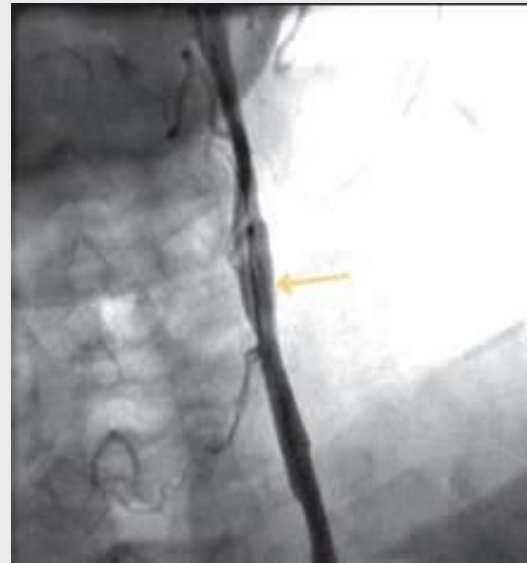
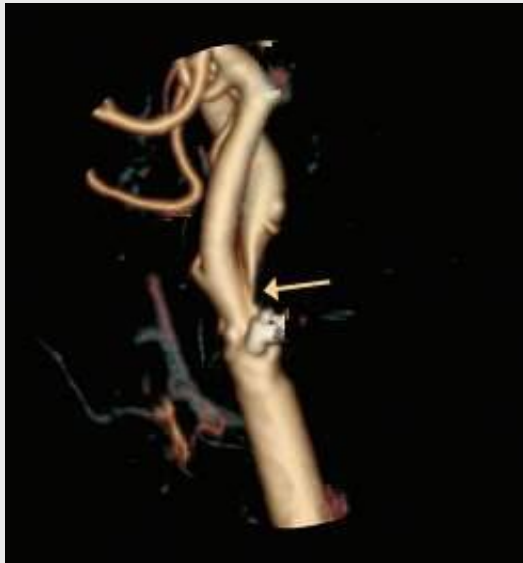
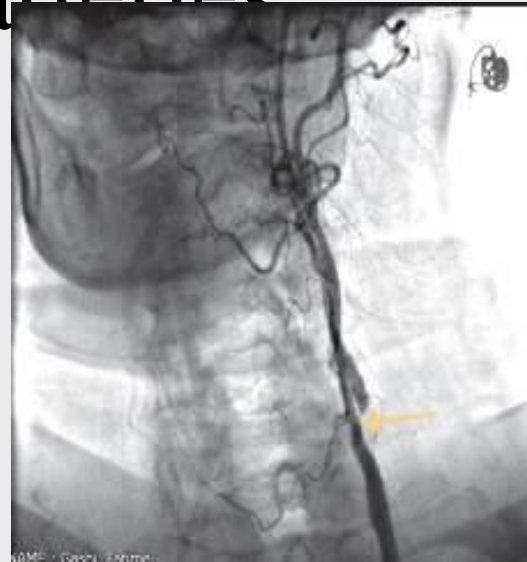
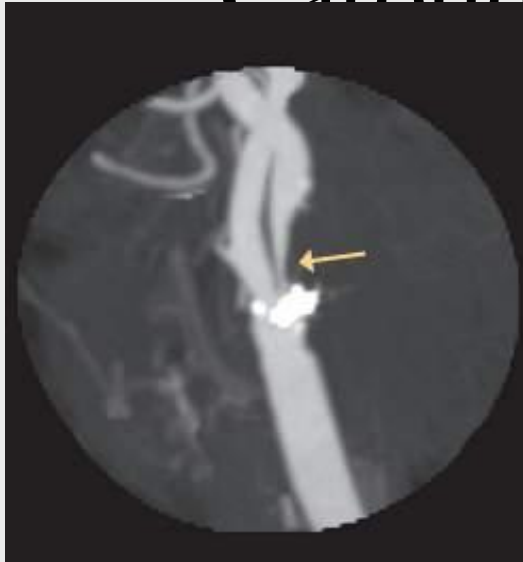**Dissection
Stanford B**

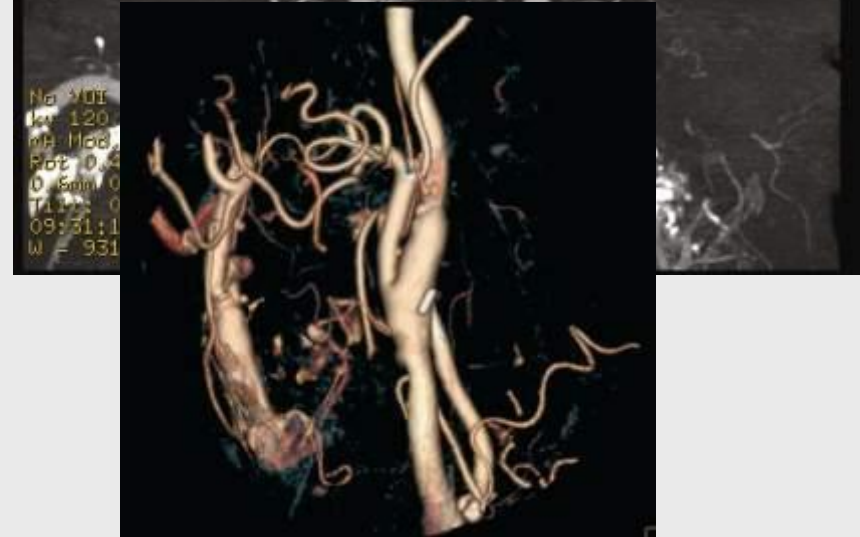
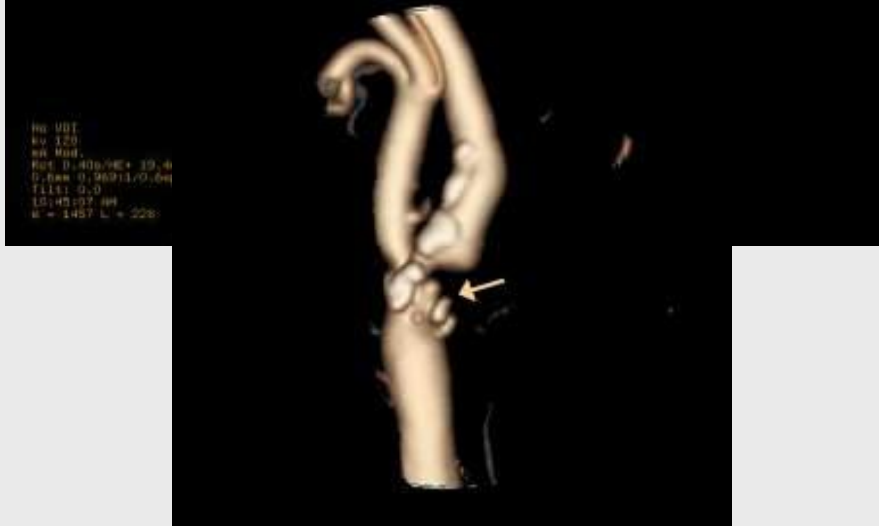
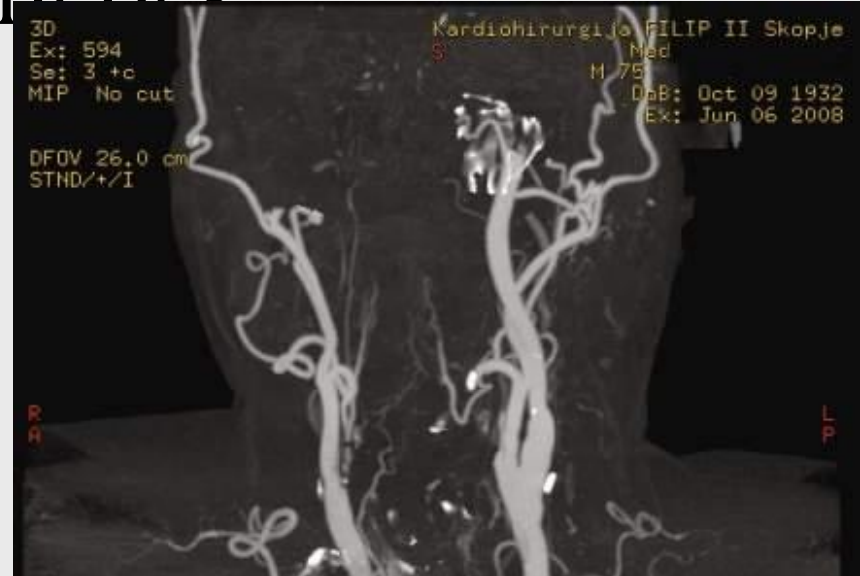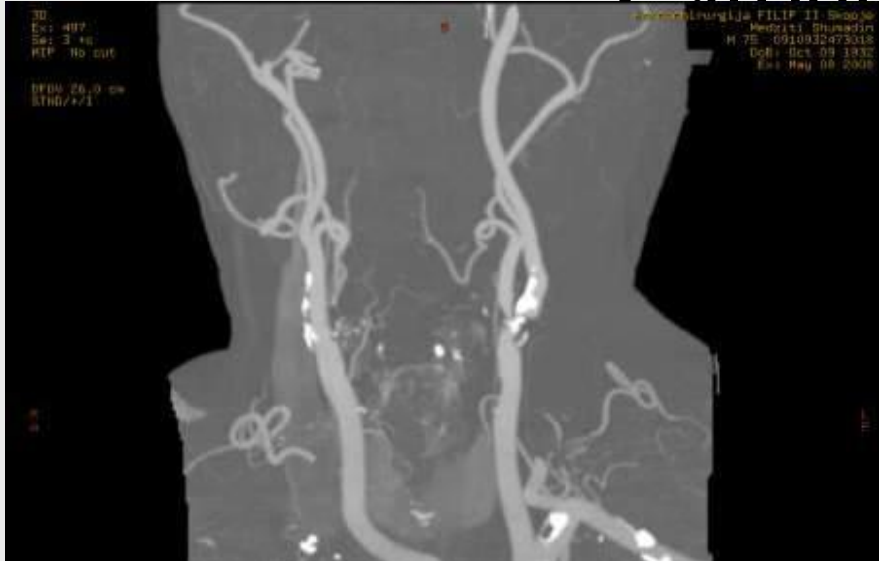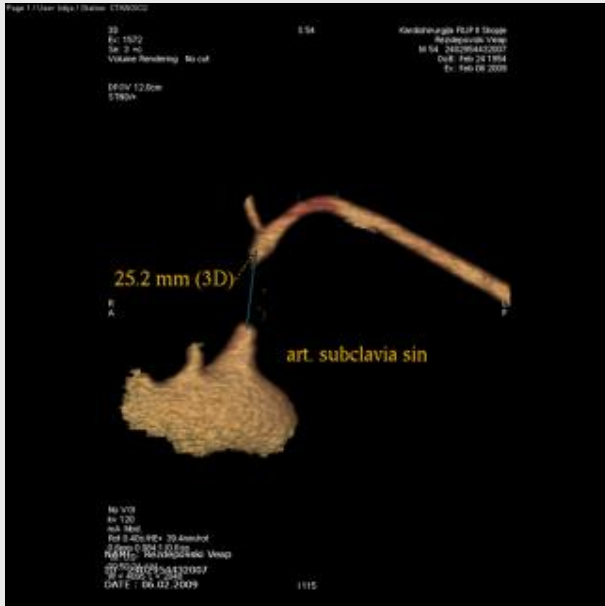


Carotid arteries

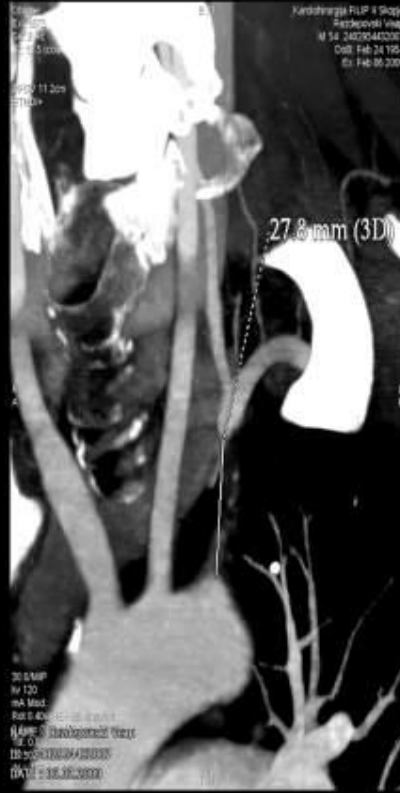

Carotid arteries

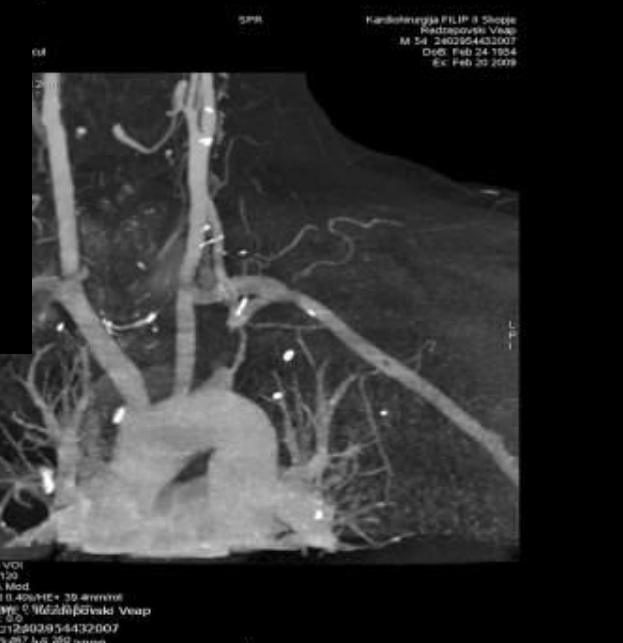
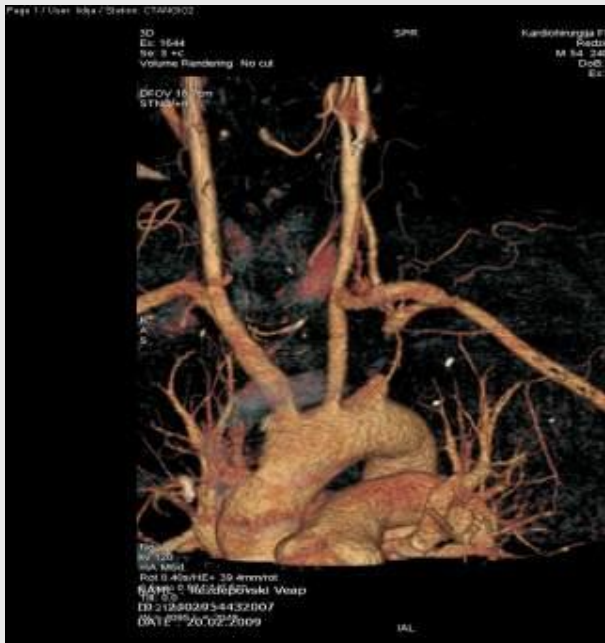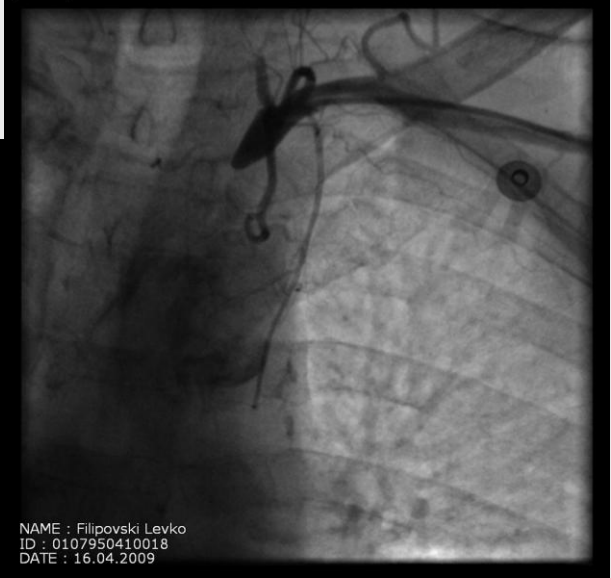




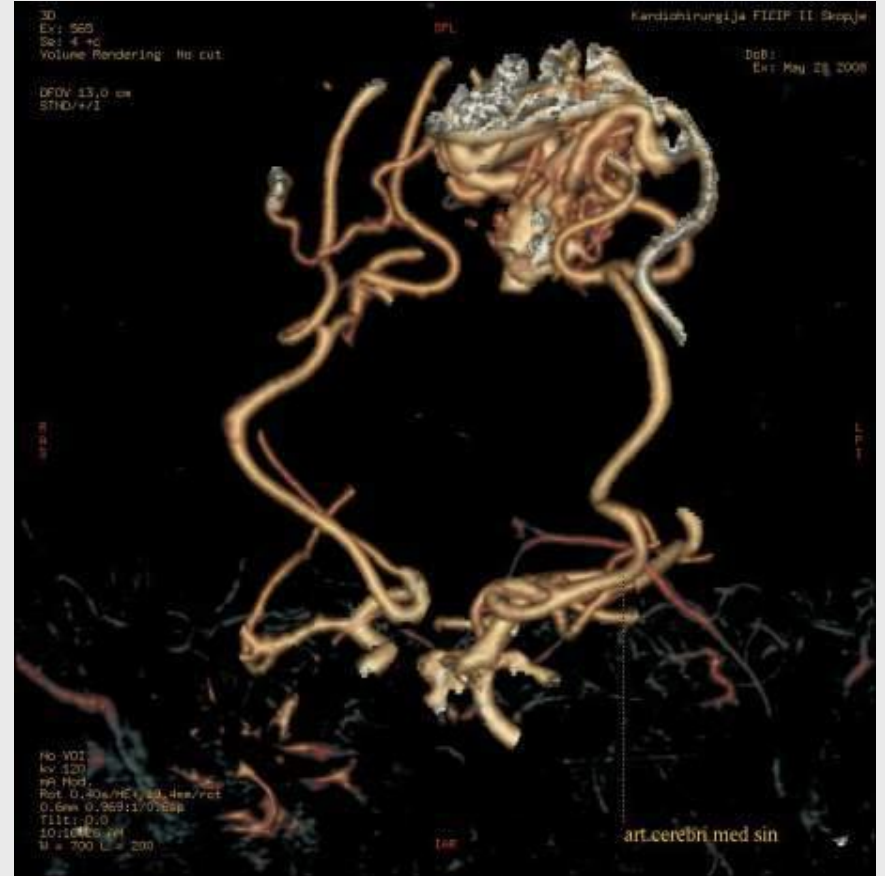
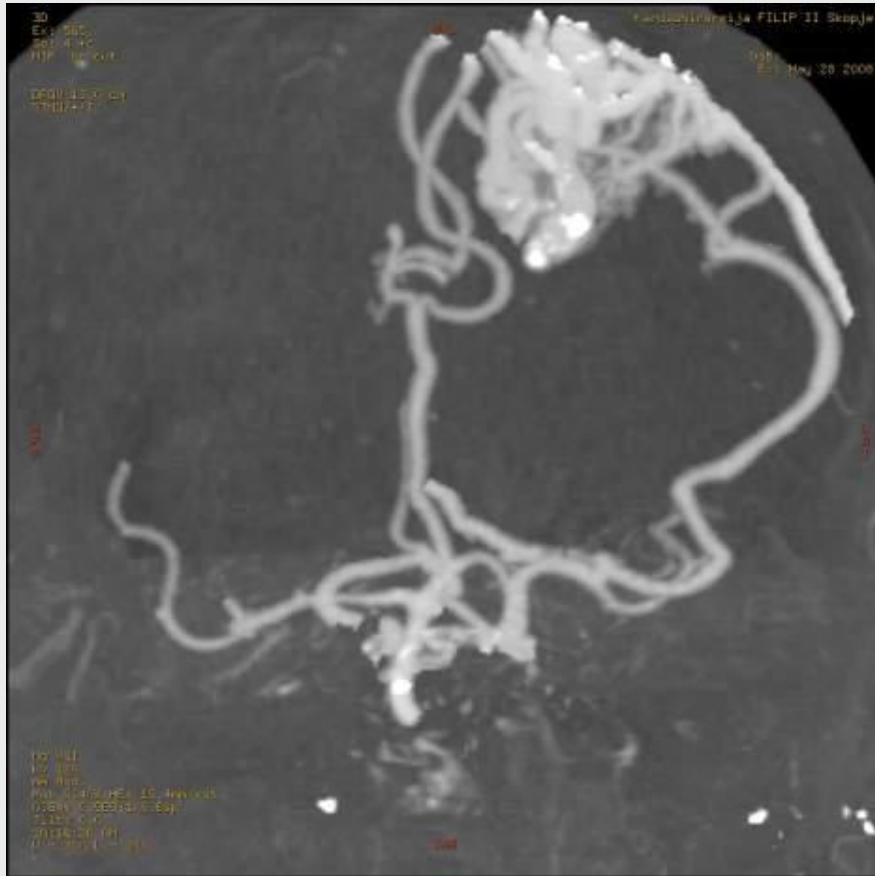
Page 1 / User: idja / Station: CT100002



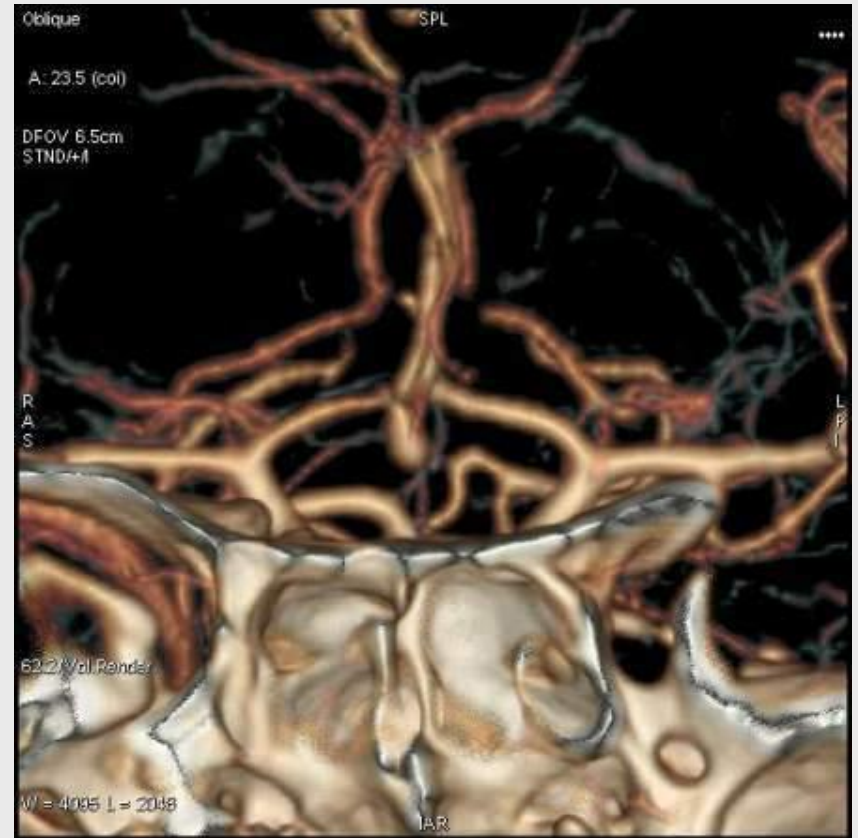
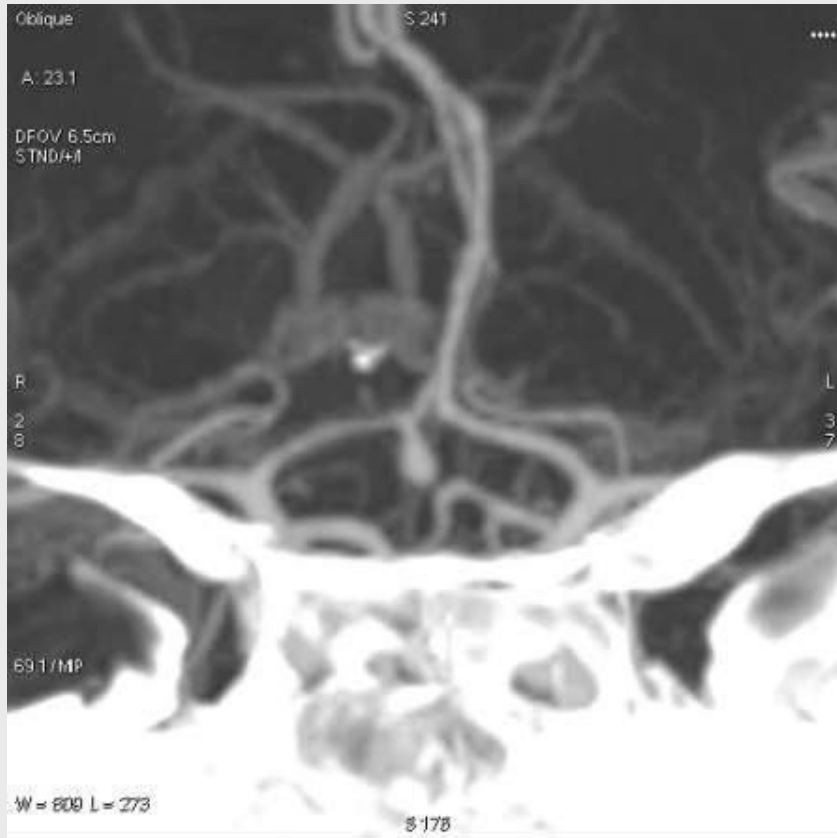
Page 1 / User: idja / Station: RT01



Intracranial vessels

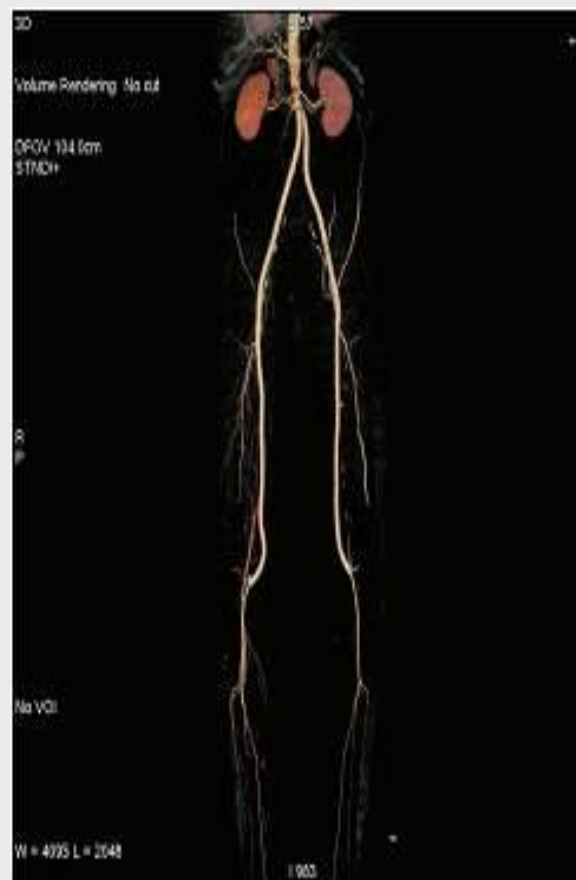
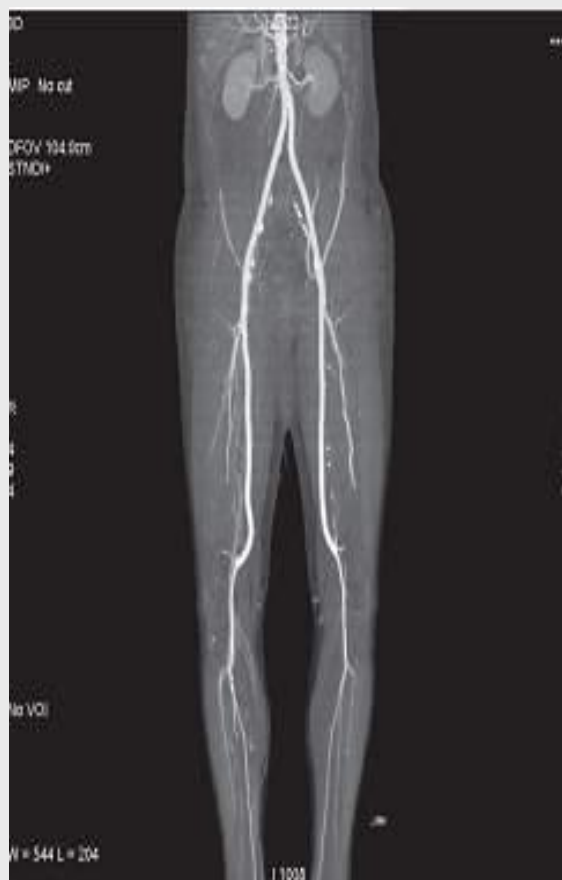
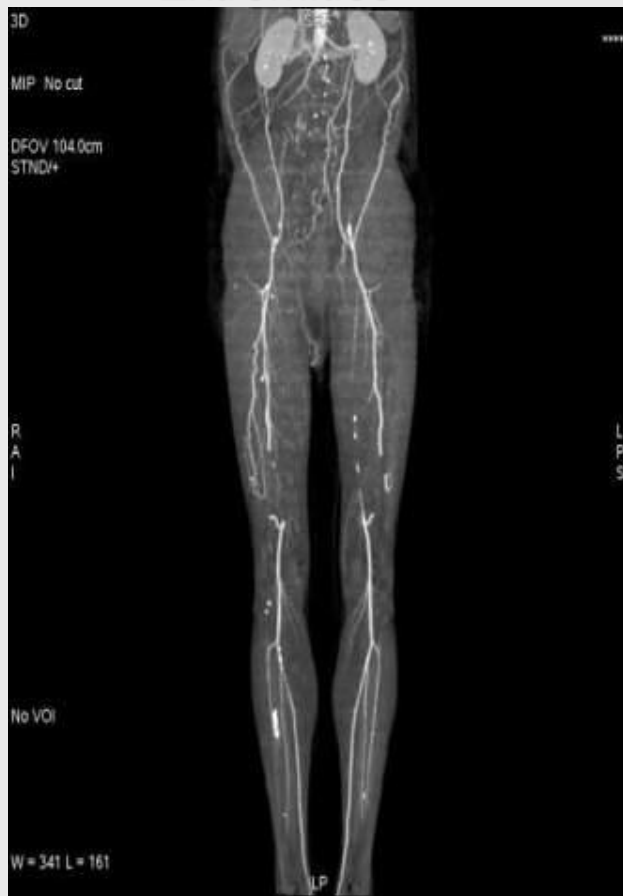Intracranial vessels



CT Angiography of the Lower Extremities

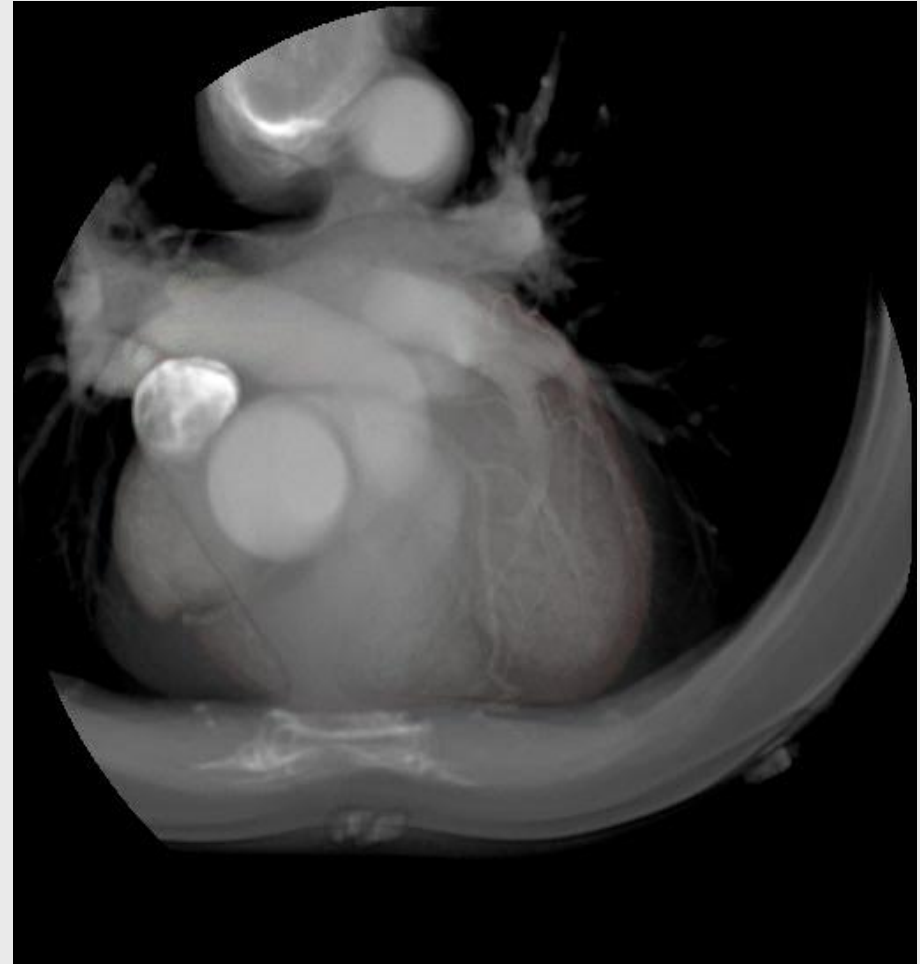
Syndrome Leriche



64 Cardiac MSCT

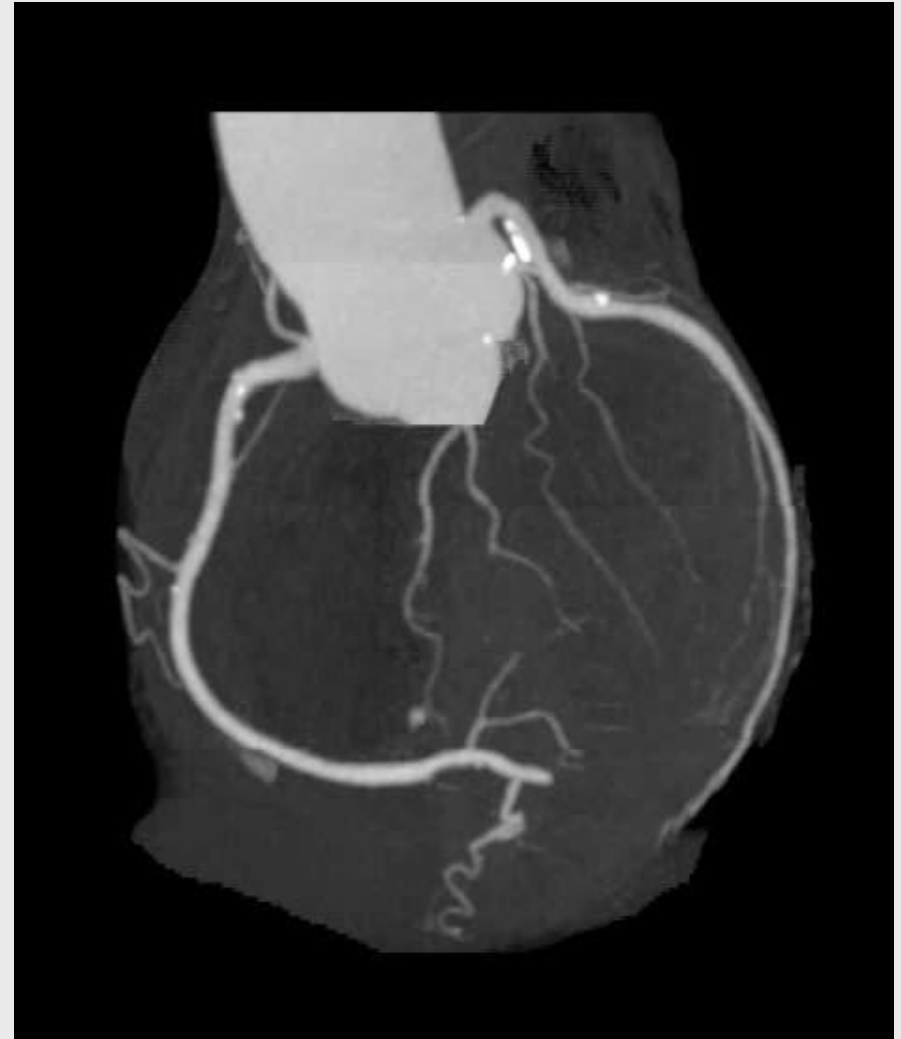Clinical impact & indication

- Cardiac CT has a role in the management of patients especially with atypical angina
- To provide an accurate diagnosis we need:
- High image quality
- Efficient post processing
- Clinical expertise

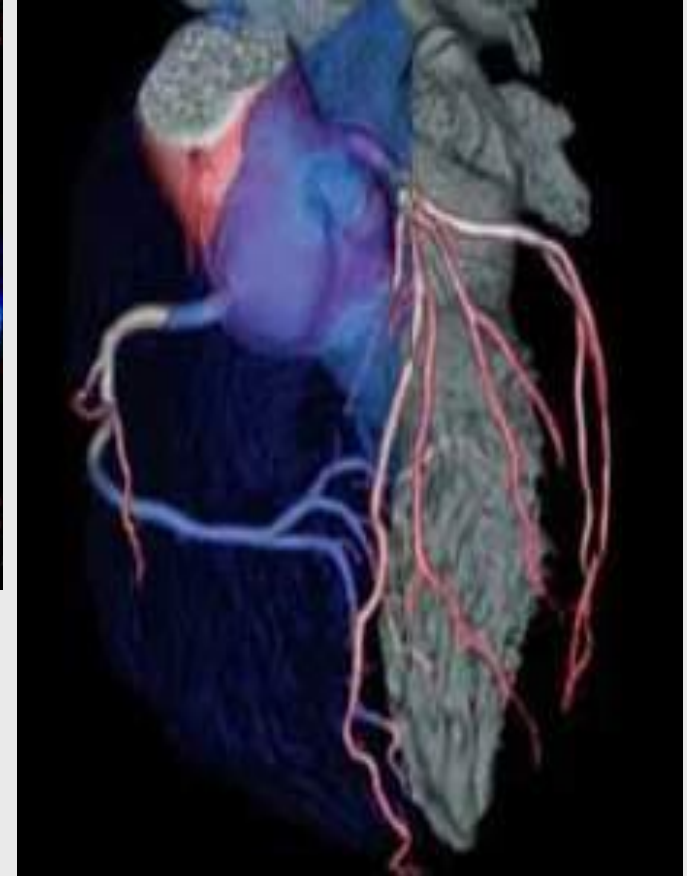
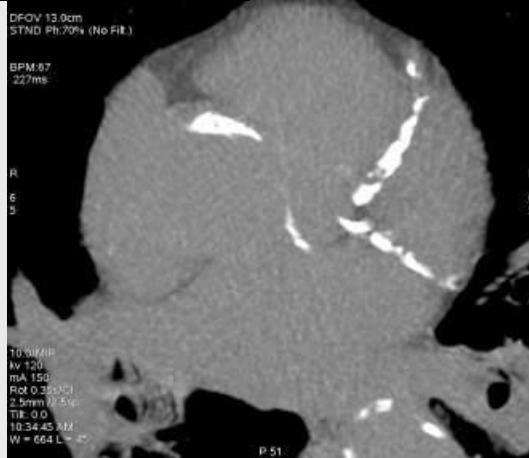
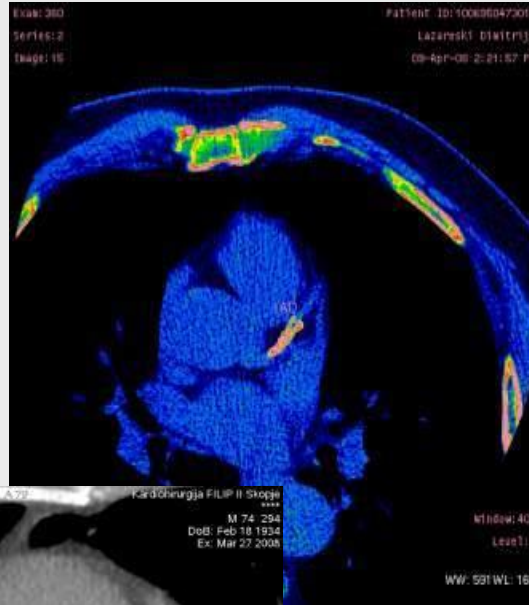
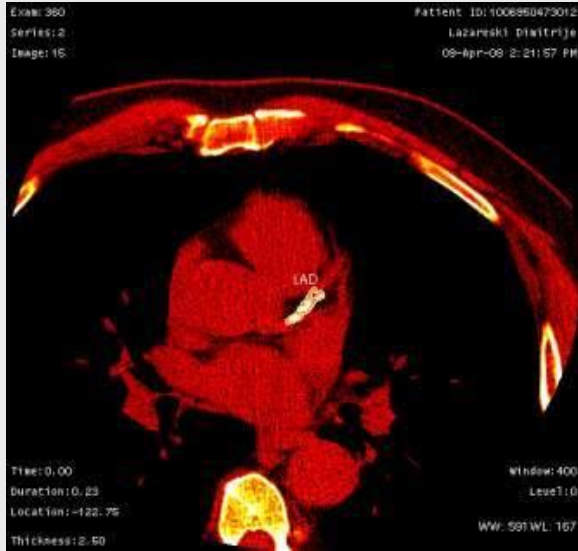

64 CARDIAC MSCT - Indications

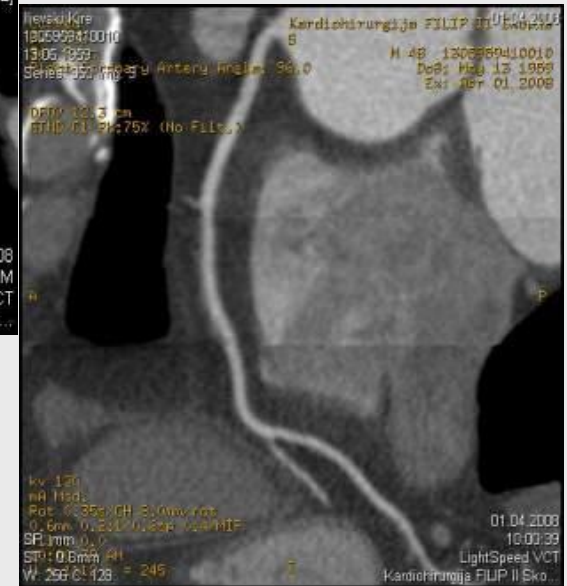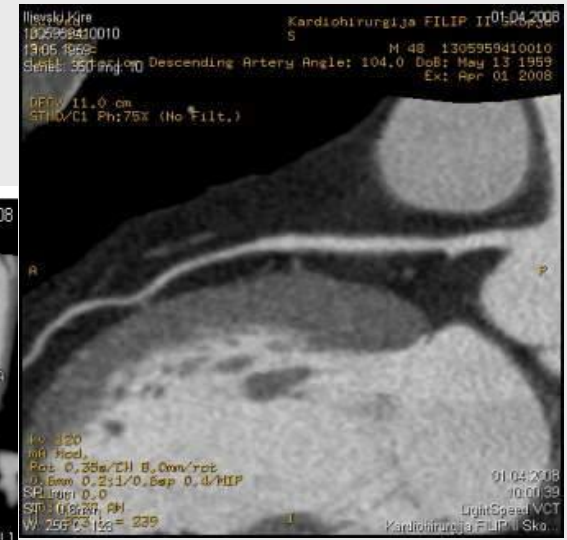
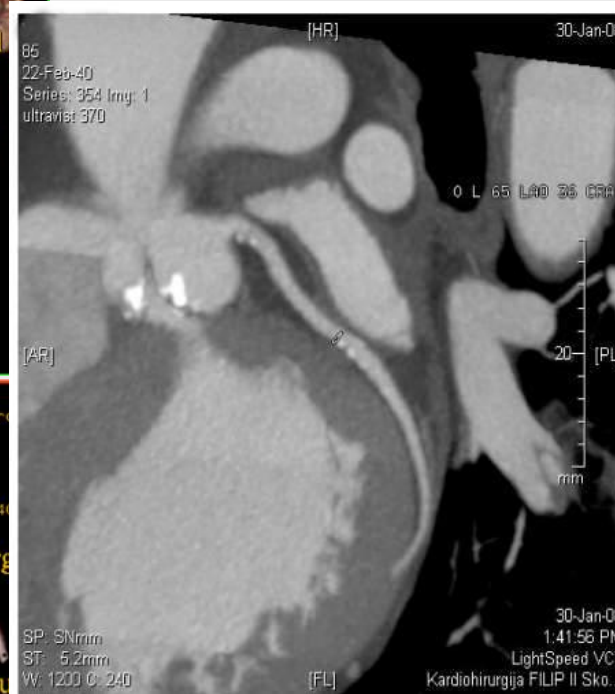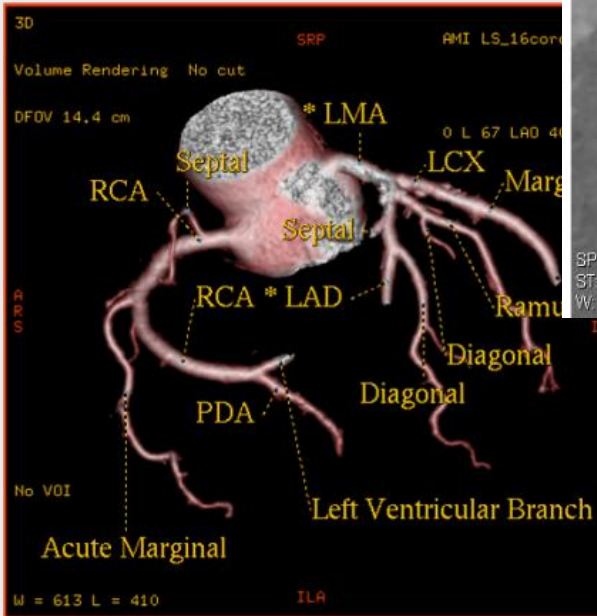
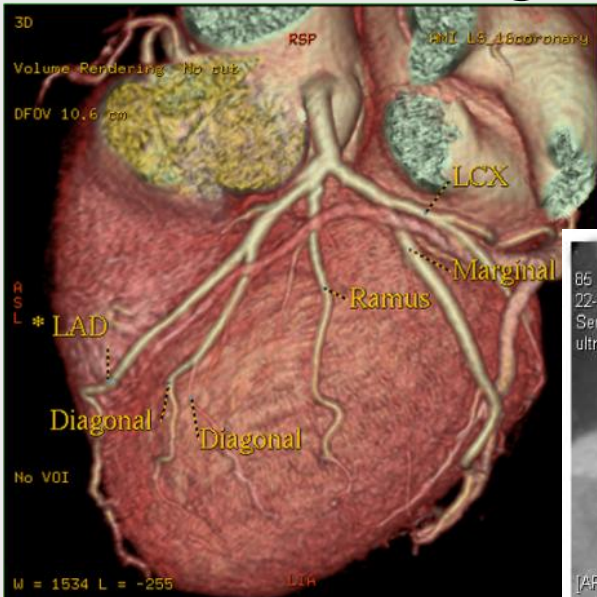
- Detection of CAD for a patient with atypical chest pain/ angina
- Screening in asymptomatic patients with high risk for CAD
- Evaluation of suspected coronary anomalies before/after cath lab
- Coronary assessment before cardiac & vascular surgery
- Planning of interventions - stenting
- Stent & CABG follow up
- Triple rule out (aortic dissection,PE,CAD)
- Evaluation of valvular and ventricular function



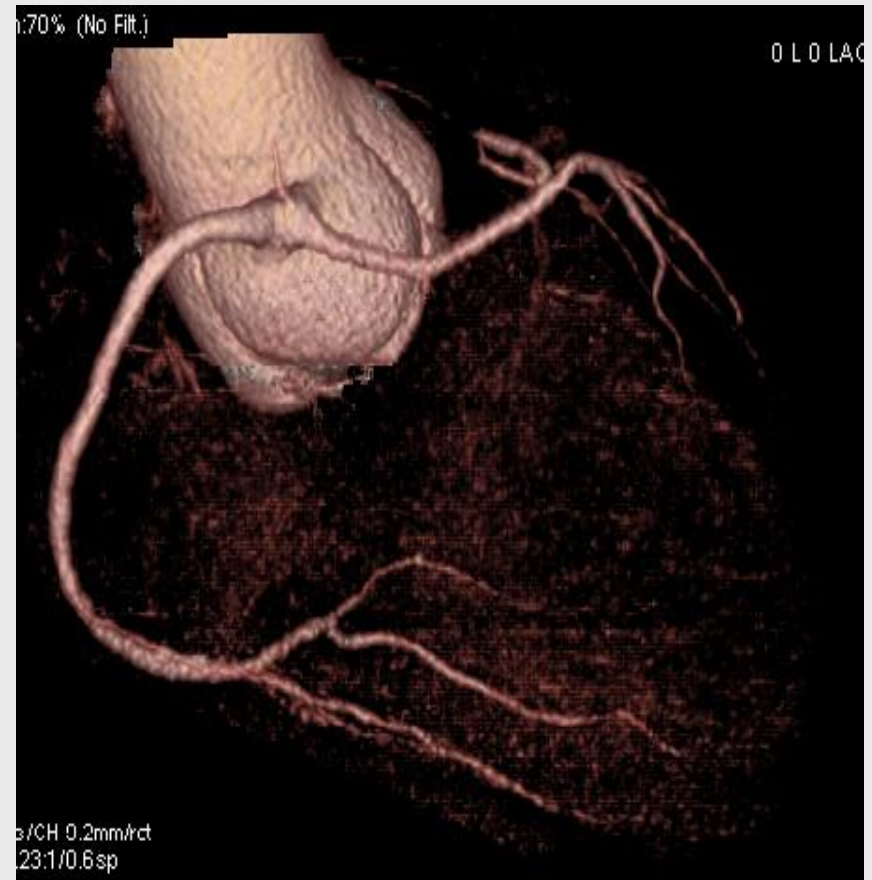
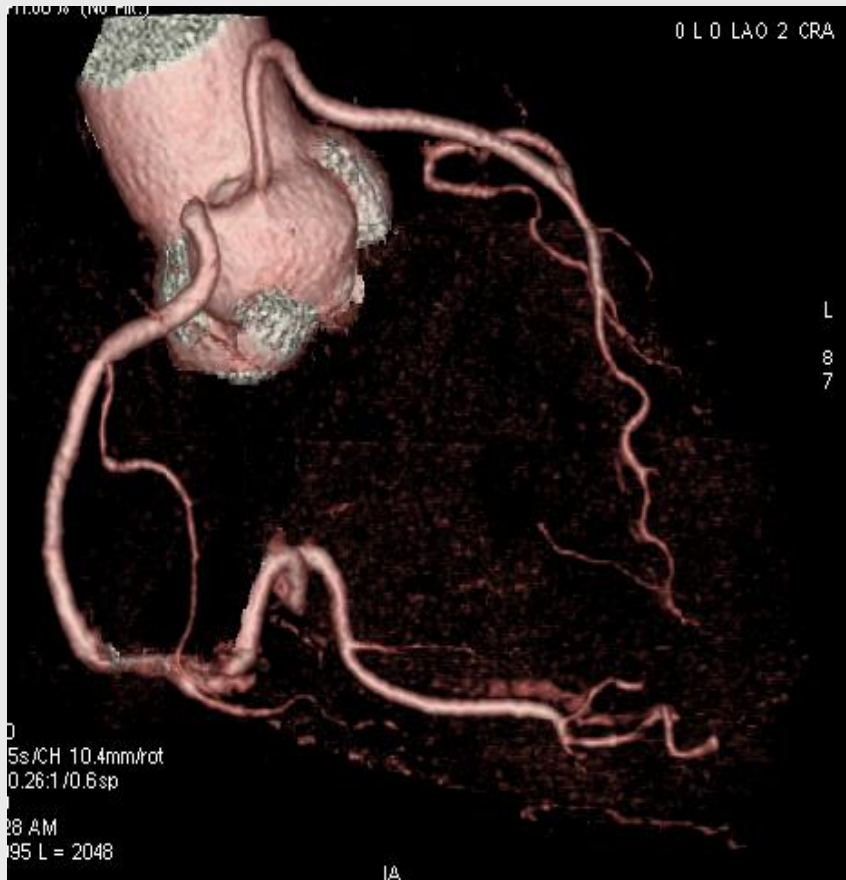Calcium Scoring Index

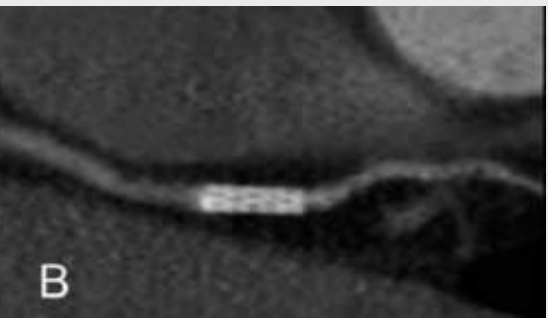
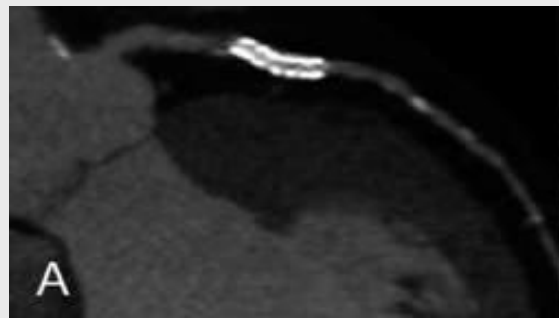
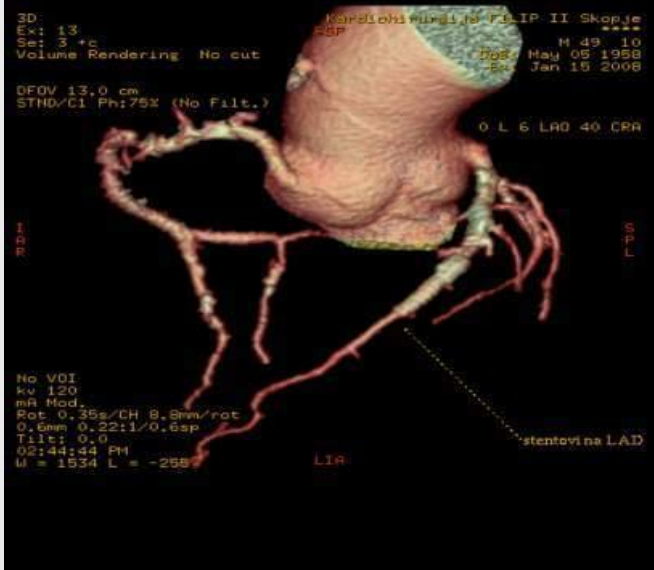
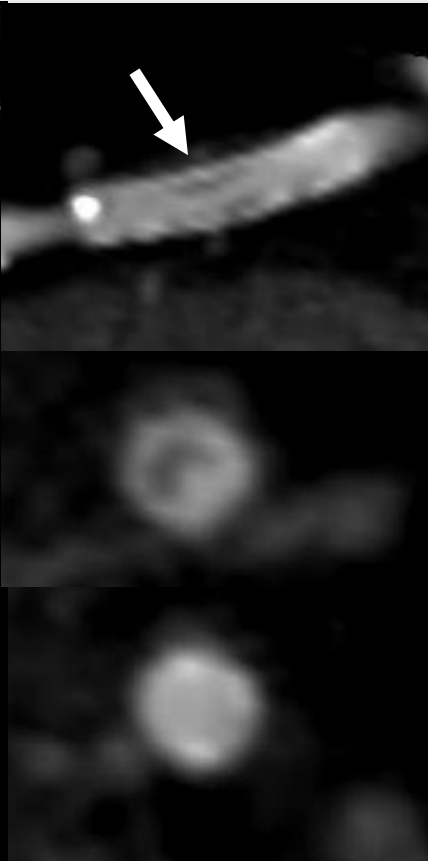
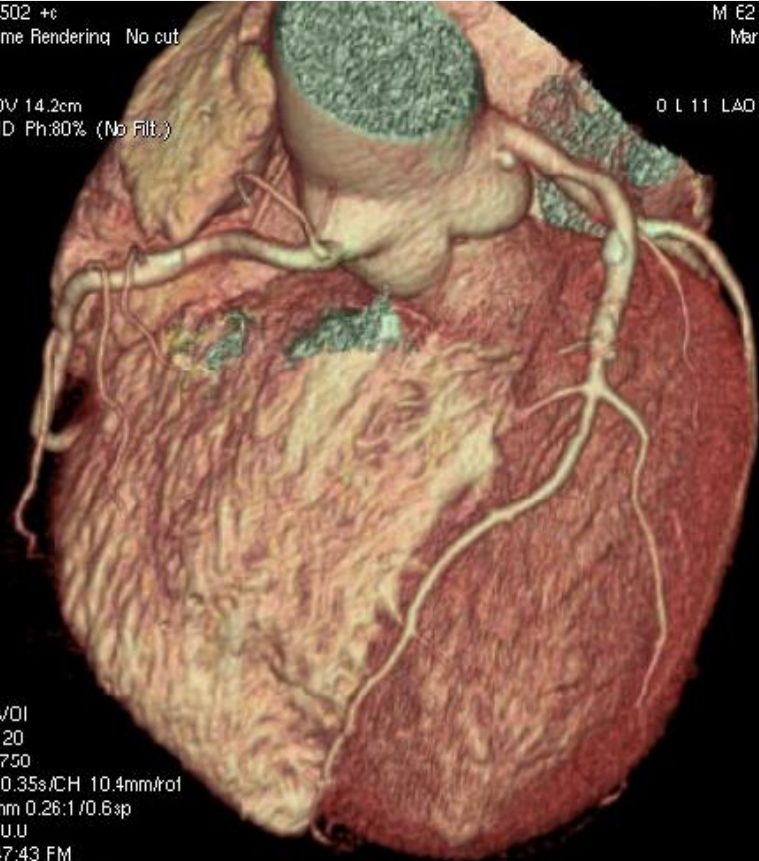
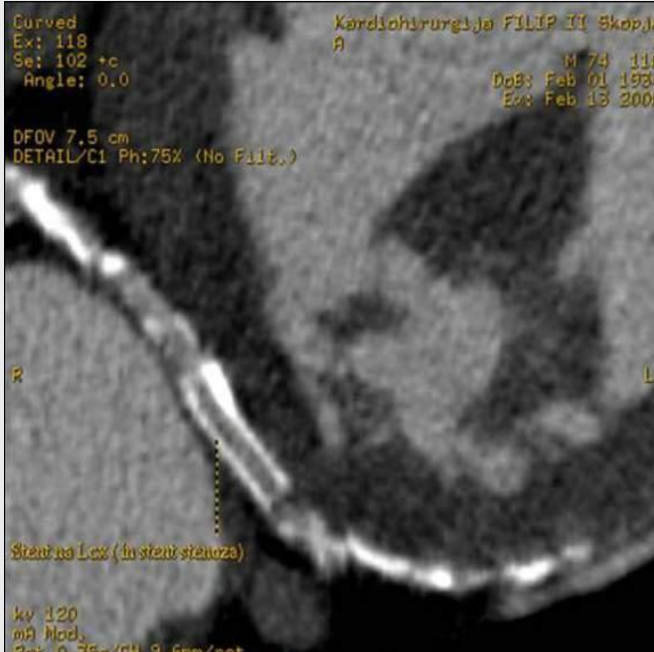

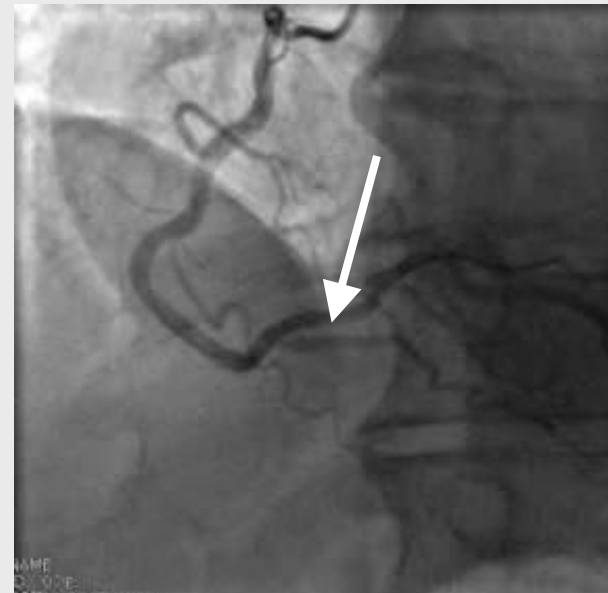
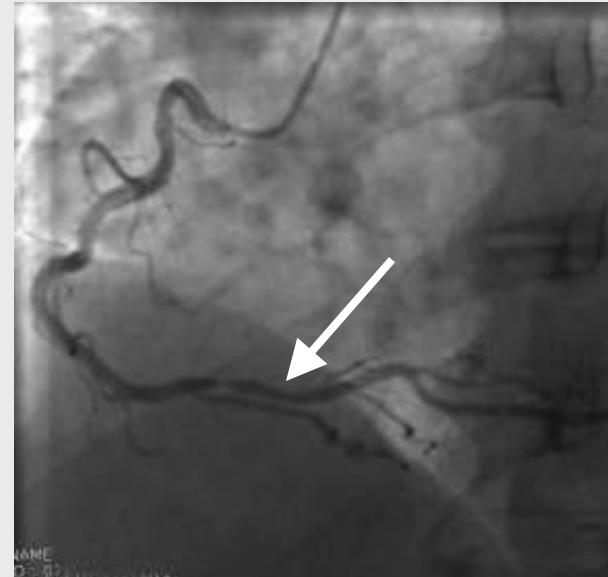
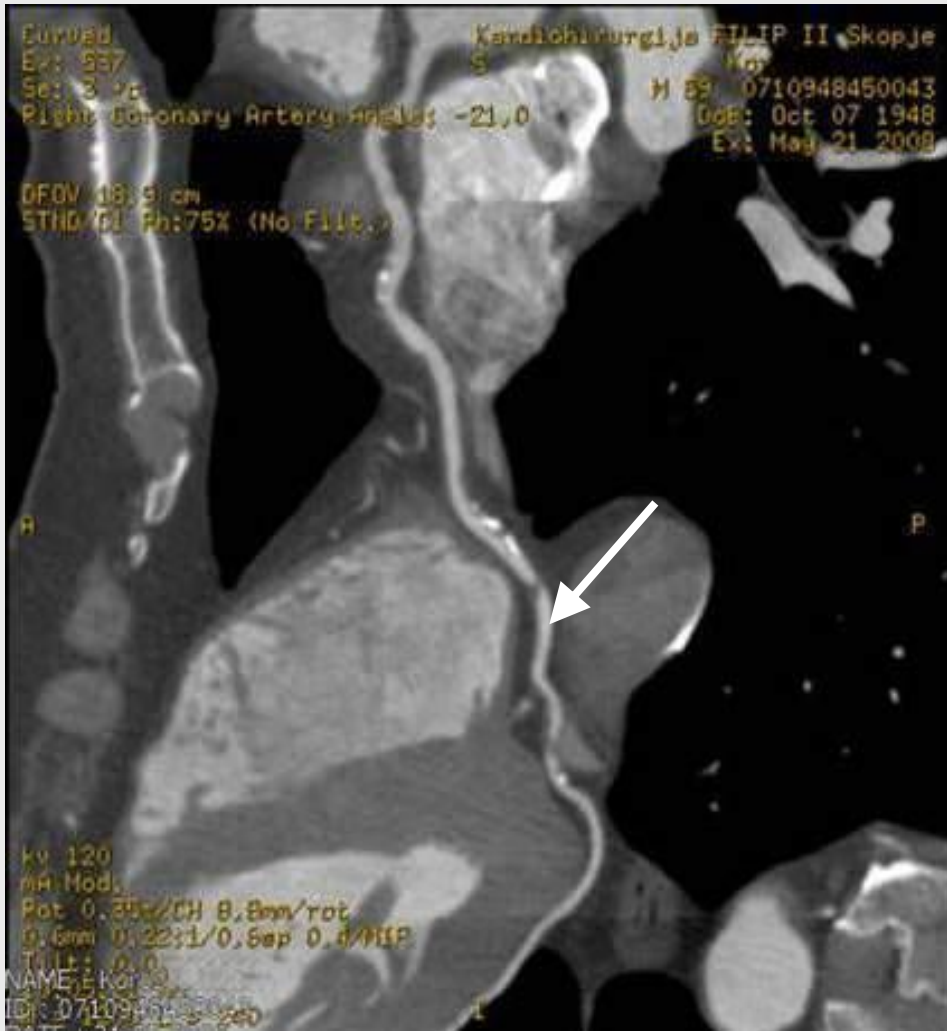
64 Cardiac MSCT



Congenital anomalies of coronary arteries



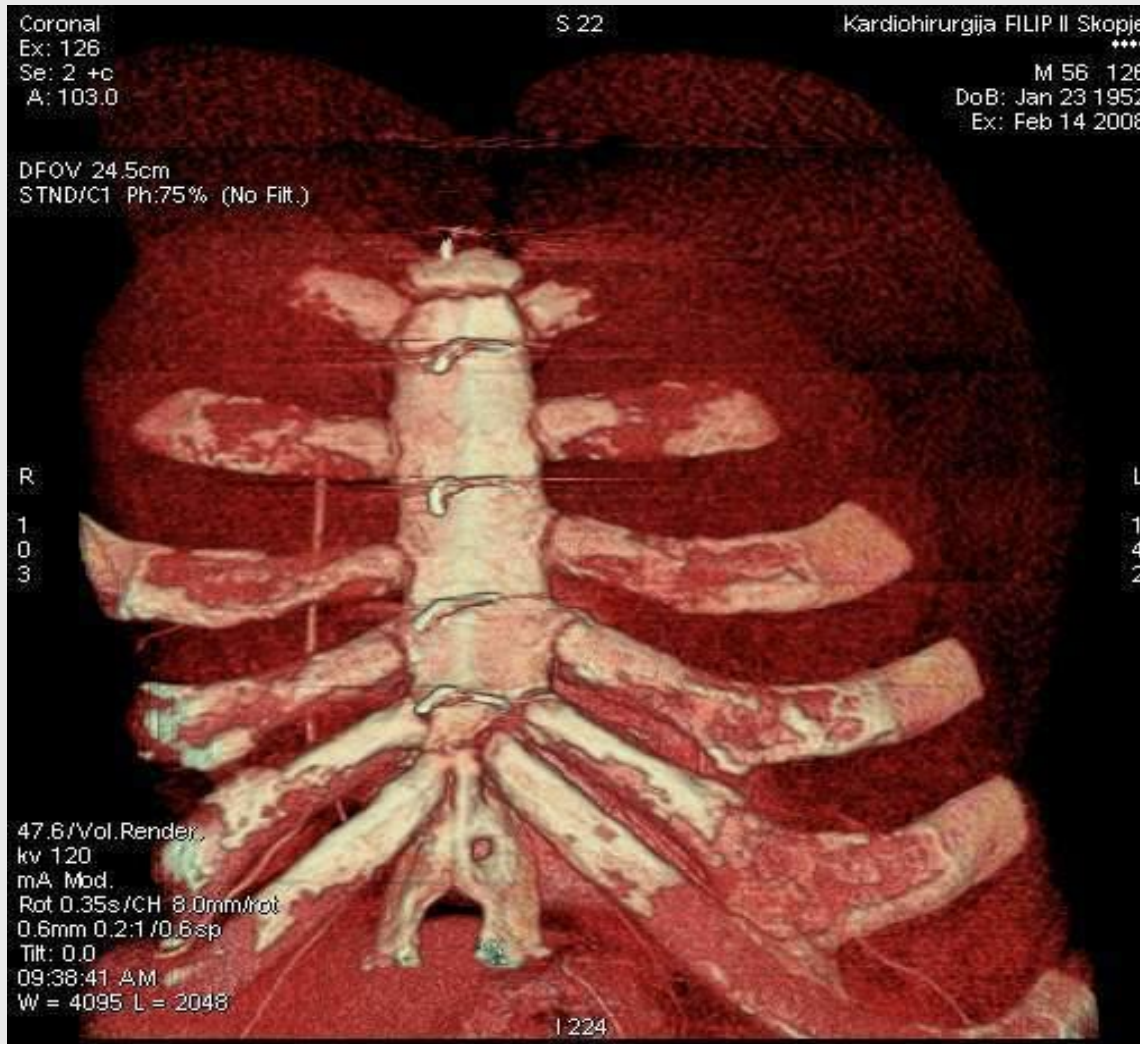




Real length of the stenosis,
suggested stent size and positioning

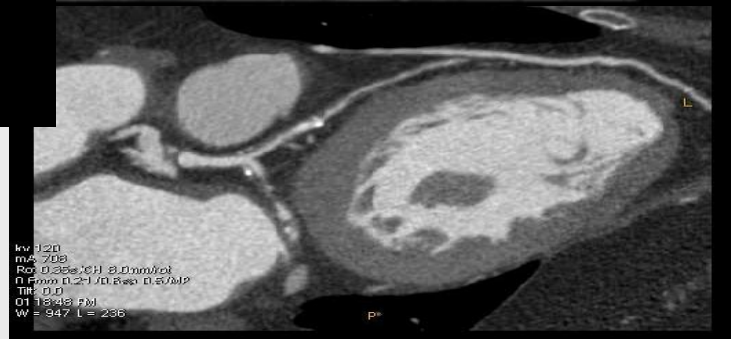
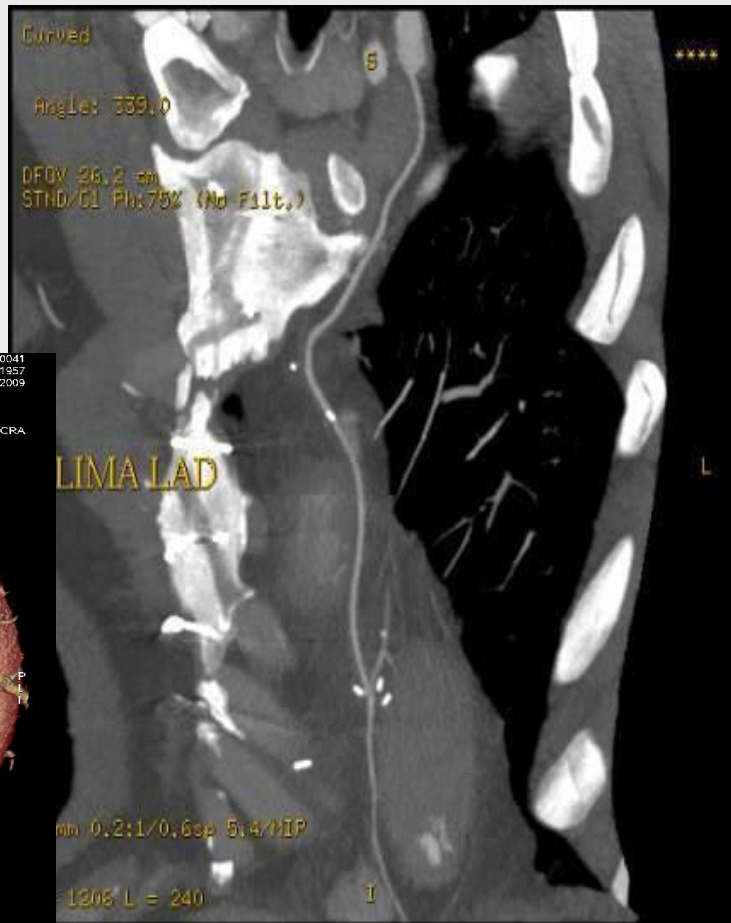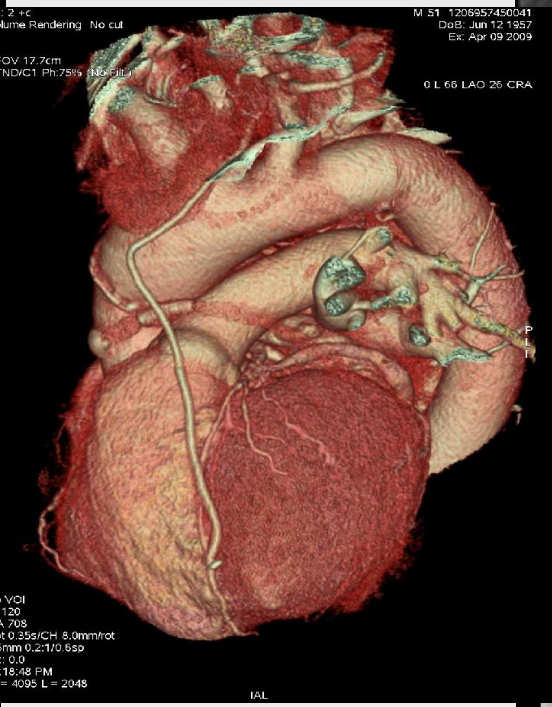

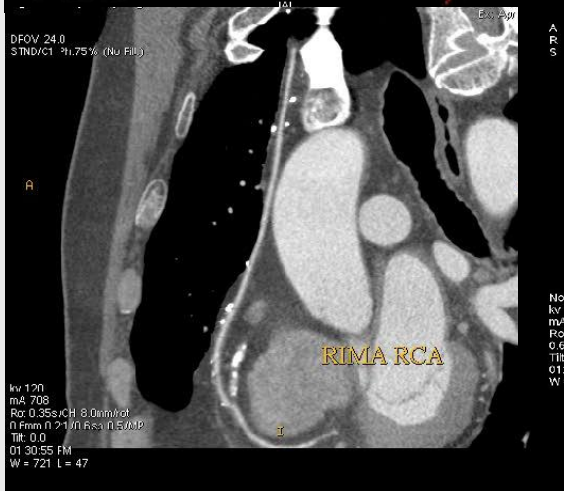
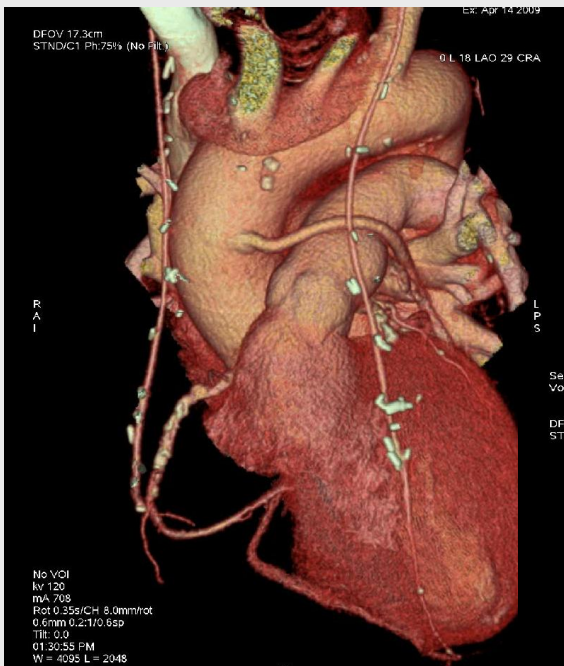


Coronary by-pass grafts



To evaluate each graft, proximal & distal anastomosis, run off & non grafted coronary artery



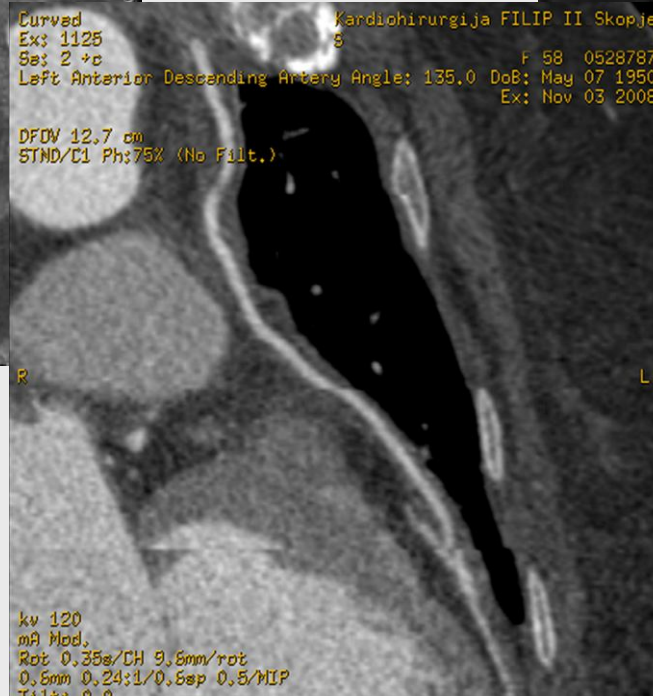
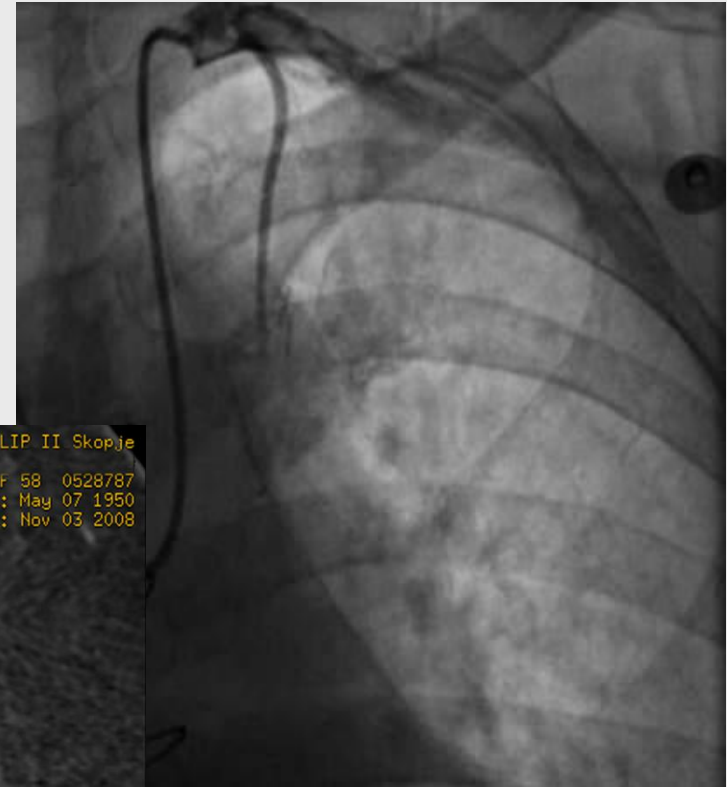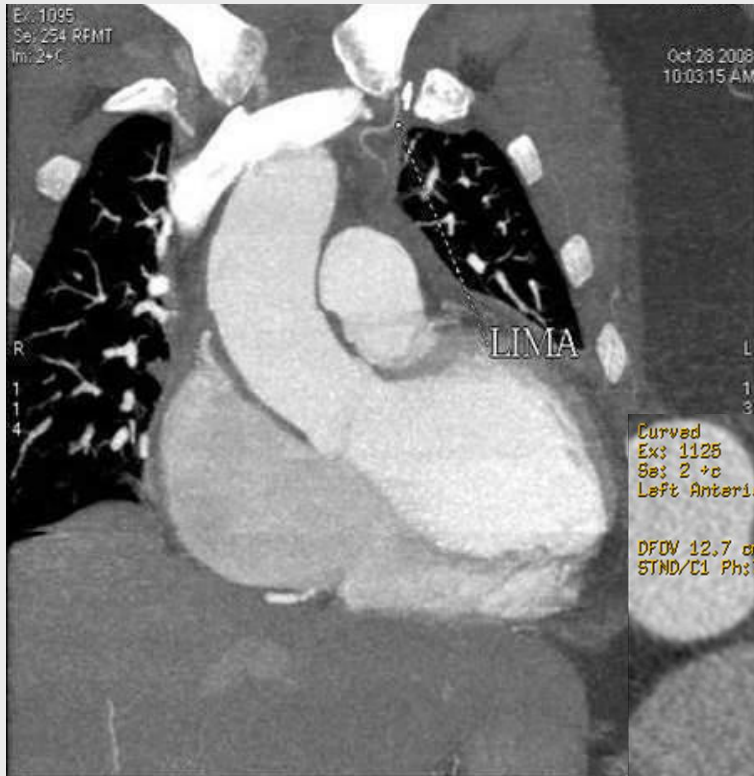


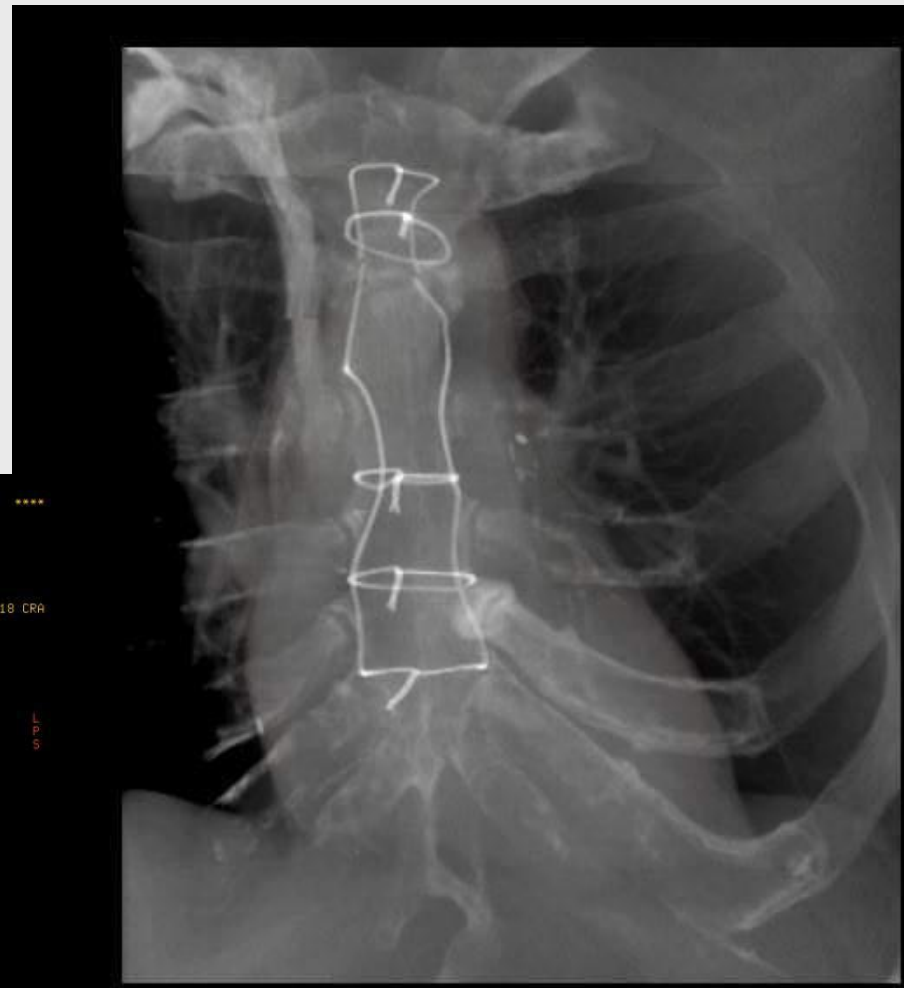
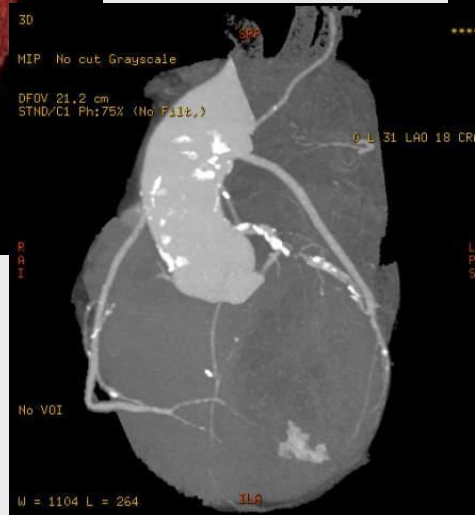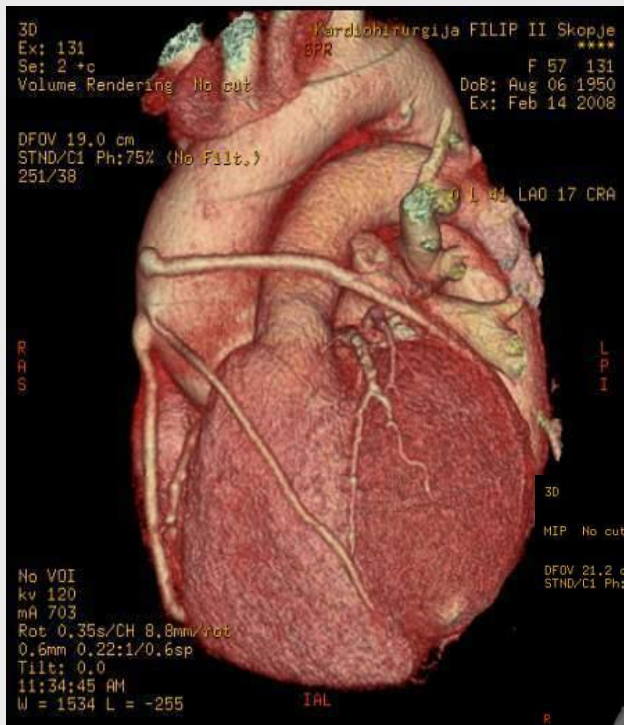
Arterial by-pass grafts:

The most frequent left internal mammary artery (LIMA).
revascularizes the LAD and the diagonal arteries.



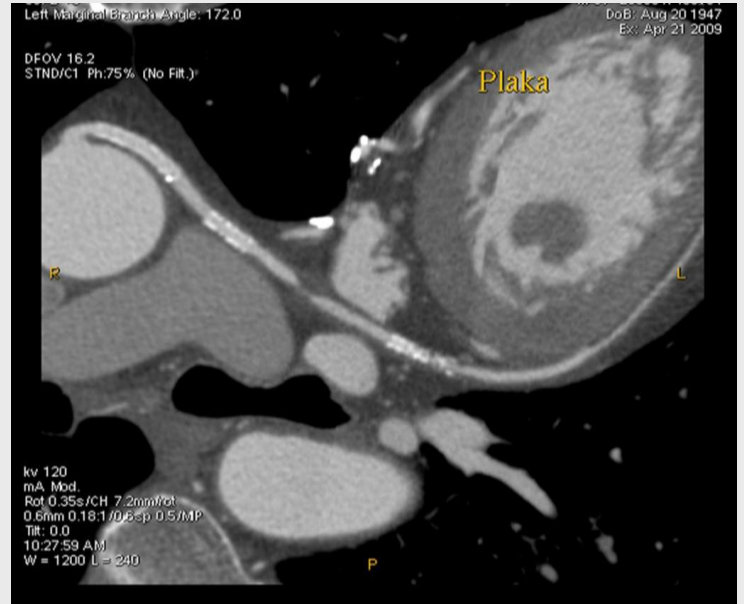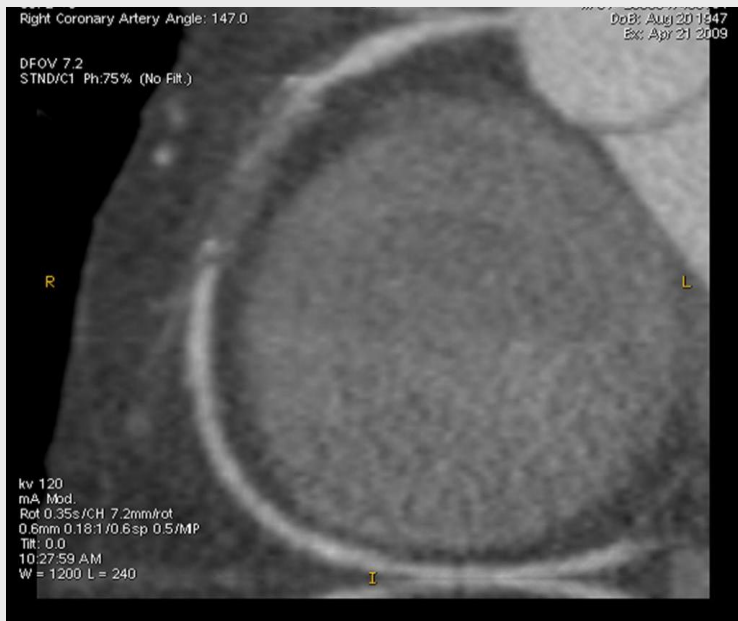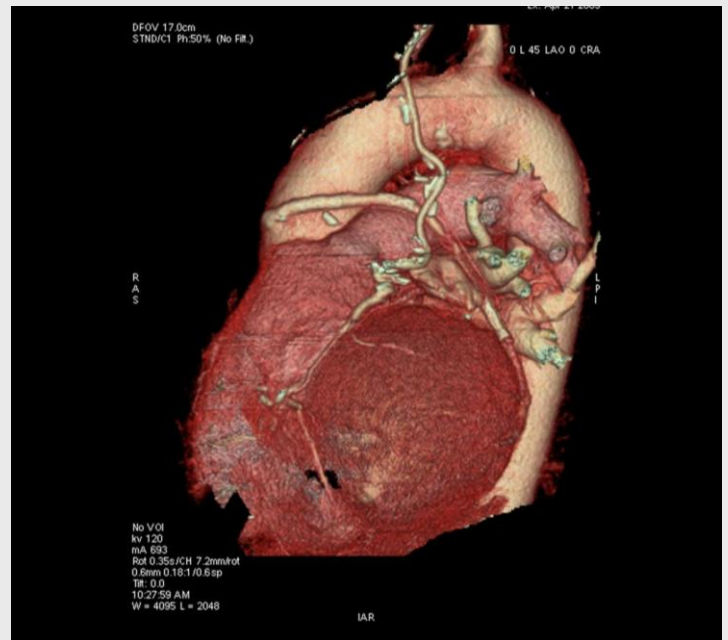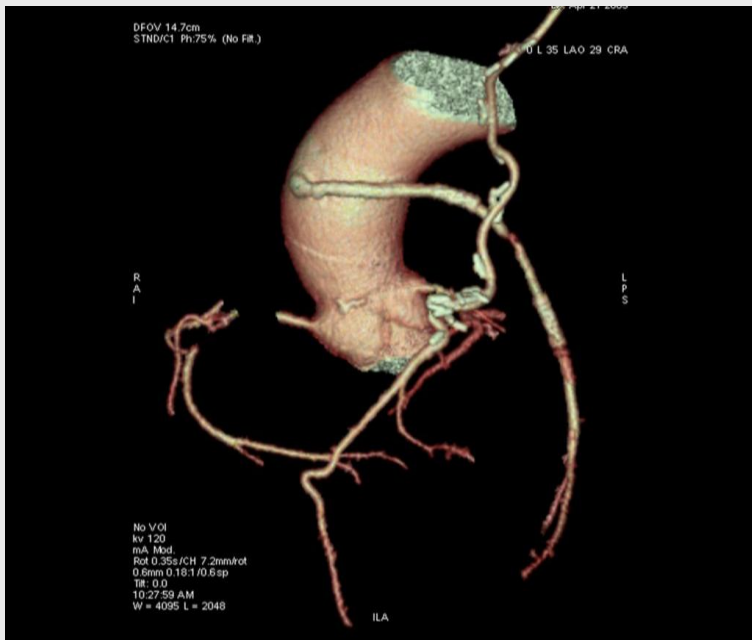
Arterial by-pass grafts:





Aorto-coronary grafts , the proximal anastomosis is located on the antero-lateral wall of the supra –coronary ascending aorta
 Venous grafts are prone to progressive atherosclerotic changes due to arterialization with consequences on the long term patency results.

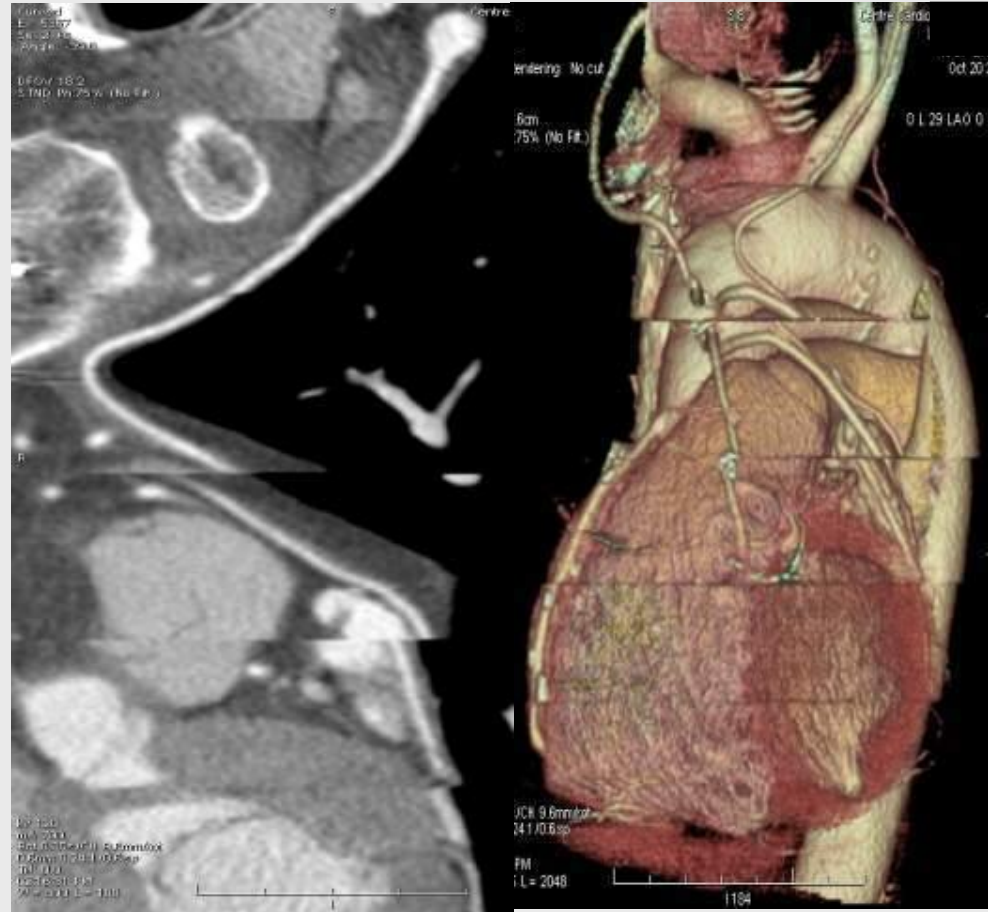



64 CARDIAC MSCT

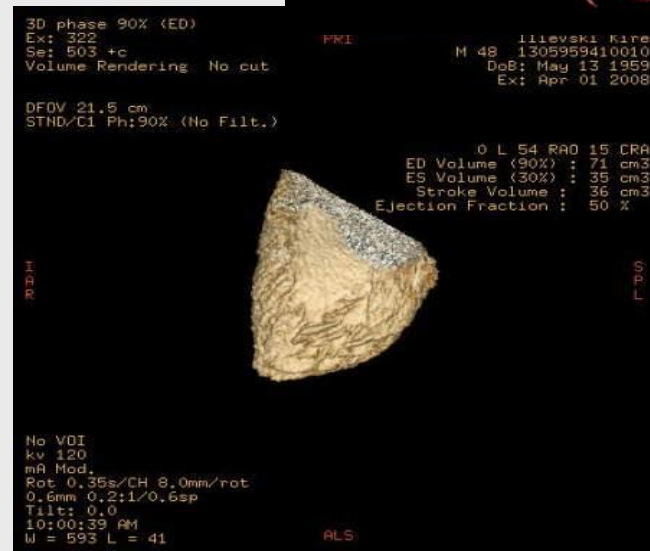
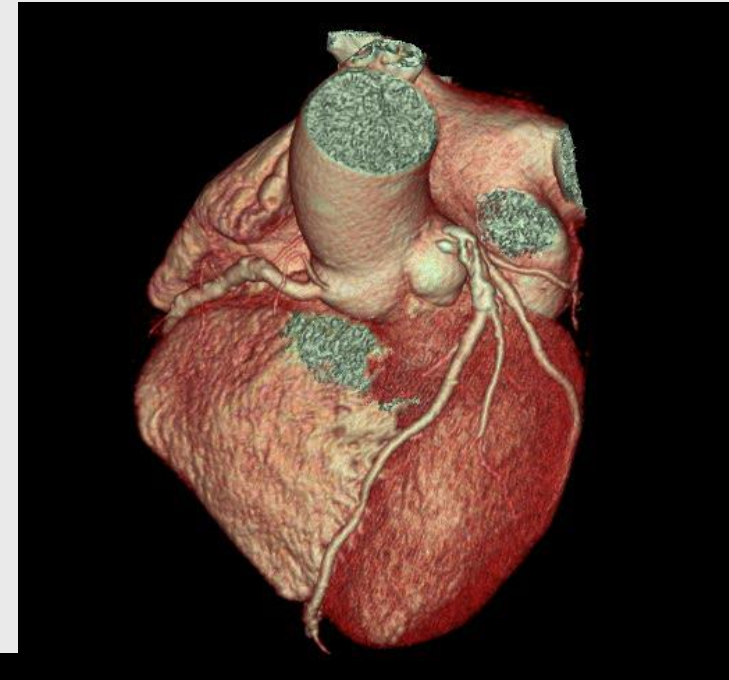
Causes of failure:

- Heart rate > 70 bpm
- High Arrhythmia
- Patient cooperation (breathing)
- High level of calcium scoring
- Careful with:
 - Renal insufficiency
 - Hyperthireosis

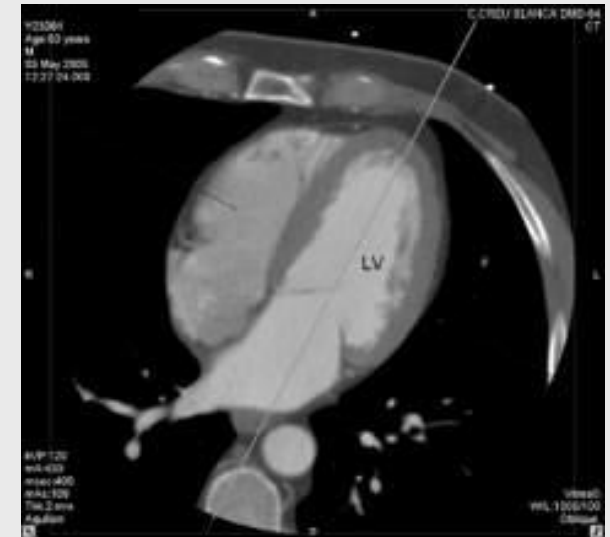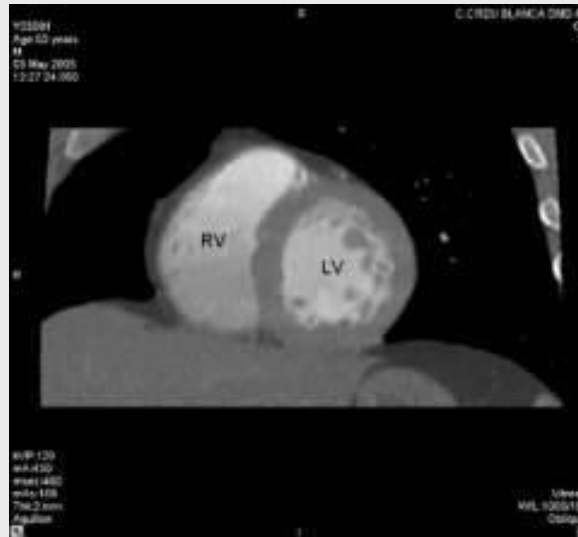
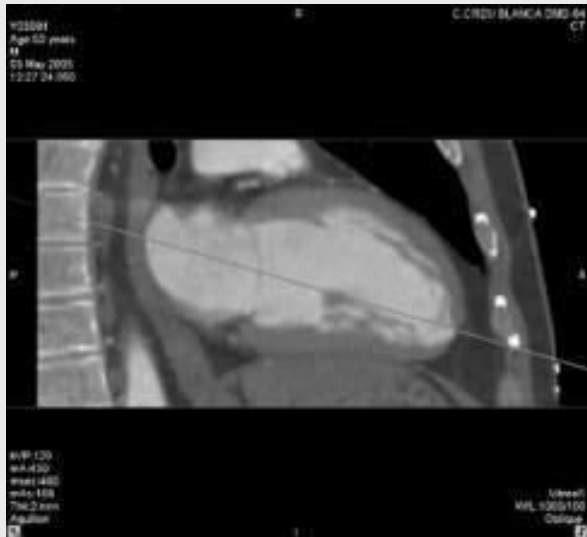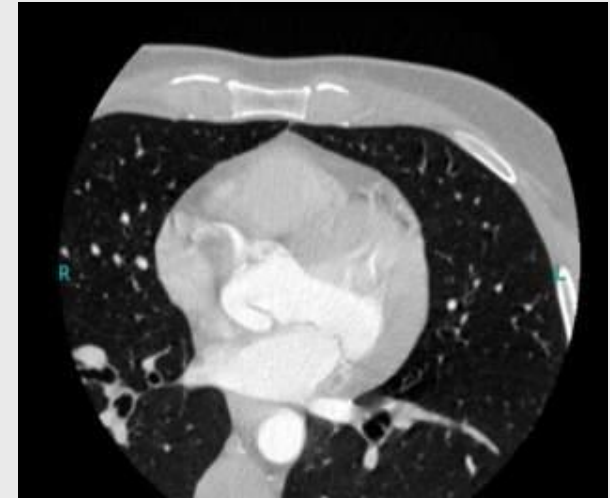


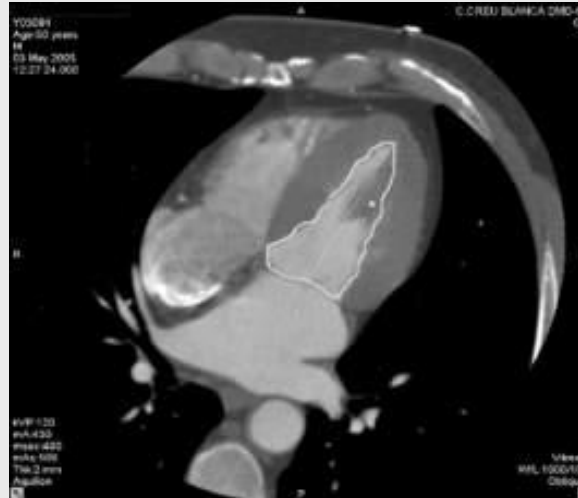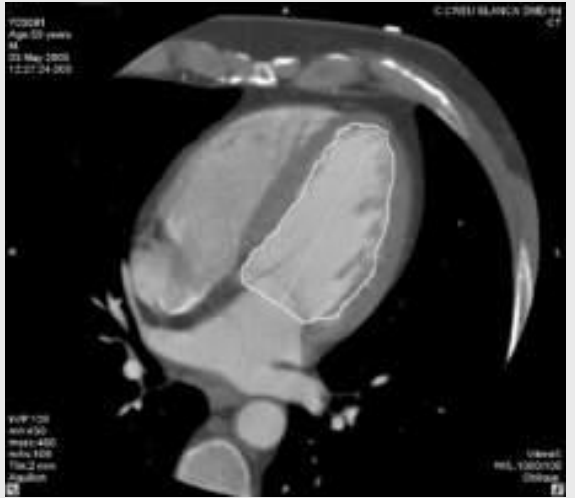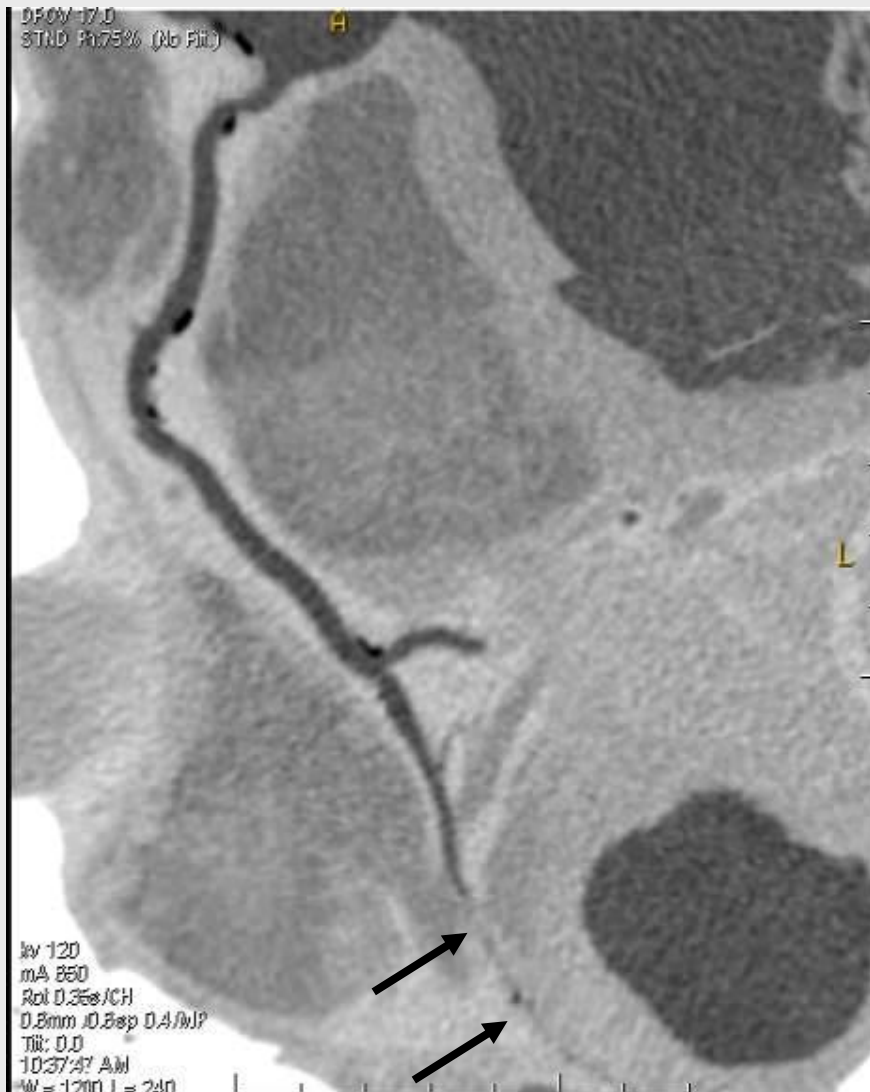64 Cardiac MSCT

- Ischemia or necrosis area.
- Atrial & Ventricular septal defect
- Aneurysm or false aneurysm
- Thrombus or tumor formation
- Pericardial effusion & calcifications
- valvular evaluation
- Ejection fraction

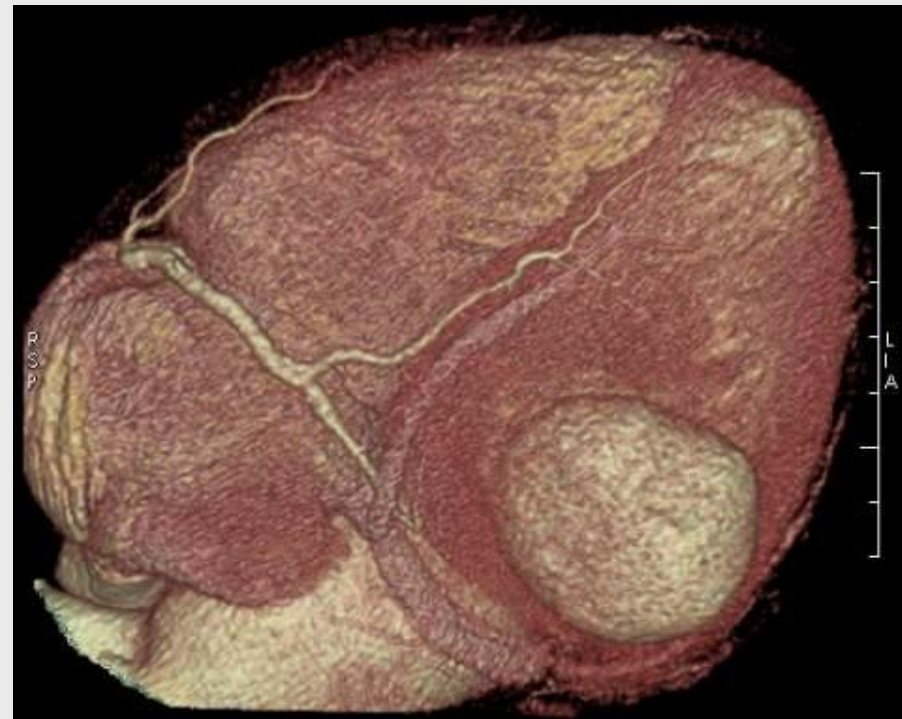


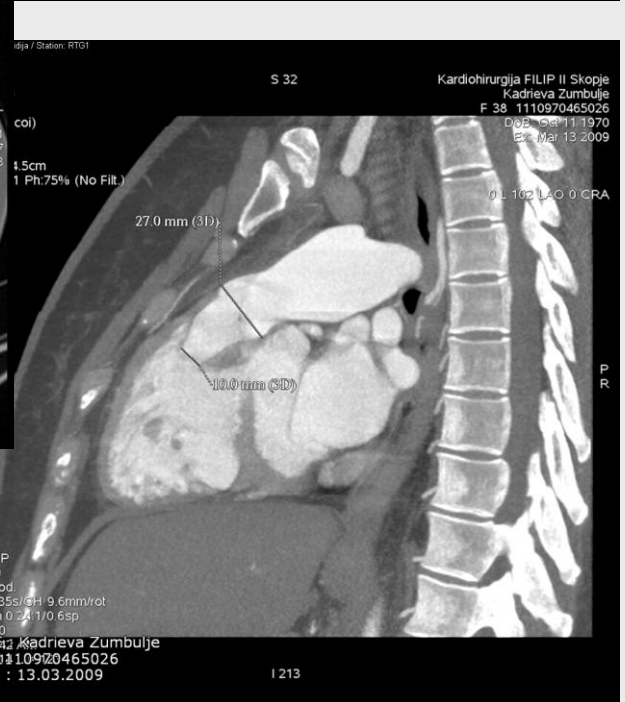
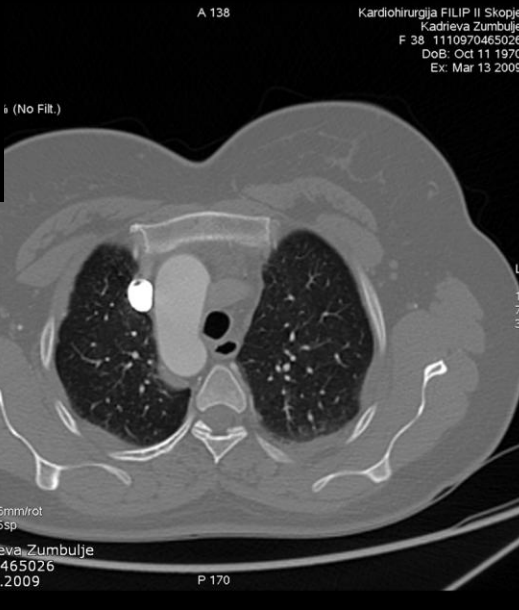
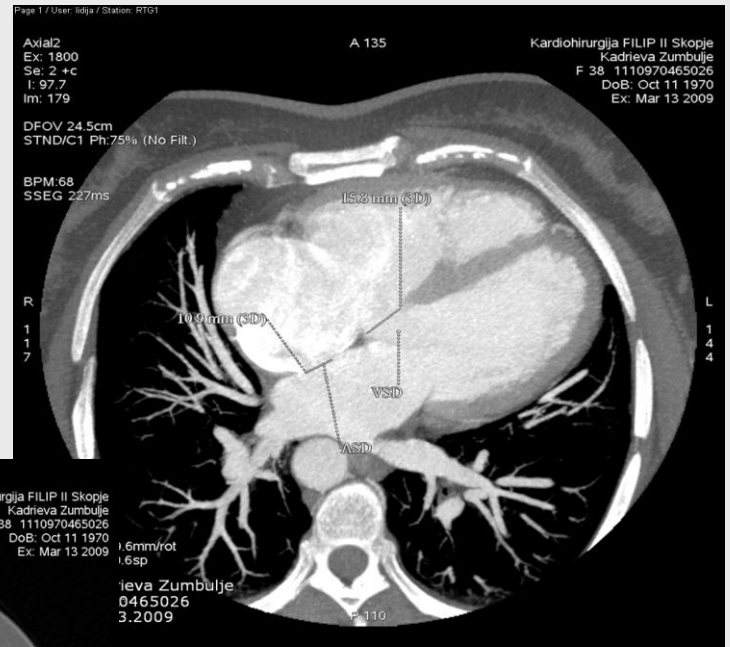
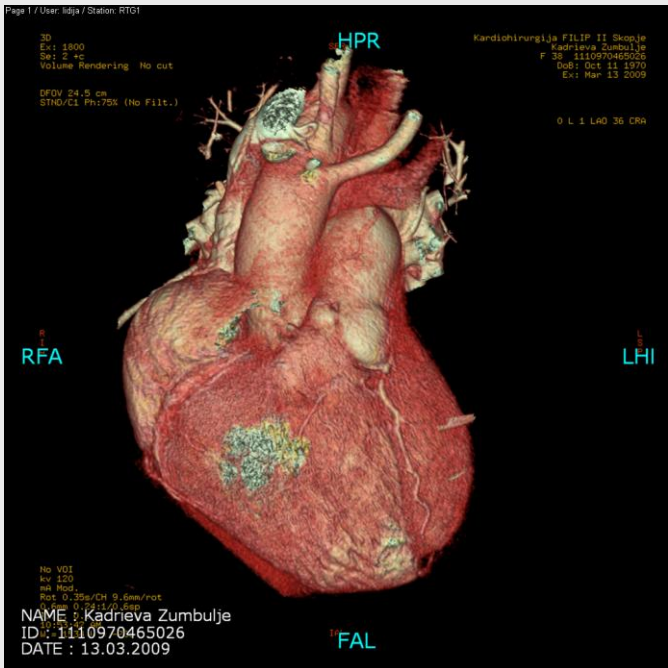
64 Cardiac MSCT





Distal PLB occlusion + Infero basal aneurysm

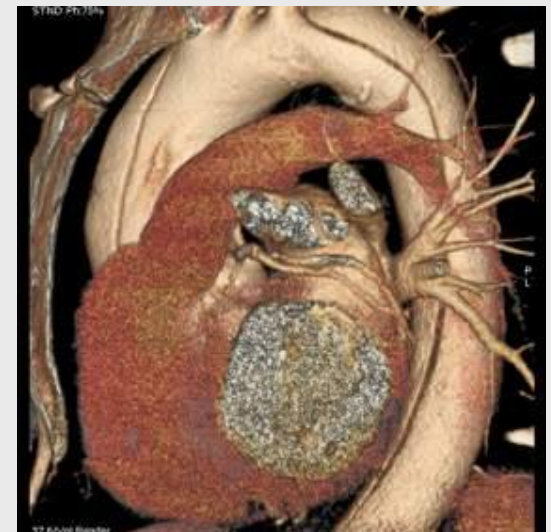
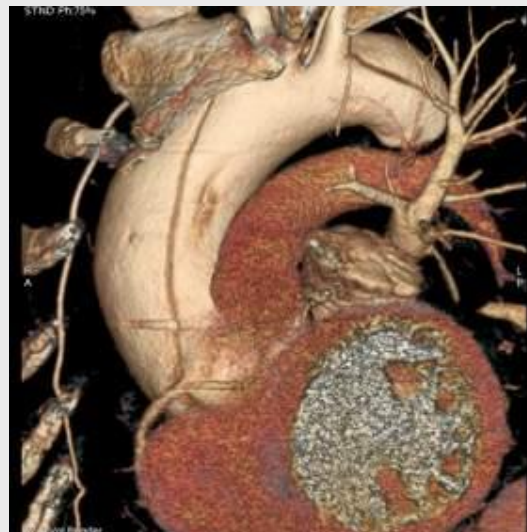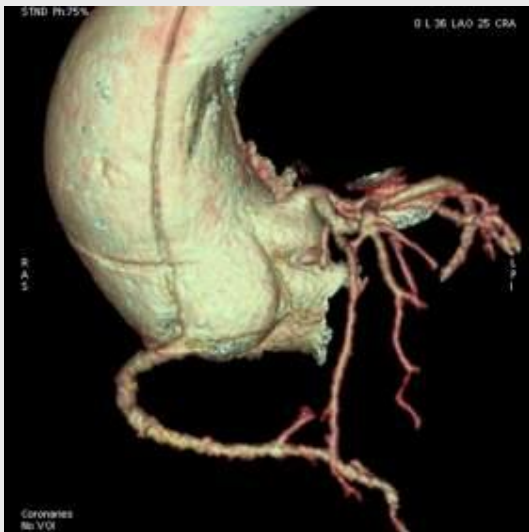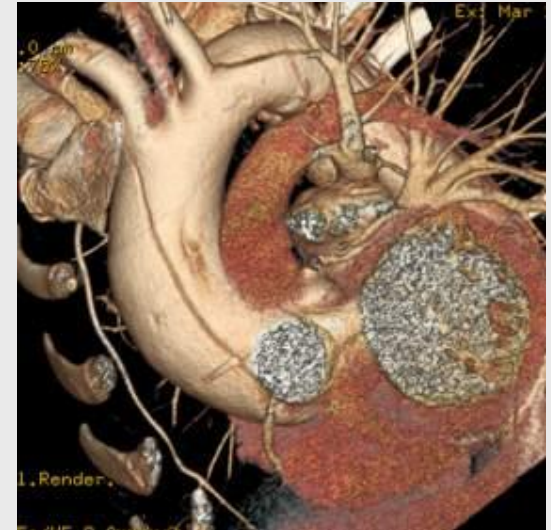


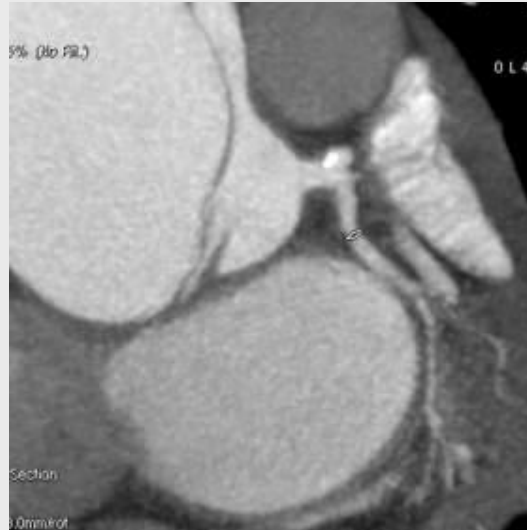
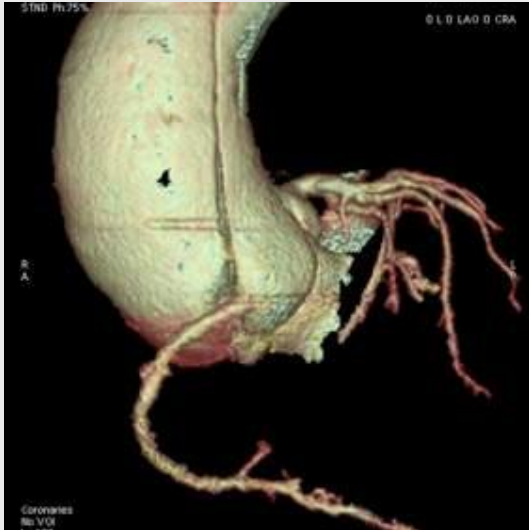
Right aortic arch, pulmonary isthmus stenoses, ASD, VSD

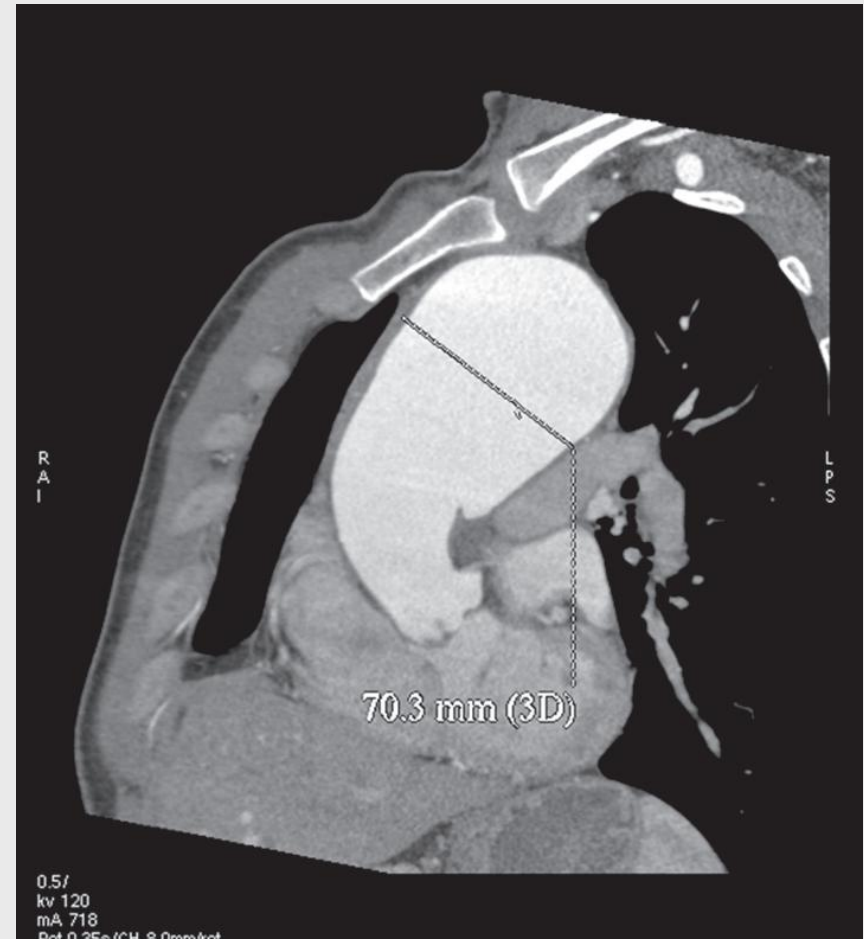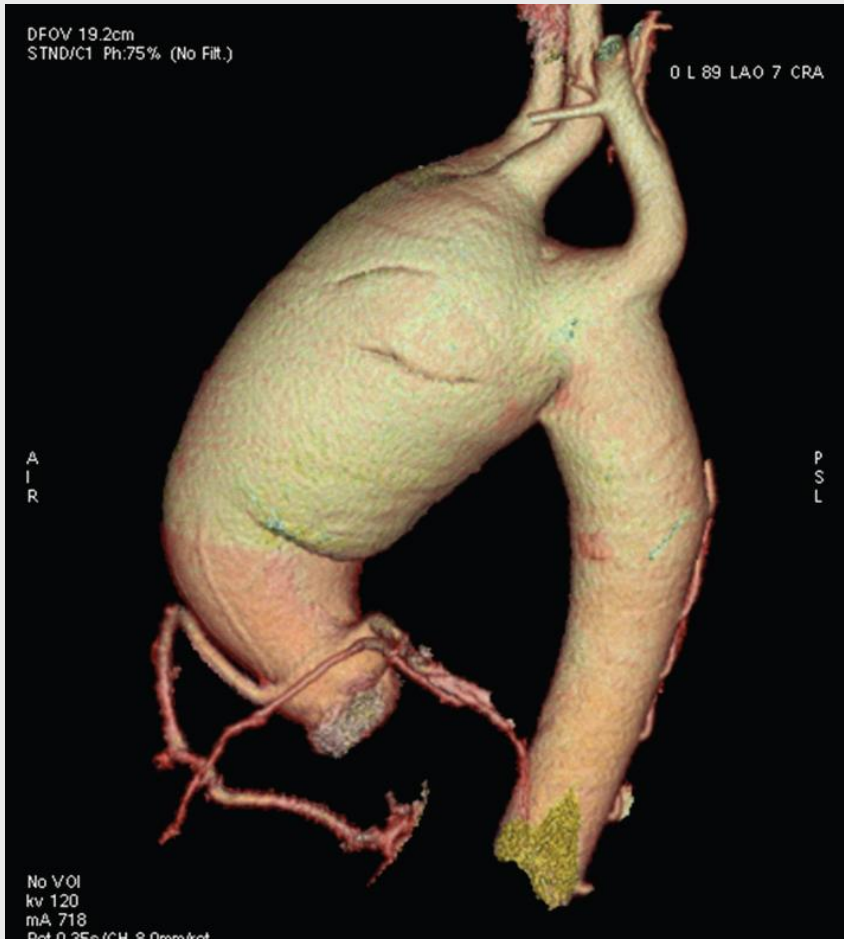


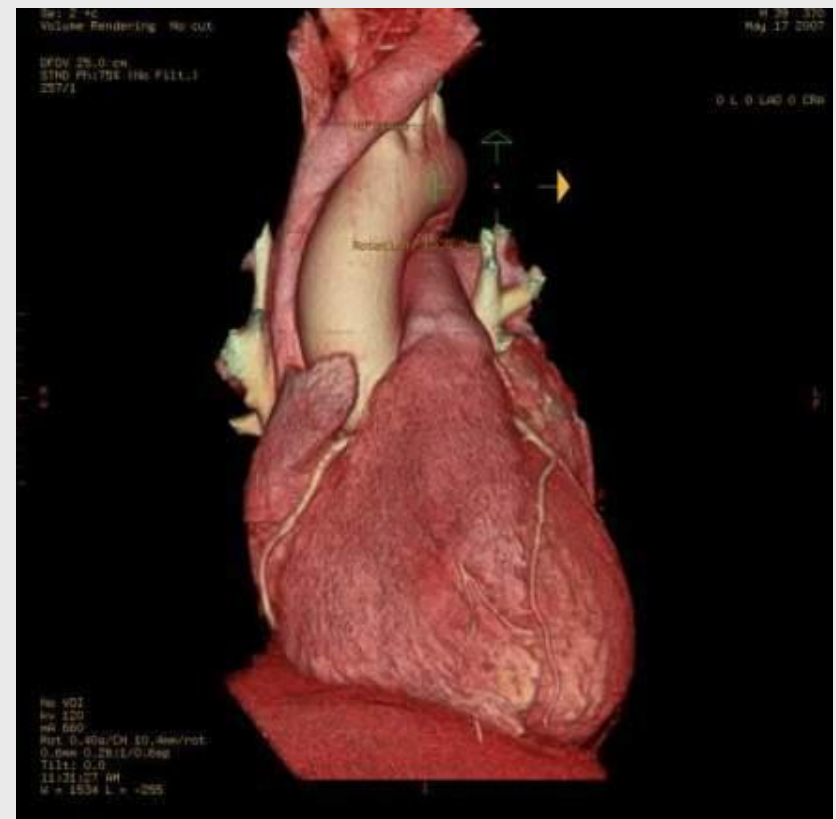
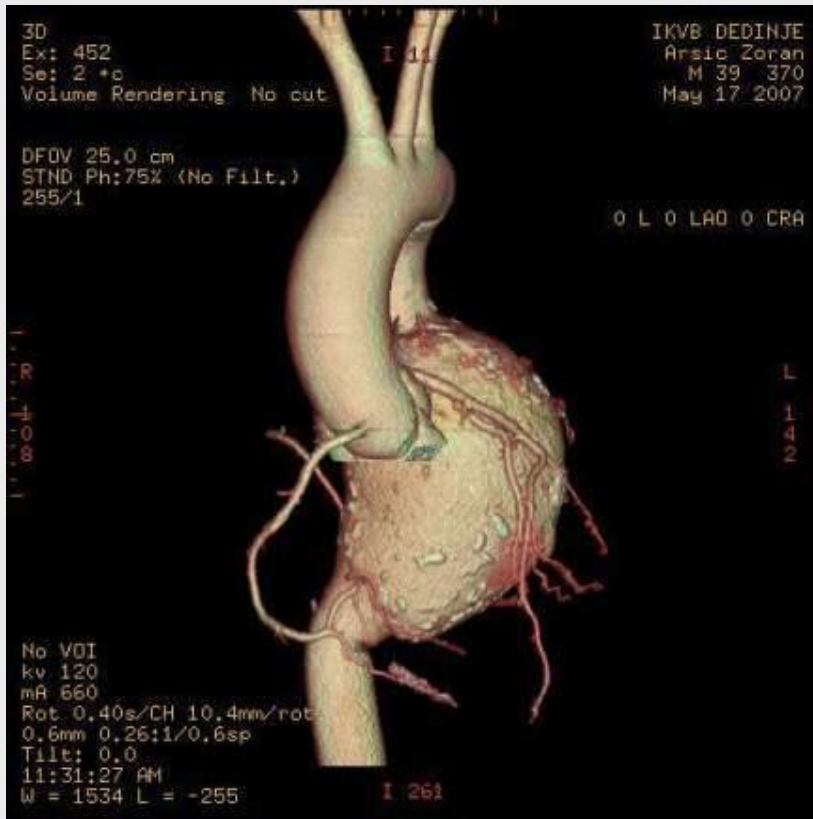
Dissection Stanford A



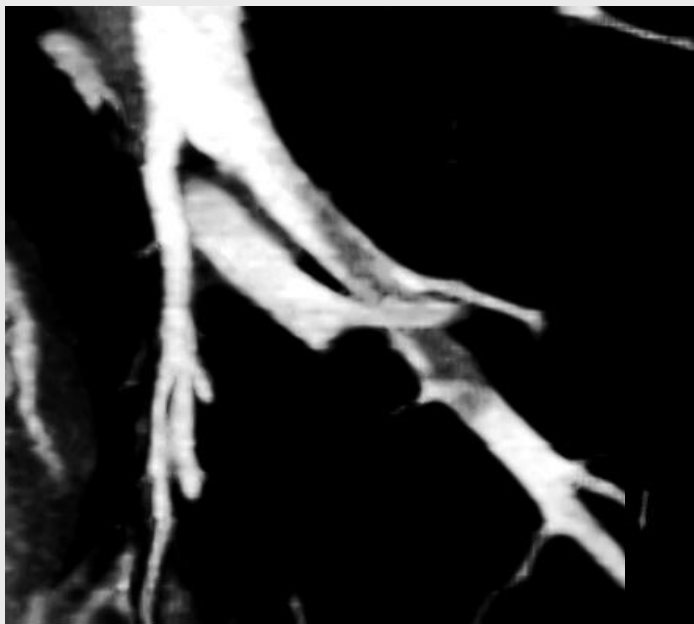64 Cardiac MSCT

Aneurysmatal disease

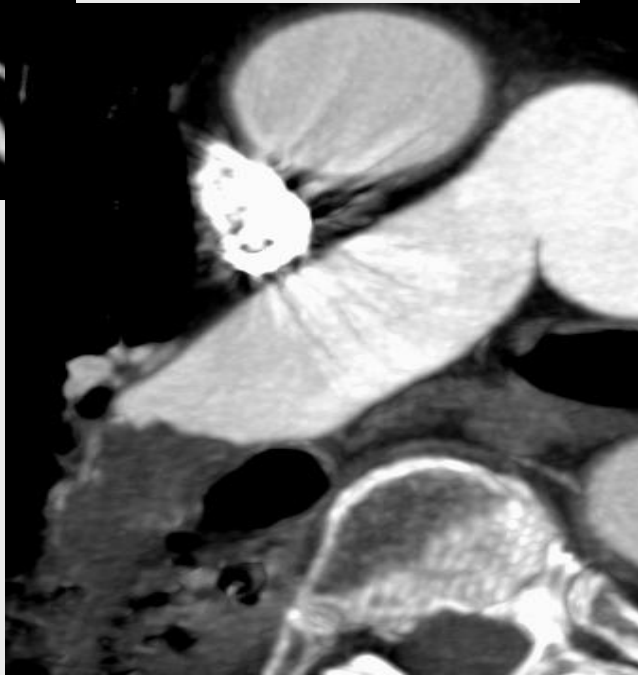
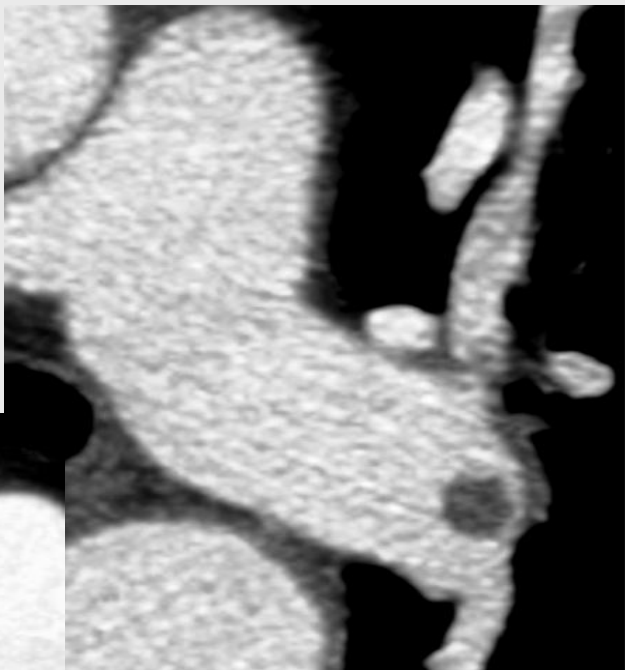




64 Cardiac MSCT

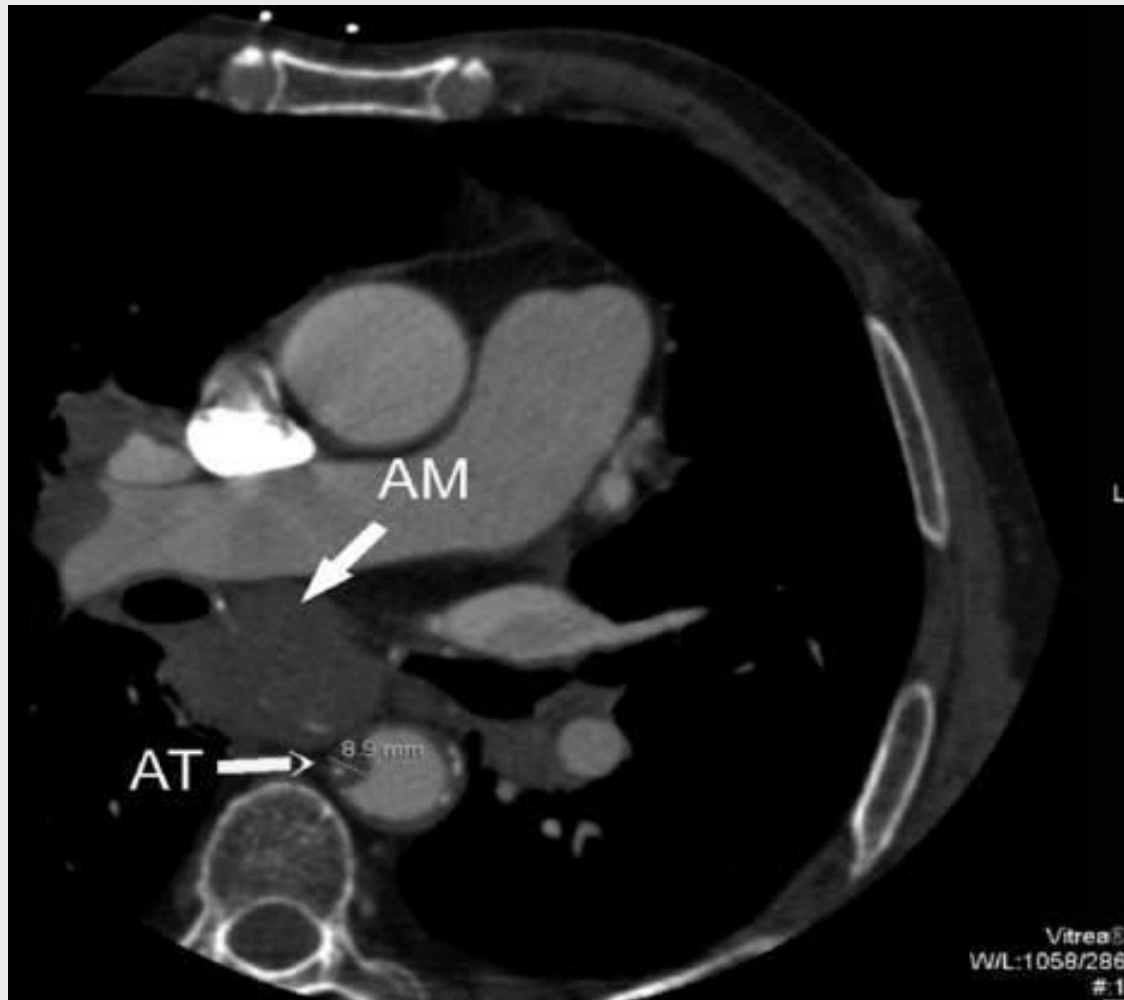


Pulmonary emboli



64 Cardiac MSCT

pulmonary carcinoma

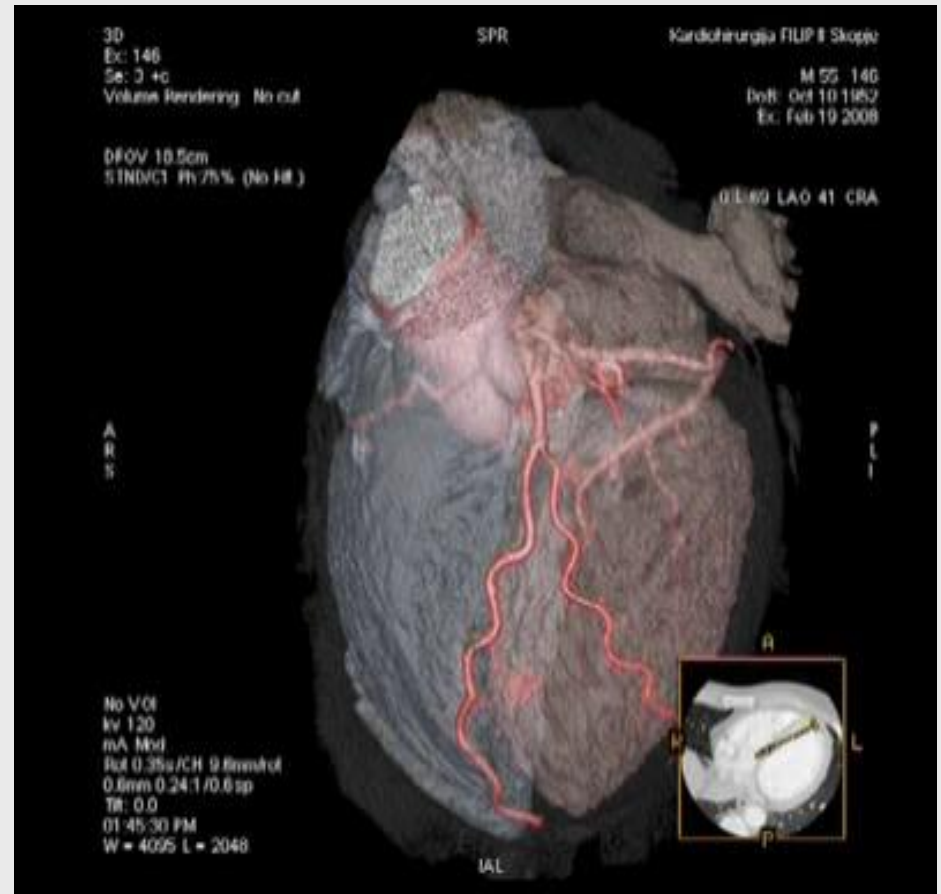


64 MSCT ANGIOGRAPHY & 64 Cardiac MSCT

Complications:

- Adverse reactions to contrast agents (prophylactic treatment)
- Extravasation of contrast material (Compartment syndrome)

Renal insufficiency induced by contrast material may be prevented by ensuring adequate hydration



CONCLUSION

64 MSCT ANGIOGRAPHY & 64 Cardiac MSCT :

Noninvasive, fast, precise, safe, without absolute contraindications

Compared to catheter angiography more patient-friendly procedure.

Decrease the number of diagnostic conventional angiography

