




UNIVERSITY "Sts. CYRIL AND METHODYUS"
FACULTY OF DENTISTRY



UNIVERSITY DENTAL CLINICAL CENTRE " St. PANTELEJMON "

DEPARTMENT OF ORAL SURGERY
DEPARTMENT OF ORTHODONTICS

SKOPJE, R. MACEDONIA



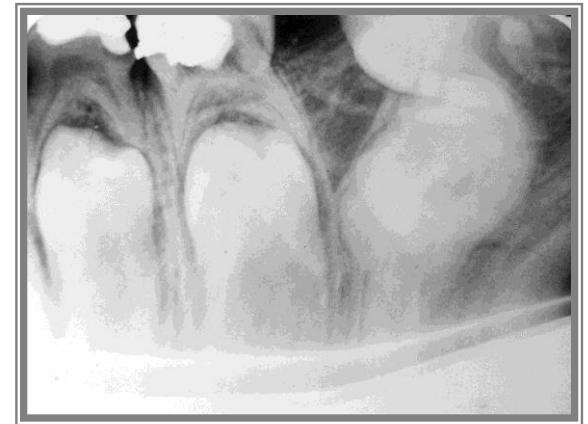
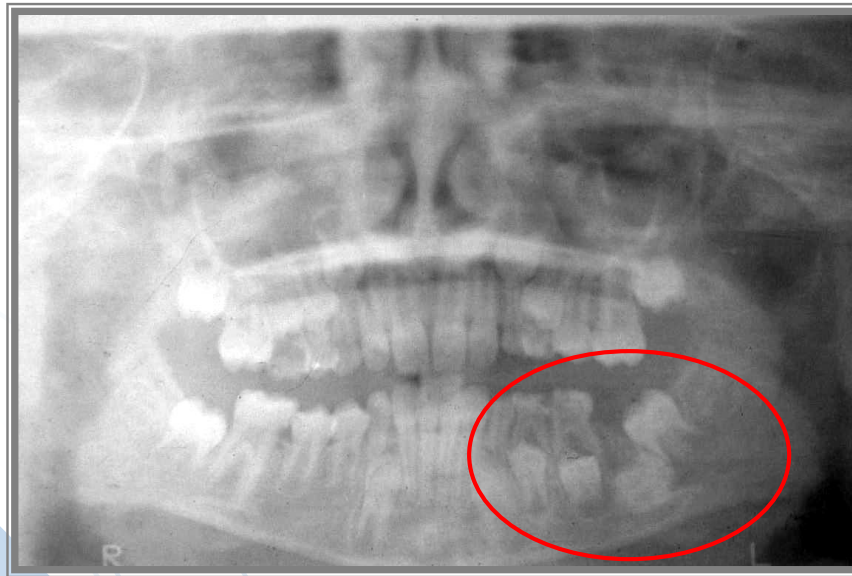
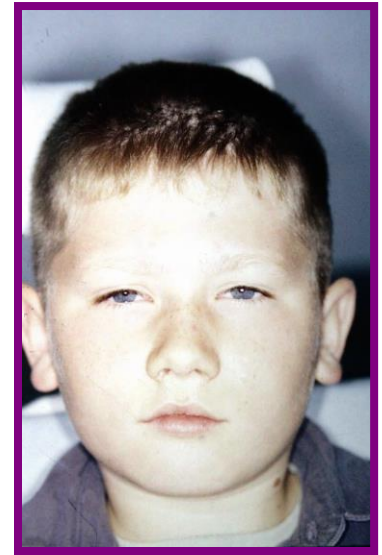
IMPACTED LOWER FIRST MOLAR

- case report -

*Dimova Cena, Maneva Marija, Kanurkova Lidija,
Janev Edvard, Stefanovski Sasho*

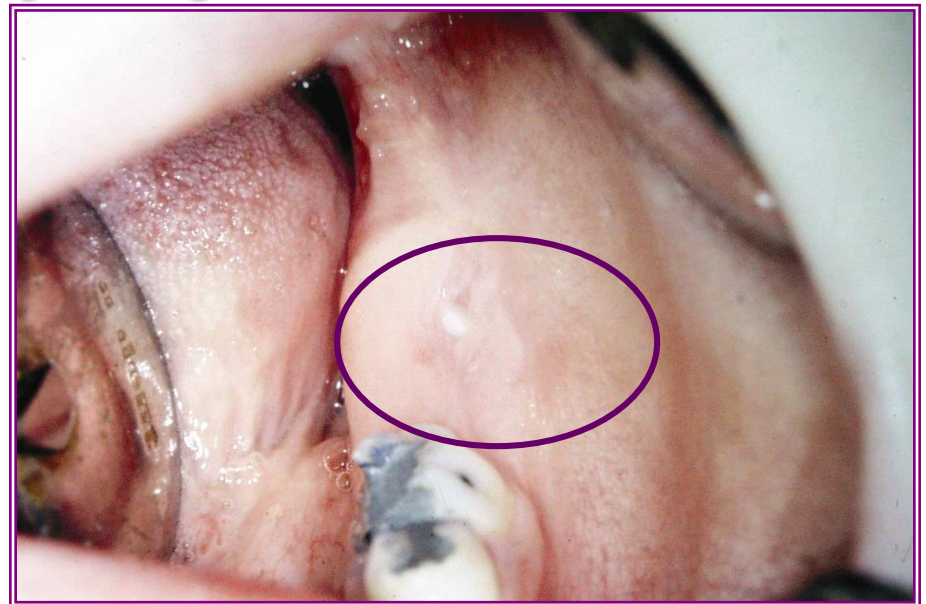
A
I
M

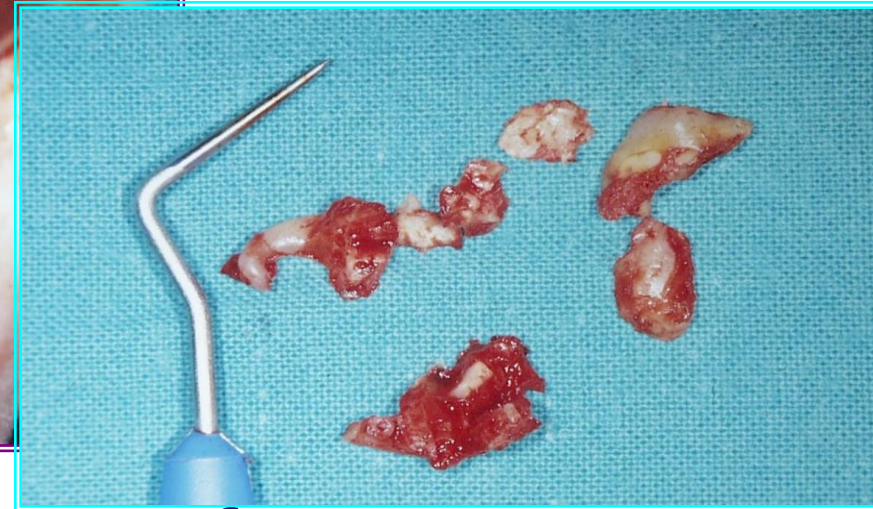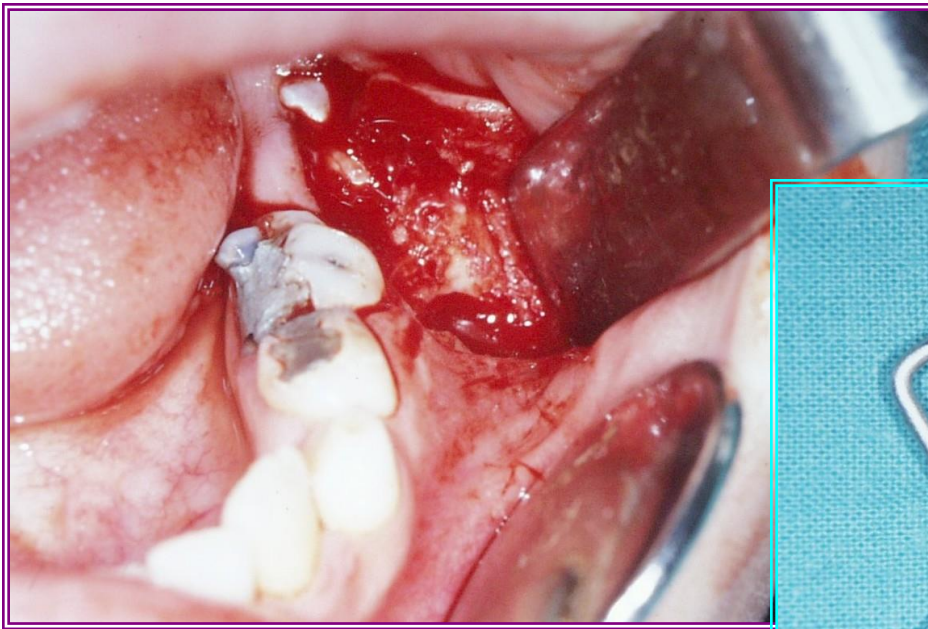
The aim of the study is to present an impacted lower first molar with atypical shape in a 9 years boy



The etiopathogenesis of this condition includes trauma due to fall at the age of 2.5 years

The specific of the eruption path of the second mandibular molar gave the primary need for RTG analyses, which confirmed the preliminary diagnoses



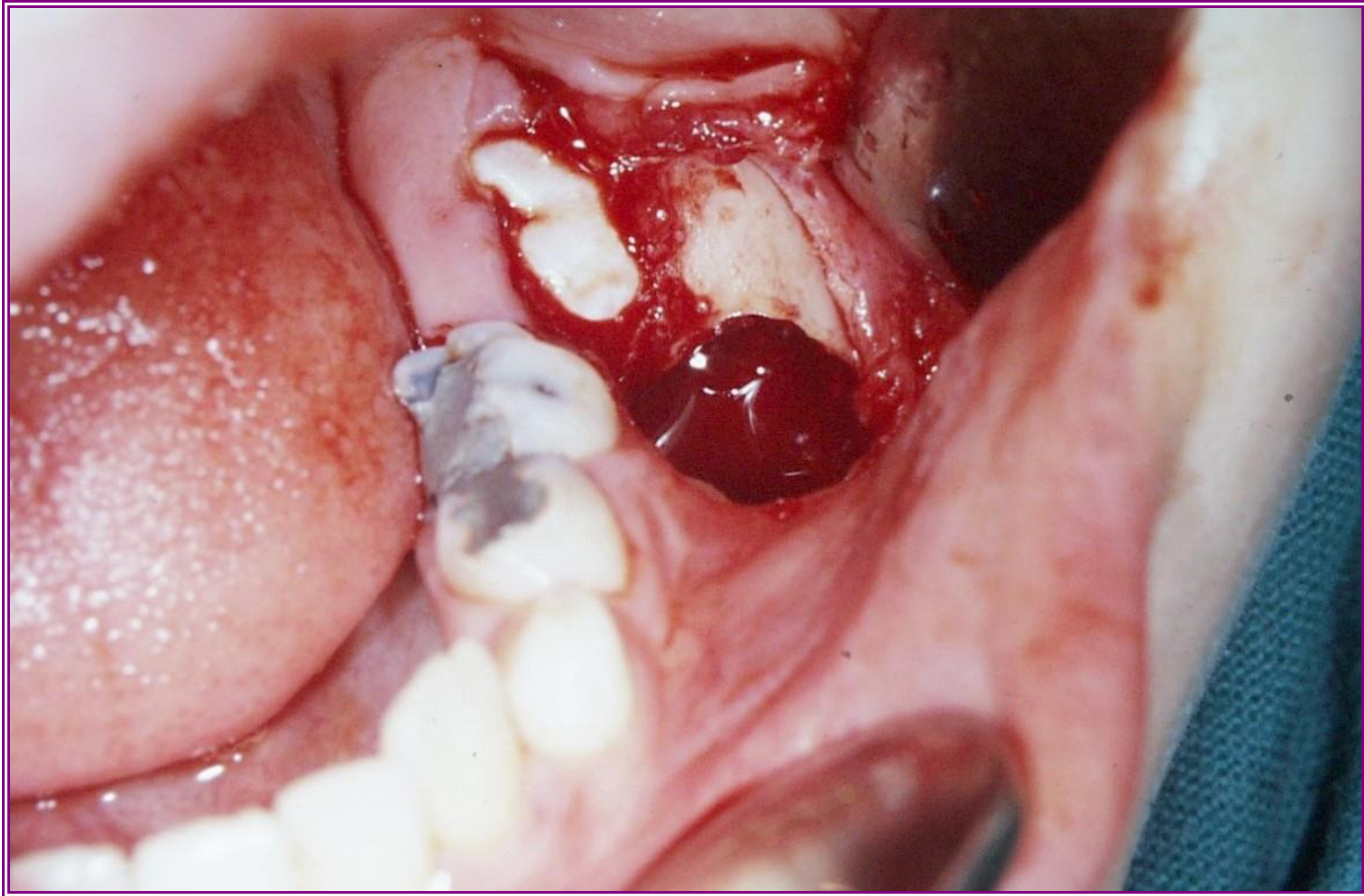


An operative extraction with separation was performed on the impacted lower first molar

The pathohistological analyses confirmed the preliminary diagnoses i.e. impacted lower first molar with atypical shape and composition

O
P
E
R
A
T
I
V
E

E
X
T
R
A
C
T
I
O
N



Intra operative view after the performed operative extraction of the impacted lower first molar

The orthodontic treatment followed after the surgical procedure and included mobile orthodontic appliance which in 8 months placed the second lower molar in the position of the first lower molar

C
O
N
C
L
U
S
I
O
N

Imperative during the treatment of the impacted teeth is multidisciplinary cooperation between the oral surgeons and orthodontics as two different dental specialties