

UNIVERSITY "Sts. CYRIL AND METHODYUS"
FACULTY OF DENTISTRY



UNIVERSITY DENTAL CLINICAL CENTRE " St. PANTELEJMON "

DEPARTMENT OF ORAL SURGERY
DEPARTMENT OF ORTHODONTICS



SKOPJE, R. MACEDONIA

FOLLICULAR CYST AT THE MANDIBULAR FIRST MOLAR - case report -

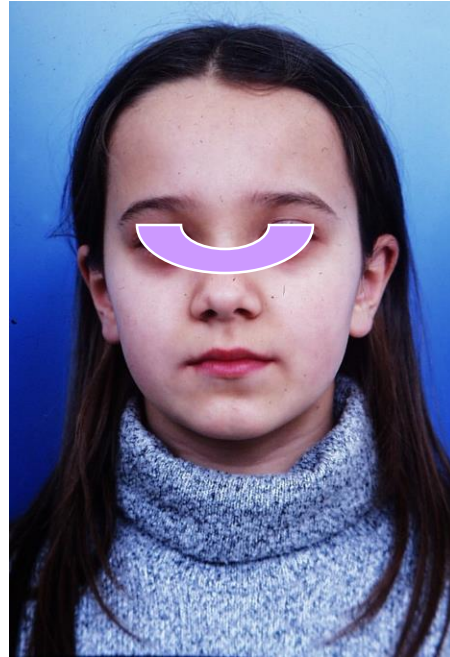
DIMOVA Cena, TRPKOVSKA-STEFANOVA Maja,

JANEV Edvard, EVROSIMOVSKA Biljana,

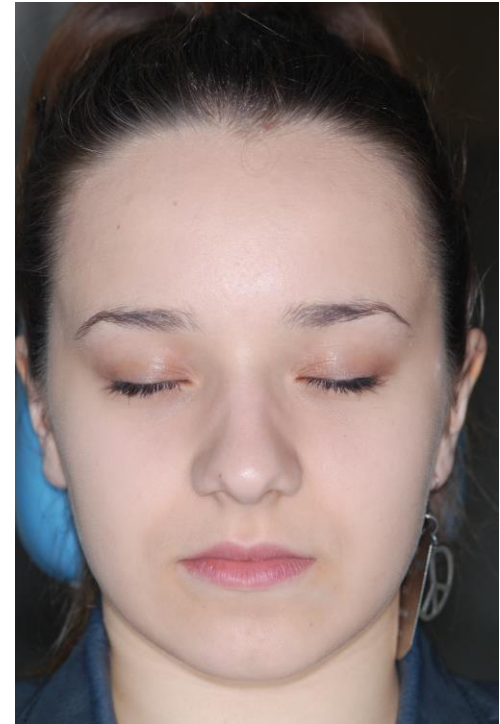
KOVACEVSKA Ivona, STOJANOSKA R. Sonja

The aim of the study is to show follicular cyst at the lower first molar in 10 years old girl with dentitio tarda

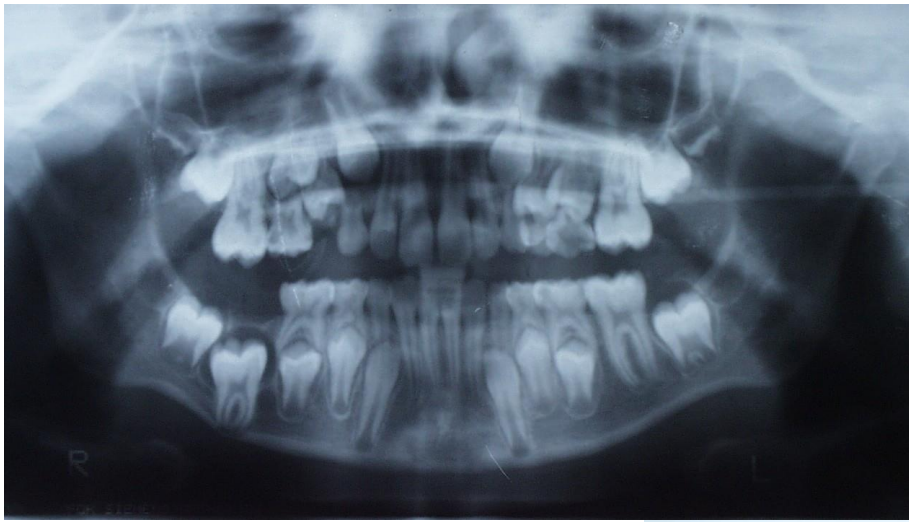AIM
AIM



AGE : 10 years

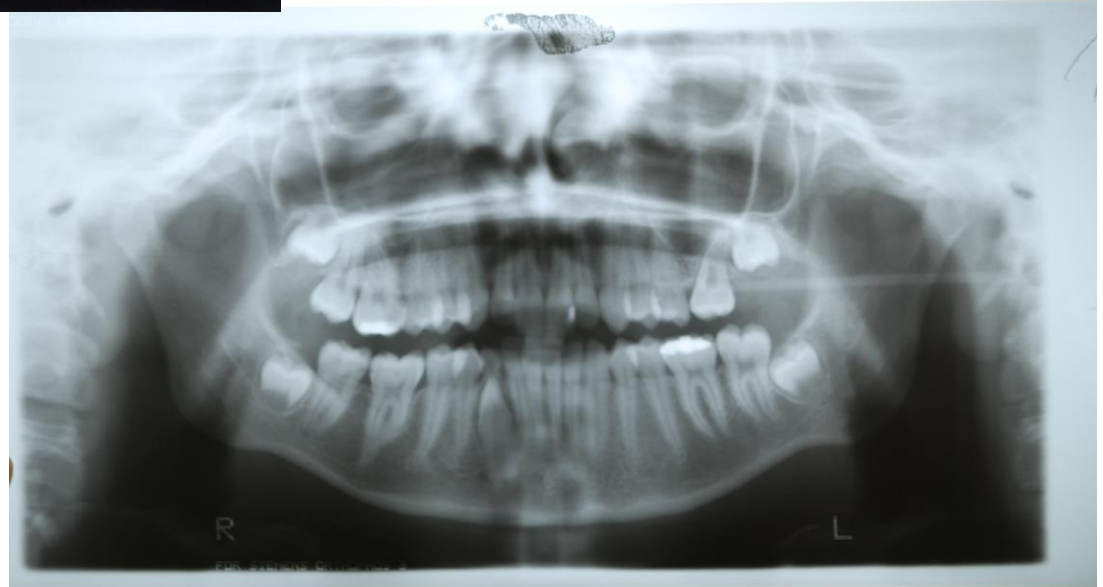

AGE : 16 years



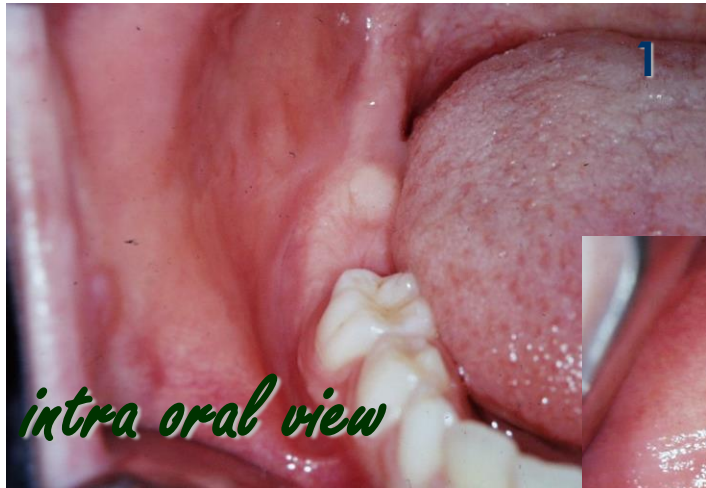before the treatment

X-ray
X-ray

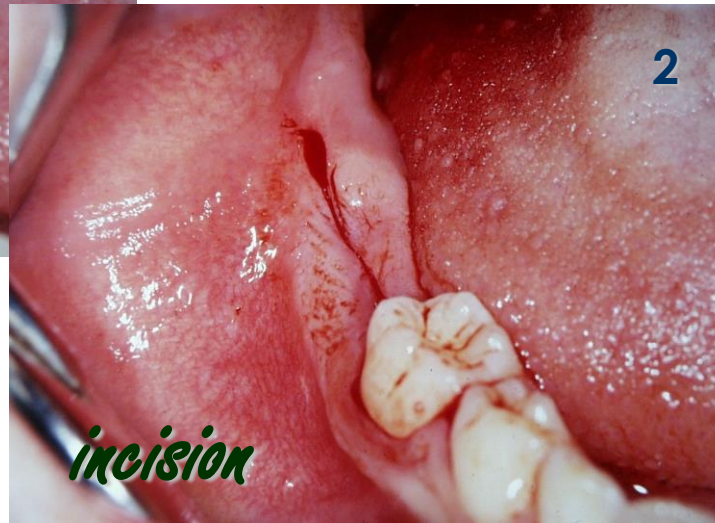

after the treatment

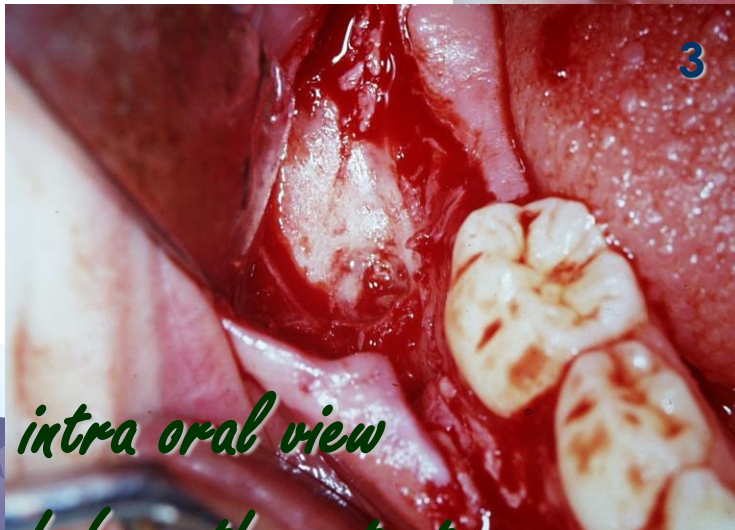OPERATIVE TREATMENT



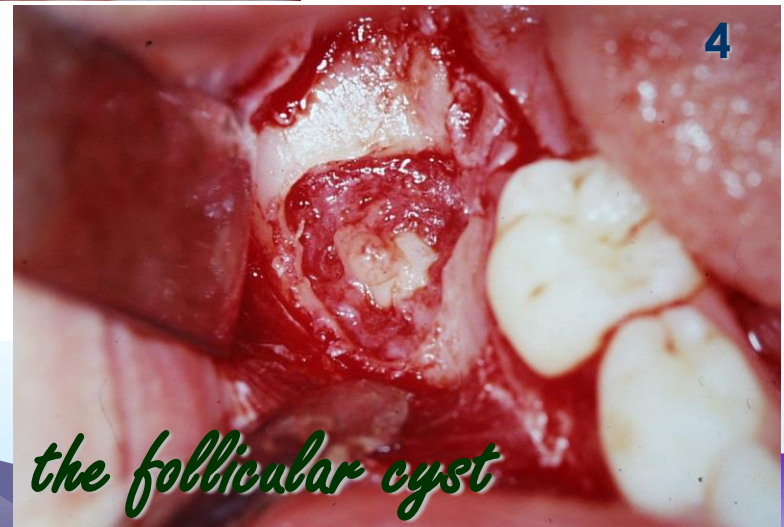*intra oral view
before the treatment*



incision

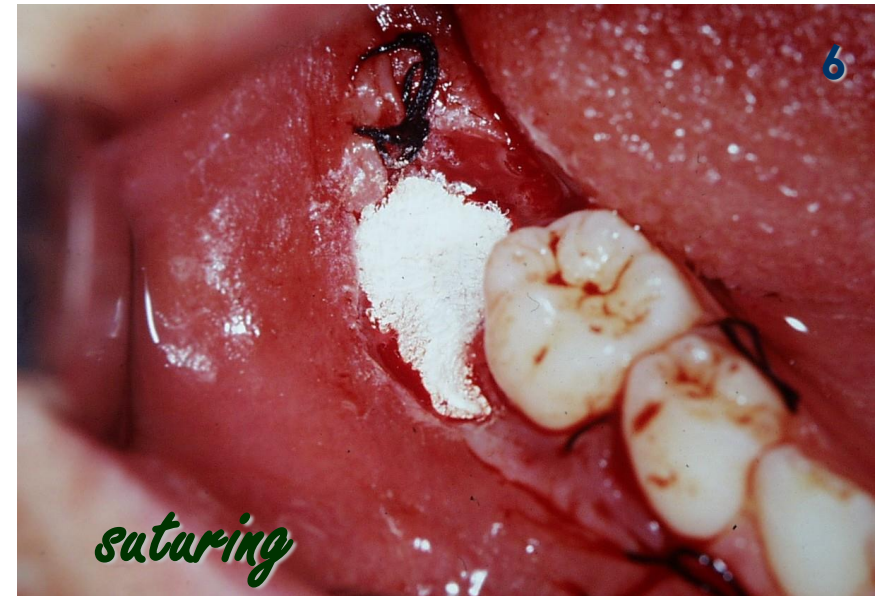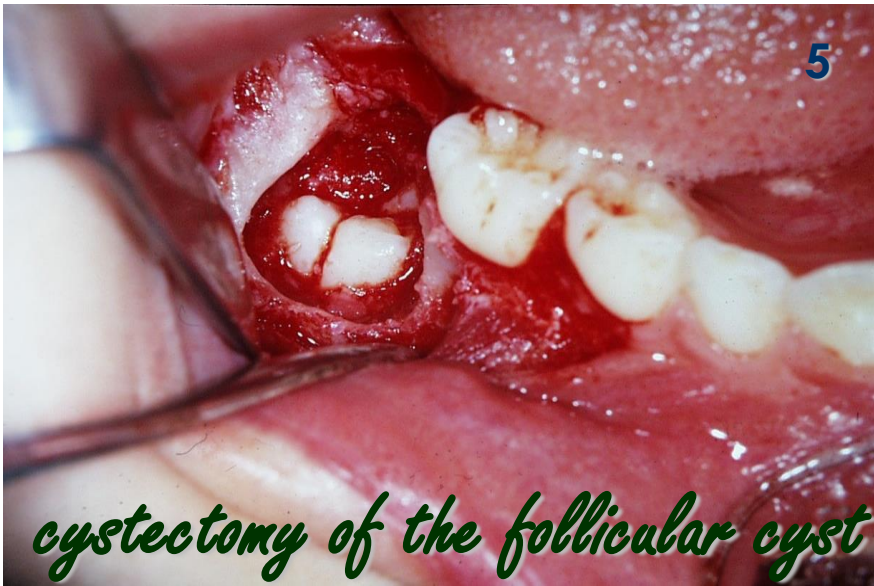


*intra oral view
before the osteotomy*



the follicular cyst

OPERATIVE TREATMENT



a cystectomy was first performed

ORTHODONTIC TREATMENT

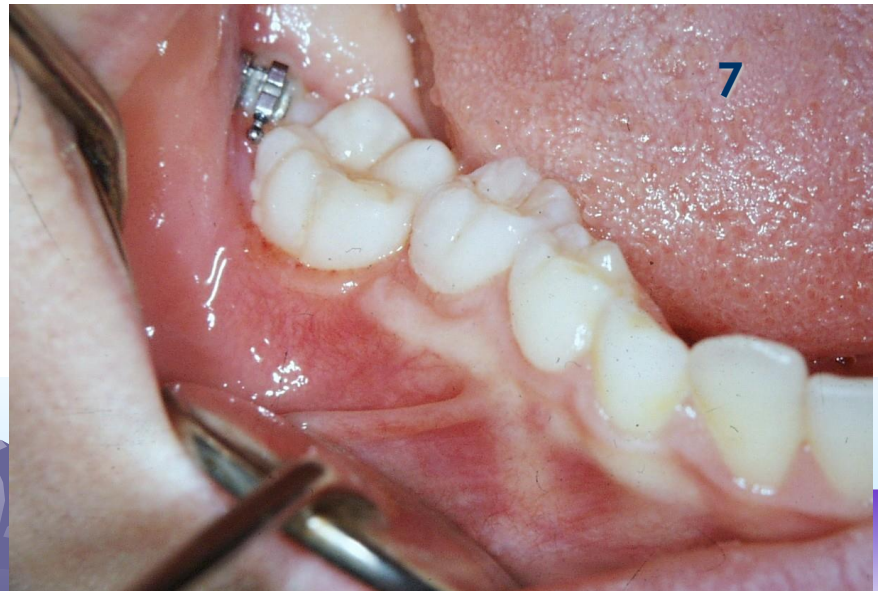Orthodontic treatment included brackets on the first and the second molar in the mandible

Also a maxillary mobile active orthodontic appliance with distal hooks was part of the treatment, and was used for elastic ligating with the brackets

ORTHODONTIC TREATMENT

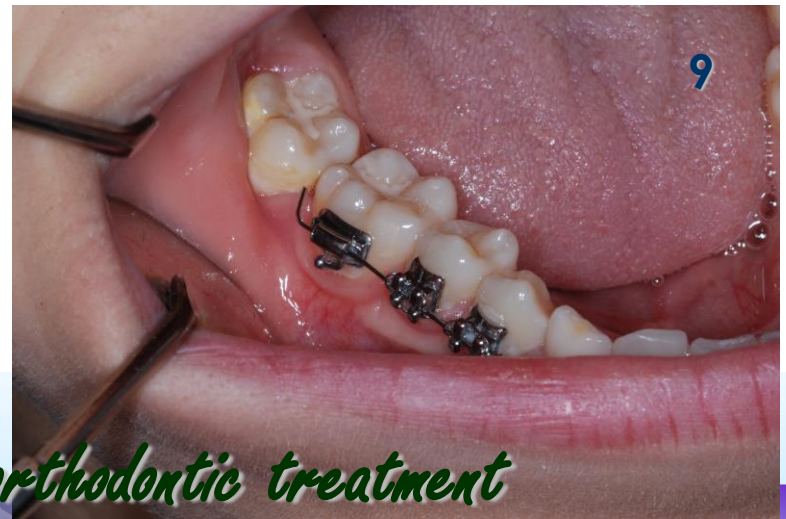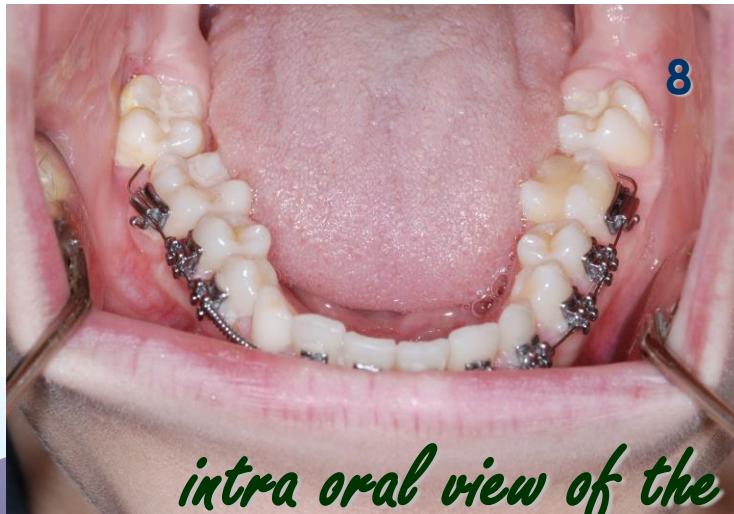
A selective stripping was performed on the lower second deciduous molar.

After 15 months treatment, the teeth were aligned and positioned in the dental arches



CONCLUSION

The interdisciplinary cooperation between the orthodontists and the oral surgeons is necessary during and while planning the treatment



intra oral view of the orthodontic treatment