

Endovascular and surgical treatment of giant pelvic tumor

Mitrev Z., MD FETCS; Anguseva T., MD; Milev I., MD; Zafiroski G., PhD MD

Center for Cardiosurgery, “Filip the II”, Skopje, Macedonia



Cardiosurgery - Skopje



Background

Giant cell tumor is an osteolytic tumor arising from epiphysis commonly seen in young adults

- **Though it is benign it is locally aggressive or malignant**
- **There is slightly female predominance.**
- **Giant cell tumors represent 5% of bone neoplasm's.**
- **They typically occur in patients between the age of 20 and 40 years**
- **Location – distal femur (most common); distal radius (most aggressive); sacrum and pelvis (very rare)**



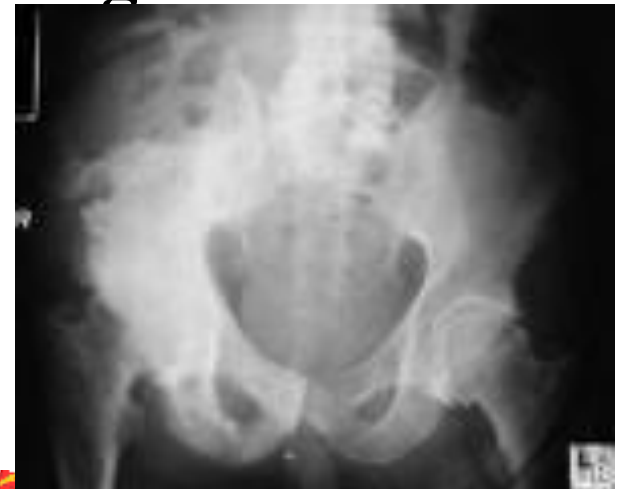Clinical features

- **Swelling**
- **Mild pain, usually pain is not presenting feature**
- **Skin over swelling is stretched**
- **No dilated veins**
- **Tenderness is moderate**
- **Egg shell cracking sensation may be present**
- **Limitations of joint movement is not seen till late stage**
- **Joint is usually not invaded**
- **Pathological fracture is usually a late feature**



Radiology

- **Osteolytic area is seen near epiphysis**
- **Cortex is expanded**
- **No periosteal bone formation is seen**
- **Thin septa of bone traverses the interior and produces a soap bubble appearance**
- **Cortex may be disrupted in late stage**



Campanacci's grading

- **Grade 1 cystic lesion**
- **Grade 2 cortex is thin but not perforated**
- **Grade 3 cortex is perforated with extension into soft tissues**
- **Giant cell tumors usually are solitary lesions; however, 1% to 2% may be synchronously or metachronously multicentric.**

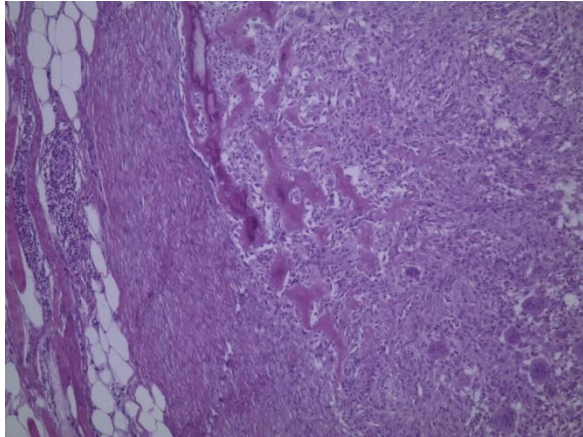


Pulmonary metastases

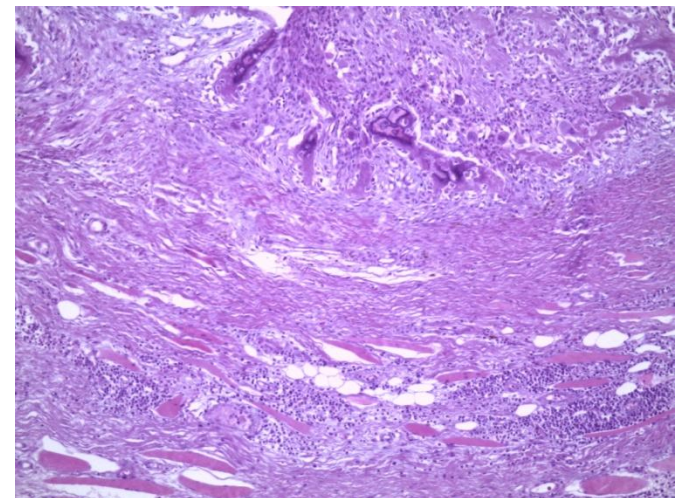
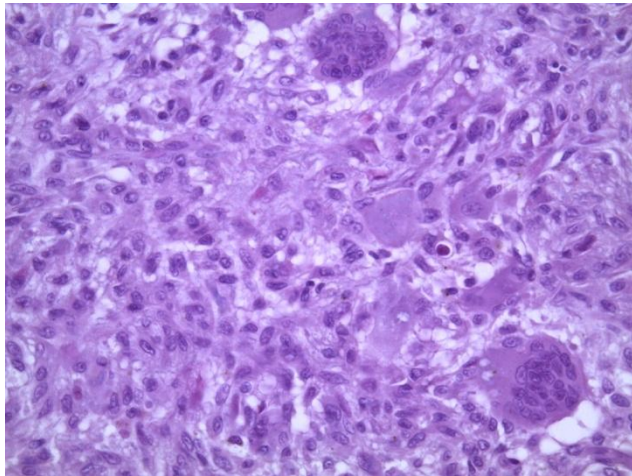
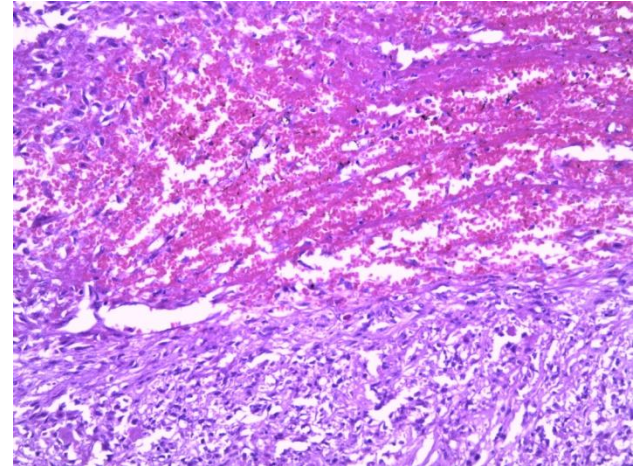
- **The overall mortality rate from the disease, for patients with it, is approximately 15%. Patients with recurrent lesions or primary lesions that appear aggressive on X-ray, graphically are at higher risk for pulmonary metastases.**
- **Malignant giant cell tumors represent less than 5% of the cases and are classified as primary or secondary**
- **Primary malignant giant cell tumors are extremely rare**



Microscopically



Giant cell tumors are composed of many multinucleated giant cells (typically 40 to 60 nuclei per cell) in a sea of mononuclear stromal cells.



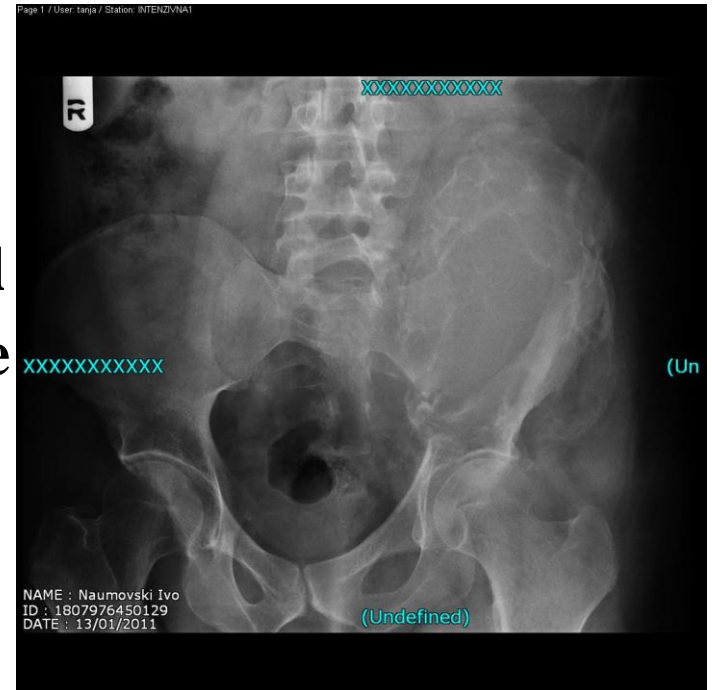
Principles of tumor treatment

- **Tumor is invasive and aggressive**
- **It commonly reoccurs, and may become malignant after unsuccessful removal**
- **Recurrence is treated with enblock excision**
- **Possible bleeding due to rich neo-revascularization**
- **Pre-operative angiography and neo-vascular net coiling**
- **Enblock excision - eroded tumor cortex and soft tissue indurations**
- **Usage of adjuvants – bone cement, for killing the remaining tumor cells**
- **Usage of bone grafts**



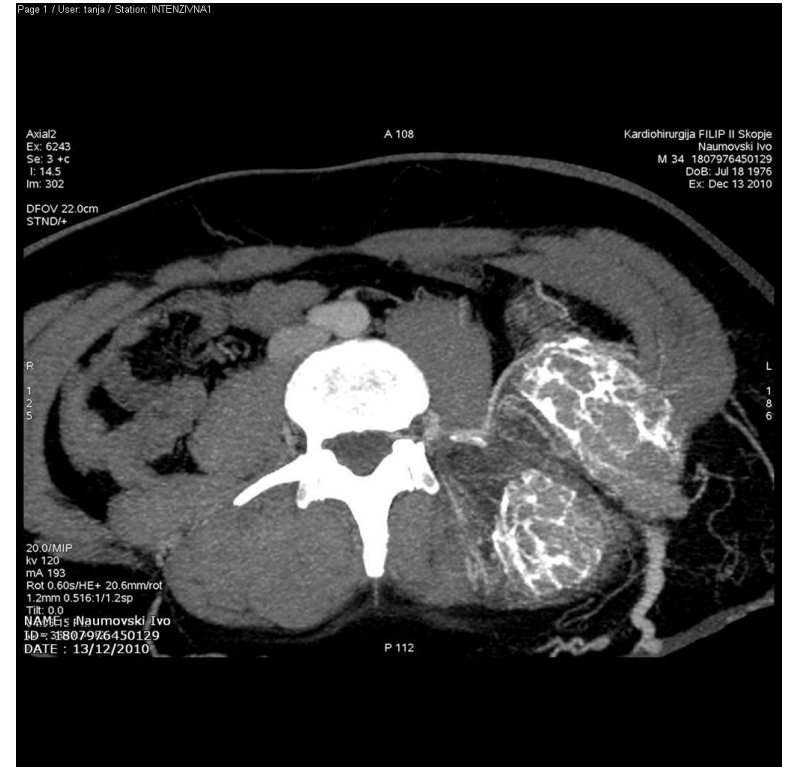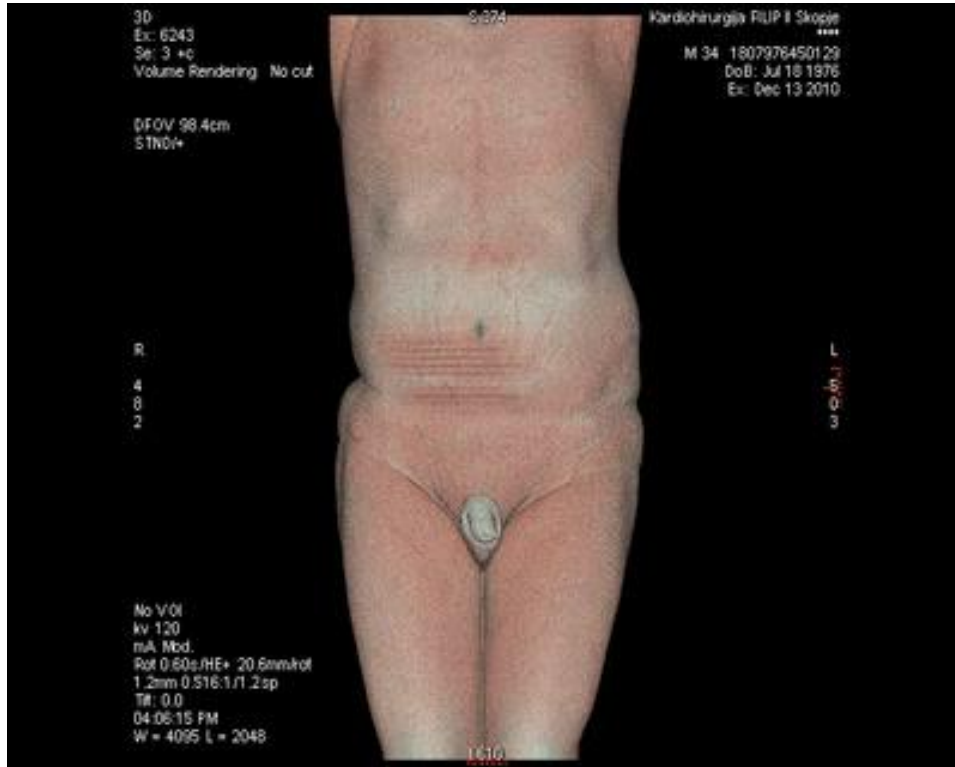
Case report - clinical manifestation

- **Giant cell tumour in 34 year old man.**
 - 2-year history of worsening low back pain that radiated down his left leg**
 - 20kg loosing on weight**
 - 2 years treated as discus hernia**
- **X Ray – typical for pelvic giant cell**
- **64 MSCT scan – giant tumor of the rich neo-vascularisation**
 - CT-guided biopsy confirmed the diagnosis**

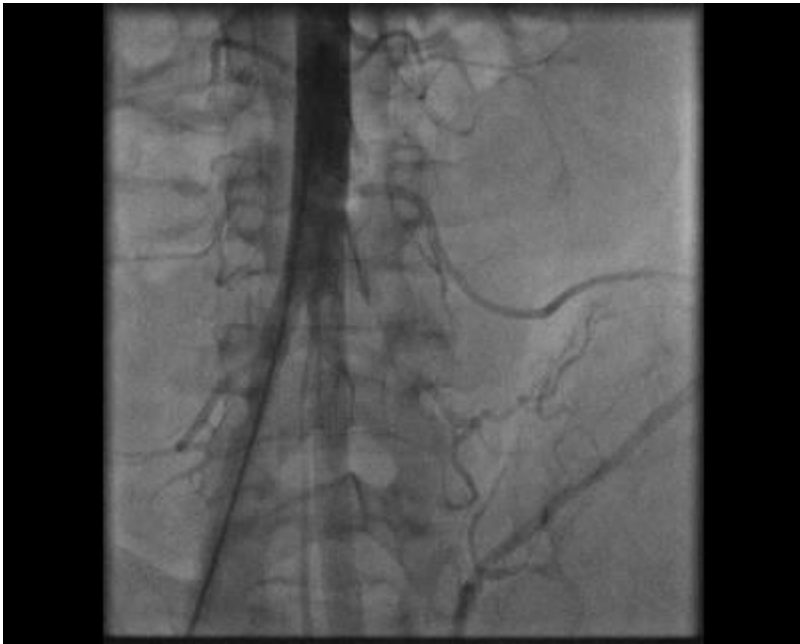


Pelvis

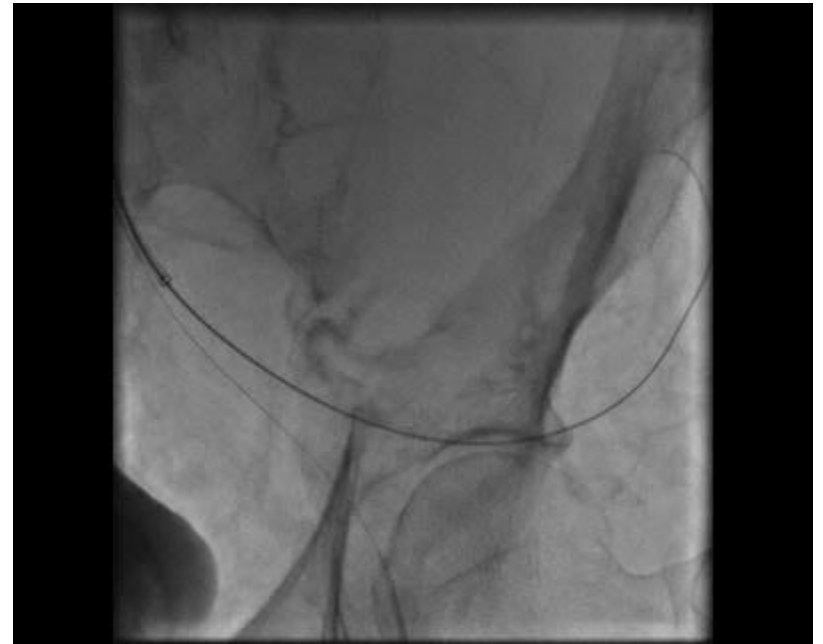
- **GCT often vascular**
 - Pre-op angiography
 - ? embolization



Angiography and interventional coiling of the neo-vascular net of a.iliaca int.l.sin



Diagnostic

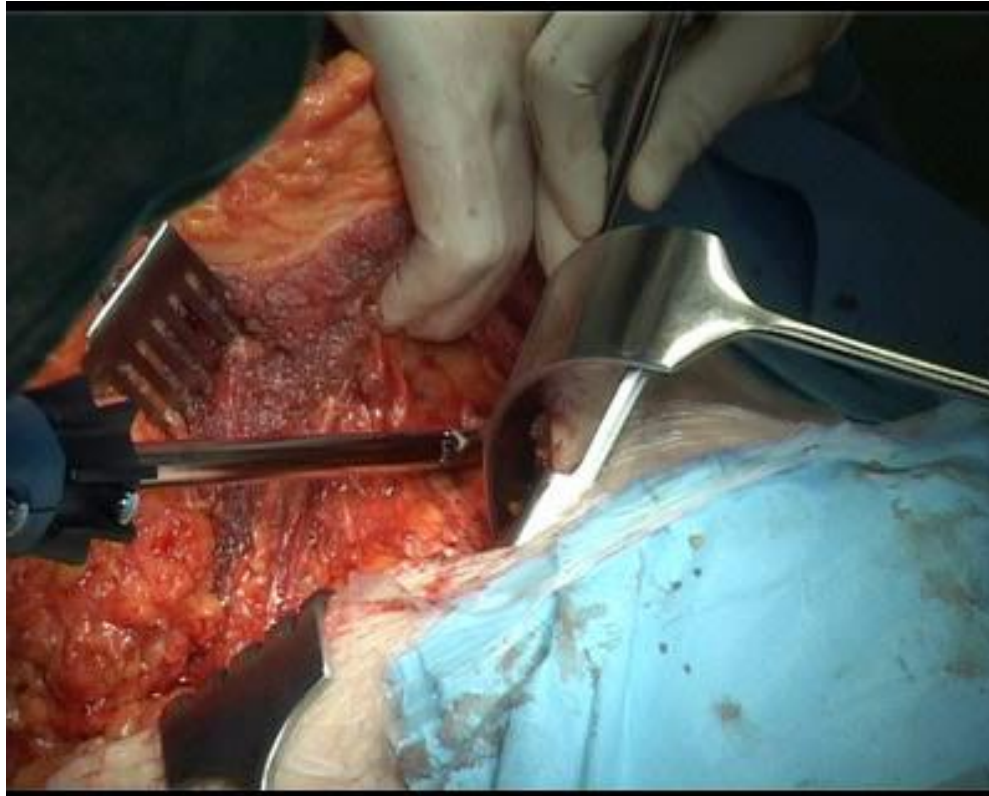

Intervention

Due to large lumen of the pathologic vessels – coiling was possible in combination with bio-glue Artex –vascular sielant



Surgery – team’s approach - vascular and orthopaedics



**Vascular surgeon performed vascular preservation of the operative field
The tumor was eradicated by combination of enblock resection and curettage.**

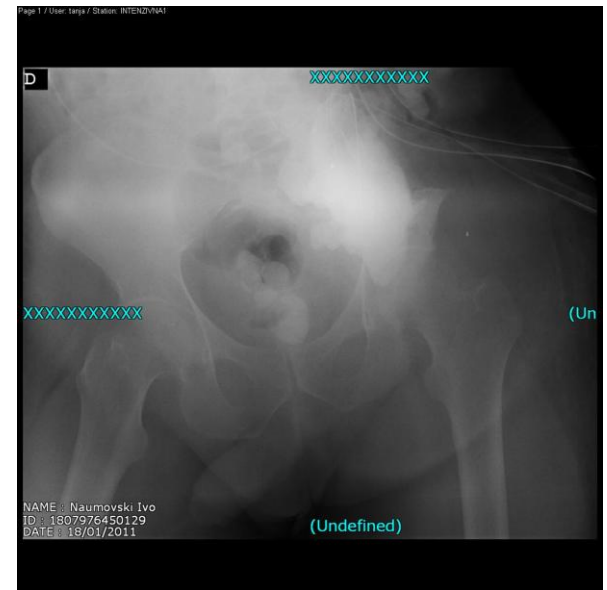Bone cement was used for remodeling of sacral and illeal bone as well as killing of residual tumor cells

At the end two Kirschner’s needles were used for strengthening of the bone cement

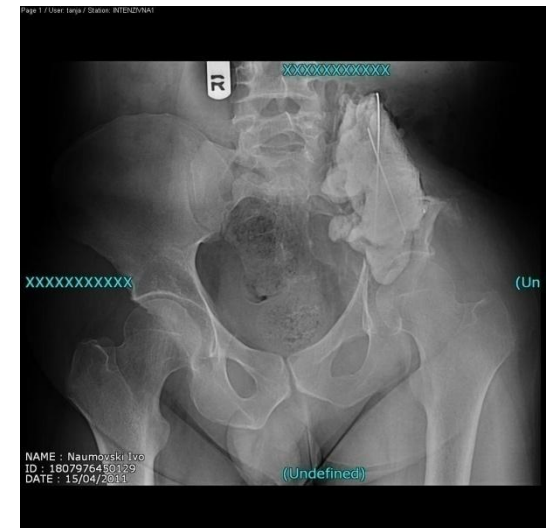

Postoperative period

- **Post-operative period**
- **1,5 l. blood lost (need of 6 EK)**
- **Early mobilization**
- **Complete functional recovery of the left leg**
- **Control X Ray of the lung b.o.**
- **Follow up period 9 months**



1st postop. day



After 3 months



Summary

- **Locally malignant**
- **Affects young adults, high degree of invalidity**
- **Giant cells are characterized with a rich neo-vascular net with topic position on pelvic bones**
- **Multidisciplinary approach in such cases results with excellent postoperative success, even in patients with progressive disease stadium**
- **Pre-operative coiling of the neo-vascular net is very important for intra-operative and post-operative bleeding prevention**

