

8th

Society of
Coloproctology
of Yugoslavia 
Founded in 1997



SCHOOL OF MEDICINE
UNIVERSITY IN BELGRADE



CLINICAL CENTER OF SERBIA

BIANNUAL INTERNATIONAL SYMPOSIUM OF COLOPROCTOLOGY

October 11-13, 2012
SAVA CENTER, BELGRADE, SERBIA

www.scpy.org

Symposium President: Zoran Krivokapić

President of SCPY: *Milan Breberina*



Organising committee:

President: *Velimir Marković*



M. Popović

G. Barišić

S. Antić

R. Lazović

I. Tripković

M. Bogar

M. Čeranić

S. Noel

R. Hinić

A. Dragičević

N. Jurošević

M. Kostić

Ž. Madžić

A. Karađozov

A. Ivanjиков

A. Sekulić

I. Dimitrijević

J. Petrović

B. Kovačević

J. Tejić

Scientific committee:

President: *Dragoslav Stevović*



M. Petrović

B. Gudurić

V. Bumbaširević

Đ. Bajec

N. Lalić

M. Milićević

D. Kecmanović

V. Čuk

M. Breberina

N. Stanković

M. Micev

D. Radovanović

Đ. Šaranović

G. Stanojević

R. Cvijanović

V. Đukić

Z. Krivokapić

L. Matija

LIST OF SELECTED PAPERS - POSTER PRESENTATION

| | | |
|------|-----------------------|-----------------------------------------------------------------------------------------------------------------------------------------------------------|
| P-1 | Franco Mitrović | Treatment of Rectal Cancer: A Clinical Study in the Period 2006-2011 |
| P-2 | Siniša Maksimović | Prognostic Significance of Mucinous Carcinoma of Colon and Rectum: Our Clinical Studies |
| P-3 | Dejan Dabić | Relationship Between Hereditary Factor and Colorectal Carcinoma - 5 Year Analysis in District General Hospital |
| P-4 | I. Đurišić | Surgical Treatment of Colorectal Cancer Liver Metastases |
| P-5 | M. Žegarac | Surgical Treatment of Colorectal Liver Metastasis After Neoadjuvant Chemotherapy |
| P-6 | Bratislav Trifunović | Incidence of Anastomotic Dehiscence After Rectal Resection |
| P-7 | Srdan Marković | Validity of Revised Bethesda Guidelines for Identification Microsatellite Instability in Unselected Colorectal Cancers in Serbian Patients |
| P-8 | Zorka Milićević | p53 and its Isoforms in Colorectal Cancer |
| P-9 | Zorka Milićević | Characterization of CD54 Glycoprotein Expression in Colorectal Cancer |
| P-10 | Miroslav Cvetanović | Treating Synchronous and Metachronous Adenocarcinomas of the Large Intestine – Our Experience |
| P-11 | Nataša Nejković | Case of Leptosuccin Induced Malignant Hyperthermia in Patient With Rectal Cancer |
| P-12 | Branko Branković | Comparative Analysis of Oxidative Stress Markers in Colorectal Cancer Postoperative Material – The Role in Prognosis And Treatment |
| P-13 | Ján Šimo | Intraluminal Presentation of Endometrioid Cancer Metastasis |
| P-14 | Aleksandar Sekulić | Neoadjuvant Therapy in a Gastrointestinal Stromal Tumor of The Rectum: Report of a Case |
| P-15 | Jugoslav Đeri | Dehiscence of Stapler Anastomosis in Colorectal Surgery in Patients With and Without Protective Ileostomy |
| P-16 | Stefan Neagu | The “Modern” Technique of Abdominoperineal Resection of the Rectum is in Fact so Old |
| P-17 | Urska Marolt | Long-Term Versus Short-Term Neoadjuvant Treatment for Patients With Locally Advanced Rectal Cancer in the Lower Two Thirds of Rectum |
| P-18 | Miran Koželj | Protective Stoma Type and Timing of Stoma Closure Following Low Anterior Rectal Resection do Not Influence the Rate of Complications: Retrospective Study |
| P-19 | Aleksandra Dragičević | Comparative Study of a Colon Epithelium Tissue by IR, UV-VIS and Opto-magnetic Spectroscopy |
| P-20 | Momčilo Stošić | Reconstruction of Anal Sphincter Injury During Childbirth - A Personal Experience |
| P-21 | Maja Pavlov | Radical Retropubic Prostatectomy, Abdominoperineal Excision of The Rectum and Bladder-Sparing Procedure for Locally Invasive Rectal Cancer |
| P-22 | Goran Tošović | Ileostomy in Modern Surgery |

| | | |
|------|----------------------------|-----------------------------------------------------------------------------------------------------------------------------------------------|
| P-23 | Goran Stanojević | Early Experience With the Compression Anastomosis Ring (CARTM 27) in Rectal Resection |
| P-24 | Constantinos Avgoustou | Acute Abdomen Due to Sigmoid and Caecal-Ascending Colon Volvulus |
| P-25 | Sokol Bilali | Surgical Treatment of Chronic Gluteal Hidradenitis Suppurativa |
| P-26 | Maja Sofronievska Glavinov | Laparostomy After a Radical Cystectomy Due to Invasive Urothelial Sarcomatoid Carcinoma of The Bladder - Case Report |
| P-27 | Slobodan Ristovski | Synchronous Tumors of Bladder and Colon- Case Report |
| P-28 | Milena Šćepanović | Early prediction of anastomotic leakage after open colorectal resections |
| P-29 | Nataša Čolović | Neutropenic Colitis After Treatment of Acute Myeloid Leukemia With Cytosine Arabinoside and Daunomycin |
| P-30 | Nataša Čolović | Primary Diffuse Large B Cell Non-Hodgkin Lymphoma of The Colon |
| P-31 | Slobodan Arandelović | Delayed Perforation of the Sigmoid Colon After Blunt Abdominal Trauma in a Patient With Multiple Injuries - A Case Report |
| P-32 | Ivan Ilić | Laparoscopic Right Colectomy Hand Assisted for Voluminous Polyp of The Ascending Colon |
| P-33 | Slobodan Arandelović | Experience in Iatrogenic Colonic Perforation Caused by Colonoscopy - Case report |
| P-34 | Rade Miletić | Submucous Lipoma of Colon Cancer With Symptoms of Occlusion and Bleeding (Case Review). |
| P-35 | Jelena Petrović | Surgical Solution of an Anterior Abdominal Wall and Parastomal Hernia after the Complication of Surgery with End Colostomy – Report of a Case |
| P-36 | Dragan Mihajlović | Diverticular Bleeding: Successful Localization and Management |
| P-37 | Vanja Pecić | Treatment Modality of Necrotizing Fasciitis |
| P-38 | Radovan Veljković | Glyceryl-Trinitrate (0.2%) Ointment - Chronic Anal Fissure – 12-year Results |
| P-39 | Svetozar Sečen | Diltiazem (2%) Ointment - Chronic Anal Fissure – 10-year Results |
| P-40 | Siniša Crnogorac | Connection Between Increased Blood Flow in Haemorrhoidal Arteries and Haemorrhoidal Disease |
| P-41 | Aleksandar Gluhović | Drainage Setton Procedure in Treatment of Paranal Fistula |
| P-42 | Zagor Zagorac | Spinal vs. General Anesthesia for Haemorrhoidectomy with LigaSure™ |
| P-43 | Zagor Zagorac | Treating Anal Fistula With the Anal Fistula Plug - Our Experience |
| P-44 | Božidar Bojić | Efficacy of Diosmin and Band Ligation in the Treatment of Haemorrhoidal Disease |
| P-45 | Miljan Čeranić | Diosmine in the Management of Bleeding Nonprolapsed Haemorrhoids |
| P-46 | Petar Petricević | Open Vs. Semi-Closed Hemorrhoidectomy and Postoperative Pain |
| P-47 | Ivan Kostić | Closed Haemorrhoidectomy-Ferguson-Our Experience |

| | | |
|------|----------------------|------------------------------------------------------------------------------------------------------------------------------------------------|
| P-48 | Aleksandar Karagozov | Presacral, Retrorectal Dermoid Cyst in a Female Patient - Case Report |
| P-49 | Ivan Dimitrijević | Long-Term Oncological Outcomes of Multivisceral Resections in Patients Treated for Locally Advanced Colorectal Carcinoma |
| P-50 | T. Dragišić | Splenectomy in refractory phase of chronic recidivant thrombotic thrombocytopenic purpura (TTP) |
| P-51 | Zagor Zagorac | Outcome of Surgical Treatment for Patients with T4 Carcinoma of the Rectum Without Preoperative Radiation Therapy |
| P-52 | Momčilo Ristanović | 3-Phosphoglycerate Dehydrogenase Polymorphism in Patients with Colorectal Carcinoma |
| P-53 | Danijela Šćepanović | Local Recurrence Rates in Rectal Cancer Patients Treated With Preoperative Radiotherapy in the Time Before and After Total Mesorectal Excision |
| P-54 | Krasimir Ivanov | Laparoscopic Intersphincteric Resection - Indications and Contraindications |
| P-55 | Ljiljana Sokolova | Consumption of meet during adolescent period as a predictor for colorectal cancer |
| P-56 | Zuvdija Kandić | Treatment of Rectal Cancer in Casuistic Clinic for Abdominal Surgery, Clinical Centre of The University of Sarajevo (2006-2010) |
| P-57 | Miloš Popović | Use of Vacuum-Assisted Closure Device in a Disastrous Form of Open Abdomen and Stoma Site Infection: A Case Report |
| P-58 | Sokol Bilali | Distant Metastases in Patients with Local Recurrence of Rectal Cancer |
| P-59 | Milica Nestorović | Surgical Management of Lower Gastrointestinal Bleeding |

PRESACRAL, RETRORECTAL DERMOID CYST IN A FEMALE PATIENT - CASE REPORT

A. Karagjozov¹, I. Milev², S. Antovic¹, E. Kadri¹

¹Clinic of Digestive Surgery, Medical Faculty – Skopje

²Department of Surgery, Clinical hospital – Štip

The retrorectal tumors are well defined, classified and understood pathological entities in the literature but in practice they represent very unusual and infrequent pathology. We are presenting a case from the group of dermoid congenital retrorectal cysts which at first manifested itself clinically as inflammatous retrorectal cyst that had spontaneously ruptured in the postanal space with local (tumor, dolor, calor, rubor, function laesa and fluctuation) and systemic signs of infection (fever, rise temperature, leukocytosis). On physical examination there was typical postanal dimple which gives a picture of “double anus” on inspection. On DRE there was retrorectal soft tumor with compression of the anorectum. Diagnosis was confirmed with MRI and fistulography. After a palliative treatment for absceding cyst with incision, Penrose drainage and daily washings with antiseptic solutions the patient was transferred in specialized institution - the Clinic of Digestive surgery at the Medical Faculty in Skopje for definitive treatment. The operation was performed with the patient in jack-knife position with conventional preparing of the colon and prophylactic antibiotic regiment started preoperatively. An on table anoscopy was performed at first which showed typical mammilla at the internal opening of the fistulous communication of the cyst with the rectum about 3 cm above the posterior crypt of Morgagni. We started with excision of the external opening, and preceded with whole excision of the pericystic granulomatous tissue about 14 cm in length till the presacral point. The fistulous communication was excised completely and the rectum was sutured in two layers with separate sutures. The wound was laid open and the patient was discharged on the 5-th postoperative day. About one month the wound was treated with daily washings with antiseptic solutions and after that one month with only water. After two months the defecation is normal, the wound is sealed and there are no signs of inflammation and secretion locally. The retrorectal tumors are difficult for treatment as well as for diagnosis where even punctional biopsy is not recommended so they should be treated in specialized institutions by experienced surgeons from the moment of diagnosis to the definitive surgical treatment.

Keywords: retrorectal cyst, excision, fistulous communication

PRESACRAL, RETRORECTAL DERMOID CYST IN A FEMALE

PATIENT – CASE REPORT

Aleksandar Karagjov¹, Ilija Milev², Svetozar Antovic¹, Edzevit Kadri¹

¹Clinic of Digestive Surgery, Medical faculty - Skopje

² Department of Surgery, Clinical hospital - Štip
Republic of Macedonia

INTRODUCTION

The presacral or retrorectal space is a common site for embryologic remnants from which neoplasms and cysts may arise. This group of heterogeneous lesions is known as retrorectal tumors. The worldwide accepted classification of the retrorectal tumors is that proposed by Uhlig and Johnson is shown on Table 1 [1, 4, 9, 7]. The incidence is very rare. Cleveland Clinic reports 50 cases over a 55-year period. The Mayo Clinic estimates the incidence to be about 1 in 40000 hospital admissions. They reported 120 cases of which 66% were congenital, 12% neurogenic, 11% osseous and 11% were miscellaneous. Stewart and al. combined reports for a total of 301 retrorectal tumors of which 63% were congenital, 8% were inflammatory, 10% neurogenic, 7% osseous and 12% miscellaneous.

| Congenital | Osseous |
|--------------------------------------------------------------------------------|----------------------|
| Developmental cysts (epidermoid, dermoid, and mucus-secreting cysts; teratoma) | Osteoma |
| Chordoma | Osteogenic sarcoma |
| Teratocarcinoma | Simple bone cyst |
| Adrenal rest tumor | Ewing's tumor |
| Anterior sacral meningocele | Chondromyosarcoma |
| Duplication of rectum | Aneurismal bone cyst |
| | Giant cell tumor |
| Inflammatory | Miscellaneous |
| Foreign body granuloma | Metastatic carcinoma |
| Perineal abscess | Liposarcoma |
| Internal fistula | Lymphangioma |
| Retrorectal abscess | Lipoma |
| Chronic infectious granuloma | Fibroma |
| | Fibrosarcoma |
| | Leiomyoma |
| | Leiomyosarcoma |
| | Hemangioma |
| | ... |

Table1

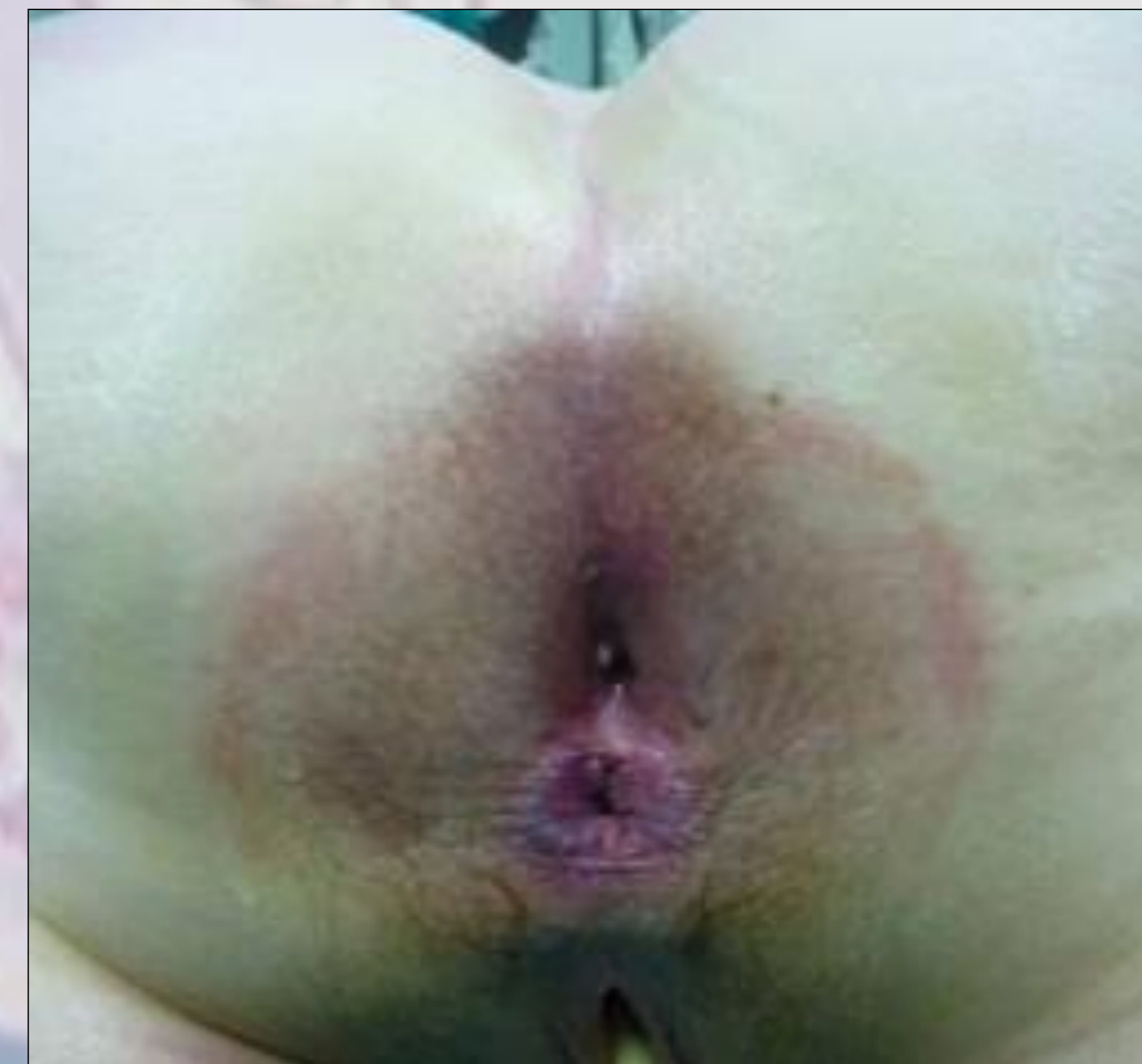

Fig. 1 "Double anus"

The symptoms of retrorectal tumors are mostly related to the size and complications such as malignisation [6] and infection. They are mainly: pain, local and systemic signs of infection and signs of recurrent perianal suppuration. Interference with pelvic outlet may lead to constipation, incontinence or dystocia [15]. Disturbances to the bladder and urinary function can be due to damage to the innervation, pressure on the bladder, urethra or ureters. CNS manifestations in form of headaches and recurrent episodes of meningitis are characteristic for anterior sacral meningocele.

Examination begins with inspection of the perineal area where one should look for characteristic postanal dimple. On DRE solid mass overlain with intact mucosa should be well recognized, whereas cystic lesions may be felt as mucosal folds and may be missed if they are not infected. The examination should proceed with plain film, sigmoidoscopy and CT scan or MRI. Barium enema and fistulography then can be indicated. Endorectal ultrasonography is a very sensitive method in assessing the rectal wall involvement and pelvic floor muscle invasion.

The biopsy is only indicated if the lesion is inoperable because if the lesion is solid spreading of malignant cells may occur, if the lesion is cystic infection may be spread and with anterior sacral meningocele meningitis may occur.

Once the retrorectal tumor is diagnosed it should always be removed usually through posterior approach with the patient in prone jack-knife for low lesions or infected cysts [8, 14] or abdominal approach with the patient in the lithotomy position for high lesions (above S4 on the imaging technics or when the upper border cannot be assessed on DRE) [1, 2, 3]

Epidermoid and dermoid cysts belong in the group of the developmental cysts as a part of the congenital lesion that account for more than 50% of all retrorectal tumors. The majority of the developmental cysts is asymptomatic and may be missed on rectal examination due to low tension in the cyst. Epidermoid and dermoid cysts are result from defective closure of the ectodermal tube which results in inclusions of skin with or without accessory appendages. Both are lined with stratified squamous epithelium, well circumscribed with thin layer of connective tissue and fill with tick yellow-green fluid. The difference is that epidermoid cysts have no skin appendages. There is 30% rate of infection presenting as either as retrorectal abscess or mistakenly diagnosed as perianal fistula.

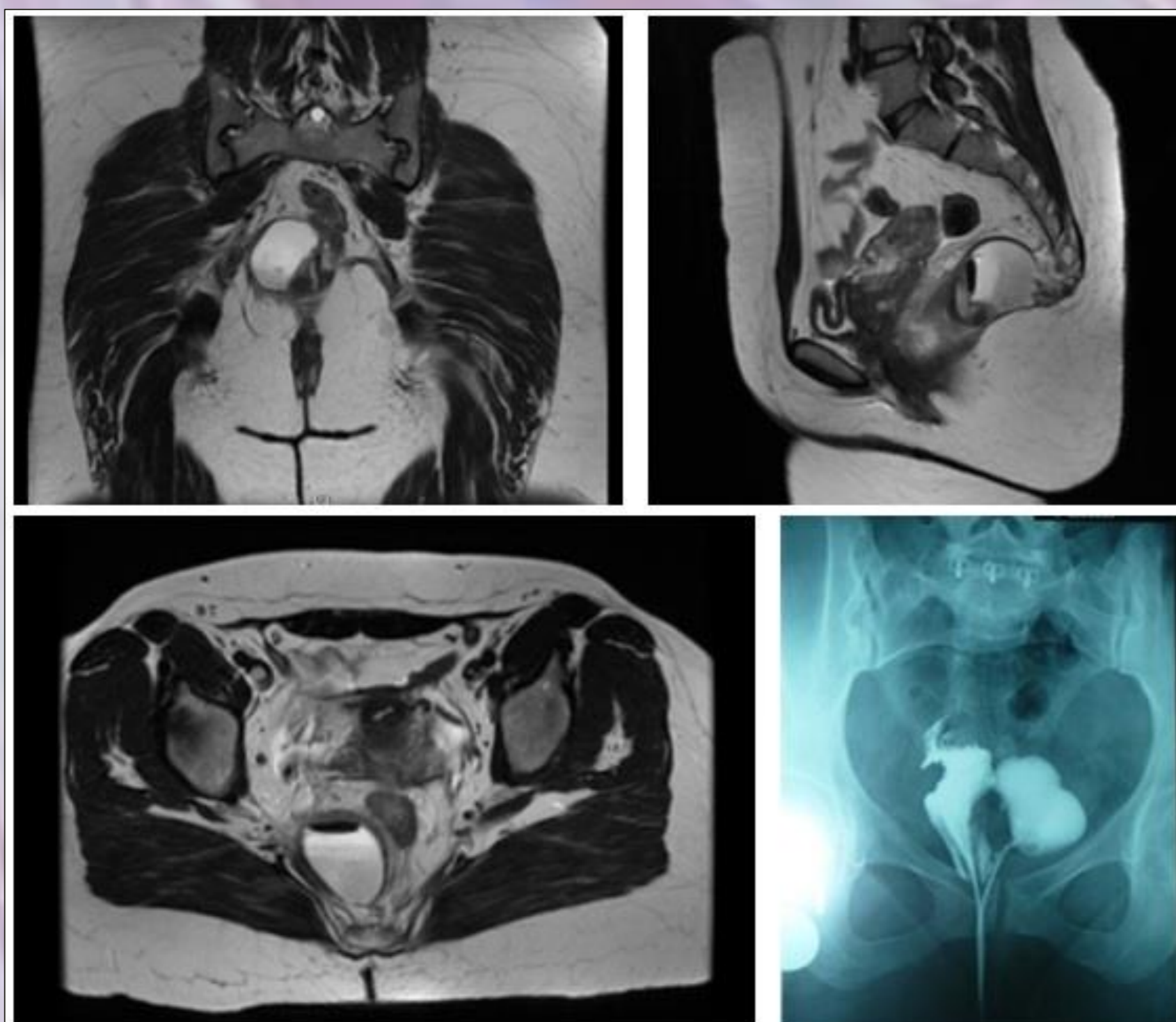


Fig. 2 MRI and fistulography

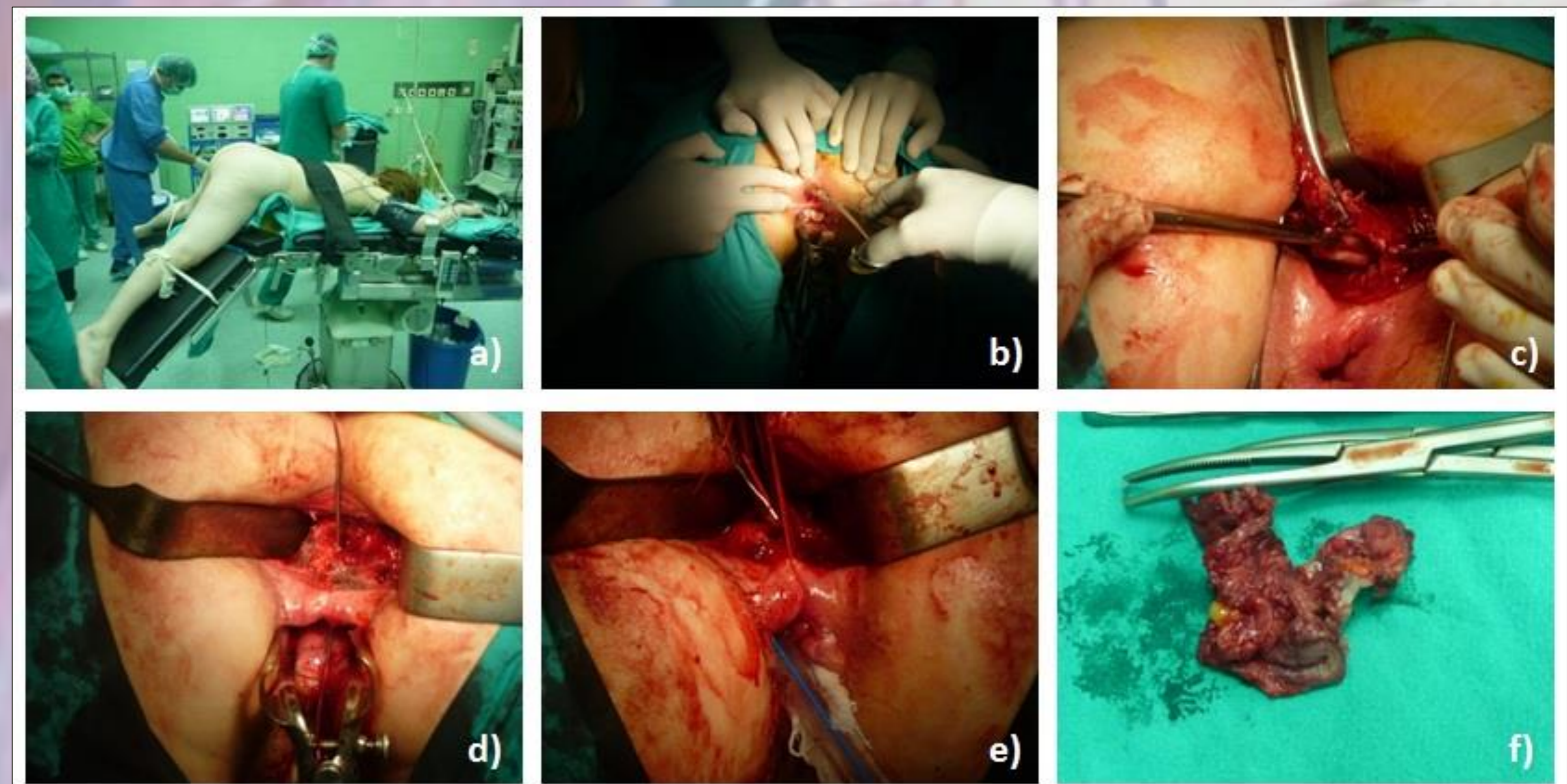


Fig. 3 Course of the operation

CASE REPORT

We are presenting 35 years old female patient who was first admitted to hospital with severe perianal and rectal pain, local signs of inflammation (tumor, dolor, calor, rubor, functio laesa and fluctuation) systemic signs of inflammation (fever, high temperature, leukocytosis) and typical so-called postanal dimple from which there was a leakage of suppurative exudate or pus. The DRE was very painful and soft tumor can be felt in the retrorectal space with intact mucosa over it. The symptoms were present about one week and the patient had no trouble before in her life. The leaking of pus started two days before admission when she felt slight relief. At first the condition was understood as retrorectal, pre-coccygeal abscess which had spontaneously ruptured in the postanal region. The patient was started on broad spectrum antibiotics and incision with evacuation of the pus from the retrorectal space was done through the spontaneous opening in the postanal dimple. Penrose drain was installed in the pre-coccygeal space which was changed daily along with daily washings with antiseptic solutions. After seven days of such treatment the local and systemic signs of inflammation were subsided as well as the suppuration and the patient was discharged. On the controls the patient was complaining on occasional perianal pain. On inspection of the perianal region there are two openings anal and epithelized postanal opening which make a picture of "double anus" (Figure 1). On bimanual examination using DRE with probing of the postanal opening the probe goes deep in the postanal pre-coccygeal and presacral region. There is constant drainage of serosanguineous fluid from the postanal opening as a sign of fistula formation and persisting tumor in the presacral space on DRE with partial compression of the anorectum. In the meantime MRI and fistulography were done that showed cystic tumor in the retrorectal, presacral space with minor communication with rectum (Figure 2). About 40 days after the first hospitalization the patient was sent on the Clinic of Digestive Surgery at the Medical faculty – Skopje for definitive treatment. Preoperatively the colon was prepared conventionally and prophylactic antibiotic regimen was started. In the operating room the patient was put in prone jack-knife position (Figure 3a) and on explorative anoscopy the internal opening of a fistula in the anorectum about 3 cm above midline posterior crypt of Morgagni was registered. The operation was started with excision of the perineal opening of the cyst (Figure 3b). The cyst is about 14 cm long and was liberated completely along with its capsule (Figure 3c, 3f) which enabled to visualize the fistulous canal which leads to the internal opening in the rectum (Figure 3d, 3e). The canal was excised with suturing the rectum in two layers first only the mucosa and then the muscle layer. The residual space after removing of the cyst was laid open and treated with daily washings with antiseptic solutions. The pathological finding at our Institute of Pathology is: CYSTA EPITELIALIS CONGENITA INFLAMATA with all characteristics for dermoid cyst included in the text of the finding. After two months the process of defecation is normal, the wound is sealed without signs of inflammation and secretion locally although the postanal dimple still exists (Figure 4).

CONCLUSION

The retrorectal tumors are well defined, classified and understood pathological entities in the literature but in practice they represent very unusual and infrequent pathology [5, 10, 13]. They are difficult for treatment as well as for diagnosis where even punctual biopsy is not recommended so they should be treated in specialized institutions by experienced surgeons from the moment of diagnosis to the definitive surgical treatment.

REFERENCES

- [1] P. H. Gordon, S. Nivatvongs: *Principles and Practice of Surgery for the Colon, Rectum and Anus*. 3rd Edition, Informa Healthcare USA, Inc., 2007.
- [2] S. C. Glasgow, D. W. Dietz: *Retrorectal Tumors*. Clin Colon Rectal Surg, 2006. 19(2): p. 61-68.
- [3] K. Bullard Dunn: *Retrorectal Tumors*. American Society of colon and rectal surgeons.
- [4] B.E. Uhlig, R.L. Johnson, *Presacral tumors and cysts in adults*. Dis Colon Rectum, 1975. 18(7): p. 581-596.
- [5] R. J. Jackman, P. LeMon Clark III, N. D. Smith: *RETRORECTAL TUMORS*; JAMA, 1951. 145(13): p. 956-962.
- [6] Z. Krivokapic, I. Dimitrijevic, G. Barisic, V. Markovic, M. Krstic: *Adenosquamous carcinoma arising within a retrorectal tailgut cyst: report of a case*. World J Gastroenterol, 2005. 11(39): p. 6225-6227.
- [7] G. Cerullo, D. Marrelli, B. Rampone, C. Miracco, S. Caruso, Di M. Marianna, M. A. Mazzei, F. Roviello: *Presacral ganglioneuroma: A case report and review of literature*. World J Gastroenterol 2007. 13(14): p. 2129-2131.
- [8] J. M. Aranda-Narváez, A. J. González-Sánchez, C. Montiel-Casado, B. Sánchez-Pérez, C. Jiménez-Mazure, M. Valle-Carbajo, J. Santoyo-Santoyo. *Posterior approach (Kraske procedure) for surgical treatment of presacral tumors*. World J Gastrointest Surg 2012. 4 (5): p. 126-130.
- [9] H.-Y. Lin, Y.-H. Huang, T.-N. Tang, A. W. Chiu: *Presacral Schwannoma: A Case Report*. JTUA, 2004. 15(1): p. 24-27.
- [10] Shu-Wen Jao, R. W. Beart, R. J. Spencer, H. M. Reiman, D. M. Ilstrup: *Retrorectal tumors Mayo clinic experience, 1960-1979*. Dis of the Colon & Rectum, 1985. 28 (9): p. 644-652.
- [11] X. Serra Aracil, C. Go'mez Diaz, J. Bombardo' Junca, L. Mora Lo'pez, M. Alca'ntara Moral, I. Agyuavives Garnica, S. Navarro Soto: *Surgical excision of retrorectal tumour using transanal endoscopic microsurgery*. Colorectal Dis, 2010. 12(6): p. 594-595.
- [12] I. Hassan, E. D. Wietfeldt: *Presacral Tumors: Diagnosis and Management*. Clin Colon Rectal Surg, 2009. 22(2): p. 84-93.
- [13] R. B. McCarty: *Presacral Tumors*. Ann Surg, 1950. 131 (3): p. 424-432.
- [14] M. E. Abel, R. Nelson, M. L. Prasad, R. K. Pearl, C. P. Orsay, H. Abcarian: *Parasacrococcygeal approach for the resection of retrorectal developmental cysts*. Dis Colon Rectum, 1985. 28(11): p. 855-858.
- [15] C. W. Sobrado, M. Mester, O. S. Simonsen, C. R. Justo, J. N. deAbreu, A. Habr-Gama: *Retrorectal tumors complicating pregnancy. Report of two cases*. Dis Colon Rectum, 39(10), 1996, pp. 1176-1179.
- [16] N. Erkan, S. Aghdeniz, A. F. Polat, M. Yildirim: *Retrorectal Dermoid Cyst*. Chir Gastroenterol, 2006. 22: p. 55-57.
- [17] H. Dahan, L. Arrivé, D. Wendum, H.D. le Pointe, H. Djouhri, J. Tubiana. *Retrorectal Developmental Cysts in Adults: Clinical and Radiologic-Histopathologic Review, Differential Diagnosis, and Treatment*. Radio Graphics, 2001. 21: p. 575-584.

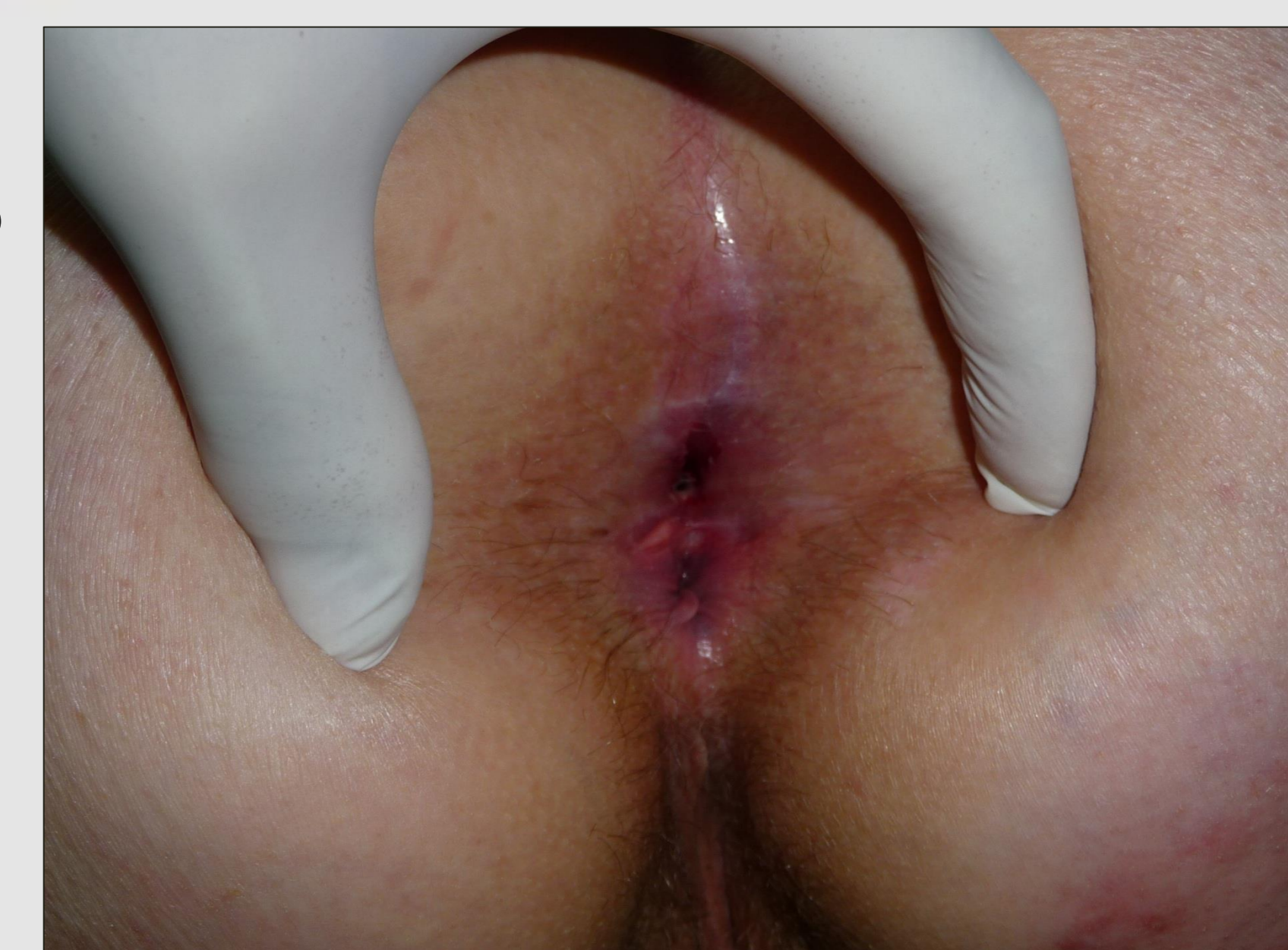

Fig. 4 Current condition