

EFFICACY OF INTRAPERITONEAL BUPIVACAINE ON PAIN RELIEF AFTER LAPAROSCOPIC CHOLECYSTECTOMY

Marija Toleska¹, Andrijan Kartalov¹, Biljana Kuzmanovska¹, Milcho Panovski², Mirjana Shosholcheva³, Aleksandar Dimitrovski¹, Risto Cholanchevski⁴, Natasha Toleska⁴, Milka Zdravkovska⁵

¹ University Clinic for Anesthesia, Reanimation and Intensive Care – KARIL, Medical Faculty, University “Ss. Cyril and Methodius” Skopje, Republic of Macedonia

² University Clinic for Digestive Surgery, Medical Faculty, University “Ss. Cyril and Methodius”, Skopje, Republic of Macedonia

³ University Clinic “St. Naum Ohridski”, Medical Faculty, University “Ss. Cyril and Methodius”, Skopje, Republic of Macedonia

⁴ University Clinic for Thoracic and Vascular Surgery, Medical Faculty, University “Ss. Cyril and Methodius”, Skopje, Republic of Macedonia

⁵ Faculty of Medical Sciences, University “Goce Delcev”, Shtip, Republic of Macedonia

Corresponding author: Marija Toleska Doneska, MD, University Clinic for Anesthesia, Reanimation and Intensive Care – KARIL, Faculty of Medicine, University “St. Cyril and Methodius” – Skopje; “Vodnjanska” Str. No.: 17, 1000 Skopje; Tel.:0038971221228; E-mail: marija_toleska@yahoo.com

ABSTRACT

Introduction: Patients undergoing laparoscopic cholecystectomy do experience postoperative pain, especially in the abdomen. Postoperative pain management remains a major challenge after laparoscopic procedures. Administration of intraperitoneal local anesthetic (IPLA) after surgery is used as a method of reducing postoperative pain. In this study, we evaluated the effect of intraperitoneal infiltration of local anesthetic (bupivacaine) for pain relief after laparoscopic cholecystectomy.

Material and methods: In this prospective, controlled, and randomized study were included 50 patients aged 25-60 years (35 female and 15 male), scheduled to laparoscopic cholecystectomy with ASA classification 1 and 2. Patients were classified randomly into two groups: group A, which included 25 patients who received intraperitoneal instillation of bupivacaine 0.5% 20 ml; and group B, which included 25 patients who didn't receive any intraperitoneal instillation. Postoperative pain was recorded using the visual analogue scale (VAS) for 24 hours after laparoscopic cholecystectomy.

Results: There was no significant difference with respect to age, weight, and sex; duration of surgery; and anesthesia time. VAS scores at different time intervals were statistically significantly lower at all times in group A compared to group B. There were statistically significant differences in VAS scores between group A and group B at all postoperative time points - 1hr, 4 hr, 8 hr, 12hr and 24hr ($p < 0.00001$).

Conclusion: Intraperitoneal instillation of bupivacaine provides good analgesia in the postoperative period after laparoscopic cholecystectomy.

Keywords: laparoscopic cholecystectomy, intraperitoneal instillation, bupivacaine

INTRODUCTION

Laparoscopic cholecystectomy (LC) is nowadays established as a gold standard form of treating patients with cholelithiasis. Laparoscopic cholecystectomy is a minimally invasive

technique and is associated with reduced surgical trauma, smaller and more cosmetic incision, reduced blood loss, and is associated usually with fewer postoperative complications and de-

creased length of hospital stay. [1] Although pain after LC is less intense than after open cholecystectomy (OC), some patients still experience considerable discomfort and pain during the first 24 to 72 postoperative hours. [2]

Postoperative pain remains the most prevalent complaint after laparoscopic cholecystectomy. This can prolong hospital stay, which is particularly of utmost importance since many centers are performing this operation as a day-case procedure. [3] Postoperative pain management remains a major challenge after laparoscopic procedures. Effective pain control encourages early ambulation, which significantly reduces the risk of deep vein thrombosis and pulmonary embolism (PE); enhances patient's ability to take deep breaths to decrease the risk of pulmonary complications (e.g., atelectasis and pneumonia); and decreases the incidence of tachycardia and unnecessary investigations related to it. Pain after laparoscopic surgery has a visceral component, as a result of surgical handling and diaphragmatic irritation by dissolved carbon dioxide and a somatic component due to the holes made in the abdominal wall for the troacars. Shoulder pain, which is associated with peritoneal insufflations, occurs especially when shoulder holders and an exaggerated Trendelenburg position are used that frequently complicate the postoperative period after the laparoscopic surgery. [4] Pain on the day of surgery is typically a diffuse abdominal pain, and more so to the right upper quadrant and right shoulder tip. [2]

Many methods have been proposed to improve pain control such as the use of local anesthetics at the trocar site, intraperitoneal injection of local anesthetics, intermittent intravenous non-steroidal anti-inflammatory drugs (NSAIDs), intermittent intramuscular narcotics, decreasing pneumoperitoneum pressure, and decreasing the number of operative ports. [5, 6] Administration of intraperitoneal local anesthetic (IPLA) after surgery is used by many surgeons as a method of reducing postoperative pain. The method of delivering local anesthetic directly to the intraperitoneal cavity was first described in 1951 by Griffin et al. [7] This method was forgotten for decades until its implementation in minimal access surgery was rekindled. Based on level A evidence it is now accepted that IPLA significantly reduces postoperative pain and opioid use after laparoscopic general surgical pro-

cedures, open hysterectomy, and laparoscopic gynecological procedures. [8]

In this prospective, randomized, and controlled study, we evaluated the effect of intraperitoneal infiltration of local anesthetic (bupivacaine) for pain relief after laparoscopic cholecystectomy.

MATERIAL AND METHODS

In this prospective, controlled, and randomized study were included 50 patients aged 25-60 years (35 female and 15 male), scheduled for laparoscopic cholecystectomy with ASA classification 1 and 2. After approval from the local ethics committee and after obtaining informed consent from each patient, the study was performed at the University Clinic for Anesthesia, Reanimation and Intensive Care-KARIL, Clinical Campus "Mother Teresa" – Skopje, during October 2016 to March 2017. From this study were excluded patients with ASA classification 3-5, history of allergy to bupivacaine, ketonal, and tramadol, patients with coagulopathy, and patients with a history of abdominal surgery. During the preoperative visit, the visual analogue scale (VAS) ranging from 0 (no pain) to 10 (worst imagined pain) was explained to every patient. The laparoscopic cholecystectomy and the intraperitoneal application of bupivacaine were performed by one surgeon.

For all patients anesthesia was induced intravenously using midazolam 0.04 mg/kg, fentanyl 1 0.002 mg/kg, propofol 1-2 mg/kg and rocuronium 0.6 mg/kg and was maintained by using sevoflurane MAC 1 combined with oxygen : air (50 : 50) and additional boluses of fentanyl and rocuronium, as required. After tracheal intubation an orogastric tube was placed. All patients were continuously monitored by both lead II and V5 ECG, repeated non-invasive mean arterial blood pressure (MAP) measurement every 5 minutes, and continuous end-tidal CO₂ and oxygen saturation (SpO₂) by pulse oxymetry. End-tidal CO₂ was maintained between 35 and 45 mmHg. During laparoscopy, intraabdominal pressure of all patients was maintained at 12 mmHg with continuous CO₂ insufflation. Additionally, fentanyl 0.5-1 microgr/kg was injected to control blood pressure and heart rate within 20% of baseline. Patients were classified ran-

domly into two groups: group A, which included 25 patients who received intraperitoneal instillation of bupivacaine 0.5% 20 ml; and group B, which included 25 patients who didn't receive any intraperitoneal instillation. Bupivacaine was instilled immediately after laparoscopic removal of the gallbladder and after performing complete washing of the peritoneal cavity and aspiration of the solution used for irrigation and before wound closure, under the visual guidance of laparoscopic camera. During the study, prophylactic antiemetics were not given.

At the end of the surgery, the abdomen was completely deflated, and muscle relaxation was reversed with intravenous (i.v.) neostigmine 0.05 mg/kg and atropine 0.01 mg/kg. No analgesics were given to patients before recovery. After the surgery, patients were taken to postanesthesia care unit (PACU). The anaesthesiologist following up the patient was blinded to the groups. The time of arrival at the PACU was defined as zero (0) hour postoperatively. The intensity of postoperative abdominal pain was assessed using a VAS, with evaluation at 1, 4, 8, 12, and 24 hours postoperatively. In patients with VAS score above 4, 100 mg of ketonal was administered i.v., while in patients with VAS score above 7, 100 mg of tramadol was administered intramuscular (i.m.) as rescue analgesia treatment. Postoperative nausea and vomiting (PONV) were planned to be treated with ondansetron 4 mg i.v.

Postoperative abdominal pain intensity in the follow-up period of 24 h was compared for both groups. The patients were observed for side effects such as pruritus, sedation, bradycardia, hypotension, and shivering during the follow-up period.

Data analysis was performed by using Statistical Package for Social Sciences (SPSS) version 17.0 software. Kolmogorov Smirnov test and Shapiro-Wilk's W test were used to identify the distribution of variables. Data were expressed as mean \pm standard deviation. Student t-test for independent groups was used for numerical variables with normal distribution, and the Mann-Whitney U test was used for nonparametric variables. A p-value less than 0.05 was considered statistically significant.

RESULTS

There was no significant difference with respect to age, weight, and sex; duration of surgery; and anesthesia time (Table 1).

Table 1. Demographic and clinical characteristics

Variable	Group A (N=25)	Group B (N=25)	P-value
Age / years	42.4 \pm 7.6	45.3 \pm 10.2	p = 0.2626
Weight / kg	84.6 \pm 9.9	83.5 \pm 12.7	p = 0.7431
Sex (M/F), number	8/17 (32% / 68%)	7/18 (28% / 72%)	p = 0.7599
Duration of surgery (minutes)	41.4 \pm 10.7	37.6 \pm 5.3	p = 0.2859
Anesthesia time (minutes)	50.7 \pm 14.5	53.5 \pm 5.4	p = 0.0572

VAS scores at different time intervals were statistically significantly lower at all times in group A compared to group B (Table 2). There were statistically significant differences in VAS scores between group A and group B at all postoperative time points - 1 hr, 4 hr, 8 hr, 12hr and

Table 2. VAS scores in group A and B at all postoperative time points

	VAS 1 h	VAS 4 h	VAS 8 h	VAS 12 h	VAS 24 h
Group A	2.04 \pm 0.67				
Group B	5.56 \pm 1.35 p < 00001				
Group A		2.64 \pm 0.75			
Group B		5.68 \pm 1.28 p < 00001			
Group A			2.56 \pm 1.0		
Group B			4.80 \pm 0.91 p < 00001		
Group A				1.76 \pm 0.88	
Group B				4.24 \pm 0.97 p < 00001	
Group A					0.76 \pm 0.72
Group B					3.44 \pm 0.58 p < 00001

24 hr ($p < 0.00001$). VAS scores in group A were significantly lower (Table 2 and Figure 1).

In the postoperative period, none of the patients from group A complained for side effects of local anesthetics, such as pruritus, sedation, bradycardia, hypotension, and shivering.

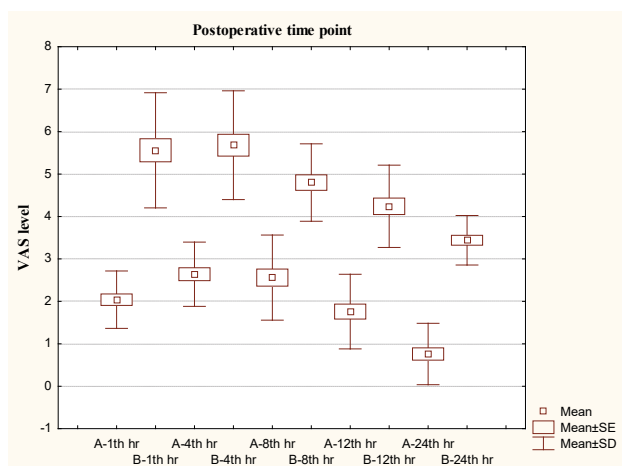


Figure 1. VAS scores in group A and B at all postoperative time points

DISCUSSION

Pain after laparoscopic cholecystectomy is less intense and lasts a shorter time, compared to pain after open cholecystectomy. [9] This explains why patients can be discharged within the first postoperative day of LC surgery and can return to their normal daily activities more quickly, compared to open cholecystectomy. However, LC is not a pain-free procedure. Postoperative pain control is directed at early mobilization, recovery, and discharge. Pain can play a major role in metabolic and endocrine responses and can impair postoperative pulmonary function. [5] Several mechanisms of postlaparoscopic pain generation have also been proposed such as ruptured blood vessels resulting from the rapid distension of the peritoneum, traumatic nerve traction, release of inflammatory molecules, trauma to the abdominal wall, trauma occurring with the removal of the gallbladder from the abdomen, pneumoperitoneum created by utilizing CO₂, maintenance of high abdominal pressure, irritation of the phrenic nerve, and application of cold CO₂. [10] Recommendations for the treatment of postoperative

pain in patients undergoing LC include NSAIDs, local anesthesia injection at the incision sites, opioids, and preoperative steroid use. [5]

Intraperitoneal local anesthetics (IPLAs) have been used since 1951. [7] IPLA has been used to reduce shoulder tip pain, overall pain, nausea and vomiting, and the time of hospital stay. [11] Based on level A evidence, it is now accepted that IPLA significantly reduces postoperative pain and opioid use after laparoscopic general surgical procedures, [11] open hysterectomy, [12] and laparoscopic gynecological procedures. [13] There are several mechanisms of IPLA that have been postulated. IPLA is likely to blockade free afferent nerve endings in the peritoneum. Systemic absorption of local anesthetic from the peritoneal cavity may also play a part in reduced nociception although this would be expected to occur after any local anesthetic technique. Systemic levels of local anesthetic are detectable in the serum circulation as soon as 2 minutes after bolus instillation into the peritoneum. [8]

In this study, intraperitoneal instillation of bupivacaine 0.5% 20 ml significantly reduced the postoperative pain and significantly reduced the analgesics requirement in the postoperative period. There was no significant difference with respect to age, weight, and sex; duration of surgery; and anesthesia time. VAS scores at different time intervals were statistically significantly lower at all times in group A compared to group B (Table 2). There were statistically significant differences in VAS scores between group A and group B at all postoperative time points - 1 hr, 4 hr, 8 hr, 12 hr and 24 hr ($p < 0.00001$). VAS scores in group A were significantly lower (Table 2 and Figure 1). In the postoperative period none of the patients from group A complained for side effects of local anesthetics, such as pruritus, sedation, bradycardia, hypotension, and shivering.

Banoria et al., in his study included 64 patients scheduled for LC, divided in two groups. Group A patients were instilled intraperitoneally using 20 ml of 0.5% injection bupivacaine in diaphragmatic surface and gallbladder fossa just after LC and Group B patients were not instilled with any injection. They found that the early postoperatively VAS scores and pain intensity after 8 hrs and 16 hrs is decreased with the use of intraperitoneal instillation of injection bupivacaine, but in the long term, it offers no added benefit to the postoperative pain relief and does not decrease the need for analgesia postoperatively. [6]

The study of Jamal et al., included 90 patients scheduled for LC, divided into 3 groups. Patients in group T received tramadol 2 mg/kg in 30 ml normal saline, in group B received bupivacaine 30 ml of 0.125% and in group BT received tramadol 2 mg/kg in 30 ml of 0.125% bupivacaine intraperitoneally. The result was that intraperitoneal application of bupivacaine with tramadol was a more effective method for postoperative pain control after LC compared to intraperitoneal bupivacaine or tramadol alone. [14]

Another study consisted of 66 patients scheduled for LC. Group BS received 15 ml of 0.25% levobupivacaine before trocar site incision and 40 ml of 0.25% levobupivacaine intraperitoneally immediately after the creation of pneumoperitoneum. Group AS received the same doses of incisional levobupivacaine at the end of the operation and intraperitoneal levobupivacaine before the trocars were withdrawn. Group C received no treatment. The combination of incisional and intraperitoneal levobupivacaine administered before or after surgery can reduce postoperative pain and analgesic and antiemetic consumption together with improved patient satisfaction. Administering levobupivacaine before surgery might be advantageous for less intraoperative fentanyl consumption, while levobupivacaine after surgery is advantageous for less postoperative rescue analgesic requirement. [3] Morsy et al., in his study included 80 patients scheduled for LC, divided into three groups. Group C received 50 ml normal saline intraperitoneally; Group L received 200 mg lidocaine intraperitoneally; and Group N received 10 mg nalbuphine intraperitoneally in 50 ml normal saline. Although both lidocaine and nalbuphine when used intraperitoneally produce postoperative analgesia, intraperitoneal lidocaine gives a better analgesic profile with fewer unwanted effects. [1]

Khan et al., used both lidocaine and bupivacaine intraperitoneally during laparoscopic cholecystectomy for postoperative analgesia and concluded that bupivacaine and lidocaine are both safe and equally effective in decreasing postoperative pain after LC. [15] Some studies evaluated the efficacy of intraperitoneal and intravenous lidocaine on pain relief after LC and they reported significantly reduced postoperative pain and opioid consumption in LC patients, compared with control infusions. [16] Another study evaluated intraperitoneal instillation of 30 ml 0.2% ropivacaine (R group) versus intraperitoneal instillation

of 30 ml 0.2% ropivacaine combined with 1 µg/kg dexmedetomidine (RD group) and they reported significantly reduced VAS scores in 24 hrs postoperatively, time to first request of analgesia was longest and total analgesic consumption was lowest in RD group compared to R group. [4]

CONCLUSION

Intraperitoneal instillation of bupivacaine provides good analgesia in the postoperative period after laparoscopic cholecystectomy. Our study showed this technique to be an effective alternative method for early pain control and to minimize the need of opioid analgesics in the postoperative period. It is easy to be administered with no adverse effects, cheap and noninvasive method, and may become a routine practice for this procedure.

REFERENCES

1. Morsy KM, Abdalla EEM. Postoperative pain relief after laparoscopic cholecystectomy: intraperitoneal lidocaine versus nalbuphine. *Ain Shams J Anesthesiol* 2014; 07: 40-44.
2. Alam MS, Hoque HW, Saifullah M, Ali MO. Port site and intraperitoneal infiltration of local anesthetics in reduction of postoperative pain after laparoscopic cholecystectomy. *Med Today* 2009; 22: 24-28.
3. Alper I, Ulukaya S, Yüksel G, Uyar M, Balcioglu T. Laparoscopic cholecystectomy pain: effects of the combination of incisional and intraperitoneal levobupivacaine before or after surgery. *Agri* 2014; 26: 107-112.
4. Chiruvella S, Nallam SR. Intraperitoneal instillation of ropivacaine plus dexmedetomidine for pain relief after laparoscopic hysterectomy: A comparison with ropivacaine alone. *J NTR Univ Health Sci* 2016; 5: 93-97.
5. Yeh et al.: Pain relief from combined wound and intraperitoneal local anesthesia for patients who undergo laparoscopic cholecystectomy. *BMC Surgery* 2014; 14: 28.
6. Banoria NK, Prakash S, Shaily, Sharma OK. Effect of local anesthetic instillation intraperitoneally on post-op pain relief after laparoscopic cholecystectomy. *Indian Journal of Clinical Anatomy and Physiology* 2016 Jul; 3(3): 322-325.

7. Griffin EM, Prystowsky H, Hingson RA. The use of topical anaesthesia of the peritoneum in poor risk surgery and in augmenting inadequate vertebral conduction anaesthesia. *N Z Med J* 1951; 50: 31-3.
8. Kahokehr A. Intraperitoneal local anesthetic for postoperative pain. *Saudi J Anaesth* 2013 Jan-Mar; 7(1): 5.
9. Trondsen E, Reiertsen O, Andersen OK, Kjaersgaard P. Laparoscopic and open cholecystectomy: a prospective, randomized study. *Eur J Surg* 1993; 159: 217-221.
10. Maharjan SK, Shrestha S. Intraperitoneal and periportal injection of bupivacaine for pain after laparoscopic cholecystectomy. *Kathmandu Univ Med J* 2009; 7: 50-53.
11. Kahokehr A, Sammour T, Soop M, Hill AG. Intraperitoneal local anesthetic in abdominal surgery – a systematic review. *ANZ J Surg* 2011; 81: 237-245.
12. Gupta A, Perniola A, Axelsson K, Thorn SE, Crafoord K, Rawal N. Postoperative pain after abdominal hysterectomy: A double-blind comparison between placebo and local anesthetic infused intraperitoneally. *AnesthAnalg* 2004; 99: 1173-1179.
13. Sripada S, Roy S, Mathur M, Hamilton M, Cranfield K, Bhattacharya S. A prospective double-blind randomized controlled trial of intraoperative pelvic instillation with bupivacaine for management of pain following laparoscopy and dye. *BJOG* 2006; 113: 835-838.
14. Jamal A, Usmani H, Khan MM, Rizvi AA, Siddiqi MH, Aslam M. Intraperitoneal pre-insufflation of 0.125% bupivacaine with tramadol for postoperative pain relief following laparoscopic cholecystectomy. *J AnaesthesiolClinPharmacol* 2016; 32: 257-260.
15. Khan MR, Raza R, Zafar SN, Shamim F, Raza SA, Pal KM, et al. Intraperitoneal lignocaine (lidocaine) versus bupivacaine after laparoscopic cholecystectomy: results of a randomized controlled trial. *J Surg Res* 2012; 2: 662-669.
16. Yang SY, Kang H, Choi GJ, Shin HY, Baek CW, Jung YH, et al. Efficacy of intraperitoneal and intravenous lidocaine on pain relief after laparoscopic cholecystectomy. *J Int Med Res* 2014; 42: 307-319.

Резиме**ЕФЕКТОТ НА ИНТРАПЕРИТОНЕАЛНО ДАДЕНИОТ BUPIVACAINE ВО НАМАЛУВАЊЕ НА БОЛКАТА ПО ЛАПАРОСКОПСКА ХОЛЕЦИСТЕКТОМИЈА**

**Марија Толеска¹, Андријан Карталов¹, Билјана Кузмановска¹,
Милчо Пановски², Мирјана Шошолчева³, Александар Димитровски¹,
Ристо Чоланчевски⁴, Наташа Толеска⁴, Милка Здравковска⁵**

¹ Универзитетска клиника за анестезија, реанимација и интензивно лекување – КАРИЛ, Медицински факултет, Универзитет „Св. Кирил и Методиј“, Скопје, Република Македонија

² Универзитетска клиника за абдоменална хирургија, Медицински факултет, Универзитет „Св. Кирил и Методиј“ Скопје, Република Македонија

³ Универзитетска Клиника „Св. Наум Охридски“, Медицински факултет, Универзитет „Св. Кирил и Методиј“, Скопје, Република Македонија

⁴ Универзитетска клиника за торакална и васкуларна хирургија, Медицински факултет, Универзитет „Св. Кирил и Методиј“, Скопје, Република Македонија

⁵ Факултет за медицински науки, Универзитет „Гоце Делчев“, Штип, Република Македонија

Вовед: Пациентите што се предвидени за лапароскопска холецистектомија имаат постоперативна болка, особено во stomакот. Третманот на болката во постоперативниот период сè уште е голем предизвик по лапароскопските операции. Давањето локален анестетик интраперитонеално (IPLA) по операцијата се користи како метод со кој се намалува постоперативната болка. Во оваа студија го оценуваме ефектот на интраперитонеалната инфилтрација на локален анестетик (bupivacaine) за намалување на болката по лапароскопска холецистектомија.

Материјал и методи: Во оваа проспективна, контролирана и рандомизирана студија беа вклучени 50 пациенти, на возраст од 25 до 60 години (35 жени и 15 мажи), предвидени за лапароскопска холецистектомија, со ASA класификација 1 и 2. Пациентите беа рандомизирани во две групи: група А, која вклучува 25 пациенти на кои им беше дадено 20 ml 0,5% bupivacaine интраперитонеално; и група Б, која вклучува 25 пациенти на кои не им беше дадено ништо интраперитонеално. Беше следена постоперативната болка со користење визуелна аналогна скала за болка (VAS) за 24 часа по лапароскопска холецистектомија.

Резултати: Немаше значителна разлика во однос на возраста, тежината и полот, траењето на операцијата и траењето на анестезијата. VAS-скоровите во различни временски интервали беа статистички значително пониски во сите времиња кај групата А во споредба со групата Б. Имаше статистички значителни разлики во VAS-скоровите меѓу групата А и групата Б во сите времиња во постоперативниот период – 1, 4, 8, 12 и 24 часа ($p < 0,00001$).

Заклучок: Интраперитонеалното аплицирање на bupivacaine дава добра аналгезија во постоперативниот период по лапароскопска холецистектомија.

Клучни зборови: лапароскопска холецистектомија, интраперитонеална апликација, bupivacaine.