

Главен и одговорен уредник  
Editor in Chief

Гоце Спасовски

Заменик уредници  
Deputy editors

Мирјана Кочова, Нели Башеска

**Редакциски одбор / Editorial board и / and Едитори по области / Subject editors**

Милена Петровска-Микробиологија, Гордана Адамова-Гинекологија, Кочо Чакаларовски-  
Интерна медицина, Марија Ралева-Психијатрија, Ненад Јоксимовиќ-Гастроентерохепатологија,  
Марина Давчева Чакар-Оториноларингологија, Спасе Јовковски-Неврохирургија,  
Снежана Стојковска-Инфективно, Горан Кондов-Хирургија

**Интернационален редакциски одбор / International Editorial board**

Bernardus Ganter - UK, Daniel Rukavina - Croatia, Pavel Poredos - Slovenia, Vladimir Ovcharov - Bulgaria,  
Stefan Tofovic - USA, Jovan Hadzi-Djokic - Serbia, Ljubisa Markovic - UK, Dusko Vasic - Republika Srpska,  
Isuf Kalo - Albanija, Marina Kos - Hrvatska, Idris T. Ocal - Arizona,  
Frank A. Chervenak - USA, Franz Porzsolt - Germanija, Lako Christiaan - Danska

**Издавачки совет / Editorial Council**

**Претседател / President**

Стојмир Петров

Гоце Спасовски, Гордана Петрушевска, Билјана Јаневска, Драгослав Младеновиќ, Ѓорѓе Ѓокиќ, Соња  
Генадиева Ставриќ, Ѓорѓи Дерибан, Глигор Димитров, Вилма Лазарова, Магдалена Генадиева

**Секретар на Редакцијата / Secretary of the Editorial Office**

В. Митревска

**Јазичен редактор на македонски јазик / Proof-reader for Macedonian**

Ј. Мартиновска

**Лектор за англиски јазик / Proof-reader for English**

Л. Даневска

**Обработка на текстот / Text editing**

С. Стамболиева

**Наслов на Редакцијата и издавачот / Address of the Editorial Office and Administration:**

1000 Скопје, Даме Груев 3, Градски сид блок 2

тел.02/3162 577; 02/3239-804

[www.mld.org.mk](http://www.mld.org.mk) / [mld@unet.com.mk](mailto:mld@unet.com.mk)

Жиро сметка / Current Account

300000000211884 - Комерцијална банка Скопје

Печати: Бранко Гапо графичко производство - Скопје

Македонски медицински преглед се печати три пати годишно. Претплатата за списанието  
изнесува 10 евра за лекари, 50 евра за установа, странство 80 евра.

**Содржина/Contents**

**I. Ревизијални трудови/ Reviews**

**ХИПЕРТЕНЗИЈА ПО ТРАНСПЛАНТАЦИЈА НА БУБРЕГ  
HYPERTENSION AFTER KIDNEY TRANSPLANTATION**  
Jelka Masin-Spasovska, Olivera Stojceva-Taneva, Borjanka Taneva and Goce Spasovski..... 1

**АСТМА И ХОББ, СИНДРОМ НА ПРЕПОКРИВАЊЕ  
ASTHMA AND COPD OVERLAP SYNDROME (ACOS)**  
Deska Dimitrievska, Marija Zdraveska, Dejan Todevski, Elena Janeva, Suzana Arbutina and Angela Debreslioska..... 8

**ПРЕГЛЕД НА СОВРЕМЕНИОТ ТРЕТМАН НА КОНКВАСАЦИИ НА  
ЕКСТРЕМИТЕТИ  
CONTEMPORARY MANAGEMENT OF MANGLED EXTREMITY: A REVIEW**  
Игор Кафтанџиев, Марко Спасов и Бисера Пендовска..... 12

**II. Оригинални трудови/ Original Articles**

**КАРАКТЕРИСТИКИ НА АКУТНОТО БУБРЕЖНО ОПШТЕТУВАЊЕ ВО  
НЕОНАТАЛНИОТ ПЕРИОД ВО ЕДИНИЦАТА ЗА ИНТЕНЗИВНА НЕГА  
CHARACTERISTICS OF ACUTE KIDNEY INJURY IN NEONATAL AGE AT - INTENSIVE  
CARE UNIT**  
Силвана Наунова-Тимовска..... 20

**КОРОНАРНИОТ СТРЕС - ТЕСТ КАКО ПРЕДИКТОР НА КВАЛИТЕТОТ НА  
ЖИВОТ КАЈ БОЛНИ СО ХРОНИЧНА СРЦЕВА СЛАБОСТ  
CORONARY STRESS TEST AS A PREDICTOR OF QUALITY OF LIFE IN CHRONIC  
HEART FAILURE PATIENTS**  
Борјанка Танева и Дејан Ристевски..... 26

**ИСХОД НА РАНО НАСПРОТИ ОДЛОЖЕНО ОПЕРИРАНИ ПАЦИЕНТИ ПОРАДИ  
СУБАРАХНОИДАЛНА ХЕМОРАГИЈА ОД РУПТУРИРАНА ЕНДОКРАНИЈАЛНА  
АНЕВРИЗМА  
OUTCOME OF EARLY VERSUS LATE OPERATED PATIENTS DUE TO SUBARACHNOID  
HEMORRHAGE FROM RUPTURED INTRACRANIAL ANEURYSM**  
Венко Филипче, Александар Чапароски и Томи Камилоски..... 30

**ВЛИЈАНИЕТО НА ХОРМОНСКАТА СУПСТИТУЦИОНА ТЕРАПИЈА ВРЗ  
ГЛИКЕМИСКАТА КОНТРОЛА КАЈ ЖЕНИ ВО МЕНОПАУЗА СО ДИЈАБЕТЕС  
МЕЛИТУС ТИП 2  
ASSOCIATION BETWEEN HORMONE REPLACEMENT THERAPY AND GLYCEMIC  
CONTROL IN POSTMENOPAUSAL WOMEN WITH TYPE 2 DIABETES**  
Iskra Bitoska, Brankica Krstevska, Tatjana Milenkovic, Snezana Markovik-Temelkova, Sasa Jovanovska-Misevska, Goran Petrovski, Katerina Adamova, Elizabeta Stojovska-Jovanovska and Biljana Novakovik-Zafirova..... 35

**III. Приказ на случај/Case reports**

**МАКУЛАРНА РЕТИНОШИЗА И НЕЈЗИНАТА СЕМИОТСКА ВАЖНОСТ  
MACULAR RETINOSCHISIS AND ITS SEMIOTIC IMPORTANCE: A CASE REPORT**  
Milena Golubovic, Bekim Tatesi, Igor Isjanovski and Karolina Buzarovska..... 40

**УСПЕШНА ТРАНСПЛАНТАЦИЈА НА БУБРЕГ КАЈ ХЕМОДИЈАЛИЗЕН  
ПАЦИЕНТ СО ИНТЕЛЕКТУАЛНА ИНФЕРИОРНОСТ  
SUCCESSFUL KIDNEY TRANSPLANTATION IN PATIENT ON HEMODIALYSIS AND  
INTELLECTUAL INFERIORITY**  
Николина Смоковска, Јелка Масин-Спасовска, Даниела Младеновска, Анастасија Спасовска, и Гоце Спасовски..... 45

**ОДЛИЧЕН ИСХОД ПРИ РАНА ХИРУРШКА ИНТЕРВЕНЦИЈА ПОРАДИ  
РУПТУРИРАНА АНЕВРИЗМА НА А. CEREBRI MEDIA КОМПЛИЦИРАНА СО  
ИНТРАЦЕРЕБРАЛНА И ИНТРАВЕНТРИКУЛАРНА ХЕМОРАГИЈА: ПРИКАЗ НА  
СЛУЧАЈ**

**EXCELLENT OUTCOME AFTER EARLY SURGERY FOR RUPTURED MIDDLE  
CEREBRAL ARTERY ANEURYSM COMPLICATED WITH INTRACEREBRAL AND  
INTRAVENTRICULAR HEMORRHAGE: A CASE REPORT**

Venko Filipce, Aleksandar Caparoski, Tomi Kamiloski and Dejan Daskalov..... 48

## МАКУЛАРНА РЕТИНОШИЗА И НЕЈЗИНАТА СЕМИОТСКА ВАЖНОСТ

### MACULAR RETINOSCHISIS AND ITS SEMIOTIC IMPORTANCE: A CASE REPORT

Milena Golubovic, Bekim Tatesi, Igor Isjanovski and Karolina Buzarovska

University Eye Disease Clinic, University "Ss Cyril and Methodius", Medical Faculty, Skopje, Republic of Macedonia

#### Апстракт

**Вовед.** Поимот ретиношиза означува раздвојување во слоевите на неуроретината. Може да се случи во периферните делови на ретината, но исто така и во регионот на макула лутеа кога зборуваме за макуларна ретиношиза.

Макуларната ретиношиза се јавува како една од карактеристиките на повеќе херидитарни заболувања. Според офталмоскопскиот изглед, лесно може да се поистовети со цистоиден макуларен едем. Иако макуларните промени, во двата случаја, со текот на време доведуваат до намалување на видната острина, дистинкцијата на макуларните промени е од семиотска важност во диференцијалната дијагноза на ретиналното заболување, што е од значење од поширок медицински аспект.

Целта на трудот е преку приказ на случај со ретко херидитарно заболување да се покаже важноста и комплементарноста во дијагностичките методи, особено на ОКТ и неговото значење во поставување на точна дијагноза.

**Приказ на случај.** Во трудот е презентираан пациент со макуларна ретиношиза во рамките на Голдман-Фавреова витреоретинална дегенерација. Тоа е херидитарно заболување кај кое, покрај шизни промени на ретината во пределот на макулата, се јавуваат и промени на пигментниот епител во пределот на медиоретината. ОКТ наод кај нашиот болен покажува цистична хипорефлексна промена во фовеата, со палисадно ориентирани помали хипорефлексивни промени помеѓу плексиформните слоеви и во внатрешниот грануларен слој во пределот на макулата. На флуоресцеинска ангиографија во пределот на макулата не постои излив на боја, но во пределот на медиоретината евидентни се промените на пигментниот епител. Сепак, периметриското иследување не покажа дефект во видното поле.

**Заклучок.** Поновите дијагностички методи, како што е оптичка кохерентна томографија, ја потврдија својата важност во процесот на дијагностика и поставување на точна дијагноза. Покрај фактот дека точната дијагноза на заболувањето често нема значење во смисла на терапевтските можности на заболувањето, нејзиното значење е важно во смисла на правилна информација за можностите на пренесување на заболувањето како и предикција на животната перспектива поврзана со намалување на видната острина.

**Клучни зборови:** ретиношиза, макула лутеа, ОКТ (оптичка кохерентна томографија)

#### Abstract

**Introduction.** The concept of retinoschisis means splitting of the layers of neural retina. It can happen equally at the peripheral part of retina, as well as in the region of macula when we talk about macular retinoschisis.

Macular retinoschisis appears as one of the characteristics of a few hereditary diseases. According to the ophthalmoscopes' picture it can easily be mixed with cystoid macular edema. Even though macular changes, in both cases, during time lead to decrease of visual acuity, distinction of macular changes is of semiotic significance in differential diagnosis of retinal diseases, which is important from a broader medical aspect. The aim of this paper is, by presenting a case with a rare hereditary disorder, to show the importance and complementarities of diagnostic methods, especially OCT and its meaning in establishing the correct diagnosis.

**Case report.** The paper presents a patient with macular retinoschisis, as a part of Goldmann-Favre vitreoretinal degeneration. It is a hereditary disorder, which in addition to schisms changes in the macula is characterized by changes in the pigmented epithelium at the medial part of retina. OCT finding in our patient showed cystic hyporeflexive change in the fovea, with palisade oriented smaller hyporeflexive changes, between plexiform layers and in the inner granular layer of the macula. On fluorescein angiography the leakage of the fluorescein in the macular region was absent, but the

changes on the level of pigmented epithelium in the area of medial retina were evident. However, perimetry did not show defect in the visual field.

**Conclusion.** Newer diagnostic methods, such as optical coherence tomography, proved their importance in the decision making process and in making the right diagnosis in macular lesions. Beside the fact that the correct diagnosis of the disorder frequently has no importance in the sense of therapeutic possibility of the disease, its value can be seen in proper information of possibility of disease transmission as well as in prediction of affected person's life perspective, associated with the decrease of visual acuity.

**Key words:** retinoschisis, macula lutea, OCT (optical coherence tomography)

---

## Introduction

Macular retinoschisis indicates splitting of the layers of neural retina, near macula lutea. This splitting of the layers from each other as well as secondary changes in receptor cells and pigment epithelium consequently lead to a decline in visual acuity.

The application of modern diagnostic imaging methods, OCT (optical coherence tomography) of the rear segment of the eye, is of great importance for visualization of changes in the central part of the retina. OCT distinction of macular changes is important in the semiotics of disorders and assumptions of other differential-diagnostic dilemmas. In this paper we present the case of a girl with macular retinoschisis within Goldmann-Favre vitreoretinal degeneration, who was diagnosed in the OCT Department, University Eye Disease Clinic in Skopje. She was referred to this Department by a secondary specialized service because of a decline in the visual acuity that could not be corrected. The referral diagnosis was cystoid macular edema.

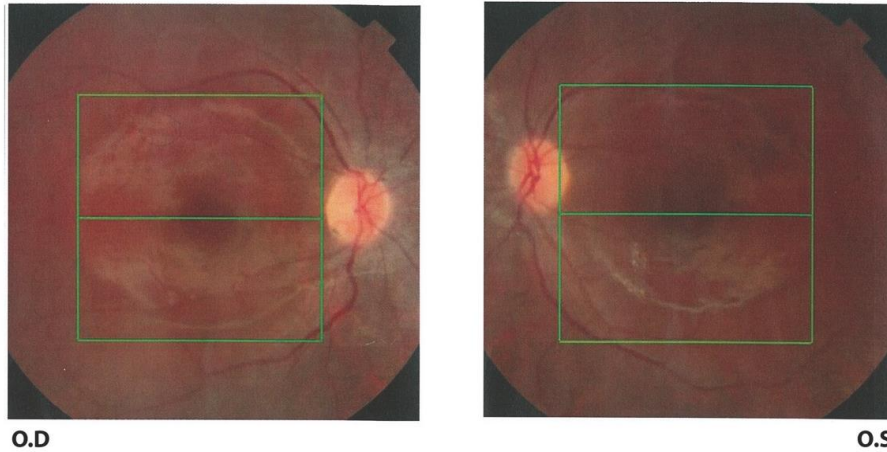
The aim of this paper is, by presenting a patient with a rare hereditary disease, to show the importance and complementarity of the diagnostic methods, especially OCT, in regards to establishing an accurate diagnosis.

## Case report

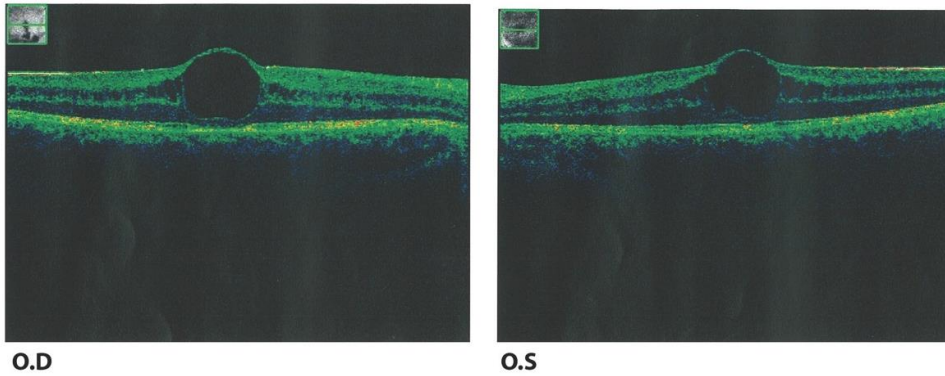
A 16-year-old girl (K.B.) was referred to the OCT Department due to changes in the area of macula lutea and a visual acuity impairment that could not be corrected with eyeglasses. Visual acuity of the right eye was BCVA 0.4, while of the left BVCA 0.3, determined with the Snellen eye chart/optotype.

The OCT image made on the rear section of the Topcon 2000 apparatus, 3D OCT (spectral domain OCT), detected a cystic formation in the fovea region, which elevated and flattened the physiological umbo by increasing the central thickness of the retina in both eyes of 527 and 542 millimicrons, yet still retaining the external complexity of the receptor cells and pigment epithelium. A swelling was detected in the perifoveal area as well as reduced reflectivity, along with an increase in the total volume of the macula area. Changes in the internal granular layer of the perifoveal zone were noted due to the presence of palisade cystic spaces (Figure 1 and Figure 2).

Because of the notable changes that spoke in favor of retinoschisis, the patient was sent for further examinations. A detailed biomicroscopy of dilated fundus was made with a magnifying glass (78D), Goldmann's triangular prism, and indirect biomicroscopy. Ophthalmoscopic examination of the eye fundus showed papilla of the optic nerve with normal colorfulness and appearance, with properly oriented blood vessels of normal caliber. An altered reflex was noticed in the foveal area with an aspect of cystic change, but also with a changed reflex in the entire macular region. In the area around the vascular arcades some white-grayish changes in the red background of the fundus as well as pigment changes could be detected. Biomicroscopy in the slit detected changes in the vitreous body, an inequality with a rougher texture of the fibrils and the existence of major lacunae in the vitreous body.



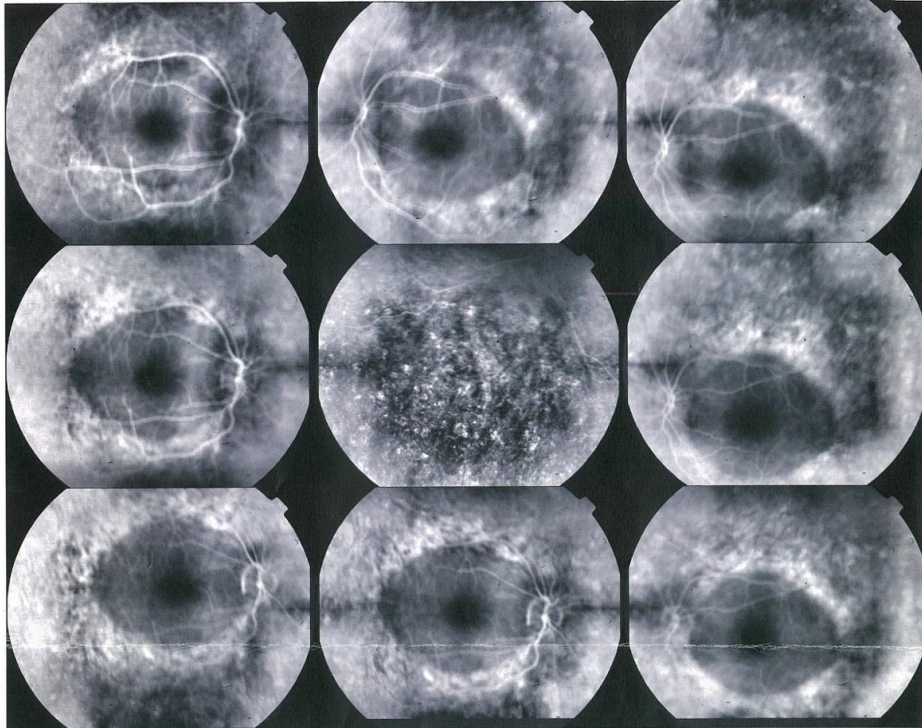
**Fig. 1.** Color photography of both maculae shows dull reflex of foveas. Changes in the pigment epithelium on the medial retinal (on the color photograph) are discrete and hardly visible



**Fig. 2.** OCT images show central thickening of both maculae with cystic space in fovea and palisade symmetrical hyporeflective zones in inner granular layer

Because of the cystic change in the fovea and changes in the medial retina a fluorescein angiogram was performed on a dilated pupil by injecting 20% natrium fluorescein of Topcon TRC-50IX. In the early stage of the angiogram, due to the defects in the pigment epithelium, the medial retina

showed hyperfluorescence which persisted throughout the transition phase of the angiography with equal to slightly reduced intensity. Throughout the angiogram, and even in the late phase, the macula remained inactive and without window defects, staining or color leakage (Figure 3).



**Fig. 3.** Angiographic image shows defect of pigment epithelium on the medial part of retina. Macula remains silent in all phases

Standard perimetric examination conducted with the automatic perimeter Optopol PTS 910 showed no vision failure or increase in the sensitivity threshold.

Medical history revealed that the patient had a visual impairment since the early school age but without specific features, although she gave an affirmative reply to the question whether she had reduced vision at night. To establish whether a hereditary disease might be involved, we examined her parents and her sister. Ophthalmologic findings in her father and sister were normal and they did not complain on any functional disorders. The examination of her mother, who had pseudophakia, indicated she might have pigment retinopathy on her fundus.

Because of the discovered changes in the macula lutea, the changes in the medial retina on the pigment epithelium level and the combined changes in the vitreous body, the patient was diagnosed with Goldmann-Favre vitreoretinal degeneration.

Due to macular schisis found in our patient, and in line with the literature data regarding treatment of juvenile macular retinoschisis by application of dorzolamide, she was given 2% dorzolamide. However, the treatment showed no effect.

## Discussion

The macula lutea is of particular importance to the retina. It is a place of clear vision, that is to say a place that determines our visual acuity as well as color differentiation and contrast sensitivity. Disorders in this part of the retina,

which can be of various natures, disturb its function and significantly influence the work capability and life quality. Retinoschisis is the condition in which splitting between the layers of the neuroretina appear. The changes often occur in the nerve fiber layer, but it is equally likely for them to affect more layers of the sensory retina [1-3]. If the changes occur in the area of the macula, it is possible to detect the gentle stellate folds that extend radially from the fovea by using the ophthalmoscope [1,2]. However, the ophthalmoscopic similarities in the appearance of particular macular changes within the frame of several diseases, and the impossibility to perform an ophthalmoscopic visualization of the subtle morphology, can lead to diagnostic errors.

Introducing new technologies, such as OCT tomography, has proved to be of immense importance in the diagnosing of disorders in the rear sections of the eye. This noninvasive method functions on the principle of low coherent interferometry with high resolution of 10 microns and makes it possible to detect relative reflective changes and other optical structures in the retina. The method is not only of great importance in diagnostics but also in monitoring retinal changes.

The significance of the method is indisputable; however, it is still just a complementary diagnostic method that contributes to the solving of the problem.

The OCT findings in our patient showed a cystic hyporeflectia in the area of the fovea, with symmetrical delayering between two plexiform layers and palisadally



arranged hyporeflexia zones in the inner granular layer. In the fovea, the retention of the outer photoreceptor/pigment epithelium complex was apparent.

Semiotically speaking, this change indicates multiple disorders that might be cause of its occurrence. First and foremost, a distinction should be made in terms of the cystoid macular edema, dominantly inherited cystoid macular edema or cystoid edema as a complication of an existing intraocular disease (uveitis, retinitis pigmentosa, diabetic retinopathy, etc.) [1]. OCT findings show a similar image with the existence of retinal thickening in the area of the fovea and perifoveal cystic hyporeflexia zones that span in the interplexiform layers, which can also expand to the external boundary layer of the retina. However, the OCT retinal cyst changes in retinoschisis are linear, more symmetrical. Between the two conditions, a fluorescein angiogram can have a discriminating meaning, that is, in cystoid macular edema fluorescence is seen in the late phase of the angiogram due to color leakage from macular capillaries in the retina. This was not the case with our patient. The macula was inactive, which suggested this to be a case of retinoschisis.

Retinoschisis in the area of macula lutea is characteristic to juvenile macular retinoschisis. This is a hereditary disease caused by XLR1 mutation, the retinoschisin protein gene which is important for the cellular-cellular reaction and adhesion of cells to the sensory retina. In most cases the disorder is transmissive. It is considered an X-linked disorder because it occurs in males, presenting its clinical picture as early as preschool age. Females are heterozygous for XLR1 gene mutation, although a case has been reported on a girl whose father was a carrier of the XLR1 mutation and, according to clinical sings, X chromosome exclusion might have happened. Another case has also been presented about three members of a Colombian family with X-linked retinoschisis, homozygotes. A deletion of (639 delG) base happened, which in the process of translation resulted in the creation of a longer protein with an altered cellular function [4]. The remaining cases of retinoschisis include autosomal dominant or autosomal recessive linked retinoschisis [5]. This form of transmission is far rarer. Clinically, despite variation in the severity of the manifestation of the disorder, the affected members of the family almost always present with peripheral retinoschisis and presence of peripheral degenerative changes.

ERG is an important examination in the diagnosing of juvenile retinoschisis, although there is certain heterogeneity in the ERG response. Often there is no strict correlation in terms of the clinical picture, visual acuity and in relation to genotype, hence it could not be considered a unique and specific examination in XLR1 [2,3].

OCT has proven to be a very useful method in visualization of the retinoschisis changes in the macular region of the retina. Delaying in the superficial as well as deeper

layers of the retina can be visualized [2,10]. A typical finding is the existence of palisade sections between retinal layers, which has also been found in our patient along with cystic formation in the perifoveal area. Genetic tests, which are positive in 90-95% of the cases, are very important for confirming the diagnosis. However, due to various reasons, they are not always available.

OCT findings in our patient and the absence of late fluorescence have confirmed macular retinoschisis. However, of utmost importance and discrimination in establishing the diagnosis, in addition to macular changes, were the changes in the medial retina and the vitreous body. The presence of even relatively discreet and modest changes in the vitreous body, in terms of degenerative changes in the formation of lacunae and rougher network of collagen fibrils, combined with the changes around the retinal vascular arcades that were evident on fluorescein angiogram, indicated this to be a case of Goldmann-Favre vitreoretinal degeneration, a disorder in which macula lutea retinoschisis type changes are imminent [6-8]. Goldmann-Favre degeneration is a hereditary recessive disorder caused by mutation of a photoreceptor NR2E3 specific transcription factor. The disease is characterized by the so-called night blindness, changes in the pigment epithelium in the area around the vascular arcades of the medial retina and degenerative changes in the vitreous body. On biomicroscopy, and even more evident on fluorescein angiogram, our patient had changes associated with this disorder, and thus she was diagnosed in that regard.

Goldmann-Favre degeneration is a progressively autosomal hereditary recessive disorder. In a large number of patients, the disease is manifested in the first two decades of life. Mutation of the NR2E3 gene encodes the retinal nuclear receptor which is important in the differentiation of photoreceptors [8].

The diagnosis is based on clinical findings, fluorescein angiogram, autofluorescence, a faded electroretinogram and an optical coherence tomography [7,8].

In the past few decades, there have been attempts of medicinal treatment of this disease. In the literature there are also data on the application of dorzolamide for juvenile macular retinoschisis [11], which by analogy to the situation of our patient, a local therapy with dorzolamide eye drops was prescribed. Unfortunately it proved ineffective in improving her vision.

Therapeutic possibilities are still limited and aimed at attempts to treat retinoschisis with gene therapy. Besides the fact that the correct diagnosis of the disorder frequently has no importance in the sense of therapeutic possibility of the disease, its value can be seen in proper information of possibility of disease transmission as well as in prediction of affected person's life perspective, associated with the decrease of visual acuity.



The aim of this paper is, by presenting a case with a rare hereditary disorder, to show the importance and complementarities of diagnostic methods, especially OCT and its meaning in establishing the correct diagnosis.

## Conclusions

Eye fundus examination with the widely accepted method of optical coherence tomography is of great importance in the diagnosing of macula lutea disorder, and the importance and complementarity of the other diagnostic methods have already been established in the differentiation of similar conditions. Discrimination and diagnostics of similar conditions of eye fundus are important in the treatment of the condition as well as in counseling for genetic examination and suggestion for transmission of the disease onto the progeny.

*Conflict of interest statement.* None declared.

## References

1. Edwards AO, Robertson JE. X-linked juvenile retinoschisis. Hereditary vitreoretinal degenerations. In: Ryan SJ, Hinton DR, Schachat AP, Wilkinson CP, editors. *RETINA*. 4th ed. Philadelphia: Elsevier Mosby 2006; 524-528.
2. Sikkink SK, Susmito Biswas S, Parry NRA, Stanga PE, Trump D. X-linked retinoschisis: an update. *J Med Genet* 2007; 44(4): 225-232.
3. Al-Swaina N, Sawsan R, Nowilaty SR. Macular hole in juvenile X-linked retinoschisis. *Saudi J Ophthalmol* 2013; 27(4): 283-286.
4. Mendoza-Londono R, Hiriyanna KT, Bingham EL, *et al.* A Colombian family with X-linked juvenile retinoschisis with three affected females finding of a frameshift mutation. *Ophthalmic Genet* 1999; 20(1): 37-43.
5. Yassar Y, Nissenkom I, Ben-Sira I, *et al.* Autosomal dominant inheritance of retinoschisis. *Am J Ophthalmol* 1982; 94(3): 338-343.
6. Schorderet DF, Haider N, Escher P. NR2E3-linked retinal degeneration: Enhanced S-cone Sensitivity, syndrome, Goldmann-Favre syndrome, Clumped Pigmentary Retinal Degeneration and Retinitis Pigmentosa. In: Traboulsi IE. *Genetic Diseases of the Eye New York: Oxford University Press* 2012; 437-447.
7. Bhandari M, Rajan R, Tandava Krishnan P, *et al.* Morphological and Functional Correlates in Goldmann-Favre Syndrome: A Case Series. *Korean J Ophthalmol* 2012; 26(2): 143-146.
8. Ikaheimo K, Tuppurainen K, Mantyjärvi M. Clinical features of Goldmann-Favre syndrome. *Acta Ophthalmol Scand* 2003; 77(4): 459-461.
9. Theodossiadis PG, Koutsandrea C, Kollia AC, Theodossiadis GP. Optical coherence tomography in the study of the Goldmann-Favre syndrome. *AJO* 2000; 129(4): 542-544.
10. Lumbroso B, Rispoli M. Macular retinoschisis. In: Lumbroso B, Huang D, Romano A, Rispoli M, Coscas G. *Clinical and face OCT atlas*. Dhaka-Bangladesh: *Nighlights Medical Publishers Ltd* 2013; 129-132.
11. Khandhadia S, Trump D, Menon G, Lotery AJ. X-linked retinoschisis maculopathy treated with topical dorzolamide, and relationship to genotype. *Eye* 2011; 25(7): 922-928.

