

# laser



international magazine of laser dentistry

1 2015

## | research

Modification of tooth neck dentin with a diode laser for desensitisation

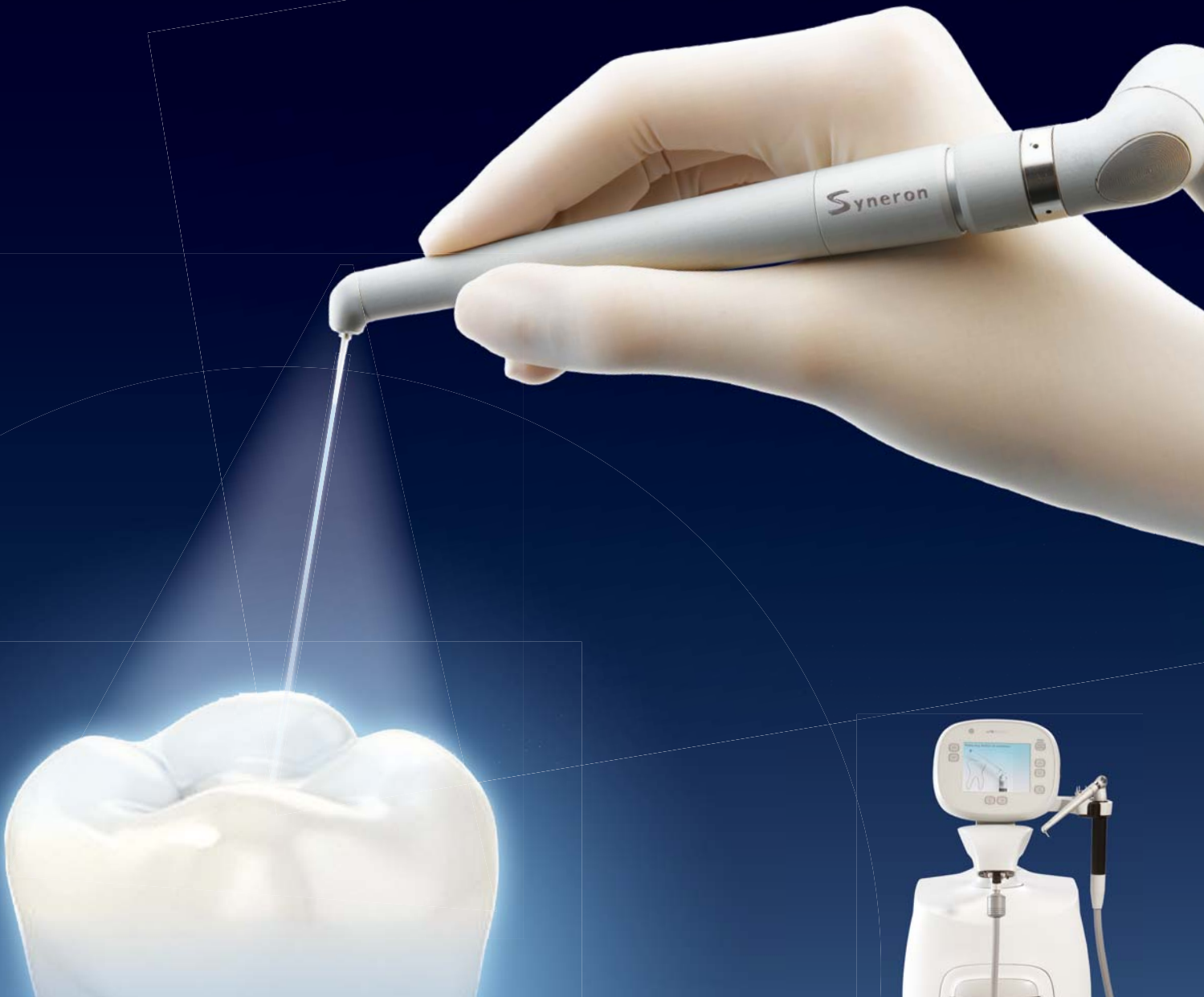## | case report

Laser assisted crown lengthening in the anterior maxilla

## | industry report

The TwinLight® approach to periimplantitis

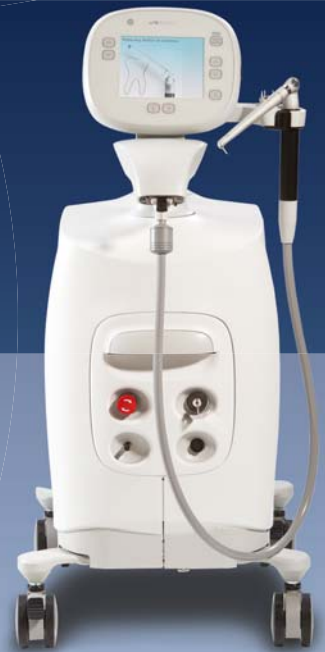



# LITETOUCH<sup>TM</sup>

Er:YAG Laser-in-Handpiece

Dentists' Choice for Hard & Soft Tissue Procedures



To learn more about our innovative technology solutions,  
contact: [dental@syneron.com](mailto:dental@syneron.com), [www.synerondental.com](http://www.synerondental.com)



# Let's try again!



Prof. Dr. Norbert Gutknecht  
Editor-in-Chief

Dear reader,

First of all, I would like to wish you a happy, healthy and blessed New Year 2015.

The prevalence of antimicrobial resistance is increasing and has been a topic of much debate recently. The results associated with this are not yet known, but are certainly more severe than described in the official media. High concentrations of antibiotic residues are ingested not only via food (meat in particular) but also owing to careless patient prescriptions. As a responsible and future-oriented practitioner, one should seriously consider relevant antibiotic alternatives.

With most laser systems used in today's dentistry, it has become possible to reduce the administration of antibiotics or even omit them entirely. This is an option particularly in periodontology, peri-implantitis therapy, endodontics and several areas of oral surgery. As scientific studies have demonstrated, bacterial reduction with laser devices is so efficient that post-operative healing is both faster and longer lasting. Based on this knowledge, we should aim for more intensive integration of laser technology in the different fields of dentistry.

Numerous congresses organised by our scientific laser society, as well as specialist continuing education events, dealing with the above-mentioned topic offer you opportunities to deepen your knowledge in this area. Announcements of these events will be published in our respective journals.

With this in mind, I am looking forward to welcoming you to one of our congresses or continuing education events.

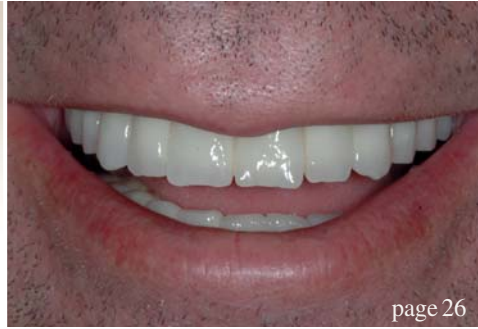Best regards,

A handwritten signature in black ink, appearing to read 'Norbert Gutknecht'. The signature is fluid and cursive, written on a light-colored background.

Prof. Norbert Gutknecht  
Editor-in-Chief



page 6



page 26



page 32

| editorial

03 Let's try again!  
| Prof. Dr Norbert Gutknecht

| research

06 Modification of tooth neck dentin with a diode laser for desensitisation  
| Dr Ute Ulrike Botzenhart

| case report

16 Laser assisted crown lengthening in the anterior maxilla  
| Ana Minovska *et al.*

20 Gingival plastic with diode laser—A case report  
| Ioannis Papadimitriou *et al.*

| industry report

26 The TwinLight® approach to peri-implantitis  
| Dr Ilay Maden *et al.*

| practice management

32 Gain power at your laser clinics!  
Physical evidence and place  
| Dr Anna Maria Yiannikos

34 Clinical governance—A system for better health care  
| Dr Kashif Hafeez

| interview

36 Lasers are becoming increasingly prevalent in dentistry  
| Dental Tribune International

| meetings

38 IDS 2015: new exhibitor record and increased exhibition space

| news

30 Manufacturer News international

42 News international

| DGL

45 Auf ein Neues!  
| Prof. Dr. Norbert Gutknecht

46 Manufacturer News germany


48 News germany

| about the publisher

50 | imprint



Cover image courtesy of Fotona, [www.fotona.com](http://www.fotona.com)



page 36

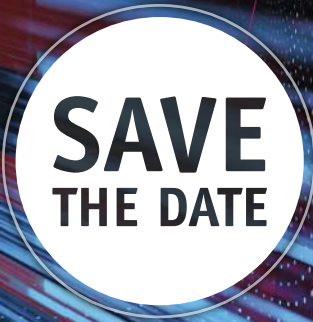

page 38



page 42





November 27–28, 2015  
Berlin, Germany  
Hotel Palace

# 24<sup>th</sup> Annual Meeting of the DGL

## LASER START UP 2015



[www.dgl-jahrestagung.de](http://www.dgl-jahrestagung.de)



[www.startup-laser.de](http://www.startup-laser.de)



### Fax Reply

+49 341 48474-290

I would like to receive further information on the

- 24<sup>th</sup> Annual Congress of the DGL e.V.     LASER START UP 2015

on November 27–28, 2015 in Berlin, Germany.

Name & email address

Practice Stamp

laser 1/15

# Modification of tooth neck dentin with a diode laser for desensitisation

Author\_Dr Ute Ulrike Botzenhart, Germany

“Cervical dentin hypersensitivity is a common phenomenon of discomfort, which affects an increasing number of young adults.”



[PICTURE: ©VLADIMIR GJORGIEV]

Cervical dentin hypersensitivity is a common phenomenon and affects an increasing number of young adults. Today, more than 30% of the adult population in industrialised nations is affected, but the number of unreported cases is presumably much higher and treatment demand is increasing.<sup>1</sup> Patients who are affected report intense and sharp pain of short duration during eating or dental hygiene, for example, that cannot be ascribed to any other form of dental defect or disease.<sup>2</sup> Dentine hypersensitivity is associated with exposure of dentine at the cemento-enamel junction and can be explained by the combined effect of several aetiological factors, such as erosion, abrasion and attrition

with erosion as the main factor.<sup>3,4</sup> Other factors, like microbiological invasion of exposed dentinal tubules with accompanying inflammation of pulpal tissue, functional overload, traumatic toothbrushing and whitening of vital teeth, also appear to be involved.<sup>5,6</sup>

To date, the commonly accepted theory of pain transmission is still Brännström's hydrodynamic theory.<sup>7</sup> It states that chemical, mechanical, osmotic and thermal stimuli induce fluid flow in exposed dentinal tubules, activation of mechanoreceptors at the pulp-dentine border and finally activation of pain fibres. The structure of the dentinal surface is

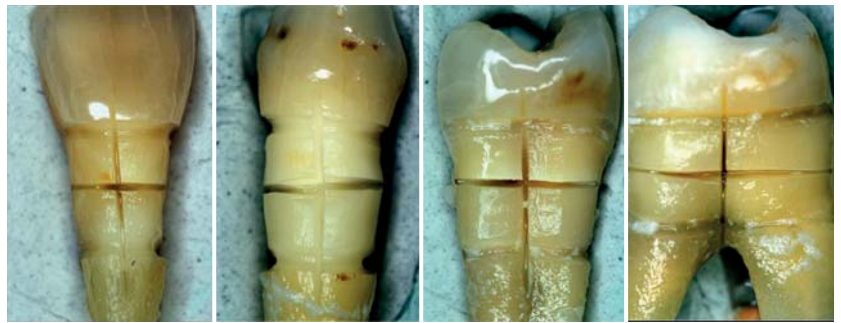

an important factor of this mechanism.<sup>8</sup> Examination of tooth necks under a scanning electron microscope (SEM) has shown that affected teeth had eight times as many exposed tubules with a diameter twice the size compared with non-sensitive dentine.<sup>8</sup> By demonstrating that the density of sensitive nerve fibres is correlated to pain intensity of a sensitive tooth,<sup>9</sup> it is also assumed that, in addition to the hydrodynamic theory, other mechanisms, such as nerve stimulation, could be involved. Thus, inflammation mediators could make nerve endings more sensitive to mild stimuli, which could induce pain.<sup>10</sup> Nevertheless, the precise physiological mechanisms underlying dentine hypersensitivity are not clearly understood yet,<sup>11, 12</sup> and despite intensive research, constant improvement of therapy methods and active substances, reports still show that there is difficulty controlling this painful condition.<sup>11</sup>

Laser treatment of dentine hypersensitivity alone or in combination with conventional treatments is a new promising option for rapid and durable pain relief.<sup>13</sup> Depending on the laser type and energy settings used, the actual reported effects of laser desensitisation are morphological alteration of the dentinal structure, for example a closure of the dentinal tubules by melting and resolidification of the dentinal structure; laser dehydration with protein deposition or deposition of insoluble salts in the dentinal tubules; as well as bio-stimulation, for example nerve analgesia, induction of sclerosis and secondary dentine formation; and placebo effects. Recently, great effort has also been made to integrate tooth structure-like components into the tooth surface with the help of laser radiation.<sup>11, 14-17</sup>

However, on account of the high temperature increase, these methods are not suitable for clinical application<sup>11, 16</sup> and too little is known about the long-term morphological and clinical effects of laser application to recommend the therapy.

The aim of our study was to examine the effects of a diode laser with a wavelength of 809 nm in the treatment of dentine hypersensitivity in terms of morphological changes. The ability of this type of laser to close open dentinal tubules, its suitability as a method for dentinal sealing, as well as the induction of recognisable morphological side-effects in the dentinal structure using this laser, were tested *in vitro*. Furthermore, the effect of laser-fluoride application was compared with single treatment options, and the acid resistance of the tested treatment modalities (fluorides, laser, and laser-fluoride treatment) was evaluated by the method of pH-cycling.



## Material and methods

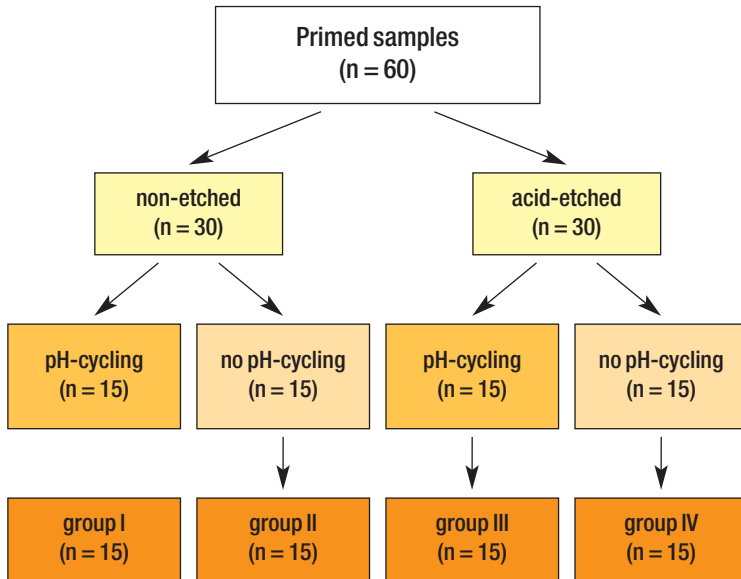
The samples used were extracted human teeth drawn from a pool of extracted teeth collected for dental research at the University Bonn, Dental Clinic once informed consent had been obtained. Surgical treatment was not linked to research in any way. All experiments were *in vitro*; hence, there were no potential risk factors to human health.

Immediately after extraction, the teeth were stored in a sodium chloride solution (0.9% NaCl, Delta-Pharma) with 0.01‰ sodium acid added and kept refrigerated at 5 °C to prevent the teeth drying out and to minimise bacterial and chemical decomposition. Teeth without carious lesions at the tooth neck and root surface ( $n = 60$ ) were divided into four groups of 15 teeth by random selection. Every test group had the same number of incisors, canines, premolars and molars from the maxillae and mandible (four maxillary incisors, one maxillary canine, two maxillary premolars, two maxillary molars, one mandibular canine, three mandibular molars and two mandibular third molars). The incisors of the mandibular arch were exchanged for third molars because the small root surface did not allow preparation of a quadrangle. The experimental surface was located at the vestibular, mesial or distal side of the root surface. Four quadrants were marked in the cervical area (Fig. 1).

Enamel and root cementum were completely removed with diamond burs under water-cooling (INTRAmatic LUX 24, KaVo) by one operator to simulate hypersensitive dentine. With removal of a 1 mm layer, we assumed that all dentinal tubules had been totally exposed. The sample surface was smoothed with a Gracey curette (#7-8; Thico-dent) and divided into quadrangles with a diamond separating disc (0.5 mm thick) under water-cooling (INTRAmatic 10 C, KaVo; Fig.1).

Groups 3 and 4 underwent a pretreatment (acid etching with 50% citric acid for 2 minutes, rinsing with distilled water for 30 seconds) to remove the smear layer created by preparation.

**Fig. 1** Samples of (a) Incisor, (b) Canini, (c) Premolar and (d) Molar after quadrangle preparation in the tooth neck area.



**Fig. 2** Flow chart to illustrate group assignment with the help of test procedure.

The test groups were as follows (Fig. 2): Groups 1 and 2 with smear layer and Groups 3 and 4 with removal of the smear layer. Quadrant 1 of each sample underwent laser application. Quadrant 2 underwent laser application followed by fluoridation. Quadrant 3 underwent fluoridation exclusively. Quadrant 4 was left untreated as a control.

The diode laser used had a wavelength of 809 nm (ORA-Laser 01 I.S.T., ORALIA). The parameters were chosen according to Gutknecht et al.,<sup>18</sup> who used an Nd:YAG laser for cervical desensitisation, because the action mechanism of both laser types is approximately similar.<sup>19</sup> The laser parameters were 1 W, 10 Hz and 60 seconds in contact mode with a 400 µm fibre in an overlapping flap. The surface of each quadrant was approximately 3–5 mm<sup>2</sup>. Owing to the penetration depth of the laser radiation used, an absorber (Contactin CO) was also used in 50% of the samples. For fluoridation, we used Bifluorid 12 (VOCO), which was left to react for 1 minute and afterwards rinsed with water spray.

**Tab.1** Results of statistical analysis of the histological examination of group I (with smear layer, with pH-cycling) and group III (without smear layer, with pH-cycling); p = 0.05.

After the treatment, all teeth of Groups 1 and 3 underwent pH-cycling for ten days according to Ten Cate et al.<sup>20</sup> as a post-treatment to simulate the conditions of the oral cavity. The teeth subsequently underwent histological and SEM examination.

	Mann-Whitney-U-Test (laser with absorber – laser without absorber)	Friedmann-Test
group I	p > 0.05	p < 0.05
group III	p > 0.05	p > 0.05

*SEM examination*

Six samples from each group (n = 6), three with and three without absorber application prior to laser treatment, were prepared for SEM examination. We used the replica technique to evaluate morphological changes and to make it possible to perform histological examination of the samples afterwards. For the replica technique, we took impressions of the samples with a light-body silicone (PRESIDENT PLUS JET light body, Coltène AG), allowed them to dry for four weeks and cast them in epoxy resin (Stycast 1266, Part A + B, T-E-Klebetchnik). The resin samples were attached to a table for SEM examination, sputter coated with a thin layer of platinum (15 W and 22 mA for 70 seconds) and mounted on the specimen stub with a conductive bridge using a special adhesive for SEM examination (Leit-C nach Görke, Neubauer Chemikalien) to ensure electrical grounding.

The observation of the samples was performed under high vacuum and in direct mode at an angle of 40 degrees, an accelerating voltage of 10 kV and 3 A, and at a magnification of 2,000x.

*Histological examination*

All samples (n = 60) were prepared for histological examination by formalin fixation (4%, pH of 6.9), followed by dehydration in alcohol of progressive concentrations, embedding in Technovit 7200 VLC (Heraeus Kulzer), cutting, grinding (EXAKT grinding unit), fixation to an object plate (Technovit 4000 VLC, Heraeus Kulzer) and burnishing to a thickness of 20–30 µm each, so that every preparation contained two quadrants of each sample. The sections were dyed with toluidine blue according to Donath et al.<sup>21</sup> and analysed with the DIALUX 20 EB (LEITZ) light microscope at a magnification of 25x. Four samples had to be excluded afterwards because of artificial alterations or incomplete removal of the enamel or root dentine, which could only be detected with light microscopy. Therefore, 56 samples with four quadrants each were examined histologically.

*Statistical analysis*

For histological examination, we used non-parametric tests (Mann-Whitney test, Friedman test and Wilcoxon signed-rank test). The various morphological effects we found under SEM examination were first analysed qualitatively by one operator and then analysed using the chi-square test. For all statistical analyses, we used SPSS (IBM Software) and the significance level was p = 0.05.

**\_Results**

*Histological examination*

In the histological examination, major structural changes in the dentine were not observed, regard-



less of the treatment modality we used. After laser irradiation, no carbonisation, cracks or other side-effects could be detected.

In Groups 2 and 4 (without pH-cycling), no structural effects were observed, whereas changes of different width indicated by staining were recorded in Groups 1 and 3 (with pH-cycling). These patterns were measured at three points and the average value was calculated (Fig. 3). With the help of a measuring scale, the width of these patterns was converted into micrometres. There was no statistically significant difference between the effect of the laser with or without absorber application in Groups 1 and 3 (Mann-Whitney test,  $p > 0.05$ ; Table 1). In Group 3 (without a smear layer), no statistically significant differences between the different surface treatments and the width of the pattern were observed (Friedman test,  $p > 0.05$ ; Table 1), whereas statistically significant differences in Group 1 (with a smear layer) in the width of the pattern were found (Friedman test,  $p < 0.05$ ; Table 1) after fluoridation and after laser irradiation (Wilcoxon signed-rank test,  $p < 0.05$ ; Mann-Whitney test,  $p < 0.05$ ; Table 2). After fluoridation, the average width of these patterns was approximately 43  $\mu\text{m}$  compared with 60  $\mu\text{m}$  after laser irradiation.

#### SEM examination

Under SEM examination, ultrastructural changes in the dentinal structure were observed. Six different structural and morphological markers were recorded:

1. Wide-open tubules (Fig. 4a)
2. Partly occluded or narrowed tubules (Fig. 4b)
3. Surfaces with impressions of tubule orifices (Fig. 4c)
4. Smooth and unstructured surfaces (Fig. 4d)
5. Surfaces with superficial precipitation (Fig. 4e)
6. Melted surfaces (Fig. 4f).

In a few cases, cracks and superficial pellets were observed, but the results were not predictable. After qualitative analysis of these structural changes, statistical analysis was performed using the chi-square test ( $p = 0.05$  significance level).

No statistically significant differences between laser application in Groups 1–4 with or without absorber application (chi-square test,  $p > 0.05$ ) and in Groups 1, 2, 3 and 4 with and without absorber application prior to laser treatment combined (chi-square test,  $p > 0.05$ ) were observed (Table 3).

AD

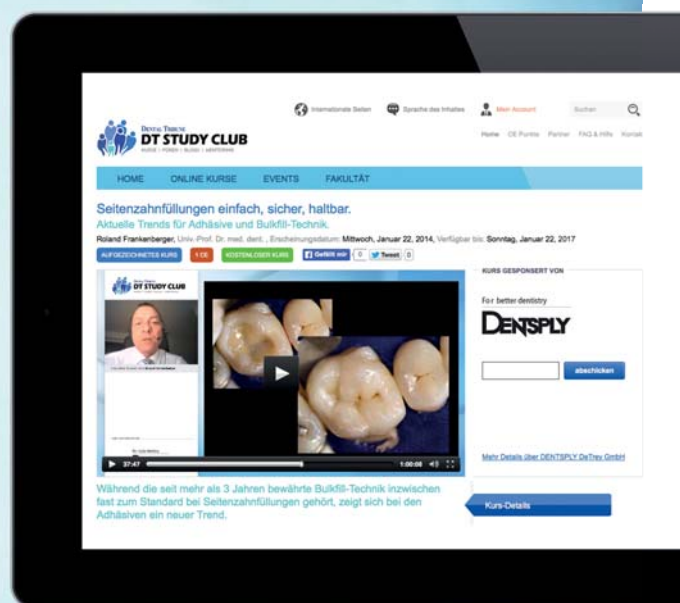
# Join the largest educational network in dentistry!

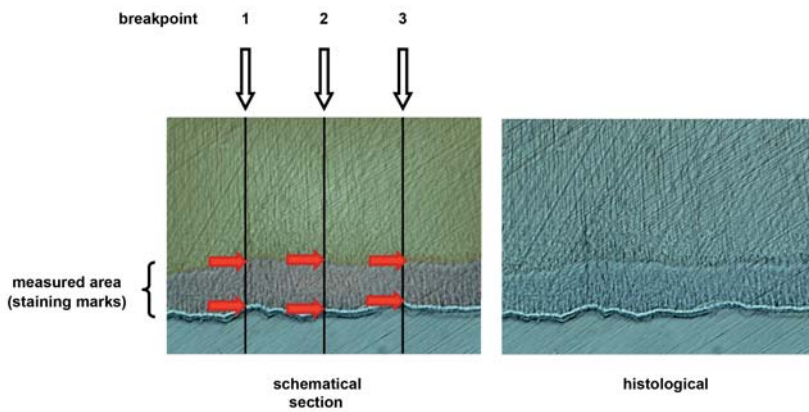


Register for  
**FREE!**

- education everywhere and anytime
- live and interactive webinars
- more than 500 archived courses
- a focused discussion forum
- free membership
- no travel costs
- no time away from the practice
- interaction with colleagues and experts across the globe
- a growing database of scientific articles and case reports
- ADA CERP-recognized credit administration

[www.DTStudyClub.com](http://www.DTStudyClub.com)





**Fig. 3** Left side: Schematic illustration of the detected pattern with breakpoints. White arrows are showing the measure points (black lines); red arrows illustrate the width of the pattern (red band); deep dentin is marked in yellow. Right side: Original specimen.

Furthermore, we analysed samples in relation to pre- and post-treatment, that is, with smear layer removal and pH-cycling. Figure 2 provides an overview of the pre- and post-treatment classification of the groups. In all samples with a smear layer (Groups 1 and 2 combined), no statistically significant differences were observed (chi-square test,  $p > 0.05$ ; Table 3), whereas statistically significant differences between the treated quadrants in all samples with the smear layer removed (Groups 3 and 4 combined) were detected (chi-square test,  $p < 0.05$ ; Table 3). After laser application and after laser-fluoride application, fewer wide-open and partly occluded tubules, and smooth and unstructured surfaces were observed. Melted surfaces predominantly were detected after laser and after laser-fluoride application. Regarding all samples with pH-cycling (Groups 1 and 3 combined) and without pH-cycling (Groups 2 and 4 combined), no statistically significant differences were observed (chi-square test,  $p > 0.05$ ; Table 3).

### Discussion

The histological and SEM examinations demonstrated that the application of a diode laser (809 nm, 1 W, 10 Hz, 60 seconds) did not induce harmful mor-

phological changes in the dentinal structure, but led to ultrastructural modification of the superficial dentinal layer. Since the degree of pain is strongly correlated to the number of open tubules at the dentinal surface<sup>10</sup>, removal of the smear layer prior to treatment best simulated hypersensitive dentine. Accordingly, under SEM examination, a great number of open tubules were observed in the control quadrants in Groups 3 and 4.

#### Results after laser-fluoride treatment

Laser-treated surfaces with a smear layer showed narrowing or complete closure of the dentinal tubules, but the results were not statistically significant. In comparison to the control and fluoridation, a statistically significant reduction in the number of open tubules was found after laser and laser-fluoride treatment of acid-etched surfaces. This demonstrated that laser application can induce sealing of hypersensitive dentine to some extent. These results are in accordance with those of Umana et al.,<sup>19</sup> who evaluated the effect of 810 nm, among others, diode laser application (Claros Nano, Elnexion) at different energy settings on human dentinal surfaces after removal of the smear layer. With an energy setting of between 0.8 W and 1 W (continuous wave, non-contact mode for 10 seconds), they found a narrowing of dentinal tubule orifices, and hence deduced that the diode laser was able to seal dentinal tubules.

In our study, melted surfaces predominantly were detected after laser application with statistical significance in Groups 1 and 3. Laser application followed by fluoridation appeared to enhance the occluding effects, but this was not of statistical significance. Melting of dentinal surfaces after laser application using different parameters with or without fluoridation has also been described previously,<sup>22-24</sup> Marchesan et al.<sup>25</sup> too demonstrated such a melting

**Tab. 2** Results of statistical analysis of the histological examination of group I (with smear layer, with pH-cycling);  $p = 0.05$ .

	Wilcoxon-Test	Mann-Whitney-U-Test
laser + fluoridation – laser (with/ without absorber)	$p > 0.05$	$p > 0.05$
fluorides – laser (with/ without absorber)	$p > 0.05$	$p > 0.05$
control – laser (with/ without absorber)	$p > 0.05$	$p > 0.05$
fluorides – laser + fluorides (with/ without absorber)	$p > 0.05$	$p > 0.05$
control – laser + fluorides (with/ without absorber)	$p > 0.05$	$p > 0.05$
control – fluorides (with/ without absorber)	$p > 0.05$	$p > 0.05$



# Master of Science (M.Sc.) in Lasers in Dentistry

Next Start: **21<sup>st</sup> September 2015**  
Aachen, Germany  
4 semesters

## Become part of the International Dental Elite

- Create new economic potential for your practice
- Two year career-accompanying postgraduate programme at the University of Excellence RWTH Aachen
- Combination of lectures, skill training sessions, live ops, tutorials, and practical workshops
- Internationally accepted and accredited by the German Government, the European Union, the Washington Accord and the Bologna Process
- Science-based and practice-orientated on highest national and international level
- Increased patient satisfaction: minimal contact reduced vibration and pain



**RWTH INTERNATIONAL ACADEMY**  
**AACHEN UNIVERSITY**

RWTH International Academy  
Kackertstraße 10 | 52072 Aachen | Germany  
phone +49 241 80 23543 | fax +49 241 80 92525  
info@academy.rwth-aachen.de  
www.academy.rwth-aachen.de

**PROFESSIONAL EDUCATION PROGRAMMES**



**Aachen Dental Laser Center**

AALZ GmbH  
Pauwelsstraße 17 | 52074 Aachen | Germany  
phone +49 241 47 57 13 10 | fax +49 241 47 57 13 29  
info@aalz.de  
www.aalz.de



effect after laser irradiation of water-filled root canals with a diode laser (980 nm).

*Comparison with Nd:YAG laser application*

The appearance of a smooth, unstructured surface with few wide-open or partly occluded tubule orifices after diode laser application and diode laser-fluoride treatment is comparable to the effects of Nd:YAG laser application, which is already known for its ability to close dentinal tubules<sup>26</sup> and for its sealing effects on root dentine.<sup>23</sup> A direct comparison of these two laser types by irradiating root canal dentine found morphological changes, such as melting and setting of the dentinal surface, but without any statistically significant differences between both laser types.<sup>27</sup>

In our study, laser-fluoride application was not found to be statistically significantly superior to laser irradiation alone. However, such a tendency could be seen. In the literature, we can also find no clear results concerning this, but a combined treatment is preferred in most cases.<sup>28,29</sup> A combined *in vivo* application of Nd:YAG laser and fluoridation, for example, achieved an improvement of symptoms that correlates to the *in vitro* reduction of open tubule orifices.<sup>30</sup>

*Effects after additional absorber application*

Although the application of an absorber prior to laser treatment enhanced the absorption at the sur-

face,<sup>31</sup> in some cases under SEM examination after laser application isolated side-effects, such as cracks, were detected, and this phenomenon could possibly be traced back to the absorber effect. In their study, Umana et al.<sup>19</sup> proved that the additional application of an absorber enhanced the laser effects, resulting in areas of fusion, melting and narrowing of the tubules, when energy settings of 0.8 W and 1 W were used. At higher energy settings (1.6 W and 2 W), not only complete occlusion of the tubules, but also cracks, dental ablation, craters and loss of substance could be seen.<sup>19</sup> The occurrence of side-effects with the 1 W output power used in our study could probably be explained by the longer exposure time of 60 seconds compared with 10 seconds in Umana et al.'s study.

Since we only observed superficial effects, we could not evaluate the penetration depth of the detected cracks. Concerning the histological examination, no cracks were found, so we assumed that they were only located in the very superficial dentinal layer and therefore of negligible clinical relevance. Concerning safety and clinical effectiveness, the energy setting of 1 W does not exceed the safety level of 3 °C for pulp injury and is harmless for pulp vitality.<sup>19</sup> Human *in vivo* studies have shown that the diode laser can be a useful instrument in clinical dentine desensitisation.<sup>32-36</sup>


The clinical effectiveness was approximately 86-88% with no differences between the different laser parameters used.<sup>36</sup> An exposure time of 60 seconds, compared with shorter irradiation times, clinically results in immediate pain relief.<sup>33</sup> No side-effects were observed<sup>34</sup> and a persistent clinical reduction of dentine hypersensitivity after laser use was observed during the follow-up period of up to six months.<sup>32,34</sup>

*Results with and without pH-cycling*

With the energy settings used in our study, side-effects were neither predictable nor statistically significant. In general in our study for all treatment groups, no statistically significant improvement was achieved by the additional use of an absorber prior to laser application or with laser-fluoride application, and absorber application did not induce additional detectable morphological effects at the surface in the majority of cases.

Under SEM examination, no statistically significant morphological differences between cycled and non-cycled groups were observed, whereas patterns of different width were detected after pH-cycling of non-etched and acid-etched samples under histological examination. The acid resistance of tooth surfaces can be detected with pH-cycling. From other studies, it is known that the application of fluorides can enhance the acid resistance of dental surfaces.<sup>37,38</sup>

**Fig. 4** Overview of the detected morphological effects in SEM examination after experimental setup (2000x, 40°). (a) wide opened tubuli, (b) partly opened tubuli, (c) impressions of tubuli orifices, (d) unstructured and smooth surface, (e) precipitates, (f) melted surface.



	Chi-square-Test (laser application with absorber) n = 3	Chi-square-Test (laser application without absorber) n = 3	Chi-square-Test (laser application with/without absorber) n = 6	Chi-square-Test n = 12
group I	p > 0.05	p > 0.05	p > 0.05	
group II	p > 0.05	p > 0.05	p > 0.05	
group III	p > 0.05	p > 0.05	p > 0.05	
group IV	p > 0.05	p > 0.05	p > 0.05	
group I+II (with smear layer)				p > 0.05
group III+IV (without smear layer)				p < 0.05
group I+III (with pH-cycling)				p > 0.05
group II+IV (without pH-cycling)				p > 0.05
group I-IV (with absorber)				p > 0.05
group I-IV (without absorber)				p > 0.05

The dimension of the pattern we detected after pH-cycling in Groups 1 and 3 was not dependent on removal of the smear layer. In fact, it was dependent on pH-cycling, because without pH-cycling (Groups 2 and 4) such a pattern could not be detected. Concerning these facts, the width of detected patterns in this study could be associated with demineralisation and remineralisation and be connected to the acid resistance of the treated dentinal samples. We assumed that the width of the pattern was inversely proportional to acid resistance; that is, it is consistent with the amount of demineralisation. Thus, an enhancement of acid resistance was demonstrated with reduced pattern width. This was the statistically significant finding after fluoridation compared with laser application in Group 1. We assumed that on surfaces with a smear layer fluorides were more easily incorporated into the dentinal surface and served as a depot. This was first used up after acid contact. In the histological examination, reduced demineralisation width was observed for this reason. In patients with hypersensitive tooth necks, in most cases, a relatively uniform and amorphous smear layer is missing, there are more areas with wider tubule orifices and sometimes even loss of intertubular dentine compared with non-sensitive tooth necks.<sup>39</sup>

Clinical observations have demonstrated at least a temporary reduction of pain after a single fluoride application.<sup>32</sup> So the question is, whether the effects detected after pH-cycling and fluoridation can enhance and sustain acid resistance *in vivo*.

#### *Acid resistance after fluoride application*

Our study demonstrated a statistically significant association between fluoride application and an enhancement of acid resistance on smear layer-afflicted surfaces only. With removal of the smear layer, no differences between the treatment modalities were observed. We assumed that fluoridation of a surface without a smear layer did not exceed the effects achieved with laser application or laser-fluoride treatment. Clinical investigations of such a combined treatment with fluoridation found no additional positive effect,<sup>34</sup> and this result is in agreement with the morphological findings of our *in vitro* study. Furthermore, laser application or a combined treatment on acid-etched surfaces was not inferior to fluoridation alone. An improvement in acid resistance has been observed when fluorides are applied prior to laser application.<sup>40</sup> Hsu et al.<sup>22</sup> demonstrated such a combined treatment with melting and setting of the dentinal surface in an *in vitro* study. Further

**Tab. 3** Results of statistical analysis of morphological effects depending on surface treatment in SEM examination; p = 0.05.

analysis demonstrated that laser application could stove constituents of the smear layer to the dentinal surface so that there was an integration of fluorides and of parts of the smear layer.<sup>24</sup>

In our study, we applied fluorides after laser irradiation; therefore, stoving was not likely. Nevertheless, we assumed that fluorides were more easily integrated into the lased surface, which served as a depot and improved acid resistance to some extent.

## Conclusion

Diode laser desensitisation of exposed tooth necks following the treatment protocol we used was not accompanied by major side-effects and led to a variety of morphological effects, which appear to be useful for sealing hypersensitive dentine and increasing acid resistance in some areas. In light of possible additional biostimulatory effects, it may even offer a treatment alternative to the application of fluorides only. However, further studies are necessary to prove the quality of the described morphological effects under clinical conditions.

## Acknowledgments

I would like to thank the AMLaReBO (Centre of Applied Medical Laser Research and Biomedical Optics, Bonn), the research platform RIsources (The research Infrastructure Portal) funded by the DFG (Deutsche Forschungsgemeinschaft) for material support and the consistent professional support and helpful hints by Prof. Dr M. Frentzen, PD Dr A. Braun during the experiments and realisation of the study as well as Mrs M. Lange for technical support. This work had not been possible without their help. The authors claim no conflict of interests.

## contact

### Dr Ute Ulrike Botzenhart

Fetscherstr. 74  
01307 Dresden, Germany  
Tel.: +49 351 4584481  
Fax: +49 351 4585318

Ute.Botzenhart@uniklinikum-dresden.de

## Kurz & bündig

Zahnfleischüberempfindlichkeit ist ein allgemeines Problem und stellt eine der häufigsten schmerzverursachenden Symptomatik dar.<sup>1</sup> In vorliegender Studie wurden morphologische und histologische Effekte sowie eine mögliche Dentinversiegelung nach *In-vitro*-Anwendung eines 809-nm-Diodenlasers zum Verschluss offener Dentintubuli im Zahnhalsbereich evaluiert.

Als Versuchspräparate dienten dabei extrahierte menschliche Zähne, die in 4 Gruppen aufgeteilt wurden. Zur Simulation überempfindlichen Dentins wurden im Zahnhalsbereich Schmelz und Zement mit einem Diamantbohrer abgetragen und ein Versuchsfeld mit je 4 Quadranten präpariert. In Gruppe I und II wurde die entstandene Schmierschicht belassen, während diese in Gruppe III und IV mittels Säureätzung entfernt wurde. Quadrant 1 und 2 wurden mit einem Diodenlaser bestrahlt. Quadrant 2 und 3 wurden anschließend fluoridiert. Quadrant 4 blieb als Kontrolle unbehandelt. Bei 50 Prozent der Proben wurde vor der Laserapplikation zusätzlich ein Absorber appliziert. Alle Proben der Gruppe I und III wurden anschließend zur Überprüfung der Säurefestigkeit für zehn Tage einer Wechselbehandlung unterzogen. Die histologische und rasterelektronenmikroskopische Auswertung erfolgte sowohl qualitativ als auch mittels Chi-Quadrat-, Mann-Whitney U- und Friedman-Test.

Wie die histologische Untersuchung zeigte, wurden keine Risse, Karbonisierungen oder andere Laser-Nebeneffekte festgestellt. Verglichen mit den Gruppen ohne Wechselbehandlung, die keine Effekte erkennen ließen, zeigten die Gruppen mit Wechselbehandlung Veränderungen unterschiedlichen Ausmaßes im Dentin, die sich in Form eines Bandenmusters darstellten und in Verbindung mit einer reduzierten Säureresistenz gebracht werden konnten. Nach Laserbestrahlung konnte in der rasterelektronenmikroskopischen Darstellung in Gruppe III und IV eine statistisch signifikante Reduktion offener Dentintubuli festgestellt werden.

Bezogen auf morphologische Effekte kann eine Laserbestrahlung exponierter Dentintubuli im Zahnhalsbereich zu einer ultrastrukturellen Veränderung oberflächlichen Dentins mit einem teilweisen Anstieg der Säureresistenz führen. Ausgehend von den Untersuchungen können aber für den Diodenlaser als Desensibilisierungsmittel keine direkten Rückschlüsse auf die klinische Situation, insbesondere bezogen auf mögliche biostimulative Effekte, die diesem Lasertyp ebenfalls zugesprochen werden, getroffen werden. Die Ergebnisse der vorliegenden Arbeit liefern aber eine Orientierung der Auswahl geeigneter Laserparameter für die klinische Anwendung. Weitere Studien sind notwendig, um die beschriebenen morphologischen Effekte dieses Lasertyps auch im Hinblick auf einen langfristigen Therapieeffekt zu untersuchen.






Bio-Emulation™



Tribune CME



# Bio-Emulation™ Colloquium 360°

4-5 July, 2015, Berlin, Germany

## Mentors



Ed McLaren



Michel Magne



Pascal Magne

## Emulators



Akinobu Ogata (guest)



Andrea Fabianelli



Antonio Saiz-Pardo Pinos



August Bruguera



David Gerdolle



Fernando Rey



Gianfranco Politano



Jason Smithson



Javier Tapia



Jungo Endo



Leandro Pereira



Marco Gresnigt



Oliver Brix



Panos Bazos



Sascha Hein



Stephane Browet



Thomas Singh



Walter Gebhard (guest)

Details & Online Registration

[www.BioEmulationCampus.com](http://www.BioEmulationCampus.com)

Registration fee: 599 EUR +VAT



**ADA CERP®**  
Continuing Education Recognition Program



Tribune Group is an ADA CERP Recognized Provider. ADA CERP is a service of the American Dental Association to assist dental professionals in identifying quality providers of continuing dental education. ADA CERP does not approve or endorse individual courses or instructors, nor does it imply acceptance of credit hours by boards of dentistry.

Tribune Group GmbH is designated as an Approved PACE Program Provider by the Academy of General Dentistry. The formal continuing dental education programs of this program provider are accepted by AGD for Fellowship, Mastership, and membership maintenance credit. Approval does not imply acceptance by a state or provincial board of dentistry or AGD endorsement.

Main Sponsor



# Laser assisted crown lengthening in the anterior maxilla

Author\_Minovska Ana, Cvetanovska Stojcheva Daniela, Macedonia

The harmonious and aesthetic appearance of the anterior maxillary region of the mouth has great impact on improving patients' physical appearance and hence their self-esteem. It is no longer enough to simply reproduce lost tooth structure. Contemporary standards emphasise the importance of avoiding procedures that will result in aesthetic compromise, as the aim is to provide patients with improved aesthetics whenever possible.

Among the most frequently used methods to achieve predictable, successful aesthetic rehabilitation of the smile is crown lengthening. Crown lengthening entails a surgical procedure performed by a dentist to expose a greater amount of tooth structure for the purpose of subsequently restoring the tooth prosthetically.<sup>1</sup> The procedure exposes more of the natural tooth by reshaping or recontouring the bone and the gingival line. This treatment can be performed on a single tooth, multiple teeth or the entire gingival line to

achieve a pleasant, aesthetically pleasing smile. When performed in the anterior maxillary region, its purpose is to facilitate an ideal gingival architecture, which involves recontouring of the hard and soft tissue in order to prevent violation of the biologic width.<sup>2,3</sup>

Since the maintenance of a healthy periodontium remains the sine qua non of a successful aesthetic and functional restoration, it is essential not to interfere with the normal arrangement or functioning of the biologic width. Because the biologic width appears to constitute a constant feature in the human periodontium, it has been suggested as an inviolate therapeutic parameter.<sup>4</sup> Clinical observation indicates that impingement of the biologic width will result in attempts by the gingival tissue to re-establish its original dimension through bone resorption or, in the presence of a thick alveolar crest, chronic gingival inflammation.<sup>5,6</sup>

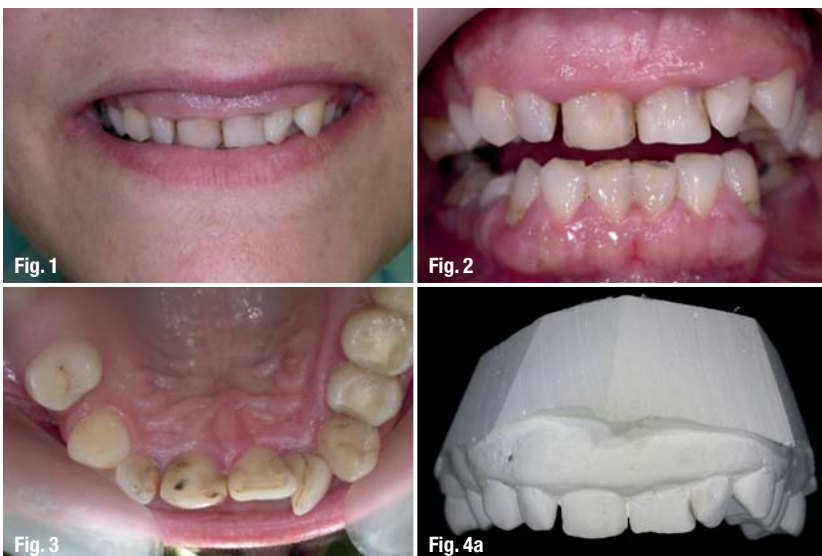The predictability of gingival line levels after crown lengthening procedures and the healing time required to achieve it are essential factors to consider. The two indications for anterior maxillary crown lengthening procedures are

1. to increase the amount of labial exposure of the clinical crown;
2. to increase the amount of tooth exposed superior to the bone to prevent impingement of the restoration on the biologic width.

## Laser-assisted crown lengthening

Critical to the long-term success of any crown lengthening procedure—whether accomplished by conventional means or by laser, and whether involving soft-tissue modification alone or in conjunction with osseous surgery—is preservation of biologic

**Figs. 1 & 2** A high smile line and the affected outline of the incisal line.  
**Fig. 3** Problems with teeth #13, 12 and 22, occlusal view.  
**Figs. 4a & b** Asymmetrical gingival line with high lip line.



width.<sup>7</sup> In order to accomplish this goal, it is necessary to consider the width of the attached gingiva and the location of the underlying alveolar crest to properly define the surgical approach for aesthetic crown lengthening. Assessing the extent of attached gingiva ascertains the relationship between the attached gingiva and the anatomic crown.

In order to determine the location of anatomical landmarks, which will indicate whether there is gingival excess or normal gingival width, and the location of the alveolar crest in relation to the cemento-enamel junction (CEJ), their measurement is required. Transgingival sounding of the alveolar crest determines its relationship to the gingival crest, the CEJ and the mucogingival junction. The surgical treatments to correct defects are based on the values of these parameters.

The ability of lasers to perform soft- and hard-tissue crown lengthening has been described in several published reports.<sup>8-11</sup> The use of the Er:YAG laser for gingival and bony recontouring has a significant impact on the way crown lengthening is performed. Since the laser cuts only at the end of the tip, the user has effective control of soft and hard tissue resection. When using traditional rotary instruments to perform osseous resection, there is always the risk that their rotation will damage adjacent root surfaces. Additionally, since the surgical laser wound is less traumatic, there is less chance of bony damage due to frictional heat, which is always possible when using rotary instrumentation without proper irrigation. This minimally invasive technology results in less post-operative discomfort and quicker healing of the patient.<sup>12</sup>

## Case presentation

A 38-year-old female patient was referred for comprehensive dental treatment. The clinical evaluation revealed a long list of problems. In addition, numerous teeth had undergone root canal treatment that would require endodontic retreatment. One of the patient's desires was to improve the appearance of her smile. The examination was completed and the appropriate diagnostic information was collected, including periodontal and occlusal evaluations. Study models were obtained and mounted with a facebow and centric relation bite records.

### Problems identified

1. Active general chronic periodontitis
2. Insufficient endodontic treatment of teeth #44 and 45
3. Insufficient fillings in teeth #18, 17, 12, 11, 21, 22, 23, 24, 25, 26, 38, 37, 33, 43-, 44, 45
4. Tooth #27 was to be extracted
5. Missing teeth: #16, 14, 28, 36, 35, 34, 46

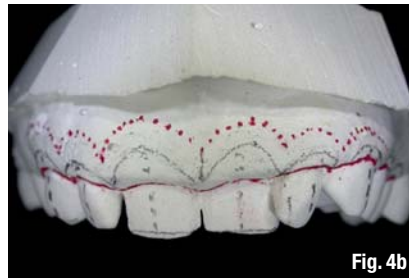

Fig. 4b

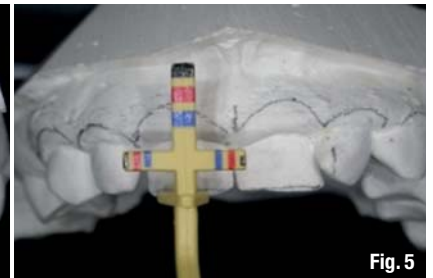


Fig. 5

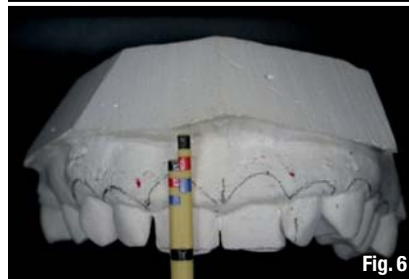

Fig. 6

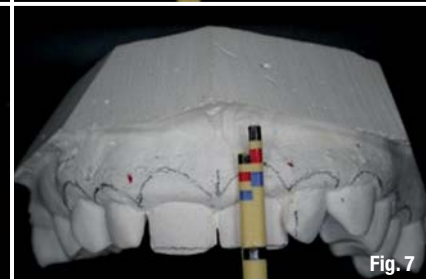

Fig. 7

6. Missing teeth to be replaced: #16, 14, 34, 35 and 36
7. Poor aesthetics: Gummy smile

**Figs. 5–8** Measuring and marking the mid-facial length of the anticipated clinical crown and the length of the biologic crown with Chu's Aesthetic Gauges.

## Step-by-step treatment plan

### Initial therapy

1. Conventional and Er:YAG laser-assisted treatment of the mild to moderate periodontitis
2. Endodontic treatment and filling
3. Tooth extraction

### Basic corrective therapy

1. Implants
2. Er:YAG-assisted crown lengthening in the anterior maxillary region (teeth #13–23) in order to correct the gummy smile

### Corrective therapy

1. Prostheses in the retro-canine regions
2. Aesthetic prostheses in the anterior maxillary region (teeth #13–23)

### Recall

First, the treatment for correction of the gummy smile was planned. The treatment planning process was initiated by evaluating the position of the maxillary teeth. The photographs show a high smile line and the affected outline of the incisal line (Figs. 1 & 2). The alignment of the teeth from the occlusal view demonstrates the problems with teeth #13, 12 and 22 (Fig. 3).

The occlusal plane of the left posterior teeth required correction in order to allow sufficient interocclusal distance to restore the mandibular left posterior region with two implants in regions #36 and 34 for supporting a small posterior bridge. Therefore, the procedure began with trimming of the incisal edge of the central and lateral incisors. Once the position of the maxillary occlusal plane had been decided, the position of the cervical or gingival line was evaluated. Since



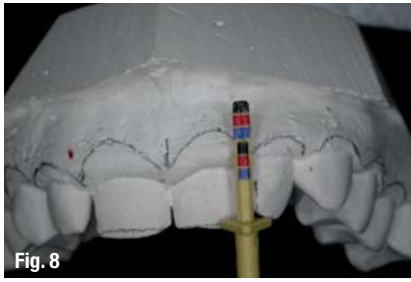

Fig. 8

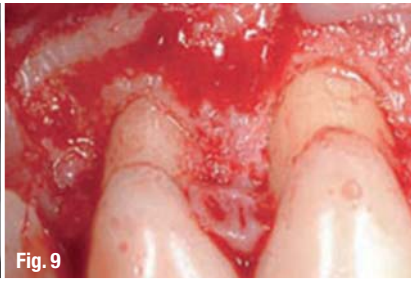


Fig. 9



Fig. 10

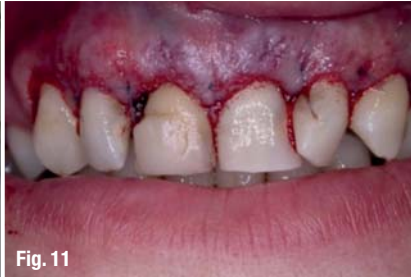

Fig. 11

**Fig. 9**\_Osseous reshaping of the alveolar crest line.

**Fig. 10**\_Reshaping was performed using the LiteTouch Er:YAG laser straight handpiece.

**Fig. 11**\_The mucoperiosteal flap was repositioned and sutured with 6-0 silk sutures, paying particular attention to primary closure of the flap.

there was an asymmetrical gingival line with a high lip line, that is, a gummy smile (Figs. 1 & 4), crown lengthening was planned in order to improve several problems with the patient's smile. Since it had been established that crown lengthening using an erbium laser would be the best treatment option for the patient, the extent of crown lengthening to be performed was determined by evaluating the patient's photographs and a template made from the diagnostic wax-up on stone models of the patient's mouth. The measuring and positioning of the gingival line and bone level were done using Chu's Crown Lengthening Gauge with the Biologic Periogauge tip (Hu-Friedy), which is designed to measure the mid-facial length of the anticipated restored clinical crown and the length of the biologic crown (i.e. from the bone crest to the incisal edge) simultaneously during surgical crown lengthening (Fig. 5).<sup>13</sup>

**Fig. 12**\_Four weeks post-operatively, the final prosthetic reconstruction took place and included crowns on the central and lateral incisors and veneers on the canines.

Measurements can be performed directly on the patient's teeth. After discussing the treatment options, the decision was made to perform crown lengthening

surgery with an open technique and osseous reshaping. After three to four weeks, the final prosthetic reconstruction would be done.

## \_Treatment

Before initiating any clinical treatment, a full set of radiographs were taken to determine whether the bone level was at or below the CEJ. Study models and a diagnostic wax-up were then prepared. The procedure began by measuring and marking the mid-facial length of the anticipated clinical crown and the length of the biologic crown with Chu's Aesthetic Gauges (Hu-Friedy; Figs. 5-8).

### *Performing an external bevel gingivectomy*

Once the new free gingival line location had been created, the first step in the process after local anaesthesia was to perform the Er:YAG laser-assisted gingivectomy with the LiteTouch laser (2,940 nm; Syneron Dental Lasers) using the straight handpiece. With the tip almost parallel to the root surface, the soft tissue was cut in a sweeping motion from mesial to distal to the level just coronal to the marked points, followed by sloping of the 90-degree gingival edge made during the first cut.

### *Recontouring the bone*

After administering anaesthetic, an incision was made with the laser at the buccal and palatal sides of teeth #13-23 and a vertical incision was not required. A full-thickness mucoperiosteal flap was then reflected. The osseous reshaping of the alveolar crest line (Fig. 9) was performed using the LiteTouch straight handpiece (Fig. 10). The buccal and palatal flaps were lifted and the area was explored for any soft tissue around the neck of the teeth. The soft tissue was ablated using the laser. Vaporisation of soft/granulation tissue (if any) after raising a flap can be achieved efficiently with the Er:YAG laser and there is often no need for hand instruments. The bone was recontoured in a sweeping motion, with the tip moving laterally from mesial to distal following the CEJ. The mucoperiosteal flap was repositioned and sutured with 6-0 silk sutures, paying particular attention to primary closure of the flap (Fig. 11).

The laser operating parameters employed for the various surgical stages were as follows:

- Flap access: wavelength of 2,940 nm (Er:YAG), 600 μ sapphire tip, soft tissue mode, contact mode, 100 mJ per pulse at 30 Hz, and total power of 3 W.
- Soft tissue removal: wavelength of 2,940 nm (Er:YAG), 1,300 μ sapphire tip, soft tissue mode, non-contact mode, 200 mJ per pulse at 20 Hz, and total power of 4 W.
- Bone surgery: wavelength of 2,940 nm (Er:YAG), 1,300 μ sapphire tip, hard tissue mode, non-contact.

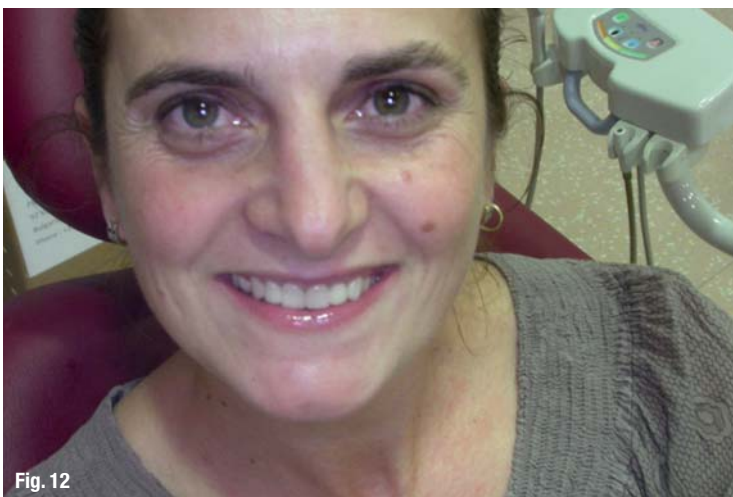


Fig. 12

mode, 200 mJ per pulse at 20 Hz, and total power of 4 W.

#### Post-operative instructions

The patient was prescribed painkillers to be taken if necessary. Instructions were given to rinse with 0.2% chlorhexidine three times per day, starting the next day for two weeks. The sutures were removed on the seventh day post-operatively, and minor laser reshaping of a few areas on the gingival line was done after three weeks using the LiteTouch (spot size of 0.8 mm with tip, soft tissue mode, non-contact mode, 100 mJ per pulse at 20 Hz, and total power of 2 W).

Four weeks post-operatively, the final prosthetic reconstruction took place and included crowns on the central and lateral incisors and veneers on the canines (Fig. 12). The recall period was set at three months for check-up and professional cleaning.

#### Conclusion

From this case report and presentation of the Er:YAG laser-assisted crown lengthening procedure, it can be concluded that the LiteTouch laser with the straight handpiece can be employed as an auxiliary device, and it has been proven to be effective and safe. The

use of the LiteTouch laser for this procedure represents numerous advantages: because the erbium laser is end cutting, collateral tissue damage frequently associated with conventional methods can be prevented; the laser uses a non-contact mode with a water spray for ablating the tissue, thereby minimising the heat generation that could lead to thermal side-effects; the lack of vibrations reduces patient discomfort during use and during post-operative recovery; and stable gingival tissue reduces the likelihood of coronal tissue proliferation or gingival recession after the procedure owing to the minimally invasive technique. Finally, the LiteTouch straight handpiece offers the dentist better and easier handling with 360-degree rotation.

#### contact

##### Prof. Dr Ana Minovska, DDS

ETERNAdent

Orce Nikolov 190-1/1

1000 Skopje, Macedonia

aminovska@eternadent.com.mk

www.eternadent.com.mk

#### Kurz & bündig

Für ein erfolgreiches Ergebnis mit Langzeitstabilität sind eine genaue Diagnose und die darauffolgende Entwicklung eines umfangreichen Behandlungsplans unabdingbar. Heutzutage können Zahnärzte Restaurationen vornehmen, die in Harmonie mit Lippen, Gesicht, benachbarten Zähnen und einem gesunden Parodontium stehen. Das Aussehen des Zahnfleisches, das die Zähne umgibt, hat großen Anteil an der Frontzahnästhetik. Abweichungen in Symmetrie und Umriss können die erwartete dentale Rehabilitation signifikant beeinflussen.

Eine der häufig verwendeten Methoden zur Erfüllung ästhetischer Anforderungen ist die chirurgische Kronenverlängerung. Diese beinhaltet entweder nur die Entfernung des Zahnfleisches oder die Entfernung von Knochen und Zahnfleisch. Dabei spielt es keine Rolle, welches unterstützende parodontale Gewebe involviert ist. Hauptziel ist es, den Anteil supragingivaler Zahnstruktur für ästhetische und/oder restaurative Zwecke zu erweitern oder zu steigern.

Im vorliegenden Fall wurde eine 38-jährige Patientin mit einer umfangreichen Liste klinischer Probleme vorgestellt. Zahlreiche Zähne wurden bereits einer Wurzelkanalbehandlung unterzogen, die eine endodontische Behandlung erforderten. Die Patientin wollte vor allem wieder ein ansprechendes Lächeln. Basierend auf einem fundierten Behandlungsplan wurde Schritt für Schritt eine umfangreiche Sanierung, beginnend bei der laserunterstützten Behandlung einer moderaten Parodontitis, eine endodontische Behandlung, Zahnextraktion, Einsetzung von Implantaten über eine laserunterstützte Kronenverlängerung bis hin zur prothetischen Versorgung, vorgenommen.

Wie der vorliegende Fall zeigt, kann eine angemessene Auswahl und die richtige Verwendung eines dentalen Lasers die chirurgische Prozedur für Patient und Doktor stark vereinfachen und ein vorhersehbares Ergebnis liefern. Der Erbium-Laser als alternatives Werkzeug für eine Kronenverlängerung stellt dabei für den Patienten eine minimalinvasive Behandlungsoption dar. Nachteilige Nebeneffekte, die mit einer konventionellen Behandlung verbunden sind, können damit minimiert werden. Die chirurgische Kronenverlängerung mit dem Laser geht schnell, ist nicht sehr schwierig und bietet dem Patienten Sicherheit und Komfort.

# Gingival plastic with diode laser

## A case report

**Authors** Ioannis Papadimitriou & Dr Petros Almagout, Germany & Greece

**Dental lasers have been used** in modern dentistry for more than three decades. The first theoretical principles of laser light were postulated by Albert Einstein in 1916. He suggested that portions of the electromagnetic field could be stimulated and thus produce amplified light. Laser was described as stimulated emission as an inversion of absorption.<sup>1</sup> More than four decades passed from theory to implementation and completion of the first laser device. The first laser, a ruby laser, was produced in 1960 by Theodore Maiman using a ruby crystal and a flash.<sup>2</sup>

The word "laser" is an acronym for light amplification by stimulated emission of radiation. Coherence in terms of time and place is one of the distinguishing features of laser light.<sup>3,4</sup> This means that all the generated laser light waves have the same colour at the same wavelength. Therefore, they are monochromatic. As laser beams are highly concentrated, when focused on a very small area, they can apply extreme energy. Laser light is reflected, transmitted or absorbed by the biological tissue. The influence of laser radiation will depend on interac-

tions with the molecules in the target tissue. The wavelength of the laser energy has different effects on certain tissues of the human body, ranging from cutting tissue to stimulating wound healing.<sup>5</sup>

In the past, laser was regarded as a complex technology with only limited use in dentistry. Through a variety of technical developments and advances, the application range of laser devices is constantly expanding. Nowadays, the number of dentists using new features of laser dentistry and incorporating laser devices into their practice routine is increasing constantly. Possible applications for lasers in dentistry can be divided into four fields: dental surgery, periodontology, endodontology and conservative dentistry, mainly laser-based cavity preparation.

In principle, three types of lasers can be distinguished nowadays. First, there are solid-state lasers, which Maiman realised with his ruby laser. This type of laser uses, among others, crystals of yttrium aluminium garnet (YAG) as the active medium and is doped with ions, such as neodymium (Nd) or erbium (Er). Second are gas lasers, which are constructed

**Fig. 1** The Ceralas D15/810 nm diode laser.  
**Fig. 2** Gingival display before laser treatment.  
**Fig. 3** Abnormal growth of the gingival tissue around the central and lateral incisors and the canines in the maxillae.



Fig. 1

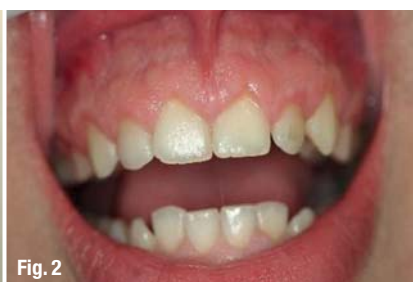

Fig. 2

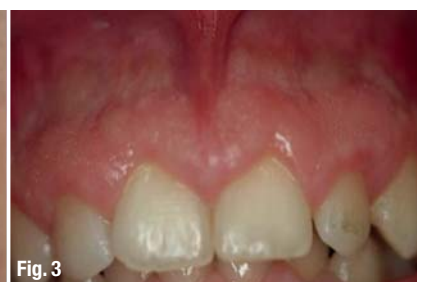

Fig. 3



slightly differently from solid-state lasers. Gas lasers contain a noble gas, metal vapours or gas molecules as the active medium. An electric current is usually induced in the gas medium by applying a high electric voltage, which then generates the gas discharge. Third, there are the semiconductor lasers. In this case, the active medium is a semiconductor crystal, such as gallium arsenide.<sup>6-8</sup>

### Laser devices and treatment ranges

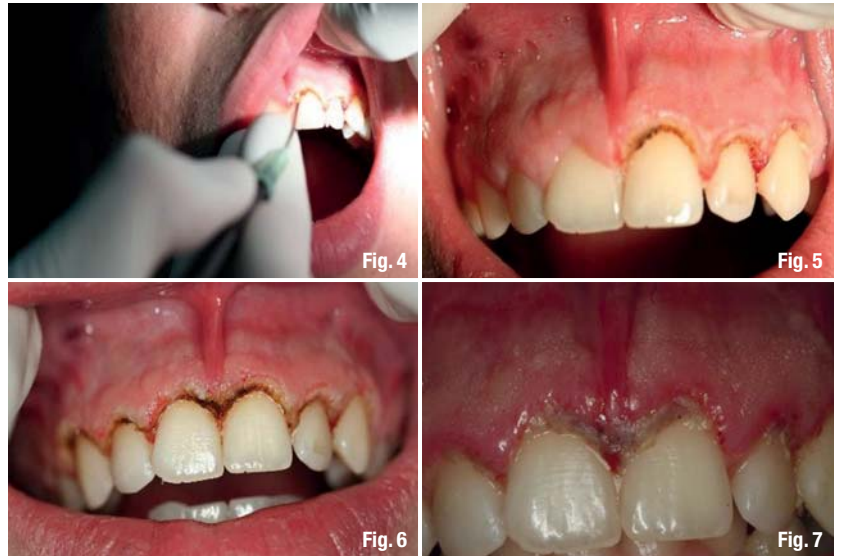The lasers that are most commonly used in dental practice are Er:YAG and Nd:YAG lasers (solid-state lasers), carbon dioxide lasers (gas lasers), as well as argon and diode lasers (semiconductor lasers).<sup>8-10</sup> The Er:YAG laser (wavelength of 1,064 nm) allows for the removal of tooth structure and enamel conditioning, and can be used in both soft-tissue surgery and dental surgery for bone cutting with extreme precision because of its excellent water absorption.<sup>9-11</sup>

The Nd:YAG laser (wavelength of 2,940 nm) is used predominantly in root canals and for the treatment of periodontal disease. There are some indications in soft-tissue surgical procedures for which this laser can be used very well. Because of its absorption range, it can be optimally applied in cases of pigmented soft tissue and pathogens.<sup>9, 10, 12, 13</sup>

The carbon dioxide laser (wavelength of 10,600 nm) is an extremely precise tool for cutting, ablation, coagulation and vaporisation of biological tissue.<sup>9, 10, 13, 14</sup> It can now be used as a matter of routine in surgery as a minimally invasive alternative to the use of the scalpel, for example in vestibuloplasty or fraenectomy. The argon laser (wavelength of 488/514 nm) is mainly absorbed by haemoglobin and is used in soft-tissue surgery.<sup>8-10</sup>

### Diode laser and applications in dentistry

The diode laser has a privileged position among the various laser devices.<sup>8-10</sup> Since its market launch in 1995, the use of diode lasers in dentistry has developed rapidly. At that point, the laser market was dominated by gas and solid-state lasers (carbon dioxide, Nd:YAG and Er lasers). A diode laser uses a solid-state crystal as the active medium. This is a semiconductor laser, which uses a combination of aluminium and gallium arsenide to convert electrical energy into light energy. In certain semiconductor configurations, monochromatic and coherent radiation emission is possible. However, there is a variety of diode lasers in the market with different wavelengths. Wavelengths mainly used in dentistry are in the near-infrared region, ranging from 635 to



980 nm. In principle, diode lasers can be found in the wavelength range of 810 nm to 980 nm, with excellent absorption in melanin and haemoglobin combined with low absorption in water and dental hard tissue. They have a good bactericidal effect and good coagulation qualities. The power spectrum ranges from 1 mW at 635 nm to about 20 W at 810 nm. Depending on the clinical indication, the energy of the injection laser (= diode laser) is transmitted in continuous wave mode or pulse mode either with fibres in contact with the tissue or with the appropriate power from a distance.<sup>9, 15, 16</sup>

The diode laser has a very wide range of indications, which can be perfectly integrated into the dental treatment spectrum. It is ideally suited for performing incisions, which are very common in dental surgery, as well as for the removal of benign tumours, fibroids or small haemangiomas in the oral cavity, for uncovering implants, and for use in soft-tissue surgery. It is specifically indicated for peri-implant surgery.<sup>15</sup> Furthermore, the diode laser is used for the decontamination of pathogen-populated surfaces (of implants and teeth).<sup>13</sup>

Laser light destroys anaerobic bacteria, especially Gram-negative bacteria. Owing to the average penetration depth of the diode laser, an overall very good deep bactericidal effect is achieved. But, in the root canal, for example, this effect is not quite as effective as with the Nd:YAG laser.<sup>12, 17</sup>

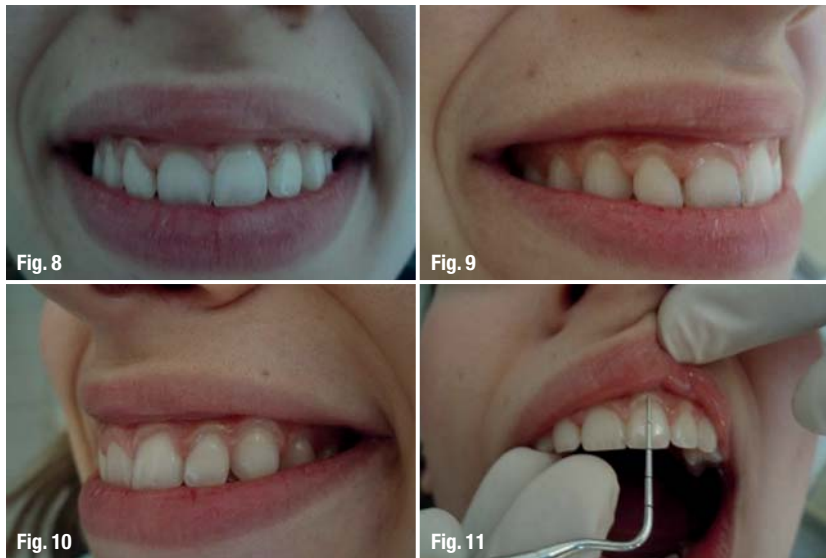Other application areas of the diode laser are antimicrobial photodynamic therapy and laser-assisted tooth whitening. Antimicrobial photodynamic therapy is used as part of the systemic treatment of periodontal disease or root canal disinfection. With antimicrobial photodynamic therapy, the bacteria are stained by a photosensitiser and elimi-

**Fig. 4** Gingivectomy of the thickened gingival tissue in the second quadrant.

**Fig. 5** Intra-op comparative photograph of the maxillae.

**Fig. 6** Post-op gingival display: State after vaporisation of the excessive gingival tissue.

**Fig. 7** Second day post-op: Granulating wound, healing by secondary intention.



the crowns. The probing depth of the pseudo-pockets was 4 mm around teeth #13, 12, 22 and 23 and 5 mm around teeth #11 and 21. The dental panoramic radiograph showed no vertical or horizontal bone loss. During clinical diagnosis of gingival enlargement induced by mouth-breathing, generalised moderate gingivitis was found. The patient wished to have the thickened tissue removed. She reported being very sensitive to pain and feared possible bleeding after surgical removal of the tissue. In response to the patient's concerns, we suggested the use of a diode laser as an alternative to the conventional method with a scalpel. The patient opted for laser treatment.

For the removal of the hyperplastic tissue, the Ceralas D15/810 nm was used with a setting of 3 W in continuous wave mode. For the local anaesthesia, Ultracain D-S 1:200,000 (Sanofi-Aventis) was administered and a total amount of 1 ml was infiltrated around the tissue to be removed. The patient and the treatment team were then equipped with the appropriate laser goggles. After verification of the anaesthesia in the surgical area with a dental explorer, removal of the thickened and lobulated tissue was performed. The fibre was guided parallel to the tooth surfaces and to the depth of the tissue (Figs. 4 & 5). Owing to the coagulating effect of the laser, no acute bleeding occurred (Fig. 6). Post-operatively, the patient was instructed to cool the surgical area and to avoid exercise. Furthermore, the patient received a prescription for painkillers in case she experienced pain, and an appointment was scheduled for two days after the surgery in order to check the wound healing. In the surgical area, good wound healing could be observed, and a fibrin layer covered the area of the removed gingiva. The patient reported having felt no pain during the healing process, and there was no restriction of food intake (Fig. 7). She was very happy with the end-result, and afterwards desired to undergo a septoplasty in order to eliminate the problem of the mouth-breathing.

Case 2

In November 2012, a 30-year-old female patient presented to our clinic for the first time. According to the patient, the anterior maxillary teeth were uneven in size (Figs. 8–10). The patient was generally healthy and had no allergies. Her mouth appeared to have been sufficiently conservatively and prosthetically restored, and oral hygiene seemed to be good. Moreover, there were no signs of specific need for periodontal treatment. No noteworthy features were observed extra-orally. The patient had an average smile line. An irregular contour of the gingival line in the anterior maxillary region was evident intra-orally. After probing, it was found that teeth #21 and 22 had a 2 mm higher clinical crown in compar-

**Fig. 8** Pre-op situation.  
**Fig. 9** First quadrant: The gingival contour was asymmetrical with the smile line.  
**Fig. 10** Second quadrant: The gingival contour on the central and lateral incisors was uneven and asymmetrical.  
**Fig. 11** Probing of the height of the clinical crowns of the incisors.

nated by light activation. In laser-assisted tooth whitening, laser energy is applied to enable and accelerate the whitening process, and the effect mechanism is based on the photocatalytic whitening process. Moreover, the diode laser is indicated for the detection of caries and mineralised deposits, such as plaque.<sup>4</sup>

**Case presentations**

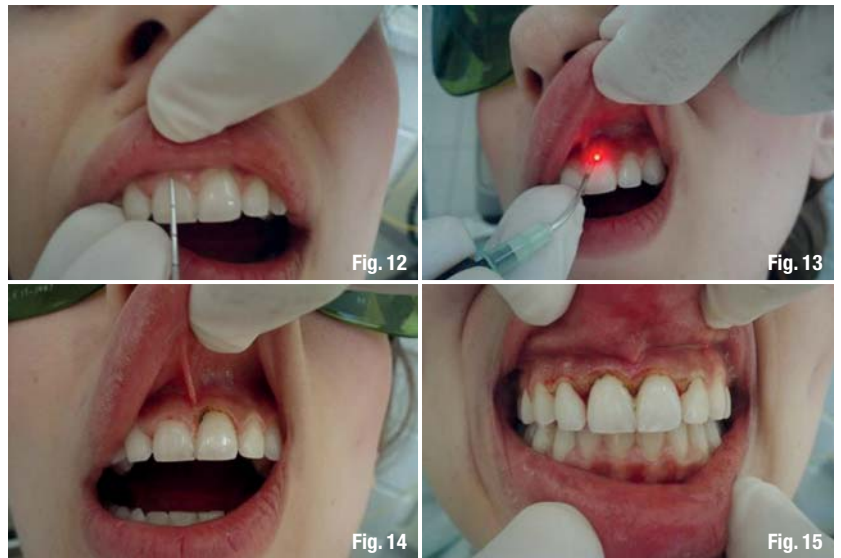In the following two clinical cases of gingival surgery using a diode laser, the surgical steps and post-operative wound healing of the patients are presented. The treatments were performed in the department of conservative dentistry and oral surgery at the Agia Varvara general hospital in Athens in Greece and in patients with gingival enlargement. For the treatments, the Ceralas D15/810 nm diode laser (biolitec; Fig. 1) was used.

Case 1

A 35-year-old female patient presented for dental examination in our department. The patient presented with generalised thickened and lobulated gingival tissue in the maxillae, where it had led to impairment of her oral care and to great discomfort. Besides a pollen allergy, the patient was generally healthy. She said that she was a former smoker. Furthermore, the patient reported that while sleeping she tended to breathe through the mouth owing to a deviation of the nasal septum. Her mouth appeared to have been sufficiently conservatively and prosthetically restored, and oral hygiene seemed to be moderate. The clinical examination found generalised gingival enlargement of the periodontium of all of the teeth in the anterior maxillary region (Figs. 2 & 3). There were generalised moderate gingivitis and pseudo-pockets. The red and swollen pseudo-pockets partially covered the vestibular aspect of

ison with teeth #11 and 12 (Figs. 11 & 12). The patient was dissatisfied with her current situation and wished for the gingival line to be symmetrical in the area of the anterior maxillary teeth and for this to be accomplished as painlessly as possible. In addition to the conventional removal of gingival tissue with a scalpel, the patient was offered treatment with the diode laser. She decided on the laser treatment.

For gingival recontouring, the Ceralas D15/810 nm was used with a setting of 3 W in continuous wave mode. For the local anaesthesia, Ultracain D-S 1:200,000 was administered and a total amount of 0.8 ml was infiltrated around the tissue to be removed. The patient and the treatment team were then equipped with the appropriate laser goggles. After verifying the anaesthesia in the surgical area with a dental explorer, gingival recontouring was performed by removing the excess gingival tissue and sculpting the gingival line. The fibre was inserted parallel to the tooth surfaces, and the thickened gingival tissue was gradually thinned and removed (Figs. 13 & 14). With the 810 nm diode laser emissions being absorbed by dark underlying substances, damage to the tooth structure was not expected. Post-operatively, the patient was instructed to cool the surgical area (Fig. 15). A wound bandage was not required. An appointment was scheduled for two days after the surgery in order to check the wound healing (Fig. 16). In the surgical area, there



was good wound healing, and granulation tissue had formed in the area of the removed tissue. The patient reported having felt no pain during the healing process and could eat normally. She was very pleased with the results.

### Conclusion

The possibilities of laser systems, as presented in the case reports using a diode laser, offer new therapeutic approaches and support to many conven-

**Fig. 12** The crowns of teeth #21 and 22 were 2 mm higher compared with teeth #11 and 12.

**Fig. 13** Gingival recontouring with an 810 nm diode laser.

**Fig. 14** Intra-op comparative photograph of the incisors.

**Fig. 15** The patient's smile after laser treatment.

AD

(PICTURE: ©SERGEY NIVENS)

# Publish -your- expertise

Hand in your article.

**Please contact:**

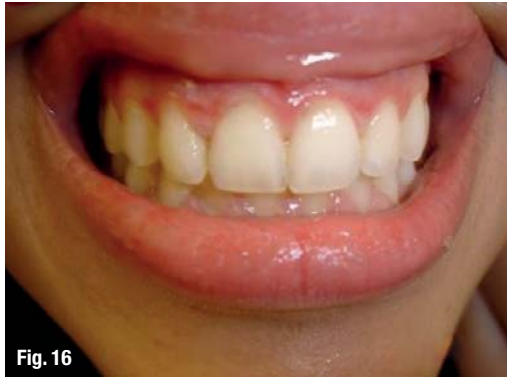**Editorial manager**  
Georg Isbaner  
g.isbaner@oemus-media.de

**Editor**  
Katrin Maiterth  
k.maiterth@oemus-media.de

laser | 23  
1\_2015



**Fig. 16** The gingival line after two days of healing.



tional treatments. Nevertheless, laser can currently be considered as an adjuvant therapy and not quite as a true alternative to traditional therapies. Advantages for the patient are painless and bloodless surgical treatment in which secondary bleeding is not expected and suturing is not absolutely necessary. Furthermore, the procedure can be performed

quickly, and the healing time is shorter than in the case of conventional gingival surgery. Time will prove whether laser will be capable of replacing traditional and very effective treatment methods through continuous improvement and development of the technology.

*Editorial note: A list of references is available from the publisher.*

## contact

### Ioannis Papadimitriou

St. Lukas Clinic  
Department of Oral and Maxillofacial Surgery  
Schwanenstraße 132  
42697 Solingen, Germany

giannis.papadimitriou\_4@hotmail.com

## Kurz & bündig

1916 legte Albert Einstein mit seinem Prinzip der stimulierten Emission die theoretischen Grundlagen für den Laser. Er nahm an, dass Teile des elektromagnetischen Feldes stimuliert werden könnten und damit verstärktes Licht produzierten. Von der Theorie zur Implementierung und Fertigstellung der ersten Lasertechnik vergingen jedoch mehr als vier Jahrzehnte. Der erste Laser – ein Rubinlaser – wurde 1960 von Theodore Maiman unter Verwendung eines Rubins und Blitzlichtes entwickelt.<sup>2</sup> Aufgrund einer Vielzahl technischer Entwicklungen und Fortschritte wurde das Anwendungsspektrum von Lasern stetig erweitert und fand so auch seinen Weg in die Zahnmedizin. Heute wächst die Zahl der Zahnärzte, die die Lasertechnologie fest in ihren Praxisalltag integriert haben.

Grundsätzlich gibt es drei Arten von Lasern: Festkörperlaser, die u. a. Yttrium-Aluminium-Granat-Kristalle (YAG) als aktives Medium verwenden und mit Ionen wie Neodym (Nd) oder Erbium (Er) dotiert sind; Gaslaser, die ein Nobelgas, Metalldämpfe oder Gasmoleküle als aktives Medium enthalten; und zu guter Letzt Halbleiterlaser, bei denen das aktive Medium ein Halbleiter-Kristall ist wie beispielsweise Galliumarsenid (GaAs-Laser).<sup>6-8</sup> Die in der Zahnarztpraxis am häufigsten gebrauchten Laser sind Er:YAG-, Nd:YAG-, CO<sub>2</sub>- sowie Argon- und Diodenlaser.<sup>9-10</sup> Dabei hat der Diodenlaser eine privilegierte Position:<sup>9-10</sup> Er eignet sich ideal zur Durchführung von Schnitten sowie zur Entfernung gutartiger Tumore, Myomen oder kleinen Hämangiomen in der Mundhöhle, zur Freilegung von Implantaten, in der Weichgewebschirurgie, bei periimplantären Eingriffen<sup>16</sup> sowie bei der Erkennung von Karies und mineralisierten Ablagerungen wie Zahnstein.<sup>9,10,13,16,17</sup>

In den beschriebenen Fällen wurden bei einer 35- und einer 30-jährigen Patientin gingivale plastische Operationen unter Verwendung eines Diodenlasers (Ceralas D15/810 nm; Biolitec, US) durchgeführt. Im Fall der 35-jährigen Patientin (Abb. 2–8) offenbarte eine durch Mundatmung verursachte Vergrößerung der Gingiva eine allgemein moderate Gingivitis. Das verdickte und gelappte Gewebe wurde mittels Laser entfernt. Aufgrund des koagulierenden Lasereffekts trat keine akute Blutung auf. Die 30-jährige Patientin (Abb. 9–17) befand ihre Oberkieferfrontzähne für ungerade hinsichtlich der Größe und wünschte sich daher eine Harmonisierung des Zahnfleisches im Bereich der oberen Frontzähne. Die Zahnfleischformung wurde durchgeführt durch Entfernung des überschüssigen Zahnfleischgewebes und Formung der Zahnfleischlinie. Dabei wurde die Laserfaser parallel zur Zahnoberfläche eingeführt und das verdickte Zahnfleischgewebe schrittweise verdünnt und entfernt. Zwei Tage nach der Behandlung zeigte sich im Operationsgebiet beider Patientinnen eine einwandfreie Wundheilung. Die Patientinnen waren insgesamt sehr zufrieden mit der Behandlung.

Die vorgestellten Fälle zeigen, dass die Anwendung des Diodenlasers neue therapeutische Ansätze bietet und damit konventionelle Behandlungsmaßnahmen unterstützt. Die Zeit wird zeigen, ob der Laser in der Lage sein wird, traditionelle und effektive Behandlungsmethoden durch kontinuierliche Verbesserung und technologische Weiterentwicklung zu ersetzen.



# CROIXTURE

PROFESSIONAL MEDICAL COUTURE



## THE NEW 2014-2015 COLLECTION

EXPERIENCE OUR ENTIRE COLLECTION ON [WWW.CROIXTURE.COM](http://WWW.CROIXTURE.COM)

# The TwinLight<sup>®</sup> approach to peri-implantitis

Author\_Dr Ilay Maden PhD, Dr Zafer Kazak, UK

As the number of dental implants being placed increases, reported cases of peri-implantitis are becoming more frequent. The available data suggest that one in five implant patients will develop peri-implantitis, an irreversible inflammatory condition characterised by bone loss around the site of an implant, while four in five will exhibit peri-implant mucositis, an early stage of the disease in which the inflammatory reaction is still reversible.<sup>1</sup>

With peri-implant mucositis, the inflammation is limited to the peri-implant mucosa, while with peri-implantitis the infection also spreads to the peri-implant bone. Both conditions include the presence of bacterial plaque and calculus, oedema and redness of tissues, and involve bleeding on probing. In the majority of cases, classical treatment methods for peri-implantitis are inadequate due to a number of complicating factors, including

- Fig. 1 Removal of the soft-granulation tissue with Er:YAG in LP mode.
- Fig. 2 Removal of the bacterial biofilm on the implant surfaces with Er:YAG in MSP mode.
- Fig. 3a Ablation of the infected bone with Er:YAG in QSP mode.
- Fig. 3b Bacterial reduction in the bone tissue with Nd:YAG in MSP mode.
- Fig. 4 Biostimulation with Nd:YAG in VLP mode.





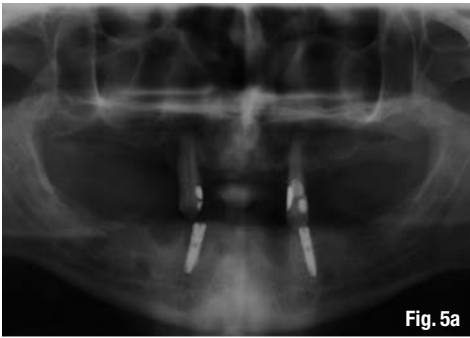

Fig. 5a



Fig. 5b

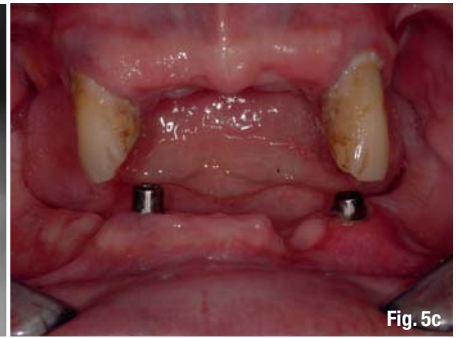

Fig. 5c

resistant bacterial strains, difficult debridement procedures and the presence of biofilm on the implant surface.<sup>2</sup>

The most prevalent reason for the development of peri-implantitis appears to be poor occlusal load distribution, with either primary contacts or cantilever bridges in implant-supported prostheses. Good oral hygiene on the patient's part is mandatory, however, the position and design of prostheses that are difficult to manage may limit the effectiveness of mechanical cleaning. Once the underlying reason has been determined and recurrence is prevented, laser therapy can help to treat peri-implantitis.

### The TwinLight® peri-implantitis treatment

A new laser treatment called TwinLight® from Fotona is proving to be one of the most effective methods for fighting peri-implantitis, successfully meeting the objectives of controlling infection by surface decontamination and halting the disease's progression. TwinLight® is a minimally invasive technique combining dentistry's two gold-standard laser wavelengths (Er:YAG and Nd:YAG) in a

synergistic process designed to improve peri-implantitis treatment success rates and shorten healing time.

With TwinLight®, the Er:YAG laser is used in a non-surgical procedure to remove microbial composition and in a surgical procedure to treat the damaged alveolar bone around the implant. Using Er:YAG, it is possible to clean the granulation tissues, both on the bone and implant surfaces, and thoroughly decontaminate the site. Removal of granulation tissue from the alveolar bone and connective tissue with Er:YAG laser is highly effective. The erbium laser targets the water content to remove the granulation tissue selectively, due to its long pulse duration and lower peak power, while ablating the microorganisms on the surface of the bone.

The bactericidal effect of Er:YAG on the surgical site is effective against lipopolysaccharides, and the implant surface is completely cleaned without chemicals. The subsequent Nd:YAG treatment step promotes faster healing by bacterial reduction and biostimulation of the bone tissue. The same principles apply also with more severe treatments that require surgical therapy.

Fig. 5a\_Pre-op X-ray.

Fig. 5b\_Pre-op X-ray zoomed.

Fig. 5c\_Pre-op clinical.

Fig. 6a\_De-granulation and disinfection of the implant surface with Er:YAG laser.

Fig. 6b\_Bacterial reduction and biostimulation of the bone with Nd:YAG laser.

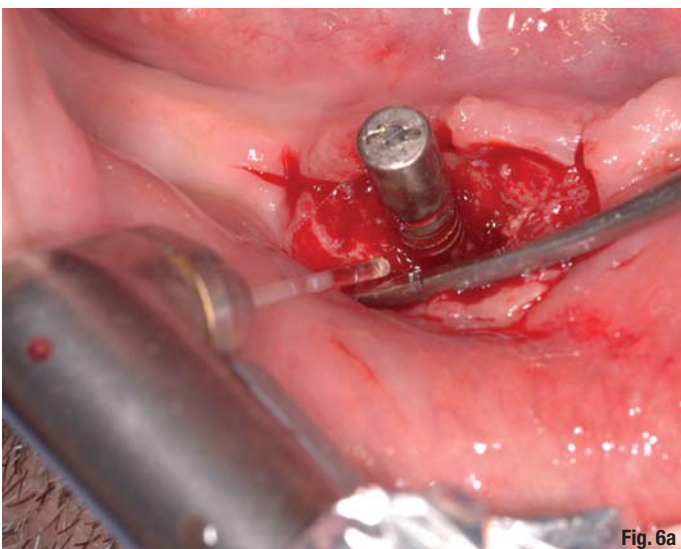

Fig. 6a

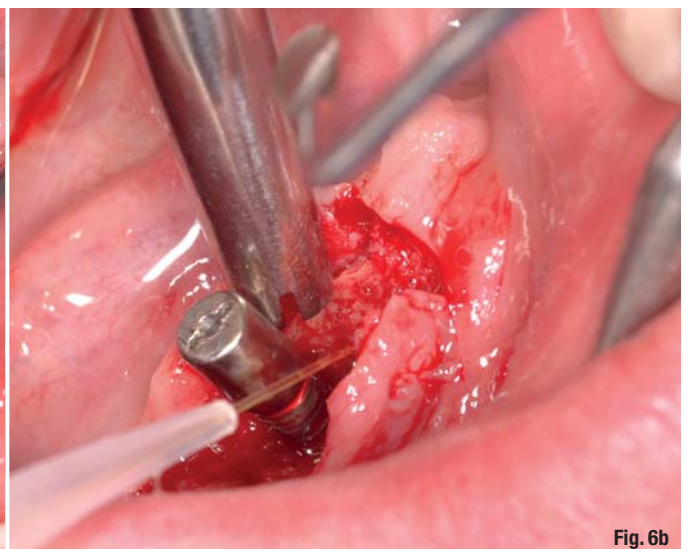


Fig. 6b

## The TwinLight® procedure

The TwinLight® procedure is performed according to the following five steps:

- Step 1: Removal of the soft-granulation tissue with Er:YAG in LP mode (Fig. 1).
- Step 2: Removal of the bacterial biofilm on the implant surfaces with Er:YAG in MSP mode (Fig. 2).
- Step 3: Ablation of the infected bone with Er:YAG in QSP mode (Fig. 3a).
- Step 4: Bacterial reduction of the bone with Nd:YAG in MSP mode (Fig. 3b).
- Step 5: Biostimulation with Nd:YAG in VLP mode (Fig. 4).

For treatment of peri-implant mucositis, only step 2 is performed.

Because the Er:YAG wavelength is used with an optimal modality, there is no danger of thermal damage to the highly fragile surrounding bone and no significant alterations of the implant surface, as is frequently the case with other lasers.<sup>3,4</sup> The effect of the laser energy on the implant surface is dependent on the amount of energy density, power and pulse duration. The parameters should be chosen cautiously—lowering the settings may make the procedure slower but safer for re-osseointegration. Non-surgical use of Er:YAG is also possible if the problem is not extensive.

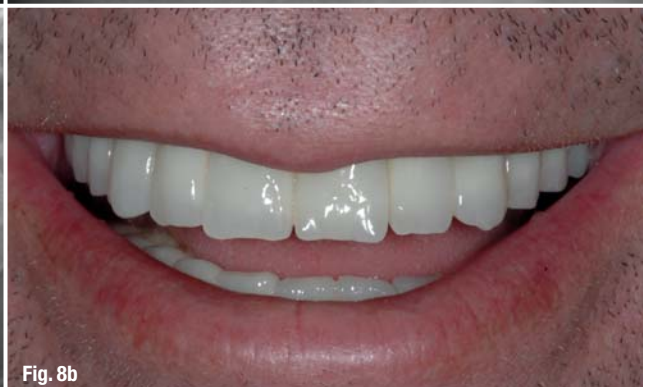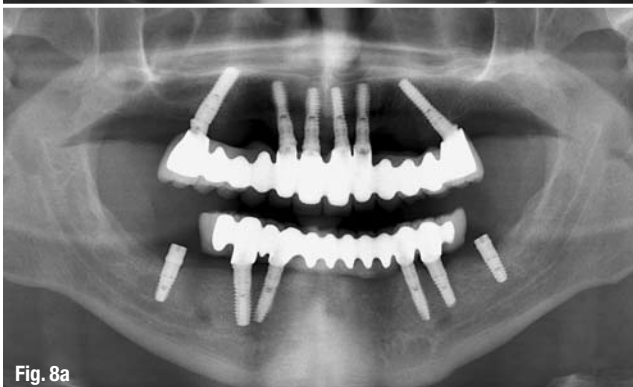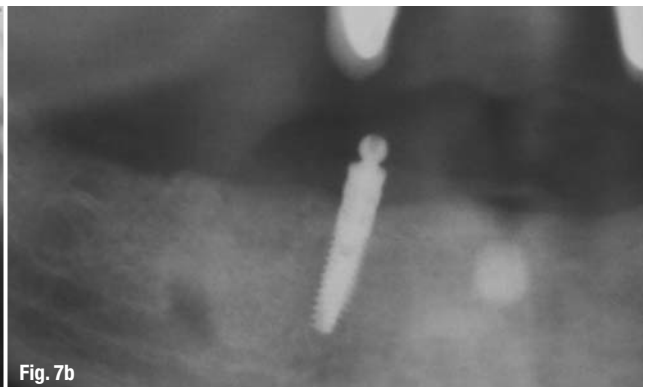
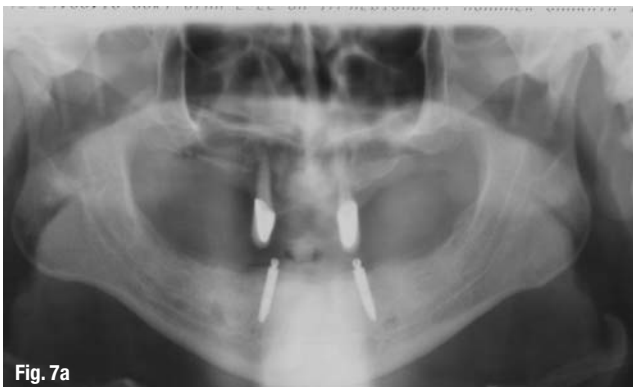## Clinical Case

In the accompanying clinical case, a removable prosthetic with two ball attachments was planned. Due to the patient's request, the implants were immediately loaded, which most probably is the reason for the resorption seen around the implant on the right lower jaw (Fig. 5). The site was directly accessed to clean the granulation tissue and disinfect the implant surface with Er:YAG laser, while bacterial reduction and biostimulation were executed with Nd:YAG laser (Fig. 6). The defect was augmented with synthetic bone substitute.

After 3 years of follow up with very good healing (Fig. 7), the patient demanded a fixed prosthetic, which was delivered with an additional placement of implants in both jaws. X-rays taken 5 years after the peri-implantitis treatment can be seen in Fig. 8. Two more implants were placed distally when the patient could afford more treatments after one year.

There are a number of advantages of using lasers in this type of case. One of them is that there is no mechanical, chemical or any other means of trauma while removing the granulation tissue around the implant—neither to the implant nor to the bone tissue. In addition to being safe, both wavelengths are known to promote healing by bacterial reduction and biostimulation of the tissue. Shorter pulses are used on the surface of the

**Fig. 7a** 3 years post-op X-ray.  
**Fig. 7b** 3 years post-op X-ray zoomed.  
**Fig. 8a** 5 years post-op X-ray.  
**Fig. 8b** 5 years post-op clinical.



implant to avoid thermal effects, but with lower energies, so as to not have a too high peak power and thereby damage the surface. With short pulses and higher peak power (higher energy), we can create bleeding spots on the bone to improve healing of the augmentation material.

The penetration of Nd:YAG through bone helps the achievement of bacterial reduction and biostimulation. Care should be taken to avoid contacting the implant surface with Nd:YAG because the absorption in titanium is high and could cause a rise in temperature. It is also important to use a fast, sweeping motion with high suction to avoid heat accumulation on one spot. Too much bleeding would block the penetration of the Nd:YAG laser.

Nd:YAG can also be used on the incision line, vestibular, the oral side of the surgical site and extra-orally after suturing, and every second day for faster and better healing, with less pain and swelling. \_\_

*Editorial note: A list of references is available from the publisher.*

## contact

### Dr Ilay Maden PhD

Seesaw Dental Education UK  
20 Halifax Road, 3 Boothroyds WF13 2NE, UK  
ilaymaden@gmail.com

## Kurz & bündig

Eine der sinnvollsten Anwendungen des Lasers innerhalb der Implantologie ist die Behandlung von Periimplantitis. Diese Erkrankung stellt die Zahnmedizin vor eine echte Herausforderung und ist mit klassischen Techniken schwierig zu behandeln. Mit zunehmender Zahl platzierter Implantate steigt auch die Zahl der Periimplantitis-Fälle. Laut aktueller Datenlage entwickelt einer von fünf Patienten mit Implantat eine Periimplantitis, eine irreversible Entzündung, die durch Knochenverlust um das Implantat charakterisiert ist. Vier von fünf Patienten entwickeln eine periimplantäre Mukositis, eine frühe Stufe der Erkrankung, in der die Entzündungsreaktion noch reversibel ist.<sup>1</sup>

Der verbreitetste Grund für die Entwicklung einer Periimplantitis scheint eine schlechte okklusale Lastverteilung zu sein, mit entweder Primärkontakten oder freitragender Brücke bei implantat-gestützten Prothesen. Eine gute Mundhygiene aufseiten des Patienten ist zwingend. Dennoch können die schwer zu bestimmende Position und das Design der Prothese die Effektivität einer mechanischen Reinigung einschränken. Ist der ursächliche Grund jedoch erkannt und ein Wiederauftreten verhindert, kann eine Lasertherapie bei der Behandlung hilfreich sein.

Die Laserbehandlung TwinLight® von Fotona hat sich dabei als eine effektive Methode zur Bekämpfung von Periimplantitis bewährt. Die Methode vereint die Vorgaben der Entzündungskontrolle durch Oberflächendekontamination und verhindert ein Fortschreiten der Erkrankung. TwinLight® ist eine minimalinvasive Technik, die die zwei zahnmedizinischen Goldstandard Laser-Wellenlängen (Er:YAG und Nd:YAG) in einem synergetischen Prozess zusammenbringt, um die Erfolgsraten der Periimplantitis-Behandlung zu verbessern und die Einheilungszeit zu verkürzen. Die Prozedur erfolgt in fünf Schritten:

- Schritt 1: Entfernung des weichen Granulationsgewebes mit Er:YAG im LP-Modus (Abb. 1).
- Schritt 2: Entfernung des bakteriellen Biofilms auf der Implantatoberfläche mit Er:YAG im MSP-Modus (Abb. 2).
- Schritt 3: Abtragung des infizierten Knochens mit Er:YAG im QSP-Modus (Abb. 3a).
- Schritt 4: Bakterielle Reduktion am Knochen mit Nd:YAG im MSP-Modus (Abb. 3b).
- Schritt 5: Biostimulation mit Nd:YAG im VLP-Modus (Abb. 4).

Zur Behandlung einer periimplantären Mukositis ist lediglich Schritt 2 erforderlich.

Im vorgestellten klinischen Fall wurde eine herausnehmbare Prothese mit zwei Kugelkopf-Attachments geplant. Auf Wunsch des Patienten wurden die Implantate sofort belastet, was wahrscheinlich auch der Grund für eine Resorption um das Implantat im rechten, unteren Kiefer war (Abb. 5). Die Behandlung erfolgte analog der fünf Schritte der TwinLight®-Lasertherapie. Im Follow-up nach drei Jahren mit sehr guter Heilung (Abb. 7) verlangte der Patient nach einer festen Prothese, die mit der Platzierung zusätzlicher Implantate in beiden Kiefern erfolgte. Die Röntgenbilder fünf Jahre nach der Periimplantitis-Behandlung sind in Abb. 8 zu sehen – nach einem Jahr wurden zwei weitere Implantate distal platziert.

Die Verwendung des Lasers in einem solchen Fall hat viele Vorteile, u.a. gibt es kein mechanisches, chemisches oder anderweitiges Trauma bei der Entfernung des Granulationsgewebes um das Implantat. Zusätzlich zur Sicherheit sind beide Wellenlängen dafür bekannt, die Heilung durch bakterielle Reduktion und Biostimulation des Gewebes zu fördern.



# Manufacturer News

AD

0277113

**laser wishes you a successful IDS 2015!**

laser  
dentistry

**IDS 2015**

Visit us at hall 04.1, booth D060-F061.

Fotona

## Erbium laser with patented technologies

Visit Fotona's booth #M050 in Hall 10.2 at IDS and get a first-hand look at the company's award-winning LightWalker AT dental laser. Renowned international dental laser experts will be on hand around the clock at the company's booth to answer questions and demonstrate the laser's advanced capabilities, especially with difficult-to-treat conditions such as peri-implantitis.

The dental laser's state-of-the-art design, engineering and patented technologies have made it one of the world's fastest-cutting Erbium laser, outperforming even rotary burs in terms of speed and precision, while simultaneously offering a wide range of highly effective hard- and soft-tissue treatments. Typical procedures with this laser are faster, easier to perform, less painful and require shorter

healing times compared to conventional treatments.

The LightWalker AT system includes high-performance Er:YAG and Nd:YAG lasers, 20W of power and Fotona's patented VSP and QSP pulse technologies for best possible performance and control during over a wide range of applications, from simple cavity preps to implantology and endodontics. LightWalker AT is also the first Erbium dental laser on the market with digitally controlled handpiece technology (X-Runner®), offering dentists new treatment possibilities and higher levels of precision.



**Fotona d.d.**

Stegne 7

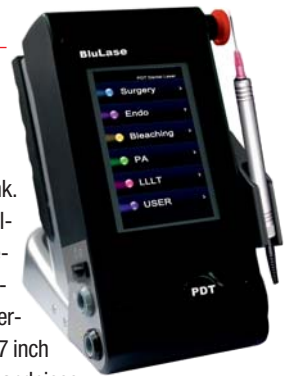1000 Ljubljana, Slovenia

[www.fotona.com](http://www.fotona.com)

Schneider Dental

## Diode laser with comprehensive service

Diode lasers in dentistry are more capable than most practitioners might think. Thereby, an intuitive and easy handling is a very important prerequisite. In collaboration with practitioners and dental clinics, Krypton Technologies has developed BluLase 810 PDT – a device suited for daily demands of a dental practice. The compact table device offers a comfortable menu navigating system; therapies are preprogrammed and divided into logical groups. The high-contrast 7 inch colour display with touch-function allows for an easy handling. The standard handpiece from anodised aluminium convinces with its low weight and ergonomics, autoclavability and flexible single-use exchangeable tips guaranteeing a maximum of hygiene. With an output power from 0,1 to 7 W, BluLase 810 PDT can be used for all diode laser indications. However, even the best device cannot fully develop its entire advantages without a professional instruction. For this reason, Krypton Technologies has outsourced its distribution and service to the company Schneider Dental. Usually, the device is delivered to the practice personally and assembled on site. Before the final handover, dentist and practice team receive a comprehensive instruction. Furthermore, Schneider Dental offers regular training courses as part of their BluLase academy.



**Schneider Dental/BluLase**

Muscherstraße 8

92367 Pilsach, Germany

[www.schneiderblulase.com](http://www.schneiderblulase.com)



# THE FUTURE IS HERE

## ► The 36th Australian Dental Congress

Brisbane Convention and Exhibition Centre - *an AEG 1EARTH venue*   
Wednesday 25th to Sunday 29th March 2015

### Invitation from the Congress Chairman

On behalf of the Local Organising Committee of the 36th Australian Dental Congress, it is with great pleasure that I invite you to attend Congress and enjoy the river city of Brisbane.

Over three and a half days, highly acclaimed International and Australian speakers supported by contemporary research, will present a wide range of subjects relevant to practice. These presentations will be complimented by hands on workshops, Lunch and Learn sessions, specific programmes for members of the dental team. Social activities will be available for relaxation purposes.

The Brisbane Convention and Exhibition Centre is adjacent to the Southbank Precinct on the banks of the Brisbane River. Nearby is the Queensland Performing Arts Complex, the Queensland Museum and the Queensland Art Gallery and Gallery of Modern Art. A comprehensive industry exhibition will be held alongside the Congress enabling delegates access between scientific sessions to view the latest in equipment and materials.

Come and join us for the scientific programme, the opportunity to meet colleagues and the experience Brisbane has to offer.

Dr David H Thomson



Congress Chairman  
36th Australian Dental Congress

Titanium sponsor:



**BOQ  
SPECIALIST**

Distinctive banking



36th Australian Dental  
**CONGRESS**

Educating for Dental Excellence

► [facebook.com/adacongress](https://facebook.com/adacongress) ► [twitter.com/adacongress](https://twitter.com/adacongress) ► [youtube.com/adacongress](https://youtube.com/adacongress) ► [adc2015.com](http://adc2015.com)

# Gain **power** at your **laser** clinics!

## Physical evidence and place

**Author** \_Dr Anna Maria Yiannikos, Germany & Cyprus

[PICTURE: ©ZIMMYTWS]

**\_Today, as a sequel of our previous articles** we will teach the next P's of our 7P's of Marketing Mix. My ultimate goal with these series of articles is to give all dentists and dental professionals a basic guideline of the marketing options available. Starting with this easy strategy, I will teach you how you can directly implement these methods to your own clinic as well as understand their value and power and thus change your professional life! The next P's of the 7P's of the marketing mix are physical evidence and place.

**“Quality can be effectively communicated to patients by the appearance of your clinic.”**

### **\_Place**

The place represents the environment of your clinic where your services are delivered. Based on Bitner, your clinic must include the following 3 elements:

#### *Ambient conditions*

This means for example music! Martin Lindstrom the author of "Buyology" and "Brainwashed" tested how consumers react to different kind of music in an urban retail store. Check out the results! The impact that kind of music and tempo have on consumers are amazing.

#### *Spatial layout*

How is the setup of your clinic? Here are some more detailed tips that you can implement right away:

Reception Area: Create a reception area that enables the receptionist to turn 90 degrees to welcome the pa-

tient, and 90 degrees away from the patient to conduct other business. This ensures that patient conversations and payment transactions remain private. Treatment Areas: Position treatment areas so that they are not visible from the public areas such as the greeting and reception areas. Designate private office and break room space away from the patient activity areas.

#### *Signs and symbols*

How is the appearance of your business cards or furnishing? Signs and symbols of your clinics such as your business cards, logo, furnishing etc. have proven to be very important for patients. For example, our logo needs to be symmetrical as companies with symmetrical logos are conceived by consumers as more ethical. Every symbol and sign must not come into conflict with the rest of your clinic's profile. For example, your decoration or furnishing have to provide a feeling of unity and continuation—every aspect of your place completes the image of your clinic and passes the message that you want to your patients.

### **\_Physical evidence**

Let's continue with physical evidence. This is very important since patients have little evidence upon what to base their perception of service quality. This is because the dental service provided is intangible and cannot be materialised. If your clinic is worn, tattered, cluttered, and poorly organised, patients may transfer that perception to the quality of the services provided and pre-judge the outcome. For example: How does a patient perceive a dentist whose waiting room is dirty and worn? Does he start to correlate the appearance of the room with the service level provided? Does he question the quality and safety standards of the clinic?





Quality can be effectively communicated to patients by the appearance of your clinic. The design should match your philosophy and your core values. Some of the questions you should ask yourself when looking at your clinic in order to see if you communicate the right message to your patients are:

- Is your environment compatible with your new technology?
- Does your clinic represent your high-tech laser equipment?
- What are your main items of capital equipment?
- How have they changed in recent years?
- How does your deployed equipment score in comparison with that of your competitors?
- How do the facilities, equipment and processes you deploy for providing your service score in comparison with those of your competitors?
- What are your plans for staying ahead, keeping apace or catching up?

### **Choosing location and size of your clinic**

Last but not least: How do you choose the location and the size of your clinic? Let's have a look on some very essential parameters:

1. Demographics of patients
2. Cost (rent/purchase)
3. Neighbourhood image
4. Proximity to market
5. Transportation
6. Parking facilities
7. Accessibility for pedestrians
8. Pollution
9. Traffic patterns
10. Types of businesses around
11. Future value of the area

12. Expansion capabilities
13. Square metre needed

All above aspects and parameters must be considered and often re-evaluated in order to keep up to date and preserve a high standard level of services. They can be implemented and considered to be more than the subjects stated. For example during a keynote speech while you are thinking of how you can make an impressive introduction you can start with the right music. You can use all the above knowledge as guideline in many ways and design the effective marketing of your clinic that will boost your sales and recognition in the market. I am sure you will use these information to transform your clinic's marketing campaign as well as other aspects of your professional life and not only. In the next part of these series, we will discuss the last P of the 7P's, which is process.

Till then, you can send me your questions and request information at [dba@yiannikosdental.com](mailto:dba@yiannikosdental.com) or via our Facebook Account [www.facebook.com/annamaria.yiannikos](http://www.facebook.com/annamaria.yiannikos). Looking forward to our next discussion!

### **contact**



#### **Dr Anna Maria Yiannikos**

Adjunct Faculty Member of AALZ at RWTH Aachen University Campus, Germany  
DDS, LSO, MSc, MBA

[dba@yiannikosdental.com](mailto:dba@yiannikosdental.com)  
[www.dba-aalz.com](http://www.dba-aalz.com)

### **Kurz & bündig**

Eine erfolgreiche Praxis erfordert ein erfolgreiches Management! Orientierung für ein gelungenes Praxismanagement geben die 7 Ps des Marketing Mix. Zwei wichtige Ps sind dabei Praxisgestaltung („physical evidence“) und Ort („place“). Der Ort repräsentiert die Umgebung der Praxis, die wiederum folgende drei Elemente enthalten sollte: Umgebungsbedingungen wie eine musikalische Untermalung der Räume, die räumliche Anordnung der Praxis, was z.B. den Empfangsbereich und die Behandlungsräume betrifft, sowie Zeichen und Symbole beispielsweise auf Visitenkarten und Einrichtungsgegenständen.

Auch die Praxisgestaltung ist von großer Bedeutung. Patienten haben zunächst wenig Anhaltspunkte, was die Servicequalität der Praxis anbelangt und stützen ihre Wahrnehmung in der Regel auf die äußere Erscheinung. Ein unaufgeräumter, unsauberer Warteraum kann erstmal ein negatives Licht auf die Behandlungsqualität werfen. Diese lässt sich also auch über das äußere Erscheinungsbild der Praxis kommunizieren: Ist die Praxis kompatibel mit neuen Technologien? Was sind die Hauptinvestitionsgüter? Gibt es einen Plan, um weiter fortschrittlich zu sein und mit Wettbewerbern Schritt zu halten?

Dies sind nur einige Fragen, die man sich in diesem Zusammenhang stellen sollte. Auch die Wahl des Praxisortes ist von Bedeutung: Wie ist die Patientendemografie in der Gegend? Wie das Nachbarschaftsimage? Gibt es Parkmöglichkeiten? Anbindungen zum öffentlichen Nahverkehr? Bei Beachtung und stetiger Evaluierung der genannten Aspekte steht einem erfolgreichen Praxismanagement nichts im Wege.

# Clinical governance— A system for better health care

Author\_Dr Kashif Hafeez, UK



**\_While accountability and improvement** have been eminent in health care systems for quite some time, there is probably no other time in history when the relevance and importance of these have been more advocated. Learning from our shortcomings and improving our health care system towards better patient care is the goal of clinical governance. I refer to it as the democracy of the health care system, in which all members of the health care team have the right to bring about positive changes.

## **\_Accountability & learning from self-criticism**

Accountability and learning from self-criticism forms the basis of clinical governance, which provides the framework for taking all the steps necessary to make the system more patient-friendly.

It is a cyclical process that once established can help to identify the decisive factors for the quality of patient care. When asked by one of my trainees when the mechanisms of clinical governance ensue in everyday practice, my answer was, "In a patient-centred practice it never stops".

It starts as early as the patient first contacts a practice or a hospital and encompasses the entire health care scenario, starting with welcoming and managing a new patient, ensuring his or her safety on our premises and advising him or her about all aspects of treatment. This combination is all about our transparency to the outside world, ensuring that arbiters and our patients can be certain of our quality of care.

More simply put, clinical governance is the umbrella under which we can provide the best care possible for our patients. It is a structural framework that incorporates all pillars of the health care system. There are channels for the health care team, management and patients alike. Particularly for the last, clinical governance provides an environment free from potential hazards. In addition, patients are given a voice in the system through patient feedback, ensuring that if they draw attention to any wrongdoing, lessons are learnt and such mistakes are not repeated.

## **\_Training and career development**

For our staff and team members, clinical governance ensures that they will be inducted into the sys-

tem effectively in the beginning and be a part of that system through organisational meetings and their annual appraisals throughout their whole career. This way, they will have the best opportunity to improve their skills and advance their professional development. Moreover, this allows them to better judge their clinical effectiveness and communication skills.

Since training and career development are integral parts of clinical governance, it helps the clinicians to identify their learning needs and plan their continued professional development accordingly. Continuing in this loop, they are able to develop improved awareness about the safety of their work environment, as risk management is one of the basic pillars of clinical governance. Through research and development opportunities, they can also learn new skills and treatment protocols.

### **Keeping all involved units in the loop**

Clinical governance is the girdle of an organisation in a health care system: it encompasses all aspects of improved patient care and keeps all involved units in the loop. The management of an organisation can monitor the quality of care provided by it. It can also rate the clinical effectiveness of a particular specialty or clinician. With patient feedback, it can furthermore identify any shortcomings in the system. It will compel the organisation to strive for the professional development of its employees, safeguarding the clinician's right to develop professionally. The impartiality of the system opens the organisation to scrutiny and maintains the absolute system of checks and balances.

Audit is an indispensable part of clinical governance, as it allows the system to self-analyse and induce changes, if needed, that is, we make improvements and then re-audit. Once this cycle has been initiated, it will become a continuous process of re-analysis and improvement. The prime feature of this system is that the whole process is self-sustainable once the system has been implemented. The checks and balances in the system will keep it going and evolving.

The process of clinical governance is quite well-established in the Western world, but it is time that this essential system of health care delivery becomes established in developing economies. After all, it is all about the patients: it is to ensure their continued good care that we study intensely and pursue professional development.

### **about the author**

**Dr Kashif Hafeez** won the "Dentist of the Year" at the prestigious APPS UK Excellence Award 2013. He is currently in private practice in Carterton in the UK.

### **contact**

**Dr Kashif Hafeez**  
Broadshires Dental Practice  
Carterton, OXON OX18 1JA  
United Kingdom  
Tel.: +44 783 334-8725

### **Kurz & bündig**

Verantwortung und Verbesserung im Gesundheitssystem sind heute relevanter und wichtiger denn je. Das Ziel von klinischem Management ist es, aus Schwächen zu lernen und eine stetig verbesserte Patientenversorgung zu gewährleisten. Klinikmanagement beginnt beim ersten Patientenkontakt, der Begrüßung und Versorgung eines neuen Patienten, die Sicherstellung seines Wohlergehens und Einweisung in alle Behandlungsaspekte. Innerhalb dieses Systems haben Patienten die Möglichkeit, Rückmeldung zum Management und zur Behandlung zu geben. Dies ist wichtig, um Schwächen im System ausfindig zu machen und es weiterzuentwickeln.

Für Personal und Teammitglieder gewährleistet Klinikmanagement eine effektive Einführung ins System und Anteilnahme durch Organisationstreffen und jährliche Bewertungen. Auf diese Weise haben sie die Möglichkeit, ihre Fähigkeiten zu verbessern und ihre berufliche Entwicklung voranzutreiben.

Klinikmanagement ist somit wie der Gürtel einer Organisation innerhalb des Gesundheitssystems: es beinhaltet sämtliche Aspekte der Patientenversorgung und bezieht alle Beteiligten in den Kreislauf der Selbstanalyse, Verbesserung und Überprüfung mit ein. Ist das System erst einmal implementiert, funktioniert es gewissermaßen selbsttragend – durch Gewaltenteilung und gegenseitige Kontrolle.

In der westlichen Welt ist Klinikmanagement ein bereits gängiger Prozess. Nun ist es an der Zeit, dieses wichtige System auch in Entwicklungsländern zu etablieren.



# Lasers are becoming increasingly prevalent in dentistry

Author\_Dental Tribune International



Recently, the Peking University School of Stomatology in China and the Hebrew University of Jerusalem's Hadassah School of Dental Medicine in Israel signed an agreement of academic and scientific cooperation. Prof. Guo Chuan-bin, Dean of the School of Stomatology, Prof. Aaron Palmon, Dean of the Hadassah School of Dental Medicine, and Prof. Adam Stabholz, head of the Laser Dentistry Project at the Hebrew University, attended the signing ceremony.

*—The research collaboration between the two dental schools is the first of its kind. What are your expectations of the project?*

**Prof. Guo Chuan-bin:** Actually, we have been familiar with the work done by the Hebrew University of Jerusalem's Hadassah School of Dental Medicine for many years, and Israel's research record is very impressive. This collaboration project will create new opportunities for both parties in the research field and will allow our scholars to exchange ideas and experiences. I am sure the research skills and expertise of the Peking University School of Stomatology will reach another level through this project.

**Prof. Aaron Palmon:** The goal of this project is scientific and academic collaboration. Both the Hebrew University and Peking University are very good academic institutions. The collaboration includes the exchange of researchers and the sharing of academic achievements. I look forward to this collaboration, which we hope will spark new ideas and achieve great successes.

*—Why did the Hebrew University choose the Peking University as a partner for this collaboration?*

**Prof. Adam Stabholz:** Lasers are one of the latest technologies globally and are becoming increasingly prevalent in dentistry. The Peking University School of Stomatology is very well known and we know that China as a country focuses on new technological developments. After Israel and China signed various agreements regarding technology, we thought it advantageous to establish collaboration in the field of dental medicine. The new technology could be introduced into daily dental practice in China through this collaboration. We are honoured to have the opportunity to work with the Peking University School of Stomatology, one of the largest dental schools in the world.



*„In what dental fields can lasers be used, and what are the main advantages?“*

**Prof. Stabholz:** Today, dental lasers are used in many fields of dentistry. Laser is able to achieve results that conventional methods cannot and has a wide range of application. For instance, laser can be used in root canal preparation, to treat periodontal disease, in prosthodontic treatment of primary dentition and to cut soft tissue. Therefore, lasers are a very useful adjunct for dentists. We have numerous ideas and research findings to be applied in practice, and we hope to achieve this through the two institutions working together.

*„In your opinion, how will dental laser technology develop in the future?“*

**Prof. Guo:** Personally, I have not used a laser yet. However, it is well established that laser technology is now widely used in many fields and industries. In dentistry, laser is applied to endodontic treatment, among others, and offers great advantages. Many dental professionals are entering the world of lasers, and I believe this technology has a very bright future.


**Prof. Palmon:** Israel is a very small country, but we are well known for our advanced technology. There are many brilliant companies operating in the development of laser products and conducting related research. Lasers are widely used in dentistry and in numerous other fields. I firmly believe this collaboration will be beneficial to my Chinese colleagues in terms of both experience and technology.

### Kurz & bündig


Die Universität Peking, Institut für Stomatologie in China, und die Hadassah Medical School der Hebräischen Universität in Jerusalem, Israel, werden in Zukunft auf akademischer und wissenschaftlicher Ebene zusammenarbeiten. An der Zeremonie zur Vertragsunterzeichnung nahmen Prof. Guo Chuan-bin, Dekan des Instituts für Stomatologie, Prof. Aaron Palmon, Dekan der Hadassah Medical School sowie Prof. Adam Stabholz, Leiter des Projekts Laserzahnmedizin in der Hebräischen Universität, teil. Im Interview betonten die Vertreter beider Einrichtungen die Relevanz von Laser in der Zahnmedizin und die Möglichkeiten, die sich aus dieser Kooperation ergeben. Laser als eine der weltweit modernsten Technologien sei in der Zahnmedizin zunehmend verbreitet, sagte Prof. Stabholz. „Dieses Kooperationsprojekt wird beiden Parteien neue Möglichkeiten im wissenschaftlichen Bereich eröffnen und einen Austausch von Ideen und Erfahrungen hervorbringen“, so Prof. Guo. Die Zusammenarbeit beinhaltet den Austausch von Wissenschaftlern und die gemeinsame Nutzung akademischer Leistungen.



# IDS 2015: new exhibitor record and increased exhibition space



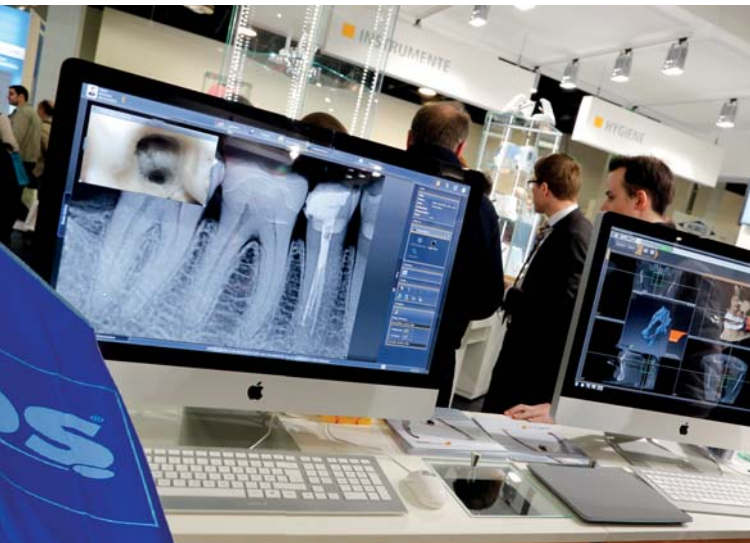The 36<sup>th</sup> International Dental Show gives every indication that the IDS will continue its success in this year. Approximately 2,200 companies from 56 countries are expected at the world's largest trade fair for dentistry and dental technology in Cologne between 10-14 March 2015 – an absolute record for the industry's leading exhibition, which can announce a new exhibitor record. The entire dental industry is represented at the IDS,



including all the international market leaders, which makes it unique in terms of depth and breadth: from dental medicine, to dental technology, infection protection and maintenance, up to customer service, information, communications and organizational materials. IDS 2015 will also set a new record in booked floor space: For the first time in its more than 90-year history, the IDS will present itself on a gross exhibition area of over 150,000 sqm.

The Society for the Promotion of the Dental Industry (GFDI), the commercial enterprise of the Association of German Dental Manufacturers (VDDI), and Koelnmesse have said in a joint statement: "The excellent number of registrations confirms that the IDS is the world's leading business and communications platform for the entire dental industry. On attendance, we are also confident that the IDS will draw on the success of last year's event





[PICTURES: ©KOELNMESSE]

when around 125,000 visitors came to Cologne. We again expect record numbers in terms of numbers of exhibitors and visitors, booked space and internationality for IDS 2015."

The International Dental Show will become the global meeting point for the international dental industry in 2015 as well. About 70 per cent of the exhibiting companies come from abroad and it is generally becoming apparent that more international companies will be represented in Cologne than in years past. The most strongly represented countries after Germany are Italy, the USA, the Republic of Korea, China, France, Switzerland, Taiwan, Turkey, Israel and Great Britain.

Moreover, numerous group participations from abroad, which are organised in collaboration with public or private sector export-promotion organisations or associations, are expected in March again. Currently, 16 group participations are registered—

from Argentina, Brazil, Bulgaria, China, France, Great Britain, Israel, Italy, Japan, Pakistan, Russia, Taiwan, Turkey and the United States. The Republic of Korea is even represented this year with two groups. This diverse and worldwide range of products provides visitors with a comprehensive overview of product innovations, customer services and current trends in the global dental industry.

### **Dealer's Day and specialist supporting programme**

In terms of the International Dental Show concept, the GFDI and the Koelnmesse will adhere to their formula for success for this year's joint event. The IDS trade fair concept clearly places the focus on business transactions and product information at the exhibitor stands. That's why the so-called "Dealer's Day" will be included in the programme again. On the first day of the trade fair (10 March 2015), this will focus on specialised dental dealers

and importers. Within this framework, we let both visitor groups conduct undisturbed sales negotiations at the exhibitor stands.

The successful "Speakers' Corner" concept will also be continued in 2015. This moderated forum lets IDS exhibitors hold specialised lectures and present products in front of visitors. Numerous IDS exhibitors took advantage of this additional opportunity to present themselves at the last event. They presented innovations and trends from their range of products and services in about 65 presentations and thus generated great interest for about 3,000 visitors.

New at IDS 2015 is its "Career Day" on 14 March, which addresses the topic of promoting young researchers in a practical way. This initiative is intended to force communication and information exchange between the companies exhibiting at IDS and students or graduates and trainees from relevant disciplines as well as secondary school students or career changers. IDS exhibitors can look forward to the "Career Day" stage, book short slots for company presentations or conduct individual interviews in the adjoining "Recruitment Lounge" with potential candidates and anyone interested.

IDS 2015 can showcase another innovation with its "Know-how Tour": after the closure of the fair interested dentists can take exclusive tours of two of the most prestigious dental offices in Cologne in three evenings. These are the "PAN-Klinik" and "Doctores Alamouti & Melchior". On the agenda is a professional exchange of expertise on the most modern and latest dental technologies in a small selected circle and in a relaxed atmosphere.

## Optimal IDS preparation with the IDS app and online services

Numerous digital services are available to visitors to optimally plan their visit to the trade show. These contribute to better trade fair preparation and a more efficient visit. The free IDS app is available immediately as a free download on the IDS website. It not only includes a list of exhibitors. Thanks to its innovative navigation system, it also guides visitors unerringly through the IDS halls. The app also contains information on the supporting programme and the on-site services. The app also provides information on the local gastronomy, on-site services and the supporting program of the event.

Visitors can thus access important information on the IDS at any time when they are on the go or in the halls. Another available digital service is Business Matchmaking 365, a communications and business platform that enables visitors and exhibitors to come into direct contact with each other - either before the fair or afterwards. The online personal organiser also lets visitors e-mail exhibitors to request meetings, while the online route planner compiles a personalised plan through the halls.

IDS takes place in Cologne every two years and is organised by the GFDI Gesellschaft zur Förderung der Dental-Industrie mbH, the commercial enterprise of the Association of German Dental Manufacturers (VDDI) and staged by Koelnmesse GmbH, Cologne.

[www.ids-cologne.de](http://www.ids-cologne.de)

### Kurz & bündig

Alles spricht dafür, dass die 36. Internationale Dental-Schau ihren Erfolg in diesem Jahr fortsetzen wird. Vom 10. bis 15. März 2015 werden circa 2.200 Unternehmen aus 56 Ländern auf der weltgrößten Messe für Zahnmedizin und Zahntechnik in Köln erwartet – ein absoluter Rekord für die führende Industrieausstellung.

Auch in puncto gebuchter Ausstellungsfläche kann die IDS einen Rekord aufweisen: Zum ersten Mal in der 90-jährigen Geschichte präsentiert sich die Dental-Schau auf einer Fläche von über 150.000 m<sup>2</sup>.

Bezüglich des Konzepts der Messe bleiben die IDS-Organisatoren GFDI (Gesellschaft zur Förderung der Dental-Industrie mbH) und Koelnmesse bei ihrem bewährten Erfolgsrezept. So wird es auch in diesem Jahr wieder den „Dealer's Day“ (10. März) mit Fokus auf dentale Händler und Importeure geben, bei dem beide Gruppen ungestörte Verkaufsverhandlungen an den Ausstellungsständen abhalten können. Auch der erfolgreiche „Speakers' Corner“ wird 2015 weitergeführt. Bei diesem moderierten Forum halten IDS-Aussteller spezialisierte Vorträge und präsentieren den Besuchern ihre Produkte.

Neu ist dagegen der „Career Day“ am 14. März, der das Thema Förderung des wissenschaftlichen Nachwuchses auf praktische Weise behandelt. Neu ist auch die „Know-how Tour“: Nach Messeschluss können interessierte Zahnärzte an drei Abenden an einer exklusiven Tour zu zwei der renommiertesten Zahnarztpraxen in Köln teilnehmen.

**Return address**

Deutsche Gesellschaft für Laserzahnheilkunde e.V.  
 c/o Universitätsklinikum Aachen  
 Klinik für Zahnerhaltung  
 Pauwelsstraße 30  
 52074 Aachen, Germany

Tel.: +49 241 8088164  
 Fax: +49 241 803388164  
 Credit institute: Sparkasse Aachen  
 IBAN: DE56 3905 0000 0042 0339 44  
 BIC.: AACSD33

# Membership application form



Name/title: \_\_\_\_\_  
 Surname: \_\_\_\_\_  
 Date of birth: \_\_\_\_\_  
 Approbation: \_\_\_\_\_

Status:     self-employed     employed     civil servant     student     dental assistant

**Address: Practice/office/institute (delete as applicable)**

ZIP/city: \_\_\_\_\_ Street: \_\_\_\_\_  
 Phone/fax: \_\_\_\_\_ Email: \_\_\_\_\_  
 Private/place: \_\_\_\_\_ Street: \_\_\_\_\_

Due to an association agreement of DGL and DGZMK, an additional reduced annual fee for DGZMK is charged (85 EUR p.a. if you are not yet a member of DGZMK). The contribution collection is made by the DGZMK office, Liesegangstr. 17a, 40211 Düsseldorf. You will be addressed hereby.

With the application for membership I ensure that

- I am owing an own practice since \_\_\_\_\_ and are working with the laser type \_\_\_\_\_ (exact name)
- I am employed at the practice \_\_\_\_\_
- I am employed at the University \_\_\_\_\_

I apply for membership in the German Association of Laser Dentistry (Deutsche Gesellschaft für Laserzahnheilkunde e.V.)

\_\_\_\_\_  
 Place, date

\_\_\_\_\_  
 Signature

**Annual fee: for voting members with direct debit € 150**

In case of no direct debit authorisation, an administration charge of €31 p/a. becomes due.

**DIRECT DEBIT AUTHORISATION**

I agree that the members fee is debited from my bank account

Name: \_\_\_\_\_ IBAN: \_\_\_\_\_  
 BIC: \_\_\_\_\_ Credit institute: \_\_\_\_\_

\_\_\_\_\_  
 Signature of account holder

\_\_\_\_\_  
 This declaration is valid until written notice of its revocation



Dentist is

## Best job of 2015

Every year, US News & World Report ranks the top 100 jobs. This year, the publisher announced that dentist and dental hygienist are again among the best jobs in the country, with dentist at No. 1. This high ranking is mainly attributable to a considerable predicted employment growth rate, a low unemployment rate and the agreeable work-life balance in the dental profession.

According to US News & World Report, seven of the top ten jobs are in the health care sector, with dentist claiming the No. 1 spot, followed by nurse practitioner at No. 2, physician at No. 3 and dental hygienist at No. 5.

The jobs were ranked based on projected openings, rate of growth, job prospects, unemployment rate and job satisfaction. The US Department of Labor's Bureau of Labor Statistics predicts an employment growth rate of nearly 16 per cent between 2012 and 2022 for the dentist profession, with more than 23,000 new openings. The estimated unemployment rate is 0.9 per cent. Dentist is also among the 2015 top best-paying jobs, US News & World Report stated, only preceded by physicians, who top



the list with an average of US\$188,440 earned in 2013. Dentists earned a median salary of US\$146,340 in 2013. The best-paid earned more than US\$187,999, while the lowest-paid earned less than US\$72,240. Overall, dentists earned more than most other dental professionals. In 2013, dental assistants received an average salary of US\$35,640 and dental hygienists earned about US\$71,530.

Caffeine found to stimulate

## Consumption of sugary drinks

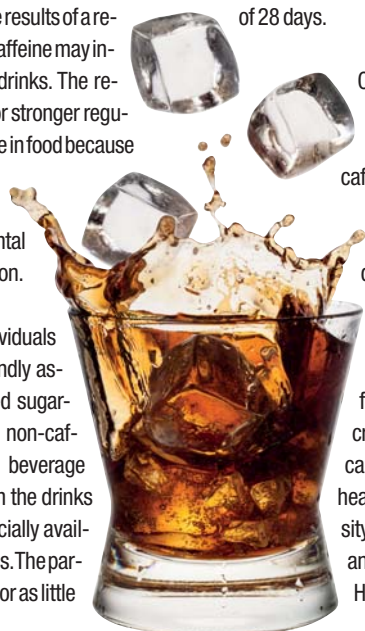Researchers at Deakin University in Melbourne in Australia have announced the results of a recent study that indicate that caffeine may increase consumption of soft drinks. The researchers have thus called for stronger regulation of caffeine as an additive in food because it appears to be a major contributor to obesity and other health issues, such as dental caries in the general population.

The study included 99 individuals aged 18 to 30, who were blindly assigned to either a caffeinated sugar-sweetened beverage or a non-caffeinated sugar-sweetened beverage group. The level of caffeine in the drinks was equal to that in commercially available cola-flavoured beverages. The participants consumed as much or as little

of their respective beverages as desired over a period of 28 days.

Overall, participants who drank caffeinated drinks consumed much more than those who drank the non-caffeinated equivalent, the researchers stated. While the first group had an average intake of 419 ml per day, the remainder drank only 273 ml per day.

"Our findings clearly show that caffeine as an additive in soft drinks increased consumption and with it sugar calories, and that is a significant public health issue given the prevalence of obesity," said Dr Lynn Riddell, senior author and associate professor at the Faculty of Health.



[PICTURE: ©TIMUR]

New device enables patients to

## Hear through tongue

An estimated 36 million people in the US alone suffer from hearing loss. Although surgically implanted hearing aid devices have been used effectively for many years, not all patients are eligible for this procedure. Researchers have now developed a new technology that could help deaf patients hear through a retainer in their mouth.

The new technology, which was developed at Colorado State University, relies on a Bluetooth-enabled earpiece that detects sounds and sends electrical impulses to an electrode-packed retainer. By pressing their tongue against the retainer, users feel a distinct pattern of electric impulses as a tingling or vibrating sensation.

The tongue contains thousands of nerves and the brain is able to decode complicated information from tongue sensations, according to the researchers.



Therefore, the patient's brain will learn to interpret specific patterns as words through training, thus allowing him or her to "hear" through his or her mouth, they explained.

After filing a provisional patent for the technology, the scientists launched a study that aims to determine which parts of the tongue detect electrical impulses and whether those areas differ from person to person. In the study, participants place an array of electrodes in their mouth and report where they feel electrical impulses and how strong they are. If nerve patterns are found to be consistent, the mouthpiece could be standardised for all patients; if not, it will have to be customised for every patient, which is likely to affect cost.

The researchers believe that their invention could become a less invasive and cost-effective alternative to cochlear implants in the future.

Sirona to attend

## IDS Career Day 2015

On Saturday, 14 March, IDS Cologne will be hosting its first Career Day, offering information on topics such as education, career planning and job prospects in the dental profession. The initiative aims to enable companies to address pupils, trainees, students and other persons interested in a career in the dental industry. Career Day will take place at the Speakers' Corner in Hall 3.1 and will include on-stage company presentations, as

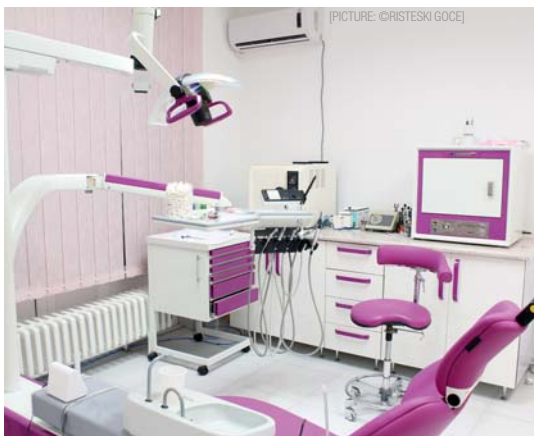

well as a Recruitment Lounge for personal meetings. As part of its presentation at Career Day, Sirona will give two lectures, one at 10 a.m. in English titled "Global market leadership requires world class HR" and another one at 2 p.m. in German on the same topic. Moreover, Sirona will be represented at the Recruitment Lounge, offering information about the company's international career prospects.

"Our employees are our innovation drivers—without them, our success would not be possible. Thus, we place a high value on a modern, open business culture, high responsibility and freedom of scope, as well as excellent career opportunities in the global context," stated Michael Elling, Vice-President of Corporate Human Resources at Sirona.

Dental practice

## Costs in Germany keep increasing



According to a report published by the Institute of German Dentists, the costs for dentists establishing their own practice in Germany have increased significantly—approximately €427,000 in 2013, which are 5 per cent more than in the previous year. Sixty-eight per cent of dentists chose to take over

an existing practice instead of establishing their own. The costs involved in take-over amounted to approximately €300,000.

"For medical care to continue at the current high level and to be comprehensive and offered close to the patient's residence, we need enough dentists who take pleasure in their profession and practise it with commitment and are willing to take the risk of self-employment," asserted Dr Wolfgang Eber, head of the National Association of Statutory Health Insurance Dentists.

For Eber, politics contribute to the uncertain future of young professionals in the country. According to him, there is no planning security owing to frequent government intervention. In addition, excessive administrative burdens take up time necessary for treatment. Furthermore, practices are placed under significant pressure caused by increasing competition and the economisation of health care.

"Smile for life" campaign:

## FDI encourages people to limit sugar intake

As World Oral Health Day (WOHD) 2015 approaches, FDI World Dental Federation advises people to consider the impact of frequent sugar consumption on their smile for life.

When one eats or drinks something sugary, the bacteria in the plaque feeds on the sugar and releases acid that attacks teeth for about one hour. Frequent con-



sumption of sugar results in prolonged acid attacks, weakening the protective outer layer of the teeth.

Speaking about this process, Dr Jaime Edelson, chairperson of the FDI WOHD task team, commented: "Sugar reacts with bacteria in the mouth, which together form an acid that damages the enamel. When this keeps happening, a hole is formed in the tooth, which then requires filling and may over time lead to an extraction. By paying close attention to how often we are consuming sugary foods and drinks, the number of acid attacks on our teeth can be reduced."

WOHD is an opportunity for the FDI to draw attention to proven oral care behaviours that people can adopt to protect their teeth—for life. These include brushing twice a day with a fluoride toothpaste, cutting down on consumption of sugary foods and drinks between meals, and chewing sugar-free gum after meals and snacks when on the go and brushing is not feasible.





27. und 28. November 2015  
in Berlin  
Hotel Palace

# 24. JAHRESTAGUNG DER DGL

## LASER START UP 2015



[www.dgl-jahrestagung.de](http://www.dgl-jahrestagung.de)



[www.startup-laser.de](http://www.startup-laser.de)



### Faxantwort

0341 48474-290

Bitte senden Sie mir das Programm zur/zum

24. JAHRESTAGUNG DER DGL     LASER START UP 2015

am 27. und 28. November 2015 in Berlin zu.

Name/E-Mail-Adresse

Praxisstempel

laser 1/15



# Auf ein Neues!



Prof. Dr. Norbert Gutknecht  
Editor-in-Chief

Liebe Kolleginnen und Kollegen,

Mit dieser Ausgabe beginnt ein neuer Abschnitt in der Deutschen Laserzahnheilkunde. Als zweitälteste Fachgesellschaft weltweit haben wir uns über die vergangenen zwei Jahrzehnte eine gute wissenschaftliche und klinische Expertise erarbeitet. Unsere älteren Mitglieder werden sich sicherlich daran erinnern, dass wir in den ersten Kongressjahren immer eine stattliche Anzahl von internationalen Referenten und internationalen Kongressteilnehmern hatten. Bedingt durch den Wunsch der WFLD und ESOLA haben wir dann auf ein zweisprachiges Kongressprogramm verzichtet und uns ausschließlich auf unsere deutschen Mitglieder und deutschen Kollegen bei den Kongresseinladungen konzentriert.

Zeiten ändern sich, Wünsche ändern sich, Zielsetzungen ändern sich, so auch in der Laserzahnheilkunde. Die wenigen ausländischen Referenten, die unsere Kongresse in den letzten Jahren besuchten, haben sich immer wieder für eine Öffnung unseres DGL-Kongresses für ein englischsprachiges Publikum ausgesprochen. Sowohl die Qualität der Vorträge als auch die Professionalität der Kongressorganisation haben dieses Ansinnen bewirkt. Nach Rücksprache mit unserem Kongressorganisationspartner, die OEMUS MEDIA AG, und nach Rücksprache mit unseren Mitgliedern sowie der Legimitation durch unsere Mitgliederversammlung, haben wir uns entschlossen, zukünftige Kongresse der DGL auch wieder international auszuschreiben.

Des Weiteren hat sich der DGL-Vorstand und die DGL-Mitgliederversammlung entschlossen, unser rein deutschsprachiges Laser Journal in ein nun zweisprachiges Lasermagazin dem **laser international magazine of laser dentistry** aufgehen zu lassen. Wir sind sicher, dass diese beiden Neuerungen nicht nur zur Belebung und zum Wachstum unserer Gesellschaft beitragen, sondern auch zu einer Erweiterung und Vertiefung des Wissens und der Anwendung des Lasers in der Zahnheilkunde führen werden. Dazu haben wir, speziell für unsere DGL-Mitglieder, unter den englischsprachigen Artikeln eine deutsche Zusammenfassung gemacht um ein besseres Verständnis des Beschriebenen zu erhalten.

In diesem Sinne wünsche ich Ihnen sehr viel Freude beim Lesen dieser ersten und aller nachfolgenden zweisprachigen Ausgaben unserer Vereinszeitschrift.

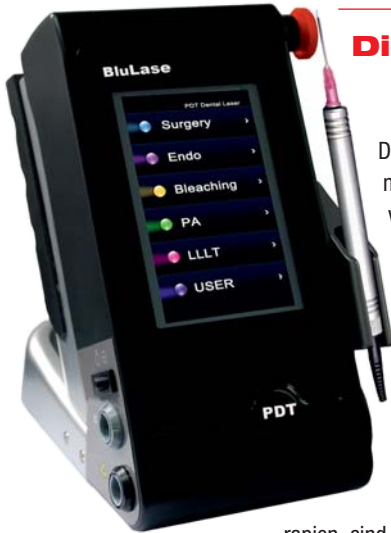Prof. Dr. Norbert Gutknecht  
Präsident der DGL



# Manufacturer News

Schneider Dental

## Diodenlaser mit umfangreichem Service



Diodenlaser in der Zahnmedizin können oft mehr, als der erste Eindruck vermittelt. Wichtig ist dabei eine intuitive und einfache Bedienung. In enger Zusammenarbeit mit Anwendern und Kliniken hat Kryptontronic Technologies deshalb den BluLase 810 PDT entwickelt – ein Gerät, das sich an den täglichen Bedürfnissen der Praxis orientiert. Das kompakte Tischgerät bietet eine komfortable Menüführung, die The-

maximale Hygiene. Die Ausgangsleistung des BluLase 810 PDT von 0,1 bis 7 Watt ermöglicht die Anwendung des kompletten Spektrums der Indikationen für Diodenlaser.

Aber auch das beste Gerät kann ohne professionelle Unterweisung nicht seine ganzen Vorteile ausspielen. Aus diesem Grund hat Kryptontronic Technologies den Vertrieb sowie den Service an die Firma Schneider Dental ausgegliedert. Das Gerät wird in der Regel persönlich in die Praxis geliefert und vor Ort montiert, eine umfangreiche Einweisung von Arzt und Personal erfolgt grundsätzlich vor der Übergabe. Darüber hinaus werden im Rahmen der BluLase-Academy durch Schneider Dental in regelmäßigen Abständen Schulungen angeboten.

rapien sind vorprogrammiert und in logische Gruppen eingeteilt. Das kontrastreiche 7-Zoll Farbdisplay mit Touch-Funktion erlaubt eine einfache Handhabung. Das Standard-Handstück aus eloxiertem Aluminium überzeugt durch sein geringes Gewicht und seine sehr gute Ergonomie, Autoklavierbarkeit und biegbare Einweg-Wechselspitzen garantieren

**Schneider Dental/BluLase**

Muscherstraße 8  
92367 Pilsach, Deutschland  
www.schneiderblulase.com

Fotona

## Erbium-Laser mit patentierten Technologien

Am IDS-Stand M050 in Halle 10.2 von Fotona erhalten Besucher einen Eindruck aus erster Hand von dem preisgekrönten zahnmedizinischen Laser LightWalker AT. Angesehene internationale Experten auf dem Gebiet der Lasierzahnmedizin werden rund um die Uhr am Stand des Unternehmens verfügbar sein, um Fragen zu beantworten und die erweiterten Funktionen des Lasers zu demonstrieren, insbesondere im Fall von schwierig zu behandelnden Bedingungen wie Periimplantitis.

Das state-of-the-art Design, die Bauweise und patentierten Technologien haben den Laser zu einem weltweit am schnellsten schneidenden Erbium-Laser gemacht. In puncto Schnelligkeit und Präzision übertrifft er damit sogar rotierende Bohrer. Gleichzeitig bietet das Gerät ein großes Spektrum effektiver Hart- und Weichgewebsbehandlungen. Typische Prozeduren mit diesem Laser sind schneller, ein-



facher auszuführen, weniger schmerzvoll und benötigen eine kürzere Heilungszeit verglichen mit konventionellen Behandlungen.

Das LightWalker AT-System enthält leistungsstarke Er:YAG- und Nd:YAG-Laser, 20 W und Fotonas patentierte VSP- und QSP-Pulstechnologien für eine bestmögliche Leistung und Kontrolle während einer Vielzahl von Anwendungen, beginnend bei einfacher Kavitätenpräparation bis zur Implantologie und Endodontie. LightWalker AT ist auch der erste Erbium-Laser auf dem zahnmedizinischen Markt mit einer digital kontrollierten Handstück-Technologie (X-Runner®), der den Zahnärzten neue Behandlungsmöglichkeiten und eine bessere Präzision ermöglicht.

**Fotona d.d.**

Stegne 7  
1000 Ljubljana, Slowenien  
www.fotona.com

AD

**laser wünscht Ihnen eine erfolgreiche IDS 2015!**

**laser**  
The Future of Laser Dentistry

**IDS 2015**

**Antwort:**

Deutsche Gesellschaft für Laserzahnheilkunde e.V.  
 c/o Universitätsklinikum Aachen  
 Klinik für Zahnerhaltung  
 Pauwelsstraße 30  
 52074 Aachen

Tel.: 0241 8088164  
 Fax: 0241 803388164  
 E-Mail: sekretariat@dgl-online.de  
 Bank: Sparkasse Aachen  
 IBAN: DE56 3905 0000 0042 0339 44  
 BIC: AACSD33

# Aufnahmeantrag



Name/Titel: \_\_\_\_\_

Vorname: \_\_\_\_\_

Geb.-Datum: \_\_\_\_\_

Approbation: \_\_\_\_\_

Status:  selbstständig  angestellt  Beamter  Student  ZMF/ZAH

**Adresse: Praxis/Dienststelle/Institut (Unzutreffendes bitte streichen)**

PLZ/Ort: \_\_\_\_\_ Straße: \_\_\_\_\_

Telefon/Fax: \_\_\_\_\_ E-Mail: \_\_\_\_\_

Privat/Ort: \_\_\_\_\_ Straße: \_\_\_\_\_

Aufgrund des bestehenden Assoziationsvertrages zwischen der DGL und der DGZMK fällt zusätzlich ein reduzierter Jahresbeitrag für die DGZMK an (85 € p.a., falls Sie noch nicht Mitglied der DGZMK sind). Der Beitragseinzug erfolgt durch die DGZMK-Geschäftsstelle, Liesegangstr. 17a, 40211 Düsseldorf. Sie werden hierfür angeschrieben.

Mit der Stellung dieses Aufnahmeantrages versichere ich, dass ich

- seit dem \_\_\_\_\_ in der eigenen Praxis mit einem Laser des Typs \_\_\_\_\_ arbeite. (genaue Bezeichnung)
- in der Praxis \_\_\_\_\_ beschäftigt bin.
- in der Abt. der Universität \_\_\_\_\_ beschäftigt bin.

Ich beantrage die Aufnahme in die Deutsche Gesellschaft für Laserzahnheilkunde e.V.

\_\_\_\_\_  
 Ort, Datum

\_\_\_\_\_  
 vollständige Unterschrift

**Jahresbeitrag: Für stimmberechtigte Mitglieder bei Bankeinzug 150,00 €.**

Sofern keine Einzugsermächtigung gewünscht wird, wird ein Verwaltungsbeitrag von 31,00 € p.a. fällig.

**EINZUGSERMÄCHTIGUNG**

Ich bin einverstanden, dass der DGL-Mitgliedsbeitrag von meinem Konto abgebucht wird.

Name: \_\_\_\_\_ IBAN: \_\_\_\_\_

BIC: \_\_\_\_\_ Geldinstitut: \_\_\_\_\_

\_\_\_\_\_  
 Unterschrift des Kto.-Inhabers

\_\_\_\_\_  
 Diese Erklärung gilt bis auf schriftlichen Widerruf



DGL beschließt aktuelles

## Abrechnungsmanual für Laserleistungen

Die Deutsche Gesellschaft für Laserzahnmedizin (DGL) hat ein aktuelles Abrechnungsmanual für Laserleistungen entwickelt. Auf Initiative des DGL-Präsidenten Prof. Dr. Norbert Gutknecht wurde eine konsentrierte Aktion zwischen DGL-Vorstandsmitgliedern, die sich schwerpunktmäßig mit Abrechnungsfragen beschäftigen, und externen GOZ-Experten ins Leben gerufen, um ein konsentriertes Abrechnungsmanual zu erstellen. In dieses Projekt wurden auch Kammern, Abrechnungsgesellschaften und ein Fachverlag integriert.

Mit dem neuen Manual ist ein wichtiger Schritt in Richtung Aufklärung über Laserleistungen getan. In den vergangenen Jahren gab es diesbezüglich viele Unklarheiten seitens privater Erstattungsstellen. Diese hatten Versicherten Leistungs-erstattungen mit Begründungen verweigert, die vor

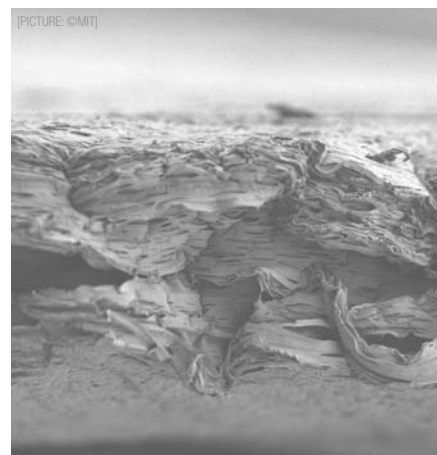
allem auf Unkenntnis beruhten – eine Situation, die sowohl für Patienten als auch für deren laseranwendende Zahnärztinnen und Zahnärzte unbefriedigend war. Bereits vor dem DGL-Jahreskongress wurde das Manual in seiner jetzigen Form vom Vorstand als offizielle Abrechnungsempfehlung der Deutschen Gesellschaft für Laserzahnheilkunde beschlossen, sodass Detlef Klotz und Peter Esser im Rahmen des Kongresses den Mitgliedern im Mainpodium von diesen Ergebnissen berichten konnten. Interessierte DGL-Mitglieder können das Abrechnungsmanual über die DGL-Geschäftsstelle in Aachen (Frau Speck, Tel.: 0241 8088164) erwerben. Alle interessierten Nichtmitglieder können das Manual direkt beim Asgard-Verlag in St. Augustin bestellen (Tel.: 02241 316-40). Das Abrechnungsmanual kann auch im Buchhandel zum Preis von 19,95 Euro bezogen werden.



Wachstumsfaktoren führen zu

## Regeneration von Knochengewebe

Chemiker des Massachusetts Institute of Technology (MIT) sind einen Schritt weitergekommen in der Regeneration von Knochengewebe. Mithilfe von Wachstumsfaktoren, die gezielt über einen längeren Zeitraum abgegeben werden, erreichten sie im Tierversuch einen signifikanten Aufbau von Knochengewebe, welches natürlich gewachsenem in nichts nachsteht. Ein Gewebegerüst ist das Zauberwort, welches die Wissenschaftler nutzen, um direkt dort anzusetzen, wo Knochengewebe benötigt wird. Dieses Gerüst ist beschichtet mit den Wachstumsfaktoren PDGF und BMP-2, die verteilt über mehrere Wochen nach und nach freigegeben werden und so in einer „natürlichen“ Geschwindigkeit für Knochenaufbau sorgen. Bei bisherigen Versuchen zeigte sich, dass eine zu rasche Gabe dieser Wachstumsfaktoren nicht zu einem Gewebeaufbau führt. Die überschüssigen Wachstumsfaktoren werden abtransportiert und es ist mit Nebenwirkungen zu rechnen. Das neue Gewebegerüst



sondert sie in Mengen im Nanogramm-Bereich ab. So sind ein natürlicher Knochenaufbau und die Bildung eines vaskulären Systems in diesem Gewebe möglich.

Das beschichtete Gewebe ist etwa 0,1 mm dick. Es kann auf eine benötigte Größe zugeschnitten und so dort eingebracht werden, wo Knochengewebe erzeugt werden soll. Von dieser Entwicklung könnten Patienten profitieren, die eine Knochenaugmentation vor dem Einsetzen von Implantaten benötigen. Das zugehörige Paper Adaptive growth factor delivery from a polyelectrolyte coating promotes synergistic bone tissue repair and reconstruction erschien kürzlich in den *Proceedings of the National Academy of Sciences*.

Kinderleichte Ausstellersuche mit dem

## today-Messeguide für die IDS 2015

Zur diesjährigen Internationalen Dental-Schau vom 10. bis 14. März in Köln werden mehr als 2.200 Aussteller auf der Koelnmesse vertreten sein und ihre innovativen Produkte einem breiten Publikum präsentieren. Der today-Messeguide hilft bei der Orientierung auf der großräumigen Dentalmesse und bei der Planung des Messebesuches. Als Besucher der Internationalen Dental-Schau legt man mitunter sehr lange Strecken auf dem großzügigen Messegelände der Koelnmesse zurück. Daher sollte ein Besuch auf der diesjährigen IDS sorgfältig geplant sein. Damit man in den Gängen der weitläufigen Messehallen nicht gänzlich den Überblick verliert, navigiert Sie der today-

Messeguide unter messeguide.today sicher durch die Hallen und Gänge der weltgrößten Dentalmesse. Mit der benutzerfreundlichen Ausstellersuche finden Sie schnell und einfach alle ausstellenden Unternehmen mit Hallen- und Standnummer. Das Handling ist dabei kinderleicht: Geben Sie im Suchfeld einfach den Namen der Firma ein, die Sie suchen, oder las-

sen Sie sich alle Aussteller zu einer bestimmten Produktgruppe in einer bestimmten Halle anzeigen. Über eine persönliche Merkliste kann man zudem favorisierte Aussteller abspeichern. Der Messeguide ist auch mobil abrufbar und kann so unterwegs bequem per Smartphone oder Tablet genutzt werden.



Mindestlohn in Praxen stellt

## Gehaltsgefüge auf den Prüfstand



Auch in Zahnarztpraxen sorgt die neue Rechtslage zum Mindestlohn für Handlungsbedarf, denn seit dem 1. Januar 2015 ist der Mindestlohn in Deutschland Gesetz. Das heißt: niedergelassene Zahnärzte sind, genau wie alle anderen Chefs mit Personalverantwortung, gut beraten, zu überprüfen, ob die Arbeitsverträge in ihrer Praxis der neuen Rechtslage entsprechen. Nach dem Mindestlohngesetz haben grundsätzlich alle abhängig beschäftigten Arbeitneh-

mer einen Anspruch auf eine Entlohnung von mindestens 8,50 EUR brutto je Arbeitsstunde. Bei einer 40-Stunden-Woche als Grundlage ergibt sich ein monatlicher Mindestlohn von 1.473 EUR. Auch Zahnärztestehen als Arbeitgeber in der Pflicht: Denn die Regelung betrifft unter anderem die Vergütung von Stomatologischen Schwestern, Zahnmedizinischen Fachangestellten oder Dentalhygienikerinnen. Dieses Mindestentgelt gilt übrigens unabhängig von der Qualifikation des Arbeitnehmers. Das heißt, ein fehlender Berufsabschluss oder mangelnde Sprach- oder Fremdsprachenkenntnisse rechtfertigen generell keine Ausnahme von der Verpflichtung zur Zahlung des Mindestlohns. Auch wenn die gesetzlichen Vorgaben in Zahnarztpraxen auf den ersten Blick meist erfüllt scheinen, sollte der Zahnarzt bei der Rückversicherung Sorgfalt walten lassen. Denn die neuen Voraussetzungen bedeuten für ihn, dass er beispielsweise auch seinen Büro- oder Reinigungskräften den Mindestlohn zahlen muss, selbst wenn er diese nur als Minijobber beschäftigt.

Neues E-Health-Gesetz erzwingt

## Preisgabe von Daten durch Ärzte und Patienten

Mit einem E-Health-Gesetz will Bundesgesundheitsminister Hermann Gröhe (CDU) die digitale Transformation im Gesundheitswesen und dabei vor allem das Projekt elektronische Gesundheitskarte (eGK) durchsetzen. Die Freie Ärzteschaft (FÄ) kritisiert den Referentenentwurf zu diesem Gesetz scharf: „Statt für gute Medizin zu sorgen, kommt jetzt ein neues Gesetz, mit dem massiv Druck auf Ärzte und Patienten ausgeübt wird“, sagte FÄ-Vorsitzender Wieland Dietrich. „Freiwilligkeit der Datenpreisgabe – informationelle Selbstbestimmung als europäisches Grundrecht – soll es nicht mehr geben!“

Schon zuvor hatte Gröhe „Blockierern“ der eGK mit Geldstrafen gedroht. Laut Referentenentwurf soll „ein Sanktionsmechanismus auf der Ebene der Arztpraxen eingeführt“ werden. Belohnt werden soll stattdessen, wer pariert. International seien Projekte wie das eGK-Projekt reihenweise gescheitert. Es gebe keinen einzigen Nachweis dafür, dass die angestrebten Ziele wie zentrale Patientenakte, elektronisches Arzneimittelmanagement oder elektronische Notfalldatensätze die medizinische Betreuung der Bevölkerung verbes-



sern würden. In dem Referentenentwurf wird darüber hinaus betont, dass nur solche Anwendungen der zentralen Infrastruktur ermöglicht und massiv ausgewertet werden sollen, die kommerziellen Zielen nützen. FÄ-Vizevorsitzende Dr. Silke Lüder macht klar: „Hier wird die Tür ganz weit aufgestoßen für die renditeorientierte Nutzung von Patientendaten, die heute schon als neue ‚Währung‘ in der Gesundheitsindustrie gehandelt werden. Zusammen mit der angekündigten Abschaffung von bis zu 25.000 Arztpraxen in Deutschland wird das E-Health-Gesetz nur dies bewirken: mehr Bürokratie, eine Medizin des Misstrauens, mehr Frust bei den im Gesundheitswesen Tätigen und noch weniger Niederlassungen junger Ärzte.“

Online Punkte sammeln mit der

## CME-Fortbildung auf ZWP online

ZWP online hat ein neues Weiterbildungs-Tool: Mit der CME-Fortbildung können Zahnärzte ab jetzt ganz bequem Punkte gemäß der Leitlinien von der Bundeszahnärztekammer (BZÄK) und der Deutschen Gesellschaft für Zahn-, Mund- und Kieferheilkunde (DGZMK) online sammeln.

CME bedeutet „Continuing Medical Education“ (kontinuierliche ärztliche Fortbildung) und ist ein



Fortbildungsangebot, welches den Vorgaben des GKV-Modernisierungsgesetzes (2006) entspricht und gemäß den Leitsätzen der BZÄK sowie der DGZMK auf freiwilliger Basis erfolgt. Vertragszahnärzte, ermächtigte Zahnärzte und angestellte Zahnärzte sind gesetzlich dazu verpflichtet, ihr Fachwissen regelmäßig und kontinuierlich auf den neuesten Stand zu bringen.

Nach der kostenlosen Registrierung unter [www.zwp-online.info/cme-fortbildung](http://www.zwp-online.info/cme-fortbildung) erhalten die Nutzer eine Bestätigungsmail und können das Fortbildungsangebot sofort vollständig nutzen. Als Grundlage dienen wissenschaftliche Artikel renommierter Experten aus den einzelnen Fachgebieten. Der dazu angebotene Fragebogen muss mindestens zu 70 Prozent korrekt ausgefüllt werden, um die jeweiligen Fortbildungspunkte gutgeschrieben zu bekommen.

Der Fragebogen steht zwei Jahre lang zur Beantwortung zur Verfügung. In diesem Zeitraum hat jeder registrierte Nutzer pro Bogen drei Mal die Möglichkeit, ihn korrekt auszufüllen. Nach drei Fehlversuchen ist die jeweilige Fortbildung für den Nutzer nicht mehr verfügbar. Bei erfolgreicher Teilnahme erhält der Nutzer ein Zertifikat über 2 CME-Punkte, was anschließend bei der Kammer einzureichen ist.

**laser**  
international magazine of laser dentistry

**WFLD** World Federation for Laser Dentistry  
Formerly ISLD, founded 1988

0277113



**Publisher**

Torsten R. Oemus  
[oemus@oemus-media.de](mailto:oemus@oemus-media.de)

**CEO**

Ingolff Döbbecke  
[doebbecke@oemus-media.de](mailto:doebbecke@oemus-media.de)

**Members of the Board**

Jürgen Isbaner  
[isbaner@oemus-media.de](mailto:isbaner@oemus-media.de)

Lutz V. Hiller

[hiller@oemus-media.de](mailto:hiller@oemus-media.de)

**Editor in Chief**

Norbert Gutknecht  
[ngutknecht@ukaachen.de](mailto:ngutknecht@ukaachen.de)

**Coeditors in Chief**

Samir Nammour  
Matthias Frentzen

**Managing Editors**

Georg Bach  
Leon Vanweersch

**Division Editors**

Umberto Romeo  
*European Division*

Melissa Marchesan  
*North American Division*

Carlos de Paula Eduardo  
*South American Division*

Toni Zeinoun  
*Middle East & Africa Division*

Ambrose Chan  
*Asia & Pacific Division*

**Senior Editors**

Aldo Brugneira Junior  
Kenji Yoshida  
Lynn Powell  
Dimitris Strakas  
Adam Stabholz  
Marcia Martins Marques

**Editorial Board**

Peter Steen Hansen, Aisha Sultan, Ahmed A Hassan, Antonis Kallis, Dimitris Strakas, Kenneth Luk, Mukul Jain, Reza Fekrazad, Sharonit Sahar-Helft, Lajos Gaspar, Paolo Vescovi, Ilay Maden, Jaana Sippus, Hideaki Suda, Ki-Suk Kim, Miguel Martins, Aslihan Üsümez, Liang Ling Seow, Shaymant Singh Makhan, Enrique Trevino, Blanca de Grande, José Correia de Campos, Carmen Todea, Saleh Ghabban Stephen Hsu, Antoni Espana Tost, Josep Arnabat, Alaa Sultan, Leif Berven, Evgeniy Mironov Ahmed Abdullah, Boris Gaspirc, Peter Fahlstedt, Ali Saad Alghamdi, Alireza Fallah, Michel Vock, Hsin-Cheng Liu, SajeeSattayut, Anna-Maria Yannikou, Ryan Seto, Joyce Fong, Iris Brader, Masoud Mojahedi, Gerd Volland, Gabriele Schindler, Ralf Borchers, Stefan Grümer, Joachim Schiffer, Detlef Klotz, Jörg Meister, ReneFranzen, Andreas Braun, Sabine Sennhenn-Kirchner, Siegfried Jänicke, Olaf Oberhofer, Thorsten Kleinert

**Editorial Office**

Georg Isbaner  
[g.isbaner@oemus-media.de](mailto:g.isbaner@oemus-media.de)

Katrin Maiterth  
[k.maiterth@oemus-media.de](mailto:k.maiterth@oemus-media.de)

**Executive Producer**

Gernot Meyer  
[meyer@oemus-media.de](mailto:meyer@oemus-media.de)

**Designer**

Sarah Fuhrmann  
[s.fuhrmann@oemus-media.de](mailto:s.fuhrmann@oemus-media.de)

**Customer Service**

Marius Mezger  
[m.mezger@oemus-media.de](mailto:m.mezger@oemus-media.de)

**Published by**

OEMUS MEDIA AG  
Holbeinstraße 29, 04229 Leipzig, Germany  
Tel.: +49 341 48474-0  
Fax: +49 341 48474-290  
[kontakt@oemus-media.de](mailto:kontakt@oemus-media.de)  
[www.oemus.com](http://www.oemus.com)

**Printed by**

Silber Druck oHG  
Am Waldstrauch 1, 34266 Niestetal, Germany

**laser** international magazine of laser dentistry is published in cooperation with the World Federation for Laser Dentistry (WFLD).

**WFLD Headquarters**

University of Aachen Medical Faculty  
Clinic of Conservative Dentistry  
Pauwelsstr. 30, 52074 Aachen, Germany  
Tel.: +49 241 808964  
Fax: +49 241 803389644  
[ngutknecht@ukaachen.de](mailto:ngutknecht@ukaachen.de)  
[www.wfld-org.info](http://www.wfld-org.info)

[www.laser-magazine.com](http://www.laser-magazine.com)

**Copyright Regulations**

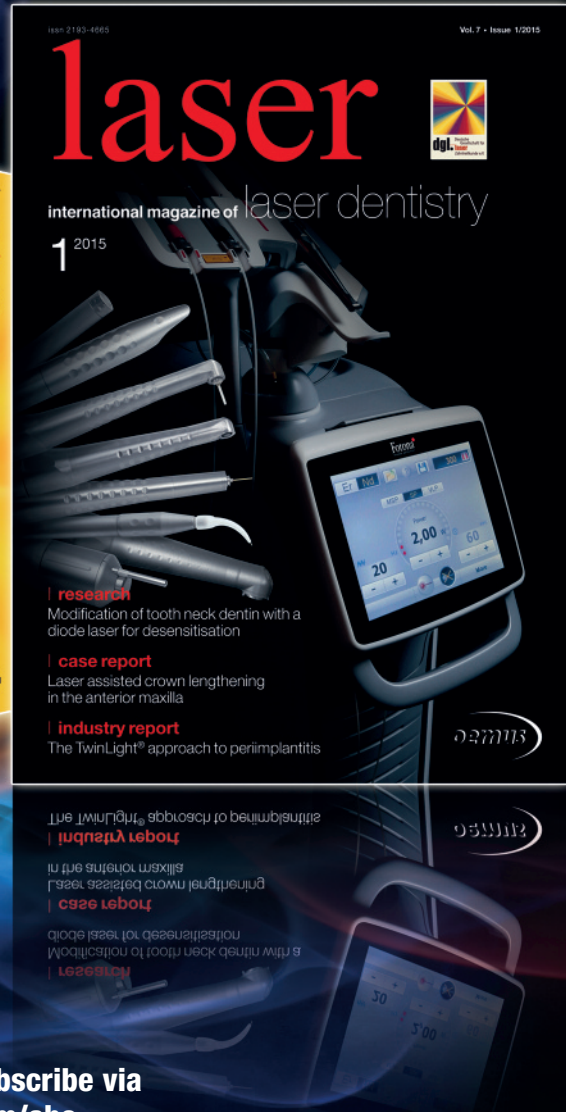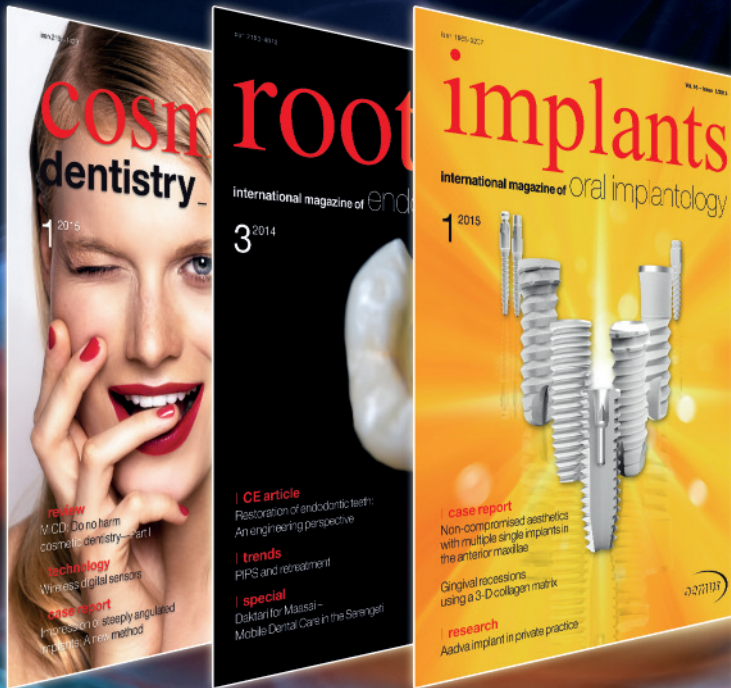**laser** international magazine of laser dentistry is published by OEMUS MEDIA AG and will appear in 2015 with one issue every quarter. The magazine and all articles and illustrations therein are protected by copyright. Any utilization without the prior consent of editor and publisher is inadmissible and liable to prosecution. This applies in particular to duplicate copies, translations, microfilms, and storage and processing in electronic systems.

Reproductions, including extracts, may only be made with the permission of the publisher. Given no statement to the contrary, any submissions to the editorial department are understood to be in agreement with a full or partial publishing of said submission. The editorial department reserves the right to check all submitted articles for formal errors and factual authority, and to make amendments if necessary. No responsibility shall be taken for unsolicited books and manuscripts. Articles bearing symbols other than that of the editorial department, or which are distinguished by the name of the author, represent the opinion of the afore-mentioned, and do not have to comply with the views of OEMUS MEDIA AG. Responsibility for such articles shall be borne by the author. Responsibility for advertisements and other specially labeled items shall not be borne by the editorial department. Likewise, no responsibility shall be assumed for information published about associations, companies and commercial markets. All cases of consequential liability arising from inaccurate or faulty representation are excluded. General terms and conditions apply, legal venue is Leipzig, Germany.



# laser

international magazine of laser dentistry



 **Subscribe now!**

You can also subscribe via  
[www.oemus.com/abo](http://www.oemus.com/abo)

I would like to subscribe to **laser international magazine of laser dentistry** (4 issues per year) for € 44 including shipping and VAT for German customers, € 46 including shipping and VAT for customers outside Germany, unless a written cancellation is sent within 14 days of the receipt of the trial subscription. The subscription will be renewed automatically every year until a written cancellation is sent to OEMUS MEDIA AG, Holbeinstr. 29, 04229 Leipzig, Germany, six weeks prior to the renewal date.

► **Reply** via Fax +49 341 48474-290 to OEMUS MEDIA AG or per E-mail to [grasse@oemus-media.de](mailto:grasse@oemus-media.de)

Last Name, First Name	
Company	
Street	
ZIP/City/County	
E-mail	Signature

Notice of revocation: I am able to revoke the subscription within 14 days after my order by sending a written cancellation to OEMUS MEDIA AG, Holbeinstr. 29, 04229 Leipzig, Germany.

Signature
-----------

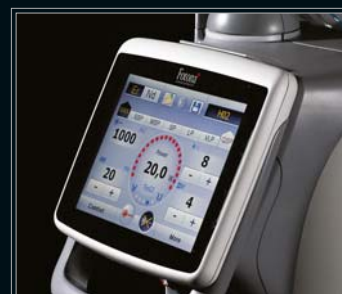


The universe at your fingertips.

## TwinLight<sup>®</sup> Peri-implantitis Treatment

A simple and effective procedure that offers the power to treat peri-implantitis – an increasing threat to oral health.

- Minimally-invasive technique
- Fast regeneration/healing
- Reduced inflammatory response
- Highly effective treatment
- No antibiotics needed



Visit Fotona at IDS, Booth M050, Hall 10.2



LightWalker<sup>®</sup>

[www.lightwalkerlaser.com](http://www.lightwalkerlaser.com)

Peri-implantitis treatment video

