

**Editor**

**NORINA CONSUELA FORNA**



**NEW INTERDISCIPLINARY APPROACHES  
IN ORAL AND GENERAL REHABILITATION**

**- VOLUME OF ABSTRACTS -**

**EDITURA "GR. T. POPA" – IAȘI**

**2015**





Organized by  
Balkan Stomatological Society  
and  
Romanian Society of Oral Rehabilitation



## BaSS 2015

20<sup>th</sup> Congress of the Balkan Stomatological Society

# *New Interdisciplinary Approaches in Oral and General Rehabilitation* **JUBILEE EDITION**

April 23<sup>rd</sup> – 26<sup>th</sup> 2015  
Bucharest, Romania, Intercontinental Hotel

[www.e-bass.org](http://www.e-bass.org)

---

April 23<sup>rd</sup> – 26<sup>th</sup>, Bucharest, Romania

Descrierea CIP a Bibliotecii Naționale a României

**CONGRESS OF THE BALKAN STOMATOLOGICAL SOCIETY**

(20 ; 2015 ; București)

**New interdisciplinary approaches in oral and general rehabilitation: 20th Congress of the Balkan Stomatological Society : April 23rd – 26th 2015 Bucharest, Romania : Volume of Abstracts** / ed.: Norina Consuela Forna. - Iași : Editura Gr.T. Popa, 2015

Bibliogr.

ISBN 978-606-544-304-4

I. Forna, Norina (ed.)

616.314(063)

*Referent științific:*

**Prof. univ. dr. Mircea Rusu – U.M.F. “Grigore T. Popa” Iași**

*Editura Gr. T. Popa ”*

Universitatea de Medicină și Farmacie Iași

Str. Universității nr. 16

**Editura “Gr. T. Popa” este acreditată de CNCIS – Consiliul Național al Cercetării Științifice din Învățământul Superior**

*Toate drepturile asupra acestei lucrări aparțin autorului și Editurii “Gr. T. Popa” Iași. Nici o parte din acest volum nu poate fi copiată sau transmisă prin nici un mijloc, electronic sau mecanic, inclusiv fotocopiere, fără permisiunea scrisă din partea autorului sau a editurii.*

---

Tiparul executat la Tipografia Universității de Medicină și Farmacie “Gr. T. Popa” Iași

Str. Universității nr. 16, cod 700115, Tel. 0232301678

---

## BASS COUNCIL MEMBERS

### EXECUTIVE COMMITTEE:

<b>President:</b>	<b>Asst. Prof. Nikolai Sharkov</b>
<b>Past President:</b>	Prof. Hamit Bostanci
<b>President Elect:</b>	Prof. Dragoslav Stamenkovic
<b>Vice President:</b>	Prof. Argirios Pissiotis
<b>Secretary General:</b>	Assoc. Prof. Nicolaos Economides
<b>Honorary Treasurer:</b>	Assoc. Prof. Stylianos Dalampiras
<b>Editor-in-Chief:</b>	Prof. Ljubomir Todorovic

### COUNCIL:

COUNTRY	Councilors	Deputy Councilors
<b>ALBANIA</b>	Ruzhdie Qafmolla Rozarka Budina	Dorjan Hysi Edit Xhajanka
<b>BOSNIA-HERZEGOVINA</b>	Maida Ganibegovic Mihael Stanojevic	D. Colic M. Lucic
<b>BULGARIA</b>	Andon Filchev Donka Stancheva Zaburtova	Miroslava Dinkova Rositca Encheva
<b>CYPRUS</b>	Georgios Pantelas Sami Solyali	Rodos Irodotou Husein Bicak
<b>F.Y.R.O.M.</b>	Ana Minovska Julio Popovski	Iliana Muratovska Marijan Dejanovski
<b>GREECE</b>	Nicos Maroufidis Anastasios Markopoulos	Georgios Tsiogas Elissavet Koulaouzidou
<b>MONTENEGRO</b>	Djenad Ganjola Mirjan Djurickovic	Branko Rasovic Aleksandar Adzic
<b>ROMANIA</b>	Norina Fornu	Ecaterina Ionescu Oana - Cella Andrei
<b>SERBIA</b>	Momir Carevic Miodrag Barjaktarevic	Dejan Markovic Slobotan Andjelkovic
<b>TURKEY</b>	Ender Kazazoglu Nejat Arpak	Murat Akkaya G. Gur

## CONGRESS COMMITTEES

### President of the Congress

Professor Dr. NORINA CONSUELA FORNA

### General Secretary of the Congress

Lecturer Dr. Sorina Mihaela Solomon

### SCIENTIFIC COMMITTEE :

#### FOREIGN MEMBERS :

Dr. Rozarka Budina	- Albania
Assoc. Prof. Dr. Dorjan Hysi	- Albania
Assoc. Prof. Dr. Alketa Qafmolla	- Albania
Prof. Dr. Ruzhdie Qafmolla	- Albania
Prof. Dr. Muhamed Ajanović	- Bosnia & Herzegovina
Prof. Dr. Maida Ganibegovic	- Bosnia & Herzegovina
Assoc. Prof. Dr. Tomic Slavoljub	- Bosnia & Herzegovina
Dr. Mihael Stanojevic	- Bosnia & Herzegovina
Prof. Dr. Selma Zukić	- Bosnia & Herzegovina
Assoc. Prof. Dr. Theodora Bolyarova	- Bulgaria
Prof. Dr. Andon Filchev	- Bulgaria
Assoc. Prof. Dr. Elka Nikolaeva Radeva	- Bulgaria
Asst. Prof. Nikolai Sharkov	- Bulgaria
Dr. Donka Stancheva Zaburtova	- Bulgaria
Prof. Dr. Atilla Berberoglu	- Cyprus
Prof. Dr. Georgios Pantelas	- Cyprus
Dr. Sami Solyali	- Cyprus
Prof. Dr. Biljana Kapusevska	- FYROM
Prof. Dr. Ana Minovska	- FYROM
Assoc. Prof. Dr. Ilijana Muratovska	- FYROM
Dr. Julio Popovski	- FYROM
Assoc. Prof. Dr. Natasa Toseska-Spasova	- FYROM
Prof. Dr. Stylianos Dalampiras	- Greece
Assoc. Prof. Dr. Nicolaos Economides	- Greece
Prof. Dr. Petros Koidis	- Greece
Prof. Dr. Anastasios Markopoulos	- Greece
Dr. Nikos Maroufidis	- Greece
Prof. Dr. Georgios Pantelas	- Greece
Prof. Dr. Argirios Pissiotis	- Greece
Lect. Dr. Antigone Delantoni	- Greece
Lect. Dr. Charis Beltes	- Greece
Dr. Mirjan Djurickovic	- Montenegro
Dr. Djenad Gjanola	- Montenegro
Dr. Zoran Vlahovic	- Montenegro
Prof. Dr. Momir Carevic	- Serbia

Prof. Dr. Kosovka Obradović Djuričić	- Serbia
Senior Lecturer Dr. Katarina Radovic	- Serbia
Prof. Dr. Dragoslav Stamenkovic	- Serbia
Prof. Dr. Ljubomir Todorovic	- Serbia
Prof. Dr. Murat Akkaya	- Turkey
Dr. Nejat Arpak	- Turkey
Prof. Dr. Hamit Bostanci	- Turkey
Prof. Dr. Kaan Orhan	- Turkey
Assoc. Prof. Dr. Hana Hubalkova	- Czech Republic
Prof. Dr. Kadhim Al Himdani	- France
Prof. Dr. Ady Palti	- Germany
Assoc. Prof. Dr. Valeriu Fala	- Republic of Moldavia
Prof. Dr. Ion Lupan	- Republic of Moldavia
Prof. Dr. Oleg Solomon	- Republic of Moldavia
Assoc. Prof. Dr. Aurelia Spinei	- Republic of Moldavia
Assoc. Prof. Dr. Valentina Trifan	- Republic of Moldavia
Assoc. Prof. Dr. Diana Uncuta	- Republic of Moldavia
Prof. Dr. Chang Heun Park	- Republic of South Korea
Prof. Dr. Kwidug Yun	- Republic of South Korea
Prof. Dr. Cheol Woong Jeong	- Republic of South Korea

#### **ROMANIAN MEMBERS :**

Acad. Dr. Constantin Balaceanu Stolnici, Bucharest	Prof. Dr. Monica Tatarciuc, Iasi
Acad. Dr. Vlad Alexandru Ciurea, Bucharest	Prof. Dr. Grigore Tinica, Iasi
Acad. Dr. Constantin Ionescu Targoviste, Bucharest	Prof. Dr. Irina Zetu, Iasi
Prof. Dr. Iulian Antoniac, Bucharest	Dr. Alexandru Brezoescu, Bucharest
Prof. Dr. Catalina Arsenescu, Iasi	Assoc. Prof. Dr. Adriana Balan, Iasi
Prof. Dr. Gabriela Bancescu, Bucharest	Assoc. Prof. Dr. Lucia Barlean, Iasi
Prof. Dr. Alexandru Bucur, Bucharest	Assoc. Prof. Dr. Gianina Iovan, Iasi
Prof. Dr. Marin Burlea, Iasi	Assoc. Prof. Dr. Luminita Maria Nica, Timisoara
Prof. Dr. Cristina Maria Bortun, Timisoara	Assoc. Prof. Dr. Liliana Porojan, Timisoara
Prof. Dr. Radu Septimiu Campian, Cluj Napoca	Assoc. Prof. Dr. Cosmin Sinescu, Timisoara
Prof. Dr. Aureliana Caraiane, Constanta	Assoc. Prof. Dr. Oana Eilina Teodorescu - Milicescu, Bucharest
Prof. Dr. Ioan Danila, Iasi	Lecturer Dr. Ana Maria Ciubara, Iasi
Prof. Dr. Liliana Foia, Iasi	Lecturer Dr. Cristina Gena Dascalu, Iasi
Prof. Dr. Stefan Octavian Georgescu, Iasi	Lecturer Dr. Smaranda Diaconescu, Iasi
Prof. Dr. Gabriela Ifteni, Iasi	Lecturer Dr. Irina Gradinaru, Iasi
Prof. Dr. Andrei Iliescu, Bucharest	Lecturer Dr. Loredana Hurjui, Iasi
Prof. Dr. Ecaterina Ionescu, Bucharest	Lecturer Dr. Marina Cristina Iordache, Iasi
Prof. Dr. Andrei Kozma, Bucharest	Lecturer Dr. Horia Octavian Manolea, Craiova
Prof. Dr. Rodica Luca, Bucharest	Lecturer Dr. Carmen Manciu, Iasi
Prof. Dr. Veronica Mercut, Craiova	Lecturer Dr. Sorina Mihaela Solomon, Iasi
Prof. Dr. Traian Mihaescu, Iasi	Lecturer Dr. Vasile Valeriu Lupu, Iasi
Prof. Dr. Meda Lavinia Negrutiu, Timisoara	Assist. Dr. Dorian Agop Forna
Prof. Dr. Mariana Pacurar, Targu Mures	Assist. Dr. Carina Balcos, Iasi
Prof. Dr. Sanda Mihaela Popescu, Craiova	Assist. Dr. Lucian Burlea, Iasi
	Assist. Dr. Claudia Florida Costea, Iasi
	Assist. Dr. Ramona Feier, Iasi

## THE BASS AWARD COMMITTEE :

Prof. Dr. Norina Forna	- President of the BaSS Congress 2015
Prof. Dr. Maida Ganibegovic	- Bosnia & Herzegovina
Dr. Julio Popovski	- FYROM
Prof. Dr. Stylianos Dalampiras	- Greece
Prof. Dr. Momir Carevic	- Serbia
Prof. Dr. Hamit Bostance	- Turkey

## ORGANIZING COMMITTEE:

Assoc. Prof. Dr. Vasilica Toma, Iasi	Assist. Dr. Ana Maria Filioreanu, Iasi
Lecturer Dr. Liana Aminov, Iasi	Assist. Dr. Ionut Luchian, Iasi
Lecturer Dr. Dan Nicolae Bosanceanu, Iasi	Assist. Dr. Alexandra Martu, Iasi
Lecturer Dr. Victor Vlad Costan, Iasi	
Lecturer Dr. Diana Diaconu, Iasi	Dr. Bardis Dimitrios, Iasi
Lecturer Dr. Loredana Hurjui, Iasi	Stud. Karina Elena Balas, Iasi
Lecturer Dr. Vasile Valeriu Lupu, Iasi	Stud. Magda Barlean, Iasi
Lecturer Dr. Alice Murariu, Iasi	Stud. Elena McAdam, Iasi
Lecturer Dr. Ana Petcu, Iasi	Stud. Bassil Raymond Victor, Iasi
Lecturer Dr. Mihaela Salceanu, Iasi	Stud. Jendoubi Sabrine, Iasi
Lecturer Dr. Carmen Savin, Iasi	Stud. Michail Timotheatos, Iasi
Lecturer Dr. Mihaela Monica Scutariu, Iasi	
Lecturer Dr. Simona Stoleriu, Iasi	

### **Romania IT Support:**

Ionut Baltag  
Manager General SC JOHN B Agency SRL  
www.socialdoc.ro / tel. +40 742 154 378





**BaSS President  
Asst. Prof. Dr. Nikolai Sharkov**

*Dear distinguished colleagues,  
Dear ladies and gentlemen,*

*On behalf of the Balkan Stomatological Society I am greatly honoured and pleased to welcome you to the 20th Edition of the Balkan Stomatological Society Congress-“New interdisciplinary approaches in Oral and General Rehabilitation” which will be held in Bucharest, 23rd -26th of April, 2015.*

*We estimate about 800 participants from all Balkan countries and not only those that will make our congress a truly European initiative. This congress is certainly a special occasion for those who work for the research and professional development of dental medicine and will feature an exciting line-up of expert speakers including top practitioners, opinion leaders and researchers. It will be an occasion to meet, to listen, to discuss, to share information and to plan for the future. Indeed, a congress is an opportunity to discuss key points of scientific and professional policies and strategies, helping us to define how we should encourage responsible conduct, to promote Dental Medicine at the European level and also to establish personal contacts with colleagues from other parts of the world.*

*By the end of the Congress, as usual, we intend to formulate the final conclusions and eventually make some recommendations, which will be a benchmark for the future and will certainly contribute to promote excellent research and appoint principles and strategies for our colleagues.*

*With these words, I hope this Congress provides you with a forum to exchange scientific ideas, inspire new research, and new contacts for closer co-operation, so that we can, together, envisage the future of a promising development of Dental Medicine in Europe and FDI, where BaSS is member.*

*I also wish you a pleasant and interesting stay in Bucharest.*

*Thank you very much!*

**President of BaSS  
Asst. Prof. Dr. Nikolai Sharkov**



President of BaSS Congress 2015

**Prof. Univ. Dr. Norina Forna**

Dean, Faculty of Dental Medicine,

Grigore T. Popa U.M.Ph., Iasi, Romania

President of the Romanian Society of Oral Rehabilitation

*Dear Colleagues,*

*It is our privilege and special pleasure to welcome you to the Jubiliary 20th Edition of the Balkan Stomatological Society Congress in Bucharest, a milestone in the history of BASS.*

*This meeting will offer practitioners from across the world an ideal opportunity to pursue continuing medical education, to learn about recent advances, likely future developments and potential research avenues, and to exchange scientific ideas and experiences in our field – all within a unique environment.*

*The BASS meeting promises to be a highlight for the multidisciplinary community that forms the heart and soul of dental medicine. There will be plenary lectures devoted to this field of interest; distinguished speakers will address the state of the art and new developments in clinical and paraclinical areas of interdisciplinary covering a broad range of topics. The multidisciplinary symposia organized throughout the meeting will truly reflect BASS's mission to interact with other European and global organizations, with the goal of providing the best possible care for our patients.*

*However, we rely on the most meaningful participation of many colleagues from all over Europe in order to make our congress a real scientific success. Thus, we wish you nice days in the heart of European culture and civilization, according to the traditional Romanian hospitality.*

**President of BaSS Congress 2015**

**Prof. Univ. Dr. Norina Forna**

Dean, Faculty of Dental Medicine,

Grigore T. Popa U.M.Ph., Iasi, Romania

President of the Romanian Society of Oral Rehabilitation



**President of the Romanian National College of Dentists  
Prof. Univ. Dr. Ecaterina Ionescu**

*Distinguished Guests,  
Dear Colleagues,  
Ladies and Gentlemen*

*As President of the Romanian National College of Dentists, I am pleased and honored to welcome our eminent speakers, the BASS delegates and all participants who will come from all over Europe in the wonderful city of Bucharest for the 20th Congress of the Balkan Stomatological Society.*

*I would like to present my compliments to all academic colleagues and administrative authorities participating in this scientific event and express to you my deep satisfaction for sharing this important moment for European Dental Medicine in our country.*

*Let me wish you all an enriching, knowledgeable, learning experience and for our overseas guests, don't forget to enjoy this city and the sights and food of Romanian cuisine.*

*Thank you,*

***President of the Romanian National College of Dentists,  
Prof. Univ. Dr. Ecaterina Ionescu***

## BaSS CONGRESS HISTORY

BaSS Congresses	Venue - Dates	President of the Congress	Presidents of Committees	BaSS President	BaSS General Secretary
1 <sup>st</sup>	Helexpo, "I. Vellidis" Congress Center Thessaloniki, Greece 28 – 31 March 1996	Prof. Dr. Dimitris Karakasis	Dr. Kostas Hatzipanagiotou Prof. Dr. Dimitris Karakasis	-	-
2 <sup>nd</sup>	Sava Center Belgrade, Yugoslavia 2 – 5 April 1997	Prof. Dr. Dragan Beloica	Prof. Dr. Marko Vulovic Prof. Dr. Ljubomir Todorovic	Prof. Dr. Dimitris Karakasis	Prof. Dr. Dimitris Iakovidis
3 <sup>rd</sup>	National Palace of Culture Sofia, Bulgaria 2 – 5 April 1998	Assoc. Prof. Dr. Nikola Atanasov	Ass.Prof. Dr. Nikolai Sharkov Prof. Dr. Elena Dulgerova	Prof. Dr. Dimitris Karakasis	Prof. Dr. Dimitris Iakovidis
4 <sup>th</sup>	Lutfi Kirdar Convention & Exhibition Center Istanbul, Turkey 22 – 25 March 1999	Prof. Dr. Nuri Yazicioglu	Prof. Dr. Nejat Arpak Prof. Dr. Hamit Bostanci	Prof. Dr. Dimitris Karakasis	Prof. Dr. Dimitris Iakovidis
5 <sup>th</sup>	Helexpo, "I. Vellidis" Congress Center Thessaloniki, Greece 13 – 16 April 2000	Prof. Dr. <u>Dimitris Iakovidis</u> (Dr. Georgios Tsiogas)	Dr. Georgios Tsiogas Prof. Dr. Ioannis Kayavis	Prof. Dr. Dragan Beloica	Prof. Dr. <u>Dimitris Iakovidis</u> (Prof. Dr. Dimitris Karakasis)
6 <sup>th</sup>	"Romexpo" International Fair Center Bucharest, Romania 3 – 6 May 2001	Prof. Dr. Andrei Iliescu	Dr. Alexandru Brezoescu Prof. Dr. Horia Traian Dumitru	Prof. Dr. Dragan Beloica	Prof. Dr. <u>Dimitris Iakovidis</u> (Prof. Dr. Dimitris Karakasis)
7 <sup>th</sup>	Pine-Bay Holiday Resort Hotel Kusadasi, Turkey 28 – 30 May 2002	Prof. Dr. Nejat Arpak	Prof. Dr. Murat Akkaya Prof. Dr. Hamit Bostanci	Prof. Dr. Nuri Yazicioglu	Prof. Dr. Dimitris Karakasis
8 <sup>th</sup>	Intercontinental Hotel Tirana, Albania 1 – 4 May 2003	Prof. Dr. Pavli Kongo	Dr. Besnik Gavazi Ass.Prof. Dr. Lindita Xhemnica	Prof. Dr. Nuri Yazicioglu	Prof. Dr. Dimitris Karakasis (Assoc. Prof. Dr. Petros Koidis)
9 <sup>th</sup>	Metropol Hotel Ohrid, FYROM 13 – 16 May 2004	Prof. Dr. Mile Carcev	Prof. Dr. Dragoljub Veleski Prof. Dr. Ana Minovska	Prof. Dr. Nikola Atanasov	Prof. Dr. Petros Koidis
10 <sup>th</sup>	Sava Center Belgrade, Yugoslavia 11 – 14 May 2005	Prof. Dr. Marko Vulovic	Prof. Dr. Dragan Beloica Prof. Dr. Dragoslav Stamenkovic	Prof. Dr. Nikola Atanasov	Prof. Dr. Petros Koidis
11 <sup>th</sup>	Holiday Inn Hotel Sarajevo, Bosnia-Herzegovina 11 – 14 May 2006	Prof. Dr. Halid Sulejmanagic	Prof. Dr. Sedin Kobaslija Prof. Dr. Olga Blagojevic	Prof. Dr. Andrei Iliescu	Assoc. Prof. Dr. Lambros Zouloumis
12 <sup>th</sup>	Grand Cevahir Hotel Istanbul, Turkey 12 – 14 April 2007	Prof. Dr. Hamit Bostanci	Prof. Dr. Nuri Yazicioglu Prof. Dr. Murat Akkaya	Prof. Dr. Andrei Iliescu	Assoc. Prof. Dr. Lambros Zouloumis
13 <sup>th</sup>	Hawaii Grand Hotel and Resort Limassol, Cyprus 1 – 4 May 2008	Dr. Irodotos Irodotou	Dr. Joseph Violaris Dr. Georgios Pandelas	Prof. Dr. Marko Vulovic (Prof. Dr. Petros Koidis)	Assoc. Prof. Dr. Lambros Zouloumis
14 <sup>th</sup>	Palace of Culture and Sports Varna, Bulgaria 6 – 9 May 2009	Ass.Prof. Dr. Nikolai Sharkov	Prof. Dr. Aneliya Klissarova Prof. Dr. Doan Ziya	Prof. Dr. <u>Marko Vulovic</u> (Prof. Dr. Petros Koidis)	Assoc. Prof. Dr. Lambros Zouloumis
15 <sup>th</sup>	Helexpo, "I. Vellidis" Congress Center Thessaloniki, Greece 22 – 25 April 2010	Prof. Dr. Theodoros Lambrianidis		Prof. Dr. Petros Koidis	Prof. Dr. Argirios Pissiotis
16 <sup>th</sup>	Grand Hotel Rin Bucharest, Romania 28-30 April 2011	Prof. Dr. Norina Consuela Forna	Prof. Dr. Andrei Iliescu Prof. Dr. Alexandru Bucur Prof. Dr. Adrian Streinu Cercel	Prof. Dr. Petros Koidis	Prof. Dr. Argirios Pissiotis
17 <sup>th</sup>	Hotel Tirana International Tirana, Albania 3-6 May 2012	Prof. Dr. Ruzhdie Qafmolla	Dr. Rozarka Budina Dr. Pavli Kongo Dr. Edit Xhajanka	Prof. Dr. Hamit Bostanci	Prof. Dr. Argirios Pissiotis
18 <sup>th</sup>	Hotel Alexandar Palace Skopje, FYROM 25-27 April 2013	Prof. Dr. Ana Minovska	Dr. Marijan Denkovski Dr. Ilijana Muratovska	Prof. Dr. Hamit Bostanci	Prof. Dr. Argirios Pissiotis
19 <sup>th</sup>	Sava Centar Belgrade, Serbia 24 - 27 April 2014	Prof. Dr. Dragoslav Stamenković	Obrad Zelić Dejan Marković	Ass. Prof. Dr. Nikolai Sharkov	Ass. Prof. Dr. Nikolaos Economides
20 <sup>th</sup>	International Hotel Bucharest, Romania 23-26 April 2015	Prof. Dr. Norina Consuela Forna		Ass. Prof. Dr. Nikolai Sharkov	Ass. Prof. Dr. Nikolaos Economides

## BUCHAREST, A VIVID CITY



Economically, Bucharest is the most prosperous city in Romania and is one of the main industrial centres and transportation hubs of Eastern Europe.

The city has a broad range of convention facilities, educational facilities, cultural venues, shopping arcades and recreational areas.

The capital of Romania is an attractive tourist destination which offers the opportunity to all of you to pay a visit to the numerous historical sites and enjoy the extraordinary Romanian scenery.



Known for its wide, tree-lined boulevards, glorious Belle Époque buildings and a reputation for the high life (which in the 1900s earned its nickname of "Little Paris"), Bucharest is today a bustling metropolis. Romanian legend has it that the city of Bucharest was founded on the banks of the Dambovită River by a shepherd named Bucur, whose name literally means "joy."

His flute playing reportedly dazzled the people and his hearty wine from nearby vineyards endeared him to the local traders, who gave his name to the place.

## BUCHAREST GENERAL INFORMATION:

<b>Location:</b>	Southern Romania
<b>Elevation:</b>	190 -295 ft (55 - 90 m)
<b>Size:</b>	City of Bucharest - 88 sq. miles (228 sq. km) Metropolitan area - 587 sq. miles (1,521 sq. km)
<b>Inhabited since:</b>	500 BC
<b>First documented:</b>	1459 AD
<b>Population:</b>	2.2 milion (2012)



## CONGRESS VENUE



## Hotel InterContinental Bucharest

*Enjoy the best of Bucharest  
in the middle of everywhere!*

**Meeting Rooms: 8**

**The biggest hall : 600 places**

**Exhibit Space Available: 1661 mp**

**Sales & Meeting Professionals On Site: 11**

The InterContinental Hotel stands tall in the heart of the city. As the hotel's story is deeply intertwined with that of the city, the Intercontinental is a true landmark of Bucharest. Besides exquisite elegance and style, the hotel's 22 floors offer absolutely amazing views of the lively city.

Whether you're looking for a great hotel, spectacular meeting rooms or just charming restaurants, the InterContinental is sure to exceed your every expectation.

Recently renovated meeting facilities and a newly renovated fitness center, comprising a heated indoor pool, a sauna and a beauty clinic, are all adding up touches of luxury not so easily found in this part of the world.



The hotel has a wide offer of rooms for all the tastes. Luxurious and spacious, suited for both business and leisure travelers, these wonderful rooms are outshone only by the amazing views they offer.



Besides this, the room amenities include: sitting and work area with desk, tea and coffee facilities, fully fitted bathroom, direct dual line speaker phone with voicemail, room safe, satellite and pay TV, high speed internet, air conditioning, hairdryer, minibar, iron and ironing board, free health club access.

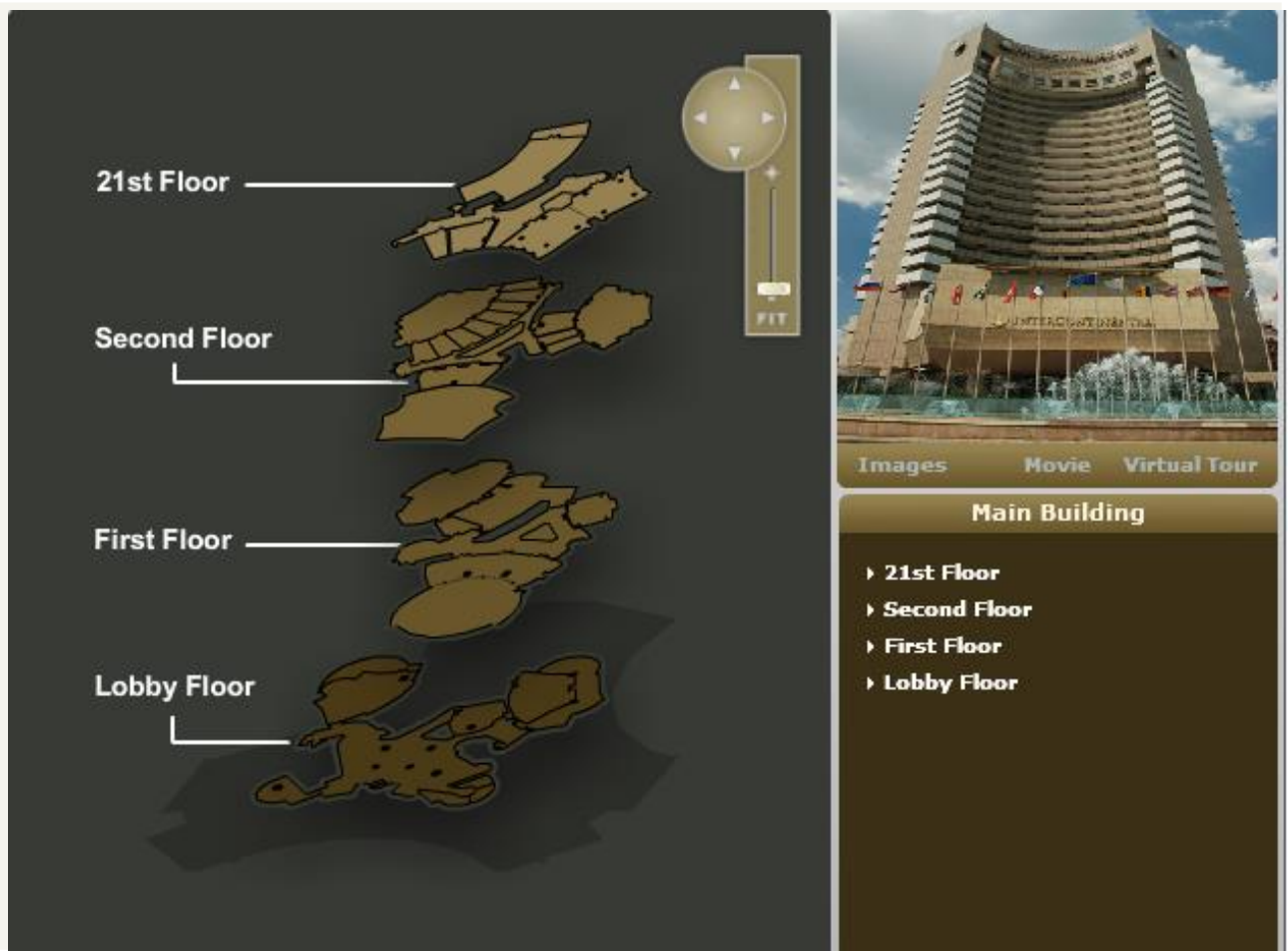
The multitude of halls, their modular structure and the latest equipment make the Conference Centre at Intercontinental Hotel the most important center of its kind in Bucharest and from all over the country. The conference center offers modern and complete

technical amenities, in an atmosphere favorable to business meetings and professional trainings as well as other specific activities.

It is certainly the best choice you can make when looking to organize a conference.

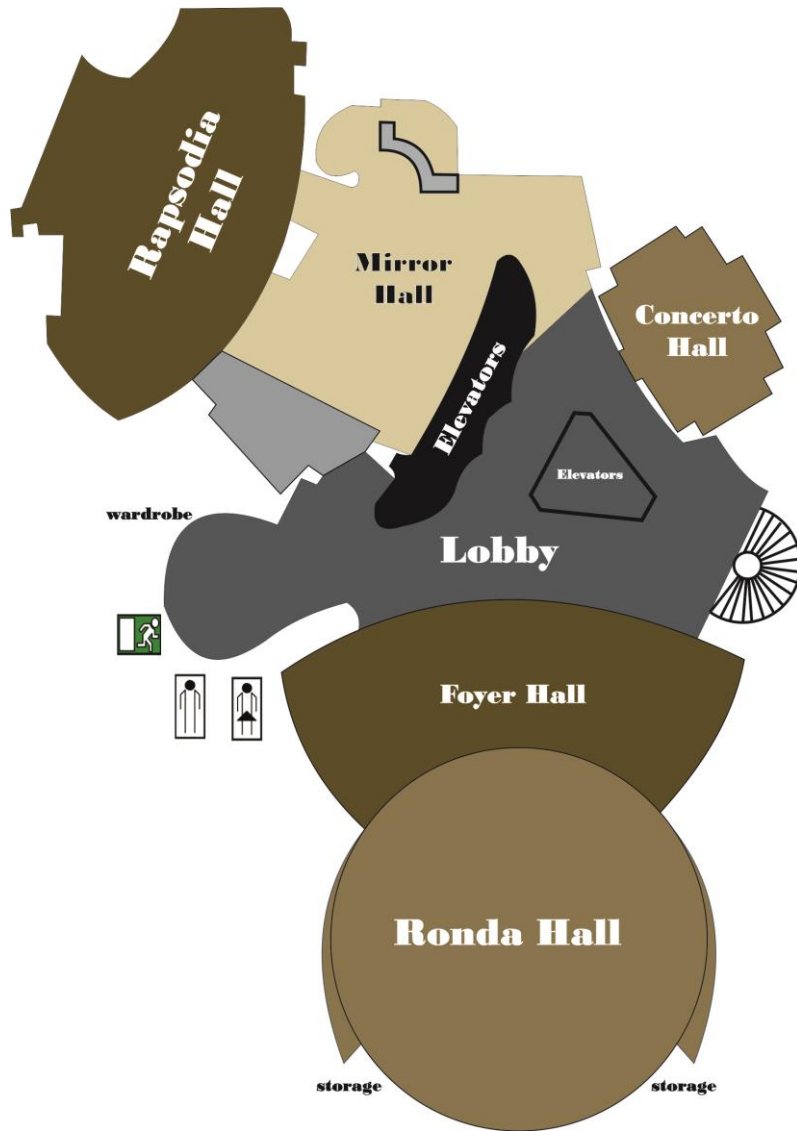


The Congress secretariat will be located in the lobby floor; the congress will take place at the 1<sup>st</sup> floor, Rhonda and Rapsodia Halls (conferences and oral presentations) and Bolero Hall (hands on and workshops). The poster presentation section will take place at the 21<sup>st</sup> floor, Fortuna Hall.

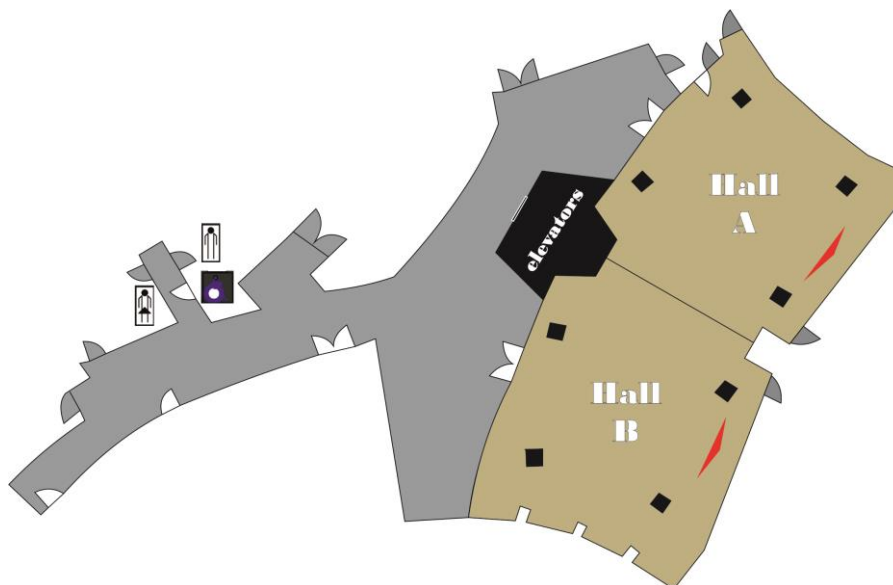




FIRST FLOOR



21<sup>st</sup> FLOOR



## SOCIAL PROGRAM AND EVENTS

### THURSDAY, April 23<sup>rd</sup>

- 17:00 – 18:00 OPENING CEREMONY  
(Rhonda Hall, Intercontinental Hotel)
- 20:00 WELCOME COCKTAIL  
(Rhonda Hall, Intercontinental Hotel)

### FRIDAY, April 24<sup>th</sup>

- 20:00 DINNER (“Jaristea” Restaurant)

### SATURDAY, April 25<sup>th</sup>

- 12:00 BaSS General Assembly  
(Rhonda Hall, Intercontinental Hotel)
- 19:00 Closing Ceremony and GALA DINNER  
(“La Trei Magari” Restaurant)

### TOURISTIC OPTIONS:

#### 1. Trip to the PRAHOVA VALLEY



#### **Bucharest - Sinaia - Bucharest**

- FEE: 39 EUR/ person/ for groups 27-36 persons
- Transport by bus
- Circuit description:
  - Peles Castle Visit (entrance ticket included)
  - Lunch at Snow Restaurant
  - Souvenir

#### 2. BUCHAREST city tour



#### **Bucharest - Sinaia - Bucharest**

- FEE: 37 EUR/ person/ for groups 27-36 persons
- Transport by bus
- Circuit description:
  - Palace of the Parliament visit
  - Lunch at “Caru cu Bere” Restaurant
  - Village Museum visit (entrance ticket included)
  - Souvenir

# SCIENTIFIC PROGRAM OVERVIEW

## PRECONGRESS

MONDAY, APRIL 20 <sup>th</sup> , 2015		TUESDAY, APRIL 21 <sup>st</sup> , 2015		WEDNESDAY, APRIL 22 <sup>nd</sup> , 2015	
<i>IAȘI, Clinical Base of Dental Education - A3 Amphitheater</i>		<i>IAȘI, Clinical Base of Dental Education</i>		<i>Bucharest, INTERCONTINENTAL HOTEL, CONCERTO HALL</i>	
08:30	LECTURE - IMPLANTOLOGY: PROBLEMS AND SOLUTIONS IN IMPLANT SURGERY ● Prof. Dr. NORINA FORNA - Romania ● Prof. Dr. STYLIANOS DALAMPIRAS - Greece	09:30	LECTURE – RESTORATIVE AND ADHESIVE DENTISTRY: THE CLINICAL AND THERAPEUTIC MANAGEMENT OF DENTAL EROSION ● Prof. Dr. SORIN ANDRIAN - Romania	10:00	PRESS CONFERENCE
11:30	8 EMC	11:30	A3 Amphitheater 8 EMC	12:00	
		09:00	WORKSHOP 18:00 „Aesthetic restoration in specific pathology of frontal teeth using wax-up technique” Speakers: MONICA TATARCIUC, SIMONA STOLERIU, IRINA NICA	17:00	ROMANIAN DEANS MEETING
		09:00	The XVth Edition of INTERNATIONAL SYMPOSIUM 12:30 “Romanian Medical Press”  Organizer: The Discipline of Modern Languages, Faculty of Dental Medicine “Grigore T. Popa” University of Medicine and Pharmacy Iasi Organizing Committee: ● Prof. Dr. MARIANA FLAISER - Romania ● Assoc. Prof. Dr. LAURA IOANA LEON - Romania	19:00	
			P7 Hall		

**THURSDAY, APRIL 23<sup>rd</sup>, 2015**  
*Bucharest, INTERCONTINENTAL HOTEL*

TIME	RHONDA Hall	RAPSODIA Hall	BOLERO Hall	FOYER RHONDA
09:00 18:00	<i>Receiving and registration of the participants</i>			
09:00 11:00	<p><b>Chairmen:</b> Prof. Dr. ANA MINOVSKA                      Prof. Dr. STYLIANOS DALAMPIRAS                      Prof. Dr. LJUBOMIR TODOROVICI</p> <p>Secretary: Assist. Prof. Dr. DORIANA AGOP FORNA</p> <p><b>ORAL IMPLANTOLOGY – Lecture:</b></p> <ul style="list-style-type: none"> <li>● <b>KADHIM AL HIMDANI:</b> - Bio Logic Implant Esthetic Concept</li> </ul> <p><b>Oral Presentations:</b></p> <ul style="list-style-type: none"> <li>● ORAL IMPLANTOLOGY (6 OP)</li> <li>● LASER (8 OP)</li> </ul>	<p><b>Chairmen:</b> Prof. Dr. ANDON FILCHEV                      Dr. DONKA STANCHEVA ZABUTOVA                      Prof. Dr. VERONICA MERCUT</p> <p>Secretary: Lect. Dr. DAN NICOLAE BOSANCEANU</p> <p><b>REMOVABLE PROSTHODONTICS – Lecture:</b></p> <ul style="list-style-type: none"> <li>● <b>MUHAMED AJANOVIC:</b> Management of deficient ridges: The case review</li> </ul> <p><b>Oral Presentations:</b></p> <ul style="list-style-type: none"> <li>● REMOVABLE PROSTHODONTICS (11 OP)</li> </ul>	<p><b>Chairmen:</b> Prof. Dr. MOMIR CAREVIC                      Dr. MIRJANA DJURICKOVIC                      Assoc. Prof. Dr. LUCIA BARLEAN</p> <p>Secretary: Lect. Dr. ALICE MURARIU</p> <p><b>ORAL PATHOLOGY (ORAL MEDICINE) – Lecture:</b></p> <ul style="list-style-type: none"> <li>● <b>DIANA UNCUTA:</b> - Treatment and Diagnosis Optimization in Herpetic Stomatitis</li> </ul> <p><b>Oral Presentations:</b></p> <ul style="list-style-type: none"> <li>● COMMUNITY DENTISTRY (3 OP)</li> <li>● PREVENTIVE DENTISTRY (6 OP)</li> <li>● ORAL PATHOLOGY (ORAL MEDICINE) (4 OP)</li> </ul>	
11:00 11:15	<b>Coffee Break</b>			
11:15 13:15	<p><b>Moderators:</b> Prof. Dr. ATTILA BERBEROGLU                      Prof. Dr. MEDA LAVINIA NEGRUTIU</p> <p><b>ORAL RADIOLOGY – Lectures:</b></p> <ul style="list-style-type: none"> <li>● <b>ATTILA BERBEROGLU:</b> Interpretation of periodontal and periapical lesions using cone beam computed tomography (CBCT)</li> <li>● <b>MEDA LAVINIA NEGRUTIU:</b> Application of the OCT Technology in Dentistry</li> <li>● <b>COSMIN SINESCU:</b> Application of the microcomputer tomography (micro CT) technology in dentistry</li> <li>● <b>KAAN ORHAN:</b> Radiographic appearances of systemic diseases in dento-maxillofacial area</li> </ul>	<p><b>Chairmen:</b> Prof. Dr. DRAGOSLAV STAMENKOVIC                      Prof. Dr. AURELIA CARAIANE                      Dr. MIHAEL STANOJEVIC</p> <p>Secretary: Lect. Dr. DIACONU DIANA</p> <p><b>FIXED PROSTHODONTICS - Lecture:</b></p> <ul style="list-style-type: none"> <li>● <b>GABRIELA IFTENI:</b> Clinical investigation of mandibular-cranial fundamental relationship</li> </ul> <p><b>Oral Presentations:</b></p> <ul style="list-style-type: none"> <li>● FIXED PROSTHODONTICS (10 OP)</li> </ul>	<p><b>HANDS-ON</b></p> <p><b>Minimally invasive dental treatments by using fiber-reinforced composite restoration: inlay, onlay and adhesive bridge (GC Romania)</b></p> <p>Prof. Dr. RADU SEPTIMIU CAMPAN / DT. WILLI ANDREI URICIUC</p>	<b>EXHIBITION OPENING</b>
13:15 15:00	<b>Lunch Break</b>			
15:00 16:45	<p><b>Moderators:</b> Prof. Dr. ECATERINA IONESCU                      Prof. Dr. ADY PALTU</p> <p><b>INTERDISCIPLINARITY IN DENTAL MEDICINE – I - Lectures:</b></p> <ul style="list-style-type: none"> <li>● <b>ECATERINA IONESCU / OANA EILINA MILICESCU TEODORESCU:</b> The Role of the First Permanent Molar in the Context of the Dynamics of the Dento-Maxillary System</li> <li>● <b>ALEXANDRU BUCUR:</b> Minimally Invasive versus Classic Procedures in Obstructive Salivary Gland Disease</li> <li>● <b>ADY PALTU:</b> Sinus floor elevations (techniques and complications)</li> <li>● <b>STEFAN OCTAVIAN GEORGESCU:</b> Iatrogen pathology</li> <li>● <b>CLAUDIO ALBI:</b> Application of the digital technologies in oral rehabilitation. Guided surgery, patient specific implants for bone reconstruction, guided corticotomy</li> </ul>	<p><b>Chairmen:</b> Prof. Dr. KIRO PAPAKOCA                      Assoc. Prof. Dr. DORJAN HYSI                      Prof. Dr. RADU SEPTIMIU CAMPAN</p> <p>Secretary: Assist. Prof. Dr. RAMONA FEIER</p> <p><b>Lecture:</b></p> <ul style="list-style-type: none"> <li>● <b>DORJAN HYSI:</b> Designing a research project, protocol writing</li> </ul> <p><b>Oral Presentations:</b></p> <ul style="list-style-type: none"> <li>● INTERDISCIPLINARY SECTION (12 OP)</li> </ul>	<p style="text-align: center;"><b>SEMINAR (1)</b></p> <p style="text-align: center;"><b>Full zirconia crown for implant prosthesis</b>                      Prof. Dr. CHEOL WOONG JEONG  <b>KUWOTECH Co., Ltd.South Korea</b></p> <p style="text-align: center;"><b>Break – 15:45 – 16:00</b></p> <p style="text-align: center;"><b>SEMINAR (2)</b></p> <p style="text-align: center;"><b>Full zirconia crown for implant prosthesis</b>                      Prof. Dr. CHEOL WOONG JEONG  <b>KUWOTECH Co., Ltd.South Korea</b></p>	<b>EXHIBITION</b>

16:45 17:00	Coffee Break			
17:00 18:00	OPENING CEREMONY, RHONDA Hall		<b>HANDS-ON</b> <b>Application of the digital technologies in oral rehabilitation. Guided surgery, patient specific implants for bone reconstruction, guided corticotomy</b> CLAUDIO ALBI / PIETRO ALBI <b>MODUS</b>	EXHIBITION
18:00 20:00				
20:00	WELCOME COCKTAIL, RHONDA Hall			

**FRIDAY, APRIL 24<sup>th</sup>, 2015**  
*Bucharest, INTERCONTINENTAL HOTEL*

TIME	RHONDA Hall	RAPSDODIA Hall	BOLERO Hall	FORTUNA Hall		FOYER RHONDA
				A	B	
09:00 18:00	<i>Receiving and registration of the participants</i>					
09:00 11:00	<b>Moderators: Prof. Dr. PETROS KOIDIS</b> <b>Prof. Dr. ARGIRIOS PISSIOTIS</b> <b>Prof. Dr. NORINA FORNA</b>	<b>Chairmen: Prof. Dr. KAAAN ORHAN</b> <b>Dr. NIKOS MAROUFIDIS</b> <b>Prof. Dr. CRISTINA MARIA BORTUN</b> Secretary: Assist. Prof. Dr. ANA MARIA FILIOREANU	<b>HANDS-ON</b>  <b>Cardio-pulmonary resuscitation (CPR) in dental practice (1)</b> Assist. Dr. FLORIN ROSU	<b>Chairmen:</b> <b>Prof. Dr. HAMIT BOSTANCI</b> <b>Prof. Dr. MURAT AKKAYA</b> Secretary: Assist. Prof. Dr. ALEXANDRA MARTU	<b>Chairmen:</b> <b>Dr. NEJAT ARPAK</b> <b>Assoc. Prof. Dr. VALERIU FALA</b> Secretary: Lect. Dr. SIMONA STOLERIU	EXHIBITION
	<b>IMPLANTOLOGY, REMOVABLE PROSTHODONTICS – Lectures:</b> <ul style="list-style-type: none"> <li>● <b>PETROS KOIDIS:</b> Dental Rehabilitation: On the Crossroads of Conventional and Regenerative Approaches</li> <li>● <b>ARGIRIOS PISSIOTIS:</b> Occlusal schemes for complete denture prostheses</li> <li>● <b>STYLIANOS DALAMPIRAS:</b> Meticulous preparation is the most important factor in implant surgery</li> <li>● <b>NORINA FORNA:</b> Modern planning of implant-prosthetic rehabilitation</li> <li>● <b>KWIDUG YUN:</b> Introduction of implant supported overdenture</li> </ul>	<b>Lectures:</b> <ul style="list-style-type: none"> <li>● <b>IULIAN ANTONIAC:</b> New trends in dental biomaterials</li> <li>● <b>ANTIGONE DELANTONI:</b> Radiographic evaluation of the temporomandibular joint pathology. Indications and guidelines</li> </ul> <b>Oral Presentations:</b> <ul style="list-style-type: none"> <li>● ORAL DIAGNOSIS – ORAL RADIOLOGY (9 OP)</li> <li>● NEW TECHNOLOGIES (1 OP)</li> <li>● DENTAL BIOMATERIALS AND DEVICES (3 OP)</li> </ul>		<b>Poster Session 1:</b>  PERIODONTOLOGY	<b>Poster Session 2:</b>  RESTORATIVE AND ADHESIVE DENTISTRY	
11:00 11:15	<b>Coffee Break</b>					
11:15 13:15	<b>Moderators: Prof. Dr. CHEOL WOONG JEONG</b> <b>Prof. Dr. SANDA MIHAELA POPESCU</b>	<b>ROUND TABLE – ORAL IMPLANTOLOGY</b> <b>Coordinator: Prof. Dr. NORINA FORNA</b> <b>Moderator: Prof. Dr. ANASTASIOS MARKOPOULOS</b>	<b>HANDS-ON</b>  <b>Cardio-pulmonary resuscitation (CPR) in dental practice (2)</b> Assist. Dr. FLORIN ROSU	<b>Chairmen:</b> <b>Prof. Dr. NICOLAOS ECONOMIDES</b> <b>Prof. Dr. ANDREI ILIESCU</b> <b>Dr. DJENAD GANJOLA</b> Secretary: Lect. Dr. LIANA AMINOV	<b>Chairmen:</b> <b>Prof. Dr. STYLIANOS DALAMPIRAS</b> <b>Prof. Dr. LILIANA FOIA</b> <b>Dr. SAMI SOLYALI</b> Secretary: Assist. Prof. Dr. ANA MARIA FILIOREANU	EXHIBITION
	<b>PERIODONTOLOGY, COMMUNITY DENTISTRY – Lectures:</b> <ul style="list-style-type: none"> <li>● <b>THEODORA NIKOLAIEVA BOLYAROVA KONOVA:</b> Relationship between periodontal and cardiovascular diseases</li> <li>● <b>SANDA MIHAELA POPESCU:</b> Oral health status and treatments needs among schoolchildren from Craiova, Romania</li> <li>● <b>KATARINA RADOVIC:</b> Vascular endothelial growth factor and oral homeostasis in diabetes mellitus type 2 immediate denture wearers</li> </ul>	<ul style="list-style-type: none"> <li>● <b>Acad. C.I. TARGOVISTE:</b> - Immunity - fundamental function of the body's defense</li> <li>● <b>ANASTASIOS MARKOPOULOS:</b> - Systemic diseases and treatments as risk factors for dental implant rehabilitation</li> <li>- Oral manifestations of metabolic bone diseases</li> </ul>		<b>Poster Session 3:</b> ● ENDODONTOLOGY	<b>Poster Session 4:</b> ● ORAL PATHOLOGY (ORAL	

	<p><b>The New Approach in Caries Prevention and Management</b>          Assist. Prof. Dr. CRISTIAN FUNIERU          Supported by Colgate-Palmolive Romania (12:50-13:20)</p>	<ul style="list-style-type: none"> <li>● <b>KADHIM AL HIMDANI:</b> - Short implant - 5 years retrospective study</li> <li>● <b>CATALINA ARSENESCU:</b> - Anterior chest pain – a multidisciplinary determination</li> </ul>		<ul style="list-style-type: none"> <li>● LASER</li> </ul>	<p>MEDICINE)  <ul style="list-style-type: none"> <li>● ORAL SURGERY AND OMF SURGERY</li> </ul> </p>	
13:15 15:00	<b>Lunch Break</b>					
<b>TIME</b>	<b>RHONDA Hall</b>	<b>RAPSODIA Hall</b>	<b>BOLERO Hall</b>	<b>FORTUNA Hall</b>		<b>FOYER RHONDA</b>
	<p>Moderators: Prof. Dr. KOSOVA OBRADOVIC DJURCIC          Assoc. Prof. Dr. LILIANA POROJAN</p>	<p>Chairmen: Assoc. Prof. Dr. THEODORA BOLYAROVA          KONOVA          Lect. Dr. CARMEN MANCIUC          Secretary: Lect. Dr. SORINA SOLOMON</p>		<p>Chairmen:          Prof. Dr. SANDA MIHAELA          POPESCU          Prof. Dr. MONICA          TATARCIUC          Assoc. Prof. Dr. VALENTINA          TRIFAN          Dr. ALEXANDRU BREZOESCU          Secretary:          Lecturer Dr. MIHAELA          MONICA SCUTARIU</p>	<p>Chairmen:          Prof. Dr. VERONICA MERCUT          Assoc. Prof. Dr. ALKETA          QAFMOLLA          Dr. CLAUDIO ALBI          Dr. LUCA ARDUINI          Secretary:          Lecturer Dr. MARINA CRISTINA          IORDACHE</p>	<b>EXHIBITION</b>
15:00 17:00	<p><b>PROSTHETICS, NEW TECHNOLOGIES – Lectures:</b></p> <ul style="list-style-type: none"> <li>● <b>KOSOVA OBRADOVIC DJURCIC:</b> How to make the prosthetic reconstruction predicable - aesthetic protocols</li> <li>● <b>CHEOL WOONG JEONG:</b> Long-term clinical results of regenerative therapy in peri-implantitis</li> <li>● <b>LILIANA POROJAN:</b> Digital design, implementation and evaluation of prosthetic single tooth restorations</li> <li>● <b>LUCA ARDUINI:</b> Re: Evolution in dental surgery. New bone compacting techniques: from Summers to new technologies</li> </ul>	<p><b>INTERDISCIPLINARY SECTION – Lecture:</b></p> <ul style="list-style-type: none"> <li>● <b>MARIN BURLEA:</b> Implications of oral transmission of Helicobacter pylori infection</li> <li>● <b>MARIANA PĂCURAR:</b> Dento-periodontal changes in orthodontic treated adult patients</li> </ul> <p><b>Oral Presentations:</b></p> <ul style="list-style-type: none"> <li>● PERIODONTOLOGY (14 OP)</li> </ul>	<b>1<sup>st</sup> BaSS COUNCIL MEETING</b>	<p><b>Poster Session 5:</b></p> <ul style="list-style-type: none"> <li>● REMOVABLE PROSTHODONTICS</li> <li>● GERODONTOLOGY</li> <li>● ORAL DIAGNOSIS</li> <li>● ORAL RADIOLOGY</li> </ul>	<p><b>Poster Session 6:</b></p> <ul style="list-style-type: none"> <li>● FIXED PROSTHODONTICS</li> <li>● ORAL IMPLANTOLOGY</li> <li>● NEW TECHNOLOGIES</li> </ul>	
17:00 17:15	<b>Coffee Break</b>					
	<p>Moderators: Prof. Dr. HANA HUBALKOVA          Prof. Dr. GEORGIOS PANTELAS</p>	<p>Chairmen: Prof. Dr. ROZARKA BUDINA          Dr. JULIO POPOVSKI          Assoc. Prof. Dr. GIANINA IOVAN          Secretary: Lect. Dr. SIMONA STOLERIU</p>		<p>Chairmen:          Prof. Dr. MAIDA          GANIBEGOVIC          Assoc. Prof. Dr. ADRIANA          BALAN          Secretary:          Assoc. Prof. Dr. VASILICA          TOMA</p>	<p>Chairmen:          Prof. Dr. NICOLAI SHARKOV          Prof. Dr. OLEG SOLOMON          Secretary:          Assist. Prof. Dr. CARINA          BALCOS</p>	<b>EXHIBITION</b>
17:15 19:15	<p><b>ORAL MAXILLOFACIAL SURGERY, BIOMATERIALS – Lectures:</b></p> <ul style="list-style-type: none"> <li>● <b>HANA HUBALKOVA:</b> Functional and aesthetical reconstruction of large maxillofacial defects</li> <li>● <b>GEORGIOS PANTELAS:</b> Diagnostic approach of parotid lump</li> <li>● <b>TOMIC SLAVOLJUB:</b> AMSA (Anterior and Middle Superior Alveolar) Injection is Efficient for Maxillary Teeth Extraction</li> <li>● <b>HORIA OCTAVIAN MANOLEA:</b> Evaluation methods of bone graft materials</li> </ul>	<p><b>Oral Presentations:</b></p> <ul style="list-style-type: none"> <li>● RESTORATIVE AND ADHESIVE DENTISTRY (15 OP)</li> </ul>	<p><b>HANDS-ON</b></p> <p>Re: Evolution in dental surgery. New bone compacting techniques: from Summers to new technologies          LUCA ARDUINI          MAGNETIC MALLETT</p>	<p><b>Poster Session 7:</b></p> <ul style="list-style-type: none"> <li>● PAEDIATRIC DENTISTRY</li> <li>● PREVENTIVE DENTISTRY</li> </ul>	<p><b>Poster Session 8:</b></p> <ul style="list-style-type: none"> <li>● ORTHODONTICS</li> <li>● COMMUNITY DENTISTRY</li> </ul>	
20:00	<b>Social Program – Rest. JARISTEA, by coach 15 min.</b>					

SATURDAY, APRIL 25<sup>th</sup>, 2015  
Bucharest, INTERCONTINENTAL HOTEL

TME	RHONDA Hall	RAPSODIA Hall	BOLERO Hall	FOYER RHONDA
09:00 11:00	Moderators: Assoc. Prof. Dr. NATASA TOESKA SPASOVA Prof. Dr. CHANG HEUN PARK	Chairmen: Assoc. Prof. Dr. LUMINITA MARIA NICA Assoc. Prof. Dr. ELKA NIKOLAEVA RADEVA Secretary: Lect. Dr. MIHAELA SALCEANU	BaSS AWARD Committee Meeting 6 OP / 9:00-10:00  2 <sup>nd</sup> BaSS COUNCIL MEETING / 10:00-12:00	
	<b>ORTHODONTICS, PEDODONTICS, COMMUNITARY STOMATOLOGY – Lectures:</b> ● CHANG HEUN PARK: Asymmetries: Diagnosis and treatment ● NATASA TOESKA SPASOVA: Oral habits and its management in orthodontics ● ILIJANA MURATOVSKA: Possible causes of dental restoration failures and current solutions ● ZORAN VLAHOVIC: CBCT in dentistry – a true need or a whim?	<b>Lectures – ENDODONTOLOGY :</b> ● IOAN DANILA: Retrospectives in oro-dental prevention of diseases in Romania ● ELKA NIKOLAEVA RADEVA: Problem solving in non-surgical endodontic retreatment ● CHARIS BELTES: Endodontic surgery. Diagnosis and therapy using cone-beam CT and operating microscope ● LUMINITA MARIA NICA : Clinical applications of bonding to root canal dentin <b>Oral Presentations:</b> ● ENDODONTOLOGY (9 OP)		
11:00 11:15	Coffee Break			
11:15 12:00	Moderators: Dr. ZORAN VLAHOVIC Prof. Dr. ANDREI KOZMA	Chairmen: Prof. Dr. ALEXANDRU BUCUR Assoc. Prof. Dr. TOMIC SLAVOLJUB Prof. Dr. ION LUPAN Secretary: Lect. Dr. VICTOR VLAD COSTAN	2 <sup>nd</sup> BaSS COUNCIL MEETING / 10:00-12:00	
	<b>INTERDISCIPLINARITY IN DENTAL MEDICINE - II – Lectures:</b> ● Acad. CONSTANTIN BALACEANU STOLNICI: Reflections about consciousness ● GRIGORE TINICA: Liver failure as risk factor in cardiac surgery ● ALKETA QAFMOLLA: Traumatic occlusion and its treatment (clinical and experimental study) ● TRAIAN MIHAESCU: Subject reserved ● ANDREI KOZMA: Dental inclusion-study of a particular aspect of the permanent teeth eruption	<b>Oral Presentations:</b> ● ORAL SURGERY AND OMF SURGERY (16 OP)		
12:00 13:00	BaSS GENERAL ASSEMBLY			
13:00 15:00	Lunch Break		Lunch Break	
15:00 17:00		SEMINAR (Ro): ACCESARE FONDURI EUROPENE PENTRU DOTARE CABINET – Medicina Dentara Banca Transilvania – divizia pt medici & Ministerul Fondurilor Europene  Chairmen: Prof. Dr. SELMA ZUKIC Prof. Dr. MARIANA PACURAR Assoc. Prof. Dr. OANA EILINA TEODORESCU-MILICESCU Secretary: Lect. Dr. CARMEN SAVIN	DEANS MEETING – BaSS	

		<b>Lectures – ORTHODONTICS:</b> <ul style="list-style-type: none"> <li>● <b>SELMA ZUKIC:</b> Dental anomalies: clinical implications and treatment challenges</li> <li>● <b>IRINA ZETU:</b> The interdisciplinary approach in orthodontics</li> </ul> <b>Oral Presentations:</b> <ul style="list-style-type: none"> <li>● ORTHODONTICS (12 OP)</li> </ul>	
17:00 17:15	<b>Coffee Break</b>		
17:15 19:00		<b>Chairmen: Prof. Dr. NICOLAI SHARKOV</b> <b>Prof. Dr. RODICA LUCA</b> Secretary: Lect. Dr. ANA PETCU <b>Lectures – PAEDIATRIC DENTISTRY:</b> <ul style="list-style-type: none"> <li>● <b>AURELIA SPINEI:</b> Oral health status of children with developmental disabilities in the Republic of Moldova</li> </ul> <b>Oral Presentations:</b> <ul style="list-style-type: none"> <li>● ORTHODONTICS (4 OP)</li> <li>● PAEDIATRIC DENTISTRY (9 OP)</li> </ul>	<b>Chairmen: Lect. Dr. IRINA GRADINARU</b> <b>Lect. Dr. LOREDANA HURJUI</b> Secretary: Assist. Prof. Dr. CLAUDIA FLORIDA COSTEA  <b>Poster Session 9:</b> <ul style="list-style-type: none"> <li>● INTERDISCIPLINARY SECTION</li> <li>● HOSPITAL DENTISTRY</li> <li>● DENTAL BIOMATERIAL AND DEVICES</li> </ul>
19:00 19:30	<b>CLOSING CEREMONY</b>		
20:00	<b>GALA DINNER</b> Restaurant “LA TREI MAGARI”, by coach 30 min		

**SUNDAY, APRIL 26<sup>th</sup>, 2015**  
*Bucharest, INTERCONTINENTAL HOTEL*

TIME	RAPSODIA Hall
9:00- 11:00	<b>Chairmen: Prof. Dr. GABRIELA BANCESCU</b> <b>Prof. Dr. MARIN BURLEA</b> Secretary: Lect. Dr. VASILE VALERIU LUPU  <b>Lectures – INTERDISCIPLINARY SECTION:</b> <ul style="list-style-type: none"> <li>● <b>MARIN BURLEA:</b> Endoscopic treatments in digestive hemorrhage in children</li> <li>● <b>GABRIELA BANCESCU:</b> The streptococci of anginosus group and their role in oral and extraoral pathology</li> <li>● <b>SMARANDA DIACONESCU:</b> Infectious endocarditis prophylaxis in dental and endoscopic procedures in children: a pediatrician's point of view</li> <li>● <b>VASILE VALERIU LUPU:</b> Oral manifestations in gastroesophageal reflux disease in children</li> </ul> <b>Oral Presentations:</b> <ul style="list-style-type: none"> <li>● INTERDISCIPLINARY SECTION (2 OP)</li> </ul>



## INVITED SPEAKERS BaSS

ALBANIA



**Assoc. Professor**  
**ALKETA QAFMOLLA**  
DMD MSc PhD  
*UMPh Tirana*



Alketa Qafmolla was graduated in 2005 in Dentistry, Medical Faculty, Tirana University. She finished her Master degree in 2008 and completed her PhD studies in September 2012. Alketa has actively participated in different national and international professional conferences and workshops. She is first author also co-author in several scientific works and books published. She is a professor in Faculty of Dental Medicine Tirane since 2 years.

ALBANIA



**Assoc. Professor**  
**DORJAN HYSI**  
DMD MSc PhD  
*UMPh Tirana*



Assoc. Prof. Dorjan Hysi is the president of the Albanian Dental Association, He was the director of University Dental Clinic, Tirana, Albania during 2012-2014. He is full time academic staff at University of Medicine of Tirana, Faculty of Dental Medicine. He performed undergraduate studies in dentistry, Master of Science in dentistry and PhD at University of Tirana. Also he followed graduate studies for Dental Public Health as a Fulbright Student at the University of Texas Health Science Center, Dental Branch at Houston. His professional experience was as the Dental Officer of the Ministry of Health of Albania and invited Lecturer at other Dental Schools inside and outside the Country. He has actively contributed in several projects and professional documents prepared by the Ministry of Health. Further he is involved in several epidemiological research and projects and parts of his work has been presented in several lectures and scientific presentations in national and international dental events Also he is author and co- author in papers published nationally and internationally cited literature and also serves as a peer reviewers for some journals and professional organizations. He is member of several international professional associations such as EADPH, FDI, CECDO, BASS etc.



**Professor**  
**MUHAMED AJANOVIC**

DMD MSc PhD

*University of Sarajevo, School of Dental Medicine*



Muhamed Ajanovic is a Vicedean for education, visiting clinical associate professor and chief of Prosthodontic Clinic at School of Dental Medicine, University of Sarajevo, Bosnia and Herzegovina and also an instructor in the field of dental implantology in IFZI, Nurnberg, Germany. From May 2008 to May 2009 he has worked at New York University, Department of Oral & Maxillofacial Pathology, Radiology and Medicine as a visiting assistant professor. He had completed undergraduate studies in 2001 and received diploma with honors for outstanding achievements in the course of studies at School of Dental Medicine, University of Sarajevo. He completed 36-month specialization in prosthodontics in 2005. He obtained his MSc degree in 2006 with topic "Role of Posttraumatic Stress Disorder in Origins of Temporomandibular Dysfunction". In 2006 he earned Bachelor of Science degree in Global Security and Intelligence Studies, Doctor of Dental Medicine degree. He was awarded PhD in Dental Science in 2008 with the dissertation "Relation of Occlusal Interferences, Signs and Symptoms of Temporomandibular Dysfunctions". In 2013 he completed certificate program in dental and oral implantology, including course work and supervised instruction in Germany and clinical work in Sarajevo. He has published more than 50 original scientific works and two books in field of dentistry.



**Assoc. Professor**  
**TOMIĆ SLAVOLJUB**

DMD MSc PhD

*University of East Sarajevo, Faculty of Medicine Foca*



Assist. Professor Tomić Slavoljub obtained his PhD thesis in 2012, with the subject "The effect of adrenaline in the local anesthetic solution on the characteristics of complementary anesthesia of the front and middle upper alveolar nerve accessed from a palatal side". Since 2008 he is Specialist in oral surgery and in 2007 he obtained the MSc-master of science title, with the thesis "Topography and radiographic localization of foramen mentale and canalis mentale"; since 2004 he is doctor of dentistry. He followed overspecialization courses about Phenix implant system (Hungary, 2013 and Luxembourg, 2013). He is author of more than 25 *in extenso* articles, published in international journals and he has a scientific project in developing, "Evaluation of retention to the cone crowns with homologous or heterologous pairs".

BOSNIA-  
HERZEGOVINA



**Professor  
SELMA ZUKIĆ**

DMD MSc PhD

*University of East Sarajevo, Faculty of Medicine Foca*



Professor Selma Zukić is specialist of dental pathology and endodontics, employed at Faculty of Dentistry, University of Sarajevo, Bosnia and Herzegovina. Currently work at Department of Preclinical dentistry, teaching dental morphology, anthropology and forensics. She is one of the founders and current President of Section of Dental Forensics at Dental Association of Federation of Bosnia and Herzegovina. She participated as invited lecturer at „International Course on Mass Graves Victims Identification in Former Yugoslavia“ held in 2007. She actively participated at several scientific and experts meetings and congresses in the field of dental morphology, anthropology and forensics. She was member of organizational boards of 4 dental congresses. Dr. Zukić is General Secretary of scientific journal „Stomatološki vijesnik“ and member of several dental associations, including IAPO. She is author and co-author of 42 scientific and professional papers.

BULGARIA



**Assoc. Professor  
ELKA NIKOLAEVA RADEVA**

DMD PhD

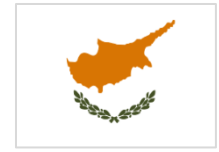*UMPh Sofia*



Dr. Elka Radeva received her DMD degree from the Medical University of Sofia, Bulgaria in 1993. She is an assistant professor in the Department of Conservative dentistry, Faculty of Dental medicine-Sofia, Bulgaria since 1993. Since then, she has been teaching students in preclinical and clinical courses in endodontics and operative dentistry. She has concluded her PhD studies in 2012 on thesis related to Acute apical periodontitis. Her research interests include the endodontic microbiology, acute and chronic apical periodontitis and endodontic surgery. Dr. Radeva has authored several articles in endodontics and operative dentistry and they are published in peer-reviewed journals. Dr. Radeva is a co-author of books on pharmacology for medicine and dental medicine students. Dr. Elka Radeva is an accredited lecturer of the Bulgarian Dental Association. She gives lectures and manages practical courses in endodontics for postgraduate education in Bulgaria. Since 2002, she has been the scientific secretary of the Journal of Dental Medicine – an edition of the Bulgarian Scientific Dental Association. She is a member of the Bulgarian Dental Association, Bulgarian Scientific Dental Association and the Bulgarian Endodontic Society.



**Professor**  
**ATILLA BERBEROĞLU**  
DMD PhD  
*Near East University of North Cyprus*



Professor Atilla Berberoğlu graduated in 1977 the Istanbul University, Faculty of Dentistry; in 1985 he obtained his Ph.D on Periodontology, at Hacettepe University. Between 1977-1982 he worked in private practice. His main area of specialization is Periodontology; between 1982-1985 he was Assistant professor, at Hacettepe University, Faculty of Dentistry, Department of Periodontology; between 1985 - 1988 he was Lecturer professor at the same university, faculty and department; between 1984 - 1985 he was Rotational assistant professor at Hacettepe University, Faculty of Medicine, Department of Pathology. Between 1992 - 1993 he worked as Periodontist at Kuwait Amiri Dental Center Dep. of Periodontology and between 1993 - 1994 he worked as Organizer periodontist at Kuwait Farwania Dental Center Dep. of Periodontology. In 1988 he became Associate professor and professor at Hacettepe University, Faculty of Dentistry, Department of Periodontology and since 2008 he is Chairmen at Near East University of North Cyprus, Faculty of Dentistry, Department of Periodontology.

He is member in many professional and scientific societies, as it follows:

- Turkish Dental Association, Education Commission secretary (1997 - 1998)
- Ankara branch of the Turkish Society of Periodontology, Board member and president (1999 - 2009)
- Turkish Society of Periodontology, Administrative Board membership (2008 - 2010)
- Hacettepe University, Faculty of Dentistry, Journal Editorial Board Membership (2003 - 2009)
- Vice President of the Turkish Cypriot Chamber of Dentists (2012 - present)
- Board member of the Near East University, Faculty of Dentistry (2008 - present)
- International Academy of Periodontology
- European Federation of Periodontology
- Anatolian sailing club, sailor and radio operator (1998 - present)



**Assoc. Professor**  
**GEORGIOS PANTELAS**  
DMD PhD  
*European University Cyprus*



He graduated from the Dental School, Aristotle University of Thessaloniki (AUTH), Medical School AUTH, specialty of oral and maxillofacial surgery at the University Hospital of Thessaloniki Papanikolaou, PhD in cognitive object of oral maxillofacial surgery at AUTH. In 1994 he started work as a head of the new clinic of Oral Maxillofacial Surgery at the Nicosia General Hospital which he serves today as Director of the clinic. He has rich clinical and surgical experience

across the spectrum of specialty with main object oncology, traumatology, and especially in surgery of tumors of salivary glands.

He is a board member of Dental Council of Cyprus, member of the Board of European Union Of Medical Specialists (UEMS), Section Of Oro-Maxillo-Facial Surgery, board member of European Association for Cranio maxillo facial Surgery (EACMFS) and board member Balkan Stomatological Society BaSS. He was chairman – member of organizing committee of many local and international scientific conferences and instructor in training seminars of nursing school, ambulance crews. He has presented papers and he gave lectures to over 150 local and international conferences and has published in Greek and international journals. He published a book. He teaches in the study program of Cyprus College. In 2013 he was elected Associate Professor of Oral and Maxillofacial Surgery at the Medical School of the European University Cyprus.



**Assistant Research Professor**  
**NATASA TOESKA-SPASOVA**  
DMD MSc PhD  
*UMPh Skopje*



Ms Natasa Toseska-Spasova was born in 1970, in Skopje, Macedonia; in 1993 she graduated at the Faculty of Stomatology, Skopje – MD; in 1993 she became specialist in Orthodontics, in 2001 she obtained the title of Mr.sci in Orthodontics and in 2009 she obtained the title of Ph.D in Orthodontics. Since 1997 Ms Toseska-Spasova is Assistant at Faculty of Stomatology, and since 2014 she is Assistant Research Professor at Faculty of Stomatology, Skopje, Macedonia. In 2012 she wrote the book “Orthodontic Morphological Analysis and Diagnostic”. Her main fields of interests concern the morphological characteristics of irregularity - crowding of the dental arches, its influence on craniofacial morphology and the treatment of orthodontics malocclusion.



**Associated Professor**  
**ILIJANA MURATOVSKA**  
DMD MSc PhD  
*UMPh Skopje*



Ms Ilijana Muratovska was born in 1969, in Skopje, Macedonia; in 1992 she graduated at Faculty of Dentistry, Skopje – MD; in 1998 she became specialist in Restorative dentistry and endodontics; in 2004 she obtained the title of Mr.sci in Restorative dentistry and endodontics and in 2010 she obtained the title of Ph.D in Restorative dentistry and endodontics. Since 1996 Ms Ilijana Muratovska is Assistant Professor at Faculty of Dentistry; in 2000 she followed a Tempus-PHARE scholarship in education at ACTA, Amsterdam, Netherlands; in 2008 she followed a professional training in Laser dentistry with Prof. PhD A. Moritz, Vienna, Austria. In 2010 she became Chief of

Department for Restorative dentistry and endodontics and since 2013 she became Associated professor and Vice-dean for international cooperation at the Faculty for Dental Medicine, Skopje. She is also Vice-cancelor in BaSS and Erasmus coordinator for the Faculty of Dentistry. Her main fields of interests concern the dentin permeability for dental restorative materials, dental adhesives and their characteristics, root canal filing techniques, root canal irrigants, smear layer.



**Professor**  
**PETROS KOIDIS**  
DMD MSc PhD  
*Aristotle University of Thessaloniki*



Petros Koidis was born in Kozani, Greece 1957. He is Professor and Chairman of the Department of Fixed Prosthesis and Implant Prosthodontics at the School of Dentistry in the Aristotle University of Thessaloniki (AUTH), in Greece. He is a graduate of AUTH, where he conducted his PhD on Temporomandibular Disorders. He obtained the degree of Master of Science at The Ohio State University (Columbus, USA), where he was also trained and certified in Advanced Fixed and Removable Prosthodontics. He has been Visiting Assistant Professor at Harvard School of Dental Medicine, Harvard University, Boston, USA (1997), Visiting Professor at the School of Dentistry, University of Belgrade, Serbia (since 2007), Adjunct Professor, "Gr. T. Popa" Medicine and Pharmacy University, Faculty of Dental Medicine at Iasi, Romania (since 2009) and Adjunct Senior Scientist in Houston Center for Biomaterials and Biomimetics of The University of Texas School of Dentistry at Houston, USA (since 2011). His research interests include the links of prosthetic rehabilitation, biomaterials, temporomandibular disorders and tissue engineering. He has been project leader and senior scientist in several funded research and operational projects. He is internationally renowned for his scientific work, reviewer in more than 30 international journals, having published over than 150 articles and having presented them in over than 200 meetings and conferences, for which he is the recipient of several awards and honors.



**Professor**  
**ANASTASIOS K. MARKOPOULOS**  
DMD MSc PhD  
*Aristotle University of Thessaloniki*



Dr. Anastasios K. Markopoulos is Professor (ret) and former Chairman & Program Director of the Department of Oral Medicine/Pathology, Section of Oral & Maxillofacial Surgery & Pathology, Faculty of Dentistry, School of Health Sciences, Aristotle University, Thessaloniki, Greece. He received his DMD degree from the School of Dentistry, Aristotle University in 1977. He

obtained his PhD degree from the same University in 1986. He also received a Master of Science degree in Oral Biology from the School of Dentistry, University of California, Los Angeles in 1991. Dr. Anastasios Markopoulos is president of the Hellenic Society of Oral Medicine and Pathology. He is councilor of Balkan Stomatological Society. He is also editor of the Hellenic committee of Balkan Journal of Stomatology. He is member of the editorial board of four International Journals. He is reviewer of several international medical and dental journals. He is an active member of American Academy of Oral and Maxillofacial Pathology and member of International Association of Oral Pathology. Dr. Markopoulos has published more than 140 articles related to Oral Medicine/Pathology in Greek and International Journals. He has also published two books; the first is titled "Maxillofacial manifestations of endocrine diseases" and the second is an online "Handbook of Oral Physiology and Oral Biology". He has performed more than 170 oral presentations and lectures in Greece, Europe and USA. His clinical and research interests are focused on oral and maxillofacial oncology, on clinico-pathologic features of oral diseases, salivary markers for cancer detection and on the immunopathology of mucosal diseases.



**Associated Professor**  
**STYLIANOS DALAMPIRAS**  
DMD, PhD  
*Aristotle University of Thessaloniki*



Assoc. Prof. Stylianos Dalampiras was born in Thessaloniki, Greece. He graduated the Dental School of Aristotle University in 1974 and the Medical School of Aristotle University in 1981. He followed post graduate studies in the University of St Etienne in the Clinic of Stomatology and Maxillofacial Surgery from April 1984 to August 1984. Immediately after that he worked for two months in the University of Bochum, Germany in the Oral & Maxillofacial Surgery clinic, under Prof. Egbert Machtens. In 1990 he was nominated specialist in Oral & Maxillofacial Surgery. In 1994 he was elected Assist. Prof. in the Dental School, Aristotle University of Thessaloniki, Greece. In 2004 he passed the examinations in Tours, France and he obtained the title of the Fellow of the European Board in Oral & Maxillofacial Surgery (FEBOMFS). He worked for two months as Visiting Prof. in Guys Hospital, London, UK, in the summer of 2008, with Prof. Mark McGurk. In 2009 was elected Assoc. Prof. in the Dept. of Oral & Maxillofacial Surgery, Dental School, Aristotle University of Thessaloniki, Greece. The academic years 2009-10 and 2010-11, he was invited as Visiting Prof. in Comenius University, Faculty of Medicine, Bratislava, Slovakia, supported by the ERASMUS program, to teach undergraduate students. The academic years 2011-12, 2012-13 and 2013-14 he was invited to the Faculty of Dental Medicine of Grigore T. Popa University in Iasi Romania, for a series of lectures in the Post-graduate program, after the invitation of the Dean Prof. Norina Forna. On the 28<sup>th</sup> of July 2014 he was elected Associate Professor of the Faculty of Dental Medicine, of Grigore T. Popa University, in Iasi, Romania.

He is elected Honorary Treasurer of the Balkan Stomatological Society (BaSS) for the years 2011-15. He is a speaker in national and international congresses and seminars lecturing colleagues in the dental profession, sponsored by public or private sponsors. He teaches undergraduate and

postgraduate students in the Dental School of the Aristotle University, Thessaloniki, Greece, the topics of Oral & Maxillofacial Surgery. He speaks English, French and Italian. He is practicing Implantology and Oral Surgery in private and in University since 1995.



**Associated Professor**  
**ARGIRIOS PISSIOTIS**  
DMD, PhD  
*Aristotle University of Thessaloniki*



Professor Argirios Pissiotis graduated the D.M.D. Dental School, Aristotle University of Thessaloniki, in 1980; between 1980-1982 he followed Postgraduate studies in Prosthodontics at the School of Dental Medicine, Tufts University, Boston Mass., USA and in 1982 he obtained his Certificate in Prosthodontics. Between 1982-1983 he was Part Time teaching to the Undergraduate Program, member of the Faculty of the Restorative Department, School of Dental Medicine, Tufts University Boston Mass USA and research as partial fulfillment of the Master's Degree Program, School of Graduate Studies, Tufts University Boston Mass, USA and in 1983 he became Master in Science School of Graduate Studies, Tufts University Boston Mass, USA. Between 1983-1989 he was Teaching assistant in the Department of Removable Prosthodontics, School of Dentistry, Aristotle University of Thessaloniki, Greece; in 1989 he obtained his Doctorate in Dentistry Degree, School of Dentistry, Aristotle University of Thessaloniki, Greece; in 1996 he became Elected lecturer in the Department of Removable Prosthodontics, School of Dentistry, Aristotle University of Thessaloniki, Greece, in 1999 he became Elected Assistant Professor and in 2001 he became Elected Associate Professor in the same department and university. He has authored and co-authored more than 60 scientific papers in Greek and International Scientific Publications, is an Associate Editor of the International Journal of Prosthodontics and has lectured widely both nationally and internationally in the area of Prosthodontics.

He is a Fellow of the International College of Dentists since 1992 and belongs to numerous Dental Academies societies, such as: Greek Osseointegration Association, Society for Odontostomatological Research, Stomatological Society of Greece, Stomatological Society of Northern Greece, Greek Academy of Esthetic Dentistry, Balkan Stomatological Society, American Academy of Fixed Prosthodontics, American Prosthodontic Society, Academy of Osseointegration, European Academy of Esthetic Dentistry, European Prosthodontic Association, International College of Prosthodontists.





**Dr**  
**ZORAN VLAHOVIĆ**  
DMD PhD  
*"V DENTAL CENTER" Podgorica*



Dr. Zoran Vlahović is Oral surgery specialist; his main domain of activity concerns the oral-surgical and implantology practice - at Private Clinics "V Dental Center" Podgorica, Montenegro; he was lecturer in eleven lectures from the field of oral surgery, implantology and Cone Beam Computer Tomography; he has a rich experience in working with CBCT devices.



**Professor**  
**NORINA CONSUELA FORNA**  
DMD MSc PhD  
*"Grigore T. Popa" UMPH Iasi*



Professor Norina Fornă is Dean of the Faculty of Dental Medicine, University of Medicine and Pharmacy „Grigore T. Popa”, Iasi. She is Primary Doctor in General Stomatology and Oromaxillofacial Surgery, as well as General Medicine Doctor; she has over specialization in Oral Implantology, Dental Prosthetics and OMF Surgery (Paris 5, 6, MSF) and an international Master's Degree in Oral Implantology and Dental Prosthetics (ICOI, USA). She is European Specialist in Dental Prosthetics - European Prosthodontic Association.


Professor Norina Fornă is President of the International Society of General and Oro-Maxillo-Facial Rehabilitation Forum Odontologicum, Switzerland (since 2013); she has a wide international recognition, materialized through the following scientific and academic titles:

- Fellow of International College of Dentistry (since 2013)
- Fellow of Academy of Dentistry International (since 2013)
- Vice-President of CIDCDF Board and Ambassador for Romania - Confederation of Deans of the Dental Medicine Faculties with Total or Partial French Expression (since 2013)
- Member in the Council of European Association of Dental Prosthetics (since 2013)
- Vice-President and Ambassador for Romania - International Congress of Oral Implantologists (SUA) - since 2010
- Fellow International Honor Dental Organisation ( since 2011)
- Chevalier dans l'Ordre des Palmes Academiques (since 2011)
- Expert AUF (L'Agence universitaire de la Francophonie) - since 2011
- Fellow and Diplomat International Congress of Oral Implantologists (since 2010)
- Member in the Leading Board of Balkan Stomatological Society (BaSS) (since 2009)
- Member of the European Society of Cosmetic Dentistry (since 2008)
- Member in the Leading Board IMAT, Germany (since 2006) and in the Leading Board EIDAM, Canada (since 2006)

- Ambassador for Romania of the Federal Bureau of the International Federation of Odontostomatology and Cranio-facial Surgery (IFOSCMFS)

Professor Norina Forna is member of several international scientific Academies: the Royal College of Surgeons of England, Periosteal Integration Academy, American Academy of Implantology, National Academy of Dental Surgery, France, American Academy of Dental Education (member in the Leading Board) and Pierre Fauchard Academy, USA. Professor Forna is also Correspondent Member of the Romanian Academy of Medical Sciences (since 2013), Associated Member of the Romanian Academy of Scientists (since 2014) and Doctor Honoris Causa of the State University of Medicine and Pharmacy „Nicolae Testemițanu” Chișinău, Rep. Moldova. Since 2007 she is also trainer in Diplome d`Universite de Chirurgie et d`Implantologie Orale (DUCIO).

In Romania Professor Norina Forna has also a very wide professional recognition at national level; she is the President of the Consortium of Romanian Dental Medicine Faculties Deans (since 2014), being also President and founding member of the Romanian Association of Medical and Dental Tourism (since 2014), Romanian Society of General and Oro-Maxillo-Facial Rehabilitation (since 2012), Romanian Society of Oral Rehabilitation (since 2008), Romanian Association for Dental Education (since 2008) and Romanian Society for Computerized Regulatory Termography (since 2008). Professor Forna is also member in many other professional and scientific societies from Romania. Author of 23 monographs, 2 treaties, 13 textbooks and 2 book chapters, over 30 articles ISI indexed, over 40 articles PUBMED and BDI indexed and over 400 articles published in abstract or in extenso in the volumes of national and international scientific manifestations, Professor Forna is the recipient of several awards and honors; she has a valuable scientific activity, being project leader and senior scientist in many funded research and operational projects.



**Acad. Professor  
CONSTANTIN BALACEANU STOLNICI**  
DMD MSc PhD  
*Romanian Academy*



Acad. Dr. Constantin Bălăceanu-Stolnici (born in 1923, Bucharest) is neurologist, Professor of Neuropsychology and Nervous System Anatomy, Professor of Culture and Science History and Honorary Member of the Romanian Academy. He is Honorary President of the Ecological University, Bucharest, President of the “Ateneul Român” Society and Associated Professor at the Newcastle-upon-Tyne University (United Kingdom), Pontifical University from Porto Alegre (Brazil), Universidad Internacional Menéndez Pelayo, Santander (Spain), Catalan Medical Academy, Barcelona (Spain) and Medical College Paris (France). He was granted with numerous distinctions and prizes: Doctor Honoris Causa, “Grigore T. Popa” University of Medicine and Pharmacy Iasi, Romania, Petrosani University and Ecological University from Bucharest, “Patriarchal Cross”, the “Star of Romanian” Order - in degree of Knight and others. He is author of more than 16 books published in prestigious publishing houses.



**Acad. Professor**  
**CONSTANTIN IONESCU TARGOVISTE**  
 DMD MSc PhD  
*Romanian Academy*



Professor Constantin Ionescu Targoviste is the President of Romanian Medical Association and the Director of the „Prof. Dr. N. Păulescu” Diabetes, Nutrition and Metabolic Diseases National Institute, Bucharest, Romania. He is also Professor at the Diabetes, Nutrition and Metabolic Diseases Clinic, “Carol Davila” University of Medicine and Pharmacy Bucharest. In more than 40 years of scientific and medical activity, Professor C.I. Targoviste brought important contributions to increase the level of diabetes and metabolic diseases medical assistance in Romania: since 1988 he represented Romania in the EURODIAB multicenter project; he created a laboratory of neurophysiological explorations where he developed original techniques of diagnosis and a laboratory of genetic researches; he collaborated with the Human Genetic Centers from Oxford and Cambridge and he made one of the most important genetical analyses of the 1st type diabete, identifying special particularities for the Romanian population. His outcomes were published in over 300 scientific articles (most of them ISI indexed), being quoted of more than 2300 times. He is author of 16 treatises and monographs, he has 5 innovation patents for anti-diabetic drugs; he is member in the Editorial Board of prestigious international scientific journals ("Diabetologia", "Alternative Medicine", "American Journal of Acupuncture", "Endocrinology", "Romanian Journal of Internal Medicine", "Proceedings of the Romanian Academy Series B: Chemistry, Life Sciences and Geosciences"). He created in 1995 and he coordinates the Medical Union BlackSeaDiab, which reunites specialists from 12 countries; since 1992 he is member of the Academy of Medical Sciences from Romania, being also Honorary Member of many international academies, scientific associations and universities.



**Professor**  
**ECATERINA IONESCU**  
 DMD MSc PhD  
*“Carol Davila” UMPH Bucharest*



Ecaterina Ionescu, PhD, MD, is Professor and the Head of the Department of Orthodontics and Dentofacial Orthopedics, Faculty of Dental Medicine, University of Medicine and Pharmacy “Carol Davila”, Bucharest, since 2008. Prof. Ionescu held the position of the vice-rector for educational policies in University since 2012. She is the President of the Romanian National College of Dentist and member of well-known national and international professional societies/associations. Prof. Ecaterina Ionescu published several books and many research articles in the field of orthodontics, general dentistry and public healthcare systems. She is also member of

the editorial board for prestigious Romanian journals. During her professional activity, Prof. Ecaterina Ionescu presented numerous lectures and conferences at national and international scientific meetings.



**Professor**  
**ALEXANDRU BUCUR**  
DMD MSc PhD  
*"Carol Davila" UMPH Bucharest*



Professor Alexandru Bucur is the Dean of the Dental Medicine Faculty, "Carol Davila University of Medicine and Pharmacy of Bucharest; he is also the Head of Oral and Maxillofacial Chair, Faculty of Dental Medicine, University of Medicine and Pharmacy "Carol Davila", Bucharest and Vice-president of the Dentists College of Romania. Among his national and international positions held we can mention the following:

- Delegate to the UEMS Section of OMF Surgery and Stomatology
- Examiner of European Board of Oral and Maxillofacial Surgery
- President of The Romanian Association of oro-maxillofacial and dento-alveolar surgeons
- Counselor for Romania of European Association for Cranio-Maxillofacial Surgery
- Member of International Association of Oral and Maxillofacial Surgeons
- Chief of Editorial board of "Romanian Journal of OMF surgery and Implantology"
- Member of C.N.T.D.C.U. Specialisee Committee for confirmation Phd Title
- Competent in Implantology
- Certificate of complementary studies in ultrasonography
- Overspecialization in lithotripsy and sialendoscopy
- Graduation certificate in Sanitary Management
- PhD coordinator
- Member in The International Academy of Oral Oncology
- Coordonator of the complementary studies program in the Inhalosedation
- Visiting Professor, Gregorio Marañón Hospital (Madrid, 2007)

Professor Alexandru Bucur is author of 8 textbooks; he had over 30 presentations at international congresses, over 150 presentations at national congresses and more than 200 scientific articles in extensor. He is author of 17 articles ISI indexed, project director and member in the working committee of grants, his activity being recognized through the following awards and distinguishes:

- Ordinance "Sanitary Virtue in rank of Commandant" 10.12.2004, Presidential Decree, No.1102/10.12.2004
- Excellence Diploma of International Congress on Oral Cancer (ICOOC) Melbourne
- Honorary Diploma of International Research Committee of Oral Implantology (IRCOI), 13-15.06.2002, Bucharest
- Excellence Diploma of Medical Journalists Association, 28 January 2005
- Included in the biography of the "Who is who" personalities' encyclopedia

His main scientific contributions regard: the insertion of the first Stryker type Condyle Prosthesis from Eastern Europe for reconstruction of temporomandibular joint (2005); the surgical bimaxillary treatment of severe dentomaxillary anomalies; the reconstruction of complex oral and maxillofacial defects with free vascularly and microsurgical anastomosed flaps and the surgical treatment of salivary gland tumours.



**Professor**  
**IULIAN ANTONIAC**  
MSc PhD  
*University Politehnica of Bucharest*



Professor Iulian Antoniac is a materials science engineer working in the field of biomaterials and medical devices. He is the leader of the Biomaterials Group from Faculty of Materials Science and Engineering, University Politehnica of Bucharest and past President of the Romanian Society for Biomaterials (SRB). He has worked at the beginning on biomaterials used for different orthopedic and dental application (such as hip prosthesis, implants for trauma, dental prosthesis). After several specialization in laboratories from Switzerland, Portugal, France, USA, on surface analysis, composite materials, implant design and biomaterials characterization, his scientific interests spans from the synthesis and characterization of biomaterials and interactions with living tissues, retrieval implant analysis, to the new composites and scaffolds based on nanostructured and biologically inspired biomaterials. His professional and scientific activity comprises: Books and chapters in specialized books: 6; Handbooks/textbooks: 5 including publication of a book entitled 'Biologically Responsive Biomaterials for Tissue Engineering', Springer, 2012; Papers published in scientific journals: 46; Papers published in the proceedings of international or national conferences: 109; Inventions: 7; Participating in different international or national research projects: 40 (6 as project manager, 9 as partner responsible, 25 as team member); Member of the scientific committee of different meetings: 24; President of international conferences: 6. He is a member of the International Editorial Board and reviewer for many journals and biomaterial conferences, member of different scientific associations. Professor Antoniac has been invited to deliver plenary or keynote lecture to many international conferences.



**Professor**  
**KOSOVKA OBRADOVIĆ DJURIČIĆ**  
 DMD MSc PhD  
*University of Belgrade, School of Dental Medicine*



Professor Kosovka Obradović Djuričić finished Belgrade School of Dentistry in Belgrade 1980. In 1981 she was employed at the Clinic for Prosthetic Dentistry as junior lecturer. Her professional carrier followed the way through lecturer senior, assistant professor, and associate professor until gaining the title professor (2006). She has Master (1985) and PhD degree (1992) of science as well as specialization in Prosthodontics (1989). Obradović Djuričić was additionally trained at the Faculty of Dentistry, Department for Dental Materials, Bergen, Norway; at Ivoclar, Lichenstain and at Vita, B.S, Germany. She has finished different courses dedicated to the implants education: Straumann, Nobel Replace, Itop CEO course, etc.

She has published extensively on dental materials, impression materials and dental ceramics. Her scientific interest resulted in more than 100 published papers and around 50 lectures by invitation. She is the author and coauthor of 9 books for basic and postgraduate studies. She is the member of several scientific national projects. Dr Kosovka Obradović Đuričić is the vice-president of Serbian Prosthodontics Society and member of different national dental associations: Serbian Medical Society, Dental Serbian Association, Prosthetic Section of Serbian Medical Society, Serbian Society of Oral Implantology, and international association: BaSS, EPA and IADR. Professor Obradović Djuričić was the chairman of the department for oral rehabilitation, assistant editor-in-chief of the first national journal for prosthetics and dental technology, the member of the editorial board of Serbian Medical Archive Journal, mentor of master and PhD thesis, and reviewer of professional monographs and textbook for postgraduate studies. Two years ago (2013) she was awarded for her longstanding research and scientific work by Serbian Medical Society.



**Senior Lecturer**  
**KATARINA RADOVIC**  
 DMD MSc PhD  
*University of Belgrade, School of Dental Medicine*



Dr Katarina Radović graduated in 1999 at School of Dental Medicine in Belgrade. In 2000 she was employed at the Clinic for Prosthodontics as a junior lecturer. She became specialist in prosthodontics in 2005 at the same Clinic. In 2007, she became MSc and in 2014 she was complete the doctoral studies and become a Ph.D. Dr Radović finished different courses dedicated to the Immunology, Gnatology and implants education (Straumann, Nobel Replace, Nobel Active, Bredent, etc.). She is continuous engage in teaching of Clinical & Preclinical Prosthodontics and Gnatology at the School of Dental Medicine in Beograd since 2000 and in postgraduate courses in

Prosthodontics since 2005. Her basic field of science is the cellular response and signaling molecules in Diabetes Mellitus type 2 dental patients. She presented 34 papers on international and national Congresses and she was a poster and oral session chair on few scientific events. Besides others, she published 8 papers in international journals indexed in MEDLINE. Dr Radović is member of team in few projects of Serbian Ministry of Education and Science.

She is a member of different national dental associations: Serbian Medical Society, Dental Serbian Association, Prosthetic Section of Serbian Medical Society, Serbian Society of Oral Implantology, and international association: European Prosthodontic Association, BaSS (poster and oral session chair on the 19<sup>th</sup> BaSS Congress) and IADR (oral session chair on Annual Congress in Dubrovnik 2014).



**Professor**  
**KAAN ORHAN**  
DDS PhD  
*Near East and Ankara University*



Kaan Orhan, DDS PhD is a Professor of DentoMaxilloFacial Radiology at the Near East and Ankara University, Faculty of Dentistry, where he serves as the chairman of Dentomaxillofacial Radiology Department, Near East University and also as a faculty in Dentomaxillofacial Radiology Department, Ankara University, Ankara, Turkey.

Dr. Orhan was born in Zonguldak, Turkey, 1976. He received his dental degree in 1998 and completed his Maxillofacial radiology residency studies in 2003 at the Osaka University Faculty of Dentistry in Osaka, Japan. In 2004, he started his academic career in Ankara University as a consultant at the Faculty of Dentistry. Between 2004-2006, he worked as Maxillofacial consultant and lecturer in the same University. He became an associate professor in 2006 and a full time professor in 2012. In 2007, he started as the chairman of Dentomaxillofacial Radiology Department, Near East University, and also continuing as a faculty in Dentomaxillofacial Radiology Department, Ankara University, Ankara, Turkey. He has over 70 SCI international publications on peer-reviewed journals, and received over 300 citations from his studies with an h index 11. He particularly made significant contributions in the Maxillofacial Radiology. He has been invited to give many lectures in national and international scientific meetings. He served as the chairman of Research and Scientific Committee, European Academy of DentoMaxillofacial Radiology between 2008-2012 and he was elected for the Vice president position (2012-2014) and then as the President for the same academy (2014-2016). He is also serving in the Research and Scientific Com in IADMFR. He is a fellow of Japanese Board of DentoMaxillofacial Radiology, European Head and Neck Radiology Society (ESHNR), European society of Magnetic Resonance in Medicine and Biology (ESRMB), Turkish Magnetic Resonance Society. He is also serving a Board member of specialization committee in Ministry of Health and served as the recognition of Dentomaxillofacial Radiology specialty in Turkey. He is in the editorial board of many journals including "Oral Surgery Oral Medicine, Oral Pathology, Oral Radiol", "Radiology: Open Access" and "Oral Radiology", Journal of Radiation and Radiation Therapy and also serving as reviewer more than 20 different journals on

his field including Oral Surgery Oral Medicine, Oral Pathology, Oral Radiol", Dentomaxillofacial Radiology, World Journal Surgical Oncology, Quintessence International, Journal of Forensic Dental Sciences, Clinical Anatomy etc.

His awards include:

- Best Study 52nd Japanese Congress of DentoMaxillofacial Radiology 2011,
- First poster study prize winner 12nd European Congress of DentoMaxillofacial Radiology, 2010.
- "Yoshida Manufacturing Award" in 7<sup>th</sup> of Congress of Asian Oral&Maxillofacial Radiology, Nara, Japan, 2008
- Second Poster Prize Winner European Society of Head and Neck Radiology, 2008.
- Japan Ministry of Education Scholarship (MONBUSHO: NEXT) 2000-2003.

## INVITED SPEAKERS abroad BaSS



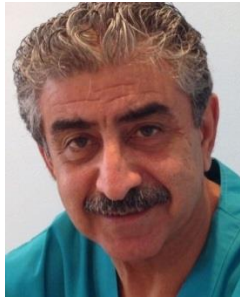**Professor**  
**ADY PALT**  
DMD MSc PhD



Dr. Ady Palti is practicing implant dentistry since more than 30 years. He is visiting Professor on various Universities, past president and board member of the DGOI & ICOI and speaker on national and international symposiums. He has many patents in the fields of oral implantology and oral surgery and various publications in national und international journals with the focus on bone augmentation materials, implant design or immediate loading und Umsetzung in the daily practice. Dr. Palti has two Dental Centers in Baden-Baden and in Kraichtal-Unteröwisheim. Both of them are members of the „Leading Dental Centers of the World“ and the „Leading Impant Centers“. Treatment key aspects of both Dental Centers are: •Implantology •Aesthetic dentistry •Periodontology •Orthodontics •Bleaching. Dr. Ady Palti, Clinical Professor New York University, is a world wide speaker frequently on global conferences, congresses and universities. He also gives lectures at the DGOI, ICOI. Dr. Palti is the Founder and Director of the educational center International Academy for Implantology (IAI), where he is teaching in courses for various groups like DGOI, Haranni Akademie and others.



FRANCE



**Dr  
KADHIM AL-HIMDANI**

BDS MSc PhD

Consultant (Maxillo-facial Surgery and Oral  
Implantology)

*French Centre for Dental Implante, Sharjah*



Dr. Kadhim Al-Himdani graduated in 1972 the College of Dentistry, Baghdad University, among first 10<sup>th</sup>; in 1985 he obtained his PhD in Oral Implantology, at University of Paris VII. He is one of the pioneers in Implantology in Middle East and Europe (France), with many researches contributed for the development of this science, especially in the field of Immediate Implantation. Between 1980 - 1983 he obtained the title of MSc in Oral Surgery, also at University of Paris VII and between 1984 - 1985 he obtained the title of MSc in Paediatric Surgery at the Medical College of Paris. He worked as Dental Surgeon in Baghdad hospitals and in his private clinic (between 1972 - 1978). Meanwhile, he was a lecturing at Baghdad University - College of Dentistry. Between 1980 - 1985 Dr. Kadhim Al-Himdani was Lecturer at the College of Dentistry at the University of Paris VII and between 1980 - 1997 he was officially appointed as Consultant in the Department of Oral & Maxillo-Facial Surgery / Cochin Hospital "Paris". He is Lecturer at the first Master course of Implantology in France and Europe (1985 - 2015). He was one of the founders of this course and granted many Arab and European students the master degree. He was also Consultant Oral Surgeon in his own clinic as well as in several hospitals in Paris "Bretonneau, Fontainebleau" (1985 - 2002). Also, he was Visiting Oral Implantologist in a number of Paris clinics and managed to achieve great success in this field. During his Professional life in France for about 25 years, Dr. Al Himdani practiced all field of Dental Art like Oral Implantology, Cosmetic Dentistry, Orthodontics, Periodontology, Prosthodontics and Pedodontics. Between 2002 - 2004 Dr Al-Himdani was Consultant Oral Implantologist & Maxillo Facial Surgeon at Al-Zahrah Private Hospital in Dubai and Sharjah, UAE and since 2004 he is Oral Surgeon & Implantologist at his own Private Center "French Centre for Dental Implante", in Sharjah.

Dr. Al Himdani brought with him all his 25 years of distinguished experience in France, so that he can offer the best solutions and interventions for his patients.

CZECH Republic



**Associated Professor  
HANA HUBALKOVA**

DMD, PhD

*Charles University Prague*



Dr. Hubalkova graduated from Stomatology as a MUDr. at Charles University in Prague, Czech Republic, in 1982. She got her training certificate - specialization in dentistry in 1985, in prosthetic dentistry in 1991 and clinical dentistry in 2012. She completed her postgraduate studies (Ph.D.) with thesis on biomedicine at Charles University in Prague in 2004 and she habilitated

(docent) in 2007. Dr. Hubalkova was recognized as an EPA Specialist in Prosthodontics in 2010. She passed trainings and courses in Heidelberg/Germany, Stockholm/Sweden, Schaan /Liechtenstein, Miami/USA.

Employment: 1982 - until now - General Teaching Hospital in Prague, Stomatological Clinic, 1987-2004 Department of Stomatology, 2004-2006 Head of the Department of Preclinical Dentistry, 2006-2014 Head of the Department of Prosthetic Dentistry. 2000-until now - First Medical Faculty, Charles University in Prague, Department of Stomatology: responsible for scientific affairs of the clinic, coordinator of the English Parallel.

Research projects: Oral Rehabilitation of Patients with Gastrointestinal Disorders, Dental Implants, Long-term Stability of Fixed Prosthetic Appliances, Compatibility of Dental Alloys with Magnetic Resonance Imaging, Therapy of Alveolar Osteitis with Ozone Generator.

Dr. Hubalkova is a member of the Czech Medical Society of J. E. Purkyne, Czech Association of Prosthetic Dentistry (scientific secretary since 1997, President since 2010), Czech Dental Chamber (member of the Academic Council since 2010), European Prosthodontic Association (since 1998, member of org. committee - 25th EPA Congress in Prague, 2001, EPA Council member since 2011, Trustees member since 2013, President Elect (2012) and EPA President 2014-2015. She is also PGS trainer in Experimental surgery, 1st Medical Faculty, Charles University, since 2004 and Editor Council of Progresdent Journal, since 2004. Her scientific activity is materialized through 152 articles, 2 monographies, chapters in books and 277 lectures at scientific meetings in the Czech Republic and abroad.

Republic of  
SOUTH KOREA



**Associated Professor**  
**KWIDUG YUN**

DMD, PhD

*Chonnam National University, School of Dentistry*



Professor Kwidug Yun obtained her MSD title in 2008, at Chonnam National University; in 2011 she obtained her PhD title at the same university. Between 2010 - 2012 she was full time lecturer at Chonnam National University, School of Dentistry, Department of Prosthodontics; between 2012 - 2014 she became Assistant Professor and since 2014 she is Associated Professor at the same university.

Republic of  
SOUTH KOREA



**Adjunct Professor**  
**CHANG HEUN PARK**

DMD, PhD

*Chonnam National University, School of Dentistry*



Dr. Chang Heun Park is Adjunct professor at the Department of Orthodontics, College of Dentistry, Chonnam national university. He is also President of Gwangju - Chonnam branch of

Korean Association of Orthodontist, member of The Korean orthodontic research institute, accredited orthodontist of Korean Association of Orthodontist, Fellow member of International orthodontic research of TWEED Foundation, International member of American Orthodontic Association and Fellow of World Federation of Orthodontists. He works also in private practice in Gwangju city.

## SPEAKERS :

BULGARIA



**Assoc. Professor**  
**THEODORA NIKOLAEVA BOLYAROVA**  
**KONOVA**  
DMD PhD  
*UMPh Sofia*



Teodora Bolyarova graduated from the Faculty of Dentistry at the Medical University, Sofia (1993). She is a specialist in "Therapeutic dentistry" (1998), "General Dentistry" (2005) and "Dental Clinical Allergology" (2014). She became an assistant at the Department of Therapeutic Dentistry (1995) by competition. T.Bolyarova has been working in the Department of Periodontology since its establishment (1998) as a senior assistant professor (1999), chief assistant professor (2005) and Associate Professor (2009). She conducts preclinical and clinical exercises on therapeutic dentistry (1995-99) and exercises on periodontology (from 1999 up to now). Bolyarova has been giving lectures to students since 2009. She takes part in postgraduate students' training. Her research interests are in the fields of periodontology, periodontal microbiology, periodontal medicine, laser treatment in periodontology, gerontostomatology and social medicine. She has over 70 publications and reports. For the last five years Bolyarova has delivered numerous lectures at regional colleges of Bulgarian Dental Association in Bulgaria.

GREECE



**Lecturer**  
**ANTIGONE DELANTONI**  
DMD MSc PhD  
*Aristotle University of Thessaloniki*



Dr. Antigone Delantoni obtained her DDS in October 1998, at Aristotle University of Thessaloniki; between August 1999 and February 2002 she carried out and obtained her MSc title, in Oral Radiology, at University of British Columbia - Vancouver, Canada. In February 2007 she obtained her PhD title with the thesis "TMJ involvement and imaging in patients with inflammatory disorders", at Aristotle University of Thessaloniki; in June 2008 she became also MD, at the same

university. She graduated in October 2009 her PostDoc studies with the thesis “MRI staging of tongue cancer, correlation of radiographic findings to pathology”, also at Aristotle University of Thessaloniki. Since 2006 she activates in research area at Aristotle University of Thessaloniki, Greece.



**Lecturer**  
**CHARIS BELTES**  
DMD MSc PhD  
*Aristotle University of Thessaloniki*



Dr. Charis Beltes is Endodontist & Oral Surgeon, DDS, MSc, MClintDent--PhD Candidate, Department of Endodontology at Aristotle University, Thessaloniki. His MClintDent Thesis, at University of Edinburgh, has the subject “Comparative ex vivo study of the effect of three ultrasonic retrotips in the isthmuses of mandibular first molars”; his MSc Thesis, at Aristotle University of Thessaloniki, concerns the “In vitro evaluation of three different root-end preparation techniques in periapical surgery”. Dr. Charis Beltes is a known personality in the world of medicine. Among his most important publications there are:

- Endodontic management in a patient with vitamin D-resistant Rickets (Journal of Endodontics);
- An ex vivo comparison of the push-out bond strength of a new endodontic filling system (Smartseal) and various gutta-percha filling techniques (Odontology)
- Dental extractions and bisphosphonates: the assessment, consent and management, a proposed algorithm (BDJ)
- Intravenous conscious sedation (SAAD Dig.)
- Current aspects of prevention and treatment during bisphosphonate therapy (Endodontie, Quintessenz)



**Professor**  
**CATALINA ARSENESCU**  
MD, MSc, PhD, FESC  
*« Grigore T. Popa » UMPH Iasi*



Professor Catalina Arsenescu is the Head of Medical Cardiology Clinic, « Prof. Dr. George I.M. Georgescu » Institute of Cardiovascular Diseases, Iasi and Professor of Internal Medicine and Cardiology at the “Grigore T. Popa” University of Medicine and Pharmacy Iasi, Faculty of Medicine; she is PhD and Internship coordinator, being also the Head of the Medical Cardiology Clinic - Iasi Center of Cardiology and the Head of the Working Group of HTA, Romanian Society of Cardiology. She has competencies in echocardiography, general echography, electrophysiology and

peacemakers; she is European Specialist in HTA. Professor Arsenescu is member of Physicians and Naturalists Society Iasi, Romanian Society of Cardiology, Romanian Society of Internal Medicine, European Society of Cardiology, European Heart Rhythm Society, European Society of Hypertension and European Association of Echocardiography and member in Editorial Board of scientific journals (Romanian Journal of Cardiology – Bucharest, Romanian Journal of Internal Medicine and Romanian Medical – Surgical Journal Iasi. Professor Arsenescu is author or co-author at 10 books, 132 scientific papers published in extensor, 245 scientific papers published in abstract and 485 communications and plenary lectures at national and international conferences, for which she was awarded with distinctions and prizes.



**Professor  
GABRIELA BANCESCU**

DMD, MSc, PhD  
*“Carol Davila” UMPH Bucharest*



Professor Gabriela Bancescu, born in 1959, in Ploiesti, graduated the Faculty of Medicine, “Grigore T.Popa” University of Medicine and Pharmacy Iasi in 1983. Between 1983 – 1992 she carried out her internship in general medicine at County Hospital Ploiesti; in 1991 she became specialist in Clinical Microbiology. Her didactic activity started in 1992; in 2006 Dr. Gabriela bancescu became Associated Professor at Microbiology Department, Faculty of Dental Medicine, « Carol Davila » University of Medicine and Pharmacy Bucharest; presently she is Professor and she coordinates the Microbiology Department at the same faculty and university. Professor Gabriela Bancescu carried on an intense research activity within the Laboratory of Oral Microbiology, Cantacuzino Institute, Bucharest; she graduated also the Master program in Oral Microbiology at UiB, Bergen, Norvegia (2004-2006); she obtained her PhD title in Medicine in 2002. Professor Bancescu was expert evaluator of biological products of INCDMI - Cantacuzino: Vaccinul dizenteric viu oral Vadizen – Shigella flexneri 2a T32 – Istrati (2 years), being also CEE projects responsible and member in the research team of 8 other research projects.



**Professor  
MARIN BURLEA**

DMD, MSc, PhD  
*« Grigore T. Popa » UMPH Iasi*



Professor Marin Burlea graduated in 1973 the Faculty of General Medicine of Medicine and Pharmacy Institute – Iasi. He became specialist in pediatrics in 1985 at the IInd Pediatrics Clinic, Children's Hospital "St. Mary" of Iasi, and in 1994 specialist physician in gastroenterology. The

activity of Prof. Dr. Burlea Marin stands out through its two directions addressed. Between 1990-1997 and 2001-2009 he occupied the position of director of the Children's Hospital "St. Maria" of Iasi. In the teaching career he became associate professor in 1999 and professor in 2002 at the Department of Pediatrics, Faculty of Dentistry and Pharmacy "Grigore T. Popa" Iasi. Since 2004 Prof. Dr. Burlea Marian was pro-rector and member of the Senate of University of Medicine and Pharmacy "Grigore T. Popa" - Iasi. In 2009 he became president of the Romanian Society of Pediatrics.



**Professor**  
**IOAN DANILA**  
DMD, MSc, PhD  
« Grigore T. Popa » UMPH Iasi



Professor Ioan Danila was born in 1945 in Tirgu Ocna; he graduated the Faculty of Stomatology, Timisoara in 1969; he became specialist in general stomatology in 1974; he obtained his PhD title in 1986. Since 1999 he is Professor at the discipline of Preventive and Community Dentistry, Faculty of Dental Medicine, "Grigore T. Popa" University of Medicine and Pharmacy Iasi. Professor Danila was member in the specialty commission, Ministry of Health from Romania. He was member in organizing committees at over 100 scientific manifestations; he coordinated the National Study regarding the Odonto-periodontal Status of 6-12 years old children from Romania and he was member in the National Committee of the National Program of Oral Diseases Prevention (10 years). He was Invited Speaker at UNAS and AMSPPR congresses (since 2000 - at present) and he coordinated many grants and research projects implemented in UMPH Iasi. He is member in national and international scientific societies (European Association of Dental Public Health, International Association of Pediatric Dentistry, National Union of Stomatological Associations, National Society of Preventive Medicine) and in the Editorial Board of scientific journals (Journal of Preventive Medicine, Journal of the Black Sea Countries, Journal of Romanian Dentistry, Medicina Stomatologica). He was awarded with prizes (Junior Robert Frank Award, Hatton Travel Award, Global University Case Contest - CED-IADR) and distinctions (Ordinul National pentru Merit in Grad de Cavalier - 2002, Excellence Certificate in recognition to outstanding career in dentistry and contribution to the International Congress of Dentistry minimally Invasive Methods and Techniques in Dentistry - 2007), as well as Excellence Diplomas.



**Professor**  
**STEFAN OCTAVIAN GEORGESCU**  
DMD, MSc, PhD  
UMPh Iasi



Dr. Stefan Octavian Georgescu is Professor at the discipline of Surgical Semiology - General surgery, Faculty of Medicine, "Grigore T. Popa" University of Medicine and Pharmacy Iasi

and head of the section "Surgery II", "Sf. Spiridon" Emergencies Iasi. He is also member in the "Grigore T. Popa" UMPH Senate and the Professional Committee, Romanian Ministry of Health, and the Vice-President of the Professional Committee of General Surgery of Romanian College of Physicians. He is member in the most significant scientific societies from Romania and abroad (the European Society of Infections in Surgery, the International Society of Bariatric Surgery, the International Society of Endoscopic Surgery, the International Society of Surgery, the European Society of Digestive Surgery and others). He is author of 12 books, 114 scientific articles, 155 scientific articles published in abstract, 222 scientific communications and member in the research team in 3 research projects.



**Professor**  
**GABRIELA IFTENI**  
DMD, MSc, PhD  
*« Grigore T. Popa » UMPH Iasi*



Professor Gabriela Ifteni is working at University of Medicine and Pharmacy "Grigore T. Popa", Faculty of Dental Medicine, Dental Prosthetics Department. Since 2002 she is the Chief of Department Gnatoprosthetic Devices and the Chief of Reduced Partial Edentation Discipline. Her main specialties are general stomatology, dental prosthetics and clinical gnatology; she has also competencies in Implantology (Mainhein, Germany, 1998). She obtained her PhD title in 1997, with the thesis "Morphological and functional correlations between the TMJ and the anterior determinant of dental occlusion". She has more than 30 years experience in her specialty and more than 20 years of experience in her didactic activity; she carried out 38 specialization lectures in different domains, in Romania and abroad, being also Lecturer in programs like these. She was Invited Speaker at many scientific congresses and conferences in Romania and abroad; she created a DVD with live video records regarding different types of organic structures preparations on simulators and in clinic environment, addressed mainly to the students. She is member in the most important scientific and professional association from Romania; she coordinated in 2007 the MSc program "Modern Techniques of Comple rehabilitation in Partial Edentation and Substance Loss", together with Professor Norina Forna; she is author of 9 books and textbooks and 27 scientific articles (2006-2011) and director of 2 research grants and 7 clinical studies.



**Professor**  
**ANDREI KOZMA**  
DMD, PhD  
*Romanian Academy of Scientists*



Dr. Andrei Kozma is the President of the Academic Society of Anthropology. In 1990 he was proposed and accepted as member in the Anthropology Committee - Romanian Academy and

the Balkanic Medical Union. Since 1999 he became member of the European Committee of Anthropology and since 2007 he became the Scientific Director of the Anthropology Committee – Romanian Academy. He participates regularly at different scientific and cultural activities, having lectures in various subjects, including the social ones. He is Founder and active member in numerous scientific, cultural, social and charity associations. At present he provides dental care in his private dental practice and collaborates with the Romanian Academy.



**Professor**  
**TRAIAN MIHAESCU**  
DMD, MSc, PhD  
« Grigore T. Popa » UMPH Iasi



Professor Traian Mihaescu is the Head of the Ist Pneumology Clinic Iasi; his prestigious professional and scientific activity was awarded with important distinctions like: participation grant at the "XIII World Conference on Health Education", Houston, Texas, SUA – offered by United States Committee for Health Education, participation grant at the Mondial Congress of Immunology, Berlin – offered by the International Federation of Immunology Societies, specialization grant at the Hospital from Bologna, Italy, offered by the Italian Society of Pneumology or International Union Against Cancer ICRETT Award; he is Invited Speaker at the most important scientific meetings and conferences in his area of competence.



**Professor**  
**MEDA LAVINIA NEGRUTIU**  
DMD, MSc, PhD  
"Victor Babeş" UMPH Timișoara



Meda-Lavinia Negruti is professor at the "Victor Babeş" University of Medicine and Pharmacy Timișoara, Faculty of Dentistry, Prosthesis Technology and Dental Materials Department. Her research activities and competences are in the fields of dental materials and prostheses technology, alternative technologies in prosthodontics; imagistic investigations in dentistry – optical coherence tomography, structural adhesives for optical bonding; articulators; polymer injection technology; numeric simulation studies; soldering and welding technologies (plasma, laser); unconventional technologies of investigation, analysis, prognosis in dentistry. She was part of the research group that developed the first Time Domain Optical Coherence Tomography and the first Spectral Domain Optical Coherence Tomography Systems dedicated to dentistry in the east of Europe. She has 541 scientific works – 240 of them published (105 listed on the ISI Web of Science) and 301 oral communications at meetings in Romania and abroad. She is an author and coauthor at 21 monographies and 6 courses, co-author of one accorded (RO 121317 B1



/29.05.2009) and three in work OSIM patents. She is member in the research team of 11 grants - by 3 of them as project manager and 1 partner project responsible. She is member in the Management Comitee, representing Romania, of the FP7 COST Action MP 1005. According to Web of Science, the Hirsch index is 6. Sum of times cited articles, without self-citations is 55 and the number of Citing Articles without self-citations is 47. The address of the researcherid.com profile is: <http://www.researcherid.com/rid/B-6974-2008>.


She is Visiting Senior Lecturer in the School of Physical Sciences, University of Kent, Canterbury, UK. She is member of the Romanian Society of Biomaterials, West Romania Multidisciplinary Research Association, Romanian Society of Lasers in Dentistry, Romanian Society of Esthetic Dentistry, SPIE, OSA.



**Professor**  
**MARIANA PACURAR**  
DMD, MSc, PhD  
*UMPh Targu Mures*



Professor Mariana Pacurar is Dean of the Dental Medicine Faculty and Head of the Department of Pedodontics - Orthodontics, University of Medicine and Pharmacy Targu Mures and Head of the Pediatric Dentistry Clinic from Targu Mures. She teaches lectures, trainings and practical demonstrations for year IV, V and VI dentistry students and III year dental techniques students, being also diploma work coordinator (88 finalized). Since 2003, she also teaches lectures of Medical Management and the Methodology of the Scientific Research. She coordinated 2 grants, being author on 6 books published in orthodontics and general dentistry field and 89 articles published in international and national reviews. She is member in prestigious scientific and professional societies (ANRO - Romanian Orthodontic Association, International Association of Pediatric Dentistry, American Society of Orthodontics ADA, European Society of Orthodontics EOS and Pierre Fouchard Academy, Vice-president of the Romanian Association of Straight-wire, the Romanian National Association of Pediatric Dentistry (founding member) and Edgewise College, President of Discipline Committee - the Romanian Medical College.



**Associated Professor**  
**LUMINITA MARIA NICA**  
DMD, MSc, PhD  
*"Victor Babeş" UMPh Timișoara*



Dr. Luminita Maria Nica is Associate Professor at the „Victor Babeş" University of Medicine and Pharmacy Timișoara, Faculty of Dental Medicine and she is currently coordinating

the Discipline of Restorative Dentistry and Endodontics. She graduated the Faculty of Dentistry from Timisoara in 1994 and received her PhD in dental medicine in 2004. She holds a position of Senior (Medicus Primarius) of general dentistry and specialist of Endodontology at the Municipal Clinical Hospital, Timisoara. She has a clinical experience of almost 20 years in the fields of restorative dentistry, endodontics and dental microscopy. Dr. Nica coordinates the undergraduate students program for Endodontics for the 4th and 5th year of study and since 2012 she was named Coordinator for the postgraduate students training program in Endodontics. She published more than 50 papers, 12 in ISI refereed journals and conference proceedings, is the author or co-author of 17 monographies and books and has 22 citations. Her main research activities are in the fields of modern endodontics, optical microscopy, dental materials, adhesion to root canal dentin, dental microbiology, principles and applications of OCT in dentistry. She is Vicepresident of the Romanian Society of Dental Microscopy and Founder Member of the Romanian Society of Dental Sciences.



**Professor**  
**SANDA MIHAELA POPESCU**  
DMD, MSc, PhD  
*UMPh Craiova*



Dr. Sanda Mihaela Popescu is Professor at the University of Medicine and Pharmacy Craiova, the Chief of Discipline "Oral Rehabilitation and Medico-Surgical Emergencies" and the Chief of the 3<sup>rd</sup> Department, Faculty of Dental Medicine, UMPH Craiova. She obtained her PhD title in 2005, with the thesis "Researches regarding pharmacological interactions between the anti-HTA drugs and the local anesthetics used in stomatology". She is author or co-author of 6 books, 28 articles published in scientific journal from Romania and abroad (Oral Surgery Oral Medicine Oral Pathology Oral Radiology And Endodontology, Journal Of Pharmaceutical And Biomedical Analysis, Oral Health and Dental Management in the Black Sea Countries, Timisoara Medical Journal, Physiology, Craiova Medicală, Revista Societății Române de Alergologie și Imunologie Clinică) and more than 70 scientific papers published in abstract in journals or in the volumes of different scientific manifestations, national or international (Journal of Chemotherapy, Magnesium Research). She is member in a research grant in the area of dental implantology. She is the President of Romanian Society for Research in Dental Medicine and member of many national scientific societies (The Romanian Society of Oral Rehabilitation, The Romanian Association for Dental Education, The Romanian Society for Magnesium Research, The Romanian Society for the Chemotherapy Study, The Romanian Association of Algesiology) and professional associations (The Romanian National College of Dentists, the Association of Stomatologist Physicians with Private Practice from Romania).



**Professor  
GRIGORE TINICA**

DMD, MSc, PhD  
*UMPh Iasi*



Dr. Grigore Tinica is Manager and primary physician in cardiovascular surgery at the Cardiovascular Surgery Clinic, "Prof. Dr. George I.M. Georgescu" Institute of Cardiovascular Diseases and Professor at the discipline Cardiac Surgery, Faculty of Medicine, "Grigore T. Popa" University of Medicine and Pharmacy Iasi. His wide professional experience was awarded with prizes and distinctions; in 2007 he became Distinguished Professor of the Carolinas Heart Institute and Heineman Medical Research, NC, USA. He founded and developed a clinical section of cardiovascular surgery at Iasi, being also the author of the first intervention on open heart from Iasi, in 08<sup>th</sup> of May, 2000; he also introduced in Iasi more than 40 types of major cardiovascular surgical interventions; some of his methods of treatment were national premieres - the first experience in Romania of BioGlue using in cardiovascular surgery. He participated at the two first liver transplants from Romania (principal surgeon Professor Dr. Irinel Popescu). He has a wide research activity, being also the Head of the Excellence in Research Center, "George I.M. Georgescu" Regional Institute of Cardiovascular Diseases and Transplant (founded in 2006).



**Professor  
IRINA ZETU**

DMD, MSc, PhD  
*« Grigore T. Popa » UMPh Iasi*



Dr. Irina Zetu is Professor at the Orthodontics and Dento-facial Orthopedics discipline, Faculty of Dental Medicine, "Grigore T. Popa" University of Medicine and Pharmacy Iasi. She is author and co-author of 5 books and more than 70 scientific articles published in extenso or in abstract. She was lecturer at more than 20 postgraduate lectures and member in the Editorial Board of scientific journals (The Journal of Orthodontics and Dento-facial Orthopedics, Quintessence Romania and Romanian Journal of Stomatology); she is President of ARSW (Romanian Association of Straight-wire), Founder Member ANRO (National Romanian Association of Orthodontics), IAPD (International, Association of Pediatric Dentistry) and WFO (World Federation of Orthodontics) and member of EOS (European Orthodontic Society), AAO (American Association of Orthodontics) and SFODF (Societe France d' Orthopedie Dento Faciale); she coordinated 3 research projects.



**Associated Professor**  
**LILIANA POROJAN**

DMD, PhD

*"Victor Babes" UMPH Timisoara*



Dr. Liliana Porojan is Associated Professor at the Faculty of Dental Medicine, University of Medicine and Pharmacy "Victor Babes" Timisoara - in the Dental Technique specialization. She is also dental physician specialized in general stomatology, orthodontics and dento-facial orthopedics and dental prosthetics; she obtained her PhD title in 2004. She was Project Manager of 5 research projects win through national contest; she is author of 13 books and monographies, 10 textbooks, 140 scientific papers published in entenso, 160 scientific papers published in abstract and 211 papers communicated at scientific manifestations. Her scientific interests concern: the tri-dimensional reconstruction of dental structures and prosthetical restorations after laser scanning and CT, numerical simulations in the area of fixed, removable and composite prosthetics, static and thermic analysis and design optimizations, modern procedures for welding of dental alloys in environment with protective gas - laser and microplasma, modern technologies for the design and the achievement of partially removable and removable prostheses.



**Associated Professor**  
**COSMIN SINESCU**

DMD, MSc, PhD

*"Victor Babeş" UMPH Timișoara*



Cosmin Sinescu is associate professor at the Victor Babeş" University of Medicine and Pharmacy Timișoara, Faculty of Dentistry, Prostheses Technology and Dental Materials Department. The PhD thesis was focused on new methods of diagnostic and forcast in dentistry. Since 2005 he is a Visiting Senior Research Fellow in the Applied Optics Group at the University of Kent at Canterbury, UK. The address of the researcherid.com profile is: <http://www.researcherid.com/rid/G-1528-2011>. His main research interests include invasive and noninvasive, destructive and nondestructive methods of investigations in dentistry, dental materials, bioengineering, biocompatibility, optoelectronics. He participated as part of the research team of the Propedeutics and Dental Materials Department in achieving, in collaboration with our partner from UK, the First OCT Prototypes, Time Domain and Spectral Domain with applications dedicated to Dental Medicine in Romania. Also, he contributed, with the imagistic group, in achieving the First Two Handpieces Samples dedicated to the Spectral Domain OCT system, for Dental Medicine use. OCT applications in Dental Medicine developed by our imagistic group until now included: Non-invasive flaw detection in metallic-ceramic, metallic-polymeric, full ceramic and full polymeric dental prosthetics studies; Non-invasive evaluation of root canal treatments sealing;

Non-invasive evaluation of marginal adaptation of dental prosthesis (in vitro si in vivo); Orthodontics non-invasive studies; Occlusion non-invasive studies; Implantology non-invasive studies; Non-invasive evaluation of the soft tissue in the maxillo-facial area. He was member in the research team of 11 projects - in 4 of them as PI. He is member in the working group of the FP7 COST Action MP 1005. He is co-author of three in work OSIM patents, published 79 papers in ISI refereed journals and conference proceedings. He is also a member of several dedicated association like SRLS, SSB, IADR, IEEE, SRB and SPIE.



**Assoc. Professor**  
**ELINA TEODORESCU**

DMD, MSc, PhD  
*"Carol Davila" UMPH Bucharest*



Elina Teodorescu, MD, Ph.D. is Associate Professor at the Department of Orthodontics and Dento-Facial Orthopedics of the Faculty of Dental Medicine, "Carol Davila" University of Medicine and Pharmacy, Bucharest since 2012. She became senior doctor in Orthodontics and Dento-Facial in 2002, with PhD in the same field in 2004. In 2003 she also became senior doctor in Advanced Dentistry and Oral Sciences. During the last 19 years she has doing research in Anthropology and Fundamental Sciences, Dento-Facial Orthopedics as well. Dr. Teodorescu published several books and many research articles in the field of orthodontics, human anthropometry and oral sciences. She is also member of the editorial board for prestigious Romanian journals. During her professional activity, Dr. Teodorescu presented numerous lectures and conferences at national and international scientific meetings.



**Lecturer**  
**SMARANDA DIACONESCU**

DMD, MSc, PhD  
*"Grigore T. Popa" UMPH Iasi*



Dr. Smaranda Diaconescu is Lecturer at the Pediatrics Department, Faculty of Medicine, University of Medicine and Pharmacy « Grigore T. Popa » from Iasi, being also primary physician in Pediatrics; she obtained her PhD title in 2005; she has also an over-specialization in Pediatric Gastroenterology (2004, "Carol Davila" UMPH Bucharest) and attestates in Pediatric Digestive Endoscopy (2004, UMPH Cluj) and general ultrasonography (2002, UMPH Bucharest). She is author of 3 books, 4 book chapters, 59 scientific papers published in extensor, 29 scientific papers published in abstract and 40 communicated scientific papers. She is member of the Romanian Society of Pediatrics, the Society of Physicians and Naturalists Iasi and the National Union of Stomatological Associations from Romania.

**Lecturer**  
**HORIA OCTAVIAN MANOLEA**  
 DMD, MSc, PhD  
*UMPh Craiova*



Dr. Horia Octavian Manolea was born in 1977 in Craiova and he graduated the Faculty of Dental Medicine, University of Medicine and Pharmacy Craiova in 2001. In 2007 he completed the doctoral courses under the guidance of Professor Emeritus Dr. Florin Bogdan. In present Dr. Horia Octavian Manolea is lecturer in the Prosthetic Technology department of Faculty of Dental Medicine, University of Medicine and Pharmacy in Craiova owning competencies in general dentistry, dental tissues morphology and prosthetic restorations with implant abutment. Dr. Horia Octavian Manolea is member in four recognized professional organizations: Romanian Society of Morphology, Romanian Society of Biomaterials, Romanian Society for Research in Dental Medicine. Since 2014 he is lecturer or Romanian National College of Dentists and the author of the book "Dental materials utilized in the technology of dental prostheses" - Ed. Medicală Universitară Craiova, 2009. He was also member in the Review Committee of the 25-th Symposium and Annual Meeting of the International Society for Ceramics in Medicine (BioCeramics 25), Bucharest, Romania, November 07-10th, 2013.



**Lecturer**  
**VASILE VALERIU LUPU**  
 DMD, MSc, PhD  
 « Grigore T. Popa » *UMPh Iasi*



Dr. Vasile Valeriu Lupu is specialist in Pediatrics and Lecturer at the Pediatric Discipline, Faculty of Medicine, "Grigore T. Popa" University of Medicine and Pharmacy Iasi; he obtained his PhD degree in 2011 and he has Attestates in Complementary Studies of Pediatric Gastroenterology (since 2012) and Pediatric Diagnostic Digestive Endoscopy (since 2010); he has competences in General Echography (since 2005). Dr. Lupu is member of the Romanian Society of Medical Genetics, Society of Gastroenterology and Pediatric Hepatology, European Pediatrics Association (since 2011), being also the general secretary of the Romanian Society of Pediatrics (since 2009). He is author of 158 scientific papers communicated at scientific congresses and conferences and 77 articles published in extenso; for his scientific activity he was granted with 2 prizes.



**Professor  
ION LUPAN**

DMD, MSc, PhD

*“Nicolae Testemitanu” USMF Chisinau*



Born in January 19<sup>th</sup>, 1952 in Republic of Moldavia, Professor Ion Lupan graduated the State Institute of Medicine from Chisinau in 1975; starting 1983, he organized the Maxillo-Facial Surgery Department in the Republican Clinic Hospital for Children “E. Cotaga”, where he worked as physician and Department head; since 2007 he became Chief of Department Pediatric Oro-Maxillo-Surgery Surgery, Pedodontics and Orthodontics at the State University of Medicine and Pharmacy “Nicolae Testemițanu”, Chisinau. In 1993 he obtained his PhD title and in 2004 he obtained his habilitation in medicine with the thesis “Medical recovery of children with facial congenital malformations”. He published more than 140 scientific papers, being also author and co-author at 9 innovation patents.

He is the Elect President of the Stomatologists Association from Republic of Moldavia and of the Cranio-Maxillo-Facial Surgeons Association from Republic of Moldavia; he is member of the Cranio-Maxillo-Facial Surgeons Association from Europe and the Stomatologists Association from Europe. He is founder and Redactor in Chief of the Stomatological Medicine Journal and member in the redactional committee of the Orthodontics Journal (Romania) and “Curierul medical” (Moldavia). Since 2009 he is the Dean of Faculty of Medical Dentistry, State University of Medicine and Pharmacy “Nicolae Testemițanu”, Chisinau; in 2008 he was elected as member of the Science Academy, Republic of Moldavia, and for special merits he was decorated with the „Nicolae Testemițanu” medal.



**Associated Professor  
OLEG SOLOMON**

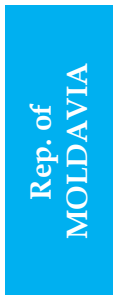DMD, MSc, PhD

*“Nicolae Testemitanu” USMF Chisinau*



Associate Professor Oleg Solomon was born 8<sup>th</sup> May, 1969 in Cotiujenii Mari village, Florești District, Republic of Moldova. He graduated in 1995 the Stomatology Faculty of Moldova State Medicine University “N. Testemițanu”. For seven years (1995-2002) he was associated professor at the Free International University in Chișinău, at the Prosthodontic and Orthodontic Department. In 1998 he became specialist in Orthodontics at the Medicine and Pharmacy University, Iași, România and in 2002 he obtain the second specialization in Orthodocny Fixed Technique, Medicine University, Poltava, Ukraine. Since 2002 he is associated professor at the Moldova State Medicine University, Pediatric Dentistry. Between 2003-2007 he was the Vice-chairman of Moldavian Association of Stomatologists and since 2006 he is member of World

Federation of Orthodontics. In 2003 and 2006 he carried out scientific internship in orthodontics laboratoire and department at The University of North Carolina at Chapel Hill. He published more than 25 articles in specialized journals and he participated into more than 20 scientific congresses. He took part in the USA volunteer programme as lecturer from the Dentistry Department, Moldova State Medicine University "N. Testemițanu" and also he have organized a computerized simulation room for studies in the classes where Orthodontic is taught.



**Assoc. Professor  
AURELIA SPINEI**

DMD, MSc, PhD

*"Nicolae Testemitanu" USMF Chisinau*



Dr. Aurelia Spinei graduated in 1989 the Faculty of Dentistry, State University of Medicine and Pharmacy "Nicolae Testemitanu"; between 1989-1991 she carried out Clinical internship at the Department of Paediatric Dentistry, State University of Medicine and Pharmacy "Nicolae Testemitanu", specialty of Pediatric Dentistry; in 2001 she obtained her PhD thesis in Medical Sciences with the subject "Aspects of prevention of dental caries in children" and between 2011-2013 she carried out post-doctoral studies at the State University of Medicine and Pharmacy "Nicolae Testemitanu". Since 2002 to present she is Associated Professor, Department of Pediatric OMF Surgery, Orthodontics and Pedodontics, State University of Medicine and Pharmacy "Nicolae Testemitanu", and since 2003 she is also the Chief of preventology course within the Department of Pediatric OMF Surgery, Orthodontics and Pedodontics. Her areas of scientific interest concern the prevention of periodontal - dental diseases in children and the dental care for children with disabilities. Dr. Aurelia Spinei is author of 4 textbooks, 2 books, 94 articles, 22 materials of scientific communications, 9 patents and 15 innovation patents. In 2000 she was the winner of the Youth Prize in Science and Technology and in 2013 she win the Best Poster Prize at the 4-th IEEE International Conference on E-Health and Bioengineering - „EHB 2013”. She is member in many international and national scientific associations, societies (the Association of Dentists in the Republic of Moldova, the European Association of Dental Public Health), she has activities within the editorial board of the scientific journals (Magazine of Oral Health and Dental Management in the Black Sea Countries, Romania, Constanta, Romanian Journal of Dental Medicine, edited by UNAS, Romania); she participated in national and international scientific projects (1997-2007 - Co-author and coordinator of the "National Program of Oral Health of Children in the Republic of Moldova", 2005-2007 - Participant in project "Prevention of dental caries in children in boarding schools and orphanages in the Republic of Moldova" with financial support of the US Armed Forces, 2012-2014- Coordinator of Oral Health Programme for children with disabilities and special educational needs, 2012-2014- BECO - 2012 - No - U - 561 35FT103 AUF, Bureau of Central and Eastern Europe, "Projet de formation a la recherche 2012-2014", regional coordinator).





**Assoc. Professor  
DIANA UNCUTA**  
DMD, MSc, PhD  
*"Nicolae Testemitanu" USMF Chisinau*



Dr. Diana Uncuta obtained her DSM title in December 2003, in the specialty Oral Pathology - General Dentistry, and her PhD title in September 2000, in the specialty General Dentistry; she also obtained her DHMS title in September 2014, in the specialty Oral Pathology - Pediatric Dentistry, all of these at the State University of Medicine and Pharmacy "Nicolae Testemitanu", Chisinau. She is certified general dentist and prosthodontist (since 2009). Since 2007 she became Associated Professor at the Department of Pediatric Oral and Maxillofacial Surgery, Pedodontics and Orthodontics, State University of Medicine and Pharmacy "Nicolae Testemitanu". Since 2010 she became also Adjunct Assistant Professor, Department of Dental Ecology, School of Dentistry, University of North Carolina at Chapel Hill. Since 2005 she is owner of General Dentistry Private Practice "Dia Dent", Chisinau, Republic of Moldavia. She is the owner of more than 20 honors and awards, the newest being Gold Medal, National Institute of Inventics "Inventica 2014", Romania, Gold Medal, European Exhibition of Creativity and Innovation, "EUROINVENT", Romania (2014), Silver Medal, Romanian Inventors Forum, Romania (2013), Gold Medal, International Specialized Exhibition "INFOINVENT", Republic of Moldova (2013), Gold Medal, European Exhibition of Creativity and Innovation "EUROINVENT", Romania (2012), Gold Medal, International Exhibition of Inventions "Pro Invent", Romania (2012), Special Award, European Exhibition of Creativity and Innovation "EUROINVENT", Romania (2012).



**Dr  
LUCA ARDUINI**  
DMD MSc PhD



Dr. Luca Arduini graduated in Dentistry at the University of "La Sapienza" of Rome (in 2006); he obtained Master's Degree with honors in endodontics, having a wide experience in the field of endodontic (2008, University of "La Sapienza" of Rome). In 2007 he obtained a specialization in Intraosseus implantology and oral implants; he attended also postgraduate lectures in different fields, like Bone deficiency (2007, Professor GB Bruschi - Rome), Implantology (2008, Professor Covani - University of Pisa) and Gnatology (2008, Professor Molina - Rome). Since 2008 he is member of ANDI - Italy. Among his professional partnerships we can mention Sweden & Martina - Padova, Italian Tutor for scientific research holding courses on Implantology (2015), Meta Ergonomica (2014 - 2015) and O.L. for European markets - Holding courses and lectures on Magnetic Mallet technique.

Dr. Arduini has deep knowledge in all the processing techniques of root canals (bore) with manual instrumentation at the beginning replaced by rotary instrumentation (Tools Ni-Ti taper

changed), as well as in the Bore Technical with two M-changed in the sequence of operation, the irrigation canal activated by ultrasonic in case of sclerotic dentin and in the techniques radicular with warm vertical condensation through continuous wave (System B) and filling thermoplastic injection (Pistol Obtura), or with mechanical technique of thermo mechanical compaction multiphase with Microseal. He has extensive experience in the retreatment of endodontic failures, even with the presence of metal pins or pins endodontic molten gold, thanks to the aid of precision instruments such as the electron microscope.

He is the creator of a new technique for endodontic root canal reaming and closing (TA) tested on 1,500 patients last year with excellent clinical results. He is also Expert in implant surgery especially with the use of regenerative techniques and expansive (ERE) partial thickness technique with outstanding results in the expansion of the edentulous ridge with a vertical displacement of the floor of the maxillary sinus.



**Dr**  
**CLAUDIO ALBI**  
DMD  
*Valtech, MODUS Group*



Dr. Claudio Albi is founder and CEO of Valtech, MODUS Group. With over 20 years of experience in the dentistry field thanks to the acquired competencies in odontology, medical surgery and engineering besides some researches in medical robotics , he deposits two international patents on guided dental surgery. Partner of prestigious italian and international Universities , he is a speaker and R&D consultant for companies and corporations in the dental implant business sector.



**Dr**  
**PIETRO ALBI**  
DMD  
*Valtech, MODUS Group*



Dr. Pietro Albi, R&D manager in Valtech, MODUS Group, has a degree in medical biotechnology and experience in odontology, medical surgery and engineering, microbiology, R&D of devices in medical robotics. He is software developer in Valtech.



**Clinical Professor**  
**CHEOL WOONG JEONG**

DMD, PhD

*Chonnam National University, School of Dentistry*

*Director of Gwangju Mir Dental Hospital, Korea*

*CEO of KUWOTECH*



Dr. Cheol Woong Jeong graduated the Chonnam Dental University, specialization in Periodontics; he obtained his PhD title and he became later Clinical Professor at the same university. He is Academic Director in Korea Academy of Periodontology and Periodontology and Implant seminar Director of MINEC; between 2005 - 2006 he was visiting scholar at UCLA, School of Dentistry. He is also Director of the International Centric-guide Academy (ICA), Director of Gwangju Mir Dental Hospital, Korea and CEO of KUWOTECH.

Dr. Jeong is author of three books and lecturer of many courses and conferences, like:

- Seoul International Dental Exhibition (SIDEX), "Occlusal Therapy in the Advanced Periodontal Disease" (2014)
- Korean Society for Biomaterials, "Long term results of the regenerative therapy in the Peri-implant Disease" (2014)
- Renew Medical & Denstply Symposium, "Long term results of the regenerative therapy in the Peri-implant Disease" (2013)
- Megagen international Symposium in Bangkok, "Clinical Usage of Centric Guide System" (2013)
- Myanmar society dentist, "Periodontal & Implant Therapy in Advanced Periodontal Disease" and "Zirconia Prosthesis in Implant (CAD/CAM)" (2013)
- Institute for Dental Implant, "Peri-implant Disease" (2013)
- Dalian Medical University (in China), "Periodontal & Implant Therapy in Advanced Periodontal Disease" and "Zirconia Prosthesis in Implant (CAD/CAM)" (2012)
- Periodontal Science Conference, "Peri-implant Disease" (2012)
- General dentists central region Social Conference "Periodontal & Implant Therapy in Advanced Periodontal Disease" (2012)
- General dentists society, Gyeonggi Conference, "Periodontal & Implant Therapy in Advanced Periodontal Disease" (2012)
- China Yantai dentist society, "Periodontal & Implant Therapy in Advanced Periodontal Disease" (2012)
- Implant Research in Gwangju Jeonnam, "Periodontal & Implant Therapy in Advanced Periodontal Disease" (2012)
- Implant Research in Jeonbuk, "Peri-implant Disease" (2012)
- Yonsei Implant Research, "Peri-implant Disease" (2012)
- Chengdu (in China) dentist Society Invited Lecture, "Zirconia Prosthesis in Implant(CAD/CAM)" "Short Implant" (2012)
- MINEC General Conference, "Peri-implant Disease" (2012)
- Conference on Oral and Maxillofacial Implants, "Peri-implant Disease" (2012)
- Korea Implant Conference, "Peri-implant Disease" (2012, 2011)
- Dentists in Taiwan society, " Zirconia Prosthesis in Implant (CAD/CAM)" (2011)

# SCIENTIFIC PROGRAM

## PRECONGRESS

**MONDAY, APRIL 20th, 2015**

*IAȘI, Clinical Base of Dental Education - A3 Amphitheater*

**08:30** **LECTURE – IMPLANTOLOGY:**  
**11:30** **PROBLEMS AND SOLUTIONS IN IMPLANT SURGERY**

**8 EMC**

**SPEAKERS:**

NORINA FORNA - *Romania*

STILIANOS DALAMPIRAS - *Greece*

### LECTURE ABSTRACT

#### PROBLEMS AND SOLUTIONS IN IMPLANT SURGERY

NORINA FORNA, STYLIANOS DALAMPIRAS

*Romania - Greece*

The expanded use of implants all over the world, with millions of patients and analogous number of implantologists, has the natural inclination of human mistakes and a percentage of postoperative lesions or problems that are very difficult to record and evaluate, because: 1.The patients are accustomed to tolerate situations even not totally correct, if they don't suffer from intense symptoms and 2.The problem is only detectable in a radiographic examination, performed mostly for a routine dental consultation. The author of this presentation deals with a variety of cases of implantology and tries to respond to the question, of "what to do" and how to treat such cases. There are cases of mistakes and failures that are very useful for a scientific discussion. The most interesting part of this lecture is the diagnostic part and the importance of the modern imaging technologies to achieve a correct diagnosis. Many kinds of treatments are in the hands of the oral surgeons and the dental practitioners, some conservative and some radical. A discussion at the end of the presentation is always very fruitful.

## TUESDAY, APRIL 21st, 2015

IAȘI, Clinical Base of Dental Education – A3 Amphitheater

09:30  
11:30

**LECTURE – RESTORATIVE AND ADHESIVE DENTISTRY:  
THE CLINICAL AND THERAPEUTIC MANAGEMENT OF DENTAL EROSION**

8 EMC

**SPEAKER:**

SORIN ANDRIAN - Romania

### SPEAKER'S SHORT PRESENTATION

ROMANIA



**Professor**  
**SORIN ANDRIAN**  
DMD, MSc, PhD  
« Grigore T. Popa » UMPH Iasi



Doctor Sorin Andrian is professor at Cariology and Operative Dentistry subject matter, Faculty of Dental Medicine, University of Medicine and Pharmacy “Gr.T. Popa”, Iași and he is doctorates manager. He was head of the Departement of Odontology and Periodontology and he was also deputy dean of the faculty. He had a Master Degree in Medical Management and he was the manager of postgraduate master in Odontology. He is also deputy editor of Journal of Roumanian Medical Dentistry and member in editorial board of Roumanian Journal of Oral Rehabilitation. He participated at ORCA and ADEE meeting in Berlin for developing the European Core Curriculum in Cariology. He is also member of University Ethical Committee and he is president of the Deontologic Committee in the Regional General Dental Council.

### LECTURE ABSTRACT

#### THE CLINICAL AND THERAPEUTIC MANAGEMENT OF DENTAL EROSION

SORIN ANDRIAN

Romania

Dental erosion is defined as a progressive irreversible loss of dental hard tissues by a chemical process (acid and/or chelation exposure) that does not involve bacteria. Dental erosion is a prevalent condition that occurs worldwide and there are some evidence that the presence of dental erosion is growing steadily. This condition does not begin as a subsurface enamel lesion that is conducive to remineralization, as in the caries process, but rather as a surface softening lesion that is susceptible to wear and resistant to remineralization by conventional therapies. Dental erosion results in tooth surface softening, which inevitably accelerates tissue loss caused by tooth-to-tooth contact while chewing and grinding (attrition) or by abrasive wear while mechanically

brushing or cleaning tooth surfaces (abrasion). Dental erosion is a multifactorial condition. To prevent further progression, it is important to detect this condition as early as possible. It is fundamental to diagnose the possible risk factors such that preventive measures can be initiated. This overview is aimed to give some basic aspects about the diagnosis and the risk factors of erosion. If it is not managed through effective interventions, it may result in substantial loss of enamel and subsequent exposure of the underlying dentin, which can, in turn, lead to dentin sensitivity, loss of vertical height and esthetic problems. Dentists have to know the clinical appearance and possible signs of progression of erosive lesions and their causes such that adequate preventive and, if necessary, therapeutic measures can be initiated. The clinical examination has to be done systematically, and a comprehensive case history should be undertaken such that all risk factors will be revealed. Effective management of dental erosion is largely dependent on a thorough understanding of its etiology and early recognition of its signs and symptoms in clinical practice.

### IAȘI, Clinical Base of Dental Education - Simulating lab, Prosthesis Technology lab 1

09:00 18:00	<p><b>HANDS-ON</b>  <b>„Aesthetic restoration in specific pathology of frontal teeth using wax-up technique”</b></p> <p><b>Theoretical and practical coordinators:</b>  <b>Module I.</b> Professor Dr. MONICA TATARCIUC,  Prosthesis Technology, Faculty of Dental Medicine, UMPH „Grigore T. Popa” Iași</p> <p><b>Module II.</b> Lecturer Dr. SIMONA STOLERIU,  Assistant Professor Dr. IRINA NICA,  Cariology and Restorative Dentistry, Faculty of Dental Medicine,  UMPh „Grigore T. Popa” Iași</p>	<b>8 EMC</b>
<p><b>1<sup>st</sup> Module. Prosthesis Technology lab 1</b>  Participants: 20 dental technicians students (2<sup>nd</sup> – 3<sup>rd</sup> year of study)</p>		
09:00 09:15 09:15 10:00 10:00 10:15 10:15 11:50 11:50 12:00	<p>Presentation of the participants and of the theoretical and practical coordinators</p> <p>Theoretical presentation of restoration the morphology of frontal teeth having diastema using indirect wax-up technique followed by a direct layering application of aesthetic composite resin</p> <p><i>Coffee break</i></p> <p>Practical session consisting of restoring the morphology of maxillary central incisors having diastema on models</p> <p>Evaluation of theoretical and practical concepts</p>	
<p><b>2<sup>nd</sup> Module. Simulating lab, 1st floor</b>  Participants: 20 Dental Medicine students (4<sup>th</sup> - 6<sup>th</sup> year of study)</p>		
14:00 14:15 14:15 15:15 15:15 15:30 15:30 17:50 17:50 18:00	<p>Presentation of the participants and of the theoretical and practical coordinators</p> <p>Theoretical presentation of indirect wax-up technique followed by a direct layering application of aesthetic composite resin on frontal teeth having diastema</p> <p><i>Coffee break</i></p> <p>Practical session consisting of diastema closure on models, using wax-up technique and Filtek Ultimate (3M ESPE) aesthetic composite resin.</p> <p>Evaluation of theoretical and practical concepts</p>	

ROMANIA



**Professor**  
**MONICA SILVIA TATARCIUC**  
DMD MSc PhD  
*"Grigore T. Popa" UMPH Iasi*



Professor Monica Tatarciuc graduated the Faculty of Stomatology within the Institute of Medicine and Pharmacy "Grigore T. Popa" Iași (1985); she is Board Certified Physician in the speciality "General Stomatology" (from 1991 to present) and Prosthetic dentistry (from 2011); her PhD theme was „Bioengineering in orthodontic treatments”(1999); she followed 28 post-graduate training and research courses. Dr. Tatarciuc is Professor at the discipline of Dental Technology, Faculty of Dental Medicine, University of Medicine and Pharmacy "Grigore T. Popa" Iași. Her main research field is Prosthetic Dentistry; she is author of 5 articles published in ISI journals, 55 articles published in journals indexed for international data bases and 35 articles published in other Romanian journals; she is member in 20 organization comities of national and international congresses, member in the research team of 2 national research projects and member in 3 educational projects.

ROMANIA



**Lecturer**  
**SIMONA STOLERIU**  
DMD MSc PhD  
*"Grigore T. Popa" UMPH Iasi*



Dr. Simona Stoleriu graduated the Faculty of Stomatology within the Institute of Medicine and Pharmacy "Grigore T. Popa" Iași (1997); she is Board Certified Physician in the speciality "General Stomatology" (from 2006 to present); she obtained her PhD title in 2009, with the research theme „Clinical and paraclinical aspects of the carious lesions evolution on fluorotic teeth" and she followed 10 post-graduate training and research courses. Dr. Stoleriu is Lecturer at the discipline of Cariology and Restorative Dentistry, Faculty of Dental Medicine, University of Medicine and Pharmacy "Grigore T. Popa" Iași; her main research field is Restorative Dentistry; she is author of 15 articles published in ISI journals, 28 articles published in journals indexed for international data bases and 29 articles published in other Romanian journals; she is member in 10 organization comities of national and international congresses, member in the research team of 2 national research projects and member in 3 educational projects.

**Assistant Professor  
IRINA NICA**

DMD MSc PhD

*"Grigore T. Popa" UMPH Iasi*

Dr. Irina Nica graduated the Faculty of Stomatology within the Institute of Medicine and Pharmacy "Gr. T. Popa" Iași (2001); she is Board Certified Physician in the speciality "General Stomatology" (from 2005-to present); she obtained in 2012 her PhD title with the research theme "Theoretical and experimental contributions to nanomaterials usage in dental medicine"; she followed 5 post-graduate training and research courses. Dr. Nica is Assistant Professor at the Discipline of Cariology and Restorative Dentistry, Faculty of Dental Medicine, University of Medicine and Pharmacy "Gr. T. Popa" Iași (from 2013 to present); her main research field is Restorative Dentistry; she is author of 5 articles published in ISI journals, 2 articles published in journals indexed for international data bases and 2 articles published in other Romanian journals.

---

**HANDS-ON ABSTRACT****AESTHETIC RESTORATION IN SPECIFIC PATHOLOGY OF FRONTAL TEETH USING WAX-UP TECHNIQUE**

MONICA TATARCIUC, SIMONA STOLERIU, IRINA NICA

*Romania*

The increasing demand of the patients for aesthetic restorations has motivated dental practitioners to achieve natural and mimetic results by using materials as composite resins. A successful aesthetic restoration is in relation with a lot of factors. Reproduction of natural tooth appearance is directly and strongly linked to the tooth color and morphology matching. In some clinical situations changes in dental morphology are needed to obtain the desired results. An indirect wax-up technique followed by a direct layering application of aesthetic composite resin could be the best option in closing diastema or in changing the volume or shape of frontal teeth. Getting good technical skills in the lab and a great expertise on restoration techniques have an important role in reproduction the frontal teeth shape, aspect and morphology, with no detail missing. During this theoretical and practical course the dental technicians students and dental medicine students will be trained in rebuilding dental morphology of frontal teeth by using wax-up technique and in obtaining a proper chromaticity of the tooth by a correct stratification of composite resins in case of diastema.



09:00 **The XVth Edition of INTERNATIONAL SYMPOSIUM**

12:30 **“Romanian Medical Press”**

**Organizer:** The Discipline of Modern Languages, Faculty of Dental Medicine  
“Grigore T. Popa” University of Medicine and Pharmacy Iasi

**Organizing Committee:**

- Prof. Dr. MARIANA FLAISER - Romania
- Assoc. Prof. Dr. LAURA IOANA LEON - Romania

## THURSDAY, APRIL 23rd, 2015

INTERCONTINENTAL HOTEL, RHONDA HALL

09:00

11:00

**ORAL IMPLANTOLOGY, LASER – PLENARY LECTURE and Oral presentations:**

Chairmen: Prof. Dr. ANA MINOVSKA  
Prof. Dr. STYLIANOS DALAMPIRAS  
Prof. Dr. LJUBOMIR TODOROVICI  
Secretary: Assist. Dr. DORIANA AGOP FORNA

**ORAL IMPLANTOLOGY – PLENARY LECTURE:**

L 615 **BIO LOGIC IMPLANT ESTHETIC CONCEPT**

KADHIM AL HIMDANI

France

**ORAL IMPLANTOLOGY, LASER - Oral presentations:**

1/ **WOUND HEALING AFTER ER:YAG LASER ASSISTED POCKET DEBRIDEMENT**

OP 502 Ana Minovska; Daniela C.Stojceva; Ana Bundalevska; Bruno Nikolovski  
FYROM

2/ **COMPLICATIONS OF IMPLANT SUPPORTED PROSTHESIS: CLINICAL APPROACH**

OP 2 Maria Malliarj; Maria Kelesi; Eleana Kontonasaki  
Greece

3/ **RETROSPECTIVE AND PROSPECTIVE STUDY ON LASER APPLICATIONS IN DENTISTRY**

OP 586 Norina Forna; Doriana Agop-Forna  
Romania

4/ **CURRENT CHALLENGES IN SURGICAL LASERS USED IN DENTO-ALVEOLAR SURGERY**

OP 587 Doriana Agop-Forna; Eugenia Popescu  
Romania

5/ **PERIPHERAL GIANT CELL GRANULOMA ASSOCIATED WITH DENTAL IMPLANTS. A CLINICAL CASE AND LITERATURE REVIEW**

OP 80 Georgia Barka; Eleni Eirinaki; Sotiria Gkampesi; Theodoros Lillis  
Greece

6/ **EFFICIENCY OF PHOTODYNAMIC THERAPY IN THE TREATMENT OF PERI-IMPLANTITIS. A RANDOMIZED CONTROLLED CLINICAL TRIAL**

Dragana Rakasevic; Bojan Rakonjac; Zoran Lazic; Zoran Aleksic

*Serbia*

- 7/  
OP 383 **HEAT TRANSFER TO THE IMPLANT-BONE INTERFACE DURING REMOVAL OF METAL COPINGS CEMENTED ONTO TITANIUM ABUTMENTS**  
Umut Cakan; Murat Cakan; Cagri Delilbasi  
*Turkey*
- 8/  
OP 460 **FIXED PROSTHETIC IMPLANT RESTORATION AND ITS EVOLUTION ON EDENTULOUS PATIENTS.SERIAL CASES**  
Marina Melescanu Imre; Ana Maria Tancu; Cristina Teodora Preoteasa; Elena Preoteasa  
*Romania*
- 9/  
OP 189 **HISTOMORPHOMETRIC EVALUATION OF THE EFFECTS OF VARIOUS DIODE LASERS AND FORCE LEVELS ON ORTHODONTIC MINISCREWS**  
Merve Goymen; Eren Isman; Lale Taner; Mehmet Kurkcü  
*Turkey*
- 10/  
OP 120 **GINGIVECTOMY: ER:YAG LASER CASE REPORT, ONE YEAR FOLLOW-UP**  
Seda Sevinc Ozberk; Caglar Korcuk; Hasan Gundogar; Kamile Erciyas  
*Turkey*
- 11/  
OP 207 **SAFETY OF THE USE OF ER,CR:YSGG LASER ON ENAMEL SURFACE DURING IN-OFFICE TOOTH BLEACHING**  
Dimitrios Dionysopoulos; Dimitrios Strakas; Eugenia Koliniotou-Koumpia  
*Greece*
- 12/  
OP 394 **USAGE OF DIODE LASER IN DENTISTRY : CASE REPORT SERIES**  
Kemal Korucuoğlu; Çağlar Körcük; Mehmet İşiker; Asli Seçilmiş  
*Turkey*
- 13/  
OP 537 **LASER THERAPY A NEW ERA IN DENTISTRY**  
Ioana Roxana Bordea; Ondine Lucaciu; Bogdan Crisan; Mihaela Baciut; Radu Septimiu Campian  
*Romania*
- 14/  
OP 557 **THE PREDICTABILITY OF IMPLANT-PROSTHETIC THERAPY; SURGICAL PRE-IMPLANTARY PROCEDURES**  
Calin Alexandru; Tataru Calin; Bartok Francisc; Doriana Agop Fornă  
*Romania*

**11:00**  
**11:15** Coffee break

**11:15**  
**13:15** **ORAL RADIOLOGY - PLENARY LECTURES:**

Moderators: Prof. Dr. ATTILA BERBEROĞLU  
Prof. Dr. MEDA LAVINIA NEGRUTIU

L 594 **INTERPRETATION OF PERIODONTAL AND PERIAPICAL LESIONS USING CONE BEAM COMPUTED TOMOGRAPHY (CBCT)**

ATTILA BERBEROĞLU  
*Cyprus*

L 142 **APPLICATION OF THE OCT TECHNOLOGY IN DENTISTRY**

MEDA LAVINIA NEGRUTIU  
*Romania*

L 150 **APPLICATION OF THE MICROCOMPUTER TOMOGRAPHY (MICRO CT) TECHNOLOGY IN DENTISTRY**

COSMIN SINESCU  
*Romania*

L 610 **RADIOGRAPHIC APPEARANCES OF SYSTEMIC DISEASES IN DENTO-MAXILLOFACIAL AREA**

KAAN ORHAN  
*Turkey*

**13:15**  
**15:00** Lunch break

<b>15:00</b>	<b>INTERDISCIPLINARITY IN DENTAL MEDICINE - I - PLENARY LECTURES:</b>
<b>16:45</b>	
	Moderator: Prof. Dr. ECATERINA IONESCU Prof. Dr. ADY PALTU
L 607	<b>THE ROLE OF THE FIRST PERMANENT MOLAR IN THE CONTEXT OF THE DYNAMICS OF THE DENTO-MAXILLARY SYSTEM</b> ECATERINA IONESCU, EILINA TEODORESCU <i>Romania</i>
L 605	<b>MINIMALLY INVASIVE VERSUS CLASSIC PROCEDURES IN OBSTRUCTIVE SALIVARY GLAND DISEASE</b> ALEXANDRU BUCUR <i>Romania</i>
L 620	<b>SINUS FLOOR ELEVATIONS (TECHNIQUES AND COMPLICATIONS)</b> ADY PALTU <i>Germany</i>
	<b>IATROGEN PATHOLOGY</b> STEFAN OCTAVIAN GEORGESCU <i>Romania</i>
L 613	<b>APPLICATION OF THE DIGITAL TECHNOLOGIES IN ORAL REHABILITATION. GUIDED SURGERY, PATIENT SPECIFIC IMPLANTS FOR BONE RECONSTRUCTION, GUIDED CORTICOTOMY</b> CLAUDIO ALBI <i>Italy</i>
<b>16:45</b>	<b>Coffee break</b>
<b>17:00</b>	

<b>17:00</b>	<b>OPENING CEREMONY – RHONDA HALL</b>
<b>18:00</b>	
<b>20:00</b>	

*INTERCONTINENTAL HOTEL, RAPSODIA HALL*

<b>09:00</b>	<b>REMOVABLE PROSTHODONTICS – LECTURE and Oral Presentations:</b>
<b>11:00</b>	
	Chairmen: Prof. Dr. ANDON FILCHEV Dr. DONKA STANCHEVA ZABUTOVA Prof. Dr. VERONICA MERCUT Secretary: Lecturer Dr. DAN NICOLAE BOSANCEANU
	<b>REMOVABLE PROSTHODONTICS – LECTURE:</b>
L 592	<b>MANAGEMENT OF DEFICIENT RIDGES: THE CASE REVIEW</b> <u>MUHAMED AJANOVIC</u> <i>Bosnia and Herzegovina</i>
	<b>REMOVABLE PROSTHODONTICS – Oral Presentations:</b>
1/ OP 15	<b>RISK FACTORS AND ORAL COMPLICATIONS IN DENTURE WEARERS WITH TYPE 2 DIABETES</b> <u>Katarina Radovic</u> ; Aleksandra Cairovic; Dragica Stojic; Jelena Roganovic; Dragoslav Stamenkovic <i>Serbia</i>
2/ OP 285	<b>ASPECTS OF INTERMAXILLARY RELATIONSHIPS REGISTRATION IN UNIMAXILLARY COMPLETELY EDENTULOUS PATIENTS</b> <u>Monica Scriciu</u> ; Veronica Mercuț; Sanda Mihaela Popescu; Roxana Iulia Marinescu; Marina Olimpia Amărășcu

Romania

- 3/  
OP 327 **PROSTHETIC REHABILITATION OF DIFFERENT PATIENTS USING IMPLANT SUPPORTED OVERDENTURES RETAINED WITH BAR ATTACHMENTS**  
Eda Ozdere  
Turkey
- 4/  
OP 333 **EFFECTS OF DIFFERENT BEVERAGES ON THE COLOR STABILITY OF DENTURE TEETH**  
Isil Karaokutan; Yener Okutan  
Turkey
- 5/  
OP 366 **CLOSURE OF DIASTEMAS USING CAD/CAM: CASE SERIES**  
Kemal Korucuoğlu; Can Poyraz; Asli Seçilmiş  
Turkey
- 6/  
OP 432 **RETENTION FORCE OF SYNCHONE CAPS MADE OF GOLD**  
Mihael Stanojevic; Irena Mladenovic; Ivica Stancic  
Bosnia and Herzegovina
- 7/  
OP 455 **COMPLEX ORODENTAL REHABILITATION IN ELDERLY PATIENTS WITH OCCLUSAL ATTACHMENT OVERDENTURE**  
Mihaela Romanita Gligor; Laura Stef; Mihaela Cernusca Mitariu  
Romania
- 8/  
OP 466 **IMPROVING DIAGNOSIS AND THERAPY IN PROSTHESES RELATED INFLAMMATIONS USING INJECTION POLYMER TECHNIQUE**  
Liviu Gavrilă Ardelean; Paul Freimann; Alexandru Petre; Iustin Olariu; Stefan Milicescu  
Romania
- 9/  
OP 508 **BIOMECHANICS STUDY OF SKELETAL PROsthESIS INTEGRATED IN THE HOMEOSTASIS OF THE STOMATOGNATHIC SYSTEM**  
Monica Andronache; Ramona Feier; Ovidiu Stamatin; Mona Gornicioiu; Cibela Caras; Norina Forna  
Romania
- 10/  
OP 552 **STATISTICAL STUDIES ON PROVISIONAL VS DEFINITIVE PROSTHETIC TREATMENT DURING THE PRACTICAL TRAINING OF DENTAL STUDENTS**  
Ovidiu Stamatin; Roxana Vasluianu; Cosmin Oniciuc; Monica Andronache; Ramona Feier; Magda Antohe; Carmen Gentimir; Norina Forna  
Romania
- 11/  
OP 553 **OPPORTUNITIES FOR CAREER GUIDANCE OF DENTAL GRADUATES**  
Ramona Feier; Cristina Dascalu; Andreea Zoderu; Norina Forna  
Romania

11:00  
11:15 **Coffee break**

11:15  
13:13 **FIXED PROSTHODONTICS – PLENARY LECTURE and Oral Presentations:**

Chairmen: Prof. Dr. DRAGOSLAV STAMENKOVIC  
Prof. Dr. AURELIA CARAIANE  
Dr. MIHAEL STANOJEVIC

Secretary: Lecturer Dr. DIANA DIACONU

**FIXED PROSTHODONTICS – PLENARY LECTURE:**

L 604 **CLINICAL INVESTIGATION OF MANDIBULAR-CRANIAL FUNDAMENTAL RELATIONSHIP**  
IFTENI GABRIELA  
Romania

**FIXED PROSTHODONTICS – Oral Presentations:**

1/  
OP 14 **CURRENT TRENDS IN THE TREATMENT OF TEETH WITH ABRASION**  
Mladen Behara; Dusica Bozovic Behara; Sladjana Sicovic; Lena Jovanovic; Natasha Randjelovic

*Serbia*

- 2/ **PROSTHETIC TREATMENT OF ANTERIOR TEETH WITH LITHIUM DISILICATE CERAMICS: 3 CLINICAL CASES**  
OP 67 Eleni-Sotiria Palla; Eleana Kontonasaki  
*Greece*
- 3/ **THE EFFECT OF RECASTING ON BIOKOMPATIBILITY OF DENTAL ALLOYS**  
OP 133 Aleksandra Čairović; Dragoslav Stamenković; Katarina Radović  
*Serbia*
- 4/ **OPAESCENCE: AN AMAZING APPEARENCE PROPERTY OF NATURAL TEETH**  
OP 146 Bulent Piskin  
*Turkey*
- 5/ **INTERDISCIPLINARY MANAGEMENT OF MISALIGNED MAXILLARY ANTERIOR TEETH WITH PROSTHETIC AND PERIODONTAL TREATMENT: CASE REPORT**  
OP 325 Yener Okutan; Ilknur Tuncer; Sema Sezgin Hakki  
*Turkey*
- 6/ **TRANSLUCENCY OF DIFFERENT FULL CERAMIC MATERIALS WITH DIFFERENT THICKNESS**  
OP 331 Ipek Guldaz; Isa Yondem  
*Turkey*
- 7/ **DENTAL IMPLANTS CEMENTED PROSTHETIC SUPERSTRUCTURE VERSUS SCREW**  
OP 424 Iustin Olariu; Cosmin Sinescu; Lavinia Meda Negrutiu; Liviu Gavrilă; Roxana Radu  
*Romania*
- 8/ **EVALUATION OF ENDODONTICALLY TREATED TEETH RESTORED WITH INTERNAL AND EXTERNAL FERRULE: A CLINICAL STUDY**  
OP 448 Sasho Jovanovski  
*FYROM*
- 9/ **EFFECT OF DENTAL MODELS POSITION ERRORS IN A VIRTUAL ARTICULATOR ON OCCLUSAL MORPHOLOGY**  
OP 464 Alexandru Petre; Liviu Gavrilă Ardelean; Paul Freimann; Stefan Milicescu  
*Romania*

13:15 **Lunch break**  
15:00

15:00 **INTERDISCIPLINARY SECTION – PLENARY LECTURE and Oral Presentations:**  
16:45

Chairmen: Prof. Dr. KIRO PAPAKOCA  
Assoc. Prof. Dr. DORJAN HYSI  
Prof. Dr. RADU SEPTIMIU CAMPAN  
Secretary: Assist. Dr. RAMONA FEIER

**INTERDISCIPLINARY SECTION – PLENARY LECTURE:  
DESIGNING A RESEARCH PROJECT, PROTOCOL WRITING**

L 591 DORJAN HYSI  
*Albania*

**INTERDISCIPLINARY SECTION – Oral Presentations:**

1/ **DIFFERENT TYPE OF DOMINANCE IN NATURAL PERMANENT ORTHOGNATHIC DENTITIONS**  
OP 125 Andon Filtchev; Dimitar Filtchev; Georgi Iliev; Samer Makki; Maria Dimova; Svetlozar Rangelov; Bogena Kocheva  
*Bulgaria*

2/ **IMPROVING THE QUALITY OF LIFE OF OUR PATIENTS BY SURGICAL ORTHODONTIC CORRECTION OF IMPACTED CANINE**  
OP 179 Ondine Lucaciu; Roxana Bordea; Adela Socaciu; Bogdan Crisan; Radu Septimiu Campian  
*Romania*

- 3/  
OP 235 **CHRONIC B AND C HEPATITIS IN THE HIV-POSITIVE POPULATION IN NORTH-EASTERN ROMANIA**  
Carmen Manciu; Liviu Prisacariu; Cristina Nicolau; Alexandra Maria Largu  
*Romania*
- 4/  
OP 253 **GOLDENHAR SYNDROME**  
Claudia Florida Costea; Cristina Rusu; Camelia Geanina Ivănescu; Dana Mihaela Turliuc;  
Ingrith Crenguța Miron  
*Romania*
- 5/  
OP 254 **UNILATERAL EXOPHTHALMOS IN A CASE OF MAXILLARY SINUS CARCINOMA WITH EYE-SOCKET INVASION**  
Claudia Florida Costea; Gabriela Florența Dumitrescu  
*Romania*
- 6/  
OP 262 **PERIODONTAL DISEASE AND CARDIOVASCULAR DISEASES**  
Irina Esanu; Paraschiv Cringuta; Mihaela Boanca  
*Romania*
- 7/  
OP 348 **FULMINANT EVOLUTION OF AN INTRAABDOMINAL MALIGNANT FIBROUS HISTIOCYTOMA: CASE REPORT**  
Ana-Maria Trofin; Bogdan Ciuntu; Mihai Zabara; Delia Rusu Andrieși; Alexandra Vornicu; Ciprian Vasiluță;  
Mircea Costache; Mădălina Palaghia; Corina Ursulescu Lupașcu; Cristian Lupașcu  
*Romania*
- 8/  
OP 369 **FROM CLASSIC TO MODERN TO TREAT EARLY EXTERNAL POSTOPERATIVE DIGESTIVE FISTULAS**  
Bogdan Ciuntu; Ciprian Vasiluta; Ana Maria Trofin; Delia Rusu Andriesi; Stefan Octavian Georgescu  
*Romania*
- 9/  
OP 377 **FULMINANT EVOLUTION OF AN INTRAABDOMINAL MALIGNANT FIBROUS HISTIOCYTOMA: CASE REPORT**  
Ana-Maria Trofin; Delia Florina Andriesi-Rusu; Bogdan Mihnea Ciuntu; Ciprian Vasiluta; Cristian Lupascu  
*Romania*
- 10/  
OP 384 **DENTAL STUDENTS' WELLBEING CHANGES OVER THE FIRST SEMESTER OF THE ACADEMIC YEAR**  
Cristina Teodora Preoteasa; Elena Preoteasa  
*Romania*
- 11/  
OP 418 **CLINICAL DIAGNOSES BASED ON THE RDC/TMD AND DENTITION-RELATED ASPECTS IN TEMPOROMANDIBULAR DISORDERS AMONG DENTAL STUDENTS**  
Irena Mladenović; Slobodan Dodić; Mihael Stanojević; Ružica Kozomara  
*Bosnia and Herzegovina*
- 12/  
OP 229 **DO INITIAL TORQUE VALUES AND PLACEMENT SPEEDS OF MINISCREWS HAVE EFFECT ON THE PRIMARY STABILITY?**  
Merve Goymen; Tolga Topcuoglu; Ali Murat Aktan; Eren Isman  
*Turkey*
- 13/  
OP 354 **COMPARISON OF LATERAL CEPHALOMETRIC VALUES BETWEEN GENDERS IN A POPULATION OF AEGEAN ANATOLIA REGION**  
ORHAN HAKKI KARATAS; RABIA MERVE CELIK KARATAS  
*Turkey*
- 14/  
OP 357 **TREATMENT OF AN IMPACTED MANDIBULAR CANINE DUE TO DENTIGEROUS CYST : A CASE REPORT**  
RABIA MERVE CELIK KARATAS; ZEHRA ILERI; ESIN DEMIR  
*Turkey*

16:45  
17:00 **Coffee break**

17:00 **OPENING CEREMONY – RHONDA HALL**  
18:00  
20:00 **WELCOME COCKTAIL – RHONDA HALL**

**09:00 ORAL PATHOLOGY (ORAL MEDICINE), COMMUNITY AND PREVENTIVE DENTISTRY –  
11:00 PLENARY LECTURE and Oral Presentations:**

Chairmen: Prof. Dr. MOMIR CAREVIC  
Dr. MIRJAN DJURICKOVIC  
Assoc. Prof. Dr. LUCIA BARLEAN  
Secretary: Lecturer Dr. ALICE MURARIU

**ORAL PATHOLOGY (ORAL MEDICINE) – PLENARY LECTURE:**

L 616 **TREATMENT AND DIAGNOSIS OPTIMIZATION IN HERPETIC STOMATITIS**  
DIANA UNCUTA  
*Republic of Moldavia*

**ORAL PATHOLOGY (ORAL MEDICINE), COMMUNITY AND PREVENTIVE DENTISTRY –  
Oral Presentations:**

- 1/  
OP 208 **EFFECTS OF BEVERAGES ON COLOR STABILITY AND ROUGHNESS OF DENTAL COMPOSITES**  
Zeynep Dereli, Makbule Tugba Tuncdemir, Ali Ihsan Erkan, Bora Ozturk  
*Turkey*
- 2/  
OP 209 **AFFECT OF SIX SURFACE TREATMENTS ON REPAIRED STRENGTHS OF AGED-COMPOSITES**  
Ali Ihsan Erkan, Makbule Tugba Tuncdemir, Nimet Unlu  
*Turkey*
- 3/  
OP 468 **THE SURGICAL COMPONENT IN DENTAL MEDICAL TREATMENTS NEED IN DISADVANTAGED POPULATION GROUPS**  
Nausica Petrescu; Aranka Ilea; Ionut Husti; Radu Septimiu Campian  
*Romania*
- 4/  
OP 188 **EFFECT OF ORAL HYGIENE MOTIVATION ON CARIES RISK FACTORS IN PREGNANT WOMEN**  
Ali Ihsan Erkan; Nimet Unlu  
*Turkey*
- 5/  
OP 197 **THE PHYSICOCHEMICAL CHARACTERISTICS OF SALIVA IN PREGNANT AND NON-PREGNANT WOMEN**  
Ali Ihsan Erkan; Nimet Unlu; Ali Unlu  
*Turkey*
- 6/  
OP 256 **EVALUATION OF THE PREVENTIVE EFFECT OF DIODE LASER AND FLUORIDE ON ENAMEL EROSION**  
Dilek Gunes; Cigdem Guler; Gul Tosun  
*Turkey*
- 7/  
OP 415 **THE RELATIONSHIP WITH DENTAL TISSUE OF TRANCE ELEMENTS**  
Cihan Öz; Mehmet Sinan Dogan; Sedat Guven; Zeki Arslanoğlu; Mehmet Unal  
*Turkey*
- 8/  
OP 475 **EVALUATION OF DIETARY HABITS REGARDING SUGAR CONSUMPTION IN 7 TO 10 YEARS OLD SCHOOL CHILDREN**  
Lucia Barlean; Livia Bobu; Carina Balcos; Dana Baciu; Magda Barlean  
*Romania*
- 9/  
OP 533 **STUDY ON KNOWLEDGE OF DENTISTS IN THE NORTH-EAST REGION OF ROMANIA CONCERNING ORAL DISEASES PREVENTION**  
Livia Bobu; Lucia Barlean; Iulia Saveanu; Carina Balcos; Irina Bamboi  
*Romania*
- 10/  
OP 157 **HEREDITARY GINGIVAL FIBROMATOSIS: A CASE REPORT**  
Hatice Umay Hoşgören; Çağlar Körcük; Süleyman Ziya Şenyurt; Hasan Gündoğar; Kamile Erciyas  
*Turkey*
- 11/  
**ORAL GRANULAR CELL TUMOR (MYOBLASTOMA): A CASE REPORT**

OP 234 Andreadis Dimitrios; Anna Dimitriou; Ioanna Patargia; Eleftherios Anagnostou; Alexandros Kolokotronis  
Greece

12/  
OP 322 **ORAL MANIFESTATIONS IN MYELODYSPLASTIC SYNDROME. REVIEW OF THE LITERATURE AND REPORT OF A  
CASE.PERIODONTITIS**

Athanasios Karampasis; Athanasios Pouloupoulos; Dimitrios Andreadis; Nikoleta Pastelli; Eirene Balntoumi  
Greece

13/  
**LICHEN PLANUS: A CASE REPORT**

OP 435 Buket Ozkaya; Seda Sevinç Özberk; Hasan Gundogar; Caglar Korcuk; Kamile Erciyas  
Turkey

**11:00 Coffee break**

**11:15**

**11:15 HANDS-ON**

**13:15 „Minimally invasive dental treatments by using fiber-reinforced composite restauration :  
inlay, onlay and adhesive bridge”**

SPEAKERS: Prof. Dr. RADU SEPTIMIU CAMPIAN

DT. WILLI ANDREI IRICIUC

Romania

#### SPEAKERS' SHORT PRESENTATION



**Professor Dr.  
RADU SEPTIMIU CAMPIAN**

DMD MSc PhD

*“Iuliu Hatieganu” UMPH Cluj Napoca*



Professor Radu Septimiu Campian is specialist in oromaxillofacial surgery; since 2008 he is Professor and Head of the Department of Oral Rehabilitation, Oral Health and Management, Faculty of Dental Medicine, “Iuliu Hatieganu” University of Medicine and Pharmacy Cluj Napoca and also the Dean of Faculty of Dental Medicine, “Iuliu Hatieganu” University of Medicine and Pharmacy Cluj Napoca. Since 2007 Professor Campian is the President of Dentists College, Cluj Napoca and member in professional committees of the Romanian National College of Dentists; he is also member in international and national professional societies (European Association for Cranio-Maxillofacial Surgery, Romanian Society of Oral and Maxillo-facial Surgery, Society of Biomaterials) and in the editorial board of scientific journals (Romanian Journal of Dental Medicine, Medic Dentist.RO). Professor Campian managed three national research projects and was member in the team of another seven projects; he is author or co-author of 11 books, 13 scientific articles published in international journals, more than 40 scientific articles published in national journals and more than 100 scientific articles published in the proceedings volumes of national and international manifestations. Professor Campian is Invited Speaker at various scientific events from Romania and abroad, where he lectured, in more than 100 conferences, about the newest trends and innovations in the field of oromaxillofacial surgery.





**Dr.**  
**WILLI ANDREI URICIUC**  
MSc PhD  
*"Iuliu Hatieganu" UMPH Cluj Napoca*



Willi Andrei Uriciuc is currently associate professor of the Oral Rehabilitation Department at the Faculty of Dentistry - University of Medicine and Pharmacy "Iuliu Hatieganu" from Cluj Napoca. He graduated in dental laboratory field (DT.) and over time, he collaborated for different courses: Ergonomics, Dental materials, Technology of Dental prosthetics and Management of Dental laboratory. He has more than 10 years experience, in metal ceramic or pure ceramics, zircon, esthetics, implants and combined work. He participated in training courses organized by the most reputable companies in Europe. Having a Master degree (MSc.) in micro and nano-materials technology (Technical University of Cluj Napoca), he creates a bridge between engineering and dentistry and dedicating itself in interdisciplinary research at PhD. level. The research results are published and indexed in databases (Springer Link) and published in scientific journals (Current Health Sciences Journal). Willi A. Uriciuc is guest lecturer at various events, national and international congresses, where he lectured about new technologies and advanced research methods of dental field.

---

#### HANDS-ON ABSTRACT

### **MINIMALLY INVASIVE DENTAL TREATMENTS BY USING FIBER-REINFORCED COMPOSITE RESTAURATION : INLAY, ONLAY AND ADHESIVE BRIDGE**

RADU SEPTIMIU CAMPAN , WILLI ANDREI URICIUC

*Romania*

This work shop familiarizes the participants with fiber-reinforced composite solution in the minimally invasive dental treatments by using GC everStick fiber, GC G-aenial composite and GC optiglaze color. The participants will meet:

- everStick NET fibre reinforcement that is a fibre mesh that adds strength and toughness to composites in several directions. everStickNET fibre reinforcement is made from bidirectional glass fibres and a polymer/ resin gel matrix.
- G-aenial Anterior and Posterior, two light-cured restoratives that were developed using extensive expertise and knowledge of dental materials
- the participants will see that restauration looks better with Optiglaze that provide -long-lasting color and surface gloss in an extremely easy way.

This work shop is a lecture hands on demonstration that has the following learning objectives :

- provide the participants with a clear overview of structure, components and physical properties of fiber-reinforced composites.
- allow the participants to identify the most suitable way to use everstick like a friendly structure and G-aenial composite like a simple way to reach aesthetics.
- provide the participants with an understanding on the longevity of the reinforced restorations.
- provide the participants with the technical knowledge to fabricate direct or indirect fiber-reinforced composite restorations of various kinds: onlays, inlays, overlays and adhesive bridge.

This work shop will be sustained with an audience of up to the capacity of the room (max. 30 participants).

**15:00 SEMINAR**

**16:45 „Full zirconia crown for implant prosthesis (1+2)”**

SPEAKER: Prof. Dr. CHEOL WOONG JEONG

*Republic of South Korea*

**18:00 HANDS-ON**

**20:00 „Application of the digital technologies in oral rehabilitation. Guided surgery, patient specific implants for bone reconstruction, guided corticotomy”**

SPEAKERS: Dr. CLAUDIO ALBI

Dr. PIETRO ALBI

*Italy*

**17:00 OPENING CEREMONY – RHONDA HALL**

**18:00**

**20:00 WELCOME COCKTAIL – RHONDA HALL**

## FRIDAY, APRIL 24th, 2015

INTERCONTINENTAL HOTEL, RHONDA HALL

09:00

11:00

### ORAL IMPLANTOLOGY, REMOVABLE PROSTHODONTICS – PLENARY LECTURES:

Moderators: Prof. Dr. PETROS KOIDIS  
Prof. Dr. ARGIRIOS PISSIOTIS  
Prof. Dr. NORINA FORNA

L 596 **DENTAL REHABILITATION: ON THE CROSSROADS OF CONVENTIONAL AND REGENERATIVE APPROACHES**  
PETROS KOIDIS

*Greece*

L 600 **OCCLUSAL SCHEMES FOR COMPLETE DENTURE PROSTHESES**

ARGIRIOS PISSIOTIS

*Greece*

L 599 **METICULOUS PREPARATION IS THE MOST IMPORTANT FACTOR IN IMPLANT SURGERY**

STYLIANOS DALAMPIRAS

*Greece*

L 556 **MODERN TECHNIQUES OF IMPLANT-PROSTHETIC REHABILITATION**

NORINA FORNA

*Romania*

L 428 **INTRODUCTION OF IMPLANT SUPPORTED OVERDENTURE**

KWIDUG YUN

*Republic of South Korea*

11:00 **Coffee break**

11:15

11:15

13:15

### PERIODONTOLOGY, COMMUNITY DENTISTRY – PLENARY LECTURES:

Moderators: Prof. Dr. CHEOLWOONG JEONG  
Senior Lect. Dr. KATARINA RADOVIC

L 136 **RELATIONSHIP BETWEEN PERIODONTAL AND CARDIOVASCULAR DISEASES**

THEODORA NIKOLAEVA BOLYAROVA KONOVA

*Bulgaria*

L 286 **ORAL HEALTH STATUS AND TREATMENTS NEEDS AMONG SCHOOLCHILDREN FROM CRAIOVA, ROMANIA**

SANDA MIHAELA POPESCU

*Romania*

L 609 **VASCULAR ENDOTHELIAL GROWTH FACTOR AND ORAL HOMEOSTASIS IN DIABETES MELLITUS TYPE 2 IMMEDIATE DENTURE WEARERS**

KATARINA RADOVIC

*Serbia*

13:15 **Lunch break**

15:00

12:50

13:20

### Comercial Presentation - COLGATE

SPEAKER: Dr. CRISTIAN FUNIERU

ROMANIA



**Assist. Dr.  
CRISTIAN FUNIERU**

DMD PhD

*"Carol Davila" UMPH Bucharest*



Among the key achievements of Dr. Cristian Funieru we can mention that he is teaching students in preventive dentistry – practical and clinical demonstrations; he is leading and being part of a lot of scientific project teams (principal investigator in “PAROGYM” study, aimed to determine prevalence of dental caries and gingivitis in Bucharest schoolchildren population, leader of „Microsal” project’s research team - Microsystem designed for treatment and monitoring patients suffering of xerostomia) and he is leader of many clinical and epidemiological studies concerning oral hygiene, dental caries, and gingivitis; he is also speaker in many scientific congresses and events and he is writing scientific papers and advertorials. Dr. Funieru is Primary dentist (since 2011) and specialist (since 2008) in dental-alveolar surgeon, within the „Carol Davila” University of Medicine and Pharmacy, Faculty of Dentistry Bucharest, Romania; since 2010 he is also physical doctor in dental medicine. He is member of Romanian Society of Periodontics, being also a very good practitioner in dentistry and a polyvalent researcher and a strong team leader for scientific studies.

---

PRESENTATION'S ABSTRACT

**THE NEW APPROACH IN CARIES PREVENTION AND MANAGEMENT**

CRISTIAN FUNIERU (supported by Colgate – Palmolive Romania)

*Romania*

The modern approach on dental caries clinical assessment influences the preventive strategy and treatment phases. The assessment and the treatment of early lesions determine a new strategy, on global level, in dental practice towards conservative methods.

The results of a 12-week , double-blind clinical study in 48 subjects, which compared twice daily brushing with a formula containing arginine, insoluble calcium compound and 1450 ppm fluoride to a 1450 ppm fluoride-only toothpaste, measured the pH of the subjects’ bacterial plaque, using a microelectrode, immediately following its collection at chair-side and the results showed that the subjects which used the formula containing arginine, insoluble calcium compound and 1450 ppm fluoride had a significantly higher plaque pH, both before ( $p \leq 0.01$ ) and after ( $p \leq 0.045$ ) a sucrose challenge, compared to those using the fluoride-only toothpaste.

The results of a two-year clinical trial conducted in over 5,000 children in Thailand, which evaluated the anti-caries efficacy of two formulations of arginine, insoluble calcium compound and 1450 ppm fluoride and a regular fluoride-only toothpaste (1450 ppm fluoride, as NaF), over a two-year period showed a statistically significant reduction in the formation of new cavities of 21.0%

and 17.7%, compared to the fluoride-only toothpaste. This result is comparable to the reductions seen in studies of fluoride versus non-fluoridated toothpastes and therefore suggests that the introduction of the formula containing arginine, insoluble calcium compound and 1450 ppm fluoride could represent the next breakthrough in caries prevention.

Fluoride helps to prevent cavity formation by reducing demineralisation and promoting remineralisation of early caries lesions, but it does not neutralise the acids in plaque. Now, with the addition of arginine which determines ammonia production in bacterial plaque, a breakthrough was achieved in cavity protection. The insoluble calcium supports fluoride to help reverse the demineralisation. The combination of arginine, insoluble calcium compound and 1450 ppm fluoride results in four time greater remineralisation of early caries lesions versus a toothpaste with the same level of fluoride alone. The innovative technology has been studied in over 14,000 people over eight years.

**15:00**  
**17:00** **PROSTHETICS, NEW TECHNOLOGIES – PLENARY LECTURES:**

Moderators: Prof. Dr. KOSOVA OBRADOVIC DJURCIC  
Assoc. Prof. Dr. LILIANA POROJAN

L 608 **HOW TO MAKE THE PROSTHETIC RECONSTRUCTION PREDICABLE - AESTHETIC PROTOCOLS**  
KOSOVA OBRADOVIC DJURCIC  
*Serbia*

L 611 **LONG-TERM CLINICAL RESULTS OF REGENERATIVE THERAPY IN PERI-IMPLANTITIS**  
CHEOL WOONG JEONG  
*Republic of South Korea*

L 413 **DIGITAL DESIGN, IMPLEMENTATION AND EVALUATION OF PROSTHETIC SINGLE TOOTH RESTORATIONS**  
LILIANA POROJAN  
*Romania*

L 612 **RE: EVOLUTION IN DENTAL SURGERY. NEW BONE COMPACTING TECHNIQUES: FROM SUMMERS TO NEW TECHNOLOGIES**  
LUCA ARDUINI  
*Italy*

**17:00** **Coffee break**  
**17:15**

**17:15**  
**19:15** **ORAL MAXILLOFACIAL SURGERY, BIOMATERIALS – PLENARY LECTURES:**

Moderators: Prof. Dr. HANA HUBALKOVA  
Prof. Dr. GEORGIOS PANTELAS

L 487 **FUNCTIONAL AND AESTHETICAL RECONSTRUCTION OF LARGE MAXILLOFACIAL DEFECTS**  
HANA HUBALKOVA  
*Czech Republic*

L 595 **DIAGNOSTIC APPROACH OF PAROTID LUMP**  
GEORGIOS PANTELAS  
*Cyprus*

L 593 **AMSA (AMSA (Anterior and Middle Superior Alveolar) Injection is Efficient for Maxillary Teeth Extraction**  
TOMIC SLAVOLJUB  
*Bosnia and Herzegovina*

L 391 **EVALUATION METHODS OF BONE GRAFT MATERIALS**  
HORIA OCTAVIAN MANOLEA

20:00 **SOCIAL PROGRAM – JARISTEA Restaurant**

*INTERCONTINENTAL HOTEL, RAPSODIA HALL*

09:00 **DENTAL BIOMATERIALS AND DEVICES, ORAL DIAGNOSIS – ORAL RADIOLOGY, NEW**  
11:00 **TECHNOLOGIES – PLENARY LECTURES and Oral Presentations:**

Chairmen: Prof. Dr. KAAAN ORHAN  
Dr. NIKOS MAROUFIDIS  
Prof. Dr. CRISTINA MARIA BORTUN  
Secretary: Assist. Dr. ANA MARIA FILIOREANU

**DENTAL BIOMATERIALS AND DEVICES, ORAL DIAGNOSIS – ORAL RADIOLOGY  
– PLENARY LECTURES:**

L 606 **NEW TRENDS IN DENTAL BIOMATERIALS**

IULIAN ANTONIAC

Romania

L 211 **RADIOGRAPHIC EVALUATION OF THE TEMPOROMANDIBULAR JOINT PATHOLOGY. INDICATIONS AND  
GUIDELINES**

ANTIGONE DELANTONI

Greece

**DENTAL BIOMATERIALS AND DEVICES, ORAL DIAGNOSIS – ORAL RADIOLOGY, NEW  
TECHNOLOGIES – Oral Presentations:**

1/ **EVALUATION OF DIFFERENT TYPES OF CEMENT FOR IMPLANT-SUPPORTED CROWNS**

OP 27 Dejan Stamenkovic; Aleksandar Todorovic

Serbia

2/ **THE INFLUENCE OF THE TIO<sub>2</sub> AND THE GRAPHENE ON THE FIBROBLAST CELL LINE**

OP 95 Cristina Maria Bortun; Meda Lavinia Negrutiu; Cosmin Sinescu; Laura Cristina Rusu

Romania

3/ **HISTOLOGICAL EFFECTS OF EMDOGAIN® GEL ON EXPOSED DENTAL PULP**

OP 225 Marijana Popović Bajić; Vesna Danilović; Prokić Branislav; Verica Milošević; Slavoljub Živković

Serbia

4/ **COMPARISON OF INTRAORAL RADIOGRAPHY AND CONE-BEAM COMPUTED TOMOGRAPHY FOR THE  
DETECTION OF PERIODONTAL DEFECTS**

OP 4 Mehmet Eray Kolsuz; Nilsun Bagis; Kaan Orhan; Sebnem Kursun

Turkey

5/ **EFFECTS OF POSITIONING UPON THE VERTICAL DIMENSION ON CONE-BEAM COMPUTED TOMOGRAPHY**

OP 77 Derya Icoz

Turkey

6/ **INTRA-ARTICULAR DISORDERS OF TMJ IN THE ALBANIAN POPULATION AT THE AGE OF 18 – 25**

OP 129 Gersi Vërçani; Alketa Qafmolla

Albania

7/ **COMPARISON OF THE ACCURACY BETWEEN CONVENTIONAL AND DIGITAL RADIOGRAPHY FOR LINEAR  
MEASUREMENT IN CLINICAL DENTISTRY**

OP 183 Dragan Ilic; Djordje Antonijevic

Serbia

- 8/ **THE EVALUATION OF MCI, MI, PMI AND GT WITH DIFFERENT AGE, GENDER AND DENTAL STATUS**  
 OP 263 Guldane Magat; Sevgi Sener  
 Turkey
- 9/ **MANDIBULAR MORPHOLOGICAL CHANGES: THE EFFECTS OF AGE, GENDER AND DENTAL STATUS**  
 OP 264 Guldane Magat; Sevgi Sener  
 Turkey
- 10/ **CBCT EVALUATION OF SELLA TURCICA MORPHOLOGY IN A GROUP OF TURKISH POPULATION**  
 OP 471 Seda Ozer; Ali Murat Aktan; Ozlem Isman  
 Turkey
- 11/ **EVALUATION OF HALITOSIS USING DIFFERENT MALODOR MEASUREMENT METHODS AND SUBJECTIVE PATIENTS' OPINION**  
 OP 472 Busra Yilmaz; Mehmet Ertugrul Ciftci; Ozlem Isman; Ali Murat Aktan  
 Turkey
- 12/ **ERGONOMIC CONCEPT IN DENTISTRY**  
 OP 569 Cristina Marina Iordache; Doriana Agop Fornă; Norina Fornă  
 Romania
- 13/ **OCCCLUSION AND AESTHETIC**  
 OP 528 Basil Raymond Victor; Jendoubi Sabrina  
 Romania

**11:00 Coffee break**  
**11:15**

**11:15**  
**13:15** **ROUND TABLE – ORAL IMPLANTOLOGY**

Coordinator: Prof. Dr. NORINA FORNA  
 Moderator: Prof. Dr. ANASTASIOS MARKOPOULOS  
**IMMUNITY - FUNDAMENTAL FUNCTION OF THE BODY'S DEFENSE**  
Acad. CONSTANTIN IONESCU TARGOVISTE  
 Romania

L 598 **SYSTEMIC DISEASES AND TREATMENTS AS RISK FACTORS FOR DENTAL IMPLANT**  
Prof. Dr. ANASTASIOS MARKOPOULOS  
 Greece

L 597 **ORAL MANIFESTATIONS OF METABOLIC BONE DISEASES**  
Prof. Dr. ANASTASIOS MARKOPOULOS  
 Greece

**ANTERIOR CHEST PAIN - A MULTIDISCIPLINARY DETERMINATION**  
Prof. Dr. CATALINA ARSENESCU  
 Romania

L 614 **SHORT IMPLANT - 5 YEARS RETROSPECTIVE STUDY**  
Prof. Dr. KADHIM AL HIMDANI  
 France

**13:15 Lunch break**  
**15:00**

**15:00**  
**17:00** **INTERDISCIPLINARY SECTION – PLENARY LECTURE and Oral Presentations:**

Chairmen: Assoc. Prof. Dr. THEODORA BOLYAROVA KONOVA  
 Lecturer Dr. CARMEN MANCIUC  
 Secretary: Lecturer Dr. SORINA SOLOMON

## INTERDISCIPLINARY SECTION – PLENARY LECTURE:

- L 617 **IMPLICATIONS OF ORAL TRANSMISSION OF HELICOBACTER PYLORI INFECTION**  
MARIN BURLEA  
*Romania*
- L 304 **DENTO-PERIODONTAL CHANGES IN ORTHODONTIC TREATED ADULT PATIENTS**  
MARIANA PĂCURAR  
*Romania*

## PERIODONTOLOGY – Oral Presentations:

- 1/  
OP 519 **EFFECT OF MENOPAUSE ON PERIODONTIUM IN WOMEN**  
Vera Nikolovska; Vera Stojanovska; Ilijana Muratovska; Natasa Toseska-Şpasova; Aneta Atanasovska-Stojanovska  
*FYROM*
- 2/  
OP 22 **LASER PHOTOBIMODULATION AS AN ADJUNCT TO NONSURGICAL TREATMENT OF AGGRESSIVE PERIODONTITIS: A PILOT STUDY**  
Hasan Gündoğar; Süleyman Ziya Şenyurt; Kemal Üstün; Kamile Erciyas  
*Turkey*
- 3/  
OP 26 **INFLUENCE OF PROSTHETIC CROWNS IN DOSE OF THE GINGIVAL FLUID AT SULCUS OF ABUTMENT TEETH**  
Ilma Robo; Ruzhdie Qafmolla  
*Albania*
- 4/  
OP 32 **THE EFFECTS OF LED PHOTO-ACTIVATED DISINFECTION ON PERIODONTAL CLINICAL PARAMETERS IN PATIENTS WITH CHRONIC PERIODONTITIS**  
Maria Alexandra Mârţu; Irina Ursărescu; Sorina Solomon; Liliana FOIA  
*Romania*
- 5/  
OP 35 **PERIODONTAL DISEASE AT PATIENTS WITH CHRONIC KIDNEY DISEASE AND SECONDARY HEMODIALYSIS THERAPY**  
Silvia Mârţu; Cerasella Sincar; Maria-Alexandra Mârţu; Sorina SOLOMON  
*Romania*
- 6/  
OP 43 **THE ASSESSMENT OF ORAL AND PERIODONTAL PARAMETERS IN PATIENTS WITH END-STAGE CHRONIC KIDNEY DISEASE**  
Sorina Solomon; Irina Ursărescu; Ionuţ Nistor; Silvia Mârţu; Gabriel Veisa  
*Romania*
- 7/  
OP 115 **LICHEN PLANUS: A CASE REPORT**  
Buket Ozkaya; Seda Sevinc Ozberk; Hasan Gundogar; Kamile Erciyas  
*Turkey*
- 8/  
OP 249 **THE EFFECT OF SMOKING ON COMPONENTS OF GINGIVAL CREVICULAR FLUID IN PATIENTS WITH PERIODONTAL DISEASE**  
Ioanna Tsachouridou; Marina Tsiraki; Lazaros Tsalikis; Antonios Konstantinidis  
*Greece*
- 9/  
OP 266 **RHEUMATOID ARTHRITIS – A FAVORING FACTOR OF CHRONIC PERIODONTITIS**  
Dora Popescu; Dorin Gheorghe; Lucian Dragomir; Melania Cojocar; Petra Surlin  
*Romania*
- 10/  
OP 375 **THE USE OF FREE GINGIVAL GRAFT FOR THE MANAGEMENT OF PERI-IMPLANT KERATINIZED SOFT TISSUES**  
Diomatari Dimitra; Kokla Efthalia; Vakou Dimitra; Papazoglou Kalliopi; Silvestros Spiridon  
*Greece*
- 11/  
OP 404 **TNFA -308G/A POLYMORPHISM AND SERUM CONCENTRATIONS IN PERIODONTITIS AND DIABETES**  
Ana Pucar; Sanja Matic Petrovic; Jovana Kuzmanovic; Nadja Nikolic; Bosko Toljic  
*Serbia*
- 12/  
OP 416 **GUMMY SMILE: DIFFERENTIAL DIAGNOSIS AND MANAGEMENT**  
Bruno Nikolovski; Ana Minovska; Danica Popovic-Monevska; Mirjana Popovska; Vera Radojkova-Nikolovska



FYROM

13/  
OP 426 **EFFECTIVENESS AND CONCERNS ACCORDING THE USE OF NON-STEROIDAL ANTI-INFLAMMATORY DRUGS (NSAIDS) IN PERIODONTOLOGY**

Ilias Liapis; Ionut Luchian; Silvia Martu  
Romania

14/  
OP 436 **USE OF EPITHELIAL GRAFTS FOR ACHIEVING AESTHETIC CONTOUR IN IMPLANT-PROSTHETIC**

Luan Mavriqi; Ilma Robo; Egresca Baca; Anila Vjeshta  
Albania

**17:00 Coffee break**

**17:15**

**17:15**

**19:15**

### **RESTORATIVE AND ADHESIVE DENTISTRY – Oral Presentations:**

Chairmen: Prof. Dr. ROZARKA BUDINA  
Dr. JULIO POPOVSKI  
Assoc. Prof. Dr. GIANINA IOVAN  
Secretary: Lecturer Dr. SIMONA STOLERIU

1/  
OP 61 **THE SHORT-TERM CLINICAL EVALUATION OF BULK-FILL COMPOSITE RESINS IN CLASS II RESTORATIONS: 6 MONTHS FOLLOW-UP**

Yusuf Bayraktar; Mehmet Mustafa Hamidi; Ertuğrul Ercan; Abdülkadir Şengün  
Turkey

2/  
OP 84 **COMPARISON OF MICROHARDNESS AND ROUGHNESS OF GLASS CARBOMER AND SELF ADHERING MATERIALS**

H. Esra Ülker; Nuray Günaydin; Alihsan Erkan; Firdevs Kahvecioglu; Mustafa Ülker  
Turkey

3/  
OP 87 **PULPAL TEMPERATURE CHANGES OF THE GLASS CARBOMER AND RESIN MODIFIED GLASS IONOMER CEMENT**

Firdevs Kahvecioglu; Gul Tosun; Esra Ulker  
Turkey

4/  
OP 170 **EFFECT OF DIFFERENT SURFACE TREATMENTS ON SHEAR BOND STRENGTH OF A REPAIRED NANO-HYBRID COMPOSITE**

Ali İhsan Erkan; Ayşe Canan Tutku Atmaca; Hayriye Esra Ulker; Mustafa Ulker  
Turkey

5/  
OP 173 **MIKROLEAKAGE OF DIFFERENT MATERIALS USED AS FISSURE SEALANT**

Nuray Gunaydin; Hayriye Esra Ulker  
Turkey

6/  
OP 175 **EFFECT OF SALIVA DECONTAMINATION PROCEDURES ON SHEAR BOND STRENGTH OF ONE-STEP ADHESIVE SYSTEM**

Esra Ülker; Selin Bilgin; Firdevs Kahvecioğlu; Ali İhsan Erkan  
Turkey

7/  
OP 205 **MIKROLEAKAGE OF DIFFERENT SELF-ADHERING MATERIALS**

Hayriye Esra Ulker; Nuray Gunaydin; Ali İhsan Erkan; Firdevs Kahvecioğlu; Mustafa Ulker  
Turkey

8/  
OP 212 **EFFECT OF DESENSITIZING AGENTS ON THE DENTIN BOND STRENGTHS OF SELF-ADHESIVE RESIN COMPOSITES**

Mustafa Ülker; Ali İhsan Erkan; Hakan Dinc; Hamdi Acar; Esra Ülker  
Turkey

9/  
OP 270 **BOND STRENGTHS TO ROOT DENTIN OF DIFFERENT SELF-ETCH ADHESIVE SYSTEMS**

Cobanoglu Nevin; Aktas Bilal; Erkan Ali İhsan; Dinç Derya  
Turkey

- 10/  
OP 301 **NON-INVASIVE APPROACH TO THE AESTHETIC REHABILITATION AFTER ORTHODONTIC TREATMENT: CASE SERIES**  
Nermin Demirkol; Merve Göymen; Merve Aycan Kir  
*Turkey*
- 11/  
OP 379 **COMPARISON OF MARGINAL MICROLEAKAGE OF COMPOSITE RESTORATIONS IN TEETH PREPARED BY BUR OR ER,CR:YSGGLASER**  
Athanasios Synarellis; Elisabeth Koulaouzidou; Pantelis Kouros; Dimitrios Strakas;  
Eugenia Koliniotou-Koumpia  
*Greece*
- 12/  
OP 414 **ORAL LICHENOID LESIONS RELATED TO CONTACT WITH DENTAL AMALGAM**  
Konstantinia Karaoulani; Dimitrios Dionisopoulos; Evangelos Parcharidis  
*Greece*
- 13/  
OP 524 **SEM EVALUATION OF ONE SINGLE-COMPONENT ADHESIVE APPLIED IN SELF- ETCHING AND TOTAL-ETCHING PROCEDURES**  
Gianina Iovan; Simona Stoleriu; Angela Ghiorghe; Irina Nica; Sorin Andrian  
*Romania*
- 14/  
OP 535 **THE EFFECTS OF DIFFERENT BLEACHING SYSTEMS ON THE VOLUME OF GINGIVAL FLUID**  
Derya Sürmelioglu; Hasan Gundogar; Burcu Bacaksiz; Kamile Erciyas; Semih Ozsevik  
*Turkey*

**20:00 SOCIAL PROGRAM – JARISTEA Restaurant**

*INTERCONTINENTAL HOTEL, BOLERO HALL*

- 09:00 **HANDS-ON**  
11:00 **„Cardio-pulmonary resuscitation (CPR) in dental practice (1)“**  
SPEAKER: Assist. Dr. FLORIN MANUEL ROSU  
*Romania*
- 11:15 **HANDS-ON**  
13:15 **„Cardio-pulmonary resuscitation (CPR) in dental practice (2)“**  
SPEAKER: Assist. Dr. FLORIN MANUEL ROSU  
*Romania*

ROMANIA



**Assist. Dr.  
FLORIN MANUEL ROSU**

DMD MSc PhD  
*Intensive Care Dept. Coordinator,  
Infectious Diseases Hospital "St. Parascheva" Iași*



Dr. Florin Rosu is specialist in Anaesthetics and Intensive Care, at Infectious Diseases Hospital "St. Parascheva" Iasi; since 2012 he is PhD and Assistant Lecturer, at University of Medicine and Pharmacy "Grigore T.Popa" Iasi, Faculty of Dentistry; he obtained his Master in Health Management in 2007, at University of Medicine and Pharmacy "Grigore T. Popa" Iasi, Faculty of Medical Bioengineering. He is member of the organizing committee of the Medical School Summer "Art therapy anti-infective, anti-infective therapy art and "Iași, 2013; he coordinated the workshop "Training center SPECIALISTS AND RESOURCES IN ORAL REHABILITATION" - 2013; he is member of the organizing committee of the Medical School Summer "Infectious pathology current therapy healing and hope" Iași, 19 to 21 June 2014, Hotel International Iași. He was Advanced Life Support Trainer "PRACTICAL WORKSHOP SCENARIOS MEDICAL EMERGENCIES" - March 6, 2014, Iasi; he was Workshop coordinator at the International conference of medical tourism and medical dental - First edition May 27 to 28, 2014, Bucharest, at the "PRACTICE SCENARIOS performance mannequin in medical emergencies FOR DENTAL PRACTICE and dental school labs", 18 to 19 June 2014, Iași and lecturer at the "Medical emergencies in dental practice", 13-14.11.2014, Ploiesti, Prahova College of Dentists and "Emergency dental care during maneuvers" , 14 to 15 November 2014, Buzau, College of Dentists.

---

HANDS-ON ABSTRACT

**CARDIO-PULMONARY RESUSCITATION (CPR) IN DENTAL PRACTICE**

FLORIN MANUEL ROSU

*Romania*

In recent years dental medicine has reached a very high level, dental treatment turning into a real surgical intervention. Patients with a history of hypertension or hypertensive, even well balanced by chronic antihypertensive medication, present a high risk in dental treatments, also, patients with convulsive disorders / epilepsy shows increased sensitivity to hypoxia, resulting in a widening crisis of seizures. Anaphylactic shock represents a brutal, dramatic, hypersensitivity reaction with hemodynamic collapse and respiratory failure after contact with body substances, especially proteins, causes the release of chemical mediators and, finally, cardio-circulatory collapse and respiratory. If to all this, which is a small part of pathology facing dentist also add congenital diseases, most often undiagnosed the border between homeostasis and cardiac arrest is collapses.

Pointing these reasons, hands-on "CPR in the dental" is intended to be a medical practitioner helping hand to the dentist in training what is cardiopulmonary resuscitation. Training shall be provided with the most modern models in practical training under the guidance of Anaesthetist and Intensive Care physician. Resuscitation techniques will be realistically achieved thanks to the possibility of simulating chest compression, artificial respiration and pulse of bilateral carotid on this simulator (Laerdal Resusci Anne). On the other hand, Laerdal ALS Simulator will provide a realistic and interactive training to simulate a wide range of advanced resuscitation techniques. With spontaneous breathing, airway blockage, voice, sounds, ECG, and other clinical characteristics it is a complete simulator for emergency treatment. **Acknowledgements.** The Laerdal Resusci Anne simulators were purchased within the project "Training Center Specialists and Resources In Oral Rehabilitation", contract No. POSDRU/87/1.3/S/62208, Contract No. POSDRU/159/1.5/S/133377, project co-financed by the European Social Fund Operational Program "Human Resources Development" for 2007-2013.

15:00  
17:00 **1<sup>st</sup> BaSS Council Meeting**

17:15 **HANDS-ON**  
19:15 **„ Re: Evolution in dental surgery. New bone compacting techniques: from Summers to new technologies”**  
SPEAKER: Dr. LUCA ARDUINI  
*Italy*

20:00 **SOCIAL PROGRAM – JARISTEA Restaurant**

### INTERCONTINENTAL HOTEL, FORTUNA HALL **Section A**

09:00  
11:00 **PERIODONTOLOGY - Poster Presentations**

**P1**

Chairmen: Prof. Dr. HAMIT BOSTANCI  
Prof. Dr. MURAT AKKAYA  
Secretary: Assist. Prof. Dr. ALEXANDRA MARTU

1/  
PP 29 **CLINICAL-BIOLOGICAL STUDY OF RHEUMATOID ARTHRITIS INFLUENCE ON SALIVARY BIOMARKERS ON PATIENTS WITH PERIODONTAL DISEASE**  
Radu-Mădălin Boatcă; Loredana Hurjui; Ioana Rudnic; Ovidiu Nicolaiuc; Silvia Mârțu  
*Romania*

2/  
PP 30 **IATROGENIC EFFECTS OF ADULT ORTHODONTIC TREATMENT ON ROOT RESORPTION DEGREE AT INCISORS**  
Cătălina Dănilă; Ioana Rudnic; Anca Mihaela Stupu; Silvia Mârțu  
*Romania*

3/  
PP 31 **LASER ASSISTED VERSUS CONVENTIONAL FRENECTOMY IN ORTHODONTIC PATIENTS**  
Ionut Luchian; Ioana Mârțu; AncutGoriuc a; Monica Tatarciuc; Irina Zetu; Silvia Mârțu  
*Romania*

4/  
PP 33 **EVALUATION OF THE EFFICIENCY OF TWO TYPES OF PERIODONTAL PROBING**  
Alexandra Mârțu; Cosmin Popa; Ionut Luchian; Ioana Mârțu; Cornelia Oanță; Silvia Mârțu

Romania

- 5/  
PP 34 **LASER ASSISTED SURGICAL MANAGEMENT OF DIFFERENT TYPES OF GINGIVAL ENLARGEMENTS**  
Ioana Mârțu; Ionut Luchian; Ancuta Goriuc; Alexandra Mârțu; Diana Mirwald; Monica Tatarciuc  
Romania
- 6/  
PP 36 **EVALUATION OF CLINICAL EFFECTS OF OCCLUSAL TRAUMA ON GINGIVAL RECESSION**  
Mihaela Moisei; Cosmin Popa; Ioana Rudnic; Nicoleta Ioanid; Dana Popa; Silvia Martu  
Romania
- 7/  
PP 37 **THE ASSOCIATION BETWEEN THE SEVERITY OF CHRONIC PERIODONTITIS AND CAROTID IMT IN PATIENTS WITH ATHEROSCLEROSIS**  
Ovidiu Nicolaiciuc; Irina Ursarescu; Teodor Ștefanache; Diana Nițescu; Liliana Păsărin; Silvia Martu  
Romania
- 8/  
PP 38 **THE EVALUATION OF THE ASSOCIATION BETWEEN CHRONIC PERIODONTITIS AND THE PREVALENCE OF HEAD-NECK CARCINOMA**  
Diana Nițescu; Ioana Martu; Cristian Martu; Irina Ursărescu; Teodor Ștefanache; Silvia Martu  
Romania
- 9/  
PP 39 **THE EFFECTS OF THE GLICEMIC CONTROL AND OF NON-SURGICAL PERIODONTAL THERAPY IN DIABETES MELLITUS PATIENTS**  
Cornelia Oanță; Alexandra Mârțu; Liliana Păsărin; Mihaela Moisei; Irina Ursărescu; Silvia Martu  
Romania
- 10/  
PP 40 **THE INFLUENCE OF SCALING AND ROOT PLANING ON THE GLICEMIC STATUS IN DIABETES MELLITUS PATIENTS**  
Liliana Păsărin; Irina Ursărescu; Sorina-Mihaela Solomon; Alexandra Mârțu; Teodor Ștefanache; Silvia Martu  
Romania
- 11/  
PP 41 **EVALUATION OF THE OCCLUSAL TRAUMA UPON THE ODONTO - PERIODONTAL STATUS OF PROSTHESES PATIENTS**  
Cosmin Popa; Ionut Luchian; Ioana Mârțu; Alexander Mirwald; Ioana Rudnic; Silvia Martu  
Romania
- 12/  
PP 42 **MICROBIOLOGICAL EVALUATION OF INTERFERENCE BETWEEN HSV-1 AND PERIODONTAL BACTERIA SPECIES**  
Ioana Rudnic; Cătălina Dănilă; Marius Andrei Dinu; Veronica Șerban; Anca Mihaela Stupu; Simona Grigoraș  
Romania
- 13/  
PP 44 **THE CLINICAL EFFECTS OF THE DRUG ADJUNCTIVE THERAPY IN THE CHRONIC GENERALIZED PERIODONTITIS-STEOPOROTIC DISEASE ASSOCIATION**  
Irina-Georgeta Ursărescu; Liliana Păsărin; Sorina-Mihaela Solomon; Alexandra Mârțu; Silvia Mârțu  
Romania
- 14/  
PP 47 **THERAPY APPROACH IN TREATMENT OF COMBINED ENDO-PERIO LESION**  
Aneta Atanasovska Stojanovska; Sashka Todoroska; Mirjana Popovska; Vera Radojkova Nikolovska; Ilijana Muratovska  
FYROM
- 15/  
PP 116 **PORPHYROMONAS GINGIVALIS LIPOPOLYSACCHARIDE DOSE HETEROGENCITY DIFFERENTIALLY MODULATES THE PROLIFERATION IN GINGIVAL AND PERIODONTAL LIGAMENT FIBROBLASTS**  
Vahdi Umut Bengi; Işil Saygun; Mehmet Vehbi Bal; Cansel Kose Ozkan; Ferit Avcu  
Turkey
- 16/  
PP 202 **MATERNAL PERIODONTAL STATUS AND PRETERM BIRTH**  
Sasa Cakic; Ljubinka Nikolic; Mia Rakic; Vanja Petrovic; Neda Perunovic  
Serbia
- 17/  
PP 221 **EFFECTS OF FIXED ORTHODONTIC TREATMENT ON ORAL HYGIENE HABITS AND GINGIVAL HEALTH**  
Gülen Kamak; Hakan Keklik  
Turkey
- 18/  
PP 222 **UPPER LIP FRENECTOMY WITH DIODE LASER AND ER; CR: YSGG LASER: COMPARISON OF TWO CASES**  
Gülen Kamak; Enes Tan

Turkey

- 19/  
PP 224 **ORTHODONTIC TREATMENT AND ORAL HEALTH RELATED QUALITY OF LIFE: A PROSPECTIVE STUDY**  
Gülen Kamak; Hakan Keklik; Enes Tan; Serhat Demirer  
Turkey
- 20/  
PP 231 **GUMMY SMILE CORRECTION AND ALVEOLAR RIDGE AUGMENTATION USING SUBEPITHELIAL CONNECTIVE TISSUE**  
Ariona Demiraj; Luan Mavriqi; Egresa Baca  
Albania
- 21/  
PP 246 **LASER-ASSISTED NON-SURGICAL TREATMENT OF GENERALIZED AGGRESSIVE PERIODONTITIS: A CASE REPORT**  
Elif Inonu; Ferhat Danisman; Sema S. Hakki  
Turkey
- 22/  
PP 248 **THE ROLE OF PROGESTERONE ON PREGNANCY GINGIVITIS**  
Vera Radojkova-Nikolovska; M Popovska; Ana Minovska; B Dzipunova; Bruno Nikolovski  
FYROM
- 23/  
PP 269 **GRAPHITE TATTOO ON GINGIVA: A CASE REPORT**  
Murat Akkaya; Necmettin Yeta; Naz Yeta  
Turkey
- 24/  
PP 274 **FREE GINGIVAL GRAFTS TO INCREASE KERATINIZED TISSUE BEFORE DENTAL IMPLANT PLACEMENT: A CASE REPORT**  
Zeynep Taştan Eroğlu; Bülent Kurtiş  
Turkey
- 25/  
PP 299 **PERIODONTAL AND ODONTAL LESIONS IN PATIENTS WITH TYPE 1 DIABETES**  
Ana-Maria Rica; Dora Popescu; Lucian Dragomir; Anne-Marie Rauten; Petra Surlin  
Romania
- 26/  
PP 340 **PERIODONTAL PATIENT PROFILE; ATTITUDE AND SATISFACTION IN FINANCIAL CRISIS: PRELIMINARY STUDY**  
Konstantinos Tzimas; Maria Tsitsara; Georgios Chatzopoulos; Lazaros Tsalikis; Antonios Konstantinidis  
Greece
- 27/  
PP 363 **FRENECTOMY. IS THERE A CLINICAL SIGNIFICANCE NOWADAYS?**  
Anastasia Violesti; Dimitris Papalexioy; Antreas Grigoriadis; Antigone Delantoni; Ioannis Vouros  
Greece
- 28/  
PP 376 **SUBGINGIVAL TOOTH FRACTURE MANAGEMENT THROUGH CLINICAL CROWN LENGTHENING. A CASE REPORT**  
Theodoros Gkomoziyas; Dimitra Vakou; Dimitra Diomatari; Magdalini Kokkonis; Spiridon Silvestros  
Greece
- 29/  
PP 412 **ORAL HEALTH-RELATED QUALITY OF LIFE IN ROMANIAN PATIENTS WITH RHEUMATOID ARTHRITIS AND PERIODONTITIS**  
Roxana-Elena Tristiu; Bianca Dumitru; Liana Lascu; Anton Sculean; Raluca Cosgarea  
Romania
- 30/  
PP 459 **IMPLANT THERAPY IN THE PERIODONTALLY COMPROMISED PATIENT**  
Dimitra Kanakousaki; Ioannis Vouros  
Greece
- 31/  
PP 467 **SEVERITY OF PERIODONTAL DISEASE IN TYPE 2 DIABETES MELLITUS PATIENTS IN MURES COUNTY**  
Adriana Maria Monea; Bukhari Csilla; Lia Maria Yero Eremie; K. Ivacson; A. Csinszka; Gabriela Beresescu  
Romania
- 32/  
PP 490 **PERIODONTITIS-ORGAN (HEART)-TARGET CONCEPT – MODERN PARADIGM IN PERIODONTOLOGY**  
Victor Lacusta; Ion Lupan; Valeriu Burlacu; Valeriu Fala; Gheorghe Bordeniuc  
Republic of Moldavia
- 33/  
**AN AESTHETIC REHABILITATION OF A PATIENT WITH GENERALIZED CHRONIC PERIODONTITIS: A CASE**

- PP 509 **REPORT**  
Tugce Zeytinci; Gokce Dogar; Ayse Kocak-Buyukdere; Esra Guzeldemir-Akcakanat  
*Turkey*
- 34/  
PP 530 **EFFECT OF CURCUMIN AND EPIGALLOCATECHIN GALLATE ON STEM CELLS DERIVED FROM HUMAN PERIODONTIUM**  
Adina Bianca Bosca; Olga Soritau; Aranka Ilea; Radu Septimiu Campian; Alina Elena Parvu  
*Romania*
- 35/  
PP 563 **THE AWARENESS AND EFFECT OF SMOKING ON PERIODONTAL HEALTH AMONGST DENTAL STUDENTS**  
Cristala Nitescu; Marwa Arzoky; Mohammad Kabir Khan; Sorina Mihaela Solomon  
*Romania*
- 36/  
PP 564 **CHLORHEXIDINE GLUCONATE APPLICATION AND ITS INFLUENCE IN PATIENTS WITH PERIODONTITIS**  
Mirjana Popovska; Sahmedin Sali; Aneta Atanasovska-Stojanovska; Vera Radojkova-Nikolovska; Ilijana Muratovska  
*FYROM*
- 37/  
PP 570 **EFFECT OF PHOTOACTIVATED DISINFECTION IN TREATMENT OF AGGRESSIVE PERIODONTITIS**  
Gabriela Beresescu; Alina Ormenisan; Simona Mucenic; Alina Camarasan; Adriana Monea  
*Romania*
- 38/  
PP 580 **THE EFFECTS OF AGMATINE ON MITOCHONDRIAL MEMBRANE POTENTIAL IN RAT GINGIVAL FIBROBLASTS**  
Dragoş Daniel Acatrinei; Ancuţa Goriuc; Geanina Bogza; Decebal Vasincu; Marcel Costuleanu  
*Romania*
- 39/  
PP 581 **THE EFFECTS OF TYRPHOSTIN AG 1295 ON MITOCHONDRIAL MEMBRANE POTENTIAL IN RAT GINGIVAL FIBROBLASTS**  
Carmen Gentimir (Amititeloai); Ancuţa Goriuc; Geanina Bogza; Liliana Chelaru; Marcel Costuleanu  
*Romania*
- 40/  
PP 555 **TREATMENT OF A RARE ENDODONTIC COMPLICATION CAUSED BY A DENTAL MALPRACTICE: A CASE REPORT**  
Nazire Nurdan Çakir; Sezer Demirbuğa  
*Turkey*

11:20

13:20

## **ENDODONTOLOGY / LASER - Poster Presentations**

**P3**

Chairmen: Prof. Dr. NICOLAOS ECONOMIDIS

Prof. Dr. ANDREI ILIESCU

Dr. DJENAD GANJOLA

Secretary: Lecturer Dr. LIANA AMINOV

- 1/  
PP 21 **EVALUATION OF REINFORCEMENT EFFECT ON TEETH BY USING INTERNAL MATRIX COMBINED WITH MTA**  
Emre Bayram; Huda Melike Bayram; Hakan Eren  
*Turkey*
- 2/  
PP 52 **ENDODONTIC TREATMENT OF AN UNUSUAL MAXILLARY MOLAR TOOTH FUSED WITH A PARAMOLAR; A CASE REPORT**  
Arslan Terlemez; Melek Akman  
*Turkey*
- 3/  
PP 59 **HEMISECTION AS A TREATMENT OPTION AFTER ROOT FRACTURE ON MANDIBULAR MOLARS - A CASE REPORT**  
Elka Radeva; Tsonko Usunov  
*Bulgaria*
- 4/  
PP 81 **A CLINICAL CASE OF COMPLICATION BY SODIUM HYPOCHLORITE DURING ENDODONTIC TREATMENT**  
Aida Meto; Agron Meto; Emiljano Tragaj; Faustina Kola  
*Albania*
- 5/  
**NON-SURGICAL APICAL BARRIER FORMATION BY USING MTA IN TEETH WITH OPEN APEX AND NECROTIC**

- PP 78 **PULP**  
Melis Alav  
*Turkey*
- 6/  
PP 91 **USING MTA AS AN APICAL BARRIER IN A MAXILLARY INCISOR WITH INTERNAL RESORPTION**  
Hande Cinar; Funda Yilmaz; Melis Alav; Durmus Asicioglu; Esra Yaman  
*Turkey*
- 7/  
PP 98 **MANAGEMENT OF SECOND TRAUMATIC INJURED COMPLICATED CROWN ROOT FRACTURE PERMANENT MAXILLARY CENTRAL INCISOR**  
Bade Sonat; Meltem Öztan; Durmuş Aşicioğlu  
*Turkey*
- 8/  
PP 105 **PERIRADICULAR HEALING IN AN OPEN APEX MAXILLARY INCISOR BY USING MTA AS AN APICAL BARRIER**  
Durmuş Aşicioğlu  
*Turkey*
- 9/  
PP 152 **INVESTIGATION OF FRACTURE RESISTANCE OF ENDOCROWN AND DIFFERENT POST SYSTEMS**  
Hakki Celebi; Emre Korkut; Arslan Terlemez; Serhan Akman; Yağmur Sener  
*Turkey*
- 10/  
PP 155 **STUDY REGARDING SOME RADIOLOGICAL ASPECTS IN ROOT PERFORATIONS**  
Liana Aminov; Mihaela Salceanu; Anca Melian; Cristian Giuroiu; Maria Vataman; Michail Timotheatos,  
*Romania*
- 11/  
PP 167 **ENDODONTIC MANAGEMENT OF DENS INVAGINATUS: USING BIODENTINE AS AN APICAL BARRIER TECHNIQUE**  
Cansu Gür; Dilek Helvacioğlu Yigit  
*Turkey*
- 12/  
PP 178 **ENDODONTIC RETREATMENT OF S-SHAPED SECOND MAXILLARY PREMOLAR. A CASE REPORT**  
Christina Razcha; Thanasis Karampasis; Lampros Intzes; Nikos Oikonomidis; Kleoniki Liroudia  
*Greece*
- 13/  
PP 186 **EXPRESSION OF INTERLEUKIN-6 IN HUMAN CYTOMEGALOVIRUS INFECTED CHRONIC PERIAPICAL LESIONS**  
Jelena Popovic; Jovanka Gasic; Aleksandar Mitic; Marija Nikolic  
*Serbia*
- 14/  
PP 193 **EFFECT OF DIFFERENT IRRIGATION PROTOCOLS ON UNTOUCHED CANAL WALLS MORPHOLOGY: A SCANNING ELECTRON MICROSCOPIC STUDY**  
Jovanka Gasic; Radomir Barac; Jelena Popovic; Aleksandar Petrovic; Marija Nikolic  
*Serbia*
- 15/  
PP 216 **EVALUATION OF SMEAR LAYER REMOVING WITH CHEMICAL AND FIZICAL METHODS: SEM ANALYSIS**  
Ivona Kovacevska; Cena Dimova; Ana Radeska; Mihajlo Petrovski; Zlatko Georgiev  
*FYROM*
- 16/  
PP 236 **TREATMENT OF PERIAPICAL LESIONS BY THE CONSERVATIVE WAY**  
Maja Delic; Snezana Raznatovic; Danijela Subotic; Dzenad Ganjola  
*Montenegro*
- 17/  
PP 292 **EXTRUSION OF ROOT CANAL SEALER IN PERIAPICAL TISSUES. REPORT OF CASES WITH DIFFERENT TREATMENT MANAGEMENT**  
Athina Dalopoulou; Nikolaos Ekonomides  
*Greece*
- 18/  
PP 297 **ORTHOGRADE AND SURGICAL RETREATMENT IN A MOLAR OBTURATED WITH SILVER CONES. A CASE REPORT**  
Konstantinos Sidiropoulos; Nikolaos Economides  
*Greece*
- 19/  
PP 312 **EVALUATION OF THERMAL EFFECTS OF DIODE LASER ON ROOT CANAL DENTIN**  
Bagdagul Helvacioğlu Kivanc; Hacer Deniz Arisu; Baran Can Sağlam; Gulcin Akca; Guliz Gorgul



Turkey

- 20/  
PP 332 **THE ENDODONTIC RETREATMENT - ALWAYS THE FIRST SOLUTION WHEN TREATING CHRONIC APICAL PERIODONTITIS**  
Oana Andreea Diaconu; Lelia Gheorghita; Iren Moraru; Cristian Petcu; Mihaela Tuculina  
*Romania*
- 21/  
PP 335 **NON-SURGICAL ENDODONTIC MANAGEMENT OF UNILATERAL FUSED MANDIBULAR ANTERIOR INCISORS: A CASE REPORT**  
Seda Aydemir; Göze Arukaslan  
*Turkey*
- 22/  
PP 344 **COMPARATIVE ANALYSIS REGARDING SOME PHYSICO-CHEMICAL PROPERTIES OF ENDODONTIC SEALERS**  
Mihaela Salceanu; Anca Melian; Liana Aminov; Cristian Giuroiu; Maria Vataman  
*Romania*
- 23/  
PP 364 **THE ENDODONTIC MANAGEMENT OF PERMANENT MAXILLARY RIGHT CENTRAL INCISOR WITH LATERAL LUXATION: A CASE REPORT**  
Fevzi Buyukgebiz; Ismail Ozkocak; Hakan Gokturk  
*Turkey*
- 24/  
PP 99 **ROOT CANAL MORPHOLOGY OF THE MAXILLARY SECOND PREMOLARS**  
Brankica Davidovic; Nikola Stojanovic; Svjetlana Jankovic; Bojana Davidovic; Ivana Simic  
*Bosnia and Herzegovina*
- 25/  
PP 498 **CONVENTIONAL ENDODONTIC THERAPY COMBINED WITH SURGICAL DECOMPRESSION IN THE TREATMENT OF RADICULAR CYST**  
Anca Melian; Mihaela Salceanu; Cristian Giuroiu; Gabriel Melian  
*Romania*
- 26/  
PP 507 **RESTORATION OF COMPLICATED CROWN-ROOT FRACTURE WITH FIBER POST SYSTEM: CASE REPORT**  
Ahmet Akti; Melek Hilal Kaplan; Hüseyin Sinan Topçuoğlu  
*Turkey*
- 27/  
PP 510 **THE CYCLIC FATIGUE RESISTANCE OF D-RACE AND PROTAPER RETREATMENT INSTRUMENTS IN CURVED ARTIFICIAL CANALS**  
Gamze Topçuoğlu; H.Sinan Topçuoğlu; Ahmet Akti  
*Turkey*
- 28/  
PP 529 **TREATMENT OF PERIAPICAL LESIONS. A CASE REPORT**  
Rodica Bodea; Diana Gaspar; Alexandru Jianu; Rodica Jianu  
*Romania*
- 
- 29/  
PP 82 **ANTIMICROBIAL ACTIVITY OF PHOTODYNAMIC THERAPY AND FOTOSAN**  
Violeta Dogandzhiyska Dimotrova; Slavcho Dimitrov; Tsonko Uzunov  
*Bulgaria*
- 30/  
PP 88 **INVESTIGATION OF ANTIBACTERIAL ACTIVITY OF PAD WITH FOTOSAN; ND:YAG LASER AND CONVENTIONAL ENDODONTIC TREATMENT.**  
Tzvetelina Gueorgieva; Slavcho Dimitrov; Raina Gergova  
*Bulgaria*
- 31/  
PP 107 **MANAGEMENT OF BENIGN TUMOR OF OROMAXILLOFACIAL AREA WITH 980 NM DIODE LASER**  
Merita Bardhoshi; Esat Bardhoshi; Edit Xhajanka; Alketa Qafmolla; Neada Hysenaj  
*Albania*
- 32/  
PP 128 **THE 980 NM DIODE LASER: A GOOD MODALITY FOR THE TREATMENT OF PROMINENT FRENULUM**  
Elton Gjini; Merita Bardhoshi; Esat Bardhoshi; Alketa Qafmolla; Neada Hysenaj  
*Albania*
- 33/  
PP 191 **INVESTIGATION OF ANTIBACTERIAL ACTIVITY OF PAD WITH FOTOSAN; ND:YAG - LASER AND STANDARD ENDODONTIC TREATMENT**  
Tzvetelina Gueorgieva; Slavcho Dimitrov; Raina Gergova

*Bulgaria*

34/ **OVERFILLING OF ENDODONTIC MATERIAL INTO THE MANDIBULAR CANAL: A CASE REPORT**

PP 218 Evgeniya Popova; Violeta Dogandzhiyska; Tsonko Uzunov; Pelo Pelov

*Bulgaria*

35/ **LABIAL FRENECTOMY USING ER,CR:YSSG LASER (2780NM)- CASES REPORT**

PP 228 Afrodite Chalkidou; Eirini Athanasiadou; Konstantinos Arapostathis

*Greece*

36/ **IS MANDIBULAR ANESTHESIA TOO RISKY?**

PP 250 Suzan Bayer; Ameer Shani Dahhan; Nihat Demirtaş; Gamze Er

*Turkey*

37/ **MENTAL NERVE PARESTHESIA TREATMENT OF AN OLD LADY**

PP 251 Suzan Bayer; Ameer Shani Dahhan; Nihat Demirtaş; Gamze Er

*Turkey*

38/ **LOW LEVEL LASER THERAPY IN POSTSURGICAL TREATMENT OF GRAFTED SOCKETS**

PP 463 Adriana Maria Monea; Gabriela Beresescu; Florentin Berneanu; Sorin Popsor

*Romania*

**15:00 REMOVABLE PROSTHODONTICS / GERODONTOLOGY / ORAL DIAGNOSIS – ORAL  
17:20 RADIOLOGY - Poster Presentations**

**P5**

Chairmen: Prof. Dr. SANDA MIHAELA POPESCU

Prof. Dr. MONICA TATARCIUC

Assoc. Prof. Dr. VALENTINA TRIFAN

Dr. ALEXANDRU BREZOESCU

Secretary: Lecturer Dr. MIHAELA MONICA SCUTARIU

1/ **THE INFLUENCE OF SMOKING ON DENTURE STOMATITIS INCIDENCE**

PP 65 Snezana Radisic; Slobodan Ivic

*Serbia*

2/ **PROSTHETIC REHABILITATION OF PATIENT WITH BILATERAL TEMPROMANDIBULAR JOINT ANKYLOSIS:  
CLINICAL REPORT**

PP 73 Betül Kökdoğan Boyacı

*Turkey*

3/ **EFFECTS OF A CUSTOM MANDIBULAR ADVANCEMENT DEVICE ON THE UPPER AIRWAY OF A SEVERE OSA  
PATIENT**

PP 147 Bulent Piskin; Bahadir Ezmek; Alper Uyar

*Turkey*

4/ **COMPLEX ORODENTAL REHABILITATION IN ELDERLY PACIENTS**

PP 151 Mihaela Romanita Gligor; Mihaela Cernusca Mitariu

*Romania*

5/ **DETERMINING THE JAW RELATION IN TOTAL REMOVABLE DENTURES THROUGH INSTRUMENTAL METHODS**

PP 159 Edit Xhajanka; Gerta Kaçani; Merita Bardhoshi; Endri Paparisto; Neada Hysenaj

*Albania*

6/ **PIESOGRAPHIC IMPRESSION AND ITS USAGE IN TOTAL REMOVABLE DENTURES**

PP 161 Edit Xhajanka; Gerta Kaçani; Merita Bardhoshi; Endri Paparisto

*Albania*

7/ **3D LASER SCANNING FOR ASSESSMENT THE FACIAL SURFACE CHANGES OF EDENTULOUS PATIENTS AFTER  
PROSTHETIC REHABILITATION**

PP 169 Anca Jivanescu; Dana Cristina Bratu; Alexandra Maroiu; Lucian Tomescu; Emanuel Bratu

*Romania*

8/ **KNOWLEDGE OF DENTURE ADHESIVES IN ALBANIAN DENTISTS**

- PP 220 Neada Hysenaj; Merita Bardhoshi; Edit Xhajanka; Suela Tabaku; Florion Tabaku  
*Albania*
- 9/  
PP 276 **TASTE DISSATISFACTION CORRELATED FACTORS IN ELDERLY PATIENTS WITH COMPLETE DENTURES**  
Katerina Zlatanovska; Julija Zarkova; Ana Radeska; Cena Dimova; Kiro Papakoca  
*FYROM*
- 10/  
PP 284 **IMMUNOHISTOCHEMICAL STUDY OF PAPILOMATOSIS GINGIVAL MUCOSA IN PATIENT WITH DENTURE INDUCED STOMATITIS**  
Veronica Mercut; Monica Scieru; Sanda Mihaela Popescu; Diana Lucia Diaconu; Mihaela Niculescu  
*Romania*
- 11/  
PP 324 **SOFT RELINING MATERIALS – AN AID IN OVERCOMING DIFFICULT CLINICAL SITUATIONS**  
Ilian Hristov; Hristo Kisov; Boyan Pavlov; Stefan Zlatev; Yosif Stanev  
*Bulgaria*
- 12/  
PP 356 **FABRICATING FINAL PROSTHETIC RESTORATION OF CLEFT PALATE PATIENT AFTER DISTRACTION SURGERY**  
Betül Kökdoğan Boyacı; Mustafa Kocacikli  
*Turkey*
- 13/  
PP 373 **DURABILITY ORAL REHABILITATION OF PATIENTS TREATED WITH REMOVABLE PARTIAL DENTURES WITH BALL ATTACHMENT SYSTEM**  
Claudiu Vasile Horga; Carmen Ioana Biris; Diana Pop; Radu Horea Bostan; Mircea Suci  
*Romania*
- 14/  
PP 378 **COMPLETE DENTURE REHABILITATION OF A PATIENT WITH ORAL MUCOSAL HYPERPLASIA AND PARKINSON'S DISEASE. CASE PRESENTATION**  
Monica Mihaela Craitoiu; Claudiu Margaritescu  
*Romania*
- 15/  
PP 461 **COMPARATIVE EVALUATION OF DIMENSIONAL CHANGES OF THREE COMMERCIALY AVAILABLE HEAT CURING RESINS**  
Armand Alushi  
*Albania*
- 16/  
PP 484 **PROSTHETIC REHABILITATION OF A PATIENT WITH WORN UPPER TEETH AND EDENTULOUS MANDIBLE**  
Eda Ozdere; Mehmet Fatih Tuncer  
*Turkey*
- 179/  
PP 491 **EARLY IDENTIFICATION OF BRUXISM SIGNS AND SYMPTOMS FOR PREVENTION OF TEMPOROMANDIBULAR DYSFUNCTIONS**  
Valeriu Fala; Vitalie Gribenco; Lilian Nistor; Vitalie Pantea.; Iulian Ursu  
*Republic of Moldavia*
- 18/  
PP 521 **LEAF-GAUGE TECHNIQUE FOR RECORDING CENTRIC RELATION IN PATIENTS WITH TEMPORO-MANDIBULAR DISORDERS**  
Vitalie Pântea; Oleg Solomon; Vitalie Gribenco; Daniela Chirița; Roșca Cristina  
*Republic of Moldavia*
- 19/  
PP 499 **EVALUATION OF ORAL FUNCTION AND ORAL HEALTH AFTER REMOVABLE PARTIAL – CLINICAL STUDY IN FACULTY OF DENTAL MEDICINE IN IASI; ROMANIA**  
Dan Nicolae Bosinceanu; Dana Gabriela Bosinceanu; Amelia Surdu ; Norina Consuela Forna  
*Romania*
- 20/  
PP 500 **ASSESSMENT OF PARTIAL DENTURE WEARERS SATISFACTION IN RELATION TO GENERAL AND LOCAL FACTORS**  
Dana Gabriela Bosinceanu; Dan Nicolae Bosinceanu; Alexandru Brezoescu; Norina Consuela Forna  
*Romania*
- 21/  
PP 511 **MASTICATORY FUNCTION IN PATIENTS WITH REMOVABLE PROSTHESIS-LITERATURE REVIEW**  
Alexandra Melania Oncescu Moraru; Cristina Teodora Preoteasa; Catalina Murariu-Magureanu; Cristina-Diana Rizea; Elena Preoteasa  
*Romania*

- 22/ **SEM ANALYSIS OF IMPLANT SYSTEMS DESIGNED FOR INCREASING REMOVABLE PROSTHESIS RETENTION**  
 PP 512 Daniela Mihaela Meghea; Cristina Teodora Preoteasa; Mihaela Marin; Elena Preoteasa  
*Romania*
- 23/ **PREDICTIVE ANALYSIS OF SURFACE QUALITY-CANDIDA ALBICANS BIOFILM RELATIONS**  
 PP 546 Elena-Raluca Baci; Irina Grădinaru; Ștefan Toma; Constantin Baci; Norina Consuela Fornă  
*Romania*
- 24/ **THE CLINICAL-TECHNOLOGICAL ALGORITHM OF EXTENDED EDENTATION REHABILITATION - CASE REPORT**  
 PP 550 Irina Grădinaru; Raluca Elena Baci; Norina Consuela Fornă  
*Romania*
- 25/ **DENTAL STUDENT EMPLOYABILITY PROFILE**  
 PP 558 Ramona Feier; Cristina Gena Dascalu; Andreea Zoderu; Norin Fornă  
*Romania*
- 26/ **COMPLEX ORAL REHABILITATION WITH REMOVABLE FLEXIBLE PROSTHESIS FOR A SCHIZOPHRENIA PATIENT**  
 PP 562 Elena Mc Adam; Carole Mahler; Julie Muller; Michail Timotheatos; Nicoleta Ioanid  
*Romania*
- 27/ **PSYCHOSOMATIC INTEGRATION OF PATIENTS WITH REMOVABLE PARTIAL DENTURES**  
 PP 574 Cosmin Oniciuc; Manuela Ciocoiu; Ruxandra Savinescu; Larisa Tarievici; Mirela Leonte; Dana Lazaruc;  
 Norina Fornă  
*Romania*
- 
- 28/ **REMOVABLE PROSTHESES IN 2015**  
 PP 319 Luciana Goguta; Anca Jivanescu; Emanuel Bratu; Corina Marcauteanu; Maroiu Alexandra  
*Romania*
- 29/ **ORAL HEALTH AND QUALITY OF LIFE OF GERIATRIC POPULATION IN RM**  
 PP 335 Natasha Stavreva; Ljubica Simjanovska; Mirjana Markovska Arsovska  
*FYROM*
- 30/ **ADDRESSABILITY OF THE ELDERLY TO DENTAL CARE**  
 PP 250 Mihaela Monica Scutariu; Dragos Fratila; Amelia Surdu; Georgiana Macovei  
*Romania*
- 
- 31/ **TONSILLOLITH OF PALATINE TONSILS: A CASE REPORT**  
 PP 20 Ali Altindag; Mehmet Hakan Kurt; Mehmet Eray Kolsuz  
*Turkey*
- 32/ **DENTIGEROUS CYST ASSOCIATED WITH MANDIBULAR CANINE : A CASE REPORT**  
 PP 90 Gülsüm Kösten; Ali Hanttash; Kaan Orhan  
*Turkey*
- 33/ **A RARE CASE OF HYALINIZING CLEAR CELL CARCINOMA IN THE MAXILLA**  
 PP 96 Ersun Gushi; Kaan Orhan; Umut Seki  
*Turkey*
- 34/ **INCIDENTAL FINDING OF AN ECTOPIC IMPACTED TOOTH IN MAXILLARY SINUS**  
 PP 106 Hilal Demir; Füsün Yaşar  
*Turkey*
- 35/ **EFFECTS OF SYSTEMIC DISEASES AND MEDICATION ON SALIVARY FLOW AND SUBJECTIVE ORAL DRYNESS**  
 PP 130 Mehmet Oğuz Borahan; Filiz Namdar Pekiner; Turhan Atalay  
*Turkey*
- 36/ **MONOSTATIC FIBROUS DYSPLASIA: A CASE REPORT**  
 PP 145 Aydan Keles; Kivanc Kamburoglu; Rana Nalcaci; Burcu Kirsan  
*Turkey*
- 37/ **THE ADVANTAGES OF USING CBCT IN MANAGEMENT OF PERIAPICAL LESIONS**  
 PP 166 Bogdan Dobrovat; Ioana Radu; Roxana Popescu; Danisia Haba  
*Romania*

38/ **TRANSMIGRATIONS OF MANDIBULAR CANINES: TWO CASE REPORTS**  
PP 219 Kadir Kaplanoglu  
*Turkey*

**17:20**  
**19:20** **PAEDIATRIC DENTISTRY / PREVENTIVE DENTISTRY - Poster Presentations**

**P7**

Chairmen: Prof. Dr. MAIDA GANIBEGOVIĆ  
Assoc. Prof. Dr. ADRIANA BALAN  
Secretary: Assoc. Prof. Dr. VASILICA TOMA

- 1/ **MULTIDISCIPLINARY TREATMENT OF AN AVULSED TOOTH: CASE REPORT**  
PP 6 Emre Korkut; Arslan Terlemez; Hakki Celebi; Yagmur Sener  
*Turkey*
- 2/ **COMPLICATED CROWN FRACTURE WITH IMMATURE ROOT DEVELOPMENT – A CASE REPORT**  
PP 49 Zoran Mandinic; Ana Vukovic; Momir Carevic; Jelena Mandic; Svetlana Novakovic  
*Serbia*
- 3/ **ETIOLOGY OF TRAUMATIC DENTAL INJURIES IN CHILDREN IN JAGODINA DISTRICT; SERBIA**  
PP 162 Marko Jeremic; Ana Vukovic; Dejan Markovic  
*Serbia*
- 4/ **TREATMENT OF TWO CASES OF EARLY CHILDHOOD CARIES UNDER GENERAL ANESTHESIA**  
PP 85 Eirini Athanasiadou; Anastasia Dermata; Afroditi Chalkidou; Konstantinos Arapostathis  
*Greece*
- 5/ **FEAR OF DENTAL TREATMENT IN CHILDREN**  
PP 92 Snezana Matijevic  
*Montenegro*
- 6/ **INFLUENCE OF RISK FACTORS FOR CARIES IN DEAF CHILDREN FROM SOFIA CITY; BULGARIA**  
PP 101 Liliya Doichinova; Milena Peneva; Peter Bakardjiev  
*Bulgaria*
- 7/ **SUSCEPTIBILITY OF DENTAL BIOFILM TO PHOTODYNAMIC THERAPY: AN IN VITRO STUDY**  
PP 103 Victor Grecu; Aurelia Spinei  
*Republic of Moldavia*
- 8/ **NUTRITIONAL HABITS AND DENTAL CARIES IN PRESCHOOL CHILDREN**  
PP 110 Peter Bakardjiev; Milena Peneva; Liliya Doichinova  
*Bulgaria*
- 9/ **MANAGEMENT OF A SEVERE EXTERNAL ROOT RESORPTION OF AN AVULSED MAXILLARY PERMANENT INCISOR WITH MTA**  
PP 144 Emine Kaya; Mesut Elbay; Ülkü Sermet Elbay  
*Turkmenistan*
- 10/ **EFFICIENCY OF MEDICATIONS ON REGENERATIVE CAPACITY OF GINGIVA AFTER FRENECTOMY**  
PP 154 Jelena Mandic; Zoran Mandinic; Dusan Kosanovic  
*Serbia*
- 11/ **PAEDODONTO-ORTHODONTIC INTEGRATIVE INTERFERENCES: EARLY CHILDHOOD CARIES**  
PP 156 Dana Cristiana Maxim; Ionut Luchian; Liana Aminov; Christina Markomanolaki; Veronica Pintiliciuc Serban  
*Romania*
- 
- 12/ **THERAPEUTIC ALTERNATIVES IN CHILDEN WITH MIH SYNDROME**  
PP 160 Dana Cristiana Maxim; Eugeniu Mihalas; Daniel Cioloca; Evangelia Vailaki; Ana Petcu  
*Romania*
- 13/ **COMPOSITE RESIN RESTORATION OF TURNER'S TOOTH – CASE REPORT**  
PP 226 Lejla Delić; Tanja Pejčinović-Janeček; Sedin Kobašlija; Elmedin Bajrić  
*Bosnia and Herzegovina*

- 14/ **IMPORTANCE OF ORAL-DENTAL ABNORMALITIES FOR THE DIAGNOSIS OF RARE GENETIC DISORDERS**  
PP 247 Cihan Alp Sonmez; Sibel Yildirim  
*Turkey*
- 15/ **PERIODONTAL HEALTH IN PATIENTS WITH ELEVATED BODY MASS**  
PP 306 Svjetlana Jankovic; Bojana Davidovic; Brankica Davidovic; Mirjana Ivanovic; Mihael Stanojevic  
*Bosnia and Herzegovina*
- 16/ **PARTICULARITIES OF THE CHEMICAL COMPOSITION OF DENTAL ENAMEL IN CHILDREN WITH SEVERE NEUROLOGICAL DISEASES**  
PP 310 Olga Bălteanu; Aurelia Spinei; Svetlana Plamadeală  
*Republic of Moldavia*
- 17/ **THE DENTAL HEALTH IN THE EARLY CHILDHOOD IN PARTICIPANTS FROM SKOPJE**  
PP 318 S Nashkova; J Alimani- Jakupi; F Veninov; S Iljovska; T Kutlovci  
*FYROM*
- 18/ **PARTICULARITIES OF THE ORAL LIQUID'S MICROCRYSTALLIZATION IN CHILDREN WITH DENTAL CARIES**  
PP 336 Svetlana Plamadeală; Aurelia Spinei; Olga Bălteanu  
*Republic of Moldavia*
- 19/ **ORAL HEALTH IN CHILDREN WITH DIABETES MELLITUS TYPE I**  
PP 362 Mirjana Djurickovic  
*Montenegro*
- 20/ **SOCIOLOGICAL SURVEY AMONG THE BULGARIAN DENTISTS FOR THEIR READINESS TO TREAT CHILDREN WITH TALASSEMIA MAJOR**  
PP 380 Hristo Bozukov; Veselina Kondeva; Nina Milcheva; Radosveta Andreeva  
*Bulgaria*
- 21/ **COMPARISON OF ANTHROPOMETRIC AND CALIPERIMETRIC DATA OF ACTIVE ATHLETIC AND NON ACTIVE CHILDREN AND ADOLESCENTS**  
PP 381 Aleksandar Atanasovski; Veselina Kondeva; Velina Stoeva  
*Bulgaria*
- 22/ **SOCIOLOGICAL SURVEY AMONG THE BULGARIAN DENTISTS FOR THEIR READINESS TO USE SPACE MAINTAINERS**  
PP 396 R Andreeva; A Belcheva; H Bozukov; N Milcheva; H Arnautska  
*Bulgaria*
- 23/ **ERUPTED UNILATERAL SUPPLEMENTAL PRIMARY MAXILLARY LATERAL TOOTH IN A NON-SYNDROMIC CHILD**  
PP 419 Baris Karabulut; Alper Kaya  
*Turkey*
- 24/ **PLAGICEPHALY INCIDENCE IN SCHOOLS OF THE REPUBLIC OF MOLDOVA WITH SPECIAL EDUCATIONAL NEEDS**  
PP 429 Silvia Railean; Ion Lupan  
*Republic of Moldavia*
- 25/ **TREATMENT OF REVERSIBLE PULPITIS IN PRIMARY TEETH WITH INDIRECT OR DIRECT PULP CAPPING**  
PP 430 Nina Milcheva; Rositsa Kabaktchieva  
*Bulgaria*
- 26/ **NON NUTRITIVE ORAL HABITS IN PRESCHOOL-AGED CHILDREN**  
PP 496 Afroditi Chalkidou; Eirini Athanasiadou\*; Victoria Adamidou  
*Greece*
- 27/ **DIAGNOSIS AND TREATMENT OPTIMIZATION IN HERPETIC STOMATITIS**  
PP 505 Diana Uncuta  
*Republic of Moldavia*
- 
- 28/ **VISITS TO THE DENTIST**  
PP 97 Bojana Davidovic; Svjetlana Jankovic; Mirjana Ivanovic; Mihael Stanojevic; Brankica Davidovic

- 29/  
PP 139 **ASSOCIATION STUDY FOR THE ROLE OF GLUT2 GENE IN CARIES SUSCEPTIBILITY; DIETARY HABITS AND BMI**  
Dobrina Karayasheva; Maria Glushkova; Ekaterina Boteva; Vanio Mitev; Tania Kadiyska  
*Bulgaria*
- 30/  
PP 281 **FLUORIDE RELEASE AND RECHARGE ABILITIES OF NEW DENTAL SEALANTS**  
Thrasyvoulos Sfeikos; Dimitrios Dionysopoulos; Kosmas Tolidis  
*Greece*
- 31/  
PP 309 **NO ASSOCIATION BETWEEN EMPLOYMENT, UNEMPLOYMENT AND RETIREMENT WITH PERIODONTAL HEALTH STATUS IN AN OLDER POPULATION**  
Efthymia Chalvatzoglou; Georgios Chatzopoulos; Lazaros Tsalikis  
*Greece*
- 32/  
PP 317 **EFFECTS OF DIFFERENT FACTORS ON DMFT COMPONENTS OF TURKISH ADOLESCENTS**  
Said Karabekiroğlu; Merve Yildiz; Nimet Ünlü  
*Turkey*
- 33/  
PP 320 **WHICH FACTORS AFFECTING ADOLESCENTS TOOTH BRUSHING PATTERN?**  
Said Karabekiroğlu; Merve Yildiz; Elif Öncü; Nimet Ünlü  
*Turkey*
- 34/  
PP 517 **SMOKING EFFECTS ON ORAL HEALTH: COMPARISON OF CLINICAL PERIODONTAL PARAMETERS OF SMOKERS AND NONSMOKERS**  
Tatiana Porosencova; Valeriu Burlacu  
*Republic of Moldavia*

*INTERCONTINENTAL HOTEL, FORTUNA HALL Section B*

09:00  
11:00

**RESTORATIVE AND ADHESIVE DENTISTRY - Poster Presentations**

**P2**

Chairmen: Dr. NEJAT ARPAK  
Assoc. Prof. Dr. VALERIU FALA  
Secretary: Lecturer Dr. SIMONA STOLERIU

- 1/  
PP 46 **CLINICAL SUCCESS OF TWO MATERIAL ON DIRECT PULP CAPPING**  
Mehmet Sahin Oguzcan; Ismail Hakki  
*Turkey*
- 2/  
PP 55 **EFFECT OF BORIC ACID APPLICATION ON MICROLEAKAGE OF DIFFERENT ADHESIVE SYSTEMS**  
Ertugrul Ercan; Damla Ibrahimov; Esra Gulal; M. Mustafa Hamidi  
*Turkey*
- 3/  
PP 56 **MICROLEAKAGE OF BULK-FILL COMPOSITE RESIN RESTORATIONS IN CERVICAL CAVITY PREPERATIONS**  
Yusuf Bayraktar; Aliihsan Erkan; Ertuğrul Ercan  
*Turkey*
- 4/  
PP 57 **COMPARISON OF SHEER BOND STRENGTH OF BULK FILL COMPOSITES WITH POSTERIOR COMPOSITES**  
Ertugrul Ercan; Abdulkadir Sengun; Damla Ibrahimov; Esra Gulal; M. Mustafa Hamidi  
*Turkey*
- 5/  
PP 58 **THE INVESTIGATION OF CAVITY ADAPTATION OF CAD/CAM INLAY SYSTEMS BY SILICON REPLICA TECHNIQUE**  
Abdulkadir Şengün; Berna Arfat; Damla Doğan; Esra Üzümcü  
*Turkey*
- 6/  
PP 60 **EFFECTS OF FILLING TECHNIQUES ON MICROLEAKAGE OF CLASS II RESTORATIONS: ER:YAG LASER VERSUS BUR PREPARATION**  
Emre Ozel; Elif Bahar Tuna; Erhan Firatli

Turkey

- 7/  
PP 62 **ESTHETIC AND FUNCTIONAL REHABILITATION OF AMELOGENESIS IMPERFECTA WITH DIRECT COMPOSITE RESTORATIONS: REPORT OF FOUR CASES**  
Neslihan Tekce; Gizem Guder; Mustafa Demirci; Safa Tuncer; Alper Sinanoglu  
Turkey
- 8/  
PP 63 **TREATMENT OF MODERATE FLUOROSIS WITH COMBINED BLEACHING PROTOCOLS**  
Ismail Hakki Baltacioglu; Ruhsan Müdüroğlu  
Turkey
- 9/  
PP 104 **RESTORATIVE THERAPY OF EROSION**  
Natasha Denkova; Ivona Kovacevska; Slobodan Rushkovski; Sanja Nashkova  
Turkey
- 10/  
PP 108 **CONSERVATIVE TREATMENT APPROACH FOR ANTERIOR DENTAL EROSION: REPORT OF TWO CASES**  
Hale Karakuyu; Aslihan Gokturk; Neslihan Tekce; Emre Ozel  
Turkey
- 11/  
PP 111 **A MULTIDISCIPLINARY APPROACH FOR REHABILITATING A PATIENT WITH UNSUCCESSFUL TREATMENT HISTORY: A CASE REPORT**  
Bade Sonat; Ayşegül Köklü; Asli Şenol; İsmail Baltacıoğlu  
Turkey
- 12/  
PP 119 **DIRECT TECHNIQUE FOR RESTORING THE ESTHETIC APPEARANCE OF PEG-SHAPED LATERAL INCISORS**  
Aslihan Gokturk; Emre Ozel  
Turkey
- 13/  
PP 121 **RESTORATION OF A MAXILLARY ANTERIOR TOOTH SPACE USING FIBER-REINFORCED COMPOSITE AND THE PATIENT'S OWN TOOTH**  
Fatih Mehmet Korkmaz; Esra Baltacioglu; Yavuz Tolga Korkmaz; Guven Aydin; Bora Bagis  
Turkey
- 14/  
PP 122 **CARIES INFILTRATION OF PROXIMAL ENAMEL LESIONS WITH RESINS. A CLINICAL GUIDELINE.**  
Panagiotis Ntovas; Christos Rahiotis  
Greece
- 15/  
PP 123 **REHABILITATION SMILE HARMONY WITH CONSERVATIVE APPROACH AND DIRECT COMPOSITE PLACEMENT: REPORT OF THREE CASES**  
Merve Efe-Serim; Emre Ozel  
Turkey
- 16/  
PP 127 **TEN MONTHS IN VITRO EVALUATION OF MARGINAL ADAPTATION OF THREE LOW-SHRINKAGE RESIN COMPOSITES**  
Sevda Yantcheva; Radosveta Vasileva  
Bulgaria
- 17/  
PP 131 **ELIMINATION OF DIASTEMAS ON MAXILLARY ANTERIOR REGION WITH MINIMAL INVASIVE REHABILITATION: A CASE REPORT**  
Betul Aka; Bilal Yasa; Serhat Koseoglu; Esra Uzer Celik  
Turkey
- 18/  
PP 132 **AN ENDODONTICALLY TREATED MOLAR RESTORED WITH RESIN NANOCERAMIC CAD/CAM ENDOCROWN: A CASE REPORT**  
Fatma Yilmaz; Bilal Yaşa; Esra Uzer Çelik  
Turkey
- 19/  
PP 137 **COMPARISON OF ADHESIVE MATERIALS IN CLASS V COMPOSITE RESTORATIONS PREPARED BY ER:YAG LASER AND BUR**  
Emre Ozel; Elif Bahar Tuna; Erhan Firatli  
Turkey
- 20/  
PP 143 **TREATMENT OF ADOLESCENT RAMPANT CARIES WITH GIOMER RESTORATIONS**  
Gürkan Gür; Gülbike Demirel



Turkey

- 21/  
PP 148 **OVERLAYS AND “TABLE TOPS” IN PATIENTS WITH PATHOLOGIC ATTRITION. A 3D FINITE ELEMENT ANALYSIS**  
Corina Marcauteanu; Florin Topala; Eniko Tunde Stoica; Cosmin Sinescu; Meda Negrutiu  
*Romania*
- 22/  
PP 149 **PRESSED ALL-CERAMIC PARTIAL CROWNS IN PATIENTS WITH DENTAL EROSION. A 3D FINITE ELEMENT METHOD STUDY**  
Eniko Tunde Stoica; Florin Topala; Corina Marcauteanu; Cosmin Sinescu; Meda Negrutiu  
*Romania*
- 23/  
PP 171 **MISSING ANTERIOR TEETH TREATMENT WITH FIBER-REINFORCED COMPOSITE BRIDGES: TWO CASE REPORTS**  
Nuray Gunaydin; Derya Dinc; Hayriye Esra Ulker  
*Turkey*
- 24/  
PP 172 **INDIRECT COMPOSITE INLAY RESTORATIONS: CASE REPORT**  
Nuray Gunaydin; Ali Riza Cetin  
*Turkey*
- 25/  
PP 184 **TREATMENT OF CONGENITALLY MISSING LATERAL INCISOR WITH DIRECT COMPOSITE VENEER: CASE REPORT**  
Fikret Yilmaz; Umut Misilli  
*Turkey*
- 26/  
PP 194 **IN VITRO EFFECT OF SOME ALCOHOLIC BEVERAGES ON DENTAL ENAMEL SURFACE MORFOLOGY AND SURFACE ROUGHNESS**  
Radomir Barac; Jovanka Gasic; Jelena Popovic; Aleksandar Mitic; Marija Nikolic  
*Serbia*
- 27/  
PP 196 **COMPARISON OF SURFACE ROUGHNESS OF THREE BULK AND ONE POSTERIOR RESIN COMPOSITE**  
Ali Ihsan Erkan; Yusuf Bayraktar; Selin Bilgin; Ertuğrul Ercan  
*Turkey*
- 28/  
PP 198 **USING PATIENT’S OWN TEETH BY USING RIBBOND: CASE REPORT**  
Ali İhsan Erkan  
*Turkey*
- 29/  
PP 199 **COMBINATION OF OFFICE BLEACHING AND COMPOSITE VENEER AT TREATMENT OF FLOROSIS: CASE REPORT**  
Ali İhsan Erkan  
*Turkey*
- 30/  
PP 230 **BLEACHING OF DISCOLOURED; ENDODONTICALLY TREATED ANTERIOR TEETH: 2 CASE REPORT**  
Derya Dinç; Nevin Cobanoglu; Murat Selim Botsali  
*Turkey*
- 31/  
PP 232 **DIASTEMA CLOSURE AND VITAL DENTAL BLEACHING**  
Mehmet Tarticj; Ruhsan Müdüroğlu; Gürkan Gür  
*Turkey*
- 32/  
PP 280 **WHAT ARE ALBANIANS REQUIREMENTS FROM AESTHETIC DENTISTRY?**  
Rozafa Dragusha; Livio Gallottini; Ruzhdie Qafmolla  
*Albania*
- 33/  
PP 287 **TEN MONTHS IN VITRO EVALUATION OF MARGINAL ADAPTATION OF THREE LOW-SHRINKAGE RESIN COMPOSITES**  
Sevda Yantcheva; Radosveta Vasileva  
*Bulgaria*
- 34/  
PP 314 **EXPERIMENTAL TIP FOR SONIC HANDPIECE FOR ANATOMICAL ROOT CANAL PREPARATION**  
Stiliyan Hristov; Hristo Kisov; Stoyan Yankov; Daniel Dimitrov; Dobromira Shopova  
*Bulgaria*

- 35/  
PP 330 **CORRELATION BETWEEN THE APPLICATION OF FLUORIDE PROPHYLAXIS AND THE STATE OF ORAL HEALTH**  
Natasha Denkova; Snezana Iljovska; Mihajlo Petrovski  
*FYROM*
- 36/  
PP 386 **PRESENTATION OF AN AESTHETIC RESTORATION IN THE ANTERIOR ZONE WITH ZIRCONIUM ¾ CROWNS**  
Maria Hatziparaskeva; Anastasios Petridis  
*Greece*
- 37/  
PP 390 **STUDY REGARDING THE SALIVARY MICROCRYSTALLIZATION INDEX VARIATION ON THE PATIENTS HAVING DENTAL EROSION LESIONS**  
Galina Pancu; Sorin Andrian; Irina Nica; Antonia Moldovanu; Simona Stoleriu  
*Romania*
- 38/  
PP 399 **STUDY REGARDING THE INFLUENCE OF DIFFERENT TOOTHPASTES ON SURFACE ROUGHNESS OF COMPOSITE RESINS**  
Simona Stoleriu; Galina Pancu; Gianina Iovan; Claudiu Topoliceanu; Sorin Andrian  
*Romania*
- 39/  
PP 449 **THE EFFECT OF DESENSITIZING AGENT ON MICROLEAKAGE OF ADHESIVE AGENT**  
Şeyda Hergüner Siso; Nazmiye Dönmez; Büşra Kabadayi  
*Turkey*
- 40/  
PP 451 **FIBER POSTS - SIGNIFICANT FACTOR IN AESTHETIC AND FUNCTIONAL REHABILITATION OF ENDODONTIC TREATED TEETH**  
Vesna Jurukovska Shotarovska; Biljana Kapushevaska; Sasho Jovanovski; Aneta Mijoska; Daniela Cvetanovska  
Stojceva  
*FYROM*
- 41/  
PP 453 **THE EFFECT OF DESENSITIZING AGENT ON MICROLEAKAGE OF ADHESIVE AGENT**  
Şeyda Hergüner Siso; Nazmi Yedonmez; Büşra Kabadayi  
*Turkey*
- 42/  
PP 506 **COMPARISON OF MICROLEAKAGE ON DIFFERENT RESTORATIVE MATERIALS AT CLASS II CAVITES: AN IN VITRO STUDY**  
Melek Hilal Kaplan; Yahya Orçun Zorba; Hatice Parlak  
*Turkey*
- 43/  
PP 518 **IN-VITRO ANTIBACTERIAL EFFECTS OF TWO DENTINE PRIMERS CONTAINING FLUOR WITH OR WITHOUT MDPB**  
Muratovska Ilijana; Kapusevska Biljana; Atanasovska-Stojanovska A; Stojanovska V; Zabokova-Bilbilova E-  
*FYROM*

**11:20 ORAL PATHOLOGY (ORAL MEDICINE) / ORAL SURGERY AND ORAL MAXILLOFACIAL**  
**13:20 SURGERY - Poster Presentations**

**P4**

Chairmen: Prof. Dr. STYLIANOS DALAMPIRAS  
Prof. Dr. LILIANA FOIA  
Dr. SAMI SOLYALI

Secretary: Assist. Prof. Dr. ANA MARIA FILIOREANU

- 1/  
PP 18 **SQUAMOUS CELL CARCINOMA OF ORAL MUCOSA: A CASE REPORT**  
Burcu Kirsan; Ali Abu Hanttash; Hakan Eren  
*Turkey*
- 2/  
PP 19 **HODGKIN'S LYMPHOMA OF MAXILLA: A CASE REPORT**  
Ceren Yildirim; Özlem Marti Akgün; Mehmet Kaplan; Eda Arat Maden  
*Turkey*
- 3/  
PP 109 **ASPERGILLOSIS OF THE MAXILLARY SINUS CAUSED BY ENDODONTIC OBTURATION MATERIALS: A CASE REPORT**  
Yavuz Tolga Korkmaz; Burak Cezairli; Nuray Yilmaz Altıntaş; Emre Balaban; Cenk Durmuslar  
*Turkey*

- 4/ **P 53; P16 AND KI67 IMMUNOEXPRESSION IN ORAL SQUAMOUS CARCINOMAS**  
 PP 265 Lucian Paul Dragomir; Dora Popescu; Mihaela Popescu; Anne-Marie Rauten; Mihai Raul Popescu  
*Romania*
- 5/ **THE IMMUNOEXPRESSION EGFR AND HER2/NEU IN ORAL SCUAMOUS CARCINOMA-OSC**  
 PP 267 Mihai Raul Popescu; Lucian Paul Dragomir; Mihaela Popescu; Dora Popescu; Iuliana Manuela Dragomir  
*Romania*
- 6/ **ANTI-HELMINTHIC MEDICATION IN RECURRENT APTHOUS**  
 PP 282 Liliana Foia; Daniel Cioloca; Mioara Trandafirescu; Catalina Holban Cioloca; Anca Chiriac  
*Romania*
- 7/ **STUDY REGARDING THE SALIVARY MICROCRYSTALLIZATION INDEX VARIATION ON THE PATIENTS HAVING DENTAL EROSION LESIONS**  
 PP 307 Pancu Galina; Sorin Andrian; Irina Nica; Antonia Moldovanu  
*Romania*
- 8/ **CALCIFYING CYSTIC ODONTOGENIC TUMOR: REPORT OF TWO CASES IN THE MANDIBULAR POSTERIOR REGION**  
 PP 323 Emre Baris; Burcu Sengüven; Faryd Museyibov; Deniz Yaman; Ayşenur Nergiz Tanidir  
*Turkey*
- 9/ **INFRARED THERMOGRAPHY - CASE REPORT OF ALOPECIA AREATA**  
 PP 329 Raya Grozdanova; Ivan Chakalov; Todor Uzunov  
*Bulgaria*
- 10/ **THERAPEUTIC AND PREVENTIVE CHALLENGES IN DENTISTRY-CASE REPORT**  
 PP 447 Ljiljana Bajic  
*Serbia*
- 11/ **THE USE OF OPTICAL DETECTION SYSTEM IN EARLY DETECTION OF (PRE)MALIGNANCIES: A SYSTEMATIC REVIEW**  
 PP 485 Bruno Nikolovski; Ana Minovska; Danica Popovic-Monevska; Mirjana Popovska; Vera Radojkova-Nikolovska  
*FYROM*
- 12/ **TREATMENT OF AN ORAL PREGNANCY TUMOUR: A CASE REPORT**  
 PP 492 Mehmet Fatih Tuncer; Ilknur Tuncer  
*Turkey*
- 13/ **HISTOPATHOLOGICAL ASPECTS IN ORAL LICHEN PLANUS VERSUS LICHENOID REACTION**  
 PP 501 Ana Maria Filioreanu; Eugenia Popescu; Cristina Popa  
*Romania*
- 14/ **ORAL MUCOSITIS IN PATIENTS WITH CHEMATOLOGICAL THERAPY**  
 PP 503 Kristina Mitic; Mirjana Popovska; Ana Belazelkoska; Aneta Mijovska  
*FYROM*
- 15/ **PREVALENCE OF ORAL MANIFESTATIONS IN PATIENTS ON RENAL REPLACEMENT THERAPY**  
 PP 541 Ana Belazelkovska; Mirjana Popovska; Kristina Mitic; Svetlana Cekovska  
*FYROM*
- 16/ **ORAL CLINICAL FINDINGS AT PATIENTS WITH DYSPEPTIC DIFFICULTIES**  
 PP 547 Mirjana Popovska; Ana Minovska; Aneta Atanasovska-Stojanovska; Kristina Mitic; Vera Radojkova-Nikolovska  
*FYROM*
- 
- 17/ **ALVEOLAR FRACTURE AND TREATMENT PLANNING: A CASE REPORT**  
 PP 13 Sinan Yasin Ertem; Murude Yazan  
*Turkey*
- 18/ **IMPACTED MAXILLARY CENTRAL INCISOR ASSOCIATED WITH SUPERNUMERARY MESIODENS. CASE REPORT**  
 PP 86 Sofia-Anna Panaretou; Maria Kaleli  
*Greece*
- 19/ **OSSIFYING FIBROMA OF THE MANDIBLE – CASE REPORT AND LITERATURE REVIEW**  
 PP 100 Martin Rubiev; Elitsa Deliverska; Lutchezar Stefanov; Dimitar Yovchev; Anelia Bobeva

*Bulgaria*

- 20/  
PP 113 **MALIGNANT TUMORS OF THE ORAL CAVITY; RETROSPECTIVE IN THE PERIOD 2009-2013; OUR EXPERIENCES**  
Marina Milinković; Miroslav Obrenović; Jelena Obrenović; Brankica Davidović; Tanja Ivanović  
*Bosnia And Herzegovina*
- 21/  
PP 114 **CLINICAL DENTAL REVIEW IN THE PREVENTION OF CANCER LIPS**  
Jelena Obrenović; Marina Milinković; Miroslav Obrenović; Jovana Hrisa Samardžija; Bojan Kujundžić  
*Bosnia And Herzegovina*
- 22/  
PP 117 **MULTIPLE IMPACTED MOLARS IN THE MANDIBLE: A CASE REPORT**  
Mehmet Eray Kolsuz; Poyzan Bozkurt  
*Turkey*
- 23/  
PP 140 **COMBINED SURGICAL-MEDICAL TREATMENT OF BRONJ USING PLASMA-RICH GROWTH FACTORS - CASE REPORT**  
Ivan Nachkov; Nikolay Nikolov; Georgi Tomov; Martin Hristov  
*Bulgaria*
- 24/  
PP 180 **MULTIPLE TEETH WITH HYPERCEMENTOSIS: A CASE REPORT**  
Poyzan Bozkurt  
*Turkey*
- 25/  
PP 195 **MATRIX METALLOPROTEINASE-8 GENE POLYMORPHISM IN CHRONIC PERIAPICAL LESIONS**  
Evrosimovska Biljana  
*FYROM*
- 26/  
PP 214 **ORAL TONGUE AND FLOOR OF THE MOUTH CANCERS IN BELGRADE POPULATION**  
Goran Videnović; Zoran Vlahović; Vojkan Lazić; Vladimir Matvijenko; Dragan Marjanović  
*Serbia*
- 27/  
PP 227 **POSSIBILITES TREATMENT POSTEXTRACTION PAIN**  
Dzenad Ganjola; Olga Djuric; Maja Delic; Snezana Raznatovic  
*Montenegro*
- 28/  
PP 242 **THE RELATIONSHIP BETWEEN THE DURATION AND THE SIZE OF NONMELANOMA SKIN CANCER**  
Vojkan Lazić; Goran Videnovic; Zoran Vlahović; Dragan Marjanović; Vladimir Matvijenko  
*Serbia*
- 29/  
PP 293 **ERUPTION DISTURBANCES: REVIEW AND REPORT OF SIMILAR CASES**  
Dimitrios Papalexiou; Anastasia Violesti; Foivos-Antonios Dalampiras; Georgia Barka; Antigone Delantoni  
*Greece*
- 30/  
PP 294 **EFFICACY OF ANTIBIOTIC THERAPY IN IMPACTED THIRD MOLAR SURGERY**  
Kiro Papakoca; Katerina Zlatanovska; Ana Radeska-Panovska; Biljana Evrosimovska; Julija Zarkova  
*FYROM*
- 31/  
PP 295 **ANATOMICAL EVALUATION OF ROOT APEX MORPHOLOGY IN FRONTAL MAXILLARY TEETH**  
Katerina Zlatanovska; Papakoca Kiro; Kovacevska Ivona; Popovska Lidija; Georgiev Zlatko  
*FYROM*
- 32/  
PP 308 **EFFECT OF BOTULINUM TOXIN ON MASSETER HYPERTROPHY VALIDATED WITH BITESTRIP: A CASE REPORT**  
Fouad Saleh Najafi; Yener Okutan  
*Turkey*
- 33/  
PP 365 **TREATMENT OF NON-MELANOMA SKIN CANCER USING 3D NON -MOH'S SURGERY**  
Goran Videnovic; Zoran Vlahovic; Vojkan Lazić  
*Serbia*
- 34/  
PP 400 **AUTOGENOUS BONE GRAFTING AND IMPLANT PLACEMENT OF ANTERIOR MAXILLA WITH ALVEOLAR DEFECT: A CASE REPORT**  
Sinan Ertem  
*Turkey*
- 35/  
**MISUSAGE OF REMOVABLE PARTIAL DENTURE CAUSES CONJUNCTION TO THE ALVEOLAR MUCOSA: A CASE**

- PP 403 **REPORT**  
Sinan Ertem  
Turkey
- 36/  
PP 405 **MISUSAGE OF FIXED PARTIAL DENTURE: A CASE REPORT**  
Sinan Yasin Ertem; Fethi Atil; Ilgi Baran  
Turkey
- 37/  
PP 407 **MODIFICATIONS IN THE STANDARD PROTOCOL OF PERIAPICAL SURGERY. A CASE SERIES STUDY**  
Thanasis Karampasis; Christina Razcha; Charis Beltes  
Greece
- 38/  
PP 409 **CALCIFYING CYSTIC ODONTOGENIC TUMOR: A RARE CASE REPORT**  
Yasin Sinan Ertem; Eser Bolat  
Turkey
- 39/  
PP 431 **INADEQUATE ROOT CANAL TREATMENT OF ADJACENT TOOTH: RISK FACTOR CAUSING PERIIMPLANTITIS? CLINICAL CASE REPORT**  
Sonja Livrinikj; Bojana Stefanovikj; Krenar Papraniku; Aleksandra Pivkova Veljanovskada; Darko Veljanovski  
FYROM
- 40/  
PP 445 **ALVEOLAR RIDGE EXPANSION VIA BONE SPLITTING TECHNIQUE. A CASE REPORT**  
Georgios-Alexandros Vakirtzian; Alexandros-Panteleimon Kontogiannis; Anastasia Zigridi; Stilianos Karamanis  
Greece
- 41/  
PP 494 **COMPARISON BETWEEN THE RETROMANDIBULAR APPROACH VERSUS MODIFIED SUBMANDIBULAR APPROACH IN CONDYLAR PROCESS FRACTURES**  
Lucian Chirila; Cristian Rotaru; Iulian Filipov  
Romania
- 42/  
PP 532 **THE VALUE OF PREEMTIVE ANALGESIA IN DENTAL ALVEOLAR OUTPATIENT SURGERY**  
Carmen Stelea; Oana E. Ciurcanu; Cristian Budacu; Ovidiu Stefanescu  
Romania
- 43/  
PP 579 **CORE BIOPSY MINIMAL INVASIVE DIAGNOSIS METHOD IN JAW TUMORS – CASE REPORT**  
Carmen Adrian; Adina Manda; Bogdan Turculeanu  
Romania

**15:00** **FIXED PROSTHODONTICS / ORAL IMPLANTOLOGY / NEW TECHNOLOGIES - Poster**  
**17:20** **Presentations**

**P6**

Chairmen: Prof. Dr. VERONICA MERCUT  
Assoc. Prof. Dr. ALKETA QAFMOLLA  
Dr. CLAUDIO ALBI  
Dr. LUCA ARDUINI  
Secretary: Lecturer Dr. MARINA CRISTINA IORDACHE

- 1/  
PP 7 **CLINICAL EXPERIENCES WITH OCCLUSAL SPLINTS IN DENTISTRY**  
Gordana Kovacevska; Nina Kovacevski ; Biljana Kapusevska; Jadranka Bundevska; Biljana Koseva  
FYROM
- 2/  
PP 10 **THERAPEUTIC APPROACH IN PATIENTS WITH DISLOCATION OF THE ARTICULAR DISC WITH REDUCTION**  
Biljana Kapusevska; Nikola Dereban; Vesna Jurukovska - Shortarovska; Marjan Petkov; Borjan Naumovski  
FYROM
- 3/  
PP 12 **THE CORRELATION BETWEEN GINGIVAL INFLAMMATION AND CHARTERS' TOOTH BRUSHING TECHNIQUE ON PATIENTS WITH FIXED PROSTHODONTICS**  
Biljana Kapusevska; Kristijan Shukov; Mirjana Popovska; Marija Andonovska; Natasa Stavreva  
FYROM
- 4/  
PP 141 **EDENTULOUS MAXILLA REHABILITATION WITH USE OF ALL-ON-FOUR IMPLANTS. A CASE REPORT**  
Adnan Ege Kösele; Serkan Saridağ; Fatih Mehmet Coşkunes

Turkey

- 5/ **PROSTHETIC REHABILITATION AT EXCESSIVELY WORN DENTITION: A CASE REPORT**  
PP 153 Zinde Guder; Onjen Tak  
Turkey
- 6/ **EVALUATION WITH SEM OF DIFFERENT FINISH LINES OF TOOTH PREPARATION**  
PP 206 Sidrit Beqiraj  
Albania
- 7/ **MECHANICAL PERFORMANCES OF FIBRE REINFORCED COMPOSITES SYSTEMS**  
PP 258 Oana Tanculescu; Raluca Mocanu; Gianina Iovan; Anca Vitalariu; Gabriela Ifteni  
Romania
- 8/ **MOLAR ROOT RESECTION AS AN ALTERNATIVE TREATMENT IN FIXED PROSTHODONTICS.**  
PP 289 Antigone Delantoni; Olga Naka; Foteini Papanikolaou; Stergoula Papamanoli; Stefania Vlachou  
Greece
- 9/ **THE EFFECT OF SOCIOECONOMIC CONDITIONS ON ORAL HEALTH STATUS OF DENTISTRY STUDENTS: A QUESTIONNAIRE STUDY**  
PP 315 Munir Tolga Yuçel  
Turkey
- 10/ **STUDY INTO THE VIEW OF DENTISTS REGARDING THE USE OF LABORATORY COMPOSITE RESIN**  
PP 326 Svetlin Aleksandrov; Georgi Todorov; Tanya Bojkova; Rada Kazakova; Viktor Hadjigaev  
Bulgaria
- 11/ **BIO AESTHETIC RECONSTRUCTION OF ABRADED TEETH USING METAL FREE AND METAL CERAMIC RESTORATIONS**  
PP 347 Natasha Stavreva; Ljuben Guguvchevski; Biljana Kapusevska; Aneta Mijoska; Vesna Ambarkova  
FYROM
- 12/ **INTRODUCTION OF NEW METHODS FOR PRECISE FABRICATION OF METAL FRAMEWORKS**  
PP 397 Nevena Koycheva  
Bulgaria
- 13/ **A NEW MODIFIED LASER PROCEDURE FOR MONOLITHIC TRANSLUCENT ZIRCONIA SURFACE**  
PP 408 Ipek Guldas; Esra Talay; Isa Yoldem; Hamdi Sukur; Abdullah Kepceoglu  
Turkey
- 14/ **INTRAORAL REPAIRMENT OF ALL-CERAMIC ZIRCONIA RESTORATIONS**  
PP 421 Aneta Mijoska; Biljana Kapusevska; Vesna Jurukovska; Natasha Stavreva  
FYROM
- 15/ **MARGINAL FIT OF SINGLE TOOTH ZIRCONIA COPINGS FABRICATED WITH DIGITAL AND CONVENTIONAL METHODS**  
PP 427 Sangwon Park; E. Shin; M. Vang; H. Yang; H. Lim; K. Yun  
Republic Of Korea
- 16/ **ENDODONTICALLY TREATED TEETH RESTORED WITH INTERNAL AND EXTERNAL FERRULE: IN VITRO STUDY**  
PP 450 Sasho Jovanovski; Trajche Jovanovski; Peter Jevnikar  
FYROM
- 17/ **EVALUATION OF BOND STRENGTH BETWEEN ZIRCONIA POSTS AND COMPOSITE CORE BUILD-UP: IN VITRO STUDY**  
PP 454 Arian Daci; Sasho Jovanovski; Vesna Jurukovska-Shotarovska; Aneta Atanasovska  
FYROM
- 18/ **PINK ESTHETICS MANAGEMENT THROUGH PROSTHETIC REHABILITATION ON IMPLANT SUPPORTED RESTORATIONS**  
PP 456 Kokkoni Magdalini; Kolovos Dimitrios; Moldovani Domna; Silvestros Spiridon; Chronopoulos Vasileios  
Greece
- 19/ **SOFT TISSUE MANAGEMENT WITH FIXED PROVISIONAL RESTORATIONS**

- PP 473 Efthalia Kokla; Domna Moldovani; Dimitrios Kolovos; Vasileios Chronopoulos; Spiridon Silvestros  
*Greece*
- 20/  
PP 482 **COLOR STABILITY OF RESIN COMPOSITE MATERIALS**  
Neada Hysenaj; Merita Bardhoshi; Suela Tabaku; Edit Xhajanka; Ditmir Borici  
*Albania*
- 21/  
PP 534 **DIAGNOSIS AND TREATMENT OF MYOGENIC DISORDERS OF THE STOMATOGNATHIC SYSTEM**  
Andrei Fachira; Oleg Solomon; Vitalie Gribenco; Daniela Chirita  
*Republic of Moldavia*
- 22/  
PP 538 **RELAXATION MOUTHGUARDS AT STUDENTS IN STRESS CONDITION FOR TONIC EQUILIBRATION OF MANDUCATORY MUSCLES**  
Laura Checherita; Norina Consuela Forna  
*Romania*
- 23/  
PP 560 **SURFACE TREATMENTS FOR IMPROVING ZIRCONIA CERAMIC BONDING**  
Aneta Mijoska; Biljana Kapusevska; Vesna Jurukovska; Kristina Mitik  
*FYROM*
- 
- 24/  
PP 17 **THE USE OF ALLOGRAFTS IN THE ATROPHIC POSTERIOR MANDIBLE PRIOR TO IMPLANT PLACEMENT**  
Luan Mavriqi; Ilma Robo; Egresa Baca; Ariona Demiraj; Bledar Mavriqi  
*Albania*
- 25/  
PP 187 **IMPLANT TREATMENT IN THE SEVERE ATROPHIC POSTERIOR MANDIBLE**  
Luan Mavriqi  
*Albania*
- 26/  
PP 568 **ROBOT SYSTEM INVOLVED IN PERFORMED ACTIVITY OF DENTAL STUDENTS**  
Doriana Agop Forna; Cristina Iordache  
*Romania*
- 27/  
PP 239 **SURGICAL REMOVAL OF POLY-ETHER-ETHER-KETONE DERIVED BASAL TYPE IMPLANTS: A CASE REPORT**  
Ilker Keskiner; Ahmet Aydogdu; Seda Ozturan  
*Turkey*
- 28/  
PP 288 **IMPLANT FOLLOW UP. BASIC INSTRUCTIONS AND GUIDELINES BASED ON PERIODONTICS AND PROSTHODONTICS**  
Antigone Delantoni; Athina Kondylidou; Stergoula Papamanoli; Foteini Papanikolaou; Georgios Karathanos  
*Greece*
- 29/  
PP 290 **SOCKET PRESERVATION WITH IMPLANT PLACEMENT IN THE DAILY PRACTICE – CASE REPORT**  
Kiro Papakoca; Cena Dimova; Gordana Papakoca; Ana Radeska-Panoska; Katerina Zlatanovska  
*FYROM*
- 30/  
PP 313 **IMPLANTATION AND IMMEDIATE IMPLANT LOADING - A CASE REPORT**  
Dusica Bozovic - Behara; Mladen Behara; Sladjana Sicovic; Lena Jovanovic; Natasha Randjelovic  
*Serbia*
- 31/  
PP 328 **RECONSTRUCTION OF ANTERIOR DEFECTS DUE TO TRAUMA USING SPLIT OSTEOTOMY: A CASE REPORT**  
Hasan Kucukkolbasi; Yener Okutan  
*Turkey*
- 32/  
PP 334 **MULTIDISCIPLINARY TREATMENT OF CONGENITALLY MISSING MAXILLARY LATERAL INCISORS (CASE REPORT)**  
Almiro Gurakuqi; Stojanka Pallko; Çeljana Toti; Alba Bimo  
*Albania*
- 33/  
PP 350 **THE CHALLENGES OF A FLAPLESS DENTAL IMPLANT PLACEMENT**  
Khader Alqawasmeh; Raksha Batajoo; Sumbal Rahman  
*Romania*
- 34/  
PP 385 **RESTORATION OF A MISSING TOOTH WITH IMMEDIATE IMPLANT PLACEMENT**  
Anastasios Petridis; Maria Hatziparaskeva

Greece

35/  
PP 401 **BENEFITS IMPRESSION WITH AN OPEN TRAY AN COMPLETELY EDENTATIONS IN IMPLANT RESTAURATIONS**  
Vasile Nicolae; Dumitra Dana Elena; Silviu Nicolae  
Romania

36/  
PP 402 **PERIIMPLANT INFECTIONS. THE THERAPY ATTITUDE**  
Vasile Nicolae; Dumitra Dana Elena; Silviu Nicolae  
Romania

37/  
PP 477 **SIMULTANEOUS IMPLANT PLACEMENT AND BONE GRAFTING IN NON-CONTAINED BONE DEFECTS**  
Lucian Chirila; Cristian Rotaru; Mircea Baldea; Davide Farronato; Iulian Filipov  
Romania

38/  
PP 543 **LOCALIZED ALVEOLAR BONE DEFECT MANAGEMENT IN DENTAL IMPLANT SUPPORTED RESTAURATION**  
Lucian Chirila; Radu Dragutescu  
Romania

---

39/  
PP 28 **TEMPERATURE FLUCTUATIONS IN SOFT TISSUES DURING THE TREATMENT OF PERIODONTITIS CHRONICA GRANULOMATOSA DIFFUSA CUM FISTULAE**  
Maria Dencheva; Olia Martinov; Stella Hristova  
Bulgaria

40/  
PP 393 **POSSIBILITY OF USING PLATELED-RICH FIBRIN (PRF) IN CORRECTION OF FACIAL ASYMMETRIES**  
Nikola Miković; Drago Jelovac; Milan Petrović; Vitomir Konstantinović  
Serbia

41/  
PP 571 **COMPUTERIZED 3D SIMULATION (DENTSIM) IN DENTISTRY**  
Marina Cristina Iordache; Doriana Agop Forna  
Romania

42/  
PP 316 **SHADE MATCHING QUALITY AMONG DENTAL STUDENTS USING VISUAL METHOD**  
Munir Tolga Yucel; Yener Okutan  
Turkey

43/  
PP 168 **BONDING PERFORMANCE OF EXPERIMENTAL SELF-ADHESIVE COMPOSITES CONTAINING DIFFERENT FUNCTIONAL MONOMERS**  
Hamdi Acar; Mustafa Ülker  
Turkey

17:20

19:20

## **ORTHODONTICS /COMMUNITY DENTISTRY - Poster Presentations**

**P8**

Chairmen: Prof. Dr. NICOLAI SHARKOV  
Prof. Dr. OLEG SOLOMON  
Secretary: Assist. Prof. Dr. CARINA BALCOS  
Assist. Prof. Dr. AMELIA SURDU

1/  
PP 74 **BULLIED CHILD TODAY; ORTHODONITC PATIENT TOMORROW?!**  
Iva Dimovska; Marija Zuzelova; Verica Dimovska  
FYROM

2/  
PP 93 **ORTHODONTIC TREATMENT IN ADULT PATIENTS**  
Jasminka Andjelic  
Montenegro

3/  
PP 112 **CORRECTION OF ANTERIOR CROSSBITE AS A MEANS OF INTERCEPTIVE GUIDANCE OF DENTITION**  
Tamer Tüzüner; Görkem Yahyaoğlu; Mehmet Birol Özel; Özgül Baygin  
Turkey

4/  
PP 124 **GENDER DETERMINATION BY ODONTOMETRICS IN A SERBIAN POPULATION**  
Gordana Filipovic; Bojana Cetenovic  
Serbia



- 5/ **CORRECTION OF CLASS II DIVISION 1 MALOCCLUSION TREATMENT OF ADULT PATIENT: CASE REPORT**  
 PP 126 Enes Tan; I. Erhan Gelgor  
*Turkey*
- 6/ **TREATMENT OF SEVERE DENTAL CROWDING: CASE REPORT**  
 PP 163 Mariella Oricchio; Rozafa Dragusha; Anna Di Nunno; Giuseppe Marzo; Livio Gallottini  
*Italy*
- 7/ **SURGICAL-ORTHODONTIC TREATMENT OF IMPACTED SECOND PERMANENT MOLAR: CASE REPORT**  
 PP 164 Almira Isufi; Mariella Oricchio; Anna Di Nunno; Ruggero Ingletto; Livio Gallottini  
*Italy*
- 8/ **TREATMENT OF II CLASS MALOCCLUSION WITH MANDIBULAR RETRUSION IN CHILDREN: CASE REPORT**  
 PP 165 Barbara Muzzarelli; Oricchio Mariella; Giovanni Manes Gravina; Giuseppe Marzo; Livio Gallottini  
*Italy*
- 9/ **THE INCIDENCE OF CERVICAL SPINE ANOMALIES AMONG SAGITTAL SKELETAL ANOMALIES**  
 PP 176 Hakan Keklik; Hasan Kamak  
*Turkey*
- 10/ **DISTRIBUTION OF THE CERVICAL VERTEBRAE ANOMALIES ACCORDING TO GENDER**  
 PP 177 Hakan Keklik; Hasan Kamak  
*Turkey*
- 11/ **RATIONAL ADMINISTRATION OF ANALGESICS DURING ORTHODONTIC TREATMENT**  
 PP 181 Sofia A. Papadaki; Ioannis Pilalas; Anastasios A. Zafeiriadis  
*Greece*
- 12/ **TREATMENT OF PATIENT WITH ANTERIOR OPENBITE USING BY MODIFIED TRANSPALATAL ARCH APPLIANCE: A CASE REPORT**  
 PP 182 Gülden Uzgören; Hasan Kamak; Hakan Keklik  
*Turkey*
- 13/ **IMPACTED CANINES - PROBLEMS AND PROGNOSIS**  
 PP 233 Snezana Raznatovic; Dzenad Ganjola; Maja Delic  
*Montenegro*
- 14/ **INTERDISCIPLINARY TREATMENT OF IMPACTED TEETH AFTER CAR ACCIDENT: CASE REPORT**  
 PP 240 Mehmet Emre Yilmaz; Mehmet Akin  
*Turkey*
- 15/ **IMPLICATIONS OF ORTHODONTIC TREATMENT ON THE PERIODONTAL TISSUE IN CHILDREN AND TEENAGERS WITH DENTO-MAXILLARY ANOMALIES**  
 PP 245 Ionela Elisabeta Ciobanu; Petra Surlin; Raul Popescu; Lucian Dragomir; Anne-Marie Rauten  
*Romania*
- 16/ **TREATMENT OF SKELETAL CLASS II MALOCCLUSION IN GROWING PATIENTS WITH FORSUS™ FATIGUE RESISTANT DEVICE**  
 PP 261 Hatice Kubra Demirtas; Merve Erol; Faruk Ayhan Basciftci  
*Turkey*
- 17/ **ORTHODONTIC TREATMENT OF POLYDIASTEMA: A CASE REPORT**  
 PP 300 Meliha Osman; Ahmet Kubilay Eroglu; Mehmet Akin  
*Turkey*
- 18/ **PREOPERATIVE ORTHOPEDIC TREATMENT OF UNILATERAL COMPLETE CLEFT LIP AND PALATE**  
 PP 275 Sevtap Alp; Mehmet Akin  
*Turkey*
- 19/ **ORTHODONTIC MANAGEMENT OF MAXILLARY CANINE FIRST PREMOLAR TRANSPOSITION: CASE REPORT**  
 PP 303 Enes Tan; Murat Çağlaroğlu  
*Turkey*
- 20/ **CRANIOFACIAL AND DENTAL CHARACTERISTICS OF PATIENT WITH CLEIDOCRANIAL DYSPLASIA**

- PP 342 Biljana Dzipunova; Mira Popovska; Ilijana Muratovska; Katerina Toseska-Trajkovska; Zoran Spasov; Natasa Toseska Spasova  
*FYROM*
- 21/  
PP 343 **EVALUATION OF ALVEOLAR STRUCTURES IN PRE-TREATED SKELETALLY MATURE PATIENTS WITH MALOCCLUSIONS IN DIFFERENT ANGLE CLASSIFICATIONS**  
Hasan Kamak; Burcu Şenel; Hakan Keklik  
*Turkey*
- 22/  
PP 345 **EVALUATION OF MAXILLARY AND MANDIBULAR ALVEOLAR STRUCTURES BETWEEN MAIL AND FEMAIL PRE-TREATED SKELETALLY MATURE PATIENTS**  
Hasan Kamak; Burcu Şenel; Hakan Keklik  
*Turkey*
- 23/  
PP 346 **TREATMENT OF BABY WITH PIERRE ROBIN SYNDROME USING MODIFIED NUTRITION PLATE: A CASE REPORT**  
A.Furkan Karakoyunlu; Hasan Kamak; Hakan Keklik  
*Turkey*
- 24/  
PP 349 **TREATMENT OF CLASS III SKELETAL ANOMALIES WITH PREMAXILLARY DISTRACTION OSTEOGENESIS: A CASE REPORT**  
İrem Geçeroğlu; Hasan Kamak; Hakan Keklik  
*Turkey*
- 25/  
PP 351 **UNILATERAL CERVICAL HEADGEAR TREATMENT OF A PATIENT WITH UNILATERAL CLASS II MOLAR RELATIONSHIP: A CASE REPORT**  
Hasan Kamak; Burcu Şenel; Gulen Kamak; Hakan Keklik  
*Turkey*
- 26/  
PP 388 **TREATMENT OF DISTAL BITE IN PERMANENT DENTITION BY FIXED APPLIANCES – CASE REPORT**  
Zorana Stamenkovic; Vanja Raickovic; Natasa Randjelovic; Tina Pajevic; Emira Lazic  
*Serbia*
- 27/  
PP 398 **THE ORTHODONTIC TREATMENT OF IMPACTED CENTRAL INCISOR TEETH - CASE STUDY**  
Slobodan Ivić; Ljiljana Stojanović ; Snežana Radišić  
*Serbia*
- 28/  
PP 444 **CORRECTION OF A MIDFACE DEFICIENCY USING REVERSE HEADGEAR: A CASE REPORT**  
Melih Osman; Zehra Ileri; Kemal Feriz  
*Turkey*
- 29/  
PP 465 **SIX ESTHETIC HORIZONTAL LINES OF SMILE**  
Luela Alushi; Armand Alushi  
*Albania*
- 30/  
PP 488 **DIAGNOSTIC VALUE OF TRIGEMINAL REFLEXES INDICES FOR CHILDREN WITH ANGLE CLASS III MALOCCLUSION**  
Trifan Valentina; Lupan Ion; Lapcusta Victor  
*Republic of Moldavia*
- 31/  
PP 489 **PREDICTION THE TENDENCY OF IMPACTION OF MAXILLARY PERMANENT CANINES - METHOD OF ARNAUTSKA-KRUMOVA**  
Ivan Bachvarov; Hristina Arnautska  
*Bulgaria*
- 32/  
PP 497 **THE EFFECT OF PRE-ORTHODONTIC FORCE APPLICATION ON PERIODONTAL TISSUE FOR REPLANTATION**  
Jin-Hyoung Cho; Ki-Heon Lee; Kyung-Min Lee; Hyeon-Shik Hwang  
*Republic of Korea*
- 33/  
PP 504 **EVALUATION OF FACIAL PROFILES IN EXTRACTION AND NON-EXTRACTION BASE TREATMENTS**  
Diana Gaspar; Rodica Bodea; Alexandru Jianu; Rodica Jianu  
*Romania*
- 34/  
**GCF VOLUME RATE IN COMBINED PERIODONTAL-ORTHODONTIC TREATMENT OF ADULT PATIENTS**

- PP 514 Alexandru Jianu; Stefan Stratul; Doina Onisei; Sarbu Ciprian  
*Romania*
- 35/ **MMP 8 LEVELS IN ADULT PERIODONTIC PATIENTS UNDERGOING ORTHODONTIC TREATMENT**
- PP 515 Alexandru Jianu; Stefan Stratul; Doina Onisei; Sarbu Ciprian  
*Romania*
- 36/ **TREATMENT OPTIONS FOR RETAINED PRIMARY TEETH. A CASE REPORT**
- PP 526 Rodica Bodea; Diana Gaspar; Alexandru Jianu; Rodica Jianu  
*Romania*
- 37/ **THE IMPACT OF THE VERTICAL CRANIOFACIAL DISPROPORTIONS ON THE CERVICOVERTEBRAL MORPHOLOGY IN ADULT SUBJECTS**
- PP 565 Emira Lazic; Aleksandar Jakovljevic; Ksenija Zelic Mihajlovic; Nenad Nedeljkovic  
*Serbia*
- 38/ **THE CHARACTERISTICS OF CRANIOFACIAL AND CERVICOVERTEBRAL MORPHOLOGY IN DIFFERENT GENETIC SYNDROMES – THREE CASE REPORTS**
- PP 578 Emira Lazic; Ksenija Zelic Mihajlovic; Aleksandar Jakovljevic; Nenad Nedeljkovic  
*Serbia*
- 
- 39/ **REASONS FOR CHOOSING DENTISTRY AS A CAREER: A SURVEY AMONG BULGARIAN AND FOREIGN STUDENTS**
- PP 16 Nadya Avramova; Ivanka Mihailova; Dimov Plamen; Peter Bojinov; Krassimir Tsokov; Boyko Bonev  
*Bulgaria*
- 40/ **ANXIETY; LOCUS OF CONTROL AND SELF-ASSESSMENT OF ORAL HEALTH AMONG III-D YEAR DENTAL STUDENTS**
- PP 45 Ivanka Mihaylova; Nadya Avramova; Boyko Bonev; Peter Bojinov; Krassimir Tsokov  
*Bulgaria*
- 41/ **FABRICATING A HOLLOW BULB OBTURATOR**
- PP 185 Ali Riza Tuncdemir; Hakki Celebi  
*Turkey*
- 42/ **CARIES EXPERIENCE OF 12-YEARS OLD CHILDREN IN THE EASTERN REGION OF THE REPUBLIC OF MACEDONIA**
- PP 190 Vesna Ambarkova; Ilijana Muratovska; Natasa Stavreva; Blagica Gorgieva; Marija Maneva  
*FYROM*
- 43/ **ROMANIAN DENTAL STUDENTS' KNOWLEDGE ABOUT ETHICAL PRINCIPLES IN DENTISTRY**
- PP 210 Alice Murariu; Stela Carmen Hanganu; Livia Bobu  
*Romania*
- 44/ **FREQUENCY AND DEGREE OF TOOTH WEAR IN ADULTS**
- PP 540 Mihail Mostovei; Oleg Solomon; Vasile Oineagra; Zuev Veceaslav; Sofia Mostovei  
*Republic of Moldavia*

## SATURDAY, APRIL 25th, 2015

INTERCONTINENTAL HOTEL, RHONDA HALL

09:00

11:00

### ORTHODONTICS, PEDODONTICS, COMMUNITARY STOMATOLOGY – PLENARY LECTURES:

Moderators: Assoc. Prof. Dr. NATASA TOESKA SPASOVA

Prof. Dr. CHANG HEUN PARK

L 337

#### ASYMMETRIES : DIAGNOSIS AND TREATMENT

CHANG HEUN PARK

*Republic of South Korea*

L 602

#### ORAL HABITS AND ITS MANAGEMENT IN ORTHODONTICS

NATASA TOESKA SPASOVA

*FYROM*

L 603

#### POSSIBLE CAUSES OF DENTAL RESTORATION FAILURES AND CURRENT SOLUTIONS

ILIJANA MURATOVSKA

*FYROM*

L 601

#### CBCT IN DENTISTRY – A TRUE NEED OR A WHIM ?

ZORAN VLAHOVIC

*Montenegro*

11:00

Coffee break

11:15

11:15

12:00

### INTERDISCIPLINARITY IN DENTAL MEDICINE - II – PLENARY LECTURES:

Moderators: Dr. ZORAN VLAHOVIC

Prof. Dr. ANDREI KOZMA

#### REFLECTIONS ABOUT CONSCIOUSNESS

CONSTANTIN BALACEANU STOLNICI

*Romania*

#### LIVER FAILURE AS RISK FACTOR IN CARDIAC SURGERY

GRIGORE TINICA, GEORGE GRADINARU, ION ROTARU, MIHAIL ENACHE, DIANA ANGHEL

*Romania*

L 590

#### TRAUMATIC OCCLUSION AND ITS TREATMENT (CLINICAL AND EXPERIMENTAL STUDY)

ALKETA QAFMOLLA

*Albania*

#### RESERVED SUBJECT

TRAIAN MIHAESCU

*Romania*

L 583

#### DENTAL INCLUSION – STUDY OF A PARTICULAR ASPECT OF THE PERMANENT TEETH ERUPTION

ANDREI KOZMA

*Romania*

12:00

13:00

BaSS GENERAL ASSEMBLY

13:00

Lunch break

15:00

09:00  
11:00

**ENDODONTOLOGY – PLENARY LECTURES and Oral presentations:**

Chairmen: Assoc. Prof. Dr. LUMINITA MARIA NICA  
Assoc. Prof. Dr. ELKA NIKOLAEVA RADEVA  
Secretary : Lect. Dr. MIHAELA SALCEANU

**ENDODONTOLOGY – PLENARY LECTURES:**

- L 523 **RETROSPECTIVES IN ORO-DENTAL PREVENTION OF DISEASES IN ROMANIA**  
IOAN DANILA  
*Romania*
- L 50 **PROBLEM SOLVING IN NON-SURGICAL ENDODONTIC RETREATMENT**  
ELKA NIKOLAEVA RADEVA  
*Bulgaria*
- L 417 **ENDODONTIC SURGERY. DIAGNOSIS AND THERAPY USING CONE-BEAM CT AND OPERATING MICROSCOPE**  
CHARIS BELTES  
*Greece*
- L 102 **CLINICAL APPLICATIONS OF BONDING TO ROOT CANAL DENTIN**  
LUMINITA MARIA NICA  
*Romania*

**ENDODONTOLOGY – Oral presentations:**

- 1/  
OP 3 **COMPARISON OF CANAL TRANSPORTATION, CENTERING RATIO BY CONE-BEAM CT AFTER PREPARATION WITH DIFFERENT FILE SYSTEMS**  
EMEL UZUNOGLU; SEVINC AKTEMUR TURKER  
*Turkey*
- 2/  
OP 51 **PERIAPICAL LESIONS IN RELATION TO THE ROOT CANAL TREATMENT**  
PEPLA ERLIND.; MIGLIAU G.; GALLI M  
*Italy*
- 3/  
OP 71 **CBCT AIDED RETREATMENT OF A PREMOLAR WITH TWO ROOTS AND TWO CANALS**  
FUNDA YILMAZ; KIVANÇ KANBUROĞLU; ELIF NAZ YETA  
*Romania*
- 4/  
OP 353 **EFFECT OF EDTA WITH VARIOUS SURFACE-MODIFYING AGENTS ON THE BOND-STRENGTH OF AN EPOXY RESIN-BASED-SEALER**  
MEHMET BURAK GUNESER; SEYIT BILAL OZDEMIR; DILARA ARSLAN; ASIYE NUR DINCER  
*Turkey*
- 5/  
OP 361 **ANTIBACTERIAL EFFICIENCY OF PHOTODYNAMIC THERAPY WITH INDOCYANINE GREEN IN ROOT CANALS INFECTED BY ENTEROCOCCUS FAECALIS**  
ISMAIL OZKOCAK; HAKAN GOKTURK; Umut SAFIYE SAY COSKUN; FATMA AYTAC  
*Turkey*
- 6/  
OP 422 **ACCURATE ENDODONTIC DIAGNOSIS USING CONE BEAM COMPUTING TOMOGRAPHY (CBCT)**  
PAULA PERLEA; CRISTINA CORALIA NISTOR; ILINCA FISER  
*Romania*
- 7/  
OP 433 **BOND STRENGTH OF AN EPOXY-BASED SEALER AFTER SODIUM HYPOCHLORITE IRRIGATION WITH OR WITHOUT SURFACE-MODIFYING AGENTS**  
MEHMET BURAK GÜNEŞER; GAMZE ER; DİLARA ARSLAN; ASIYE NUR DİNÇER  
*Turkey*
- 8/  
OP 438 **THE EFFECT OF VARIOUS RETROCAVITY PREPARATION TECHNIQUES AND RETROFILLING WITH BIODENTINE ON APICAL MICROLEAKAGE**

DILARA ARSLAN; FATMA KAPLAN; MEHMET BURAK GUNESER; ASLIHAN USUMEZ  
*Turkey*

9/  
OP 559 **BIOCHEMICAL AND SEM ANALYSIS OF TISSULAR REACTIONS AFTER ENDODONTIC MATERIALS  
IMPLANTATION IN EXPERIMENTAL ANIMALS**  
LIANA AMINOV; PAULA PERLEA; ALEXANDRU ANDREI ILIESCU; MIHAELA SALCEANU; ANCA MELIAN; GIUROIU  
CRISTIAN; MARIA VATAMAN  
*Romania*

11:00 **Coffee break**  
11:15

11:15 **ORAL SURGERY AND OROMAXILLOFACIAL SURGERY – PLENARY LECTURES:**  
12:00

**Chairmen: Prof. Dr. ALEXANDRU BUCUR**  
**Assoc. Prof. Dr. TOMIC SLAVOLJUB**  
**Prof. Dr. ION LUPAN**  
**Secretary : Lect. Dr. VICTOR VLAD COSTAN**

1/  
OP 66 **CLINICAL OSTEOMYELITIS, REPORT OF A VERY RARE CASE**  
SOTIRIA GKAMPESI; FOIVOS DALAMPIRAS; M DALAMPIRA; ELENI TOUFA  
*Greece*

2/  
OP 200 **THE IMPORTANCE OF THE CONDITION OF THE DONOR TEETH AND JAWS DURING ALLOGENEIC FACE  
TRANSPLANTATION**  
AYŞİM ŞENOL; ZEYNEP ASLI GÜÇLÜ; AYŞE GÜLŞEN; SELAHATTIN ÖZMEN  
*Turkey*

3/  
OP 277 **HARD TISSUE RECONSTRUCTION IN DENTAL IMPLANTOLOGY**  
VIOREL IBRIC CIORANU  
*Romania*

4/  
OP 539 **REMOVABLE PROSTHESIS IN THE PATIENTS WITH ORAL MUCOSA CARCINOMA**  
VICTOR-VLAD COSTAN; DORIANA AGOP FORNA; OTILIA BOISTEANU; EUGENIA POPESCU  
*Romania*

5/  
OP 387 **ADVANCES OF THE ER.YAG LASER SURGERY OF LABIAL FRENA**  
MARINA KACARSKA; MAJA GJOROVSKA  
*Greece*

6/  
OP 561 **SURGICAL SPECIFIC TECHNIQUES OF PROSTHETIC FIELD ENHANCEMENT IN ASSISTED CASES; CLASSICAL  
TECHNIQUES VERSUS SURGICAL LASER**  
DORIANA AGOP FORNA; HENRIETTE LERNER; FLORIN ROSU; CATALINA CIOLOCA HOLBAN; EUGENIA POPESCU  
*Romania*

7/  
OP 392 **MALPRACTICE IN SURGICAL ORTHODONTICS**  
PAVLINA DIMITRIADI; ANASTASIOS VOSSOS; PHOEBUS DALAMPIRAS; DIMITRIOS BARDIS;  
STYLIANOS DALAMPIRAS  
*Greece*

8/  
OP 406 **SCHNEIDERIAN MEMBRANE PERFORATIONS: THE MOST COMMON COMPLICATION OF MAXILLARY SINUS  
FLOOR ELEVATION**  
KALLIOPI PAPAZOGLU; DIMITRA DIOMATARI; THODORIS GKOMOZIAS; EFTHALIA KOKLA; SPIRIDON  
SILVESTROS  
*Greece*

9/  
OP 439 **FIBRIN RICH PLASMA IN THE TREATMENT OF MEDICATION-RELATED OSTEONECROSIS OF THE JAW\_MIHAI**  
MIHAI BUCUR; CRISTIAN VLĂDAN; TIBERIU NIŢĂ; ALEXANDRU BUCUR  
*Romania*

10/  
OP 441 **SECOND GENERATION PLATELET CONCENTRATE USE IN MAXILLOFACIAL SURGERY**  
MIHAI BUCUR; CRISTIAN VLĂDAN; COSMIN TOTAN; OCTAVIAN DINCĂ

Romania

- 11/  
OP 442 **MANDIBLE RECONSTRUCTION AFTER SEGMENTAL RESECTION AT BRONJ PATIENTS**  
ALEXANDRU BUCUR; TIBERIU NIȚĂ; CRISTIAN VLĂDAN; COSMIN TOTAN; OCTAVIAN DINCĂ  
Romania
- 12/  
OP 462 **DIFFERENTIATION OF ADIPOSE TISSUE STEM CELLS ON 3D PRINTED SCAFFOLDS, UNDER THE GROWTH FACTORS ACTION**  
ARANKA ILEA; OLGA SORIȚĂU; BIANCA BOȘCA; MIHAI CENARIU; RADU SEPTIMIU CÂMPIAN  
Romania
- 13/  
OP 469 **BONE LOSS MANAGEMENT IN MAXILLARY CYSTS**  
VICTOR-VLAD COSTAN; OVIDIU STAMATIN; OTILIA BOISTEANU; EUGENIA POPESCU  
Romania
- 14/  
OP 582 **THE CONE BEAM COMPUTER TOMOGRAPHY (CBCT) APPROACH IN PARANASAL SINUS DISEASE EXAMINATIONS**  
DANISIA HABA, GABRIELA DUMITRESCU, CRISTIAN BUDACU, ANA PETCU, M.S.C. HABA, RALUCA VREME, NICOLETA DUMITRESCU, ANA NEMTOI, VICTOR COSTAN, CONSTANTIN MIHAI  
Romania
- 15/  
OP 516 **SELECTION OF THE AUTOGENOUS GRAFTS IN THE SURGICAL RECOVERY OF CLEFT LIP AND PALATE PATIENTS**  
ION LUPAN; EGOR POROSENCOV  
Rep. Moldova

13:00 **SEMINAR (Ro): ACCESARE FONDURI EUROPENE PENTRU DOTARE CABINET – Medicina Dentara**  
15:00 **Banca Transilvania – divizia pt medici & Ministerul Fondurilor Europene**

15:00 **ORTHODONTICS – PLENARY LECTURES and Oral presentations:**  
17:00

Chairmen: Prof. Dr. SELMA ZUKIC  
Prof. Dr. MARIANA PACURAR  
Assoc. Prof. Dr. OANA EILINA TEODORESCU-MILICESCU  
Secretary : Lect. Dr. CARMEN SAVIN

**ORTHODONTICS – PLENARY LECTURES:**

**DENTAL ANOMALIES: CLINICAL IMPLICATIONS AND TREATMENT CHALLENGES**

SELMA ZUKIC

*Bosnia and Herzegovina*

L 536 **THE INTERDISCIPLINARY APPROACH IN ORTHODONTICS**

IRINA ZETU; MARIANA PACURAR; LIVIU ZETU

*Romania*

**ORTHODONTICS – Oral presentations:**

- 1/  
OP 304 **DENTO-PERIODONTAL CHANGES IN ORTHODONTIC TREATED ADULT PATIENTS**  
MARIANA PĂCURAR; MONICA MONEA; TUDOR HĂNȚOIU; STEFANIA DINU; IRINA ZETU  
Romania
- 2/  
OP 259 **THE ORTHODONTIC TREATMENT OF SEVERE SKELETAL CLASS II PATIENT**  
EMIRE AYBUKE ERDUR; AHMET VURAL; FARUK AYHAN BASCIFTCI  
Turkey
- 3/  
OP 260 **THE ORTHODONTIC TREATMENT OF SEVERE CROWDING PATIENTS WITH DAMON SYSTEM: CASE REPORT**  
EMIRE AYBUKE ERDUR; RABIA MERVE CELIK; AHMET VURAL; FARUK AYHAN BASCIFTCI  
Turkey
- 4/  
OP 278 **COMBINED ORTHODONTIC AND RESTORATIVE TREATMENT OF PEG-SHAPED OR MISSING MAXILLARY LATERAL INCISORS: CASE REPORT**  
RABIA MERVE CELIK KARATAS; ALI IHSAN ERKAN; MEHMET TUGRAN; MEHMET AKIN

Turkey

5/  
OP 279 **COMBINED ORTHODONTIC AND RESTORATIVE TREATMENT OF ENAMEL HYPOPLASIA : CASE REPORT**  
RABIA MERVE CELIK KARATAS; ALI IHSAN ERKAN; MEHMET TUGRAN; MEHMET AKIN

Turkey

6/  
OP 291 **ETIOLOGICAL RISK FACTORS AND PREDICTORS FOR CORRECTIVE TREATMENT OF CROSSBITES**  
GEORGETA ZEGAN; CRISTINA GENA DASCALU; RADU BOGDAN MAVRU; LOREDANA GOLOVCENCU; DANIELA ANISTOROAEI

Romania

7/  
OP 321 **MORPHOLOGICAL, AESTHETIC AND FUNCTIONAL BALANCE OF THE PATIENT WITH DENTAL AND FACIAL ASYMMETRY**

DANIELA ANISTOROAEI; GEORGETA ZEGAN; LOREDANA GOLOVCENCU; ALINA SODOR

Romania

8/  
OP 358 **ORTHODONTIC MANAGEMENT OF MAXILLARY CANINE-LATERAL INCISOR TRANSPOSITION**

RABIA MERVE CELIK KARATAS; ZEHRA ILERI

Turkey

9/  
OP 359 **THE EFFECTS OF STRONTIUM RANELAT ON SUTURAL BONE FORMATION: A HISTOLOGICAL AND IMMUNOHISTOCHEMICAL STUDY**

ORHAN HAKKI KARATAS; EBUBEKIR TOY; HATICE TOY; SUMEYYE KOZACIOGLU; ABDULLAH DEMIR

Turkey

10/  
OP 372 **EFFECTS OF REMOVABLE AND FIXED FUNCTIONAL THERAPIES ON UVULO-GLOSSOPHARINGEAL DIMENSIONS IN CLASS II MALOCCLUSION PATIENTS**

MEHMET ALI YAVAN; N.EREN İŞMAN; MERVE AYCAN KIR; MERVE GÖYMEN; ÖMER ALPARSLAN KIR

Turkey

17:00 Coffee break

17:15

17:15 **PAEDIATRIC DENTISTRY AND ORTHODONTICS – PLENARY LECTURES and Oral presentations:**

19:15

Chairmen: Prof. Dr. NICOLAI SHARKOV

Prof. Dr. RODICA LUCA

Secretary : Lect. Dr. ANA PETCU

**PAEDIATRIC DENTISTRY – PLENARY LECTURES:**

L 585 **ORAL HEALTH STATUS OF CHILDREN WITH DEVELOPMENTAL DISABILITIES IN THE REPUBLIC OF MOLDOVA**

AURELIA SPINEI

Republic of Moldavia

**ORTHODONTICS AND PAEDIATRIC DENTISTRY – Oral presentations:**

1/  
OP 296 **MICROBIOLOGICAL ASPECTS OF PERIODONTAL DISEASES IN JUVENILE DIABETES**

VASILICA TOMA; ANCURTA GORIUC; DANIEL PETRU CIOLOCA; LOREDANA HURJUI; ADRIANA BALAN

Romania

2/  
OP 520 **ORTHODONTIC TREATMENT OPTIONS AS AN AID FOR ORAL REHABILITATION**

LOREDANA GOLOVCENCU; ALINA SODOR; DANIELA ANISTOROAEI; GEORGETA ZEGAN

Romania

3/  
OP 446 **THE IN VITRO STUDY OF THE CITOTOXICITY OF ORTHODONTIC ELASTOMERIC CHAINS AND LIGATURES**

ALINA SODOR; DANIELA ANISTOROAEI; LOREDANA GOLOVCENCU; TUDOR PETREUS; VALENTINA DOROBAT

Romania

4/  
OP 458 **HYPNOSIS - A HANDY AND HELPFUL TOOL IN PAEDIATRIC DENTISTRY**

ARINA VINEREANU

Romania

5/  
**ORTHODONTIC TREATMENT OF ECTOPIC CANINES (CASE REPORTS)**



- OP 486 IRIS CAÇANI; ANILA VJESHTA; CELJANA TOTI; EDLIRA SUBASHI; NINETA FINO  
*Albania*
- 6/  
OP 567 **MULTIDISCIPLINARY APPROACH OF TMJ PATIENT**  
ADINA SIRBU; ONDINE LUCACIU; MINODORA MOGA; ANCA IONEL; RADU CAMPIAN  
*Romania*
- 7/  
OP 244 **MINERAL CONTENT VARIATIONS AND MORPHOLOGICAL CHANGES OF MICE INCISORS ENAMEL ASSOCIATED WITH CHRONIC FLUORIDE OVEREXPOSURE**  
EUGENIU MIHALAŞ; DANA CRISTIANA MAXIM; ADINA COROABĂ; NICOLAE GHEŢU; LAVINIA MATRICALA  
*Romania*
- 8/  
OP 470 **POST RESTORATIONS OF UNCOMPLICATED CROWN FRACTURES - A FINITE ELEMENT ANALYSIS**  
DAN-CRISTIAN IONEL; RODICA LUCA; DOINA BOAZU  
*Romania*
- 9/  
OP 474 **DENTAL AGE IN CHILDREN WITH HYPODONTIA**  
ANETA MUNTEANU; RODICA LUCA; ARINA VINEREANU; CATALINA FARCASIU; ANDREEA FOCSA  
*Romania*
- 10/  
OP 483 **PSYCHOMETRIC PROPERTIES OF THE ROMANIAN VERSION OF THE CHILD PERCEPTIONS QUESTIONNAIRE (CPQ8-10)**  
EUGENIU MIHALAŞ; LAURA GAVRILĂ; ANA PETCU; ADRIANA BĂLAN; CARMEN SAVIN  
*Romania*
- 11/  
OP 525 **SOCIO-BEHAVIOURAL FACTORS ASSOCIATED WITH DENTAL CARIES IN 6-7 YEARS OLD CHILDREN**  
DIANA DANIELA DACIANA ZMARANDACHE; RODICA LUCA  
*Romania*
- 12/  
OP 531 **ORAL REHABILITATION OF ECTODERMAL DYSPLASIA WITH ANODONTIA: CASE REPORT**  
VIORICA TARMURE; RADU SEPTIMIU CAMPAN; ARANKA ILEA; ONDINE LUCACIU; ANDREEA-SIMONA POP  
*Romania*
- 13/  
OP 548 **ETIOPATHOGENIC STUDY ON THE INCIDENCE OF TEMPORARY MOLARS PREMATURE LOSS**  
ANA PETCU; LAURA MARIA VASILCA; ADRIANA BALAN; DANA MAXIM; CARMEN SAVIN  
*Romania*

## INTERCONTINENTAL HOTEL, CONCERTO HALL

- 09:00** **BASS AWARD Committee Meeting**
- 10:00** **Oral Presentations of BaSS AWARD Candidates**
- 1/  
OP 545 **APICAL EXTRUSION DURING ENDODONTIC RETREATMENT USING THREE ROTARY NICKEL-TITANIUM RETREATMENT INSTRUMENTS AND HAND FILES**  
SOTIRIA GKAMPESI  
*Greece*
- 2/  
OP 215 **INFLUENCE OF DENTAL RESTORATIONS AND MASTICATION LOADINGS ON DENTIN FATIGUE BEHAVIOR: IMAGE-BASED MODELING APPROACH**  
KSENIJA ZELIC MIHAJLOVIC  
*Serbia*
- 3/  
OP 192 **LOWER THIRD MOLAR AND ITS INFLUENCE ON THE FRAGILITY OF THE MANDIBULAR ANGLE AND CONDYLE**  
SVETLANA ANTIC  
*Serbia*
- 4/  
OP 305 **ACCURACY OF FIT OF IMPLANT-SUPPORTED BARS FABRICATED ON DEFINITIVE CASTS MADE BY DIFFERENT DENTAL STONES**  
IOANNIS KIOLEOGLOU

Greece

5/ **PAIN REDUCTION WITH STABILIZATION SPLINT IN PATIENTS WITH TEMPOROMANDIBULAR DISORDERS-  
META- ANALYSIS**

OP 367

JOVANA KUZMANOVIC PFICER

Serbia

6/ **PERIODONTOPATHIC BACTERIA IN EDENTULOUS PATIENTS-BEFORE AND AFTER COMPLETE DENTURE  
TREATMENT**

OP 584

MARKO ANDJELKOVIC

Serbia

10:00

**2<sup>ND</sup> BASS COUNCIL MEETING**

12:00

12:00

**BaSS GENERAL ASSEMBLY -- Rhonda Hall**

13:00

13:00

**Lunch Break**

15:00

15:00

**DEANS MEETING – BaSS**

17:00

17:00

**Coffee Break**

17:15

17:15

**INTERDISCIPLINARITY, HOSPITAL DENTISTRY, DENTAL BIOMATERIALS AND DEVICES -**

19:15

**Poster presentations:**

**P9**

**Chairmen: Lect. Dr. IRINA GRADINARIU**

**Lect. Dr. LOREDANA HURJUI**

**Secretary : Assist. Prof. Dr. CLAUDIA FLORIDA COSTEA**

**Assist. Prof. Dr. IONUT LUCHIAN**

1/

**RESTORATION OF FUNCTIONAL OCCLUSION WITH SELECTIVE TEETH GRINDING**

PP 9

Biljana Kapusevska; Nikola Dereban; Gulaba Dereban; Aneta Mijoska; Budima Pejkovska - Saspaska  
*FYROM*

2/

**REESTABLISHMENT OF OCCLUSION WITH FULL MOUTH REHABILITATION: REPORT OF THREE CASES**

PP 72

Yeliz Arslan, Hüseyin Yazicioğlu, Merve Bankoğlu Güngör  
*Turkey*

3/

**EVALUATION OF CROSS INFECTION CONTROL IN DENTAL LABORATORIES**

PP 204

Diana Antonela Diaconu; Monica Silvia Tatarciuc; Diana Tatarciuc; Anca Mihaela Vitalariu  
*Romania*

4/

**DIFFERENTIATION POTENTIAL OF DENTAL PULP MESENCHYMAL STEM CELLS**

PP 255

Nikolay Ishkitiev; Vanyo Mitev; Ken Yaegaki  
*Bulgaria*

5/

**A STUDENT PERSPECTIVE ON DENTAL TRAINING USING VIRTUAL PATIENTS**

PP 257

Adrian Doloca; Oana Tănculescu; Simona Stoleriu; Gabriela Ifteni  
*Romania*

6/

**SALIVARY AND SERUM BIOMARKERS FOR THE STUDY OF SIDE EFFECTS OF ARIPIRAZOLE AND  
MIRTAZAPINE**

PP 273

Petra Surlin; Maria Bogdan; Isabela Silosi; Andrei Adrian Tica; Oana Sorina Tica  
*Romania*

7/

**AIDING PROTHESES FOR MARSUPIALIZATION OF CYSTS :A CASE SERIES**

PP 339

Kübra Değirmenci; Ayşe Koçak Büyükdere; Öngen Tak; Serkan Sarıdağ  
*Turkey*

8/

**A STUDY OF QUALITY OF DECONTAMINATION BEFORE STERILIZATION OF DENTAL INSTRUMENTS IN**

114

20<sup>th</sup> Congress of BaSS, 2015

- PP 382 **ROUTINE DENTAL PRACTICE**  
Velina Stoeva; Veselina Kondeva; Ani Kevorkyan; Aleksandar Atanasovski; Alica Raycheva  
*Bulgaria*
- 9/  
 PP 389 **STUDY ON ROOT MORPHOLOGY VARIABILITY OF MANDIBULAR MOLARS 3**  
Tiberiu Tirca; Marina Amarascu  
*Romania*
- 10/  
 PP 425 **HOW DOES SMOKING INFLUENCE TOOTH COLOR**  
 Julija Zarkova; Katerina Zlatanovska; Ana Radeska- Panoska; Kiro Papakoca; Katerina Foteva  
*FYROM*
- 11/  
 PP 443 **ADVANCES IN TEACHING HEAD AND NECK SEMIOLOGY. A MULTIDISCIPLINARY APPROACH**  
 Silvia Cristina Tone; Gheorghe Gh. Balan; Adriana Balan  
*Romania*
- 
- 12/  
 PP 24 **HODGKIN'S LYMPHOMA OF MAXILLA: A CASE REPORT**  
 Ceren Yildirim; Özlem Marti Akgün; Mehmet Kaplan; Eda Arat Maden  
*Turkey*
- 13/  
 PP 481 **HOSPITAL DENTIST VERSUS PRIVATE DENTIST**  
Afroditi Chalkidou  
*Greece*
- 
- 14/  
 PP 138 **EVALUATING THE EFFECTS OF CAPPARIDACEAE SPINOSA ON PULP CELLS WITH XCELLIGENCE SYSTEM**  
Huseyin Tort; Elif Aybala Oktay; Fulya Toksoy Topcu  
*Turkey*
- 15/  
 PP 201 **EFFECT OF IN-VITRO AGING ON THE MECHANICAL PROPERTIES OF MONOLITHIC ZIRCONIA CERAMICS FOR DENTAL RESTORATIONS**  
 Eleana Kontonasaki; Despoina Delichristou; Panagiotis Kavouras; Petros Koidis  
*Greece*
- 16/  
 PP 311 **CHEMICOPHYSICAL PROPERTIES OF NEW NANOSTRUCTURED MATERIAL FOR APPLICATION IN DENTISTRY**  
Bojana Cetenovic; Dejan Markovic; Gordana Filipovic; Vukoman Jokanovic  
*Serbia*
- 17/  
 PP 372 **THE SHORTCOMINGS OF CONVENTIONAL OCCLUSAL REGISTRATION METHODS**  
Carmen Ioana Biris; Monica Dana Monea; Diana Pop; Claudiu Vasile Horga; Mircea Suciu  
*Romania*
- 18/  
 PP 577 **PROGNOSIS STUDY REGARDING THE ANNUAL RATIO OF MALOCCLUSION REPORTED CASES IN IASI USING THE TIME-SERIES ANALYSIS**  
Cristina Gena Dascalu; Georgeta Zegan  
*Romania*
- 19/  
 PP 452 **EFFECT OF DENTURE BASE MATERIALS IMMERSION IN NATURAL AND ARTIFICIAL SALIVA**  
Alexandru-Titus Farcasiu; Oana-Cella Andrei; Mihaela Pauna; Catalina Farcasiu  
*Romania*
- 20/  
 PP 542 **COMPARATIVE STUDY REGARDING THE MICRO-HARDNESS OF SOME AESTHETIC RESTORATIVE MATERIALS**  
Irina Grădinaru; Elena Raluca Baci; Daniela Calamaz; Maria Baci  
*Romania*

## SUNDAY, APRIL 26th, 2015

INTERCONTINENTAL HOTEL, RAPSODIA HALL

09:00

11:00

### **INTERDISCIPLINARY SECTION – PLENARY LECTURES and Oral presentations:**

**Chairmen: Prof. Dr. GABRIELA BANCESCU**

**Prof. Dr. MARIN BURLEA**

**Secretary: Lecturer Dr. VASILE VALERIU LUPU**

### **INTERDISCIPLINARY SECTION – PLENARY LECTURES:**

- L 554 **ENDOSCOPIC TREATMENTS IN DIGESTIVE HEMORRHAGE IN CHILDREN**  
MARIN BURLEA  
*Romania*
- OP 551 **GASTRIC ULCER AFTER SHORT-TERM NSAIDS ADMINISTRATION IN A SMALL CHILD - CASE REPORT**  
VASILE VALERIU LUPU; ANCUȚA IGNAT; GABRIELA PADURARU; ANAMARIA CIUBARA; MARIN BURLEA  
*Romania*
- OP 589 **DENTAL PATHOLOGY IN PATIENTS WITH SCHIZOPHRENIA**  
ANAMARIA CIUBARA  
*Romania*
- L 252 **INFECTIOUS ENDOCARDITIS PROPHYLAXIS IN DENTAL AND ENDOSCOPIC PROCEDURES IN CHILDREN: A PEDIATRICIAN'S POINT OF VIEW**  
SMARANDA DIACONESCU  
*Romania*
- L 437 **THE STREPTOCOCCI OF ANGINOSUS GROUP AND THEIR ROLE IN ORAL AND EXTRAORAL PATHOLOGY**  
GABRIELA BANCESCU  
*Romania*
- L 549 **ORAL MANIFESTATIONS IN GASTROESOPHAGEAL REFLUX DISEASE IN CHILDREN**  
VASILE VALERIU LUPU  
*Romania*
- OP 618 **DIAGNOSIS PROCEDURES AND THERAPEUTIC MANAGEMENT OF ENDODONTIC EMERGENCIES**  
MĂDĂLINA MATEI, KAMEL EARAR, MĂLINA COMAN, RĂZVAN LEATĂ, MIHAELA MOISEI  
*Romania*

# ABSTRACTS PLENARY LECTURES

## ABSTRACTS – PLENARY LECTURES

### L 50 PROBLEM SOLVING IN NON-SURGICAL ENDODONTIC RETREATMENT

ELKA RADEVA

*Bulgaria*

#### ENDODONTOLOGY

The use of modern endodontic treatment protocols, instruments and techniques result in high success rates for primary endodontic treatment. However, due to certain anatomical variations or after iatrogenic interference treatment might not result in a positive outcome. Nowadays, many of these cases can be treated non-surgically with a high long term success rate. There are available many rotary instruments, ultrasonic tips and special devices that can be used to remove gutta-percha, sealer, separated endodontic files, metal and fiber posts. Based on clinical evidence and supported by current literature this presentation will highlight a variety of clinical situation successfully manage using different techniques and instruments.

### L 102 CLINICAL APPLICATIONS OF BONDING TO ROOT CANAL DENTIN

LUMINITA MARIA NICA

*Romania*

#### ENDODONTOLOGY

Clinical applications of bonding to root canal dentin **Background:** Glass fiber posts adhesively cemented into root canal are currently the most accepted method for the restoration of endodontically treated teeth, with the proper clinical indication. The main objective is to create an adhesive monoblock into the root canal system. The effectiveness of this procedure mainly depends on the adhesion between the luting cement and the dentin; also, the type of endodontic sealer, the shape of the post or of the canal, the type of the luting cement and the structure of the root canal dentin may influence the mechanical resistance of this type of restorations. **Methods and materials:** Different types of adhesive cements were used in conjunction with fiber posts and two types of root canal filling materials in order to evaluate the adhesion to root canal dentin. Recently extracted human teeth were used in this study. The root canal preparation was completed with rotary NiTi instruments under a precise irrigation protocol. Teeth were randomly divided into groups, according to the root canal filling material and to the adhesive cement used for luting the post. One glass fiber posts was cemented in each root canal. The samples were sectioned in 1-mm height slices starting from the tip of the post and tested for push-out. Failure modes were microscopically evaluated and statistically analyzed using one-way ANOVA test. **Results:** The type of the filling material, the adhesive cement, the region of the root canal and the shape of the post are statistically influencing the push-out bond strength and the adhesion to root canal dentin. The predominant failure mode was a mixed one. Also, a higher percentage of adhesive failures between dentin and cement were observed. **Conclusion:** The restoration of endodontically treated teeth with fiber posts is nowadays the most used clinical method.

L 136

**RELATIONSHIP BETWEEN PERIODONTAL DISEASE AND CARDIOVASCULAR DISEASE**TEODORA NIKOLAEVA BOLYAROVA-KONOVA*Bulgaria*

PERIODONTOLOGY

Many epidemiological, experimental and clinical studies have provided evidence of periodontal infection as a risk factor for cardiovascular pathology. Mechanisms of interaction between such complex multifactorial diseases such as periodontal and cardiovascular ones are not fully understood yet, but suggest a few hypotheses: • direct involvement of bacteria of periodontal infection in the processes of atherogenesis and thrombosis; • direct involvement of inflammatory mediators of microorganism resulting from periodontal disease in the processes of atherogenesis and thrombosis; • existence of common independent risk factors for periodontal diseases and atherosclerosis – age, male gender, smoking, etc. • interaction resulting from combining the above mechanisms. On the basis of numerous references and results of her own studies, the author assesses the systematic effect of periodontal disease and reveals the essence of this interdisciplinary problem in order to justify again the need for prevention and treatment of periodontal diseases as a condition for prevention and control of widespread and frequently fatal cardiovascular diseases.

L 142

**APPLICATION OF THE OCT TECHNOLOGY IN DENTISTRY**MEDA LAVINIA NEGRUTIU; COSMIN SINESCU; CRISTINA MARIA BORTUN;  
VIRGIL FLORIN DUMA; ADRIAN GHEORGHE PODOLEANU*Romania*

NEW TECHNOLOGIES

**Introduction:** Optical coherence tomography represents a state of the art noninvasive method used for evaluation and prognostic in dentistry. The need of such an investigation method, rely on the need of dental clinician to have much more, better and faster amount of information from the interested dental area. **Material and methods:** Time Domain OCT system working at 1300 nm and Spectral Domain system working at 870 nm were used for this presentation. The depth of the investigations was approx. 3 mm in air for the TDOCT and 2 mm in air for the SDOCT. The slices obtained were used for the 3D reconstruction for the areas of interest. **Results:** The TDOCT system provides a much more depth information for a longer period of time (approx. 1 min) whiles the SDOCT system allow a much faster investigation (approx. few milliseconds) at a smaller depth inside the samples. The 3D reconstruction allows a better understanding of the information within the investigated samples. The ex vivo applications could be used for dental technology along with the research morphological considerations. The in vivo applications are related to many dental areas, including the dental therapy, endodontics, prosthodontics, orthodontics and implantology. **Conclusions:** The advantages along with the limitation of the OCT technology promote it as valuable tool in the future clinical dental procedures.

L 150

**APPLICATION OF THE MICROCOMPUTER TOMOGRAPHY (MICRO CT) TECHNOLOGY IN DENTISTRY**

COSMIN SINESCU; MEDA LAVINIA NEGRUTIU; NICA LUMINITA; CRISTINA MARIA BORTUN; VIRGIL FLORIN DUMA; ADRIAN MANESCU

*Romania*

**NEW TECHNOLOGIES**

**Introduction:** Computer X-ray micro tomography (micro-CT) is similar to conventional CT systems usually employed in medical diagnosis, as well as in industrial applied research. However, unlike these systems, which typically have a maximum spatial resolution of about 0.5 mm, advanced micro-CT is capable of achieving a spatial resolution of approximate 0.1 micrometers. **Material and methods:** Laboratory systems and synchrotron radiation facilities were used for this work and their features are discussed. The protocols of the samples preparation were different for each considered system and they are presented as applied. The investigation technology provides slices that were then used for the tridimensional (3D) reconstruction of the investigated samples. **Results:** The use of the X-rays delivered by Synchrotron Facilities has several advantages compared to the X-rays produced by Laboratory or Industrial sources. These advantages include: (i) a high photon flux which permits measurements at high spatial resolution; (ii) the X-ray source is tunable, thus allowing for measurements at different energy levels; (iii) the X-ray radiation is monochromatic, which eliminates beam hardening effects; (iv) parallel beam acquisition allows for the use of exact tomographic reconstruction algorithms. The ex vivo applications of the technique are related to numerous dental areas, including dental therapy, endodontics, prosthodontics, orthodontics and implantology. A discussion on these aspects is provided. **Conclusions:** Microcomputer tomography represents a high quality evaluation method designed for ex vivo investigations. The method also provides valuable validations for other imaging methods with lower resolution but with in vivo investigation capabilities, such as Optical Coherence Tomography (OCT).

L 211

**RADIOGRAPHIC EVALUATION OF THE TEMPOROMANDIBULAR JOINT PATHOLOGY. INDICATIONS AND GUIDELINES**

ANTIGONE DELANTONI

*Greece*

**ORAL DIAGNOSIS-ORAL RADIOLOGY**

The temporomandibular joint is an area difficult to investigate radiographically. There are a large number of radiographic techniques that may be used for showing different parts of the joint. Knowledge of the normal anatomy of the joint as well as the large number of pathological conditions that may affect the joint is required prior to a thorough radiographic examination. The aim of this lecture is to present the main indications of each radiographic technique for temporomandibular joint imaging, the diagnostic information they provide as well as the selection criteria for each. Also the main pathological conditions affecting the joint will be presented together with their main radiographic features. Overall the international guidelines and directions for radiographic imaging of the temporomandibular joint will be given together with the radiation dose



for each technique. The indications for each technique will be analyzed together with technique selection based on the type of pathological condition affecting the joint. The main techniques for TMJ pathology evaluation are: • Panoramic radiography indications include TMJ pain dysfunction syndrome, initial joint investigation, fractures of the condylar head, condylar hypo and hyperplasia and it provides information on the condylar shape and gives a direct comparison of both joints. • ConeBeam Computer Tomography is increasingly being used to investigate bony elements of the facial skeleton. Its main indications include full assessment of the whole of the joint to determine any bone disease, assessment of the extent of the pathological bony pathosis and detailed description of the disease affecting the joint • Magnetic Resonance Imaging is established as one of the most useful investigation of bony and soft tissue elements of the TMJ. IT is useful in establishing the position and form of the disc with open and closed mouth, the extent of internal derangement and as a preoperative tool prior to disc surgery.

**L 252**    **INFECTIOUS ENDOCARDITIS PROPHYLAXIS IN DENTAL AND ENDOSCOPIC PROCEDURES IN CHILDREN: A PEDIATRICIAN'S POINT OF VIEW**

SMARANDA DIACONESCU

*Romania*

**INTERDISCIPLINARITY**

Digestive endoscopy is part of modern methods of investigation of gastrointestinal tract in childhood, offering multiple diagnostic and therapeutic possibilities. Even if the procedure is invasive it has clear advantages in terms of the possibility of biopsy samplings under direct visualization of the mucosa biopsies and surveillance of celiac disease, intestinal polyposis syndromes and even of potential malignant lesions New techniques derived from the adult begin to be applied on a larger scale by the pediatric gastroenterologists in both diagnostic (enteroscopy, echo endoscopy) and therapeutic (pneumatic dilatations, esophageal varices banding, treatment of digestive hemorrhage by combined endoscopic clipping or argon plasma coagulation, PEG placement, endoscopic polypectomy, ERCP). In the last years the recommendations on subacute bacterian endocarditis prophylaxis in children with cardiac disorders which imposed digestive endoscopy were reviewed considering that the negative effects outweigh the benefits of antibiotic administration given that antibiotic prophylaxis can prevent only an extremely small number of cases. Currently prophylaxis is reserved only for high-risk patients (severe cardiac impairment associate with digestive tract infections), in some laborious procedures in digestive endoscopy (being no longer recommended in exploratory purposes) and also in dental procedures that involve manipulation of either gingival tissue or the periapical region of teeth or perforation of oral mucosa. Maintenance of optimal oral health and hygiene may reduce the incidence of bacteremia from daily activities and is more important than prophylactic antibiotics to reduce the risk of infective endocarditis.

**ORAL HEALTH STATUS AND TREATMENTS NEEDS AMONG SCHOOLCHILDREN FROM CRAIOVA, ROMANIA**SANDA MIHAELA POPESCU*Romania***COMMUNITY DENTISTRY**

**Objectives:** To assess caries prevalence, oral health status and treatment needs in a 6-12 years old schoolchildren population in Craiova, Romania. **Methods:** 1056 children were randomly selected from 8 schools in Craiova. Dental caries and treatment needs were evaluated using international methodological standards of World Health Organization. **Results:** The DMFT index averaged 0.77 and the DMFT index was 2.77. While 36.75% of the children had caries on permanent teeth, 73.94% of children had caries on temporary teeth. High caries risk index was found for 48.54% of all children, while 46.6% of all children showed moderate caries risk index. Treatment needs reach a mean value of 3.54 teeth per person. Over 90% of the caries lesions were found in pits and fissures. Dental sealant and resin preventive restorations were the most indicated interventions for the sample children. The next most indicated dental treatment is filling of one surface. **Conclusions:** The prevalence of caries and treatment needs among schoolchildren of Craiova is high. Extended caries preventive programs are needed to be developed in schools and kindergartens with special emphasis on prevention in high risk caries group.

**DENTO-PERIODONTAL CHANGES IN ORTHODONTIC TREATED ADULT PATIENTS**MARIANA PĂCURAR; MONICA MONEA; TUDOR HĂNȚOIU; STEFANIA DINU; IRINA ZETU*Romania***ORTHODONTICS**

The correlation between the presence of dento-maxillary anomalies and periodontal suffering was highlighted by many researchers. The existence of significant number of adult patients with malocclusions accompanied by periodontal changes occurred early or late orthodontic treatment is a real problem. The purpose of this study is to evaluate the level of periodontal changes during fixed orthodontic therapy and also to present the options treatment for late complications: cervical resorptions. **Material and method:** A clinical statistical study on 52 adult patients, males and females, aged 30-50 was conducted to estimate the prevalence of gingival recession, root resorption and cervical resorption, caused by orthodontic treatment. Orthodontic treatment was by straight-wire method, Roth prescription 0,22, using light forces. The patients had periodontal exam before treatment for evaluate the gingival level. They had also OPT before treatment, at six month and after brackets removed. **Results:** The authors found a less prevalence of periodontal changes: cervical resorption: 1%, gingival recession 2% and root resorption 3%. These changes can be reduced by a good oro-dental hygiene, by avoid the intrusive forces in frontal area and by monitoring the patient during orthodontic treatment. **Conclusions:** Fixed orthodontic treatment in adult patients should be established after assessment of marginal periodontium, including level and type of attached gingiva.

**L 337 ASYMMETRIES : DIAGNOSIS AND TREATMENT****CHANGE-HEUN PARK***Republic of Korea***ORTHODONTICS**

Asymmetry in the face and dentition is a naturally occurring phenomenon. In most cases facial asymmetry can only be detected by comparing homologous parts of the face. The etiology of asymmetry includes: a) Genetic or congenital malformations e.g. hemifacial microsomia and unilateral clefts of the lip and palate; b) Environmental factors, e.g. habits and trauma; c) Functional deviations, e.g. mandibular shifts as a result of tooth interferences. Dental asymmetries and a variety of functional deviations can be treated orthodontically. On the other hand, significant structural facial asymmetries are not easily amenable orthodontic treatment and may need to have surgery. If a patient wants to treatment asymmetries, orthodontist should diagnosis and establish treatment plan. In diagnosing facial and dental asymmetries, a thorough clinical examination and radiographic survey; the lateral cephalogram, the panorama, the frontal cephalogram, submentovertex view and 3D CT are necessary. Frontal X-ray is easily and economically obtained and useful to diagnosis and treatment planning of patients with asymmetric problems. There are a number of analyses of frontal x-ray. I would like to introduce very simple and useful asymmetry analysis and my clinical experience.

**L 391 EVALUATION METHODS OF BONE GRAFT MATERIALS****HORIA-OCTAVIAN MANOLEA; MONICA CRĂIȚOIU; EDUARD CIUCĂ; ADRIAN FRONIE; RADU RÎCĂ***Romania***DENTAL BIOMATERIALS AND DEVICES**

Bone graft substitute materials play an important role in oral rehabilitation and understanding the biological effects of these materials is important for an optimum use. Many bone graft substitutes have been approved for clinical use but this large variability make it hard to select a graft materials. The evaluation methods of bone graft materials include in vivo and in vitro methods. In vivo methods comprise clinical and imagistic evaluation such as radiological or CT exams. Although the particular linear measurements are quite accurate, they can only provide an estimate of the augmented bone's volume. CBCT scan is the imaging method of choice in the graft materials reparation of the osseous defects because provides 3D volumetric measurements of newly formed hard tissues. For the in vitro methods histological and histomorphometrical methods represents the classical evaluation of the bone graft materials biological integration. The bone biopsy samples may be taken from patients receiving two-stage augmentation therapy in implantation areas or from laboratory animals models. Histomorphometric measurements are used to quantify the relative amounts of different tissue types within the grafted area. However new emerging methods give new opportunities to a more accurate research of these materials. Optical Coherence Tomography (OCT) is an imaging technique characterized by high spatial resolution and noninvasive subsurface detection. OCT images are useful to evaluate optical properties of bone

tissues. The microcomputed tomography analysis may determine the relationships and differences in three-dimensional bone mineral density and microtrabecular structures between bone grafts and their adjacent native bone. To design and produce an efficient bone graft, the researchers and clinicians should have sufficient knowledge of the characteristics of grafts such as osteogenesis, osteoinductivity, and osteoconductivity, and their other advantages and disadvantages.

**L 413**    **DIGITAL DESIGN, IMPLEMENTATION AND EVALUATION OF PROSTHETIC SINGLE TOOTH RESTORATIONS**

LILIANA POROJAN; SORIN POROJAN

*Romania*

**NEW TECHNOLOGIES**

As a result of technological developments, changes occurred both in production methods and concepts within the evaluation of single tooth prosthetic restorations. Advances in computer technology, allows the production of individual pieces and have become increasingly common in recent years. Cercon system (DeguDent) was used for technological steps be taken to achieve single tooth restorations. Most of the benefits associated with computer generated dental prosthetic restorations include: access to new industrial prefabricated and controlled materials, without defects, an increase in quality and reproducibility and also an emerging data storage in a standardized production chain, an improvement in the precision and planning, as well as an increase in efficiency. In parallel with this digitization technology, in dental prosthodontics began to impose calculations which require knowledge of modern computer-assisted design and evaluation, namely numerical simulations. Finite element studies provide a mechanistic explanation for single tooth restored teeth with different prostheses. Different geometry parameters and the correlation between them were evaluated. The advantage of this type of analysis is that it allows the simulation for various situations. The analyses evolve continuously, both in terms of three-dimensional modeling and computer aided design methods and numerical analysis. CAD / CAM technology of single tooth restorations is now at a stage where they can be achieved to similar functional standards as conventional counterparts and computerized assessment procedures allow the optimization of the design adapted to the new materials.

**L 417**    **ENDODONTIC SURGERY. DIAGNOSIS AND THERAPY USING CONE-BEAM CT AND OPERATING MICROSCOPE**

CHARIS BELTES

*Greece*

**ENDODONTOLOGY**

This presentation intends to display indicative periapical surgery cases, illustrating the parameters to be considered in order to select the appropriate treatment plan, following an accurate preoperative evaluation comparing conventional radiograph and cone beam computed tomography (CBCT). The radiographic findings were taken under consideration and reassessed, intraoperatively, through examination under dental operating microscope, in order to investigate all

the reasons of failure in the non-surgical endodontic treatment. CBCT is available to provide small field of view images at low dose with sufficient spatial resolution for applications in endodontic diagnosis and treatment guidance and especially for pre-surgical case planning, in order to determine the exact location of root apex/apices and overall morphology, the detection of periapical pathology, to evaluate the proximity of adjacent anatomical structures, to assess overextended root canal obturation materials, separated endodontic instruments, calcified canal identification, and localization of perforations and internal / external resorptions. The application of dental operating microscope in surgical endodontics is associated with the improvement of clinical and radiographic outcomes, in relevance with the pre- and intraoperative findings. The exact identification and management of endodontic failure can be achieved through accurate three-dimensional representations and microscopic inspection during surgery. CBCT is helpful for diagnosis and treatment planning in most of cases for endodontic surgery. The combination of both CBCT and operating microscope in endodontic surgery, when they are essential, can provide all the benefits to be performed with an accuracy and predictability of results that were not possible to reach 10 - 15 years ago.

**L 428 INTRODUCTION OF IMPLANT SUPPORTED OVERDENTURE**

KWIDUG YUN

*Republic of Korea*

**ORAL IMPLANTOLOGY**

The dental profession and the public are more aware of the problems associated with a complete denture than any other dental prosthesis. The placement of implants enhances the support, retention, and stability of a denture. There is greater flexibility in implant position or prosthesis fabrication with a denture, and as a result, it is also an ideal treatment modality to begin a learning curve in implant dentistry. I prepared the overview of implant overdenture. Through my presentation, I hope that implant dentistry or implant overdenture will be your treatment option.

**L 437 THE STREPTOCOCCI OF ANGINOSUS GROUP AND THEIR ROLE IN ORAL AND EXTRAORAL PATHOLOGY**

GABRIELA BANCESCU; ADRIAN BANCESCU

*Romania*

**INTERDISCIPLINARITY**

The oral streptococci belonging to anginosus group (which was previously known as Streptococcus milleri group) are included into three different species: Streptococcus intermedius, Streptococcus constellatus and Streptococcus anginosus. S. constellatus is subdivided into: S. constellatus subsp. constellatus and S. constellatus subsp. pharyngitis. The strains of S. intermedius are alpha- or gamma-haemolytic, while more than one-tenth and one-third of S. anginosus and S. constellatus, respectively, are beta-haemolytic. The members of S. anginosus group are known as commensal microorganisms in the oropharynx, gastrointestinal and genitourinary tract. These oral streptococci may be involved in many oro-maxillo-facial pyogenic diseases and can determine also

invasive infections (especially in immunocompromised patients), with deep-seated abscesses formation. *S. intermedius* is often isolated from liver and lung abscesses, while the other two species are involved in a wider spectrum of infections (e.g., different head and neck infections, ear, nose and throat infections, cardiovascular infections, pleuropulmonary infections, abdominal infections, urogenital infections, skin and subcutaneous infections, musculoskeletal infections, obstetrical and neonatal infections). The strains belonging to this streptococcal group are usually susceptible to penicillin. However, the infections caused by the streptococci of anginosus group are often requiring surgical procedures also. Because of its importance for human pathology, this group of bacteria deserves a better understanding and attention from clinicians.

**L 487**    **FUNCTIONAL AND AESTHETICAL RECONSTRUCTION OF LARGE MAXILLOFACIAL DEFECTS**

HANA HUBALKOVA; MARIE BARTONOVA; JINDRICH CHARVAT; JIRI MAZANEK;  
RENE FOLTAN  
*Czech Republic*

**INTERDISCIPLINARITY**

Oncological diagnoses, injuries and born anomalies of the head and neck area are frequently joined with extensive defects of soft and hard tissues. They are also caused by initial oncological surgery. After performing reconstruction therapy the next task for members of medical team is to ensure patient's rehabilitation enabling better health-related quality of life. Prosthetic treatment using a facial epithesis is often used for aesthetical and functional replacement of lost facial structures. Goal of the presentation is to demonstrate borders of state-of-art prosthodontic technologies in reconstruction of large maxillofacial defects. Presented case reports document specific prosthodontic rehabilitation of a facial basalioma or granuloma gigantocellularis in the young patient after several surgical interventions; facial injury caused by the horse fling with a fracture Le Fort II or by the blow by a log from a circular saw; branchial arches congenital developmental defect of the left auricular area or a cleft patient. Prosthodontic care involving modern materials and technologies, e.g. titanium implants, dental ceramics, CAD/CAM, magnets, aesthetical silicones, rounded out previous multidisciplinary treatment. Contemporary technologies and materials are able to rehabilitate missing maxillofacial structures aesthetically and often functionally, but highly sophisticated biological structures and their functions (sight, salivation) are beyond today's know-how.

**L 523**    **RETROSPECTIVES IN ORO-DENTAL PREVENTION OF DISEASES IN ROMANIA**

IOAN DANILA; CATALINA IULIA SAVEANU  
*Romania*

**PREVENTIVE DENTISTRY**

**Background:** Prevention of oral and dental diseases is one of the most important and inexpensive treatment methods available today. World Health Organization projects for the future that children aged 12 will have a DMF index value (teeth that are decayed, missing and filled) of up

to 1. This aim can only be achieved through the involvement of decision-making forums in accepting funding for preventive oral and dental programs. For this purpose we conducted a research based on the dynamic monitoring over a period of 10 years that assessed the dental status of preschool children and schoolchildren with ages up to 12 years. Our studies also evaluated the level of food hygiene and oral hygiene knowledge in school teachers, mothers and children. **Results:** Subsequent to implementation of educational programs and local fluoridation with weekly fluoride rinses, the results indicate an improvement in the educational level, a growth rate in children brushing and a decrease of dental caries prevalence, intensity and gravity. **Conclusions:** The present desire in promoting oral health through school programs is to increase the children's quality of life, for children's health is an indicator of the community's health.

**L 536 THE INTERDISCIPLINARY APPROACH IN ORTHODONTICS**

IRINA ZETU; MARIANA PACURAR; LIVIU ZETU

*Romania*

**ORTHODONTICS**

As Dekker said, Orthodontics is the art of rearranging dento-maxillary unit in the context of functional and esthetic equilibrium. In the last years, orthodontics has progressed a lot, because of the development of the diagnostic methods and treatment options. Orthodontics is on the threshold of a change in diagnosis and treatment planning from the traditional emphasis on the dental and skeletal components of a problem to a greater attention to soft tissue. This change is occurring because of a paradigm shift in conceptual underpinnings of orthodontics. This increased attention to soft tissue and deemphasis on perfection combine to form a biologically driven paradigm that will better serve orthodontics in the twenty first century. It represents a philosophical "180-degree turn" in the orthodontic conceptual framework. Also we see an increase in the addressability of patients with dentomaxilar abnormalities both as young patients and adult patients. The complexity of the dentomaxilar abnormalities requires increasingly more and more an interdisciplinary approach and team work. The multidisciplinary team is composed of the following specialists: pediatrician, dentist, ENT specialist, periodontist, prosthetist, oral and maxillofacial surgeon. Also, nowadays the orthodontic pre-prosthetic treatment is a must, not a luxury. In the following conference, we will present some complex cases, which needed an interdisciplinary approach: orthodontics-periodontology, orthodontics-prosthetics, orthodontics-ENT, orthodontics-maxillo facial surgery.

**L 549 ORAL MANIFESTATIONS IN GASTROESOPHAGEAL REFLUX DISEASE IN CHILDREN**

VASILE VALERIU LUPU

*Romania*

**INTERDISCIPLINARITY**

The gastroesophageal reflux disease (GERD), also called „the disease of the 3-rd millennium“, is the intermittent or permanent passage of gastric contents in the esophagus. It may be manifested by typical symptoms (vomiting, regurgitation) and atypical ones (respiratory,

neurobehavioral and oropharyngeal). Patients with GERD present higher incidence of dental erosion, canker sores, mouth burning sensation, sensitivity and sour taste. The presence of *Helicobacter pylori* (*H. pylori*) in dental plaque may occur as the result of GERD. It is still unclear if the low numbers of *H. pylori* present in the mouths of most patients would be sufficient to serve as a source of infection or reinfection for gastric conditions. Whether dental plaque is a significant source for reinfection of the gastric mucosa among patients with fair to poor oral hygiene remains to be confirmed. *H. pylori* may also be a cofactor in the recurrence of aphthous ulceration. GERD therapy consists of general and dietary measures, medical and surgical treatment.

**L 554**    **ENDOSCOPIC TREATMENTS IN DIGESTIVE HEMORRHAGE IN CHILDREN**

MARIN BURLEA

*Romania*

**INTERDISCIPLINARITY**

Digestive hemorrhage in children may evolve from the occult form up to events with major vital risk. The etiology includes extra-digestive diseases (acute pathology of the nervous system, coagulopathies, portal hypertension) or digestive (infectious, malformations, inflammatory) with a frequency depending on age. The personal history with numerous chances of error is completed with a systematic exploration: the severity of blood loss, its reflection on vital organs functions, detecting underlying medical reasons or surgical causes malformative or acquired. Treatment is depending on the severity of blood loss, on the necessary medicines with etiopathogenic impact. Digestive endoscopy, in addition to its important role as diagnosis method, is sometimes also a therapeutic method.

**L 556**    **IMPLANTO-PROSTHETIC MODERN REHABILITATION TECHNIQUES**

NORINA FORNA

*Romania*

**ORAL IMPLANTOLOGY**

Classical implant-prosthetic rehabilitation techniques always have a very small registry of use as they have limited accuracy, which involves the implantation axis imperfections that are directly related to inaccurate occlusal reports. Computerized techniques increasingly occupy more of the implantation interventions of prosthetic restorations, interventions that have high accuracy, efficiency, and are time-saving. Robots used for a number of patients evaluated both by classical and modern techniques offered in 80% of the cases, the ideal implant position with maximum economy of bone. The precision of choosing an optimal implantation axis helps to reduce angulation of the implant abutment and therefore helps obtaining a correct occlusion rapport. Navigation in implantology as any other type of medical navigation provides an accurate picture in real time execution avoiding any future risks and failures. Implant planning will seek thereby adequate implant-prosthetic treatment plan.



**L 583****DENTAL INCLUSION - STUDY OF A PARTICULAR ASPECT OF THE PERMANENT TEETH ERUPTION**ANDREI KOZMA; CRISTIANA GLAVCE*Romania***INTERDISCIPLINARITY**

Dental inclusion is an isolated dental position anomaly, which is emerging during tooth eruption, as a particular aspect. Dental inclusion mean when dental tooth remains unerupted in the jawbone, the age at which normally should have been in the arcade. In etiopathogenic terms dental inclusions are generated by multiple items, different authors systematized in many classifications in which predominate local causes. Some of them, including us, consider the disproportionate reducing of maxillary (arches and teeth) as a cause of occurrence of dento-maxillary anomaly with lack of space, resulting especially inclusion of canines and molars. We realized a study of dental inclusions in one part of the population investigated regarding an mixed-longitudinal study of dental eruption. Of the total of 1235 cases investigated in order to determine the frequency of dental inclusions 6.8% of individuals presenting various forms of inclusion. Inclusion was observed predominance of permanent teeth equally to boys and girls, except canine upper jaw with predominance in girls. Clinical variability of dental inclusion at the subjects examined by us was detected depending on the affected tooth: 47% is noticeable for canine and 53% in the rest of inclusions.

**L 585****ORAL HEALTH STATUS OF CHILDREN WITH DEVELOPMENTAL DISABILITIES IN THE REPUBLIC OF MOLDOVA**AURELIA SPINEI*Republic of Moldavia***PAEDIATRIC DENTISTRY**

The aim of the study was to evaluate prevalence of caries and oral hygiene status of children with different disabilities in the Republic of Moldova. **Material and methods:** A case control study on disabled children was conducted between 2011 and 2014. Two groups of randomly selected children aged 1-18 years old were examined. The first group comprised 2315 children with disabilities and the second (control) group included 2358 healthy children. Clinical data on dental caries were collected according to the World Health Organization index criteria. The following indices have been estimated: prevalence index (PI) of dental caries, and DMFT index. The degree of oral hygiene was evaluated according to the OHI-S index values. The study was conducted in compliance with ethical requirements. SPSS program was used for statistical analysis. **Results:** Significant differences were noted in the frequency of dental caries among subjects with disabilities and their healthy controls ( $p < 0.001$ ). Dental caries was present in  $79.39 \pm 0.9\%$  of children with disabilities compared with  $56.49 \pm 1.0\%$  of children ( $t = 12.9$ ;  $p < 0.001$ ) from the control group. The probability of dental caries in the group of disabled children is 3 times higher ( $OR = 3.04$ , 95% CI: 2.7-3.4) than in children without disabilities. The values of OHI-S index ranged between 3.8 and 4.53 in disabled children and between 2.73-2.84 in healthy children. To reduce dental caries and periodontal diseases "The oral health programme in children with disabilities and special

educational needs” was worked out, it having been implemented since 2012. **Conclusion:** The results revealed a significantly poor level of oral hygiene and a quite high level of caries prevalence in both disabled and healthy children, emphasizing the need to reorganize preventive care measurements and improve dental care, particularly in disabled children in the Republic of Moldova. The results of this study will be used to select the methods and remedies for prevention of dental caries in children with disabilities.

**L 590** **TRAUMATIC OCCLUSION AND ITS TREATMENT (CLINICAL AND EXPERIMENTAL STUDY)**

ALKETA QAFMOLLA

*Albania*

**FIXED PROSTHODONTICS**

The absence of teeth is followed by functional and structural changes which need to be considered. This absence of teeth is the main factor of traumatic occlusion. The traumatic occlusion is a continuous overcharge of the dental system during the biting function which damages the periodontium. This depends on the time, size and direction of the damage in the periodont and alveolar bone. **The aim of the study:** is to identify the factors contributing on the traumatic occlusion and the treatment options. The main attractive is the study of the factors of the traumatic occlusion tested in animals and comparing the results with the studies conducted in humans. **Material and method:** 88 patients 35-70 years old are involved in this study for 4 years period. The study is taking into consideration the age of the patient. The traumatic occlusion is provoked experimentally in animals putting a prosthesis in abnormal position. The clinical and histopathological changes are investigated. The treatment of the patients was performed by therapeutic prosthesis. **Discussion and Results:** The absence of the teeth and not substituting them for a long time causes overcharge of the remaining teeth. We prepared 109 prosthesis of which 72(66.05%) were skeletal prosthesis. 27(24.77%) were bridges and 10(9.18%) were splints. The dual effects were 49(68.05%) of the total cases and 23(31.95%) were single defects. The results were evaluated by subjective, clinical and röntgen parameters, which have shown improvement and interruption of the pathological process. The improvement that happened were described by fact, because the teeth haven't any charges, and then the periodont has enough time to recover its normal function through its compensation forces. **Conclusion:** The prosthetic rehabilitation of missing teeth is efficient option for treatment of the traumatic occlusion.

**L 591** **DESIGNING A RESEARCH PROJECT, PROTOCOL WRITING**

DORJAN HYSI

*Albania*

**INTERDISCIPLINARITY**

Research means a scientific and systematic search for information on a specific topic. The purpose of research is to discover answers to questions through the application of scientific procedures. Research designs refers to the plan, structure, and strategy of research, the guideline that will lead the research process. To design a research project several stages need to be followed. It

starts with the initial idea, topic and definition of a research question. It is fundamental for the research topic to be important to the individual or group concerned. The research question should indicate the goal of the study, a summary of what is to be achieved. The next stage is a literature search about previous work that has been done on our topic, the methodologies used, the results obtained and the quality of these researches. This will help us to focus and refine our question. Now it is time for planning the study by defining the aim, objectives and if it will be a qualitative or quantitative one. Every type of study has its specification that are not the focus of this presentation. The most important stage is writing the research protocol. It is the starting point for all quality research and indicates that the proposers have, as far as possible, considered all relevant points before starting the project. This is a formal document that normally covers the title, administrative details and a summary, introduction, aim, statement of the problem, methods, analysis of data, proposed schedule, facilities required, budget, further considerations and references. This section will be discussed further during the presentation. Also part of the research are obtaining ethical approval and funding. When everything is set it is time for piloting study methodology and project implementing. Then the data collected will be analyzed and at the end it should be planned to write and disseminate the results.

**L 592**     **MANAGEMENT OF DEFICIENT RIDGES: THE CASE REVIEW**  
MUHAMED AJANOVIC  
*Bosnia and Herzegovina*

#### REMOVABLE PROSTHODONTICS

This lecture will demonstrate basics of bone augmentation in maxilla and the treatment of two advanced cases of maxillary deficiency. The emphasis of this presentation will be on GBR and sinus lift state-of-the-art surgical augmentation therapies to optimize dimensional increases in the deficient ridges in the maxilla. The first case presented, of severe and moderate bone defect, in the Anterior Maxilla, the bone were reconstructed by using the GBR/TiMesh technique in a systematic team oriented protocol to get the best esthetic results. The second case is lateral-window approach for maxillary sinus augmentation to allow for the placement of implants in maxillary posterior edentulous sites with significant pneumatization of the sinus cavity. Implants placed simultaneously with the lateral window sinus augmentation technique enjoy high success rates that are reported to be similar to implants placed in pristine bone in the maxilla.

**L 593**     **AMSA (ANTERIOR AND MIDDLE SUPERIOR ALVEOLAR) INJECTION IS EFFICIENT FOR MAXILLARY TEETH EXTRACTION**  
TOMIĆ SLAVOLJUB  
*Bosnia and Herzegovina*

#### ORAL SURGERY - ORAL MAXILLOFACIAL SURGERY

**Background:** The anterior and middle superior alveolar (AMSA) nerve block was claimed to be unpredictably efficient for clinical application. The **aim** of this report was to establish the efficacy of the AMSA nerve block, applied with a computer-controlled injection system or a conventional syringe, for upper premolars extraction. **Material and method:** Sixty healthy adults

were divided in two groups regarding the device used: the first group was injected by a computer-controlled injection system and the second group by a conventional syringe. Pain ratings were obtained via a visual analog scale and a verbal rating scale. **Results:** AMSA injection enabled a painless extraction in all patients, regardless the local anesthetic or injection system used. It was slightly less painful when administered by a computer-controlled injection system, but insignificantly when evaluated by VRS. **Conclusion:** The AMSA nerve block may be recommended if maxillary permanent premolars have to be extracted. This is a relatively new technique for anesthesia in the upper jaw and the goal of this session is to highlight the advantages of this technique has in oral surgery removing the upper premolars and point to the possibility to application of the classical karpul anesthesia syringe and computer-assisted system, and the possibility of its application with all the gentle benefits in other areas of dentistry.

**L 594** **INTERPRETATION OF PERIODONTAL AND PERIAPICAL LESIONS USING  
CONE BEAM COMPUTED TOMOGRAPHY (CBCT)**

ATILLA BERBEROGLU

*Cyprus*

**ORAL DIAGNOSIS - ORAL RADIOLOGY**

Cone beam CT (CBCT) produces three-dimensional information on the facial skeleton and teeth and is increasingly being used in many of the dental specialties, including periodontics, endodontics, orthodontics, orthognathic surgery, trauma and implantology. Being familiar with anatomy and pathology especially in periodontology and Periapical lesions as well as endodontics/trauma patients would help professions to discover occult diseases and maxillofacial pathology cases esp. that has refereed pain earlier. In this presentation, based on the literature and own experience, an overview is given of the current potential of CBCT in interpretation of periodontal and Periapical lesions.

**L 595** **DIAGNOSTIC APPROACH OF PAROTID LUMPS**

GEORGIOS PANTELAS

*Cyprus*

**ORAL SURGERY - ORAL MAXILLOFACIAL SURGERY**

Parotid, "para oti", is a Greek word, which means near the ear, so any lump near the ear must be considered as parotid tumor until proven otherwise. The parotid gland tumours comprise 3% of all tumours of the human body and from these the 75% - 85% concern benign tumors and 20-25% are malignant. Their behaviour varies according to the histopathological subtype. The final accurate diagnosis of parotid lump is done with surgical excision of tumor and histopathological examination. There are several key points in the preoperative examination of a patient with a parotid tumor. Is the tumor is benign or malignant, does the tumor involve the facial nerve or involve the deep lobe, neck dissection is required or not? In this presentation we analyzed the factors that indicate malignancy and the preoperative diagnostic aids which give useful information

and help in planning to the treatment, through our experience of more than 300 operated parotid gland tumors.

**L 596 DENTAL REHABILITATION: ON THE CROSSROADS OF CONVENTIONAL AND REGENERATIVE APPROACHES**

PETROS KOIDIS

*Greece*

**ORAL IMPLANTOLOGY**

Dental diseases, such as caries, periodontitis, tooth loss and orofacial/dental trauma are major public health problems worldwide, with a profound effect on an individual's quality of life. Current conventional strategies of rehabilitation and problem management are based on non-biological artificial substitutes, such as dental fillings, fixed and removable partial dentures supported by teeth and/or implants, complete dentures etc. All these have served our profession and patients' needs for several decades through a continuous evolution in materials and techniques, overpassing limitations and disadvantages while targeting patient satisfaction and long-term therapeutic efficacy. Furthermore, the need for alternative therapies is evident in several reports, which reveal startling statistics about the high incidence of tooth loss and edentulism. Recent progress in dental tissue engineering have provided the opportunity envisioning innovative alternative therapies based on regeneration strategies of the lost dental, periodontal and bone tissues in the craniofacial area. The aim of this presentation is to bring more insight into the current achievements on both conventional and regenerative rehabilitatin tools and technologies and to present some current scientific data of our research group in this field.

**L 597 ORAL MANIFESTATIONS OF METABOLIC BONE DISEASES**

ANASTASIOS MARKOPOULOS

*Greece*

**ORAL IMPLANTOLOGY**

Metabolic bone disease is a term referring to abnormalities of bones caused by a broad spectrum of disorders. The most common metabolic bone diseases are osteoporosis, osteomalacia, Paget's disease and hyperparathyroidism (osteitis fibrosa cystica). Usually, these disorders are caused by abnormalities of minerals such as calcium, phosphorus, magnesium or vitamin D and may give stomatognathic manifestations. The purpose of this lecture is to highlight these stomatognathic manifestations of the metabolic diseases, so a general dental practitioner can be able to recognize them. The clinical features of every disease and the differential diagnosis will be analyzed. The treatment options of each disorder will also be discussed.

**L 598****SYSTEMIC DISEASES AND TREATMENTS AS RISK FACTORS FOR DENTAL IMPLANT REHABILITATION**ANASTASIOS MARKOPOULOS*Greece***ORAL IMPLANTOLOGY**

Systemic diseases may affect oral tissues either by manifesting lesions, by increasing their susceptibility to other diseases or by interfering with healing. The purpose of this lecture is to evaluate whether systemic diseases or various treatments are risk factors of implant failure and therefore diminish success of dental implant rehabilitation. Systemic diseases and treatments that will be discussed, include: scleroderma, Sjögren's syndrome, neuropsychiatric disorders and/or Parkinson disease, oral lichen planus, AIDS or HIV, ectodermal dysplasia, Crohn's disease, transplantation, cardiovascular diseases, diabetes or insulin therapy or glucose intolerance, osteoporosis, intake of oral bisphosphonates and irradiation for oral cancer. Generally, the level of evidence indicative of absolute and relative contraindications for implant therapy due to systemic diseases is low and needs further research.

**L 599****METICULOUS PREPARATION IS THE MOST IMPORTANT FACTOR IN IMPLANT SURGERY**STYLIANOS DALAMPIRAS*Greece***ORAL IMPLANTOLOGY**

There are almost 30 years of experience with implants, but failures are seen in daily practice. And after the examination of cases, in order to understand the reasons of failure, someone can see that the problems are the outcome of common violations of the rules of implantology. The most common observation is that many implants are placed with high risk of failure, since they are not surrounded with bone or are simply outside of bone. This is hundred percent a human error and most likely is a result of total lack of preparation. What is the meaning of preparation in implant surgery? Preparation in implant surgery is the summary of methods in use to assure the correct placement of implants in to an adequate bony tissue environment. This is most important and if not more, is as important as the selection of a patient free of systemic diseases (diabetes etc.) How we can achieve our goal for a correct placement? There are many ways to a successful surgery but besides the perfect manipulation in the operative field, the surgeon must know exactly where to drill and how deep he can drill. So the preoperative period is dedicated to the precise imaging of the area and above all the measurements of the bone along with the axis of insertion of the drill. All these parameters are today a routine procedure and they can assure a safe and prosperous operation. MATERIAL: The material of this presentation is a series of failures attributed to the lack of preparation and to the arrogance of the experienced surgeon. Emphasis is given to the correct measures someone must take in the planning (preoperative) period.

**L 600****OCCLUSAL SCHEMES FOR COMPLETE DENTURE PROSTHESIS**ARGIRIOS PISSIOTIS*Greece***ORAL IMPLANTOLOGY**

In complete denture prostheses the anterior teeth determine the esthetic and phonetic rehabilitation of the edentulous patient whereas the posterior teeth determine the functional performance of the complete dentures. It has been from a long time established, that the functional requirement of the complete denture prostheses is a bilaterally balanced occlusion. Although research has not demonstrated that this is true, bilateral balanced occlusion is still considered the gold standard. Over the years other more simplified occlusal schemes have been introduced along with the design of posterior teeth that can be used to accommodate them. Nowadays the clinician has a variety of occlusal schemes that can be prescribed in order to provide functional complete dentures for the edentulous patient. These occlusal schemes will be presented and guidelines for their selection will be outlined.

**L 601****CBCT IN DENTISTRY - A TRUE NEED OR A WHIM?**ZORAN VLAHOVIĆ*Montenegro***ORAL DIAGNOSIS - ORAL RADIOLOGY**

Cone Beam Computer Tomography (CBCT) is a relatively new type of computer tomography which has been used since 1996. Its basic characteristics include: lower radiation level, cheaper technology and exquisitely good possibility for its application in dentistry. Cone Beam Computer Tomography is a medical imaging technique promoted as a new concept of diagnostic radiology, but with the advancement of technical features of medical devices and accompanying software support, today, it is the gold standard when it comes to diagnostic procedure methods for the craniofacial region for both dentistry and otolaryngology. In relation to "classic" computer tomography which uses multiple or prolonged x-ray exposure, the technical concept of CBCT device is to use one circular cone beam x-ray exposure in order to produce an x-ray image. Our presentation explains the concept of a CBCT device, technical characteristics, how a 3D image is being generated and advantages and disadvantages of this technique as well. We will present some interesting cases from different branches of dentistry (endodontic treatment, planing of orthodontic therapy, oral surgery diagnostics, implantology planing) where the use of CBCT is of vital importance from the diagnostic standpoint. Furthermore, on concrete practical cases, we will present the role of CBCT within computer-assisted dentistry, i.e. computer-aided navigation in dental implantology and 3D printing of implant surgical guides.

Habit is defined as a fixed or constant practice established by frequent repetition. It is a frequent or constant practice or acquired tendency, which has been fixed by frequent repetition. Habit is also defined as a tendency towards an act or an act that has become a repeated performance, relatively fixed, consistent, easy to perform and almost automatic. Oral habit is any repetitive behaviour that utilizes the oral cavity. Oral habits are learned patterns of muscular contractions. When habit cause defect in orofacial structure it is termed as pernicious oral habit. Oral habits in infancy and early child hood can be considered normal. The presence of an oral habit in the 3 to 6 year old is an important finding in the clinical examination. An oral habit is no longer considered "normal" for children near the end of this age group, because it may produce harmful effects on the development of maxillofacial complex. The type of changes resulting from oral habits depends on: 1. Intensity 2. Duration 3. Frequency of the habit. Intensity is the amount of force that is applied to the teeth while performing the habit. Duration is defined as the amount of time spent performing the habit. Frequency is the number of times the habit is practiced throughout the day. All those factors together should be considered, but duration plays the most important and critical role in tooth movement. The lecture focuses on systematic review of a few classifications by many authors. More information is introduced and commented covering the topics of many oral habits such as: useful habits/ harmful habits; pressure habit/ non-pressure habit; compulsive/ non-compulsive habits; empty/ meaningful habits; functional oral habit, muscular habits, combined muscular habits, postural habits are. The presentation gives valuable information regarding causative factors, prevalence and development of oral habits. The lecture analyzes clinical features (extraoral and intraoral examination), management and treatment modalities of introduced oral habits. The identification and assessment of an abnormal habits and its immediate and long term effect on the craniofacial complex and dentition should be made as early as possible to minimize the potential deleterious effect on dentofacial complex.

Dental bonding procedures started a new era in restorative dentistry. The improvement in adhesive techniques produces a strong connection with the tooth structure and in the same time high esthetical level recognition. Although, clinically the final success depends from the knowledge of the dentist, technique sensitiveness of the available system and how is applied to the clinical situation. Ideal dental adhesive system should provide and fulfill a lot of criteria such as biocompatibility, bond strength, preventing of microleakage and recurrent caries etc. This topic analyze the latest systems of dental market, comparing them between them opportunities to achieve



as many of the expected features. Here are represented weak points that need to be taken and offer possible solutions to avoid them. Tooth hypersensitivity following the restoration is uncomfortable for both participants. Role of the wettability of the dentin in bonding process could be one of the main factors because of the supstrats while conditioning can increase the surface free energy and thereby help this process. The advantage of the systems containing antibacterial agents, and in that it has not reduced the strength of binding are available. Bonding agent containing methacryloyloxydodecylpyridinium bromide (MDPB) is eradicating bacteria in tooth cavity and inhibit caries and in the same time they may have applicability to other adhesives, cements, sealants and composites. Share bond strength measuring indicate that incorporation of MDPB into dentin primer do not lose the the strength of the connection and could be beneficial for eliminating the residual bacteria in cavities.

**L 604** **CLINICAL INVESTIGATION OF MANDIBULAR-CRANIAL FUNDAMENTAL RELATIONSHIP**

GABRIELA IFTENI

*Romania*

**FIXED PROSTHODONTICS**

Based on a 30 year experience, we present in this paper an original method of clinical examination of the fundamental relations between the mandible and cranium. We analyse the posture relation, and also, the practical analysis for it, then, the centric relation, the static and dynamic occlusion. The presentation is followings the steps of the clinical exam - in concordance with the gnatological examination chart submitted.

**L 605** **THERAPY OF SALIVARY GLAND OBSTRUCTIVE SYNDROME BETWEEN CLASSIC AND MODERN**

ALEXANDRU BUCUR

*Romania*

**ORAL SURGERY - ORAL MAXILLOFACIAL SURGERY**

Over the past decade, minimally invasive surgery has gained popularity as a means of optimising early postoperative rehabilitation and increasing patient satisfaction and cosmesis following obstructive salivary Gland disorder. The minimally invasive treatment was developed to speed patient recovery and improve the early clinical results. The purpose of this work review was to appraise the entire evidence base to compare the clinical and imagistic outcomes of patients who have undergone a traditional surgery to interventional sialendoscopy and extracorporeal shockwave lithotripsy. The primary aim of the systematic review was to determine whether minimally invasive techniques in the diagnosis and management of obstructive sialadenitis are superior to a conventional surgery with reference to short- and long-term outcomes.

The development of new biomaterials for application in dentistry has become a need in the present. A significant numbers of biomaterials including metals, ceramic, polymers, composites and now some nanomaterials exist and are used for current and potential applications as dental implants, restoration and filling tooth roots. This review focuses on some newly developed potential dental materials as well as the novel technologies used for dental biomaterials processing. The surface properties of the dental applications have been recognized to play an important role in interactions with dental tissues, cellular response and osseointegration, and many scientists have developed and studies different generation of dental applications with modified surfaces. The surface modification and adhesion phenomena will be reviewed and discussed with particular reference to their relevance in biomaterials-tissue interactions phenomena. Advanced microscopically techniques such as scanning electron microscopy and atomic force microscopy are used now to determine the interfacial structure/ property/biofunctionality relationships of synthetic dental biomaterials with dental tissues. Different practical examination of surface modified dental biomaterials will be presented in order to show the advantage given by this microscopically techniques. Emerging nanobiomaterials and nanotechnologies and all of its outstanding features have the potential to add new dimension in dentistry. Nanoparticles of various compositions represent the most widespread use of nanoscale units in dentistry and some of them are currently being used in resin-based composite restorations. In addition, some concerns and limitations of the currently and novel dental biomaterials and further research on it will also be discussed. In conclusion, extensive studies on some promising dental biomaterials are essential in terms of biocompatibility, structure and properties in order to make them clinically viable. This review focuses on some potential and promising dental materials and ongoing research on them.

In the context of the dento-facial orthopaedics, the "six-year molar" influences many treatment decisions, as it plays a major role in the facial growth and the inter-arch equilibrium. The six-year molar is not influenced by the evolutionary changes that occur, as it is not, or in very rare occasions susceptible to agenesis. It not only changes the structure of the arches, but it also modifies the whole facial architecture, by altering the vertical dimension of occlusion while the TMJ is growing and developing. Judging by it's position in the upper arch, the first permanent molar transmits the occlusal forces through the zygomatic crest and it then disperses throughout the neuro-cranium, being named the "key ridge" and the "trajectory ridge" by different authors. Angle was among the first to have seen the potential influences the first permanent molar - especially the

upper first molar - could exert upon the dento-maxillary system, it being named by him the “key of occlusion”. It also plays a most important role in oral rehabilitation, as many cases at least in our country present with old first permanent molar extractions which produce big changes in the occlusion and possibly the TMJ, as the adjacent teeth migrate to close the gap. This text offers a detailed and case-oriented view upon the influences the first permanent molar has in the large context of the dento-maxillary system.

**L 608 HOW TO MAKE THE PROSTHETIC RECONSTRUCTION PREDICIBLE  
- AESTHETIC PROTOCOLS**

KOSOVKA OBRADOVIĆ DJURIČIĆ

*Serbia*

**FIXED PROSTHODONTICS**

As a result of a different level of dental health care, the adequate restorative treatments are needed. The basic aim of any therapy is to overhaul the disease, which finally leads to a general welfare. Special attention must be paid to the creation of the proper link between three important elements which define the dental treatment: the health, the function and the aesthetic. Additionally, contemporary prosthetic therapy becomes successful only if it has achieved the harmony between the functional and the aesthetic parameters, essential for dental health. The objective aesthetic evaluation of dentofacial composition is quite complex, particularly if we start with the hypothesis that the aesthetic is primary the art and passion not the science and skill. The fact is that a great number of pleasant art pieces are based on fundamental geometric and mathematic concepts present in nature. So, recognition of those concepts might be the first step into making the artwork of specific beauty. The imagination and creativity of the technics and the therapist are the key factors that change concepts and ensure that the outcome will be masterpiece in health and art sense. All mentioned is acceptable if it matches the patients' wishes, which are always a result of several factors: life experience, individual character and personality, habits, social status, etc. in combination with the persuasive mass media pictures of the ideal. The subjectivity of the patients and the insufficient reality in judging the aesthetic qualities, reference on the need of the objective methods in aesthetic analysis which are to respect mathematic rules, already present in nature. Therefore, this presentation of aesthetic protocols in prosthetic dentistry aims to start a vivid discussion of facial, dentofacial, dental and gingival composition.

**L 609 VASCULAR ENDOTHELIAL GROWTH FACTOR AND ORAL HOMEOSTASIS IN  
DIABETES MELLITUS TYPE 2 IMMEDIATE DENTURE WEARERS**

KATARINA RADOVIC

*Serbia*

**FIXED PROSTHODONTICS**

**Background:** VEGF, critical factor of angiogenesis is constitutively expressed in oral tissues. It is well documented that DM type 2 associated with basic complications and increased incidence of pathological oral conditions alters VEGF levels. Complete immediate dentures (CID)s as the best choice for DM candidates for teeth extractions because of providing the adequate nutrition in the postextraction period, additionally affect the oral conditions. This lecture presents

the relation between gingival and salivary VEGF levels and denture pressure, postextraction wound healing process under CIDs and appearance of denture stomatitis in diabetics and controls. **Methods and materials:** The study was conducted on DM type 2 and healthy, removable partial denture wearers, candidates for CIDs. Gingival VEGF was measured in tissue samples taken during teeth extraction. Salivary VEGF was measured before teeth extraction, on the third day of the postextraction period and one year of wearing relined CID. Wound healing quality was evaluated in period of three weeks. The presence of denture stomatitis was ranged according to the Newton classification. VEGF concentrations in human gingival tissue lysates and saliva were determined by enzyme-linked immunosorbent assay (ELISA). **Results:** Gingival VEGF levels in compressive tissue specimens were significantly lower comparing to VEGF levels measured in acompressive tissue specimens, in both groups of participants, with the higher decrease of VEGF levels in diabetics comparing to controls. Salivary VEGF concentrations in diabetics were significantly higher comparing to controls. Diabetics exhibited altered values of wound healing parameters. The incidence of denture stomatitis was higher in diabetics comparing to controls, with VEGF levels corresponding to the severity of inflammation. **Conclusion:** Determination of salivary and gingival VEGF levels highlight the process of wound healing, influence of pressure on denture-bearing mucosa and appearance of denture stomatitis. Modulation of VEGF could be therapeutic approach for regulation of DM type 2 oral complications.

**L 610** **RADIOGRAPHIC APPEARANCES OF SYSTEMIC DISEASES IN DENTOMAXILLOFACIAL AREA**  
KAAN ORHAN  
*Turkey*

#### ORAL DIAGNOSIS - ORAL RADIOLOGY

Treatment planning for maxillofacial pathologies involves gathering as much information as possible. Key tools to successful treatment planning are the appropriate radiographic techniques, allowing visualization of a site in all three dimensional aspect with less ionizing radiation as possible. Moreover, aware of the systemic diseases and their appearances of the maxillofacial complex is crucial for appropriate diagnose and treatment. In this presentation, based on the literature and own experience, an overview is given of the systemic diseases from radiological point of view. Moreover during the presentation the various radiological manifestations of systemic diseases will be evaluated to enhance the diagnose and treatment together with cases.

**L 611** **LONG-TERM CLINICAL RESULTS OF REGENERATIVE THERAPY IN PERI-IMPLANTITIS**  
CHEOLWOONG JUNG  
*Republic of South Korea*

#### PERIODONTOLOGY

As implant material and surgical technique have evolved, the long term prognosis of implant has been improved. However peri-implantitis were reported to be happen from 2.7% up to 47.1%, which is debliitating condition that might result in loss of function and esthetic without proper manage (Fransson et al). In 1993, The first euripean workshop on periodontology defined

the concept of Peri-implant disease, and in the sixth European workshop, consensus report on peri-implant disease was issued (J Clin Periodontol 2008; 35). Peri-implant disease could be classified into Peri-implant mucositis and peri-implantitis. Peri implant mucositis is a reversible inflammatory condition of soft tissue around functional implant, and showing no bone resorption. Peri-implantitis is irreversible inflammatory condition which shows bone resorption. The cause of these peri-implant disease are bacterial factor and occlusal factor (Isidor 1994 & Kozlovsky 2007). The aim of treating Peri-implantitis include removal of diseased tissue, stopping further progress of inflammation, recover functionality of implant and regeneration of tissues. Non surgical treatment include applying of antibiotics, curettage with plastic or carbon curette while surgical treatment include respective and regenerative surgery. Lang (2000) reported that if the periodontal pocket is deeper than 5mm and the bone loss is over 2mm, the surgical method should be chosen. The criterion of selecting regenerative/respective method is degree of bone loss. When clinician makes decision between regenerative and respective method, periodontal biotype should be also considered. Because different types of soft tissue reaction and bone resorption have been observed according to the biotype. Regenerative method should be performed after immaculate removal of disease tissue. Bone graft and membrane might be used independently. Numerous research has reported reosseointegration and bone regeneration after performing treatment mentioned above. Following clinical report on peri-implantitis is also based on those researches.

**L 612 RE:EVOLUTION IN DENTAL SURGERY. NEW BONE COMPACTING  
TECHNIQUES: FROM SUMMERS TO NEW TECHNOLOGIES**  
LUCA ARDUINI

*Italy*

**ORAL IMPLANTOLOGY**

The surgeon often has operate on the maxillary bone mass even in the presence of an insufficient thickness. In this case, to raise the floor of the sinus, it is possible to use the technique Summers, able to preserve the pre-existing bone mass and obtain increased by means of its compaction. However, the type of accelerative forces obtained with osteotome and mallet manual are moderated, affect the whole mass of the skull of the patient and can cause the displacement of the otoliths in the inner ear, causing the syndrome Benign Paroxysmal Vertigo. Furthermore, the difficulties related to the dexterity of the practice, limit the diffusion of this technique, in itself very versatile. The device presented here is able to overcome the drawbacks of manual practice transmitting a percussive pulse of high intensity, applied in a short time, so that the mass of the skull of the patient is not affected by the impact and preventing the BPV. Since the movement of the mechanical device, the progress of the osteotome is predictable and constant; so the surgeon can predict the results that will get and has the benefit of using a single hand getting more control and visibility. The surgical technique with this device makes the surgery more reliable, more rapid and less invasive for the patient. Also optional hand-pieces planned for this tool allow you to extend the practice to surgical extractions and removal of capsules.

**L 613 APPLICATION OF THE DIGITAL TECHNOLOGIES IN ORAL REHABILITATION.  
GUIDED SURGERY, PATIENT SPECIFIC IMPLANTS FOR BONE  
RECONSTRUCTION, GUIDED CORTICOTOMY**

CLAUDIO ALBI

*Italy*

**ORAL IMPLANTOLOGY**

Oral rehabilitation is aimed to restore functionality and to obtain satisfactory aesthetic results. Know how in implant systems coupled with a proven expertise in guided surgery are the drivers. Modus system for guided surgery, equipped with customized instruments, allows the dentist to foresee how to position the implant by simulating the procedure in a digital model and assessing anatomy and bone conditions. The treatment planning guarantees the certainty of the result, thus reducing time of intervention, increasing productivity and performance. The software is intuitive and focused on the surgical side providing a substantial support to the dentist. The system covers the digital workflow from CT/CB-CT acquisitions to surgical intervention (conventional and/or immediate loading). Our clinical experience sums up more than 2000 surgical cases in the last five years. Furthermore, a system for guided corticotomy allows, through guided cortical incisions among tooth roots, a quicker orthodontic procedure reducing costs and risks. Several technologies are used to manufacture different dental components with specific geometries and materials. We provide a clinically proven line of patient-specific dental implants for jaw bone reconstructions. We put the above knowledge and technologies at the service of the dentist to speed up, improve the quality and outcome of his clinical day - to- day practice.

**L 614 SHORT IMPLANT. 5 YEARS RETROSPECTIVE STUDY**

KADHIM AL HIMDANI

*France*

**ORAL IMPLANTOLOGY**

Alveolar ridge atrophy which occurs normally after tooth extraction “especially in the posterior region where the masticatory forces are very important” together with the presence of anatomical land marks as “Dental Nerve & the Maxillary Sinus” will considerably reduce the height of the Alveolar Ridge. Studies show that 38 - 50 % of patients have a residual ridge height which not exceeds 6 mm. That means with Implant average length of 11 mm “as used normally” near half of our patients can’t benefit from such type of treatments unless they undergo longer, more complicated, painful & costly procedures such as Ridge management, Bone Grafting Repositioning of Dental Nerve or sinus floor elevation. **Objectives:** The objective of this study is to show our clinical experience for the last 5 years with short implant for different critical clinical situations of bone height deficiency with very satisfying durable results from both esthetic and functional point of view without going through more sophisticated, long, traumatic, painful and costly procedures of ridge management by bone grafting or nerve repositioning. **Materials and methods:** Our clinical study for the last 5 years comprised more than 280 patients and 448 short implant of a different length & diameters. No any exclusion criteria in case selection were implicated. Manual surgical procedure by means of hand reamers was the technique of choice to gate benefit from bone elasticity and collecting autogenous bone to overcome certain bone deficiency. Prosthetic restoration with separated crowns was the role for the majority of cases.

**Conclusion:** Short implant could be considered as a real implant and not only as implant of substitution for long one in case of bone height deficiency (if we respect certain factures during surgical & prosthetic phase). The excellent durable functional & esthetic results make from it our implant of choice even when we have sufficient bone height. The survival and successful rates of short implants were comparable to those of long implants reported in several International Clinical Institutes.

**L 615** **BIO LOGIC IMPLANT ESTHETIC CONCEPT**

KADHIM AL HIMDANI

*France*

**ORAL IMPLANTOLOGY**

**Objectives:** The objective of this study is to show our clinical experience through which we obtained very satisfying durable esthetic results for different critical clinical situations of bone deficiency in esthetic zones without going through sophisticated, long, painful and costly procedures of ridge management like bone augmentation, ridge splitting, and distraction osteogenesis. **Materials and methods:** Our clinical study comprised 98 implants placed on 60 patients in sites with bone deficiency in the anterior zones of the maxilla and mandible. Selection of proper implant macro-geometric design and size, appropriate surgical approach and procedure, manual atraumatic bone appreciation osteotomy preparation (esthetic osteotomy preparation), proper implant orientation and subcrestal position, adapted prosthetic restoration specially with the use of integrated abutment crowns are factors we took into consideration to avoid pre-operative ridge management and bone augmentation procedures, with 3 years follow-up. Cases with sites without bone deficiency were excluded. Xenografts were used simultaneously in a few cases to give hard and soft tissue support, yet implants osseointegration was independent from the grafting material. **Results:** When following our proposed criteria of implant treatment planning in sites with bone deficiency, survival rate of 95.9% and a success rate of 97% were reported. **Conclusion:** Satisfying esthetic results in sites with bone deficiency can be obtained without pre-operative ridge management procedures. We highlight the significance of implant design, implant orientation and subcrestal position, surgical approach and procedure, and finally adequate prosthetic restoration and fixation; all these elements clinically proved their efficiency to overcome going through long, complicated, risky, painful, and costly procedures. Thus achieving the Minimal Invasive Implantology and shifting the conventional "Restoration-Driven Implant Placement" concept towards "Bone-Driven Implant Placement".

**L 616** **TREATMENT AND DIAGNOSIS OPTIMIZATION IN HERPETIC STOMATITIS**

DIANA UNCUTA

*Republic of Moldavia*

**ORAL PATHOLOGY**

The study assessed the accuracy and specificity of different methods of herpetic stomatitis diagnosis in out-patient dental clinics, argued the practicality of cytological and cytomorphological examination as the first test of express diagnosis in vesicular lesions of buccal mucous membrane, developed an applicable diagnostic protocol in recurrent and acute herpetic stomatitis at different

stages of clinical observation, elaborated different herpetic stomatitis treatment programs to achieve sustainable recovery and prevention of herpetic recurrence, determined clinical efficiency of BioR remedy that can be applied both singly and in antiviral preparation combination, including its preventive use.

**L 617** **IMPLICATIONS OF ORAL TRANSMISSION OF HELICOBACTER PYLORI INFECTION**

MARIN BURLEA, ANCUȚA IGNAT

*Romania*

**ORAL PATHOLOGY**

*Helicobacter pylori* (H. pylori) is one of the most frequently occurring and persistent bacterial infections worldwide. H. pylori bacteria are associated with peptic ulcer disease, mucosa associated lymphoid tissue lymphoma and gastric cancer. The prevalence of H. pylori in dental plaques has been reported by several studies, with findings ranging from 0% to 100%. Saliva may be a reservoir from where H. pylori is transmitted to the stomach. In symptomatic patients, it is strongly associated with stomach infection. This wide variation may be explained by the characteristics of the different sample populations, differing sampling procedures, and differing methodologies used to detect H. pylori in dental plaque. H. pylori can be detected in specimens including saliva, subgingival biofilm, dental plaque and gastric juice. The ability to detect H. pylori antibodies in saliva is lower than in blood-based serology.



# **ABSTRACTS**

## **BaSS AWARD Contest**

## ABSTRACTS – BaSS AWARD contest

### OP 192 LOWER THIRD MOLAR AND ITS INFLUENCE ON THE FRAGILITY OF MANDIBULAR ANGLE AND CONDYLE

SVETLANA ANTIC; IGOR SAVELJIC; DALIBOR NIKOLIC; ARSO VUKICEVIC;  
NENAD FILIPOVIC; ZORAN RAKOCEVIC; MARIJA DJURIC

*Serbia*

#### ORAL DIAGNOSIS-ORAL RADIOLOGY

**Background:** Clinical data suggested a higher angle and decreased condylar fragility in cases with lower third molar (M3). The impact of the M3 eruption status on the risk of angle and condylar fractures was the subject of various epidemiological studies, but the results were quite inconsistent. Since experiments on humans are limited, investigations concentrated on Finite Element Analysis- FEA, a computational method for predicting the biomechanical response of complex structures submitted to loading. The objective of the present study was to investigate the influence of the M3 eruption status on the fragility of mandibular angle and condyle, using FEA. **Material and method:** From CT scans of a human mandible with normally erupted M3, two additional virtual models were generated: a mandibular model with partially impacted M3 and model with totally impacted M3. A 2000N force, simulating a frontal blow, was directed perpendicular to the area of 1cm<sup>2</sup> in the symphyseal region of each model. **Results:** The results are based on the chromatic analysis of distributed effective and principal stresses, and calculation of their failure indices. The values of stress measured in the angle and condylar regions differed among the models. All the models showed higher stress in the angle regions than in condylar regions. The highest stress was measured in the angle region with totally impacted M3. Failure occurred only in cases with unerupted M3s, and was caused by tensile stress in the angle regions. **Conclusion:** The eruption status of the M3 influences the fragility of mandibular angle and condyle.

### OP 215 INFLUENCE OF DENTAL RESTORATIONS AND MASTICATION LOADINGS ON DENTIN FATIGUE BEHAVIOR: IMAGE-BASED MODELING APPROACH

KSENIJA ZELIC MIHAJLOVIC; ARSO VUKICEVIC; NENAD FILIPOVIC;  
MARIJA DJURIC; GORDANA JOVICIC

*Serbia*

#### ENDODONTOLOGY

**Background:** The analysis of tooth fatigue under mastication load is very important question in restored teeth and, particularly, teeth with root-canal-treatment. Furthermore, simulation of fatigue is very difficult to perform. We used FEA (Finite-Element-Analysis) and Fatigue theory for analysis of fatigue behavior of human dentin in intact and composite restored teeth with root-canal-treatment. **Material and methods:** Dentin fatigue behavior was analyzed in three virtual models: intact, composite-restored and endodontically-treated tooth. Low and high

volumetric change during the polymerization of composite was modeled by thermal expansion in a heat transfer analysis. Mastication forces were 100N, 150N and 200N. Assuming one million cycles, Fatigue Failure Index (FFI). Since the stresses caused by shrinkage and mastication are usually multiaxial with dominant tensile stresses in the dentin, the Equivalent Stress Theory (EST) was used as reliable for multiaxial fatigue analysis of materials with ductile behavior. **Results:** The analysis of the Goodman diagram gave maximal number of cycles for the given stress ratio. For the given conditions, fatigue-failure is not likely to happen neither in the intact tooth nor in treated teeth with low shrinkage stress. In the cases of high shrinkage stress, failure occurred with 150N and 200N loads. In the tooth with root canal treatment induced somewhat higher FFI than in the case of tooth with only composite restoration. **Conclusions:** Main factors that lead to dentin fatigue are levels of occlusal load and polymerization stress. However, root canal treatment has small influence on dentine fatigue.

**OP 305 ACCURACY OF FIT OF IMPLANT-SUPPORTED BARS FABRICATED ON DEFINITIVE CASTS MADE BY DIFFERENT DENTAL STONES**

IOANNIS KIOLEOGLOU; KONSTANTINOS MICHALAKIS; IOANNIS EMMANOUIL;  
ARGIRIOS PISIOTIS

*Greece*

**ORAL IMPLANTOLOGY**

**Background:** The purpose of this study was to evaluate the accuracy of fitting of an implant-supported screw-retained bar made on definitive casts produced by 4 dental stones. **Materials and methods:** The stones tested were QuickRock (Type III), FujiRock (Type IV), JadeStone (Type V) and Moldasynth (Type IV). Three external-hexagon implants were placed in a polyoxymethylene block. Impressions were made using custom trays and definitive models from the different dental stones were fabricated. Three castable cylinders with a machined non-engaging base were cast and connected with very small quantity of PMMA to a cast bar, which was used to verify the marginal discrepancies between the abutments and the prosthetic platforms of the implants. For that purpose, a special software and a camera mounted on an optical microscope were used. The gap was measured by taking 10 measurements on each abutment, after the Sheffield test was applied. Twelve definitive casts were fabricated for each gypsum product and 40 measurements were performed for each cast. **Results:** The analysis of variance revealed a statistically significant effect of the stone factor on the marginal discrepancy for all Sheffield test combinations. **Conclusions:** A significant correlation exists between marginal discrepancy and different dental gypsum products. The smallest marginal discrepancy was noted on bars fabricated on definitive casts made by Type III mounting stone, and the biggest marginal discrepancy on bars fabricated on definitive casts made by Type V dental stone. The marginal discrepancies presented on bars fabricated on definitive casts made by two types of Type IV dental stone were not significantly different.

**OP 367 PAIN REDUCTION WITH STABILIZATION SPLINT IN PATIENTS WITH TEMPOROMANDIBULAR DISORDERS- META-ANALYSIS**

JOVANA KUZMANOVIC PFICER; SLOBODAN DODIC; SANJA MATIC;

BILJANA MILICIC

*Serbia*

**REMOVABLE PROSTHODONTICS**

In recent years there has been an increasing need for finding appropriate therapy for the treatment of patients with temporomandibular disorders (TMDs). In our meta- analysis we wanted to evaluate efficacy of stabilization splint therapy. This study was aimed to compare the effects of occlusal splint therapy and control splint therapy in patients with TMDs. We searched electronic database MEDLINE of clinical trials for stabilization splint of TMDs during the years from 1987 to 2014. Selection criteria included clinical trials assessing the efficacy of stabilization splint therapy and control splint for pain. Pain relief outcome measures were used in meta-analysis. Variability among the studies in calculation of the aggregate value of the effect size is achieved by choosing a model with a random effect (for odds ratio (OR). A total of 516 patients were included in the 11 randomized trials. Obtained results show that successful outcome (pain reduction) occurs more often in the study intervention group then in the control group. The overall OR of 2.80 was statistically significant ( $p=0.0007$ ) with 95% confidence interval (CI) 1.55- 5.07;  $I^2=54\%$ ). Meta-analysis is an objective method based on precise mathematical and statistical rules that are performed according to the protocol. In addition, these results will help in planning and selection of therapeutic procedures as well as the standardization and improvement of the protocol for the treatment of temporomandibular disorders.

**OP 545 APICAL EXTRUSION DURING ENDODONTIC RETREATMENT USING THREE ROTARY NICKEL-TITANIUM RETREATMENT INSTRUMENTS AND HAND FILES**

SOTIRIA GKAMPESI; ZOUMPOULIA MYLONA; THEODORE LAMPRIANIDIS

*Greece*

**ENDODONTOLOGY**

**Background:** The aim of this study was to evaluate the amount of debris and irrigants extruded apically during endodontic retreatment using ProTaper (Dentsply Maillefer, Ballaigues, Switzerland), MTwo (VDW, Munich, Germany) and R-Endo (Micro-Mega, Besancon, France) nickel-titanium (NiTi) rotary retreatment instruments and hand files. **Materials and methods:** 44 freshly extracted human single-rooted teeth were prepared with Protaper rotary files and filled with gutta-percha and MTA Fillapex sealer. The teeth were then randomly assigned to 4 groups in which ProTaper, MTtwo, R-Endo retreatment files and Hedstrom hand files respectively were used. Debris extruded apically during the removal of canal filling material were collected into preweighed vials. The extruded irrigant was collected and measured using an insulin injector. In order to evaluate the debris extruded but were still on the root surface the roots were washed with 0,5 ml saline solution and the vials were stored for five days to allow the evaporation of saline. Then the second weighing was accomplished. The weight of the dry extruded debris was established by subtracting the

preretreatment and postretreatment weight of vials. The data obtained were analyzed using Man Whitney and Kruskal-Wallis tests. **Results:** There was no statistical difference between the groups concerning the extrusion either of gutta-percha or NaOCl ( $p < 0.05$ ). Concerning time, less time was needed for retreatment with MTwo system following of R-Endo and Protaper and Hand files successively. **Conclusion:** These findings show that both rotary NiTi retreatment files and hand files caused gutta-percha and irrigant extrusion with no significant difference.

**OP 584 PERIODONTOPATHIC BACTERIA IN ELDERLY EDENTULOUS PATIENTS - BEFORE AND AFTER COMPLETE DENTURE TREATMENT**

MARKO ANDJELKOVIC

*Serbia*

**REMOVABLE PROSTHODONTICS**

**Background:** The need for understanding the composition of oral microflora in edentulous patients has been recognized by some authors, but no studies have dealt with the changes that occur in periodontal pathogens` prevalence as a result of complete dentures. **Aim** of this study was to determine if wearing complete dentures can cause changes in prevalence of some of the most common periodontal pathogens including Porphyromonas gingivalis, Treponema denticola, Tannerella forsythia, Fusobacterium nucleatum, Prevotella intermedia and Aggregatibacter actinomycetemcomitans in elderly edentulous patients. **Materials and methods:** 30 edentulous elderly patients participated in the study. Complete dentures were fabricated for each patient and residual alveolar ridges were swabbed before denture insertion. After a period of 6 months swabs were taken again. Identification of Prevotella intermedia, Aggregatibacter actinomycetemcomitans, Porphyromonas gingivalis, Tannerella forsythia, Treponema denticola and Fusobacterium nucleatum was done by polymerase chain reaction (PCR) method and primers specific for each microorganism. **Results:** A noticeable increase in the presence of periodontal pathogens was observed after six months of denture wearing; targeted bacteria were identified in 17 pre-insertion samples compared to 28 post-insertion samples. However, only three microorganisms showed a statistically significant difference between the first and second swabbing - Aggregatibacter actinomycetemcomitans (6.7% vs. 40.0%,  $p = 0.006$ ), Prevotella intermedia (30.0% vs. 73.3%,  $p = 0.004$ ) and Tannerella forsythia (6.7% vs. 30.0%,  $p = 0.004$ ). There was also an increase in bacteria co-associations 6 months post insertion of complete dentures. **Conclusions:** The results of the present study suggested that wearing complete dentures caused a considerable increase of periodontopathic bacteria prevalence in elderly patients. Better understanding of oral microflora and impact that dental treatment has on bacterial colonies is important in modern dentistry.

# ABSTRACTS ORAL PRESENTATIONS

## ABSTRACTS – ORAL PRESENTATIONS

### OP 2 COMPLICATIONS OF IMPLANT SUPPORTED PROSTHESIS: CLINICAL APPROACH

MARIA MALLIARI; MARIA KELESI; ELEANA KONTONASAKI

*Greece*

#### ORAL IMPLANTOLOGY

**Introduction:** Implants today are the most popular option for the rehabilitation of various types of edentulism. Before decision-making, both dentists and patients should be aware of biological and technical complications concerning implants and suprastructures. The purpose of this presentation is to discuss clinical aspects related to the technical complications of implant supported prosthesis through the presentation of relevant clinical cases. **Methods and materials:** Cases of patients treated with implants at the Post Graduate Prosthodontics clinic of Aristotle University of Thessaloniki, that presented technical complications at follow-up examinations, were used for this presentation. The reasons of the observed complications and the further management of these cases are also presented. Additionally, the incidence of technical complications of implant supported prosthesis over an observation period of at least 5 years was assessed through literature review. **Results:** A large number of technical complications have been identified. The most common are abutment- or screw-loosening, loss of screw access hole restoration, loss of retention, fracture of the veneering material whereas fracture of components is more rarely reported. An overall complication rate can't be calculated because various factors can affect the type of technical complication, like the number of implants supporting the prosthesis, the type of suprastructure, parafunctional habits and opposing arch condition. **Conclusion:** Dentists should be aware of the existing risks of implant therapy and inform their patients about the potential complications and the additional costs involved in repairing them. Furthermore, patients should follow maintenance sessions for the long term survival of their prosthesis.

### OP 3 COMPARISON OF CANAL TRANSPORTATION, CENTERING RATIO BY CONE-BEAM CT AFTER PREPARATION WITH DIFFERENT FILE SYSTEMS

EMEL UZUNOGLU; SEVINC AKTEMUR TURKER

*Turkey*

#### ENDODONTOLOGY

**Background:** One Shape Apical 1 (OSA 1, Micro-Mega, Besançon, France) is a new file for preparing the apical aspect of the root canal. This study compared apical transportation and centering ratios in curved root canals when instrumenting with a Protaper Next (PTN, Dentsply Tulsa Dental Specialties, Tulsa, OK) up to size X3 with OSA 1. **Methods and materials:** Forty-eight mesial canals of mandibular molars were evenly allocated into 2 balanced groups (n = 24) with a 13-mm average canal length and 20° average curvature. Canals were accessed in a conventional manner and instrumentation was completed with PTN files up to X3 or with OSA 1 according to the

manufacturer's protocol. Apical transportation was assessed pre- and post-instrumentation using cone-beam computed tomographic scans of 1-, 2-, 3-, 4-, and 5-mm sections. A Friedman test was performed to assess the significance between file systems. **Results and Conclusion:** No significant difference was found between the PTN and OSA 1 groups with regard to apical transportation and centering ratio values ( $p > 0.05$ ). Transportation in the mesial direction was greater than the distal transportation for both file systems. All instruments were safe to use. The results suggest that no difference exists between the two systems when considering apical transportation and centering ratio in curved canals.

**OP 4 COMPARISON OF INTRAORAL RADIOGRAPHY AND CONE-BEAM COMPUTED TOMOGRAPHY FOR THE DETECTION OF PERIODONTAL DEFECTS**

MEHMET ERAY KOLSUZ; NILSUN BAGIS; KAAAN ORHAN; SEBNEM KURSUN

*Turkey*

**ORAL DIAGNOSIS-ORAL RADIOLOGY**

**Background:** This study aimed to compare the diagnostic accuracy of cone-beam computed tomography (CBCT) unit with digital intraoral radiography technique for detecting periodontal defects. **Methods:** The study material comprised 12 dry skulls with maxilla and mandible. Artificial defects (dehiscence, tunnel, fenestration) were created on anterior, premolar and molar teeth separately using burs. In total 14 dehiscences, 13 fenestrations, 8 tunnel and 16 without periodontal defect were used in the study. These were randomly created on dry skulls. Each teeth with and without defects were images at various vertical angles using each of the following modalities: a Planmeca Promax Cone Beam CT and a Digora photostimulable phosphor plates. Specificity and sensitivity for assessing periodontal defects by each radiographic technique were calculated. Chi-square statistics were used to evaluate differences between modalities. Kappa statistics assessed the agreement between observers. Results were considered significant at  $P < 0.05$ . **Results:** The kappa values for inter-observer agreement between observers ranged between 0.78 and 0.96 for the CBCT, and 0.43 and 0.72 of intraoral images. The Kappa values for detecting defects on anterior teeth was the least, following premolar and molar teeth both CBCT and intraoral imaging. **Conclusions:** CBCT has the highest sensitivity and diagnostic accuracy for detecting various periodontal defects among the radiographic modalities examined. CBCT should be considered as the most reliable imaging modality of choice for the diagnosis of periodontal defects.

**OP 14 CURRENT TRENDS IN THE TREATMENT OF TEETH WITH ABRASION**

MLADEN BEHARA; DUSICA BOZOVIC BEHARA; SLADJANA SICOVIC;  
LENA JOVANOVIC; NATASHA RANDJELOVIC

*Serbia*

**FIXED PROSTHODONTICS**

Progressive wear- abrasion of the tooth is in honor of the appearance of patients who visit the dental office. The forms of attrition of teeth can be different and individual teeth surgery, dental group or dental arches as a whole. The abrasion of the teeth is primarily functional and aesthetic problems of our patients and their reasons for coming to the clinic increased tooth sensitivity abradiranih to chemical and thermal stimuli or poor aesthetics. The clinical picture shows a huge



variety of abrasion. It has no age limits appear abrasion of teeth, often to young people. New dental materials now provide new therapeutic options in the treatment of damaged teeth abrasion. Before the dentist to ask many questions when confronted with a patient and his teeth, abraded, the question of whether our patient, we can easily solve the fast? How to enable him to live without pain? What could be the reasons for the emergence of tooth abrasion? What are the changes in dental tissues during tooth abrasion? As attrition of teeth affects the distribution of loads on the structure of the temporomandibular joint and stomatognathic system as a whole? What can be therapeutic solutions abradiranih teeth? Is it possible to prevent abrasion of the tooth and prevent? Is tooth abrasion therapy is just the domain Prosthodontist? Do you still have teeth, abraded, sanded? The lecture is designed to respond to some of the questions.

**OP 15 RISK FACTORS AND ORAL COMPLICATIONS IN DENTURE WEARERS WITH TYPE 2 DIABETES**

KATARINA RADOVIC; ALEKSANDRA CAIROVIC; DRAGICA STOJIC; JELENA ROGANOVIC; DRAGOSLAV STAMENKOVIC

*Serbia*

**REMOVABLE PROSTHODONTICS**

**Background:** Diabetes mellitus type 2 (DM type 2) is linked at the clinical level with various oral complications and at the cellular level with vascular endothelial growth factor (VEGF) alterations. Therefore, we investigated risk factors associated with the mucosal changes in complete denture wearers with and without DM type 2, as well as, relation between levels of tissue VEGF and presence of denture stomatitis in both groups of patients. **Material and methods:** Healthy (42) and DM type 2 (36) candidates for complete dentures were included in the study. After three years of wearing complete dentures, patients were checked for denture stomatitis and risk factors. Tissue VEGF levels were measured using ELISA. **Results:** The incidence of denture stomatitis was 61% in DM type 2 and 38% in control subjects. Low denture stability and DM type 2, were risk factors for denture stomatitis. Tissue VEGF concentrations at the beginning of the study were  $37.64 \pm 9.7$  pg/ml in DM type 2 and  $34.22 \pm 2.6$  pg/ml in control subjects. In patients with denture stomatitis VEGF levels were  $121.18 \pm 21.4$  pg/ml in diabetic, and  $56.58 \pm 10.0$  pg/ml in controls, respectively. **Conclusion:** Perceived denture stability and DM type 2 are independent risk factors for occurrence of denture stomatitis. Altered tissue VEGF levels associated with presence denture stomatitis could be expected in DM type 2 complete denture wearers.

**OP 22 LASER PHOTOBIO-MODULATION AS AN ADJUNCT TO NONSURGICAL TREATMENT OF AGGRESSIVE PERIODONTITIS: A PILOT STUDY**

HASAN GÜNDOĞAR; SÜLEYMAN ZİYA ŞENYURT; KEMAL ÜSTÜN; KAMİLE ERCİYAS

*Turkey*

**PERIODONTOLOGY**

**Aim:** Aggressive Periodontitis (AgP) has a genetic background and it is an inflammatory and infectious disease. The treatment of aggressive periodontitis has contained scaling and root planning with or without combined antibiotics. The aim of this split-mouth, single-blind,

randomized controlled trial was to evaluate the efficiency of low level laser therapy (LLLT) on treatment of aggressive periodontitis. **Material and Methods:** Six systemically healthy patients with AgP were assessed for Gingival Index (GI), bleeding on probing (BOP), periodontal pocket depth (PPD) and clinical attachment level (CAL) at baseline and first, third and sixth months after the treatment. Gingival crevicular fluid samples (GCF) were collected at baseline and 1 week and 1 month after treatment. The test site was randomly selected with coin test. After the periodontal treatment, low laser therapy (980 nm diode laser, 0.1w, 15 sec. with energy density of 7,64 J/cm) was applied four times (0, 1, 3, 7 days post-treatment). The levels of biomarkers in GCF were evaluated using a multiplex bead immunoassay (MAGPIX) with Bio-Plex Pro Human Cytokine 27-Plex Immunoassay. **Results:** LLLT group showed that statistically lower PPD levels (at 3th and 6th months) and CAL levels (3th months) ( $P < 0.005$ ). GCF biomarkers and other clinical markers showed no statistically differences between groups. **Conclusion:** Within the limits, this study showed that LLLT as an adjunct to treatment of AgP was effective in the reduction of clinical parameters.

**OP 26 INFLUENCE OF PROSTHETIC CROWNS IN DOSE OF THE GINGIVAL FLUID AT SULCUS OF ABUTMENT TEETH**

ILMA ROBO; RUZHDI QAFMOLLA

*Albania*

**PERIODONTOLOGY**

**Purpose:** Evaluation of the impact that has a foreign body in the gingival sulcus, expressed in scale to cause significant gingival infection. **Materials and methods:** In a sample of ten clinical cases with fixed prosthetic in oral cavity are measured the levels of gingival fluid to bridge anchoring teeth and to the same opposition respectively teeth in the mandible and in maxilla. Measurement of gingival fluid is done with the blue colored absorbent paper, for 60 seconds to keep the gingival sulcus. With the technique of centrifugation are found the respective values of gingival fluid. **Result:** Distinguishable difference in one unit of the dose is measured during the assessment of gingival fluid to anchor teeth to bridge that is higher than at natural teeth. **Conclusions:** Signs of onset of primary infection is increased gingival fluid. The presence of a foreign body causing an increase of gingival fluid in sulcus, as a stage of physical harassment that causes it, and subsequently as the initial stage of possible infection of the gingiva.

**OP 27 EVALUATION OF DIFFERENT TYPES OF CEMENT FOR IMPLANT-SUPPORTED CROWNS**

DEJAN STAMENKOVIC; ALEKSANDAR TODOROVIC

*Serbia*

**DENTAL BIOMATERIALS AND DEVICES**

**Background:** For cement-retained implant prostheses, the retention forces of luting cements are one of the most important criterion when is about to selected luting cement. This study was aimed to evaluate different types of cement in implant-supported crowns to fit on solid titanium abutment. **Material and methods:** Prefabricated burnout caps were placed on the titanium abutments and wax drops added to the occlusal surface. Samples were casted with base metal alloy,

and sprues are adjusted for holding in grips of the testing machine. Crowns are cemented to the abutments, which were previously screwed to the implant replica. 5 cements were tested in this study. Each type of cement was a separate group. Measurements of each group were conducted on 7 samples. After cementation, samples were subjected to a take out test using testing machine, at a crosshead speed of 0,5 mm/min. Loads required to remove the crowns were recorded and mean values for each group determined. **Results:** Composite and carboxylate cements showed approximately the same value of retention force. Zn-phosphate cement had a slightly lower retention force. All cements for permanent bonding showed almost identical nature of the separation. Temporary and glass-ionomer cements showed significantly lower retention force and the different nature of the charge separation of replicas of the implants. **Conclusion:** Measurement of retention force showed that retention depends on the type of cement. Because of the great retention force, but also because of the good properties, composite cements should be given priority in cementing restorations on implants.

**OP 32 THE EFFECTS OF LED PHOTO-ACTIVATED DISINFECTION ON PERIODONTAL CLINICAL PARAMETERS IN PATIENTS WITH CHRONIC PERIODONTITIS**

MARIA ALEXANDRA MÂRȚU; IRINA URSĂRESCU; SORINA SOLOMON;  
LILIANA FOIA  
*Romania*

**PERIODONTOLOGY**

**Background:** The purpose of the study was to assess the effects of LED-PAD and tolonium chloride on periodontal clinical parameters in chronic periodontitis. **Materials and methods:** We recruited 66 patients with chronic periodontitis, divided in two groups (control group and study group which, besides the conventional therapy measures, also received PAD therapy). The periodontal clinical parameters were registered at baseline and after 3 months: The post-therapy evaluation revealed significantly improved results for the periodontal clinical parameters in the study group, when compared to the control group. Our results support the literature studies conducted on chronic periodontitis patients but without any systemic diseases. **Conclusions:** The PAD disinfection determined a significant improvement for the periodontal clinical parameters in patients with periodontal disease.

**OP 35 PERIODONTAL DISEASE AT PATIENTS WITH CHRONIC KIDNEY DISEASE AND SECONDARY HEMODIALYSIS THERAPY**

SILVIA MÂRȚU; CERASELLA SINCAR; MARIA-ALEXANDRA MÂRȚU; SORINA SOLOMON  
*Romania*

**PERIODONTOLOGY**

**Background:** Patients with chronic kidney disease evidenced various periodontal tissue alterations, due to renal dysfunction and their association with infection plaque, the diagnosis and therapeutic management are frequently. The **purpose** of this study was to examine the effect of secondary HPT on the periodontium of patients on hemodialysis. **Material and method:** The experimental group consisted of 35 patients with chronic renal failure treated by hemodialysis (A

group). A control group (B group) was formed from 35 healthy subjects. Blood samples were taken from the group, and the active intact parathyroid hormone was assayed. Also a clinical and X-ray periodontal examination was performed. **Results:** Demographically, both groups were similar with no statistical difference. PI was also similar and GI was slightly greater in the A group. PD in the A group was identical to that of the B group. Likewise, CAL in the A group did not differ from CAL in the B group. **Conclusion:** From this study it can be concluded that secondary HPT does not hyperparathyroidism have an appreciable effect on periodontal indices and radiographic bone height.

**OP 43 THE ASSESSMENT OF ORAL AND PERIODONTAL PARAMETERS IN PATIENTS WITH END-STAGE CHRONIC KIDNEY DISEASE**

SORINA SOLOMON; IRINA URSĂRESCU; IONUȚ NISTOR; SILVIA MĂRȚU;  
GABRIEL VEISA

*Romania*

**PERIODONTOLOGY**

**Background:** The purpose of the study was to assess the oral cavity status in patients with terminal chronic kidney disease and hemodialysis. **Materials and methods:** The study was conducted on 69 patients with end-stage CKD, who were following hemodialysis regime. The data regarding the age, gender, environment, associated diseases were obtained from the clinical charts. The patients were submitted to a clinical examination which also included the periodontal probing and the gingival bleeding assessment. The type of edentulous ridge was recorded. Each patient filled a questionnaire which offered data regarding the oral hygiene habits, diet, vicious habits and the presence/absence of xerostomia. **Results:** The main cause for end-stage CKD was renal, followed by diabetes mellitus and arterial hypertension. The main associated diseases to CKD were clearly secondary arterial hypertension and secondary anemia; other associated diseases were represented by cardiac diseases, hepatitis, gastro-intestinal diseases, secondary hyperparathyroidism, cirrhosis, hypersplenism, epilepsy and neoplastic diseases. 62.31% of the patients accused frequent xerostomia. When recording the edentulous type, we observed a high percentage of terminal tooth loss. **Conclusions:** There is a close link between the systemic changes in the CKD patient and the oral manifestations. Even two of the main causes of CKD (hypertension and diabetes mellitus) exert important changes on the tissues in the oral cavity, leading to significant tooth loss and masticatory impairment, thus, to a poor quality of life.

**OP 51 PERIAPICAL LESIONS IN RELATION TO THE ROOT CANAL TREATMENT**

ERLIND PEPLA; GUIDO MIGLIAU; MASSIMO GALLI

*Italy*

**ENDODONTOLOGY**

**Introduction:** This study is an overview of the state art of endodontics in Italy. In particular, it analyzes the relationship between the quality of the apical seal and the presence of periapical lesion and the frequency in endodontically treated or not elements. **Materials and methods:** The study was done by analyzing a sample of 312 subjects, 191 women and 121 men, between 11 and 79 years. We excluded all subjects in primary dentition and mixed, and all subjects

with less than 9 dental elements. The sample consisted of patients of a private clinic in Rome, where it was performed digital OPT and which are collected in addition to the personal data also the reason for the visit. Periapical status was assessed using a periapical index (PAI), with a score.

**OP 61 THE SHORT-TERM CLINICAL EVALUATION OF BULK-FILL COMPOSITE RESINS IN CLASS II RESTORATIONS: 6 MONTHS FOLLOW-UP**

YUSUF BAYRAKTAR; MEHMET MUSTAFA HAMIDI; ERTUĞRUL ERCAN;  
ABDÜLKADIR ŞENGÜN

*Turkey*

**RESTORATIVE AND ADHESIVE DENTISTRY**

**Background:** The aim of this study was to evaluate the short-term clinical performance of three different bulk-fill composite resins in Class II cavities. A conventional posterior hybrid composite resin was used as control group. **Methods and materials:** With the studying conditions, 50 patients were selected by one clinical investigator. After the approval of consent form, four Class II preparations performed for each patient. Totally 200 preparations were performed. The preparations restored with four different composites. The first group preparations were restored with a conventional hybrid composite produced for posterior restorations by using incremental technique. The second group was restored with using a low-viscosity bulk-fill composite as a liner and a conventional posterior hybrid resin as a capping layer. The third and fourth groups were restored with two posterior bulk-fill composites by using bulk technique. Clinical evaluation was performed by using modified USPHS criteria. The baseline scores were noted after one week examination. Then the patients were recalled for evaluation once every three months. The 6 months data were collected and analyzed with SPSS 16.00 program. **Results and Conclusion:** At the three months and six months recalls, the recall rates were 98% and 92% respectively. (n1= 49 and n2= 46) Clinically acceptable changes were found in a few restorations. Only one failure was found in Group 2 after 6 months recall due to the post-op sensitivity. The clinical performances were found similar for all groups and no significant differences were found from baseline to six months evaluation.

**OP 66 CLINICAL OSTEOMYELITIS, REPORT OF A VERY RARE CASE**

SOTIRIA GKAMPESI; FOIVOS DALAMPIRAS; M DALAMPIRA; ELENI TOUFA

*Greece*

**ORAL SURGERY AND ORAL MAXILLOFACIAL SURGERY**

**Introduction:** Osteomyelitis of the jaws is an inflammation of the medullary cavity and haversian systems, which extends to involve the periosteum of the affected area. The infection becomes established in the calcified portion of bone, when pus in the medullary cavity or beneath the periosteum obstructs the blood supply. Following ischemia, the infected bone becomes necrotic. The disease is primarily caused by odontogenic bacteria, with trauma being the second leading cause. **Methods and materials:** The present report documents a rare case of maxillary osteomyelitis in a 30-year-old male who was referred to our department of Oral and Maxillofacial Surgery after a

five- day treatment with IV administration of antibiotics with a lesion on the left posterior maxilla. The past history revealed a root canal therapy of 26 some years prior to presentation. Intraoral examination revealed a chronic hard brown ulcer appearing as exposed bony sequestrum, in the maxillary left quadrant, accompanied by swelling and pain. The hard part of the lesion was very fragile in our manipulations. The odor of the lesion showed the necrotic procedure. Effusion was not found in the area. Treatment included antibiotic therapy followed by total enucleation of the necrotic bone and extraction of the involved tooth (26). **Results:** Osteomyelitis of the jaws appears significant morbidity unless it is recognized promptly and treated directly. Early recognition of osteomyelitis and appropriate antibiotic treatment can prevent extensive loss of bone and teeth.

**OP 67 PROSTHETIC TREATMENT OF ANTERIOR TEETH WITH LITHIUM DISILICATE CERAMICS: 3 CLINICAL CASES**

ELENI-SOTIRIA PALLA; ELEANA KONTONASAKI

*Greece*

**FIXED PROSTHODONTICS**

**Background:** Changes in restorative treatment therapeutic approaches and the introduction of new and improved materials and techniques, led to an increased demand for aesthetic dentistry. In the field of prosthetic dentistry, a new glass ceramic material called lithium disilicate (LS2), has been proved particularly efficient for esthetic rehabilitation. However, only short and medium-term data are available concerning its clinical survival. The aim of this work was to present three clinical cases with increased aesthetic demands restored with lithium disilicate and to present an update on the clinical survival of lithium disilicate restorations. **Methods and materials:** Three clinical cases with increased aesthetic demands and complexity treated in the clinic of Fixed Prosthesis and Implant Prosthodontics of the Aristotle University of Thessaloniki are presented. A systematic search in the English literature was undertaken in PUBMED using specific keywords: (survival OR success) AND lithium disilicate. **Results:** The clinical cases presented support the excellent aesthetic properties of lithium disilicate ceramics. Lithium disilicate is recommended when high translucency and shade is required. The results of the literature review showed different survival patterns concerning single crowns and fixed partial dentures. Long-term survival is still controversial especially concerning fixed dental prostheses. **Conclusion:** Lithium-disilicate glass ceramic is an excellent material in cases with increased aesthetic demands. Although the short-term survival of single crowns is high, caution is recommended for fixed dental prostheses, as currently the clinical evidence for long-term survival seems poor.

**OP 71 CBCT AIDED RETREATMENT OF A PREMOLAR WITH TWO ROOTS AND TWO CANALS**

FUNDA YILMAZ; KIVANÇ KANBUROĞLU; ELIF NAZ YETA

*Turkey*

**ENDODONTOLOGY**

Mandibular first premolars usually have only one root along with a root canal. However, they may demonstrate unusual morphological characteristics. A clear understanding of the root canal anatomy of the human dentition is a pre-requisite for conventional endodontic procedures.

The anatomical complexities of root canal anatomy have been highlighted in the literature and the need for the clinician to understand probable aberrations was emphasized. In addition, a thorough knowledge of the radiological features is very important for a successful diagnosis and treatment. We report CBCT aided diagnosis and root canal therapy of a root canal filled mandibular first premolar tooth with periapical pathology in relation to an undiagnosed and unfilled root canal. A 35 year old male patient was referred to our clinic with a recent history of an acute pain on his mandibular right first premolar tooth which was treated by root canal therapy two years before. Periapical radiographic findings showed an ideal root canal treatment along with a periapical radiolucency. A detailed radiological assessment with CBCT images showed the presence of an extra non-treated root canal in relation periapical pathology. At this initial visit root canals were prepared and filled with calcium hydroxide. A week later, root canal was finally obturated with gutta-percha and AH Plus. The coronal portion of the tooth was restored with composite resin. Keeping in mind concerns over dose, CBCT may be used to assess root canal morphology and diagnose periapical pathology in cases where two dimensional techniques fail to provide adequate information.

**OP 77**    **EFFECTS OF POSITIONING UPON THE VERTICAL DIMENSION ON CONE-BEAM COMPUTED TOMOGRAPHY**

DERYA ICOZ

*Turkey*

**ORAL DIAGNOSIS-ORAL RADIOLOGY**

**Background:** The success of implant therapy mostly depends on radiographic assessment. A review of the literature for cone-beam computed tomography indicated that excellent accuracy in measurements. The aim of this study was to investigate the effects of positioning on vertical dimension according to tooth location. **Materials and methods:** 28 implant shaped stainless steel pins were placed on a dry skull for every tooth location. CBCT images of the dry mandible were taken in 24 different positions. -5, -10, 0, +5 and +10 angles were used for both vertical and horizontal planes. But when the angle was +10 both in vertical and horizontal planes, it was not possible to take an image. Finally, vertical dimension of the pins were measured twice by the same observer and statistically analyzed. **Results:** There was high compatibility between first and second measurements of the observer and for statistical analyze second measurements were tested by means of ANOVA. For both vertical and horizontal angle changes the measurements of the mandibular molar region were not statistically significant ( $p>0,05$ ). For vertical angle changes the measurements of the anterior maxilla, anterior mandibula and mandibular premolar regions were statistically significant ( $p<0,05$ ) and for horizontal angle changes maxillar premolar and maxillar molar regions were statistically significant ( $p<0,05$ ). **Conclusion:** For vertical and horizontal angle changes between -10 to +10 CBCT can be used safely on the mandibular molar region. Changing the position reduced the accuracy of vertical dimensions on CBCT.

**OP 80 PERIPHERAL GIANT CELL GRANULOMA ASSOCIATED WITH DENTAL IMPLANTS. A CLINICAL CASE AND LITERATURE REVIEW.**

GEORGIA BARKA; ELENI EIRINAKI; SOTIRIA GKAMPESI; THEODOROS LILLIS

*Greece*

**ORAL IMPLANTOLOGY**

Background peripheral giant cell granuloma is the most common giant cell lesion of the jaws. Although rare, there are reports showing an association with dental implants. This case report aims to enrich the pool of the existing data and help to further determine the etiology, pathogenesis and surgical management of these lesions developing around dental implants. **Methods and materials:** A male patient presented at our private dental practice with a chief complaint of swelling reoccurrence around a dental implant in the mandibular right later incisor position. The patient was treated with two implants in lower lateral incisor positions to support a four unit cement retained fixed prosthesis. The same lesion arose one year after implant placement but was inadequately treated which led six months later to reoccurrence. The associated with the lesion implant presented good clinical stability but radiological findings showed severe marginal bone loss. The treatment plan this time comprised of both surgical removal of the complete lesion and explantation. Histopathology confirmed once again the diagnosis of peripheral giant cell granuloma. **Results:** The case was treated uneventfully. Complete healing of the wound was achieved and with no evidence of relapse 12 months after surgery. **Conclusion:** Peripheral giant cell granuloma is an aggressive reactive lesion associated with dental implant therapy jeopardizing its success. Therefore, in all cases of peri-implant tissue reaction, early and definitive diagnosis with biopsy and histological examination is mandatory to avoid irreversible complications of such lesions including severe bone loss and sacrifice of the involved implant.

**OP 84 COMPARISON OF MICROHARDNESS AND ROUGHNESS OF GLASS CARBOMER AND SELF ADHERING MATERIALS**

H. ESRA ÜLKER; NURAY GÜNAYDIN; ALIHSAN ERKAN;  
FİRDEVS KAHVECIOGLU; MUSTAFA ÜLKER

*Turkey*

**RESTORATIVE AND ADHESIVE DENTISTRY**

**Aim:** Hardness and roughness values are mechanical properties of materials which used in dentistry this indicators effect durability, polishability. The aim of this study was to compare the Vickers microhardness and roughness values of Glass Carbomer, resin modified glass ionomer and self-adhering flowable composite materials. **Materials and methods:** Fifteen Samples were prepared for tests in standard teflon discs (2X5 mm) per group (n=15). Group 1 was filled with resin modified glass ionomer (Fuji II LC Capsule, Japan), Group 2 was filled with Glass Carbomer (Glass Fill, Germany) and Group 3 was filled with self adhesive resin composite (Vertise Flow, USA). Samples stored in 370C distilled water for 24 hours. After polishing Vickers Microhardness was determined (Matsuzava, Japan). Test specimens of each material were submitted to the Vickers Microhardness test for 10 seconds at a load of 100 gf. Same samples were repolished and surface roughness readouts were taken. And data's were statistically analysed with one-way ANOVA followed



Tukey's HSD test. **Results:** The results of the Vickers microhardness test showed that Glass Carbomer had the highest value and Vertise Flow had the lowest values. Statistically three groups were different from each other ( $p < 0.05$ ). The Glass Carbomer material demonstrated more surface roughness than other groups ( $p < 0.05$ ). **Conclusion:** The hardness and surface roughness of Glass Carbomer material is higher than resin modified glass ionomer cement and self adhering flowable composite resin.

**OP 87 PULPAL TEMPERATURE CHANGES OF THE GLASS CARBOMER AND RESIN MODIFIED GLASS IONOMER CEMENT**

FİRDEVŞ KAHVECİOĞLU; GUL TOSUN; ESRA ULKER

*Turkey*

**RESTORATIVE AND ADHESIVE DENTISTRY**

**Aim:** The purpose of this study was to investigate the pulpal temperature increase induced during the setting reaction of glass carbomer cement and polymerization of resin modified glass ionomer cement in pulpal chamber of primary and permanent molar tooth. **Methods:** A non-retentive class I cavity was prepared in an extracted primary and permanent molar tooth, leaving a dentin layer in 1 mm thickness between pulp chamber and pulpal cavity wall. Glass carbomer cement was placed to the cavity and setted with carboLED curing unit. Resin modified glass ionomer cement was placed to the cavity and polymerized with LED curing unit. Temperature rise during setting reaction were measured with a J-type thermocouple wire that was connected to a data logger. Data were analyzed with two way ANOVA and Mann Whitney U tests. **Results:** In permanent teeth Fuji II and Glass Carbomer caused mean 1.36, 3.93 °C increase in temperature, respectively ( $p < 0.05$ ). In primary teeth Fuji II and Glass Carbomer caused mean 4.65, 4.43 °C increase in temperature, respectively ( $p > 0.05$ ). Primary tooth showed significantly higher temperature increases in pulp chamber than the permanent tooth ( $p < 0.05$ ). **Conclusion:** Despite the significant differences among the groups, the temperature increases recorded for all groups were below the critical value of 5.5 °C that can cause irreversible harmful changes in pulp tissue. It can be concluded that, with regard to temperature increase, both two materials evaluated in this study can be used safely.

**OP 95 THE INFLUENCE OF THE TiO<sub>2</sub> AND THE GRAPHENE ON THE FIBROBLAST CELL LINE**

CRISTINA MARIA BORTUN; MEDA LAVINIA NEGRUTIU; COSMIN SINESCU;  
LAURA CRISTINA RUSU

*Romania*

**DENTAL BIOMATERIALS AND DEVICES**

**Background:** This study investigated the influence of the TiO<sub>2</sub> and graphene on the human fibroblasts cellular line (HDFa). **Methods and materials:** The materials used in this study are TiO<sub>2</sub> and the graphene for relining removable partial dentures. The viability was investigated by Annexin-V/PI, flowcitometry test for the cellular apoptosis. The proliferation rate was studied with the xCELLigenceRTCA DP system, a dual system for cellular analysis without marks. The substrate adherence capacity with ICAM and VCAM molecules was made by Flowchamber method. **Results:**

The apoptosis rate was bigger in case of TiO<sub>2</sub> than in the case of graphene. The proliferation rate and the adherence capacity was bigger in the case of the graphene. The results of the Flowcitometry proved that the line cells in contact with the graphene works as mezenchimal stem cells because of the markers, the chemo tactics adherence capacity with VCAM and ICAM cells. **Conclusion:** The viability, proliferation and adherence capacity of the fibroblast cell line in contact with the graphene was better than in the contact with TiO<sub>2</sub>. That's the reason to recommend the graphene as a good material for relining prostheses. Key words: TiO<sub>2</sub>/graphene, fibroblasts cellular line, relining prostheses.

**OP 115 LICHEN PLANUS: A CASE REPORT**

BUKET OZKAYA; SEDA SEVINC OZBERK; HASAN GUNDOGAR; KAMILE ERCIYAS  
*Turkey*

**PERIODONTOLOGY**

**Introduction:** Lichen planus (LP) is frequent dermatoses that observed between mostly 40-70 years of age, effected women more than men, skin and mucous membranes were affected. Although LP's etiology is unclear, most acceptable pathological mechanism theory is autoimmune reaction against antigens in the host epithelium and T lymphocytes are the major determinant cell thought to be involved in the formation of lichen planus. **Case summary:** A 33-year-old female patient who had reticular lesion at inner oral mucosa referred our clinic from department of dermatology. Major complaints were burning feel and pain at the area of the lesion when she eats something sour or hot. Incisional biopsy had done to the region with some healthy tissue and specimen had put in a formaldehyde solution and sent to the pathology department with pre-diagnosis of oral lichen planus. Histopathological examination was showed that focal keratotic area, acanthotic granular layer of epithelium, and squamous epithelium showing subepidermal separation. There was lymphocytic infiltrates in the style of the band under the epithelium. When all the information about the patient put together, patient referred to dermatology department with the diagnosis of oral lichen planus. Dermatology department prescribed a topical corticosteroid to the patient. **Conclusion:** Oral Lichen Planus effects %0.5-2 of the population and is one of the more common oral mucosal diseases. Biopsy is required for definitive diagnosis. Dentists should be careful because of the first signs of this type of dermatoses is often seen in the oral mucosa.

**OP 118 LASERS IN DENTISTRY: CASE SERIES**

CAGLAR KORCUK; KEMAL KORUCUOGLU; HASAN GUNDOGAR;  
KAMILE ERCIYAS  
*Turkey*

**LASERS**

**Introduction:** Due to the new developments in dental technology, lasers have been more popular in recent years. There has been considerable advancement in technology since lasers were introduced for the treatment of oral diseases. As a result, numerous laser systems are currently available for oral use. The application of lasers in soft tissue surgery, hard tissues, periodontics and endodontics has been evaluated from a safety point of view, for gingival pigmentation, root canal disinfection, surgical and non-surgical periodontal treatment, surface modification of enamel, cavity

preparation, in oral surgery excision; for example frenectomy, epulis fissuratum and fibroma. **Case Summary:** In this case series we'll present six different cases with laser assisted treated every dentist can see in his/her daily practice and thinks different about the treatment protocol. A hopeless perio-endo lesion, two depigmentation cases with different wavelengths (2940 nm Er:YAG laser and 980 nm diode laser), two frenectomy cases with 810nm diode laser, a surface modification with Er:YAG laser, a laser assisted periodontal therapy with 810 nm diode laser for an aggressive periodontitis patient, a removal of caries for deciduous teeth. **Conclusion:** Laser application in surgery provides relatively bloodless surgical and post surgical courses with minimal swelling and scarring. In endodontics lasers can reach even the lateral root canals because of the transmission. In this case series, we would like to describe the positive characteristics of lasers in different wavelengths for different indications, which indicate its potential as a new treatment modality in dentistry.

**OP 120 GINGIVECTOMY: ER:YAG LASER CASE REPORT, ONE YEAR FOLLOW-UP**

SEDA SEVINC OZBERK; CAGLAR KORCUK; HASAN GUNDOGAR;

KAMILE ERCIYAS

*Turkey*

**LASERS**

**Introduction:** Er:YAG laser is an infrared light and with a wavelength of 2940 nm. It is strongly absorbed by water. Its high absorption ability in water and hydroxyapatite have shown the effectiveness of this laser for both hard and soft tissue surgery. Chronic inflammatory gingival overgrowths are quite common in daily practice. This kind of problems can be solved with lasers easily. Er:YAG lasers are one of the safest methods for soft tissue applications, because of the absorption at water and no transmission to the deeper layers. In this case report, we evaluated removal of gingival overgrowth with an Er:YAG laser outcomes at one years. **Case report:** A 25-year-old, systemically healthy, non-smoker, female patient was referred to our department with aesthetic problems associated with gingival overgrowth in maxillary anterior region. First of all the patient examined in terms of mouth breathing and consulted to Otorhinolaryngology department. Er:YAG laser was applied at the settings of 120mj 20 hz VLP mode as non contact with just topical anesthesia. In the patient, no discomfort, no pain complications were found intraoperatively or postoperatively. Patient was recalled at the days post-op 1, 3 and 10 days after laser surgery and the patient has been followed up for one year. **Conclusion:** Er:YAG lasers surgery caused less hemorrhage and resulted in better wound healing when compared with conventional methods. If patient has dental and injection phobia Er:YAG surgery may be preferred than the other conventional methods. Removal of gingival overgrowth may be performed safely with Er:YAG.

**OP 125 DIFFERENT TYPE OF DOMINANCE IN NATURAL PERMANENT ORTHOGNATHIC DENTITIONS**

ANDON FILTCHEV; DIMITAR FILTCHEV; GEORGI ILIEV; SAMER MAKKI;

MARIA DIMOVA; SVETLOZAR RANGELOV; BOGENA KOCHEVA

*Bulgaria*

**INTERDISCIPLINARITY**

**Background:** The purpose of the study is by analyzing photographs of natural permanent orthognathic dentitions to determine different types of dominance of one teeth group to the other. We define three types of teeth arrangements: with strong dominance of the central incisor and the canines and delicate laterals, middle dominance-central incisors and canines are almost the same measurements and normal laterals and low dominance where there are no essential difference between the three dental groups of central, lateral incisors and canines. **Materials and methods:** 106 photos were made (53 – females, 53 – males). All photos were made with DSLR camera with lip retractor and black contrastyor. The distance to the object and the camera adjustments were the same to all patients. The photos were imported and analyzed in a software Autodesk Autocad. Statistical processing of the results was made. **Results and Conclusion:** All cases were classified according to their type of dominance in present age. Mathematical formula was derived to describe each dominance. This study shows different types of teeth compositions found in natural permanent orthognathic dentitions different from well-known golden proportion.

**OP 129 INTRA-ARTICULAR DISORDERS OF TMJ IN THE ALBANIAN POPULATION AT THE AGE OF 18 - 25**

GERSI VËRÇANI; ALKETA QAFMOLLA

*Albania*

**ORAL DIAGNOSIS-ORAL RADIOLOGY**

Temporomandibular joint as all the other joints of organism is affected by a lot of various diseases. But, the frequent pathology that we face in the clinic practice is the dysfunctional disorder. Functional, psychological and anatomic factors are included in the display of this pathology. From this point of view, our study aims at defining the main factor that affects this group of population in the development of intra-articular disorders of TMJ. During 2013 – 2014, 211 patients at the age of 18 – 25 were investigated, from which 166 female and 45 male. The patients were examined intra-oral and extra-oral. The anamnesis was taken from them to verify not only the presence of these disorder symptoms but also their cause. 12 patients were subdued to the examination of Magnetic Resonance (MRI). The treatments of these patients were combined therapeutic - prosthetic through different splints or night guards. The mean age of patients was 19.7 ( $\pm 1.5$ ). 166 (78.7%) were females and 45 (21.3%) males. Pain and a joint click sound were found in 15.1% and 27% of patients respectively, abrasion in 51%, bruxism in 27 % and hypertrophy of masseter in 11.8%. Bruxism was positively associated with generalized abrasion ( $p < 0.01$ ). Bruxism was cured in 100% of cases through splint or night guards associated with NSAIDs and muscle relaxants. Intra-articular disorders maybe developed every age and the sooner we examine, the better we cure.

**OP 133 THE EFFECT OF RECASTING ON BIOKOMPATIBILITY OF DENTAL ALLOYS**

ALEKSANDRA CAIROVIC; DRAGOSLAV STAMENKOVIĆ; KATARINA RADOVIĆ

*Serbia*

**FIXED PROSTHODONTICS**

Within the procedure of making dental prosthetic restorations the alloys are melted and cast, which leads to changes in their physical, mechanical and biological properties. **Aim of the study:** The aim of this study was to compare the effect of recasting on two commercial dental alloys,

Ni-Cr and Au-Pt. **Material and method:** There were cast two groups of samples, after the first and after the fourth recasting, without adding any new amount of alloy. To show the influence of recasting on cytotoxicity of the two tested dental alloys there were used two tests: 24h cytotoxicity test and 3 days cytotoxicity test, both tests on L929 fibroblasts. **Results:** The qualitative 24h cytotoxicity test showed that the cells that were next to the samples also as the cells in the distant zones from the samples did not show any changes comparing to the negative control. The quantitative 24h test did not show any cytotoxic effect, also. The results of the quantitative 3 days cytotoxicity test showed some discreet changes, like inhibited cell growth in the areas around the samples. The quantitative 3 days cytotoxicity test showed different percentage of necrotic cells between the Au-Pt samples made after one and four recasting, but also the Ni-Cr samples made after one and four recasting showed the same changes. **Conclusion:** Cytotoxicity of dental casting alloys depends on their composition and element release. Recasting may affect these characteristics.

**OP 146 OPALESCENCE: AN AMAZING APPEARENCE PROPERTY OF NATURAL TEETH.**

BULENT PISKIN

*Turkey*

**FIXED PROSTHODONTICS**

Translucency, luminescence, fluorescence and opalescence are very important appearance properties of natural teeth. These appearance properties of natural teeth have to be successfully mimicked by restoration for obtain satisfied esthetic result. Opalescence, maybe, is the most important optical phenomenon among all these appearance properties. Despite that, there is very sparse that about opalescence of natural teeth and direct and indirect restorative materials. Moreover, some studies published in the leading scientific periodicals may lead a confusion for readers. This is because the lack of descriptive information in the literature. Purpose the present paper is given as follow: 1. To describe etymological roots of the word of opalescence, 2. Making a comprehensive definition of opalescence, 3. To give some details on opal effects of natural teeth and restorative materials, 4. To explain how to ensure opal feature in direct or indirect restorations.

**OP 157 HEREDITARY GINGIVAL FIBROMATOSIS: A CASE REPORT**

HATICE U MAY HOŞGÖREN; CAGLAR KORCUK; SÜLEYMAN ZIYA ŞENYURT;  
HASAN GÜNDOĞAR; KAMILE ERCIYAS

*Turkey*

**ORAL PATHOLOGY-ORAL MEDICINE**

**Introduction:** Gingival fibromatosis is the overgrowth of the gingiva characterized by the expansion and accumulation of the connective tissue with the occasional presence of an increased number of cells. It is a hereditary condition and it can cause malocclusion. It is a rare condition and can be shown with familial transmission. **Case Summary:** A 21 year-old female patient with gingival enlargement and serious malocclusion was referred to our department for not chewing anything because of her gingival overgrowth. When clinical examination has done, abnormal, fibrotic gingival hyperplasia had seen especially on the posterior teeth. On her anamnesis she hasn't got any systemic disease and her father, uncle and sister also have gingival enlargement. On the first visit non-surgical periodontal treatment was performed and oral hygiene instructions were

given. After one month, gingivectomy operation and excisional biopsy had been performed. Specimen had sent to the department of pathology and after the histopathological examination, the case diagnosed as a gingival fibromatosis. **Conclusion:** As a result; hereditary gingival fibromatosis traditionally considered as an autosomal dominant disease but in the current literature there were no clear consensus about that. Due to this situation generally treatment modalities depends on patient's clinical features. This case report is a quite specific example for excessive hereditary gingival fibromatosis.

**PP 168 BONDING PERFORMANCE OF EXPERIMENTAL SELF-ADHESIVE COMPOSITES CONTAINING DIFFERENT FUNCTIONAL MONOMERS**

HAMDİ ACAR; MUSTAFA ÜLKER

*Turkey*

**RESTORATIVE AND ADHESIVE DENTISTRY**

**Objectives:** To prepare six experimental self-adhesive composites containing different functional monomers (10-MDP, Bis -GPDMA, Bis-HEMA P, HEMA P, 4-META & 10-MDP + 4-META) than to compare their dentin shear bond strengths with one commercial self-adhesive composite (Vertise Flow, Kerr) and three all-in-one adhesive/flowable composite combinations (Optibond All In One/Premise Flowable, Kerr; G Bond/G-Aenial Universal Flo, GC; Clearfil S3 Bond/Clearfil Majesty Flow, Kuraray). **Methods:** Flat dentin surfaces were created on 250 extracted caries free human third molars. The teeth were embedded in cylindrical molds leaving flat dentin surfaces uncovered. While commercial bonding agents and composites were applied according to the manufacturers' directions, experimental self-adhesive composites were applied as Vertise Flow (n=25). Resin blocks were created by packing the material into cylindrical shaped plastic matrices. Specimens were stored in distilled water for 24 h at 37 °C before shear bond strength testing. Data were calculated as MPa and analyzed with one-way ANOVA and Tukey's HSD tests. **Results:** Optibond All In One showed the highest dentin shear bond strength (26,20±3,73) (p<0.05). All self-etching adhesives showed higher bond strengths than did all commercial and experimental self-adhesive composites (p<0.05). The bond strength of an experimental self-adhesive composite (10-MDP + 4-META) (14,82±3,93) was higher than those of other experimental self-adhesive composites and Vertise Flow (9,18±4,03). **Conclusions:** A self-adhesive composite that is having better bonding performance than commercial ones can be prepared. However, using a separate adhesive system is still the best way to bond the composite to the dentin.

**OP 170 EFFECT OF DIFFERENT SURFACE TREATMENTS ON SHEAR BOND STRENGTH OF A REPAIRED NANO-HYBRID COMPOSITE**

ALI IHSAN ERKAN; AYSE CANAN TUTKU ATMACA; HAYRIYE ESRA ULKER;  
MUSTAFA ULKER

*Turkey*

**RESTORATIVE AND ADHESIVE DENTISTRY**

**Objective:** Aged resin composites have a limited number of carbon-carbon double bonds to adhere to a new layer of resin. The aim of this study was to evaluate the effect of three different surface treatments (Er:YAG laser, air-abrasion and diamond bur) on repaired shear bond strength.

**Methods:** Sixty disk-shape, nano-hybrid resin composite specimens (Filtek™ Z550, 3M ESPE) were fabricated and the specimens were assigned to four treatment groups of 15 specimens each: 1) Er:YAG laser (wavelength of 2.94 μm at 150 mj, 10Hz, Fotona) 2) Air-abrasion (50-μm aluminum oxide) 3) Diamond bur 4) No treatment (control group). After surface treatments, silane (Clearfil Porcelain Bond Activator, Kuraray) and then adhesive resin (Single Bond Universal, 3M ESPE) was applied on each composite surface. Composite blocks were created by packing the material into cylindrical shaped plastic matrices. Specimens were stored in distilled water for 24 h at 37 °C before shear bond strength testing. Data were calculated as MPa and analyzed with one way ANOVA and Tukey's HSD tests. **Results:** Shear bond strength of Er:YAG laser group (10,72 ± 4,30) was higher than the shear bond strengths of diamond bur (6,33 ± 2,51) and control (6 ± 2,71) groups. However, there was no statistically difference between the shear bond strengths of Er:YAG laser and sandblasting (9,49 ± 3,46) groups. **Conclusions:** Based on the results of this study Er:YAG laser was confirmed to be as effective as air abrasion for composite repair.

**OP 173** **MIKROLEAKAGE OF DIFFERENT MATERIALS USED AS FISSURE SEALANT**

NURAY GUNAYDIN; HAYRIYE ESRA ULKER

*Turkey*

**RESTORATIVE AND ADHESIVE DENTISTRY**

**Background:** The aim of this study was to determine the microleakage of resin infiltration, glass carbomer cement and F1 Theethmate fissure sealant. **Material and method:** Thirty freshly extracted non-carious human molar teeth randomly separated into three groups and resin infiltration system (Icon, DMG Dental, Germany), glass carbomer cement (GCP Dental, Germany) and F1 Teethmate (Kuraray, Japan) applied to the pits and fissures according to manufacturers' directions (n=10). The specimens were immersed in 0.5 % basic fuchsin dye at 37°C for 24 hours. The teeth were sectioned into two pieces buccolingually in an occlusoapical direction. Each section was viewed under stereomicroscope with magnification of 30× and the degree of microleakage was evaluated using specific scoring criteria. Data were analyzed using the Kruskal Wallis and Mann Whitney U test (p < 0.05). **Result:** Glass Carbomer Cement exhibited significantly higher microleakage scores compared to the Icon resin infiltration system and F1 Teethmate fissure sealant (p < 0.05). The resin infiltration system and F1 Teethmate fissure sealant produced very low microleakage scores (p > 0.05). **Conclusion:** Icon resin infiltration system and F1 Teethmate fissure sealant showed feasible sealing ability. According to the results of this in vitro study it can be concluded that Icon resin infiltration system can be used as a good alternative of a fissure sealing material.

**OP 174** **EFFECT OF SALIVA DECONTAMINATION PROCEDURES ON SHEAR BOND STRENGTH OF ONE-STEP ADHESIVE SYSTEM**

ESRA ULKER; SELIN BILGIN; FIRDEVŞ KAHVECIOĞLU; ALI İHSAN ERKAN

*Turkey*

**RESTORATIVE AND ADHESIVE DENTISTRY**

**Backgrounds:** To evaluate the effect of different saliva decontamination procedures on the shear bond strength of an one step universal adhesive system (Single Bond™ Universal Adhesive,

3M ESPE). **Materials and methods:** The occlusal surfaces of 75 human third molars were ground to expose dentin. Group 1 control group; Single Bond™ Universal Adhesive applied to the prepared tooth and rub it in for 20 seconds and gently air dry the adhesive for approximately 5 seconds to evaporate the solvent and light cured for 10 seconds. Group 2 (bonding, saliva contamination, dry), Group 3 (bonding, saliva contamination, rinse and dry), group 4 (after procedure of group 2, reapplication of bonding) and group 5 (after procedure of group 3, reapplication of bonding). Then composite resins were applied by cylindrical shaped plastic matrixes and light cured. For shear bond testing, a notch-shape force transducer apparatus was applied each specimen at the interface between the tooth and composite until failure occurred. The data were statistically analyzed with Kruskal Wallis one way ANOVA test. **Results:** Mean values and standard deviations of observed MPa values were: Group 1a;(12,94 ± 5,81), Group 2b( 8,55 ± 1,83), Group 3a(12,26 ± 3,63), Group 4b (8,02 ± 2,19), Group 5a (12,26 ±3,39). **Conclusion:** According to the results of this in vitro study it can be concluded that groups which were not rinsed with water showed lowest values. It seems that rinsing with water a necessary step when contaminated with saliva for bonding agent which used in this study.

**OP 179 IMPROVING THE QUALITY OF LIFE OF OUR PATIENTS BY SURGICAL ORTHODONTIC CORRECTION OF IMPACTED CANINE**

ONDINE LUCACIU; ROXANA BORDEA; ADELA SOCACIU; BOGDAN CRISAN;  
RADU SEPTIMIU CAMPAN

*Romania*

**INTERDISCIPLINARITY**

The **aim** of this study was to determine the degree of influence of surgical-orthodontic treatment of impacted canine on the patient's quality of life. The study was performed in a group of 94 patients aged between 13 and 65 years, in various offices in Cluj-Napoca. The **method** used for the collection of the data was to fill a questionnaire by each patient. The questionnaire included questions related to the evolution of an impacted canine from diagnosis to therapeutic results. The **results** of our study demonstrated that the majority of the patients included were diagnosed by the dentists, with an impacted canine in the age range from 13 to 20 years. The most common symptom associated with impacted canine was gingival bulging towards the cheek or palate. Out of all the patients included in our study, limitation of social life occurred in a percentage of 61.7%, due to modified facial appearance. The professional life of our patients (29.79%) was weakly affected by canine impaction. The most frequent treatment applied was surgical-orthodontic correction (76.60%). After completion of the treatment the quality of life of our patients was improved. Canine impaction is a disorder that does not create major discomfort, but can be considered as having a greater effect on the women's quality of life when speaking about the discomfort felt. Our study shows a correlation between the age at which treatment was initiated and an improvement in the quality of life at the completion of treatment.



**OP 183 COMPARISON OF THE ACCURACY BETWEEN CONVENTIONAL AND DIGITAL RADIOGRAPHY FOR LINEAR MEASUREMENT IN CLINICAL DENTISTRY**

DRAGAN ILIC; DJORDJE ANTONIJEVIC

*Serbia*

**ORAL DIAGNOSIS-ORAL RADIOLOGY**

Comparison of the accuracy between conventional and digital radiography for linear measurement in clinical dentistry **Background:** Numerous literature data reports about wide specter of the use of digital radiography – radiovisiography (RVG) in dental practice. The aim of the study was to apply RVG and compare to the conventional radiographic technique – CRDG for accuracy in linear measurement in dentistry. **Material and methods:** The study was performed on the lower dogs' teeth considering a) incisors' crown width and b) height of surrounded alveolar bone using RVG and CRDG techniques. The control technique (CONT) was used by direct measurement in the dog's mouth. All measurements were done by two examiners. **Results:** There were no significant statistical difference in measurement of incisor crown width comparing CRDG, RVG and CONT themselves ( $p>0,01$ ). Concerning the alveolar height gauging there were no significant difference in measured values using whether CRDG or RVG ( $p>0,01$ ). Inter-examiner agreement was noted as high for all used techniques (CRDG, RVG and CONT). **Conclusion:** Although RVG did not expose higher accuracy then CRDG, opulent tool service exhibits the first technique more comfortable during measuring process in this study.

**OP 188 EFFECT OF ORAL HYGIENE MOTIVATION ON CARIES RISK FACTORS IN PREGNANT WOMEN**

ALI IHSAN ERKAN; NIMET UNLU

*Turkey*

**PREVENTIVE DENTISTRY**

**Background:** The aim of this study was to evaluate effectively of oral hygiene motivation, education and dietary advices on caries risk factors in pregnancy. **Material and methods:** This project is supported by TUBITAK with project number of 114S046. Fifty healthy pregnant women who were between 8-12 weeks (G1a) and 50 (G2) who were between 28-32 weeks (G2-control) were randomly selected ( $n=100$ ). G1a will be recalled again between 28-32 weeks (G1b). DMFT, dietary analyses, oral hygiene habits, plaque amount, gingival bleeding, Streptococcus Mutans (SM) and Lactobacillus (L) levels were recorded. 8-12 weeks pregnant (G1a) were given oral hygiene motivation and education (brushing and flossing) by dental professional. They were warned about dental problems during pregnancy and correct eating habits were advised (avoid from sugar, snacks etc.). 28-32 weeks (G2) were taken all motivation and education ethically. 8-12 weeks pregnant women called again between 28-32 weeks (G1b). Four women didn't continue to study ( $n=46$ ). The obtained data from G1b and G2 were statistically compared by using Chi-Square and Mann-Whitney-U tests. **Results:** Oral hygiene habits, plaque amount and SM level were statistically different between G1b and G2 ( $p<0,05$ ). There was no difference in dietary habits, gingival bleeding and L level ( $p>0,05$ ). Although, improving oral care habits may be caused reduction of SM level and plaque amount. Indifferent L level shows bad effect of wrong eating habits. **Conclusion:** Reducing

of SM level can prevent from caries initiation. But high L level may cause caries progression. This can cause toothache before birth and can reduce pregnant's life quality.

**OP 189 HISTOMORPHOMETRIC EVALUATION OF THE EFFECTS OF VARIOUS DIODE LASERS AND FORCE LEVELS ON ORTHODONTIC MINISCREWS**

MERVE GOYMEN; EREN ISMAN; LALE TANER; MEHMET KURKCU

*Turkey*

**LASERS**

**Introduction:** Low level laser therapy speeds up the blood flow, improves the mechanism of the revitalization processes, reduces the risk of infection, boosts the metabolic activities and accelerates the healing of the damaged tissue. Although, there are many researches about low level laser therapy applications in a variety of areas, no investigations were noticed concerning the mini screw stability using various laser dose levels with different force level applications. To evaluate the effects of different laser dose and force levels on the stability of orthodontic mini screws used for anchorage by histomorphometric analyses. **Methods:** Seventeen New-Zealand white rabbits were used. A total of 68 cylindrical, self-drilling orthodontic miniscrews were threaded at the fibula. Experimental subjects were divided into six groups; force application was not performed in the first three groups, while 150g of force were applied via nickel-titanium closed-coil springs placed between two mini screws. Measurements of the initial torque values (10Ncm) were manipulated by a digital portable torque gauge. Various low level laser doses were applied to the groups during the postoperative 10 days. After four weeks, bone to implant contact and cortical bone thickness were histomorphometrically analyzed. **Results:** In 150g force+20j/cm<sup>2</sup> dosage group, the highest bone to implant contact values were observed.(p<0.05) There were no statistically significant correlations between cortical bone thickness and bone to implant contact values whereas no significant difference was found between same groups in terms of cortical bone thickness values.(p>0.05) **Conclusions:** Low level laser therapy was noticed to induce the mini screw-bone contact area. Low level laser therapy may be a supplementary treatment method to increase the stability of the orthodontic miniscrew.

**OP 197 THE PHYSICOCHEMICAL CHARACTERISTICS OF SALIVA IN PREGNANT AND NON-PREGNANT WOMEN**

ALI IHSAN ERKAN; NIMET UNLU, ALI UNLU

*Turkey*

**PREVENTIVE DENTISTRY**

**Background:** The present study was undertaken to evaluate the salivary flow rate, buffer capacity, calcium, total antioxidant, total protein and phosphate levels in pregnant and non-pregnant women. **Materials and methods:** This project is supported by TUBITAK with project number of 114S046. Study was carried out on 50 pregnant women who were between 8-12 weeks (G1a) and 50 non-pregnant women (G2) between 18-40 years age (n=100). Stimulated saliva was collected in a measured cup. Flow rate was recorded in ml/min and buffer capacity determined according to color change. Remaining saliva stored in -80oC for later calcium, total protein, total

antioxidant and phosphate levels. G1a was recalled again between 28-32 weeks (G1b). Four women didn't continue the study (n=46). Saliva samples were collected with same methods and determined the buffer capacity. Previous frozen saliva samples and present samples analyzed for biochemical test at same time. Statistical analyses were done with Chi-Square, MannWhitney-U and Wilcoxon tests. **Results:** Salivary flow rate and antioxidant level were insignificant between G1a and G1b ( $p>0.05$ ), also these groups significantly higher from G2 ( $p<0.05$ ). Total protein level was significantly higher in G1b and G2 than G1a. Looking at the calcium level, all groups were different from each other ( $p<0.05$ ). There was no difference between all groups in saliva buffer capacity and phosphate level ( $p>0.05$ ). **Conclusion:** Great hormonal and physiological changes occur in pregnancy. These changes might be resulted saliva changes in pregnancy, even different periods of pregnancy. So pregnant should prevent by dental follow-up, including education about oral health.

**OP 200 THE IMPORTANCE OF THE CONDITION OF THE DONOR TEETH AND JAWS DURING ALLOGENEIC FACE TRANSPLANTATION**

AYŞİM ŞENOL; ZEYNEP ASLI GÜÇLÜ; AYŞE GÜLŞEN; SELAHATTIN ÖZMEN

*Turkey*

**ORAL SURGERY AND ORAL MAXILLOFACIAL SURGERY**

We aimed to present dental treatment of the cadaveric tooth in a transplanted maxilla in a facial transplantation patient with bony framework and soft tissue envelope. The treatment procedure was scheduled after physical examination, and the final plan was designed according to the patient's special medical condition. We reported the first successful endodontic treatment of an allogeneic cadaveric donor tooth in a face transplant patient. Dental disease represents a potential risk for infection in allogeneic transplant patients, which could affect the success of tissue transplantation and might lead to life threatening conditions. The (re)treatment of the diseased teeth is possible even after the transplantation. The health of the teeth and jaws of the donor should be evaluated before transplantation, especially when maxilla or mandible transplantation is planned.

**OP 205 MICROLEAKAGE OF DIFFERENT SELF-ADHERING MATERIALS**

HAYRIYE ESRA ULKER; NURAY GUNAYDIN; ALI IHSAN ERKAN;  
FIRDEVS KAHVECIOĞLU; MUSTAFA ULKER

*Turkey*

**RESTORATIVE AND ADHESIVE DENTISTRY**

**Background:** The aim of this study was to compare the mikroleakage of the glass carbomer cement with resin modified glass ionomer and self-adhering flowable composite material in Class V cavities. **Materials and methods:** 45 freshly extracted non-cariou human third molar teeth were randomly separated into three groups. Class V standardized (4 mm wide × 2 mm high × 2 mm deep) cavities were prepared and glass carbomer cement (Glass Fill, Germany), resin modified glass ionomer (Fuji II LC Capsule, Japan) and self-adhering flowable composite material (Vertise Flow, USA) applied to the cavities according to manufacturers' directions (n=15). The specimens were immersed in 0.5 % basic fuchsine dye at 37°C for 24 hours. The teeth were sectioned into two pieces buccolingually in an occlusoapical direction. Each section was viewed under stereomicroscope with

magnification of 30× and the degree of microleakage was evaluated using specific scoring criteria. For grading the microleakage, maximum dye penetration was selected. Data were analyzed using the Kruskal Wallis and Mann Whitney U test ( $p < 0.05$ ). **Results:** When the self-adhering materials were compared, Glass Carbomer Cement showed the highest leakage scores but statistically different from only Vertise flow in the gingival surfaces ( $p < 0.05$ ). Little or no microleakage was observed in the occlusal surfaces, and these differences was not statistically significant ( $p > 0.05$ ). **Conclusion:** These self-adhering materials can be used for older patient or pediatric patients because of its practical use and ability to bond to tooth structures without any bonding agent.

**OP 207 SAFETY OF THE USE OF ER,Cr:YSGG LASER ON ENAMEL SURFACE DURING IN-OFFICE TOOTH BLEACHING**

DIMITRIOS DIONYSOPOULOS; DIMITRIOS STRAKAS;  
EUGENIA KOLINIOTOU-KOUMPIA

*Greece*

**LASERS**

**Objective:** To evaluate the safety of Er,Cr:YSGG laser during in-office tooth bleaching on bovine enamel. **Materials and methods:** Forty-eight enamel specimens were prepared and divided into 4 groups: Group 1 specimens received no bleaching treatment; Group 2 received at-home bleaching treatment (22% carbamide peroxide) for 7 days, Group 3 received in-office bleaching treatment (35% H<sub>2</sub>O<sub>2</sub>) and Group 4 received the same in-office bleaching therapy with Group 3 using Er,Cr:YSGG laser. The specimens were stored for 10 days after the bleaching treatments in artificial saliva. Vickers hardness was determined using a microhardness tester and surface roughness was evaluated using a VSI microscope. Three specimens of each experimental group were examined under SEM and the mineral composition of the specimens was evaluated using EDS. **Results:** The enamel surface microhardness was reduced after in-office bleaching treatments ( $p < 0.05$ ), but not affected after at-home bleaching treatment ( $p > 0.05$ ). Moreover, the surface roughness was not significantly changed after tooth bleaching. EDS analysis did not show alterations in the enamel mineral composition, while SEM observations indicated changes in the surface morphology, especially after in-office tooth bleaching ( $p < 0.05$ ). **Conclusions:** The laser-assisted bleaching treatment with Er,Cr:YSGG laser did not affect the enamel surface compared with the conventional bleaching technique.

**OP 212 EFFECT OF DESENSITIZING AGENTS ON THE DENTIN BOND STRENGTHS OF SELF-ADHESIVE RESIN COMPOSITES**

MUSTAFA ÜLKER; ALI IHSAN ERKAN; HAKAN DINC; HAMDI ACAR; ESRA  
ULKER

*Turkey*

**RESTORATIVE AND ADHESIVE DENTISTRY**

**Background:** The aim of this study was to evaluate the effect of two desensitizer agents (Gluma Desensitizer, Heraeus Kulzer & Teethmate Desensitizer, Kuraray) on the shear dentin bond strengths of two different self-adhesive resin composites (Vertise Flow, Kerr & An experimental self-adhesive composite containing 10-MDP + 4-META monomers) **Material and methods:** Flat

dentin surfaces were created on 90 extracted caries free human third molars. The teeth were embedded in cylindrical molds with fast-setting acrylic resins leaving flat dentin surfaces uncovered. The specimens were assigned to six different groups of 15 specimens each. Desensitizing agents were applied according to manufacturer instructions. Untreated specimens were used as control. Then, resin blocks of self-adhesive resin composites were created by packing the material into cylindrical shaped plastic matrices with an internal diameter of 2.34mm and a height of 3mm. Specimens were stored in distilled water for 24 h at 37 °C before shear bond strength testing. Data were calculated as MPa and analyzed with Kruskal–Wallis and Mann–Whitney U-tests. **Results:** In comparison to the control group, Gluma Desensitizer application did not significantly influence the shear bond strength of self-adhesive resin composites ( $p > 0.05$ ). However, Teethmate Desensitizer application significantly decreased the shear bond strength of self-adhesive resin composites ( $p < 0.05$ ). **Conclusion:** Application of Teethmate Desensitizer may lead to low dentin bond strength values for self-adhesive resin composites.

**OP 225 HISTOLOGICAL EFFECTS OF EMDOGAIN® GEL ON EXPOSED DENTAL PULP**  
MARIJANA POPOVIĆ BAJIĆ; VESNA DANILOVIĆ; PROKIĆ BRANISLAV; VERICA  
MILOŠEVIĆ; SLAVOLJUB ŽIVKOVIĆ  
*Serbia*

#### DENTAL BIOMATERIALS AND DEVICES

**Background:** The aim of this study was to examine the histological effects of enamel proteins in Emdogain® Gel on exposed tooth pulp of a Vietnamese pig. **Material and method:** The study comprised 20 teeth of a Vietnamese pig. After class V preparation on the vestibular surfaces of incisors, canines and first premolars pulp was exposed. In the experimental group, the perforations were covered with Emdogain® Gel (Biore AB, Malmö, Sweden), and the control with MTA® (Dentsply Tulsa Dental, Johnson City, TN, USA). All cavities were restored with glass ionomer cement (GC Fuji VIII, GC Corporation, Tokyo, Japan). The observational period was 28 days, after which the animals were sacrificed, histological preparations were made. A light microscope was used to analyze the presence of dentin bridge formation, tissue reorganization and inflammation, and the presence of bacteria in the pulp. **Results:** The formation of the dentin bridge was observed in the experimental and control group. Inflammation of the pulp was mild to moderate in the experimental and control groups. Angiogenesis and many odontoblast-like cells, which are responsible for the formation of the dentin bridge, were observed. Necrosis was not observed in either case, as well as the presence of bacteria in the pulp. **Conclusions:** Histological analysis indicated a favorable therapeutic effect of Emdogain® Gel in direct pulp capping of Vietnamese pigs. The reaction of the pulp was similar to that of MTA.

**OP 229 DO INITIAL TORQUE VALUES AND PLACEMENT SPEEDS OF MINISCREWS HAVE EFFECT ON THE PRIMARY STABILITY?**

MERVE GOYMEN; TOLGA TOPCUOGLU; ALI MURAT AKTAN; EREN ISMAN

*Turkey*

**INTERDISCIPLINARITY**

**Aim:** The purpose of this study was to assess the relationship of the placement speeds and initial torque values (ITV) with the removal torque values (RTV) of mini screws and find out optimal placement parameters to get better primary stability. **Methods:** Sixty mini screws were randomly divided into six equal groups. The identification of the group 1 to 6 was performed according to the initial torque values and placement speeds of mini screws (10 Ncm-15 rpm, 20 Ncm-15 rpm, 30 Ncm-15 rpm, 10 Ncm-20 rpm, 20 Ncm-20 rpm, and 30 Ncm-20 rpm, respectively). Cone beam computed tomography (CBCT) images were used for standardization of cortical bone thickness of bovine bone samples. A digital portable torque gauge was used to place mini screws. A screwdriver was placed into another digital portable torque gauge to record removal torque values of each mini screw. The gradual increasing torque was applied in counter clockwise rotation until the mini screw moved slightly within the adjacent bone and the peak removal torque values were recorded. SPSS version 21.0 for Mac was used for statistical analyses. **Results:** The highest mean RTV value was observed in group 4 (5.62Ncm), followed by groups 6, 1, 5, 2 and 3 (5.54Ncm, 5.09Ncm, 4.84Ncm, 3.87Ncm, 3.42Ncm, respectively). Intergroup comparison presented significant differences in RTV values ( $p < 0.05$ ). **Conclusion:** Within the limitations of this study, it was concluded that the ITVs and placement speeds of mini screws have a significant effect on primary stability of mini screws. Furthermore, parameters of 10 Ncm and 20 rpm for placement of a mini screw might be recommended to provide better primary stability.

**OP 234 ORAL GRANULAR CELL TUMOR (MYOBLASTOMA): A CASE REPORT**

ANDREADIS DIMITRIOS; ANNA DIMITRIOU; IOANNA PATARGIA;  
ELEFThERIOS ANAGNOSTOU; ALEXANDROS KOLOKOTRONIS

*Greece*

**ORAL PATHOLOGY-ORAL MEDICINE**

**Introduction:** Oral Granular cell tumor (GCT) is now considered to be of neural origin (Schwann cell type). It is usually found at the tongue or floor of the mouth, and at extraoral positions including skin, larynx etc. **Case study:** A 60-year old woman was referred with a 6-month, well-defined, round-shaped, solid to elastic on palpation tumorous lesion, sized 0.5x1cm at the dorsal surface of the tongue. The overlying mucosa was ulcerated. After total excision, the histologic examination revealed aggregations of polygonal to rounded cells with small nuclei, which were usually centrally located, and eosinophilic cytoplasm contained coarse granules. Also, a severe pseudoepitheliomatous hyperplasia of the overlying epithelium was present. After 2 month follow up the patient was free of recurrence. **Conclusion-Clinical Relevance:** Due to its clinical similarities to other oral benign/malignant oral soft tissue tumors and the rare existence of aggressive behavior of GCT, emphasis should be given in its inclusion in differential diagnosis. Noteworthy, histologic

examination is also valuable because the pseudoepitheliomatous hyperplasia could be misdiagnosed as dysplastic lesion or even oral squamous cell carcinoma.

**OP 235 CHRONIC B AND C HEPATITIS IN THE HIV-POSITIVE POPULATION IN NORTH-EASTERN ROMANIA**

CARMEN MANCIUC; LIVIU PRISACARIU; CRISTINA NICOLAU; ALEXANDRA MARIA LARGU  
*Romania*

**INTERDISCIPLINARITY**

**Background:** Oral medicine and dental practice can be confronted with the possibility of nosocomial infections due to parenteral transmission viruses, HIV alongside hepatitis B and C being the most frequent. **Aim:** Evaluating the percent of hepatitis B and C in the HIV-positive population. **Material and methods:** HIV-positive patients' files have been analyzed retrospectively, highlighting confections with hepatitis B and C. **Results:** In the North-Eastern part of Romania 1446 patients are living with HIV/AIDS; 17.6% are B and C hepatitis virus coinfecting; 50% female. The largest number of patients is in Vaslui county (25%), and the smallest number in Bacau (4.31%). Most are infected with HBV (91.7%), the rest with HCV (7.45%), with two exceptions: one coinfection with B+C in Neamt, and one iv drug user with B+C+D. All patients receive antiretroviral therapy (ART); 58% of patients with HBV have in their HAART regime lamivudine; 12% receive raltegravirum; in 8% of cases there were ALAT changes, with a maximum of 475 ui/ml. For our region, hepatitis C and HIV infection do not have access to peginterferon and ribavirine. All patients are virologically, immunologically, clinically and psychologically monitored twice a year. Compliance and adherence to ART is <80%; the last viral load was detectable for >40% of patients. **Conclusions:** Due to the large number of HIV-positive patients with HVB and HVC coinfections, with a reduced adherence to antiretroviral therapy, it is important to raise awareness especially in the dental environment.

**OP 244 MINERAL CONTENT VARIATIONS AND MORPHOLOGICAL CHANGES OF MICE INCISORS ENAMEL ASSOCIATED WITH CHRONIC FLUORIDE OVEREXPOSURE**

EUGENIU MIHALAŞ; DANA CRISTIANA MAXIM; ADINA COROABĂ;  
NICOLAE GHEŢU; LAVINIA MATRICALA  
*Romania*

**PAEDIATRIC DENTISTRY**

**Background:** Fluoride overexposure can lead to dental fluorosis. Fluoride affects the ameloblasts function during the secretory and the maturation phase, causing poor mineralization and porous enamel formation. **Method and materials:** Twenty-one C57BL/6 male mice were randomly divided into a control group and 2 experimental groups. The experimental groups were treated with 25ppm and 50ppm of NaF. NaF was supplied through drinking water for 60 days. After that, lower incisors' enamel was subjected to SEM and EDX analysis. **Results:** EDX elemental analysis in both experimental groups showed higher weight content of C, O, N, Na and lower

weight content of Ca, P, F, Fe, and Cl. SEM analyses showed morphological changes which ranged from small, isolated enamel pits with regular margins, to extensive and deep loss of dental hard tissues with irregular margins and dentine exposed areas, as well as multiple fissures in the enamel surface. **Conclusion:** The severity of the morphological changes in mouse enamel varied with the supplied dose of NaF. The time period chosen to supply NaF was enough to induce lesions with uniform pattern in each experimental group. The SEM and EDX analysis confirmed the compositional and morphological changes specific to dental fluorosis. **Acknowledgements:** This work received financial support through the “Program of Excellence in multidisciplinary doctoral and postdoctoral research in chronic diseases”, contract no. POSDRU/159/1.5/S/133377, project co-financed by the European Social Fund Operational Programme “Human Resources Development” for 2007-2013.

**OP 249 THE EFFECT OF SMOKING ON COMPONENTS OF GINGIVAL CREVICULAR FLUID IN PATIENTS WITH PERIODONTAL DISEASE**

IOANNA TSACHOURIDOU; MARINA TSIRAKI; LAZAROS TSALIKIS;

ANTONIOS KONSTANTINIDIS

*Greece*

**PERIODONTOLOGY**

**Background:** Smoking is one of the major environmental risk factors for periodontal diseases. It may be hypothesized that the gingival crevicular fluid profile in periodontal patients who are also smokers differs from the profile of non-smokers. The aim of this systematic review is to examine if smoking affects the composition of gingival crevicular fluid in patients with chronic periodontitis. **Methods and materials:** Databases were searched from 2000 to 2014 using different combinations of keywords. Titles and abstracts of articles that satisfied the eligibility criteria were screened by the authors and checked for agreement. Only articles published in English were included. **Results:** Twelve studies were included. One study reported no differences in Il-1b and Il-1ra between smokers and non-smokers, whether another study showed significantly lower concentration of Il-1b in smokers in deep bleeding sites and Il-1ra in all sites. Two studies reported significantly reduced Il-1ra in smokers. One study found significantly less U-PA, Il-6, Il-12 and Il-8 in smokers, while another showed increased GM in smokers. Two studies reported no significant differences between the groups as for their cytokine and inflammatory mediator release. One study showed different vascular function and another one reported decreased host defense in smokers, while another found the opposite results. **Conclusion:** An overall conclusion cannot be reached about the GCF profile in smokers and non-smokers. Therefore it is suggested that further research should be conducted, focusing in the same components of GCF with the same methods of collection in order to make a meta- analysis.



**OP 253 GOLDENHAR SYNDROME**

CLAUDIA FLORIDA COSTEA; CRISTINA RUSU; CAMELIA GEANINA IVĂNESCU;  
DANA MIHAELA TURLIUC; INGRITH CRENGUȚA MIRON

*Romania*

**INTERDISCIPLINARITY**

Goldenhar syndrome - complete form (Oculo-Auriculo-Vertebral Spectrum) (OAVS) is a rare congenital condition characterized by craniofacial abnormalities associated with anomalies of the spine, heart, kidney, central nervous and gastrointestinal system. Craniofacial abnormalities include the incomplete development of the eye, ear, nose, soft palate, lips and jaw. We report a case of Goldenhar syndrome - complete form (Oculo-Auriculo-Vertebral Spectrum) (OAVS) in a 14-years-old male patient. There are no other identified cases of congenital diseases in the patient's family history. At the age of 2, the patient was operated for complete right cleft lip and cleft palate dehiscence and it was then, that the suspicion for Goldenhar syndrome was harbored. The genetic examination confirmed the diagnosis of Goldenhar Syndrome - complete form (Oculo-Auriculo-Vertebral Spectrum) (OAVS). The ophthalmologic examination revealed the microphthalmia of the right eyeball. The ENT exam revealed facial dysmorphism, malformation of the right auricular pavilion with atresia of the external auditory canal and right nasal fossa malformation with deviated septum. The CT examination revealed complex cervical vertebral malformations. The cardiologic examination did not reveal structural and functional abnormalities. The renal ultrasound did not show any changes. The psychological consultation revealed a slight mental deficiency and dyslalia in the context of the disease. Being a rare syndrome with many defects, early diagnosis is important, in order to apply appropriate treatment.

**OP 254 UNILATERAL EXOPHTHALMOS IN A CASE OF MAXILLARY SINUS CARCINOMA WITH EYE-SOCKET INVASION**

CLAUDIA FLORIDA COSTEA; GABRIELA FLORENȚA DUMITRESCU

*Romania*

**INTERDISCIPLINARITY**

Unilateral exophthalmos is a rare pathology, encountered in clinical practice. Its multiple etiologies require correct diagnosis by the family physician and patient referral to a specialist physician. We are presenting the case of a 46-year-old female patient who was admitted to Ophthalmology Unit of the "Prof. Dr. Nicolae Oblu" Emergency Clinical Hospital, Iasi, Romania with a non-reductive left-sided exophthalmos and hemicrania, displacement of the upper left eyeball and diplopia. The CT exam revealed a parenchymal tumor formation located in the left maxillary sinus, which produced the destruction of the lateral and internal wall of the maxillary sinus and the lesser wing of the sphenoid bone, with extension in the nasal fossa, ethmoid cells, left zygomatic lodge and intraorbital. The patient was operated in the Neurosurgery Unit of the "Prof. Dr. Nicolae Oblu" Emergency Clinical Hospital by a joint team comprising a neurosurgeon and maxillofacial surgeon, and partial tumor resection and eye socket evisceration were performed. The pathological examination revealed an undifferentiated carcinoma originating in the maxillary sinus mucosa, infiltrating the vascular connective tissue of the eye socket. She was subsequently sent to the Oncology Clinic, where she undertook palliative chemotherapy and radiotherapy treatment.

The surgical treatment combined with radiotherapy and chemotherapy can control the disease to a certain extent, only in the case of early diagnosis of the disease.

**OP 256 EVALUATION OF THE PREVENTIVE EFFECT OF DIODE LASER AND FLUORIDE ON ENAMEL EROSION**

DILEK GUNES; CIGDEM GULER; GUL TOSUN

*Turkey*

**PREVENTIVE DENTISTRY**

**Background:** The aim of this study is to evaluate the effect of preventive of enamel erosion by diode laser and fluoride on bovine teeth. **Materials and methods:** Totally 4 experimental groups [control (K), fluoride (F), diode laser (D) and F +D] were formed whereby each group was consisted of 10 enamel specimens. All samples were subjected to 10 day erosion cycle. Beginning, after the treatment, after the 1, 3, 5 and 10 days erosion cycle, amounts of F, Ca, P and ratios of Ca/P in enamel surfaces were calculated by EDX. Morphological changes were investigated by SEM. All datas were evaluated statistically. **Results:** Amount of F uptake on the enamel surface in the F+D group were higher than other groups ( $p < 0.05$ ). After application of diode laser, decrease was detected in the of F values and Ca/P ratios on the enamel surface. Considering the F values and Ca/P ratios of the groups was exposed to erosion cycle, while the highest value in the F+D group, the lowest values were found to be the K group. Analyzing the SEM images were founded that F+D group was the most resistant group to erosion and control group was the most vulnerable group to erosion. **Conclusion:** As a result, the combined use of the diode laser with F prevented the enamel erosion by enhances the fluoride uptake enamel surface. Thus the combined use of the diode laser with F may be an alternative treatment method for prevent enamel erosion.

**OP 259 THE ORTHODONTIC TREATMENT OF SEVERE SKELETAL CLASS II PATIENT**

EMIRE AYBUKE ERDUR; AHMET VURAL; FARUK AYHAN BASCIFTCI

*Turkey*

**ORTHODONTICS**

**Aim:** Functional jaw orthopedics one of the most effective treatment methods for the correction skeletal class II malocclusion. The use of functional jaw orthopedics, patients ultimately have beautiful smile, better lateral profile and functional occlusion. Second phase of treatment is fixed orthodontic treatment to provide teeth alignment. The aim of this presentation is to show the success of twin-block treatment in subjects with a severe skeletal class II malocclusion in early-childhood. **Material and methods:** The patient was a 12-year-old adolescent boy, who presented with a class II division I malocclusion. Examination of the occlusion revealed a severe Class-II malocclusion with an overjet of 13.55mm and an overbite of 8mm and class II canine and molar relationship were recorded. In radiological examination, it was observed that he was in mixed dentition and had retrognathic mandibula. Maxillary and mandibular dental arch crowdings were 2,3 mm and 6 mm respectively. In the clinical examination, a convex profile and incompetence lips were recorded. The twin block appliance was applied for the correction of mandibular retrognathism. After the functional treatment, fixed orthodontic treatment was applied with mandibular incisor extraction. **Results:** After the functional treatment patients had esthetic profile

and functional occlusion. In spite of mandibular incisor extraction's side effects, he had much better esthetic smile design. Class I canine and molar relationship and harmonious overjet and overbite were obtained. **Conclusion:** Although the degree of mandibular retrusion is maximum, successful treatment results can be obtained with early skeletal treatment protocol.

**OP 260 THE ORTHODONTIC TREATMENT OF SEVERE CROWDING PATIENTS WITH DAMON SYSTEM: CASE REPORT**

EMIRE AYBUKE ERDUR; RABIA MERVE CELIK; AHMET VURAL;  
FARUK AYHAN BASCIFTCI

*Turkey*

**ORTHODONTICS**

**Aim:** The aim of this case report is to show non-extraction treatment results of severe crowding patients with Damon system. **Materials and methods:** In this case report, two patients - admitted to our clinic for aesthetic reasons- were presented. Both patients had excessive dental arch crowding and buccal corridors and cephalometric analysis showed that maxilla and mandibula were in class I skeletal relationship. The first patient was a 17-year-old girl. Clinical examination showed that the patient had normal overjet and overbite. Maxillary and mandibular dental arch crowding were 8mm and 7,5mm respectively. The second patient was a 15-year-old girl. Clinical examination showed that, the patient had 0,5mm overjet and 1,5mm overbite. Maxillary and mandibular dental arch crowding were 12,3mm and 1,6mm respectively.. Both patients were treated with the Damon system. **Results:** After orthodontic treatment, dental arch crowding was resolved, class I molar and canine relationship was maintained, ideal overbite and overjet were achieved. Smile aesthetics and buccal corridors were improved. **Conclusions:** Patients with arch length discrepancy may require teeth extraction; however in some cases the profile may be effected negatively by extraction treatment. Damon brackets has been suggested that this system have some advantages like improve profile, reduced disturbance and pain. Also Damon system increases intermolar width with the arches less proclination of anterior teeth and reduced requirement of tooth extraction. As a conclusion, after successful treatment with damon system brackets there is no need extractions for the ideal occlusion and patients have a better smile and profile.

**OP 262 PERIODONTAL DISEASE AND CARDIOVASCULAR DISEASES**

IRINA ESANU; CRINGUTA PARASCHIV; MIHAELA BOANCA

*Romania*

**INTERDISCIPLINARITY**

Advanced periodontal disease are responsible for 30-35% of extractions in patients aged over 40 years, men were more likely than women. Periodontal lesions cause gingival inflammation and destruction of periodontal ligament and alveolar bone, eventually forming periodontal pockets. The factors that place a person having an increased risk for periodontal disease can be the same as those which put at high risk for systemic diseases such as cardiovascular diseases. Common risk factors in the environment are smoking, stress, age, race or ethnicity and male sex. In the category of

other possible risk factors with implications for cardiovascular disease are chronic infections and inflammation in periodontal disease. Periodontal disease is able to predispose an individual to cardiovascular diseases because of the multitude of gram-negative species involved, elevated levels of proinflammatory cytokines, immune and inflammatory infiltrates present strong association with elevated levels of fibrinogen and the white blood cells. Prevention of cardiovascular disease can lead to significant benefits on the economic cost of treatment of periodontal insertion and subsequent loss of dental implants.

**OP 263 THE EVALUATION OF MCI, MI, PMI AND GT WITH DIFFERENT AGE, GENDER AND DENTAL STATUS**

GULDANE MAGAT; SEVGI SENER

*Turkey*

**ORAL DIAGNOSIS-ORAL RADIOLOGY**

**Background:** The aim of this study was to measure the mandibular cortical index (MCI), mental index (MI), panoramic mandibular index (PMI) and cortical bone thickness in the zone of gonial angle (GT) in panoramic radiographies from a large sample of men and women and to determine how it relates to patients' age, gender and dental status. **Materials and methods:** Nine hundred and ten panoramic radiographs were obtained and they were grouped into age, dental status and gender. The MCI, MI, PMI and GT were analyzed. **Results:** Remarkable differences were observed for MCI and GT regarding gender, age groups and dental status on both sides ( $p < 0,05$ ). While age, dental status had effect on MI and PMI in females, dental status had effect on MI and PMI in males ( $p < 0,05$ ). Also, gender had effect on MI and PMI ( $p < 0,05$ ). **Conclusion:** The effects of age and tooth loss are different on females and males. In females, the harmful effects of tooth loss and age are more prominent according to the PMI and MI measurements. The effect of age and tooth loss in GT and MCI measurements are similar, these indices can be accepted more reliable in the studies include both genders.

**OP 264 MANDIBULAR MORPHOLOGICAL CHANGES: THE EFFECTS OF AGE, GENDER AND DENTAL STATUS**

GULDANE MAGAT; SEVGI SENER

*Turkey*

**ORAL DIAGNOSIS-ORAL RADIOLOGY**

**Background:** The aim of this study was to measure the gonial angle (GA), antegonial angle (AGA), antegonial depth (AGD), condylar height (CH), ramus height (RH) and ramus width (RW) in panoramic radiographies from a large sample of men and women and to determine how it relates to patients' age, gender and dental status. **Materials and methods:** Nine hundred and ten panoramic radiographs were obtained and they were grouped into age, dental status and gender. The GA, AGA, AGD, CH, RH, and RW were analyzed. **Results:** No differences were observed for CH regarding gender, age groups and dental status on both sides ( $p > 0,05$ ). Age had effect on RW in females and AGD in males. Dental status had effect on AGA and RW in females and GA and RW in

males ( $p < 0,05$ ). Also, gender had effect on GA, RH, AGA and AGD ( $p < 0,05$ ). **Conclusion:** The results of this study demonstrated that the gonial and antegonial, and ramus regions undergo remodeling according to age, gender and dental status. This remodeling affects specific regions in mandible. It can be concluded that the differences related age, gender and dental status can be associated with variance in the masticatory activity in this region of mandible. Because age, gender and dental status have no effect on CH, the significant changes of CH length can be considered as some abnormal situations' signs.

**OP 266 RHEUMATOID ARTHRITIS - A FAVORING FACTOR OF CHRONIC PERIODONTITIS**

DORA POPESCU; DORIN GHEORGHE; LUCIAN DRAGOMIR;  
MELANIA COJOCARU; PETRA SURLIN  
*Romania*

**PERIODONTOLOGY**

**Background:** Despite some differences between rheumatoid arthritis (RA) and the chronic periodontal disease, regarding etiology and clinical manifestations, over time, a number of studies have proved the links connecting these two conditions. The **aim** of our study was to analyze the level of the periodontal disease in patients with RA. **Methods and materials:** The study group was made out of subjects with periodontal issues, who either did or did not suffer from RA. The subjects were then divided into two groups, those suffering from both conditions and those manifesting only periodontal disease. Complete periodontal diagnosis was conducted, while data for the RA was collected from the patients' medical records at the Craiova Rheumatology ward. **Results:** The results obtained showed an increased number of affected teeth with periodontal disease (pockets larger than 4mm) for the group with both RA and periodontal conditions rather than for the group suffering only from periodontal condition. Pocket depths larger than 6mm were also more frequent in the first group (RA + periodontal disease). **Conclusions:** the data shows a link between the two conditions, who despite having different etiology, both infer a general disturbance of the immune system. The study also shows a higher degree of periodontal disease in patients who also suffer from RA. Further studies on larger samples of subjects are required in order to confirm our results.

**OP 270 BOND STRENGTHS TO ROOT DENTIN OF DIFFERENT SELF-ETCH ADHESIVE SYSTEMS**

COBANOGLU NEVIN; AKTAS BILAL; ERKAN ALI İHSAN; DINÇ DERYA  
*Turkey*

**RESTORATIVE AND ADHESIVE DENTISTRY**

**Background:** Bonding to root dentin is important for quality of adhesive restorations on the root surface. So, the aim of this study was to compare bond strengths to root dentin of a two-step and three all-in- one self-etch adhesive systems. **Material and methods:** Flat root dentin surfaces were created on 60 extracted caries free human third molars by separating from enamel-cement border. Teeth were embedded in cylindrical moulds with fast-setting acrylic resins leaving

flat root dentin surfaces uncovered. The specimens were assigned to four different groups: Single Bond Universal (SB), Adper Easy One (AE), Clearfil SE Bond (SE), Imicryl Nova Compo-B Plus (IN), (n=15). All bonding agents applied to manufacturer's instructions. Resin blocks with Filtek Z550 were created by packing the material into cylindrical shaped plastic matrices with an internal diameter of 2.34 mm and a height of 3mm. Specimens were stored in distilled water for 24 h at 37 °C and shear bond strengths were determined. Data were calculated as MPa and analyzed with Kruskal-Wallis and Mann-Whitney U-tests. **Results:** Mean values and std. deviations of groups were; SB: 14,3(±4,51), AE :9,09(±3,55), SE: 7,41(±3,86), IN: 8,46(±5,33). Bond strength in SB was statistically significant higher than other groups. There was no statistically significant difference between the other groups. **Conclusion:** Bond strengths to root dentin of all-in-one adhesives were higher than two-step self-adhesive used in this study.

**OP 277 HARD TISSUE RECONSTRUCTION IN DENTAL IMPLANTOLOGY**

VIORIEL IBRIC CIORANU

*Romania*

**ORAL SURGERY AND ORAL MAXILLOFACIAL SURGERY**

Dental implantology has become a current method of prosthetic treatment. One of the major problems that clinicians have to face is the lack of bone volume in the planned positions of the implants. The missing hard tissues can be rebuild using various technics depending on case selection. We present the different methods that our department uses on every day bases. We focus on autologous bone harvested from the intraoral sites but also extraoral approaches (ilium, calvaria). Calvaria grafts have allowed patients with large defects to benefit from the comfort of fixed implant cemented prosthesis.

**OP 278 COMBINED ORTHODONTIC AND RESTORATIVE TREATMENT OF PEG-SHAPED OR MISSING MAXILLARY LATERAL INCISORS: CASE REPORT**

RABIA MERVE CELIK KARATAS; ALI IHSAN ERKAN; MEHMET TUGRAN;

MEHMET AKIN

*Turkey*

**ORTHODONTICS**

**Aim:** The aim of this case report is to show the results of the combined orthodontic and restorative treatments of patients with peg-shaped or missing maxillary lateral incisors. **Materials and methods:** Three patients with maxillary peg-shaped lateral or missing lateral incisors were referred to the Selcuk University Faculty of Dentistry, Department of Orthodontics for aesthetic reasons. First patient was a 15 year old girl. Clinical examination showed that the patient had a peg-shaped maxillary lateral incisor. After the fixed orthodontic treatment the peg lateral was restored with composite resin restoration. Second patient was a 24 year old girl. Clinical examination showed that the patient had a peg-shaped lateral incisor and a congenitally missing lateral incisor. After the fixed orthodontic treatment the restorative treatment was performed. The peg-shaped lateral incisor was built up and the canine was reshaped to simulate the lateral incisors with

composite resin restorations. Third patient was an 11 year old girl. Clinical examination showed that the patient had a peg-shaped maxillary lateral incisor and a impacted canine. After the fixed orthodontic treatment the restorative treatment was performed. The peg-shaped lateral incisor was built up with composite resin restoration. **Results:** At the end of the orthodontic and restorative combined treatment, spaces at the maxillary anterior region were closed. Ideal overbite and overjet were provided. Smile aesthetic was improved. **Conclusion:** Patients with peg-shaped or missing maxillary lateral incisors have some aesthetic problems. The combined orthodontic and restorative treatment is useful to improve smile aesthetic in patients with peg-shaped or missing maxillary lateral incisors.

**OP 279** **COMBINED ORTHODONTIC AND RESTORATIVE TREATMENT OF ENAMEL HYPOPLASIA : CASE REPORT**

RABIA MERVE CELIK KARATAS; ALI IHSAN ERKAN; MEHMET TUGRAN;  
MEHMET AKIN

*Turkey*

**ORTHODONTICS**

**Aim:** The aim of this case report is to show the results of the orthodontic and restorative correction of enamel hypoplasia on the maxillary anterior teeth. **Materials and methods:** The patient was a 14 year 6 month old girl referred to the Selcuk University Faculty of Dentistry Department of Orthodontics for aesthetic reasons. Clinical examination showed that the patient had enamel hypoplasia especially on the maxillary anterior teeth. She had class II molar and class I canine relationship. Radiological examination showed that the patient had impacted premolar at the left side of the maxilla. After the fixed orthodontic treatment Class I canine and molar relationships were achieved. Afterwards the restorative treatment was performed. Hypoplastic teeth were corrected with composite resin restorations. **Results:** At the end of the combined orthodontic and restorative treatment, smile aesthetic was improved, diastemas were closed and crowding was resolved. Ideal overbite and overjet were provided. **Conclusion:** Patients with hypoplasia have some aesthetic problems. The combined orthodontic and restorative treatment is useful to improve smile aesthetic in patients with hypoplasia.

**OP 285** **ASPECTS OF INTERMAXILLARY RELATIONSHIPS REGISTRATION IN UNIMAXILLARY COMPLETELY EDENTULOUS PATIENTS**

MONICA SCRIECIU; VERONICA MERCUȚ; SANDA MIHAELA POPESCU; ROXANA IULIA MARINESCU; MARINA OLIMPIA AMĂRĂSCU

*Romania*

**REMOVABLE PROSTHODONTICS**

**Introduction:** The complete edentulism is associated with specific bone changes that can cause alterations in intermaxillary relationships. The tooth keeping on the antagonist arch in unimaxillary complete edentulism adds difficulty in registration of intermaxillary relationships and rehabilitation of edentulous arch. **Material and method:** The present study highlights the

differences between steps of intermaxillary relationships registration in two complete edentulous patients: one with maxillary complete edentulism and one with mandibular complete edentulism. Two facial bows manually handled were used for both patients: facial bow KaVo Protar Evo 7 (KaVo Company) for the position registration of maxilla to the base skull and the facial bow CONTACT LZ (Bayer Company) for recording the condylar path during opening and closing movements of the mouth. Determination of vertical occlusal dimension was made with an acrylic appliance for dentate jaw and a wax occlusion rim for edentulous jaw. Recording of central relation was made by the intraoral Gothic arch tracing method using Gerber's two plates: one plate with central needle and one plate coated with thin film of blue wax. **Results:** The steps of the registration of intermaxillary relationships differed for two types of unimaxillary complete edentulism. The utilization of different manually handled devices could allow to the patients an easier adaptation with complete dentures, although the errors can occur. **Conclusion:** The recording of intermaxillary relationships needs theoretical knowledge, practical skills and specific equipment.

**OP 291 ETIOLOGICAL RISK FACTORS AND PREDICTORS FOR CORRECTIVE TREATMENT OF CROSSBITES**

GEORGETA ZEGAN; CRISTINA GENA DASCALU; RADU BOGDAN MAVRU;  
LOREDANA GOLOVCENCU; DANIELA ANISTOROAEI  
*Romania*

**ORTHODONTICS**

**Background:** Crossbite is an orthodontics emergency, which must be early detected by dental practitioners. The purpose of this study was to determine the etiological risk factors and predictors of crossbites' treatment at children. **Methods and materials:** This retrospective case-control study was conducted for 525 orthodontic patients (217 males and 308 females) aged between 6-18 years old. There were examined 270 cases with crossbites and 255 controls with other malocclusions, matched for gender, dentition stages and Angle Class malocclusions. The crossbites cases were divided in group I (anterior crossbite), group II (posterior crossbite) and group III (anterior and posterior crossbites) and were compared between them and with controls. Baseline evaluation included social parameters, oral status, etiology, associations with other signs, need and types of treatment. **Results:** Bivariate logistic regression was used to analyze risk factors and predictors. There were found significant differences between the groups of crossbites cases ( $p < 0.05$ ). Non-atritioned deciduous teeth and Class II malocclusion were found as risk factors for posterior crossbite; non-atritition and permanent teeth extractions were found for anterior and posterior crossbites. We found sucking habit, non-atritition and buds crowding as high significant predictors for precocious corrective treatment; mouth breathing and buds crowding for normal treatment; Class III malocclusion, dental crowding and TMJ disorders for late treatment; eruption anomalies and buds crowding for maxillary expansion; macrodontia and TMJ disorders for oral associated surgery (HL test,  $p > 0.05$ ). **Conclusions:** We identified only dental risk factors; the predictors of treatment were adequate with dentition, etiology and disorders at age identification.



**OP 296 MICROBIOLOGICAL ASPECTS OF PERIODONTAL DISEASES IN JUVENILE DIABETES**

VASILICA TOMA; ANCUȚA GORIUC; DANIEL PETRU CIOLOCA;  
LOREDANA HURJUI; ADRIANA BALAN

*Romania*

**PAEDIATRIC DENTISTRY**

**Material and methods:** The study was conducted on 45 children and adolescents divided into 3 groups (15 subjects each) as follows: control group - children with good general condition, good metabolic control IDDM (insulin dependent diabetes mellitus) group (HbA1c <7.5%) and poor controlled IDDM group (HbA1c > 7.5%). A total of 97 GCF samples (collected on paper cones of mesial sites from prime permanent molars and central incisors from the enrolled subjects) were divided into two groups including: group with various degrees of gingivitis (mild - 19 samples, moderate - 29 samples, severe - 16 samples) and the healthy group (33 samples). Periodontal bacteria were identified by the DNA extracted from GCF using multiplex PCR kit for *Actinobacillus actinomycetemcomitans* (A. a), *Fusobacterium nucleatum* (Fn), *Porphyromonas gingivalis* (Pg) and *Tannerella forsythensis* (Tf). **Results:** In moderate and severe forms of gingivitis, the number Fn, Pg, Tf was significantly increased compared to mild gingivitis group. Statistically significant differences were recorded between groups of children with IDDM as well, the values being notably elevated in the group of children with poorly controlled IDDM compared to those with good IDDM metabolic control ( $p < 0.05$ ). Moreover, the most expanded values were registered for Fn bacteria in samples from IDDM children with severe gingivitis and poor metabolic control. **Conclusions:** In children with IDDM there is a boost in GCF number of Pg, Fn, Tf in parallel with the progression of periodontal inflammation that could be correlated with the degree of metabolic control of diabetes.

**OP 301 NON-INVASIVE APPROACH TO THE AESTHETIC REHABILITATION AFTER ORTHODONTIC TREATMENT: CASE SERIES**

NERMIN DEMIRKOL; MERVE GÖYMEN; MERVE AYCAN KIR

*Turkey*

**RESTORATIVE AND ADHESIVE DENTISTRY**

**Introduction:** Malformations, mineralization disorders, decalcification around bracket/band after orthodontic treatment may hinder the ideal aesthetic appearance after orthodontic treatment. Composite restorations are one of the most commonly used methods for obtaining ideal result. These restorations are an invasive process and applied easily. The **aim** of this case series is to demonstrate ideal aesthetic results with multi-disciplinary treatment and direct composite restoration. **Material and method:** This multi-disciplinary case series report had 5 patients who were referred to the Prosthodontics Department Clinic with aesthetic requirements after completed orthodontic treatment. These patients had anterior diastemas because of wedge-shaped or microdontic teeth. Photographic records were obtained before and after treatment. Composite material was selected according to the natural tooth colour. Conventional composite material application was done invasively. After then composite was polished with coarse grain through the fine grain. Patients were informed and treatment was completed. **Results:** The shape and dimensions of tooth were

corrected. Diastemas were closed. Desired smiling was achieved in all cases. Patients' quality of life was improved. **Conclusion:** The direct composite restoration, which has advantage of non-invasive approach, should be given consideration as a reasonable option for the treatment of microdontic and wedge-shaped teeth after orthodontic treatment. It is understood that ideal aesthetic results can be provided by this technique.

**OP 302 EFFICIENCY OF PHOTODYNAMIC THERAPY IN THE TREATMENT OF PERI-IMPLANTITIS. A RANDOMIZED CONTROLLED CLINICAL TRIAL.**

DRAGANA RAKASEVIC; BOJAN RAKONJAC; ZORAN LAZIC; ZORAN ALEKSIC  
*Serbia*

**ORAL IMPLANTOLOGY**

**Background:** The aim of this study was to evaluate clinical and microbiological outcomes, prior to and following the treatment of peri-implantitis, using surgical methods with or without an adjunctive photodynamic therapy. **Materials and methods:** 30 systemically healthy patients with peri-implantitis diagnosed were divided into two groups. In the experimental group (15 patients) photodynamic therapy was used for decontamination of implant surface and peri-implant tissues during the surgical procedure. Decontamination of implant surface and peri-implant tissues in the control group (15 patients), was performed with chlorhexidine gel followed by saline irrigation. Bleeding on probing (BOP), plaque index (PI), peri-implant probing depth (PPD), mucosal recession (MR), and clinical attachment level (CAL) were recorded at baseline and at 3 months after the surgical treatment. Samples for microbiological identification were collected before therapy, during surgical therapy and 3 month after therapies. Anaerobes' identification systems using enzymatic tests were applied for the identification of the isolated anaerobes. **Results:** The photodynamic therapy application was associated with significant decontamination of implant surfaces and peri-implant tissues with complete elimination of anaerobic bacteria when compared with chlorhexidine application, immediately after surgical procedure and 3 month after. The use of photodynamic therapy resulted in significant decrease of BOP when compared with chlorhexidine. There was no significant difference in PD and CAL results between two groups. **Conclusion:** The results of this study indicate that the photodynamic therapy can be used as an adjuvant therapy for decontamination of implant surface and surrounding peri-implant tissues in the treatment of periimplantitis.

**OP 316 SHADE MATCHING QUALITY AMONG DENTAL STUDENTS USING VISUAL METHOD**

MUNIR TOLGA YUCEL; YENER OKUTAN  
*Turkey*

**FIXED PROSTHODONTICS**

**Background:** Shade selection by matching natural teeth with shade guide tabs is common practice in dentistry today. To select the right color of the restoration matching the remaining natural teeth is always a challenging task. The purpose of this study was to evaluate and compare

the shade-matching ability of dental students using a shade guide. **Methods and materials:** A ceramic specimen was made (3M3 shade) as a master guide and confirmed by a spectrophotometer. The study was performed at the Selcuk University Faculty of Dentistry with the help of 75 preclinical and 75 clinical students using a Vita 3D-Master shade guide. The participants viewed the specimen and shade guide from a distance of approximately 25 cm under the same lighting condition. The selected shades were recorded and statistical analysis was performed to evaluate the data. **Results:** The overall ability for all students was low (31.3%) with the visual method. There was a statistical difference for experience in terms of ability to select the correct shade. Preclinical students' color match choices showed large variety than the other participants. Experienced participants were statistically better in color matching than the preclinical students. **Conclusion:** Although the color matching ability of dental students is strongly dependent on individual perceptual ability, clinical experience and knowledge can lead to better performance in color matching.

**OP 321 MORPHOLOGICAL, AESTHETIC AND FUNCTIONAL BALANCE OF THE PATIENT WITH DENTAL AND FACIAL ASYMMETRY**  
DANIELA ANISTOROAEI; GEORGETA ZEGAN; LOREDANA GOLOVCENCU;  
ALINA SODOR  
*Romania*

#### ORTHODONTICS

Symmetry and correspondence of dental midline represent key elements in assessing facial harmony and balance. The patients with malocclusions have more asymmetry and lack of correlation of dental midline affects the overall facial aesthetics. **Material and methods:** The aim of the study was evaluate the midlines deviation among orthodontic patients. The data from orthodontic files of 384 subjects (220 girls and 164 boys) aged between 6 and 23 years (mean age 10.11 years) who ask for orthodontic treatment were evaluated by a single examiner. For all patients was recorded the midline deviation, age, gender, socio-ecological environment origin, type of dentition, type of dento-maxillary anomalies. Chi-square tests were computed to determine correlations. **Results and discussions:** In the study group, midline deviation was recorded in 20.7% of patients (8.3% to mandible and 12% to maxillary). Midline deviation was more frequent at 12 years (29.1%). The Chi- square test showed statistically significant results between midline deviation and type of dentition ( $p = 0.001$ ) and age of patients ( $p = 0.027 < 0.05$ ); no statistically significant results between the classes of anomaly, gender and socio-ecological environment. **Conclusions:** The diagnosis of the midlines deviation should be accomplished before any orthodontic treatment. In the study group midline deviation was recorded in 20.7% of patients, the results suggesting that the phenomenon is related to dental permutation.

**OP 322 ORAL MANIFESTATIONS IN MYELODYSPLASTIC SYNDROME. REVIEW OF THE LITERATURE AND REPORT OF A CASE. PERIODONTITIS**

ATHANASIOS KARAMPASIS; ATHANASIOS POULOPOULOS;

DIMITRIOS ANDREADIS; NIKOLETA PASTELLI; EIRENE BALNTOUMI

*Greece*

**ORAL PATHOLOGY-ORAL MEDICINE**

Myelodysplastic syndromes (MDS) comprise a heterogeneous group of clonal hematopoietic stem cell disorders characterized by dysplasia, ineffective hematopoiesis leading to peripheral blood cytopenias, and a variable risk of leukemic progression. MDS is frequently overlooked and underdiagnosed. Our purpose was to describe an unusual case of MDS with initial early manifestation of recurrent oral ulceration. A 53-year-old white woman presented to our department for the management of oral ulceration located on her lower lip. Her past medical history included only gastroesophageal reflux disease. After few days the patient presented with a new episode of oral ulceration. Full blood investigations were performed which revealed pancytopenia (red blood cell count 2,81/ $\mu$ L; white blood count 1,6/ $\mu$ L; platelets 24/ $\mu$ L; hematocrit 25,4; hemoglobin 9,1g/dL). The patient immediately was hospitalized for further laboratory investigations. The findings of a bone marrow examination led to the diagnosis of MDS. Furthermore a bone marrow aspiration and biopsy revealed the presence of blast cells (12-15%). Dentists are likely to encounter both patients with MDS and patients in whom MDS should be suspected. Oral manifestations of MDS include recurrent oral ulceration, gingival hyperplasia with spontaneous gingival hemorrhage and persistent herpes labialis, which may be among the first signs and often reflect degrees of neutropenia or neutrophil dysfunction. These manifestations may be clinical indicators of MDS in otherwise healthy, undiagnosed individuals. In suspicion of possible MDS early full blood analysis and bone marrow biopsy is required.

**OP 325 INTERDISCIPLINARY MANAGEMENT OF MISALIGNED MAXILLARY ANTERIOR TEETH WITH PROSTHETIC AND PERIODONTAL TREATMENT: CASE REPORT**

YENER OKUTAN; ILKNUR TUNCER; SEMA SEZGİN HAKKI

*Turkey*

**FIXED PROSTHODONTICS**

**Background:** Gingival counturing is required to obtain predictable esthetic results for prosthetic treatment of misaligned dentition. The aim of this case report was to describe a treatment using periodontal and prosthetic techniques to restore esthetics in a patient with misaligned maxillary anterior teeth. **Case report:** The chief complaint of healthy, 36 year-old male patient's was the lack of esthetics in the maxillary anterior region, especially the maxillary left side misaligned lateral and central incisor. His other concerns were the exposed root surfaces, anterior discolored teeth, non-aesthetic gingival architecture and the missing teeth at the posterior regions. After intraoral and radiographic examinations, coronally advanced flap was performed. Three months after operation maxillary anterior teeth restored with the combination of CAD/CAM Zirconia and E.max system. Additionally, metal-ceramic restorations applied to the posterior regions. The patient's functional and esthetic expectations were successfully met with the treatment. Clinical and radiological control was made 6 months after treatment. **Conclusion:** It is difficult to obtain esthetic

outcome in some cases with misaligned teeth and gingival deformity. Interdisciplinary approach is critical to achieve a satisfactory result.

**OP 327 PROSTHETIC REHABILITATION OF DIFFERENT PATIENTS USING IMPLANT SUPPORTED OVERDENTURES RETAINED WITH BAR ATTACHMENTS**

EDA OZDERE

*Turkey*

**REMOVABLE PROSTHODONTICS**

**Background:** Bar attachments are widely used to stabilize overdentures on implants in the mandible and less in the maxilla. There is strong evidence that retention of the attachment is an important factor for a patient's satisfaction. But the cost of this treatment modality is higher than traditional dentures. **Materials and methods:** Four patients with multiple missing teeth were rehabilitated by implant supported overdentures retained with bar attachments. The clinical and laboratory processes will be presented in this clinical report. The first completely edentulous patient had two dental implants placed in the anterior part of the mandible. The second completely edentulous patient had 8 implants (4 upper and 4 lower). The third patient had partially edentulous lower and totally edentulous upper jaw with four implants. The last patient had partially edentulous lower and upper jaw with four implants. All the patients had different brands of implants and they were rehabilitated with implant supported overdentures retained with bar attachments. Traditional movable dentures and metal fused to porcelain crowns were also used to decrease the cost of the treatment. The bar attachments assessed 6 months later. **Results and Conclusion:** The rehabilitation of patients with multiple missing teeth is a complex task. Different treatment options should be presented to the patient with the time commitments and costs. The patient's expectations about the retention of the prosthesis are also important in treatment planning. Implant supported overdentures help to increase the retention of the prosthesis and improve the quality of life.

**OP 331 TRANSLUCENCY OF DIFFERENT FULL CERAMIC MATERIALS WITH DIFFERENT THICKNESS**

IPEK GULDAS; ISA YONDEM

*Turkey*

**FIXED PROSTHODONTICS**

**Purpose:** Yttrium partially stabilized polycrystalline zirconia (Y-TZP) is the material of choice for all-ceramic restorations with its excellent mechanical properties. However, the polycrystalline content causes increased opacity that changes the optical properties of the material. The **aim** of this study is to evaluate translucency of lithium disilicate glass ceramic (IPS e.max CAD), new generation full ceramic system with different zirconia contains (Vita Suprinity) and high translucency zirconia systems (Prettau Zirconia, Lava Plus). **Material and methods:** Lithium disilicate glass ceramic (IPS e.max CAD), new generation full ceramic system with different zirconia contains (Vita Suprinity) and high translucency zirconia systems (Prettau Zirconia, Lava Plus) were used in this study. Cores specimens were made in three different thickness (0.5 mm, 0.8 mm, 1 mm) with Isomet; Buehler for each ceramic systems. The translucency and color coordinates of specimens

were measured using Konica Minolta colorimeter on black and white background. Contrast ratios and translucency parameters were used to assess the translucency of all materials. For color evaluation, CIE L\*a\*b\* color coordinates were recorded. Data were analyzed using one-way ANOVA test. **Results:** According to the one-way ANOVA results, when comparing different thickness, there were statistically significant differences among groups ( $P < 0.05$ ). For any thickness, there appeared to be adequate translucency of the IPS e.max CAD and Vita Suprinity samples. There were no significant differences in Prettau Zirconia and Lava Plus groups **Conclusion:** Translucency of the high translucency zirconia systems were significantly lower than the other groups.

**OP 333 EFFECTS OF DIFFERENT BEVERAGES ON THE COLOR STABILITY OF DENTURE TEETH**

ISIL KARAOKUTAN; YENER OKUTAN

*Turkey*

**REMOVABLE PROSTHODONTICS**

**Background:** The purpose of this in vitro study was to evaluate the color stability of conventional acrylic resin, reinforced acrylic resin and porcelain teeth in different daily beverages. **Methods and materials:** Forty maxillary incisors of each brand (total=120) were divided into four groups according to staining solution as coffee, cola, tea and distilled water (as a control). Baseline color measurements were performed with a spectrophotometer. The specimens were immersed in solutions for a total of 6 days at  $37 \pm 1$  °C. This test period simulates the effects of 6 months of denture usage. According to this simulation, the baseline, 1 week, 1 month, 3 months and 6 months values for colour change of denture teeth were measured.  $\Delta E$  values were analyzed with 3-way repeated measures ANOVA. **Results:** Significant color differences were found among the teeth and staining solutions, but all of the color differences were in the clinically acceptable range ( $\Delta E < 5.5$ ). Instant coffee was found to be the most colorant agent among the solutions tested ( $p < .001$ ) and the amount of color change for each group increased proportionally with time. Porcelain denture teeth demonstrated the lowest  $\Delta E$  values for all solutions. **Conclusion:** Porcelain denture teeth were found to be more resistant to discoloration. Conventional and reinforced acrylic resin teeth were more susceptible to staining.

**OP 353 EFFECT OF EDTA WITH VARIOUS SURFACE-MODIFYING AGENTS ON THE BOND-STRENGTH OF AN EPOXY RESIN-BASED-SEALER**

MEHMET BURAK GUNESER; SEYIT BILAL OZDEMIR; DILARA ARSLAN;  
ASIYE NUR DINCER

*Turkey*

**ENDODONTOLOGY**

**Background:** The aim of this in vitro study was to evaluate the effect of the addition of various surface-modifying agents to EDTA solution on the push-out bond strength of an epoxy-based sealer to the root canal dentin. **Methods and materials:** Sixty single-rooted human mandibular premolars were decoronated and instrumented using the rotary system to size F4. The specimens were then randomly divided into four groups ( $n=15$ ) according to the irrigation with

different 17% EDTA (Wizard; RehberKimya, Istanbul, Turkey) solution combinations as follows: Group1: 17% EDTA-0.1% Triton X-100; Group2: 17% EDTA-0.1% Tween 80; Group3: 17% EDTA-0.1% benzalkonium chloride and Group4: 17% EDTA without any surface-modifying agents as a control group. The roots were irrigated with 5 mL of EDTA solutions followed by 5 mL of 5% sodium hypochlorite (Wizard; RehberKimya, Istanbul, Turkey) for 1 min. Obturation was performed with gutta-percha and AH Plus sealer (Dentsply DeTrey GmbH, Konstanz, Germany) using cold lateral compaction technique. A push-out test was used to measure the bond strength between the root canal dentin and sealer. The data were analyzed using the two-way analysis of variance and Tukey post hoc tests ( $P = 0.05$ ). **Results:** The bond strength of sealer in groups irrigated with EDTA in combination with surface-modifying-agents did not differ from that of EDTA without any agents ( $P > .05$ ). Moreover, the apical third showed the lowest mean bond strength values ( $P < .05$ ). **Conclusion:** The addition of surface-modifying agents to EDTA solution did not affect the bond strength of the epoxy resin-based sealer.

**OP 354 COMPARISON OF LATERAL CEPHALOMETRIC VALUES BETWEEN GENDERS IN A POPULATION OF AEGEAN ANATOLIA REGION**

ORHAN HAKKI KARATAS; RABIA MERVE CELIK KARATAS

*Turkey*

**ORTHODONTICS**

The aim of this study was to evaluate differences of various cephalometric measurements between genders of the orthodontic patients who apply to our department in Aegean Anatolia region 550 (296 females, 254 males) digital lateral cephalometric films were randomly selected from the pre-treatment records of patients within the age of 7-26 years applied to the Department of Orthodontics, Faculty of Dentistry, Kocatepe University were evaluated. 7 angular (SNA, SNB, ANB, SN-GoGn, FMA, Y-Axis, PP/MP), 4 linear (N-ANS, ANS-Me, N-Me, Wits appraisal) cephalometric values were used. The subjects were divided into 3 groups according to ANB angle and Wits appraisal; Class 1,2,3. The angles of perpendicular direction of the face were used in classification for growth direction; neutral; hypodivergent and hyperdivergent. Despite Skeletal Class 1 and 2 malocclusion was showed higher rate (58% and 57%) in females, Class 3 malocclusion was showed higher rate (55%) in males ( $p < 0.05$ ). The other angular values did not show statistical differences for genders. Both of genders (female 59%, male 58%) showed to neutral growth pattern. Both of N-ANS and ANS-Me is significantly higher in males ( N-ANS: mean  $50,00 \pm 4,13$  mm; ANS-Me: mean  $61,34 \pm 6,76$  mm) than females (N-ANS: mean  $49,04 \pm 3,58$  mm; ANS-Me: mean  $59,13 \pm 5,95$  mm). Also anterior face length (N-Me male mean:  $111,35 \pm 8,94$  mm; N-Me female mean:  $108,17 \pm 7,88$  mm) was determined higher in males ( $p < 0,001$ ). It was observed that most of female orthodontics patients in Aegean Anatolia region have skeletal Class 2 malocclusion and normal growth pattern. Anterior facial length was observed higher in males.

**OP 357 TREATMENT OF AN IMPACTED MANDIBULAR CANINE DUE TO DENTIGEROUS CYST : A CASE REPORT**

RABIA MERVE CELIK KARATAS; ZEHRA ILERI; ESIN DEMIR

*Turkey*

**ORTHODONTICS**

**Aim:** Dentigerous cysts are frequently associated with crown of unerupted or developing teeth and therapy requires interdisciplinary collaboration. **Material and methods:** An 11 year old male patient referred to the department of orthodontics with the chief complaint of delayed exfoliation of his primary teeth. In radiographic examination, an impacted tooth associated with possible dentigerous cyst formation was diagnosed. Intraoral examination revealed a Class II molar relationship on both sides and normal overjet and overbite in anterior region with the absence of 33 by a dentigerous cyst. The patient was treated with fixed orthodontic appliances and an obturator. **Results:** After the obtaining adequate space for the eruption of the tooth and marsupialization , spontaneously eruption of the impacted mandibular left canine was observed. Class I molar and canine relationship was maintained, ideal overbite and overjet were achieved. Smile aesthetics was improved. **Conclusion:** Dentigerous cyst will result in failure of eruption and leads to aesthetic and orthodontic problems. In the cases of delayed tooth eruption and impacted permanent teeth, appropriate diagnosis and therapeutic treatment steps should be considered.

**OP 358 ORTHODONTIC MANAGEMENT OF MAXILLARY CANINE-LATERAL INCISOR TRANSPOSITION**

RABIA MERVE CELIK KARATAS; ZEHRA ILERI

*Turkey*

**ORTHODONTICS**

**Aim:** To show the results of the orthodontic correction of a transposed impacted maxillary canine and lateral incisor. **Material and method:** The patient was a 12 year and 11 month old girl. She had skeletal and dental class I relationships. The clinical and radiographic examinations showed that the left maxillary canine was impacted due to insufficient space, and the malposition of the impacted maxillary upper left canine and maxillary upper left lateral incisor was defined as a complete transposition according to the radiograph. The patient was treated with fixed appliances in both arches. The impacted canine was erupted spontaneously though the lateral tooth space during the treatment. Following the eruption of the impacted tooth, the upper and lower dental arches were coordinated. At the end of the orthodontic treatment, the restorative treatment was performed to reach anatomic lateral and canine tooth shapes. Pre- and post- treatment study cast analysis was carried out; and lateral cephalograms, dental pantomograms and extraoral and intraoral photographs were obtained. **Results:** The maxillary impacted tooth was successfully erupted and the post treatment results showed the correction of the unaesthetic malocclusion. Facial esthetics was improved. The post treatment panoramic radiographs reflected normal structures considering the root, periodontium and surrounding tissues. **Conclusion:** Maxillary canine and lateral incisor transposition is a relatively rare anomaly, with both dental and facial esthetic implications. The esthetic outcome required greater effort to accomplish successful treatment of this unusual abnormality.



**OP 359 THE EFFECTS OF STRONTIUM RANELAT ON SUTURAL BONE FORMATION: A HISTOLOGICAL AND IMMUNOHISTOCHEMICAL STUDY**

ORHAN HAKKI KARATAS; EBUBEKIR TOY; HATICE TOY; SUMEYYE KOZACIOGLU; ABDULLAH DEMIR

*Turkey*

**ORTHODONTICS**

**Aim:** Rapid maxillary expansion is performed to correct skeletal transversal deficiency of the upper jaw, which is frequently encountered in orthodontic anomalies. Strontium ranelate (SrR) is a novel agent and has a dual action, as the anti-resorptive and bone-forming effects. The aim of this study was to evaluate the effects of systemically applied SrR on osteoblastic bone formation on midpalatal sutures of rats after the expansion using histological and immunohistochemical tests.

**Materials and method:** A total of 24 Wistar rats were randomly divided into two equal groups in this study. In both groups, 5-day expansion was applied and the rats were kept for a 7-day retention period, during which 625mg/kg/day SrR diluted with saline solution was administered orally to the experimental group. All the rats were sacrificed for histological and immunohistochemical assessments after the retention period. **Results:** According to the histological findings, the osteoblastic activity and the width of the blood vessels were found to be significantly increased in the SrR group compared to the control group ( $p<0.05$ ). Ossification was also observed to be better by staining osteonectin, osteocalcin, VEGF and TGF- $\beta$  antibodies in the experimental group ( $p<0.05$ ). In the evaluation of immunohistochemical staining performed with osteonectin, osteocalcin, VEGF and TGF- $\beta$  antibodies, significant immunoreactivity was observed in the experimental group ( $p<0.05$ ). **Conclusion:** From the results of this study, it may be concluded that SrR contributed to the osteogenesis in the expansion region by stimulating bone formation. Thus, the retention period can be shortened and the application of SrR after the expansion can reduce relapse.

**OP 361 ANTIBACTERIAL EFFICIENCY OF PHOTODYNAMIC THERAPY WITH INDOCYANINE GREEN IN ROOT CANALS INFECTED BY ENTEROCOCCUS FAECALIS**

ISMAIL OZKOCAK; HAKAN GOKTURK; UMUT SAFIYE SAY COSKUN; FATMA AYTAC

*Turkey*

**ENDODONTOLOGY**

**Introduction:** The purpose of this study was to evaluate bacterial reduction after using different irrigants, lasers and photodynamic therapy in root canals infected by E. Faecalis. **Method and materials:** Seventy human maxillary incisors were used in this study. After endodontic preparation sixty teeth were infected by 20  $\mu$ l E. Faecalis (ATCC 29212) and specimens incubated for 72 hours. Groups were formed as follows; group1: negative control, group 2: positive control, group 3: 10 ml %2 Chlorhexidine, group 4: 10 ml %5 NaOCl, group 5: diode laser, group 6: Er:YAG laser, group 7: ICG-diode laser (PDT). After disinfection procedures the received samples from root canals were placed into the blood agar and incubated at 37°C for 24 h and then the CFUs were counted. ANOVA test was used in the evaluation of datas. For Multiple Comparisons, Tamhane's T2 test was

used. **Results:** The results were considered statistically significant for  $p < 0,5$ . The highest bacterial colonization was observed in the positive control group. There was no statistically significant difference between Chlorhexidine, NaOCl and ICG- diode laser groups; bacterial colonization has been shown to lower when compared with laser groups used alone. **Conclusions:** Promising results were obtained by using photodynamic therapy with indocyanine green. This procedure can be considered as an alternative disinfection method to other endodontic irrigants in clinical use.

#### OP 368 CLOSURE OF DIASTEMAS USING CAD/CAM: CASE SERIES

KEMAL KORUCUOĞLU; CAN POYRAZ; ASLI SEÇILMIŞ

*Turkey*

#### REMOVABLE PROSTHODONTICS

Diastema is a common esthetic problem which affects patient's appearance and self-confidence. Different treatment options exist like builds up with resin composite, orthodontics, prosthodontics, and combinations of the above. The successful treatment of diastema depends on etiological factors, size of the diastema, and patient's affordability. The present case series described the use of polychromatic felsphatic laminates manufactured with Computer Aided Design and Computer Aided Manufacturing (CAD/ CAM) on 4 patients. While 3 of the patients had multiple diastemas the other patient had maxillary midline diastema. Patients with multiple diastemas had laminates on their maxillary anteriors (11, 12, 13, 21, 22, 23). The mock up technique had used for closure of interdental spaces using proximal build-ups with resin composite without bonding to show what we were trying to accomplish. The mock-up technique is advised also for delicate understanding of the required spaces. The prepared facial surface is terminated at the incisal edge nearly 0.3 mm. After cementation with Variolink, veneer restorations were evaluated at baseline and post-op 6 and 12 month. Color match, marginal discoloration, recurrent caries, contour, and marginal integrity were evaluated using the modified U.S. Public Health Service criteria. CAD/CAM is a new but promising technology. These cases are successful managements of diastema closure with CAD/CAM.

#### OP 369 FROM CLASSIC TO MODERN TO TREAT EARLY EXTERNAL POSTOPERATIVE DIGESTIVE FISTULAS

BOGDAN CIUNTU; CIPRIAN VASILUTA; ANA MARIA TROFIN; DELIA FLORINA ANDRIESI-RUSU; STEFAN OCTAVIAN GEORGESCU

*Romania*

#### INTERDISCIPLINARITY

Foreign digestive fistulas may result from certain varieties of conditions and circumstances. Care of these patients can be challenging, frustrating and ultimately satisfying. Patients with enterocutaneous fistula may present for surgeons a real challenge related to local conditions, altered anatomy, physiological and metabolic imbalances that require close monitoring and also an optimal approach regarding invasive gestures. We present a case of a patient aged 46 years, which was

admitted in our service for an external postoperative digestive fistula arising in the context of liver cirrhosis mixed decompensated of toxic etiology.

**OP 371 EFFECTS OF USING PLAQUE DISCLOSING TABLETS AT HOME ON ORAL HYGIENE IN ORTHODONTIC PATIENTS**

MEHMET ALI YAVAN; ORAL SÖKÜCÜ; DLER MOURAD; MERVE GÖYMEN;  
SERHAT ÖZDEMİR

*Turkey*

**ORTHODONTICS**

**Objectives:** The aim of this study was to investigate the effects of using plaque disclosing tablets on plaque and gingival index scores in patients wearing fixed orthodontic appliances. **Material and methods:** This study was conducted as a double blinded and randomized clinical trial. 48 patients in age range of 12-18 years, who need fixed orthodontic treatment were randomly distributed to 3 groups. In group A (n=16), the subjects were motivated by conventional oral hygiene instructions including verbal information about tooth brushing, demonstration on model and self-application by patients; patients in group B (n=17) were motivated by plaque disclosing tablets to show the location of the biofilm at chair in addition to same instructions of group A. Those in group C were (n=15) given disclosing tablets for use at home 1 times in 2 days besides same motivation techniques in group B. Periodontal parameters were recorded at each appointment during a 3-month follow-up. **Results:** The plaque index scores of group C were significantly lower ( $p < 0,05$ ) compared with group A and B after first (T2) and third months (T3), however no significant differences ( $p > 0,05$ ) were found between group A and B. Gingival status of group C didn't change significantly ( $p > 0,05$ ) during three months and statistically lower compared with group A and B. Gradual increases in mean gingival index scores in group A and B were found ( $p < 0,05$ ). **Conclusion:** Using plaque disclosure tablets at home increased efficiency of plaque removal and stability of gingival health.

**OP 372 EFFECTS OF REMOVABLE AND FIXED FUNCTIONAL THERAPIES ON UVULO-GLOSSOPHARINGEAL DIMENSIONS IN CLASS 2 MALOCCLUSION PATIENTS**

MEHMET ALI YAVAN; N.EREN İŞMAN; MERVE AYCAN KIR; MERVE GÖYMEN;  
ÖMER ALPARSLAN KIR

*Turkey*

**ORTHODONTICS**

**Objective:** The aim of this retrospective study was to compare the effects of two different functional appliances on airway dimensions, dentoalveolar changes, tongue and hyoid positions. **Material and methods:** Pre- and post-treatment lateral cephalograms of 45 adolescent class 2 patients with retrognathic mandible were obtained from archive and divided into two groups according to functional therapy. Subjects in group A (9 females, 11 males, mean age:13,5±2,8) were treated with Forsus FRD and in group B; (17 females, 8 males, mean age:12,5±3,4) functional therapy was performed with Twin Block. Skeletal, dentoalveolar, tongue, soft palate, hyoid position and upper airway parameters were measured by Dolphin software and uvulo-glossopharyngeal area measurements were performed by AutoCAD software. **Results:** Protrusion of mandible and inclination of lower incisors were significant ( $p < 0,05$ ) in twin block group therefore there was

significant increase in oropharyngeal and tongue area ( $p < 0,05$ ), hyoid position was changed statistically ( $p < 0,05$ ) but only sagittal dimension of superior airway space (SPAS) was increased significantly ( $p < 0,05$ ). However in Forsus FRD group, there was no significant change in oropharyngeal area ( $p > 0,05$ ); tongue and soft palate area increased significantly ( $p < 0,05$ ). Sagittal dimension of inferior airway space decreased and SPAS increased significantly ( $p < 0,05$ ). Hyoid position didn't change statistically ( $p > 0,05$ ) in this group. No significant differences were found in all parameters between two groups ( $p > 0,05$ ) except SNB. **Conclusion:** Uvulo-glossopharyngeal dimension changes didn't significantly vary with two different functional therapies.

**OP 375 THE USE OF FREE GINGIVAL GRAFT FOR THE MANAGEMENT OF PERI-IMPLANT KERATINIZED SOFT TISSUES**

DIMITRA DIOMATARI; EFTHALIA KOKLA; DIMITRA VAKOU;  
KALLIOPI PAPAZOGLOU; SPIRIDON SILVESTROS

*Greece*

**PERIODONTOLOGY**

**Background:** Although the importance of attached gingiva around implants is a controversial issue, many clinicians suggest the use of periodontal plastic surgery techniques to increase the width of keratinized tissues (KT). The **aim** of this presentation is to address the use of the free gingival graft, as a technique to improve peri-implant health. **Material and methods:** A literature review was performed in PubMed using the key words: FGG technique, peri-implant soft tissues, keratinized mucosa, gingival recession around implants, keratinized mucosa width. Furthermore, clinical cases will be presented managing insufficient ( $< 2\text{mm}$ ) peri-implant keratinized soft tissues by using the free gingival graft technique (FGG). **Results:** The FGG is the gold standard among the periodontal plastic surgical techniques because: (1) results in greater amount of keratinized mucosa (2) alleviates frenum/muscle pull, and (3) when performed in teeth, results could be improved over time through creeping attachment. **Conclusion:** In some clinical implant cases, soft tissue augmentation must be considered. Although the implant survival is not affected by the lack of attached gingiva, the use of soft tissue augmentation techniques may be beneficial for the health of peri-implant mucosa. Peri-implant plastic surgeries, such as FGG technique, are used to increase keratinized mucosa width (KMW), helping to restore and retain long-term peri-implant health.

**OP 377 FULMINANT EVOLUTION OF AN INTRAABDOMINAL MALIGNANT FIBROUS HISTIOCYTOMA: CASE REPORT**

ANA MARIA TROFIN; DELIA FLORINA ANDRIESI-RUSU; BOGDAN CIUNTU;  
CIPRIAN VASILUTA; CRISTIAN LUPASCU

*Romania*

**INTERDISCIPLINARITY**

Malignant fibrous histiocytoma (MFH) is a sarcoma originating from the mesenchymal tissue, affecting the soft tissues of the body, especially the extremities and retro peritoneum, with an

annual incidence of 30 cases in one million populations. We report the case of a malignant fibrous histiocytoma occupying the Medio abdominal region affecting the colon and the abdominal wall in a 59 years old male, who presented for enlargement of the abdomen associated with anorexia and pain. Imaging procedures revealed a large and relatively well defined unhomogeneous mass located in the medial and lower abdomen, with a diameter of 170 mm, with cystic-necrotic areas and compression the left ureter left hydronephrosis and colon. The surgical approach was the treatment of choice and 'en bloc' resection of the tumor with the sigmoid resection and left iliac colostomy was undertaken. Despite the surgical treatment and the immediate oncologic care, the outcome was very poor. One month evaluation showed multiple large intraabdominal tumors with the same imaging characteristics, without surgical possibilities of removal. Malignant fibrous histiocytoma is a rare neoplasm with an aggressive biological behavior. Complete surgical excision is preferred and adjuvant therapies such as radiotherapy, chemotherapy (doxorubicin and ifosfamide), and immunotherapy can be included in the treatment plan.

**OP 379** **COMPARISON OF MARGINAL MICROLEAKAGE OF COMPOSITE RESTORATIONS IN TEETH PREPARED BY BUR OR ER,Cr:YSGGLASER**  
ATHANASIOS SYNARELLIS; ELISABETH KOULAOUZIDOU; PANTELIS KOUROS;  
DIMITRIOS STRAKAS; EUGENIA KOLINIOTOU-KOUMPIA  
*Greece*

#### RESTORATIVE AND ADHESIVE DENTISTRY

**Background:** Laser irradiation has been introduced as an alternative way of cavity preparation to overcome disadvantages of conventional bur cutting instruments. The purpose of this study was to compare cavity marginal microleakage of composite cervical restorations on teeth after preparation by Er,Cr:YSGG laser or carbide bur. **Materials and methods:** Identically sized class V cavities were prepared on 60 bovine incisors and divided into 3 groups: G1: laser cavity preparation and diamond bur beveling, G2: high-speed carbide bur cavity preparation and diamond bur beveling, G3: laser cavity preparation and laser ablation of enamel margins. All cavities were restored with the same adhesive/ resin composite system. After thermocycling, the teeth apices were covered with sticky wax and nail varnish, immersed in 2% methylene blue solution for 24h and sectioned longitudinally. Digital photographs of each specimen were taken under stereomicroscope and two examiners blinded to the groups graded microleakage on a 0- to 3-grade scale. Mean scores were calculated for each specimen. **Results:** Mann Whitney test showed statistically significant differences between occlusal and cervical margins for G1 ( $p < 0.05$ ). Occlusal margin's microleakage was significantly higher in G3 than in G1 and G2, according to Dunn's test. In parallel, Dunn's test indicated significantly lower cervical microleakage in G2 than G1 and G3 ( $p < 0.05$ ). **Conclusions:** The conventional method of cavity preparation with a carbide bur performed better in terms of microleakage comparing to laser preparation at both margins. The enamel margin's beveling with diamond bur performed better than laser ablation in terms of microleakage.

**OP 383 HEAT TRANSFER TO THE IMPLANT-BONE INTERFACE DURING REMOVAL OF METAL COPINGS CEMENTED ONTO TITANIUM ABUTMENTS**

UMUT CAKAN; MURAT CAKAN; CAGRI DELILBASI

*Turkey*

**ORAL IMPLANTOLOGY**

**Background:** The cutting process to access an abutment screw channel or sectioning the metal base of the restoration may generate frictional heat. The purpose of this investigation was to measure the temperature rise due to heat transferred to the implant-bone interface when the abutment screw channel is accessed or a metal ceramic crown is sectioned buccal either with diamond or tungsten carbide bur, using air-rotor, with or without irrigation. **Materials and methods:** K-type thermocouples were entwisted around the cervical, middle and apical parts of titanium plasma sprayed bone level implant. Eight copings in 1.0 mm thickness were milled from Co-Cr block and cemented onto prefabricated straight titanium abutment with noneugenol temporary cement. Eight abutment screw accessing and crown sectioning modalities using diamond or tungsten carbide bur, with or without water irrigation were tested. The temperature changes were recorded via thermocouples connected to a monitoring system for each test modality over a time period of 1 minute. **Results:** The highest temperature of 40.6°C was observed at the cervical part of the implant during coping sectioning with diamond bur and without water irrigation. The lowest temperature measured was 34.9°C for screw accessing with tungsten carbide bur with water irrigation. **Conclusion:** Both crown removal methods either with diamond or tungsten carbide burs resulted in an increase in temperature at the implant-bone interface. However, this temperature change did not exceed 47°C, the potentially damaging threshold for bone reported in the literature.

**OP 384 DENTAL STUDENTS' WELLBEING CHANGES OVER THE FIRST SEMESTER OF THE ACADEMIC YEAR**

CRISTINA TEODORA PREOTEASA; ELENA PREOTEASA

*Romania*

**INTERDISCIPLINARITY**

**Introduction:** Wellbeing influences work performance and generally the ability to achieve one's full potential. The aim of the study was to assess the psychological wellbeing of the dental students over the first semester of the academic year. **Methods:** A cohort of 2nd year dental students from Carol Davila University of Medicine and Pharmacy, Bucharest, was analyzed. Data was collected by the usage of WHO-Five Wellbeing Index (WHO-5), in two moments respectively during the first two weeks of the semester and in the last week of the semester evaluation period. **Results:** The convenience sample included 76 dental students, from which 55 were females, with mean age of 20 years. WHO-5 scores were higher in the beginning of the first semester (median=68) compared to the winter examination period (median=56), the difference being statistically significant ( $p=0,009$ ). In the beginning of the semester only 17 (22,4%) students were recommended to be further investigated in order to diagnose depression, compared to 35 (46,1%) that were identified during winter examination period. Considering the cut off value of 10, considered significant for a change in wellbeing, 35 (46%) students registered a poorer wellbeing state, 23 (30%) lack a significant change of wellbeing and 18 (24%) a better wellbeing state in the winter

examination period. **Conclusions:** Dental students' wellbeing is poorer in the semester examination period, therefore adequate methods to help students cope with academic stress should be implemented. **Acknowledgement:** This research was supported by a postdoctoral fellowship, part of the project with the ID of POSDRU/159/1.5/S/133377.

**OP 387 ADVANCES OF THE ER.YAG LASER SURGERY OF LABIAL FRENA**

MARINA KACARSKA; MAJA GJOROVSKA  
FYROM

**ORAL SURGERY AND ORAL MAXILLOFACIAL SURGERY**

**Background:** The Er:YAG laser surgery of low and overactive labial frena has inherent characteristics of minimal bleeding, a reduced need for anesthesia and excellent healing. **Aim:** To demonstrate the advances of the Er:YAG laser surgery of labial frena. **Materials and methods:** Patients who were referred to the University department of oral surgery for labial frenectomies for orthodontic reasons, were included in this study. The clinical examination and evaluation revealed aberrant labial frena (class III and IV). The laser surgery was performed with Er:YAG laser (Fotona Fidelis III) and non contact hand piece R02. Special consideration was attended to the laser parameters, use of anesthesia, the patients' compliance, quality of the hemostasis and the postoperative outcome. **Results:** Small amounts (0,2-0,3ml) of infiltrative terminal anesthesia was used in all cases. The bleeding was scarce and sutures weren't necessary. The postoperative healing periods were uneventful, pain-free. The fibrin coating was visible on the following day. The healing was completed in three weeks period with minimized scarring. The results were maintained and re-surgeries weren't necessary. **Conclusion:** Er:YAG laser surgery of the labial frena were minimally invasive procedures with predictable outcome, and may be considered as a first choice procedure, especially in pediatric patients.

**OP 392 MALPRACTICE IN SURGICAL ORTHODONTICS**

PAVLINA DIMITRIADI; ANASTASIOS VOSSOS; PHOEBUS DALAMPIRAS;  
BARDIS DIMITRIOS; STYLIANOS DALAMPIRAS  
Greece

**ORAL SURGERY AND ORAL MAXILLOFACIAL SURGERY**

**Background:** Surgical assisting orthodontic procedure is routine practice in clinic of oral and maxillofacial surgeons. The orthodontist instructs the oral surgeon some surgical operations, which aim to promote the orthodontic process according to the treatment plan that he concluded. These operations are usually exposures of impacted teeth, frenulectomies and / or other surgical treatments of orthognathic surgery, which exceed the limits of local anesthesia. Every surgical operation should be dictated by the strict rules of operative procedure (e.g. sterility), it should also be performed by an oral and maxillofacial surgeon at a clinic that has the necessary surgical and mechanical equipment. Any deviation from these rules may lead to failure with unpredictable results not only for the well-being of the patient but also for the progress of orthodontic planning. **Material and methods:** A case of a female adolescent with two impacted maxillary canines, who was operated by a non-specialist and he caused iatrogenic damage to the patient. The young patient was referred to the local hospital with a postoperative bleeding and had to be hospitalized for a

week. Unfortunately, the performed operation was far from the rules and protocols of intraoral surgery and the results were disastrous. The patient needs surgical reconstruction after the malpractice. **Conclusion:** The aim of this presentation is to stress the importance of operating and acting according to the principals of oral and maxillofacial surgery in every case even in minor operations. Diagnosis, treatment planning and postoperative management are also required.

**OP 394 USAGE OF DIODE LASER IN DENTİSTRY : CASE REPORT SERIES**

KEMAL KORUCUOĞLU; CAGLAR KORCUK; MEHMET İŞIKER; ASLI SEÇILMIŞ

*Turkey*

**LASERS**

Lasers have been used for many years in dentistry. Suitable wavelengths for dental use are between 810 and 980 nm for diode laser. The advantages of diode laser application are that it provides relatively bloodless surgical and post-surgical courses with minimal swelling and scarring and successful at disinfection of the root canals. Diode laser in dentistry is used disinfection of root canal, endodontics, close curettage, soft tissue treatment, root planing, dentin hypersensitivity and bleaching. In this case report, four patients were treated by 810 nm diode laser including frenectomy, gingivectomy, epulis removal and laser supported endodontic treatment. A patient unsatisfied with the teeth color has been applied 980 nm diode laser for bleaching. The patients treated surgically were called for control in the day after the surgery, for the first and second week. Even at the day of the surgery there was neither pain nor swelling. Control visits for laser supported endodontic treatment were on the first, second and sixth month. After 6 month periapical lesion was seen to shrink. Diode laser applications were well tolerated by all patients. More studies need to be performed in order to precisely clear up the effects of the lasers and its use in dentistry.

**OP 404 TNFA -308G/A POLYMORPHISM AND SERUM CONCENTRATIONS IN PERIODONTITIS AND DIABETES**

ANA PUCAR; SANJA MATIC PETROVIC; JOVANA KUZMANOVIC;  
NADJA NIKOLIC; BOSKO TOLJIC

*Serbia*

**PERIODONTOLOGY**

The relationship between periodontitis and diabetes is bidirectional. Tumor necrosis factor alpha (TNF $\alpha$ ) is key mediator of periodontal inflammation and implicated in insulin resistance mechanisms. Single nucleotide polymorphism (SNP) at position -308G/A, affects transcription of TNF $\alpha$  gene. This study was aimed to determine the distribution of -G308A TNF $\alpha$  genotypes and TNFR $\alpha$  serum concentrations in patients with type 2 diabetes (T2D) and chronic periodontitis (CP), nondiabetics with CP and healthy controls. This study included 167 patients divided into three groups: T2D+CP (group A, n=65), nondiabetics+CP (Group B, n=50) and healthy control (group C, n=52). T2D was diagnosed according to 2013 WHO criteria and periodontitis was diagnosed according to 1999 International Workshop for Classification of Periodontal Diseases and Conditions. -G308A TNF $\alpha$  was genotyped using PCR/RFLP. TNF  $\alpha$  level were measured by ELISA. There was no statistically significant difference in TNFR $\alpha$  levels among groups. There was significant correlation between Periodontal Epithelial Surface Area (PESA) and Periodontal Inflamed Surface



Area (PISA) and TNFR $\alpha$  serum concentration in group A (PESA:  $r=0,829$ ,  $p=0.000$ ; PISA:  $r=0,559$ ,  $p=0,030$ ). There was no association between genotypes and TNFR $\alpha$  serum concentration in any of groups (Kruskal-Wallis,  $p>0,05$ ). Genotypes frequency did not differ between groups ( $\chi^2=0,534$ ). Our results demonstrated that in T2D group, the higher concentration of TNFR $\alpha$  was associated with higher parameters of impact of periodontal inflammation on health-PESA and PISA. Although A allele (-308 G>A) has shown a somewhat lower risk of occurrence of the disease difference did not reach statistical significance, most likely due to low number of subjects.

**OP 406 SCHNEIDERIAN MEMBRANE PERFORATIONS: THE MOST COMMON COMPLICATION OF MAXILLARY SINUS FLOOR ELEVATION**

KALLIOPI PAPAZOGLOU; DIMITRA DIOMATARI; THODORIS GKOMOZIAS;  
EFTHALIA KOKLA; SPIRIDON SILVESTROS

*Greece*

**ORAL SURGERY AND ORAL MAXILLOFACIAL SURGERY**

**Background:** Sinus floor elevation for implant placement is an established and predictable procedure for the augmentation of bone volume in the posterior maxilla. Intra and postoperative complications may occur and the most common is the perforation of Schneiderian membrane, usually resulting from bone cutting during lateral window osteotomy. Numerous methods have been suggested for managing this complication. The aim of this presentation is to address the most frequent causes of membrane perforation and the most effective treatment solution. **Methods and materials:** A review of the literature was performed, as far as Schneiderian membrane perforations are concerned. The prevalence of this complication, risk factors, classification, management and their connection with the survival of implants will be discussed. Furthermore, two clinical cases of maxillary sinus membrane perforations along with treatment will be presented in order to address effective methods to deal with this complication during sinus floor elevation. **Results:** The incidence of sinus membrane perforation is 10-33%. Anatomic factors and surgical manipulations may lead to perforations. Several techniques have been proposed to manage this complication. The size of the defect is crucial for the selection of the surgical technique. **Conclusions:** Maxillary sinus membrane perforation is the most prevalent intra-operative complication of the sinus lift technique. All the evidence-based reviews suggest the placement of a resorbable collagen membrane and conclude that sinus membrane perforations can usually be managed effectively and predictably.

**OP 414 ORAL LICHENOID LESIONS RELATED TO CONTACT WITH DENTAL AMALGAM**

KONSTANTINIA KARAOULANI; DIMITRIOS DIONYSOPOULOS;  
EVANGELOS PARCHARIDIS

*Greece*

**RESTORATIVE AND ADHESIVE DENTISTRY**

Human oral mucosa is subjected to many noxious stimuli. One of these substances is dental amalgam which contains mercury, silver, tin, copper, zinc and other trace metals. Components of amalgam may, in rare instances, cause local side effects or allergic reactions referred to as oral lichenoid lesions. Mercury salts that accumulate in healthy and damaged oral mucosa will cause

this hypersensitivity reaction in only a susceptible minority of the population with resulting reticular white patches, papules, plaques, erosion or ulceration, similar to that found in oral lichen planus. Oral lichenoid lesions resemble those of oral lichen planus, and it is therefore necessary to exclude likely lichenoid lesions when making a diagnosis of oral lichen planus. Both oral lichen planus and oral lichenoid lesions can be considered potentially malignant and is important for subsequent management to be able to accurately diagnose each condition. It is not possible to confirm the diagnosis of oral lichenoid lesions through histology, due to the difficulty in differentiating oral lichen planus from oral lichenoid lesions from the histological viewpoint. Histopathological study is not always necessary except when their clinical presentation is atypical in order to exclude the existence of malignancy. Currently, the use of epicutaneous patch test to detect sensitivity to specific substances in patients suspected of suffering contact allergy is controversial. Treatment of oral lichenoid lesions related to contact consists of the removal, replacement or recovering of fillings in direct physical contact with mucosa lesions, that are suspected of playing a causal role.

**OP 415 THE RELATIONSHIP WITH DENTAL TISSUE OF TRACE ELEMENTS**  
ÇİHAN ÖZ; MEHMET SINAN DOĞAN; SEDAT GUVEN; ZEKI ARSLANOĞLU;  
MEHMET UNAL  
*Turkey*

#### PREVENTIVE DENTISTRY

All organs in our body, including teeth, occurred from organic and inorganic elements. Organic elements are generally animal origin and they act as a structural member in the body. Some of the inorganic elements locate in very small amounts in the body and they are called trace elements. They take roles in the synthesis of hormones and enzymes. They also locate in the content. Trace elements are important elements for development, growth and physiology of organism. But these elements are needed in small amounts. Trace elements take complex and important role in human and animal metabolism. Trace elements are found different densities in different layers of the enamel. Trace elements may cause changes in the structure of dental tissue. Trace elements may create resistance or predisposition to caries formation in enamel and dentin. Proving of the relationship between a single trace element with dental caries is difficult. Therefore, many studies should be made on this subject. It is thought that some of trace elements may create resistance to tooth decay, some of them are ineffective and some of them may create predisposition to tooth decay.

**OP 416 GUMMY SMILE: DIFFERENTIAL DIAGNOSIS AND MANAGEMENT**  
BRUNO NIKOLOVSKI; ANA MINOVSKA; DANICA POPOVIC-MONEVSKA;  
MIRJANA POPOVSKA; VERA RADOJKOVA-NIKOLOVSKA  
*FYROM*

#### PERIODONTOLOGY

Smile is the most complex and sophisticated facial expression, formed from synergic action of facial expression muscles. Excessive gingival display, commonly referred to as “gummy/gingival smile” is seen usually when more than 3 mm of the gingiva is visible. Gummy smile can be due to

incomplete passive eruption, maxillary protrusion, hyperactive muscle of lips, short lip, gingival enlargement, etc. The form of the lips and the position of lips during speech and smiling can be changed by the dentist, who can modify/control the form of the teeth, interdental papilla, and position of the gingival margin and incisal edges of the teeth. Esthetic dentistry should follow the concept and treatment protocol which can provide a simple, comprehensive, patient friendly and minimally invasive treatment approach with the emphasis on psychology, health, function, and esthetics of the patient. An interdisciplinary approach is needed for management of gummy smiles to achieve stable results.

**OP 418 CLINICAL DIAGNOSES BASED ON THE RDC/TMD AND DENTITION-RELATED ASPECTS IN TEMPOROMANDIBULAR DISORDERS AMONG DENTAL STUDENTS**

IRENA MLADENović; SLOBODAN DODIĆ; MIHAEL STANOJEVIĆ; RUŽICA KOZOMARA

*Bosnia and Herzegovina*

**INTERDISCIPLINARITY**

**Introduction:** The etiology of temporomandibular disorders (TMD) is multifactorial, with occlusal, craniofacial, psychological, genetic factors, trauma, age or gender as risk or contributing factors. Introduction of the Research Diagnostic Criteria for TMD (RDC/TMD) was aimed to standardize clinical protocols for TMD assessment and decrease variability of results between the studies. **Aim:** To investigate the presence of TMD according to the RDC/TMD, and their relation to gender and occlusal factors among dental students. **Materials and methods:** One hundred and fifty students of dentistry (mean age 24.5 years) underwent physical evaluation by RDC/TMD protocol. According to presence or absence of RDC/TMD diagnosis, they were divided into the TMD group (N=68) and the Control group (N=82). In both groups occlusal analysis was performed according to Helkimo's occlusal index. Descriptive and bivariate statistics were computed and the P value was set at .05. **Results:** Myofascial pain, disc displacement and other joint disorders were observed in 25.0%, 48.5% and 32.4% of TMD patients, respectively. Prevalence of females was over twice as high in the TMD group compared with the controls (P<0.05). Lower overbite values were observed among patients with joint disorders (P<0.05). **Conclusion:** Dental students exhibited high prevalence of TMD, with disc displacement as the most prominent subtype. While presence of TMD in general was related to female gender, decreased overbite could be related to joint disorders. Other variables that might also play a role should be investigated.

**OP 422 ACCURATE ENDODONTIC DIAGNOSIS USING CONE BEAM COMPUTING TOMOGRAPHY (CBCT)**

PAULA PERLEA; CRISTINA CORALIA NISTOR; ILINCA FISER

*Romania*

**ENDODONTOLOGY**

**Introduction:** Accurate endodontic diagnosis is influenced in a decisive way by the information provided through imagistic means. The cone beam computing tomography (CBCT) is essential for establishing or confirming the diagnosis in difficult cases. The founding aids the

treatment planning decision and the management of each clinical case. The aim of this study is to show the prevalence of mandatory use of the CBCT when establishing a precise diagnostic. **Materials and methods:** Over a period of 6 months, 216 patients were referred for endodontic treatment in our clinic. For a precise diagnosis, comprehensive clinical and conventional radiological investigations were made. When the diagnosis was uncertain, the subjects were referred to CBCT-scanning for additional imagistic information. **Results:** Out of the 216 patients a number of 19 were advised to get a CBCT for accurate diagnosis. In 8,79 % of the cases CBCT aided to formulate the correct diagnosis for better management of the treatment planning. **Conclusions:** Real size of internal root resorptions, full extent of external cervical resorptions, the localization of separated instruments, identification of missed canals, perforations of the pulp chamber floor and root canal perforations, sinus pathology, loss of bone osseous plates are situations in which small field of view (FOV) CBCT is justified. The focused field CBCT is the state of the art for endodontic diagnosis because of the higher resolution, less radiation exposure, less time consuming and good focus. Additional information is enhancing the management of the treatment.

**OP 424 CEMENT-RETAINED VERSUS SCREW-RETAINED IMPLANT RESTORATIONS**

IUSTIN OLARIU; COSMIN SINESCU; LAVINIA MEDA NEGRUTIU; LIVIU GAVRILA;  
ROXANA RADU

*Romania*

**FIXED PROSTHODONTICS**

**Purpose:** This paper wants to emphasize that screw-retained prostheses present advantages compared to cement-retained prostheses. **Methods:** For a number of 12 patients implant restorations were made in the VivasDent Implantology Excellence Clinique in Arad. The group of patients was divided into 2 subgroups, each of 6 patients. For the first subgroup the restorations were cement-retained and for the second subgroup the restorations were screw-retained. **Results:** For the first subgroup after three years we observed the following: To a number of 3 patients the restorations were partially or totally decemented, in another case one abutment unscrewed, leading to ablation of prosthesis and so configuring a new one. For the remaining two patients no problems were reported. For the 6 patients of the second subgroup we noted: One prosthesis unscrewed, for another case the resin covering the screw hole fell out. For the other four patients no problems were reported. **Conclusions:** Given the statistics results we found that screw-retained restorations have a longer duration and stability. I consider it appropriate to present to the patient the advantages and disadvantages of each of the two types of aggregation in the early steps of the treatment plan.

**OP 426 EFFECTIVENESS AND CONCERNS ACCORDING THE USE OF NON-STEROIDAL ANTI-INFLAMMATORY DRUGS (NSAIDS) IN PERIODONTOLOGY**

ILIAS LIAPIS; IONUT LUCHIAN; SILVIA MARTU

*Romania*

**PERIODONTOLOGY**

**Introduction:** The feeling of pain is inherent in any surgery in a different degree. According to the literature, patients quantify the intensity of pain following periodontal and implant surgery by rating around 50 to 100 in the visual analogue scale of pain (VAS scale). The first

position to relieve the patient from the holding postoperative pain is held by the NSAIDs. The NSAIDs are a group of drugs, with comprising subs all of which exhibit analgesic, anti-inflammatory and antipyretic activity. The mode of action is based on inhibition of the production of the enzyme cyclooxygenase, which has two isoforms. The former is secreted continuously by the body and the concentration is relatively stable, and the COX-2 produced as part of the inflammatory response of the body and plays a key role in the transduction of pain and inflammation escalation. The " first generation" NSAIDs, which are mainly represented by ibuprofen are nonselective inhibitors of cyclooxygenase, whereas the " new generation" of these drugs consists of selective inhibitors of COX-2. **Materials and methods:** For this purpose, selected and analyzed survey data from 1995 to today and under these data protocols was designed a practical use of NSAIDs for pain relief, minimizing the background depending on the individual patient's risk of adverse complications the general health of the patient and the successful implant osseointegration. **Conclusion:** A three-day postoperative protocol treatment with NSAIDs is proposed, which according to the literature seems to be sufficient to control the pain intensity.

#### OP 432 RETENTION FORCE OF SYNCONE CAPS MADE OF GOLD

MIHAEL STANOJEVIC; IRENA MLADENOVIC; IVICA STANCIC

*Bosnia and Herzegovina*

#### REMOVABLE PROSTHODONTICS

**Introduction:** SynCone system is a double conical crown system fixed on implants. Until now widely in use have been cones whit 4° i 6°. Recently, on the demand from practitioners, it has been introduced a cone whit 5°. Aim of this study was to determine the retention force on double conical crown whit 5°, in the Ankylos SynCone concept, at the beginning of the use, during and after 10,000 cycles. **Material and method:** In this study we have used a SynCone conical abutment made of titan whit 5° angle and 1.5 mm gingival height, inserted on the implant, as the iner part of the conical pair. For the outer part (SynCone Cap) of the conical pair we have used a: 1. Prefabricate SynCone cap made of gold 2. Casted cap made of gold. For this study we have used Kausimulator CS-4.8 (SD MECHATRONIC; Germany) for cycles. The conical pairs have been submitted to 10.000 separation cycles. We have measured the force on the cycles no1, no 120 and 10000. **Results:** We have found that there is a difference in the first group between F1 and F10000 ( $p < 0.05$ ) and between F120 and F10000 ( $p < 0.05$ ). In the second group we have found no statistical relevant difference.

#### OP 433 BOND STRENGTH OF AN EPOXY-BASED SEALER AFTER SODIUM

HYPOCHLORITE IRRIGATION WITH OR WITHOUT SURFACE-MODIFYING AGENTS

MEHMET BURAK GÜNEŞER; GAMZE ER; DILARA ARSLAN; ASIYE NUR DINCER

*Turkey*

#### ENDODONTOLOGY

**Background:** The purpose of this in vitro study was to evaluate the effect of sodium hypochlorite (NaOCl) irrigation with or without surface-modifying agents on the bond-strength of an epoxy-based sealer to the root canal dentin. **Methods and materials:** Sixty decoronated single-rooted human mandibular premolars were instrumented using the rotary system to size F4. After

instrumentation, the roots were rinsed with 5 ml of 17% EDTA (Wizard, RehberKimya, Istanbul, Turkey) for 1 min and then randomly divided into four groups according to the irrigation with 5 ml of 5% sodium hypochlorite (Wizard, RehberKimya, Istanbul, Turkey) with or without surface-modifying agents: Group1: 5% NaOCl-0.1% Triton X-100; Group2: 5% NaOCl-0.1% Tween 80; Group3: 5% NaOCl-0.1% benzalkonium chloride and 5% NaOCl without any agents as a control group. Roots were obturated with gutta-percha and AH Plus sealer (Dentsply DeTrey GmbH, Konstanz, Germany) using cold lateral compaction technique. A push-out test was used to measure the bond strength between the root canal dentin and sealer. The data were analyzed using the two-way analysis of variance and Tukey post-hoc tests ( $P = 0.05$ ). **Results:** Group1 demonstrated the highest mean bond-strength values in all root thirds amongst the groups ( $P < .05$ ). However, the bond strength of sealer in group2 and group3 did not differ from the control group ( $P > .05$ ). Additionally, the bond strength values mostly decreased in the coronapical direction for all groups ( $P < .05$ ). **Conclusion:** The addition of Triton X-100 to NaOCl solution improved the bond strength of the epoxy resin-based sealer.

#### OP 435 LICHEN PLANUS: A CASE REPORT

BUKET OZKAYA; SEDA SEVINÇ ÖZBERK; HASAN GUNDOGAR;  
CAGLAR KORCUK; KAMILE ERCIYAS

*Turkey*

#### ORAL PATHOLOGY-ORAL MEDICINE

Lichen planus (LP) is frequent dermatoses that observed between mostly 40-70 years of age, effected women more than men, skin and mucous membranes were effected. Although LP's etiology is unclear, most acceptable pathological mechanism theory is autoimmune reaction against antigens in the host epithelium and T lymphocytes are the major determinant cell thought to be involved in the formation of lichen planus. A 33-year-old female patient who had reticular lesion at inner left and right oral mucosa referred our clinic from department of dermatology. Major complaints were burning feel and pain at the area of the lesion when she eats something sour or hot. Incisional biopsy had done to the region with some healthy tissue and specimen had put in a formaldehyde solution and sent to the pathology department with pre-diagnosis of oral lichen planus. Histopathological examination was showed that focal keratotic area, acanthotic granular layer of ephitelium, and squamous epithelium showing subepidermal separation. There was lymphocytic infiltrates in the style of the band under the epithelium. When all the information about the patient put together, patient referred to dermatology department with the diagnosis of oral lichen planus. Dermatology department prescribed a topical corticosteroid to the patient. Oral Lichen Planus effects %0.5-2 of the population and is one of the more common oral mucosal diseases. Biopsy is required for definitive diagnosis. Dentists should be careful because of the first signs of this type of dermatoses is often seen in the oral mucosa.

**OP 436 USE OF EPITHELIAL GRAFTS FOR ACHIEVING AESTHETIC CONTOUR IN IMPLANT-PROSTHETIC**

LUAN MAVRIQI; ILMA ROBO; EGRESA BACA; ANILA VJESHTA

*Albania*

**PERIODONTOLOGY**

**Purpose:** This clinical case shows the importance of using of epithelial grafts for the increasing of gingival contour of mucosa, for achieving a much more satisfactory aesthetically in implant-prosthetic. **Materials and methods:** Patient E.A. appeared in the clinic after 3 months that had performed a surgical intervention, for placing an implant in area of 14. The problem that worried was the presence of a concave shape along modeling the implant. Normal radiographic assessment showed the presence of strong tissue, whereas in clinical evaluation highlighted a dilution of buccal gingival layer to the area of the implant 14. It was suggested adding the epithelial grafts to compensate for concavity in the area. In palatine side took a horizontal incision and opened a mucosal flap, with two incisions perpendicular to the first incision, up to the bone, took the outer with epithelial tissue raspator redistributed to these incision. On the buccal side were held two parallel incisions, took the outer with the sharp instrument past the instrument beyond the distal side, forming a tunnel. **Results:** 10 days after the patient was presented for the sutures removed, the area was recovered and in healing process. In periodic checks after 3, 6, 12 months, gingival mucosa continue to show a very a good condition. **Conclusions:** Root coverage around dental implants depends on the presence of bone quantity of which is based on the soft tissues. In this case the procedure of placing the epithelial grafts confirmed a very satisfactory aesthetic result.

**OP 438 THE EFFECT OF VARIOUS RETROCAVITY PREPARATION TECHNIQUES AND RETROFILLING WITH BIODENTINE ON APICAL MICROLEAKAGE**

DILARA ARSLAN; FATMA KAPLAN; MEHMET BURAK GUNESER;

ASLIHAN USUMEZ

*Turkey*

**ENDODONTOLOGY**

**Background:** The aim of this study was to compare the apical microleakage of root-end cavities prepared by Er:YAG (400 mJ, 10 Hz) or Nd:YAG (150 mJ, 10 Hz) laser and the effect of Biodentine by using dye penetration method. **Methods and materials:** Sixty-four extracted and then decoronated single-rooted human teeth were prepared using ProTaper® and obturated by lateral condensation technique. The 3-mm of 90° apicoectomy was performed by low-speed diamond burs. The roots were randomly divided into eight groups (n=8) as follows; Group1: Only apicoectomy without a cavity preparation (CP); Group2: Nd:YAG laser after apicoectomy without a CP; Group: CP with bur; Group4: CP/bur and filled with Biodentine; Group5: CP/bur+Nd:YAG irradiation+Biodentine; Group6: CP with Er:YAG; Group7: CP/Er:YAG+Biodentine; Group8: CP/Er:YAG+Nd:YAG irradiation+Biodentine. The root surfaces were coated with a double layer of nail varnish except the retrograde-filled surfaces and roots were immersed in Indian-ink for 15 days. Dye penetration level was assessed with clearing technique. Data were statistically analyzed by using Kruskal-Wallis and Mann Whitney U test. **Results:** Retrofilling with Biodentine groups

showed the lowest microleakage ( $p < 0.05$ ). There was no significant difference apical leakage between the roots-filled Biodentine groups ( $p > 0.05$ ). However; there were statistical significant differences between apicoectomy and apicoectomy+Nd:YAG laser group ( $p < 0.05$ ). **Conclusion:** Within the limitations of this in vitro study, it can be concluded that retro-filling with Biodentine prevented the apical microleakage. In addition, the treatment of apical surfaces with Nd:YAG laser without a retro-preparation decreases the microleakage in comparison with only apicoectomy.

**OP 439 FIBRIN RICH PLASMA IN THE TREATMENT OF MEDICATION-RELATED OSTEONECROSIS OF THE JAW**

MIHAI BUCUR; CRISTIAN VLĂDAN; TIBERIU NIȚĂ; ALEXANDRU BUCUR

*Romania*

**ORAL SURGERY AND ORAL MAXILLOFACIAL SURGERY**

Medication-related osteonecrosis of the jaw (MRONJ) is an adverse drug reaction consisting of progressive bone destruction in the maxillofacial region of patients under current or previous treatment with antiresorptive and antiangiogenic medications. The most adequate therapeutic procedure is far from being standardized. In our study, we considered a cohort of patients with MRONJ with surgical therapy with fibrin rich plasma (PRF) to evaluate its therapeutic effect in promoting bone healing. Good results showed by PRF in improving wound healing give away to case-control randomized studies that could give definitive evidence of its effectiveness.

**OP 441 SECOND GENERATION PLATELET CONCENTRATE USE IN MAXILLOFACIAL SURGERY**

MIHAI BUCUR; CRISTIAN VLĂDAN; COSMIN TOTAN; OCTAVIAN DINCĂ

*Romania*

**ORAL SURGERY AND ORAL MAXILLOFACIAL SURGERY**

One of the great challenges of clinical research has been the development of bioactive surgical additives, which help to regulate inflammation and increase the speed of healing process. In this study we are looking at the evolution of the second generation platelet concentrate and its uses in oral and maxillofacial surgery.

**OP 442 MANDIBLE RECONSTRUCTION AFTER SEGMENTAL RESECTION AT BRONJ PATIENTS**

ALEXANDRU BUCUR; TIBERIU NIȚĂ; CRISTIAN VLĂDAN; COSMIN TOTAN; OCTAVIAN DINCĂ

*Romania*

**ORAL SURGERY AND ORAL MAXILLOFACIAL SURGERY**

The purpose of this study is to determine the indications for the different types of mandible reconstruction in BRONJ patients and evaluate the functional and aesthetical results of the method. Good aesthetical and functional results can be achieved.



**OP 446 THE IN VITRO STUDY OF THE CITOTOXICITY OF ORTHODONTIC ELASTOMERIC CHAINS AND LIGATURES**

ALINA SODOR; DANIELA ANISTOROAEI; LOREDANA GOLOVCENCU;  
TUDOR PETREUS; VALENTINA DOROBAT

Romania

**ORTHODONTICS**

**Introduction:** Modern orthodontics uses a wide range of materials that are continuously improved in order to achieve the best results with less side effects. Elastomeric ligatures and chains have an almost universal acceptance among the orthodontists but despite their great popularity there are concerns regarding their biocompatibility. **Purpose:** The purpose of this study was to assess the in vitro biocompatibility of several type of elastomeric chains and ligatures. **Material and methods:** The study was developed on normal human fibroblasts. Elastomeric ligatures of different colours and from different producers and elastomeric chain (Ortho Classic) were selected to be tested. The elastomeric ligatures were divided in three groups (according to their manufacturer) named C1 (Ortho Classic), C2 (Ortho Classic) and C3 (GAC). As positive control we used dental copper amalgam. As negative control we used the pure cell culture. After 3 and respective 6 days the samples were analysed by direct method and microscopic analysis with a contrast phase microscope Nikon Eclipse TE300. **Results:** The elastic chain determined important morphologic changes. The U1 material showed a relative biocompatibility. The U2 material exhibited a good biocompatibility. The U3 material displayed a relative compatibility at 3 days, but a high toxic character at 6 days. **Conclusions:** Elastomeric ligatures and chains may determine adverse reactions enhanced by the time of use and composition of materials. Further studies are necessary to assess the component that causes adverse reaction and weather the colorants may enhance the biotoxicity.

**OP 448 EVALUATION OF ENDODONTICALLY TREATED TEETH RESTORED WITH INTERNAL AND EXTERNAL FERRULE: A CLINICAL STUDY**

SASHO JOVANSKI

FYROM

**FIXED PROSTHODONTICS**

**Statement of problem:** The application of metal-free posts and cores for restoration of endodontically treated teeth are focus of interest in esthetic dentistry. Zirconia was introduced to dentistry because of its good mechanical and chemical properties. **Purpose:** The purpose of this clinical study was to evaluate internal and external ferrule on the clinical behavior of endodontically treated teeth restored with zirconia posts with three retentive rings, upgraded with composite material and press crowns. **Material and methods:** In this clinical study, different patients are presented with maxillary central and second incisors. Treatment included all ceramic crowns supported by zirconia ceramic posts, which have retentive rings in the coronal part, and core buildup. **Results:** This clinical study presents different restorative criteria for the aesthetic placement and build up of post and core materials, as well as the preservation of maximum coronal and root structure. The high flexural strength values, however, is speculated to contribute to increased level of root fracture. Many in vitro studies about zirconia posts use have been published,

but long-term clinical studies are very important. **Conclusion:** The results indicate that the zirconia posts with retentive rings present high level of reparable fractures and sufficient esthetics effects.

**OP 455 COMPLEX ORODENTAL REHABILITATION IN ELDERLY PATIENTS WITH OCCLUSAL ATTACHMENT OVERDENTURE**

MIHAELA ROMANITA GLIGOR; LAURA STEF; MIHAELA CERNUSCA MITARIU

*Romania*

**REMOVABLE PROSTHODONTICS**

Prosthetic treatment in elderly patient is most of the time the first solution for toothless extended situation frequently met at old age. Chronic disease, with its complex treatment, with many secondary reactions is restricting the large scale of solution treatments. The goal of a good treatment solution is to preserve the existing teeth and to realize prosthesis with transmission of occlusal force in the long axis of the tooth. Special prosthodontic systems with occlusal attachment cap system allow technical solution for overdenture which protects edentulous crest from decubitus lesions, and offer good stability, comfort and aesthetics. The more occlusal caps on dental support the more stable the overdenture.

**OP 458 HYPNOSIS - A HANDY AND HELPFUL TOOL IN PAEDIATRIC DENTISTRY**

ARINA VINEREANU

*Romania*

**PAEDIATRIC DENTISTRY**

Currently defined as “a modified state of consciousness where the individual is functioning at a level of awareness other than the ordinary conscious state” and far from myth, hypnosis is a natural mental state. Children are often in a state of self-hypnosis while playing imaginary games. Hypnosis basically relies on the subject’s concentration and imagination; the practitioner is only guiding the patient’s subconscious to bring to surface subject's own inner resources in order to reach a therapeutic goal. Hypnosis can be outstandingly useful in paediatric dentistry. Hypnosis of children was first described by Mesmer (1779), who reportedly used hypnotherapy to treat a child with visual problems. Despite the initial reluctance towards the applicability of hypnosis in paediatric patients, in the 1970's observations suggested that children were actually easier to hypnotize than adults. Children have vivid imagination, which makes it much easier for them to reach an “altered mental state” through relaxation techniques and mental images, to access the unconscious and bring about the desired change. If adequately chosen, different techniques such as visualization, stories, puppets and role-playing can help control anxiety in initially reluctant young patients, can significantly increase the level of cooperation, decrease the need for sedation and may also dramatically reduce the amount of anesthetics needed to obtain analgesia for dental treatment. Several clinical cases of children treated under hypnosis are presented in order to support the above statements. The dynamics of patients’ dental compliance is also depicted, emphasizing the role played by hypnosis in this evolution.

**OP 460** **FIXED PROSTHETIC IMPLANT RESTORATION AND ITS EVOLUTION ON EDENTULOUS PATIENTS.SERIAL CASES**

MARINA MELESCANU IMRE; ANA MARIA TANCU; CRISTINA TEODORA PREOTEASA; ELENA PREOTEASA

*Romania*

**ORAL IMPLANTOLOGY**

**Aim:** The implant therapy introduced fundamental changes in full edentulism restoration. From all the alternatives that dental implants offers for full edentulism, the fixed prosthetic solution is the one preferred, due to the multiple functional benefits, by a large number of patients. Due to the complexity of this treatment not all the cases can benefit of this therapy. **Material and method:** Presentation of a series of cases of maxillary, mandibular and bimaxillary cases restored with fixed prosthetics on implants. This complex treatment begins after clinical and imagistic evaluation, highlighting the prosthetic and surgical particularities of each case, focusing on key aspects. The amplitude of the surgical procedures of sinus lifting and bone augmentation was assessed. The provisional prosthetic treatment was an important matter, due to the long period that this treatment requires. The evolution was evaluated, clinically and radiologic in 3 years term. **Results and Discussion:** The fixed prosthetic implant restoration is a complex treatment that requires, 2 stages-surgical and prosthetic, both with risks, costs and implications on the final result. The follow-up of the 3 cases shows a low rate of bone resorption and good clinical aspect of functionality. This treatment requires a longer time of treatment, functional provisional, rigorous follow-up and hygiene instructions. **Conclusion:** The analysis of the functional benefits, patient satisfaction, preservation of the support structure-assessed factors, confirm the fixed prosthetic implant restoration as first option in full edentulism cases, especially on young patients.

**OP 462** **DIFFERENTIATION OF ADIPOSE TISSUE STEM CELLS ON 3D PRINTED SCAFFOLDS, UNDER THE GROWTH FACTORS ACTION**

ARANKA ILEA; OLGA SORIȚĂU; BIANCA BOȘCA; MIHAI CENARIU; RADU SEPTIMIU CAMPAN

*Romania*

**ORAL SURGERY AND ORAL MAXILLOFACIAL SURGERY**

**Introduction:** Growth factors like BMP2 (Bone Morphogenetic Protein 2) and TGF- $\beta$ 1 (Transforming Growth Factor-  $\beta$ 1) have important roles in bone formation and TGF- $\beta$ 1, also in mitogenesis. Objectives Assessment of bone differentiation in vitro of porcine mesenchymal adipose derived stem cells (pADSCs), under the action of BMP2 and /or TGF- $\beta$ 1, on 3D printed scaffolds. **Materials and methods:** The adipose tissue pieces were harvested from 8 Vietnamese pigs. pADSCs were isolated, cultured and then characterized by immunocytochemistry and flow-cytometry. pADSCs were differentiated with growth factors on 6-well plates, on 3D printed scaffolds: two wells were control (pADSCs+medium DF1215%, pADSCs+medium DF1210%), a well with medium osteogenic simple (OS), a well with OS+BMP2, a well with OS+TGF- $\beta$ 1 and a well with OS+BMP2+TGF- $\beta$ 1. Bone differentiation was noticed in optical microscopy; at flow-cytometry and immunocytochemistry by expressing markers for osteopontin and alkaline phosphatase. **Results:** At

characterization of pADSCs were found the stemness characters: positivity for CD90 and Sox2 markers, partially positivity for CD73 and Oct3/4. Under the action of the OS or OC (osteogenic complex) medium, the stem cells have become polyhedral shape and showed nodules of osteogenesis. The best results at bone differentiation were achieved with OS+BMP2 and OS+BMP2+TGF- $\beta$ 1 mediums. pADSC differentiated into osteoblasts expressed markers for osteopontin and alkaline phosphatase. **Conclusions:** Culture mediums OS, respectively OC+BMP2 and /or TGF- $\beta$ 1 determined differentiation of pADSCs into bone, in vitro. The best results at bone differentiation were achieved with OS+BMP2 and OS+BMP2+TGF- $\beta$ 1 mediums. pADSCs bone differentiation in vitro ensuring the optimum conditions for their implantation in vivo.

**OP 464 EFFECT OF DENTAL MODELS POSITION ERRORS IN A VIRTUAL ARTICULATOR ON OCCLUSAL MORPHOLOGY**

ALEXANDRU PETRE; LIVIU GAVRILA ARDELEAN; PAUL FREIMANN;  
STEFAN MILICESCU

*Romania*

**FIXED PROSTHODONTICS**

We designed a virtual model of dental crowns which one allow free changes of dental models position in a virtual articulator of a commercial CAD system. We calculated the effect of these changes on the volume of dental crowns for different temporomandibular joint parameters. We haven't got important differences in usual clinical limits variations, of dental models position. Practical significance - accurate recording of mandibular rotation axis does not bring significant benefits on occlusal adjustment of dental crowns in relation to dental models mounted with a facial arch using a fast technique.

**OP 466 IMPROVING DIAGNOSIS AND THERAPY IN PROSTHESES RELATED INFLAMMATIONS USING INJECTION POLYMER TECHNIQUE**

LIVIU GAVRILA ARDELEAN; PAUL FREIMANN; ALEXANDRU PETRE;  
IUSTIN OLARIU; STEFAN MILICESCU

*Romania*

**REMOVABLE PROSTHODONTICS**

Project PI / 6 / 21.07.2014 internal research Grants financed by Vasile Goldis Western University of Arad, Romania. Prostheses related inflammations are a frequent problem caused by acrylic complete denture bases. According to our clinical experience, the maxillary acrylic complete denture occurs more frequent with this pathology. Maxillary denture base is larger and thinner than mandibular base. We used Polyan polymer for obtaining completes maxillary dentures, especially when heavy occlusal forces are involved. These prostheses will be intimate applied on Ah zone. The content in residual monomer of thermoplastic injectable resin Polyan is low, 0,3%, compared to other thermopolymerized resins which content 2-4 % residual monomer. Practical significance - the content in residual monomer is low, extremely important for the health of the stomatognathic system.

**OP 469 BONE LOSS MANAGEMENT IN MAXILLARY CYSTS**

VICTOR-VLAD COSTAN; OVIDIU STAMATIN; OTILIA BOISTEANU;  
EUGENIA POPESCU

*Romania*

**ORAL SURGERY AND ORAL MAXILLOFACIAL SURGERY**

**Introduction:** Bone grafts are frequently used in the treatment of limited bone defects such as maxillary cysts. Bone harvesting can cause postoperative complications and sometimes does not provide a sufficient quantity of bone. Different biomaterials have been identified as an alternative to autogenous bone grafts and large defects demand maxillary obturator. Aim and Objectives: The aim of this study was to evaluate and compare different techniques and bone grafting materials as substitute in maxillary cystic bony defects and physiognomy and functional rehabilitation through maxillary obturator. Patients were analyzed by computerized analysis and digital radiography. **Materials and methods:** In the study, 12 patients group were included randomly after clinical and radiological evaluation. The integration of bone graft was assessed with mean bone density, surgical location and radiological bone formation characteristics using computer analysis and radiovisiography. **Results:** After 6 months period, the grafted defects radiological and statistically showed similar volumes of bone formation. The significant changes observed in the formation of bone and merging of material and surgical site margin were analyzed after 1 week and 1 month interval, while 2 cases required maxillary obturators. The results were significant and correlating with the clinical parameters showing the necessity of the grafting for early bone formation. **Conclusion:** Cancellous autogenous bone graft used for maxillary cysts can be harvested from the iliac crest, tibial proximal part, distal end of the radius and greater trochanter. The technique of intramedullary bone-graft harvest can provide a possible alternative, although outcomes and complications are not yet fully defined.

**OP 470 POST RESTORATIONS OF UNCOMPLICATED CROWN FRACTURES - A FINITE ELEMENT ANALYSIS**

DAN-CRISTIAN IONEL; RODICA LUCA; DOINA BOAZU

*Romania*

**PAEDIATRIC DENTISTRY**

**Background:** Uncomplicated crown fractures (UCF) can quite often "upset" the balance between long lasting restoration and tooth development. The "effectiveness" of different post restorations used in UCF was evaluated. **Methods and material:** A 3D finite element analysis (FEA) - COSMOS/M software, of a worst case scenario: horizontal UCF near the pulp of an upper central incisor was performed. 4 restoration types were tested: composite restoration without reinforcement (case 1) or reinforced with metal pins (case 2); carbon nanotubes (case 3) and quartz (case 4) posts. Contacts between materials were considered perfect and the structures tooth-alike. Evaluation criteria: von Mises stresses and strains (vMs) in dentin and total displacement (TD) of the reconstructed area. **Clinical situations:** (A) horizontal load (F=550N) applied tangentially to the posterior edge of the restoration and (B) oblique load (F=390N) at an angle of 45degrees to the upper-posterior surface of the restoration. **Results:** TD in the first situation (A), varied from 0.373mm (case 1) to 0.370mm (cases 2 and 3). The minimum vMs were:  $1.9967 \times 10^8$  Pa (case 1) and  $2.019 \times 10^8$  Pa (case 2). In the second simulation (B) the TD was: 0.213mm (case 1) and 0.210mm

(case 2-4). The lowest vMs were:  $1.265 \times 10^8$  Pa (case 2) and for the post restorations  $1.294 \times 10^8$  Pa (case 4). **Conclusions:** All the reinforced reconstructions presented similar behavior with a slight advantage (low TD and vMs) for the metal ones. In both situations lower displacements (TD) were associated with higher strains (vMs) in dentin and restoration.

#### OP 471 CBCT EVALUATION OF SELLA TURCICA MORPHOLOGY IN A GROUP OF TURKISH POPULATION

SEDA OZER; ALI MURAT AKTAN; OZLEM ISMAN

*Turkey*

#### ORAL DIAGNOSIS-ORAL RADIOLOGY

**Objectives:** The aim of the study was to analyze the variations of the sella turcica and their relationship to gender and age. **Materials and methods:** The CBCT images of the patients who referred to Gaziantep University, Faculty of Dentistry, Department of Dentomaxillofacial Radiology between January 2012 and December 2014 were analyzed and 200 CBCT images were evaluated retrospectively. Sella turcica shape of individuals were described according to Axelsson's classification as either normal or with aberrations including; oblique anterior wall, double contour of the floor, sella turcica bridging, irregularity in the posterior part of the dorsum sella, and pyramidal shape of the dorsum sella. **Results:** Normal sella turcica was the most common type seen in 100 individuals with a rate of % 49, 8. The secondary common type was double contour of the floor of sella turcica seen in 46 patient (% 22, 9). 32 patients (% 15, 9) had oblique anterior wall on sella turcica. 17 individuals (% 8, 5) had pyramidal shape of the dorsum sella. The least common shape was irregularity (notching) in the posterior part of the sella turcica. None of the patients had sella turcica bridging. There were no statistically significant relationship between variations of the sella turcica either gender or age. **Conclusion:** Sella turcica varies in shape and morphology apart from age and gender. Normal sella turcica was the most frequent type in the study group.

#### OP 472 EVALUATION OF HALITOSIS USING DIFFERENT MALODOR MEASUREMENT METHODS AND SUBJECTIVE PATIENTS' OPINION

BUSRA YILMAZ; MEHMET ERTUGRUL CIFTCI; OZLEM ISMAN;  
ALI MURAT AKTAN

*Turkey*

#### ORAL DIAGNOSIS-ORAL RADIOLOGY

**Objectives:** The aim of the study was to evaluate halitosis using the different malodor measurement methods and to determine alignment between the measurements and subjective patients' opinion. **Materials and methods:** A questionnaire was completed by 198 patients, 122 females (%61.6) and 76 males (%38.4) aged 13-65 years (average 29.78 years). Each person was also examined for organoleptic score and measure odor scores (volatile sulfur compounds) using breath checker (Tanita Corporation, Tokyo, Japan). Tongue coating was also determined. Halitosis was diagnosed if the average level of breath checker was  $\geq 2$  using 1-4 point scale and the organoleptic measurement using 0-5 point scale was  $\geq 2$ . Statistical analysis was performed using chi-square test and Spearman correlation. **Results:** There was a moderate agreement ( $\kappa$ : 0.404) between organoleptic scores and breath checker scores. There was a significant correlation between years of

smoking habit (0.356), frequency of the relative complaints about malodor (0.329), tongue coating (0.350). There was no significant correlation between organoleptic scores and patients own feelings about bad breath. Age and gender had no significant effect on malodor. **Conclusion:** There was a moderate agreement between organoleptic scores and breath checker. Patients own feelings didn't correlate organoleptic scores.

#### OP 474 DENTAL AGE IN CHILDREN WITH HYPODONTIA

ANETA MUNTEANU; RODICA LUCA; ARINA VINEREANU; CATALINA FARCASIU;  
ANDREEA FOCSA  
*Romania*

#### PAEDIATRIC DENTISTRY

**Background:** The studies from literature show inconsistent data about how dental age is influenced by hypodontia. The aim of the study was to compare dental age (DA) to chronological age (CA) and to potentially correlate the differences to number of missing dental units and patient's gender. **Methods and material:** A cross-sectional study was conducted on a sample of 30 patients (17 boys, 13 girls) aged between 5 and 14 years (mean age =  $9.08 \pm 2.42$  years) from Pedodontics Department, Carol Davila University, Bucharest. Patients were diagnosed with hypodontia in permanent dentition, having 1-4 congenitally missing teeth (CMT). Dental age was assessed using Demirjian method. **Results:** a) Most of the children (76.66%) had 1-2 CMT (mild hypodontia); b) For the entire sample, mean DA ( $8.76 \pm 2.33$  age) was delayed with  $0.32 \pm 0.12$  years compared to CA, the most important difference being found in patients with 3-4 missing teeth (moderate hypodontia) -  $0.90 \pm 0.25$  years; c) in 70% (n=16) of 23 patients with mild hypodontia DA was consistent with CA; d) Related to gender, mean DA in boys was delayed with  $0.11 \pm 0.17$  years and in girls with  $0.59 \pm 0.02$  years. **Conclusions:** 1) Dental age of children with hypodontia is different from chronological age; differences are related to the number of missing teeth and the patient's gender; 2) The most considerable delay of dental age was found in moderate hypodontia; 3) Regarding gender differences, delay in dental age was higher in girls.

#### OP 475 EVALUATION OF DIETARY HABITS REGARDING SUGAR CONSUMPTION IN 7 TO 10 YEARS OLD SCHOOL CHILDREN

LUCIA BARLEAN; LIVIA BOBU; CARINA BALCOS; DANA BACIU;  
MAGDA BARLEAN  
*Romania*

#### PREVENTIVE DENTISTRY

Nutritional factors, especially sugar consumption, are directly involved in the etiology and development of oral diseases representing a significant risk factor. The aim of this study was to assess the dietary habits regarding the carbohydrates intake in 7 to 10 years schoolchildren. **Methods:** The authors initiated a questionnaire-based study including 504 children aged between 7 and 10 (classes I-IV) from 12 schools in 5 cities in Romania (Iași, Cluj, București, Tg, Mureș, Timișoara). The questionnaire included 18 questions regarding the amount and frequency of carbohydrate intake. Data were analyzed using SPSS 14.0 system and ANOVA test. **Results:** 89.3% of the subjects like sweets, with no difference depending on gender (89,2% of women and 85,5% of

men ) , age, socio-economic status or residence. 84.6% of subjects take snacks during the day consisting of sweets for most of them. Significant more children in rural areas (77.2%) eat sweets between meals comparing with children in urban areas (67,6%). The number of carbohydrates intake is more than 5 times per day for 61.7% of children. 93% of the subjects of high socio-economic level and 80% of the children of low income level occasionally eat hard food. **Conclusion:** As the intake of cariogenic sugars as quantity and frequency is high, nutritional counseling is essential for the prevention of oral diseases and improvement of general health.

**OP 483 PSYCHOMETRIC PROPERTIES OF THE ROMANIAN VERSION OF THE CHILD PERCEPTIONS QUESTIONNAIRE (CPQ8-10)**

EUGENIU MIHALAŞ; LAURA GAVRILĂ; ANA PETCU; ADRIANA BALAN;  
CARMEN SAVIN  
*Romania*

**PAEDIATRIC DENTISTRY**

**Background:** CPQ8-10, as part of the Child Oral Health Related Quality of Life (COHRQoL), is a self-reported questionnaire for children aged between 8-10 years, and is often used in oral health surveys around the world. The Romanian version of the CPQ8-10 has not been published yet. **Method and materials:** Following translation and cross-cultural adaptation, the CPQ8-10 was tested on 120 children from 8 to 10 year-old. The internal consistency of the instrument was assessed by Cronbach's Alpha Coefficient and the test-retest reliability by Intraclass Correlation Coefficient. Spearman's correlation coefficients were calculated to assess construct validity between the total and subscale scores and the respondents' global ratings on oral health and well-being. Discriminant validity was analyzed using the Kruskal-Wallis or Mann-Whitney tests in groups defined by gender, family socioeconomic status, caries experience, place of residence (rural or urban) and presence of dental dystrophies. **Results:** The mean score on the CPQ8-10 was 14.91 (SD=1.06), and the scores on all the domains were found to be highly skewed and platykurtic. Cronbach's alpha ranged from 0.67 to 0.88. Test-retest reliability revealed almost perfect reproducibility (ICC = 0.98). The global ratings on oral health and well-being were correlated to the total score ( $r_s=0.87$  and  $0.72$  respectively) and to the sub-scores (varied between 0.56 and 0.82). The CPQ8-10 score was able to discriminate between all defined groups, except gender group that did not reach statistical significance. **Conclusion:** The Romanian version of the CPQ8-10 appears to be a reliable, valid instrument for Romanian children.

**OP 486 ORTHODONTIC TREATMENT OF ECTOPIC CANINES (CASE REPORTS)**

IRIS ÇAÇANI; ANILA VJESHTA; CELJANA TOTI; EDLIRA SUBASHI; NINETA FINO  
*Albania*

**ORTHODONTICS**

The **aim** of this presentation is to show some case reports of the treatments of ectopic canines. Canine is the last tooth to erupt in the upper jaw, and it is very often erupted in an ectopic position. The ectopic position of this tooth could be on the palatal or on the vestibular side. The canine is a very important tooth regarding the esthetic and function. It is the tooth that plays a very important role in the guide of the movement of the jaws. **Method:** The diagnose was based basically



to an extra and intraoral examination. The radiographic evaluation was very helpful in deciding the diagnosis and planning the orthodontic treatment. We decided to solve most of the cases with fixed braces. After aligning the teeth we continued with opening the spaces for the canines and than ligate the canine to the wire. **Result:** The orthodontic treatment took almost two years, because it is very important not only to align the teeth, but also to repair the malocclusion. The result should be therefore more stable with the passing of time. **Conclusion:** Even the canines are very often ectopic, it is very important to reposition them on the dental arch, and therefore the smile of the patients would not be compromised. The patients were very content and happy at the end of the treatments and they smiled and eat a lot better.

**OP 502 WOUND HEALING AFTER ER:YAG LASER ASSISTED POCKET DEBRIDEMENT**

ANA MINOVSKA; DANIELA C.STOJCEVA; ANA BUNDALEVSKA;  
BRUNO NIKOLOVSKI  
FYROM

**PERIODONTOLOGY**

**Objective:** The present study was conducted to provide immune-histochemical and histomorphometric analysis of early phase of wound healing following low energy erbium YAG laser assisted pocked debridement compared to conventional hand instrumentation scrutinizing the inflammatory cells and healing picture within initial phase. **Material and method:** 15 patients were selected with chronic periodontitis and attachment lost  $\geq 5$  mm on one aspect of the tooth. The active treatment consists of initial therapy- "closed debridement" conventional vs. laser assisted, using energy density of about 178 mJ/ mm<sup>2</sup> for soft tissue and 256 mJ/ mm<sup>2</sup> for scaling and root planning . The tissue biopsy was taken 24 and 72 hour after preformed periodontal treatment and following parameters were assessed: myeloperoxidase, CD68, vimentin and CD34. **Results:** The obtained result forhand instruments treated group versus laser treated group after 24h shows significant differences ( $p < 0,001$ ) on all parameters. Very similar results were obtained for hand instruments treated group versus laser treated group after 72h; significant difference between two groups ( $p < 0,001$ ) were obtained with higher CD34 expression for laser treated group. **Conclusion:** Obtained results showed relatively low postoperative cellular inflammatory response for myeloperoxidase, CD68, vimentin and higher CD34 expression most likely attributed to the minimally invasive pocket instrumentation and very narrow soft tissue zone of thermal disruption which could be interpreted as a positive signal insuring directs of appropriate cell types to area of inflammation in temporally correct manner.

**OP 508 BIOMECHANICS STUDY OF SKELETAL PROSTHESIS INTEGRATED IN THE HOMEOSTASIS OH THE STOMATOGNATHIC SYSTEM**

MONICA ANDRONACHE; RAMONA FEIER; OVIDIU STAMATIN;  
MONA GORNICIOIU; CIBELA CARAS; NORINA FORNA  
Romania

**REMOVABLE PROSTHODONTICS**

This project aims at expanding the area of biochemical testing methods in dental prosthetics as an essential aspect for the development and improvement of quality of the partially

removable prosthetic substitutes based on the scientific collaboration between the medical, mathematical, statistical and engineering domains. The goal of this study is to highlight the distribution of stresses and strains within the partial skeletal prostheses subjected to the action of masticating forces and then to compare the influences of different parameters (saddles, main connector, maintenance, support and stabilization elements) on the prosthesis design. We tried to render the real conditions as accurately as possible in the context of replacement by partially removable skeletal prostheses, which is a mandatory condition in order to obtain pertinent results. Besides the possibility to visualize the distribution of stresses on a wide surface via PhotoStress technique, we may determine the effective values of main strains and stresses in the points of interest on the surface covered in photosensitive material of the object under study. This is possible because the optical properties of the photosensitive plastic material highlights the state of strain of the object under study.

**OP 516 SELECTION OF THE AUTOGENOUS GRAFTS IN THE SURGICAL RECOVERY OF CLEFT LIP AND PALATE PATIENTS**

ION LUPAN; EGOR POROSENCOV

*Republic of Moldavia*

**ORAL SURGERY AND ORAL MAXILLOFACIAL SURGERY**

**Background:** Cleft lip and palate patients need a recovery of the alveolar process defect with osteoplasty using autogenous bone grafts also combined with xenogeneic and alloplastic materials. **Methods and materials:** In our clinic for osteoplasty of alveolar defect are accepted grafts from donor sites: iliac crest, symphysis and mandibular ramus. In the period from 2011-2014, 30 bone grafting procedures were done to 25 patients with lip and palate cleft by the age 18-25. In 8 operations was used iliac crest bone graft, in 14 cases from symphysis and in 6 from mandibular ramus. By our protocol the bone was divided in to cortical mini-plates, the rest was crashed by the bone-cruncher and mixed 1:1 with xenocollagen and hydroxyapatite granules. The grafted bone side was covered with a collagen membrane only in the cases of periosteum deficiency. To evaluate the bone volume CBCT 3-D examination was performed pre-operative and 6 month post-operative . **Results:** According to CBCT 3-D results the necessary bone volume was present in 25 patients and implants were successfully installed. But in 5 cases after 6 month additional bone grafting was needed, because of the complications: graft exposure -2 patients, oro-nasal fistula -2 patients, insufficient formation of bone -1 patient. **Conclusion:** Bone grafts from iliac crest, mandibular ramus and symphysis can be used with success in osteoplasty of alveolar congenital defects. There were no significant difference between this three graft sites, important is the recipient bone place. To gain more relevant conclusion in time the study is continuing.

**OP 519 EFFECT OF MENOPAUSE ON PERIODONTIUM IN WOMEN**

VERA NIKOLOVSKA; VERA STOJANOVSKA; ILIJANA MURATOVSKA; NATASA TOSESKA-SPASOVA; ANETA ATANASOVSKA STOJANOVSKA  
FYROM

**PERIODONTOLOGY**

**Introduction:** In women, during menopause, there is a fluctuation in the production of sex steroid hormones which results in increased gingival inflammation, gingival bleeding, cervicular fluid flow, microbial and pathohistological changes. **Aim:** To establish serum levels of 17 $\beta$ -estradiol in women in the postmenopausal period; to determine its influence on periodontal complex, followed by indexes of periodontal health; by immune-histochemical analyzes to determine the presence of sex hormones 17 $\beta$ -estradiol in gingival tissue. **Material and method:** 30 post menopausal women were examined clinically and performed laboratory tests, pathohistological and immune-histochemical analyzes. **Results:** The average values of periodontal indexes demonstrated moderate form of periodontal disease with moderate to strong correlative value between indexes of periodontal status ( $r = 0,26$  to  $0,57$ ). In immune-histochemical analysis, we were able to detect nuclear and cytoplasmic positivity for estradiol, as in the epithelium and in the connective tissue of gingiva. **Conclusion:** The results of hormone concentrations show potent impact they manifest on periodontal health, which suggests the role of dentists in treatment modalities in postmenopausal period in women.

**OP 520 ORTHODONTIC TREATMENT OPTIONS AS AN AID FOR ORAL REHABILITATION**

LOREDANA GOLOVCENCU; ALINA SODOR; DANIELA ANISTOROAEI;  
GEORGETA ZEGAN  
*Romania*

**ORTHODONTICS**

Orthodontics in the third millennium became an active part of the oral rehabilitation treatment which involves a multidisciplinary team of dental specialists. Orthodontics is also a useful tool for dentists in order to move teeth or to correct teeth positions for prosthodontic reasons. Moreover, the combined orthodontic and surgical treatment is a complex oral rehabilitation treatment option for those non-growing patients with skeletal imbalances. **Case reports: Case 1.** Female patient, 24 years old, class I malocclusion, mild bimaxillary prognathism, mild hyperdivergent growth pattern, crowding in the upper arch, palatally displaced 23, extracted 16,36, missing 18, 48, compromised 14. The treatment plan was 14 and 25 extraction, dental alignment, settle occlusion, implant placement for 14 and 36. **Case 2.** Female patient, 20 years old, class II division 2 malocclusion, maxillary prognathism, mild mandibular retrognathism, hypodivergent growth pattern, missing 22, nanic 12, deep bite. The treatment plan was to correct the occlusion, to reopen the space for 22 and implant placement and to reshape 12 with veneer. **Case 3.** Female patient, 23 years old, class III skeletal malocclusion, mandibular prognathism, hyperdivergent growth pattern, crowding in the lower arch. The treatment plan involves combined orthodontics and surgery for dental alignment and correction of skeletal imbalance. **Conclusions:** The

orthodontic treatment represents now a new opportunity for teenagers and adult patients to achieve a better dental and facial esthetics , a good occlusion and a pleasant smile

**OP 524 SEM EVALUATION OF ONE SINGLE-COMPONENT ADHESIVE APPLIED IN SELF- ETCHING AND TOTAL-ETCHING PROCEDURES**

GIANINA IOVAN; SIMONA STOLERIU; ANGELA GHIORGHE; IRINA NICA;  
SORIN ANDRIAN

*Romania*

**RESTORATIVE AND ADHESIVE DENTISTRY**

SEM evaluation of one single-component adhesive applied in self- etching and total-etching procedures The attempts to simplify the bonding systems seem to result in decreased adhesion in most cases. The combination of these adhesives with preliminary etching using phosphoric acid is still a controversial issue. The aim of this study was to analyze the adhesive joint with enamel and dentin for a single-component system which can be used in either self- or total-etching procedures. **Materials and methods:** 40 cavities were prepared in 20 extracted third molars and restored using the composite resin Filtek Z550 and the adhesive Single Bond Universal (3M ESPE). On the same tooth, in each cavity the adhesive was applied using either total-etching or self-etching technique. The axial sections were observed by scanning electron microscopy using a VEGA II LSH (TESCAN) microscope. **Results:** The adhesive layer interposed between the enamel and the composite resin was thicker in most samples were the specimens were subjected to acid etching. Preliminary etching of dentin with phosphoric acid resulted in thicker hybrid layers and augmented resin tags in the tubules. However, total etching did not seem to significantly improve the quality of the dentin sealing, with gaps still being present in some areas of the adhesive joint. **Conclusions:** The appearance of the adhesive joint was influenced by the way in which the tested adhesive had been used; the preliminary etching with phosphoric acid seemed to increase the quality of enamel sealing, and had inconsistent effects on dentin sealing.

**OP 525 SOCIO-BEHAVIOURAL FACTORS ASSOCIATED WITH DENTAL CARIES IN 6-7 YEARS OLD CHILDREN**

DIANA DANIELA DACIANA ZMARANDACHE; RODICA LUCA

*Romania*

**PAEDIATRIC DENTISTRY**

**Aim:** To evaluate some social factors (parents socioeconomic condition) and behavioral factors (oral hygiene and alimentary habits) and establish a possible association between these factors and dental caries. **Material and methods:** A transversal study performed on 200 children (100 girls and 100 boys, mean age=7.2±0.06 years) involving each children clinical examination and interview was developed. The children habits related to oral hygiene and diet were registered. Children were divided in three groups according to socio-economic family condition (SSE): low, average and high. The caries experience indices (Prevalence Index-Ip, dmft/s, DMFT/S) were determined according to children SSE. The results were statistically processed with SPSS program,

version 16.0. The parents and authorities approval was obtained. **Results:** Children with low SSE: Ip=89.3%, dmft=3.73±2.46, dmfs=8.83±7.9, DMFT=1.13±1.3, DMFS=1.34±1.7. Children with average SSE: Ip=86.5%, dmft=4.3±3.16, dmfs=8.16±7.2, DMFT=0.76±1.15, DMFS= 1.02±1.7. Children with high SSE: Ip=78.2%, dmft=3.56±2.57, dmfs=6.98±7.3, DMFT=0.47±0.99, DMFS=0.5±1.1. **Conclusions:** Caries experience indices were lower in children with higher SSE. Different life condition of children from the same region may explain the various types of carioactivity.

#### OP 527 OCCLUSION AND AESTHETIC

BASSIL RAYMOND VICTOR; JENDOUBI SABRINE

*Romania*

#### NEW TECHNOLOGIES

Without a good occlusion there is no good aesthetic. In fact, occlusion is the key of success in dentistry. In our presentation we are going to introduce you nowadays technologies which guide the practitioner to a successful treatment. Patient asks for aesthetics, practitioner asks for perfection. Let's talk about T-scan and all new technologies which provide good results.

#### OP 531 ORAL REHABILITATION OF ECTODERMAL DYSPLASIA WITH ANODONTIA: CASE REPORT

VIORICA TARMURE; RADU-SEPTIMIU CAMPAN; ARANKA ILEA;  
ONDINE LUCACIU; ANDREEA-SIMONA POP

*Romania*

#### PAEDIATRIC DENTISTRY

The hereditary condition known as ectodermal dysplasia is characterized by the absence or defect of 2 or more ectodermal derived structures. Oral manifestations are extremely various, there might be missing only 2 teeth, 4-6 teeth (usually with abnormal shape- short, curved or thin roots) or even complete anodontia, which is the most unrelenting form. **Purpose:** There is no clear link between the teeth which are most frequently missing, their form or position. Often, the teeth position on the dental arch is unfavorable, a complex interdisciplinary treatment is needed. **Method and materials:** A five years old patient with ectodermal dysplasia is presented. Oral, physical and psychological aspects were considered. The treatment consisted in complete removable denture, according with the patient's age. The orthodontic treatment is the first step, followed by the prosthetic treatment consisted of infant removable denture during childhood, and, finally, on the end of growth dental implants and overdenture. **Results and Conclusions:** Due to complete oral rehabilitation it is essential the age of the young patient, the number of missing teeth and their form; also the grade of the growth process is needed. The final treatment plan is complete overdenture on implants at adult age.

**OP 533 STUDY ON KNOWLEDGE OF DENTISTS IN THE NORTH-EAST REGION OF ROMANIA CONCERNING ORAL DISEASES PREVENTION**

LIVIA BOBU; LUCIA BARLEAN; IULIA SAVEANU; CARINA BALCOS;

IRINA BAMBOI

*Romania*

**PREVENTIVE DENTISTRY**

The study was conducted as a part of the project entitled “Ergonomics, prevention, performing management in dentistry in alignment with European standards”, finalized in 2013 and aiming to train the dental staff in the field of ergonomics, prevention and modern management. The **purpose** of the present study was to assess dentists’ knowledge in preventing oral diseases, after having participated in professional training courses. **Material and methods:** The study included 337 dentists from the north-east region of Romania, aged 25-65 years. Data were collected using a 10 item questionnaire with simple / multiple responses and then analyzed using the SPSS 14. **Results:** More than 75% of the investigated dentists knew the principles of preventive resin restorations, but only 60% of them were familiar with the characteristics of the materials used in primary and secondary prevention of dental caries. The characteristics of individual toothbrushing methods were known by a little more than half of the dentists included in the study. 47% of the investigated practitioners considered ultrasonic scaling as a substitute, not only a complementary method to manual scaling. 45.2% of the dentists recommended combined administration of local and general methods of fluoride application, irrespective of caries risk category. **Conclusion:** The main methods and techniques for oral diseases prevention are known by most of the practitioners, but further training programs are required in the area to increase the level of knowledge.

**OP 535 THE EFFECTS OF DIFFERENT BLEACHING SYSTEMS ON THE VOLUME OF GINGIVAL FLUID**

DERYA SÜRMELOGLU; HASAN GUNDOGAR; BURCU BACAKSIZ;

KAMILE ERCIYAS; SEMIH OZSEVIK

*Turkey*

**RESTORATIVE AND ADHESIVE DENTISTRY**

**Background:** In office bleaching procedure is very popular in aesthetic dentistry. However bleaching agents can adhere to the gingiva and peripheral tissues by accidentally. This study aimed to see the effects of different bleaching agents and techniques on gingival crevicular fluid (GCF). **Methods and materials:** Sixty eight volunteer patients were included in this study. Patients were randomly assigned to four bleaching groups. Group A and C were bleached with % 40 H2O2 gel (Opalacences Boost, Ultradent), and Group B and D were bleached with % 35 H2O2 gel (Whiteness HP Blue Calcium, FGM) according to the manufacturer’s instructions. The bleaching agents were activated 980 nm diode laser (Gigaa laser products, China); irradiation in the group C and D. GFC samples were collected from the mesial sites of maxilla anterior tooth per subject using periopaper and the volume was determined using Peritron 8000 (Orafow Inc., Plainview, USA ). It was repeated three times ; before the bleaching process, 24 hours later and after the last seance and 2 weeks later. The data obtained were analyzed using one-way ANOVA and Tukey HSD tests.

**Results:** Group A GCF volume was statistically higher than group D volumes and had significantly difference among them ( $p < 0.05$ ). **Conclusions:** Laser activated bleaching systems could be considered as safer in the tooth and maintaining GCF when compared with a chemically activated bleaching system, which might lead to increased GCF volumes. **Acknowledgement:** This study was supported by TUBITAK in project number 114S507.

**OP 537 LASER THERAPY A NEW ERA IN DENTISTRY**

IOANA ROXANA BORDEA; ONDINE LUCACIU; BOGDAN CRISAN;  
MIHAELA BACIUT; RADU SEPTIMIU CAMPAN

*Romania*

**LASERS**

The use of lasers in various domains of oral and maxillofacial surgery is now a current topic of research among specialists. Different kinds of lasers have been introduced for treating soft and hard tissues since the late 20<sup>th</sup> century. The applications of lasers in modern medicine are very large in several specialties including dentistry, oral-maxillofacial surgery, ENT, ophthalmology, dermatology, neurosurgery, cardiology. The diode laser ( $\lambda = 980$  nm) is mainly used for soft tissue surgery, whereas the erbium - YAG laser ( $\lambda = 2940$  nm) for soft and hard tissue (bone and teeth). The aim of this study was to show the benefits of laser therapy versus conventional surgery in the treatment of soft and hard tissue. We conducted a case control study with a control and a study group. Each group included 10 patients diagnosed with various diseases of the soft and hard tissue in the oromaxillofacial area. The subjects from the control group were treated with conventional therapy and those from study group with laser therapy. Due to the better results obtained in the treatment in comparison to conventional therapy the use of lasers gain more ground. Patients treated with laser had a better wound recovery, less edema and pain after surgery. Given the results of the comparison study presented, the authors think laser therapy opens a new era in dentistry. **Acknowledgement:** This paper was published under the frame of European Social Found, Human Resources Development Operational Program 2007-2013, project nr. POSDRU/159/1.5/S/138776.

**OP 539 REMOVABLE PROSTHESIS IN THE PATIENTS WITH ORAL MUCOSA CARCINOMA**

VICTOR-VLAD COSTAN; DORIANA AGOP FORNA; OTILIA BOISTEANU;  
EUGENIA POPESCU

*Romania*

**ORAL SURGERY AND ORAL MAXILLOFACIAL SURGERY**

Clinical-statistical studies have established that the malignant tumors of the floor of the mouth rank second among the cancers of the oral cavity, with a percentage almost equal to the one for tongue cancer. They represent 25-30% of oral cancers and 2% of all cancers in humans. From the group of patients treated in the OMF Clinic of "Gr. T. Popa" University Iasi, was selected a number of 15 men diagnosed with carcinomas, in different stages, T1, T2, T3. From the mentioned group, 5 men presented carcinomas of the anterior floor of the mouth, 3 presented carcinomas of the lateral floor of the mouth, and 6 had tongue carcinomas. All the cases benefited from removable prosthesis

performed in the OMF surgery clinic, prosthetics that were preceded by tumor ablation and the plasty of the perimandibular grooves. The plasty was preceded by the removal of the tumor (partial pelvectomy or glossectomy with or without marginal bony resection, and hemi-pelvi-mandibulectomy or hemi- glosso-pelvi-mandibulectomy for T3 and T4 stages). The opportunity for major surgery in relation to the clinical and paraclinical evaluation will be an important decisional moment that will be succeeded by radio-chemotherapy or radiotherapy with curative or palliative intention, applying the prosthesis being mandatory after the strengthening and healing of the postoperative tissues. The prosthetic work will restore the lost functions and mutilations resulting from the surgical ablation and will rebalance the homeostasis of the stomatognathic system.

**OP 548 ETIOPATHOGENIC STUDY ON THE INCIDENCE OF TEMPORARY MOLARS  
PREMATURE LOSS**

ANA PETCU; LAURA MARIA VASILCA; ADRIANA BALAN; DANA MAXIM;  
CARMEN SAVIN

*Romania*

**PAEDIATRIC DENTISTRY**

Premature loss of temporary molars is still quite frequent pathology in the pediatric population in Romania. This study aim is to quantify the data on this pathology obtained from the evaluation of a representative sample of patients aged 3-10 years. **Material and methods:** The study group consisted of 438 patients with a number of diverse oral pathologies, which were presented at the pediatric dentistry clinic of Iasi between May 2009 and September 2014. Clinical examination was performed under standard conditions by inspection and palpation using dental examination kit. The existence of significant associations was tested with bivalent analysis (Pearson chi-square tests), considering a value of  $\alpha = 0.05$  reject the hypothesis proposed. **Result:** It met an impairment by premature loss of temporary molars in 47.9 % of patients from rural areas and 53.5 % of cases from urban areas. Instead, patients from rural areas showed more temporary molars lost prematurely as those in urban areas (6 temporary molars lost prematurely in 4.2 % of cases in rural areas compared to 0.5 % of cases in urban areas, while one temporary molar lost prematurely to 8.3% of cases from rural as opposed to 20.8 % of patients in urban areas). **Conclusions:** 1. Prevalence of premature loss of molars was 52.4 %, which slightly exceeds the literature. 2. Prevalence of premature loss was higher in urban areas (53.5 %) than in rural areas (47.9 %), test Pearson chi-square showing that there is a statistically significant correlation.

**OP 551 GASTRIC ULCER AFTER SHORT-TERM NSAIDS ADMINISTRATION IN A  
SMALL CHILD - CASE REPORT**

VASILE VALERIU LUPU; ANCURA IGNAT; GABRIELA PADURARU; ANAMARIA  
CIUBARA; MARIN BURLEA

*Romania*

**INTERDISCIPLINARITY**

Peptic ulcer disease in children is reported worldwide, although it is relatively rare as compared with adults. *Helicobacter pylori* (*H. pylori*) infection is a common cause of gastric ulcer in the pediatric age. Other risk factors include the use of nonsteroidal anti-inflammatory agents



(NSAIDs), steroids, immunosuppressive drugs, and stressful events. NSAIDs are a heterogeneous group of often unrelated chemical substances acting on certain stages of the inflammatory response in order to reduce it. NSAIDs produce gastric lesions through two mechanisms: local irritation and systemic action. A 2 year and 10 months old female received NSAID for acute upper respiratory infection for 2 days and she developed coffee ground vomitus one day later, being admitted to our hospital. Upper gastrointestinal endoscopy revealed a gastric ulcer. She was negative for H. pylori infection, and she was diagnosed with NSAID - induced acute gastric ulcer in the absence of other causes of gastric ulcer. Gastric ulcers sometimes develop during the long-term administration of NSAIDs, but very rarely after a short-term administration, which prompted us to report this case. Balancing the risk and the benefit of eradication therapy, it is indicated, for every patient who must follow a chronic treatment with anti-inflammatory drugs, to look for possible associated risk factors.

**OP 552** **STATISTICAL STUDIES ON PROVISIONAL VS DEFINITIVE PROSTHETIC TREATMENT DURING THE PRACTICAL TRAINING OF DENTAL STUDENTS**  
OVIDIU STAMATIN, ROXANA VASLUIANU; COSMIN ONICIUC; MONICA ANDRONACHE; RAMONA FEIER; MAGDA ANTOHE, CARMEN GENTIMIR, NORINA FORNA  
*Romania*

#### REMOVABLE PROSTHODONTICS

**Background:** This statistical clinical study is aimed to evaluate the results of provisional versus definitive treatment through removable partial dentures (RPDs), treated during clinical stages of dental students and clinical indexes assessment of the cases. **Materials and methods:** The study is based on a number of 193 patients who received 206 acrylic RPDs as provisional treatment and 90 definitive prosthesis over a period of 3 years. Patient gender, general health status, partial edentation complications, edentation location (maxilla/mandible), number and distribution (Kennedy classes) of abutment elements, the evaluation of clinical indexes on probability were analyzed. Statistical assay was conducted using the Kaplan-Meier method ( $P < .05$ ) along with Cox regression analysis. **Results:** During the analyzed period, 93% of the cases indicated the pre-prosthetic treatment while 76% had the recommendation for pro-prosthetic treatment. Mean provisional RPD was recommended as first stage therapy, with a positive outcome prediction after definitive treatment. Edentation topography and therapeutic solution were the only parameters that significantly ( $P < .05$ ) impacted the case evolution. **Conclusion:** The comparative analysis between provisional and definitive therapeutic solution indicates that the clinical index is better in the latter, and the number and types of specific and nonspecific prosthetic treatment is at outmost importance in both cases for the final outcome.

**OP 553** **OPPORTUNITIES FOR CAREER GUIDANCE OF DENTAL GRADUATES**  
RAMONA FEIER; CRISTINA GENA DASCALU; ANDREEA ZODERU; NORIN FORNA  
*Romania*

#### REMOVABLE PROSTHODONTICS

The choice of profession is an expression of personality interest inventories, job satisfaction, stability and achievement in the profession depends on the congruence between their personality

and the environment they work or will work. Given the dynamic on the labor market and accelerated changes occurring lately put an increasing emphasis on career planning and its management at both the individual and organizational level. **Purpose:** The purpose of this study is to evaluate the congruence between stated preferences in career choice by graduate's promotions 2011-2013 from the Faculty of Dentistry Iasi and the concrete reality of their employment. Our concern was to assess, by this approach the level of interest that they manifest for career counseling. **Material and method:** We used a questionnaire developed by Prof. Dr. Norina Fornă and we applied it for 371 dental students in the period 2011-2013. To assess chosen career path, we opted for a second questionnaire on the path followed by them after completion of studies and work today. We applied the survey for 201 students during April-September 2014. Both questionnaires were interpreted statistically using SPSS 22 statistical analysis program. **Conclusions:** The two studies showed large discrepancies between student's option during school and the chosen path after graduation, emphasizing that students do not know to choose a career because they lack the ability to select a fewer options to follow. We obtained significant results for all the possible career paths, which finally showed that career counseling is of most importance for the future success.

**OP 557 THE PREDICTABILITY OF IMPLANT-PROSTHETIC THERAPY; SURGICAL PRE-IMPLANTARY PROCEDURES**

ALEXANDRU CALIN; CALIN TATARU; FRANCISC BARTOK;

DORIANA AGOP FORNA

*Romania*

**ORAL IMPLANTOLOGY**

The purpose of this study consists of the identification of surgical procedures regarding the oral rehabilitation using implants, associated with identifying the specific biomaterials in perfect accordance with each case particularity, without leaving aside the bone-tissue deficiency etiology. **Material and methods:** A representative number of clinical cases were selected, cases which are relevant for the chosen theme. The reconstruction of substance loss using different surgical techniques is of critical importance in re-establishing the optimal parameters which characterize the edentulous alveolar ridge areas. The possibility of reconstructing the natural parameters of the edentulous alveolar ridge areas is various, starting with augmentation materials of the autogenous and heterograft type biomaterials, including the mixing of these two types of biomaterials. **Results:** When it comes to the biomechanical and aesthetic reconstruction of the arcade, in the majority of the cases the implant variant was preferred, followed by the fixed or removable prosthesis, which were realized either on a separate, post-augmentation stage, or in the same time with the augmentation stage. **Conclusions:** The importance of surgical procedures involved in pre and implant rehabilitation is reflected in the appreciation of the predictability of the therapeutic solution, according with resorption and atrophy process on the edentulous crest level and this appreciation has a defining influence upon accomplishing the final stage of the clinical case.

**OP 559** **BIOCHEMICAL AND SEM ANALYSIS OF TISSULAR REACTIONS AFTER ENDODONTIC MATERIALS IMPLANTATION IN EXPERIMENTAL ANIMALS**  
LIANA AMINOV; PAULA PERLEA; ALEXANDRU ANDREI ILIESCU;  
MIHAELA SALCEANU; ANCA MELIAN; CRISTIAN GIUROIU; MARIA VATAMAN  
*Romania*

#### ENDODONTOLOGY

**Introduction:** The reparative materials used in endodontic treatment are placed in intimate contact with both soft and hard tissue of periodontium. Their chemical composition can influence the final result by local or systemic adverse effects. **Materials and method:** The study attempts to evaluate the bone tissue response after the implantation of three biomaterials in the connective tissue of experimental animals, in close proximity to the bone. Examination by scanning electron microscopy was performed using a Tescan- VEGA3 SEM system. The biomaterials used in the study were: MTA (Mineral Trioxide Aggregate, Dentsply, Tulsa Dental) DiaRoot BioAggregate (Innovative BioCaramix Inc., Vancouver, BC, Canada) and Sealapex (Kerr, Switzerland). The biochemical profile of implanted animals was analyzed postoperatively for alkaline phosphatase, reported at surgery with initial biochemical parameters corresponding to the three materials. **Results and discussions:** Electron microscopy images taken 30 days post-implantation show the presence of numerous osteoblasts included in ossein seizures, with a tendency towards osteoid structure organization. After analyzing the biochemical profile of implanted animals at intervals of 7 days, 30 days and 60 days after surgery, higher levels of alkaline phosphatase were found within 7 days, growth that increased, reaching significantly higher levels than the control group, after 30 days ( $p=0,0007$ ), the highest values being found for BioAggregate (181,9 ui/l). **Conclusions:** It is noted that for all materials the alkaline phosphatase decreased significantly after 30 days, reaching at 60 days levels without significant difference from the control group.

**OP 561** **SURGICAL SPECIFIC TECHNIQUES OF PROSTHETIC FIELD ENHANCEMENT IN ASSISTED CASES; CLASSICAL TECHNIQUES VERSUS SURGICAL LASER**  
DORIANA AGOP FORNA; HENRIETTE LERNER; FLORIN ROSU;  
CATALINA CIOLOCA HOLBAN; EUGENIA POPESCU  
*Romania*

#### ORAL SURGERY AND ORAL MAXILLOFACIAL SURGERY

Identification and selection of cases eligible for implanto-prosthesis treatment, modern or classic is governed by the knowledge that 90% of cases present major complications of stomatognathic system elements, these complications are the result of untreated or improperly treated edentulous. The patients were selected from the practical training of students in Dentistry, IV, V, VI year of study. For the selected patients for prosthetic treatment, over 50% required interventions that addressed to periodontium with the purpose of rehabilitation or regeneration, or for aesthetic reasons (gingivectomy, periodontal surgery). On the other hand there were surgeries that were addressed for the edentulous ridge or mucosa at a rate of 25%, and aimed removal of fibromatous mucosa, or papillomas of the jugal mucosa. Regarding bone support, we intervened by removing the edentulous ridge exostosis, tuberosity plasty and piriform tuberculli for 25% of patients. Finally, for 25% of patients were performed in the periodontal bone surgery (osteotomy or removal of necrotic bone tissue) and bone grafts such as xenografts, autograft transplants and

mineral grafts, adding the post extraction socket grafts. All the surgeries were performed by both classical and modern method, the modern technique using surgical lasers.

**OP 567 MULTIDISCIPLINARY APPROACH OF TMJ PATIENT**

ADINA SIRBU; ONDINE LUCACIU; MINODORA MOGA; ANCA IONEL;  
RADU CAMPAN  
*Romania*

**ORTHODONTICS**

Our clinical experience regarding the treatment of head and neck pain led us closer to a multidisciplinary approach in the examination and treatment of temporomandibular joint dysfunctions (TMJ). TMJ dysfunction in children can cause changes in the growth of the jaw. In adults TMJ dysfunction can cause degenerative changes in the disc, condyle and dental structures. Clinical symptoms in TMJ dysfunction are: localized and referred pain, changes in mandibular growth, reducible or irreducible disc displacement, limitation in mouth opening. Diagnostic and treatment protocol is established after careful examination of the causes and clinical manifestations: mounting models; CBCT for the changes in shape and volume of bone structures; MRI changes for the disc and soft tissue analysis. As a therapeutic tool we use upper jaw splint to get into a musculoskeletal stable position.

**OP 569 ERGONOMIC CONCEPT IN DENTISTRY**

CRISTINA MARINA IORDACHE; DORIANA AGOP FORNA; NORINA FORNA  
*Romania*

**ORAL DIAGNOSIS-ORAL RADIOLOGY**

It is widely accepted that dentistry may be accompanied and play a role in different musculoskeletal pathologies; the main aspects are related to several factors including the repetitive activity, vicious positions maintained for long time as well as high precision work with significant impairment on stabilizing muscles of the peripheral joints and of the spine, particularly the cervical and lumbar segments. In order to assess the electrophysiological muscle activity of both lumbar and cervical region in the sitting or orthostatic position, an electromyography evaluation of the above mention muscles has been done. **Material and method:** The study group consisted of ten dentists with at least 5 years of work experience. The electromyography study (EMG) compared the obtained parameters at the level of lumbar and cervical muscles both in orthostatic and sitting position. **Results:** We have demonstrated significant differences between the main characteristics of the EMG signal corresponding to muscular activity in different working postures. The EMG abnormalities are particularly seen the sitting position supporting data from literature that account for a more challenging pattern when sitting. Moreover, electromyography changes are more evident for the lumbar muscles and the splenius capitis ones. **Conclusion:** The EMG study performed in two different postures with particular relevance for the dentist has demonstrated a greater stress on the muscles while sitting.

**OP 582 THE CONE BEAM COMPUTER TOMOGRAPHY (CBCT)  
APPROACH IN PARANASAL SINUS DISEASE EXAMINATIONS**

DANISIA HABA, GABRIELA DUMITRESCU, C. BUDACU, ANA PETCU,  
M.S.C. HABA, RALUCA VREME, NICOLETA DUMITRESCU, A. NEMTOI,  
V. COSTAN, C. MIHAI

Romania

**ORAL SURGERY AND ORAL MAXILLOFACIAL SURGERY**

With the advancement of paranasal sinus imaging, CBCT has become the procedure of choice, allowing the evaluation of size, position and the structures involved by lesions of the paranasal sinus or by extrinsic diseases involving the paranasal sinus. The acquired images provide useful information to the maxillofacial or ENT surgeons implicated in this disease management with good results in its treatment and follow up. *Aim:* Our study presents the paranasal sinus anatomy on CBCT imaging and illustrative cases of intrinsic and extrinsic diseases involving the paranasal sinus. **Material and methods:** 165 patients previously treated for chronic or recurrent sinusitis have undergone CBCT of the paranasal sinus and subsequent MPR axial, coronal, sagittal and oblique plans, at our clinic between June 2013 and December 2014. We reviewed the anatomy of the paranasal sinus and the CBCT imaging findings. We also compared the radiological and the histopathological findings in 35 cases, in order to find a better correlation between these two preclinical investigations. **Results:** There were 7 oral/sinus communication, 5 nasal poliposis with sinus obstruction, 15 periapical lesions and inflammation of paranasal sinus, 3 odontogen cysts, 5 malignant tumors, 3 benign tumors, 2 dysplastic lesions, and 17 foreign dental materials. All the other cases had chronic or recurrent sinusitis, with or no anatomical variants of the paranasal sinus. **Conclusion:** CBCT imaging allows a proper exploration of the various diseases of the paranasal sinus and the correlation with histopathological features provides essential information necessary during different stages of medical or surgical treatment.

**OP 586 RETROSPECTIVE AND PROSPECTIVE STUDY ON LASER APPLICATIONS IN  
DENTISTRY**

NORINA FORNA; DORIANA AGOP FORNA

Romania

**LASERS**

**Background:** Laser applications in dentistry have proven covering all areas of work, by comparison classical techniques being deficient in terms of: pain, bleeding and hemostasis, sterilization of the laser application area, rapidity of execution on soft tissue, removal of pathological bone and soft tissue secondary to curettage. **Material and method:** We performed a comparative study, classical surgical method versus laser on a number of 50 patients noting: For laser interventions 90% decreased bleeding, 65% decreased pain, 99% increased rapidity in maneuvers for soft tissues, and 60% increased rapidity for hard tissues, 100% sterilization and curettage. **Conclusions:** laser interventions constitute a starting point for new techniques, materials, concepts and even mentalities both practically and academically. **Acknowledgement:** POSDRU/160/2.1/S/139881.

**OP 587 CURRENT CHALLENGES IN SURGICAL LASERS USED IN DENTO-ALVEOLAR SURGERY**

DORIANA AGOP-FORNA; POPESCU EUGENIA

*Romania*

**LASERS**

**Background:** Laser technique facilitates the practical execution of interventions on both hard tissues (regularization, slicing, and apicoectomy) and on soft tissue (frenectomy, gingivectomy, incision, curettage, ablation of cysts, granulomas). **Material and methods:** For a number of 60 cases we used both the Biolase laser system, and Kavo Key 3 laser, noting differences compared to the classical surgical technique, on the basis of duration, pain, bleeding, sterilization, and by comparing two laser systems. **Results:** For the Biolase system we obtained decreased time of execution, higher accuracy, and higher sterilization than for Kavo system. Rigor and difficulty to finish the maneuvers were by 2% higher for Kavo than for Biolase system. **Acknowledgement:** POSDRU/160/2.1/S/139881.

**OP 588 MULTIDISCIPLINARY APROACH OF TMJ PATIENT**

ADINA SIRBU, RADU CÂMPIAN, MINODORA MOGA, ONDINE LUCACIU, ANCA IONEL

*Romania*

**INTERDISCIPLINARITY**

Our clinical experience with the treatment of head and neck pain led us closer to a multidisciplinary approach in the examination and treatment of temporomandibular joint dysfunctions (TMJ). TMJ dysfunction in children can cause changes in the growth of the jaw. In adults TMJ dysfunction can cause degenerative changes in the disc, condyle and dental structures. Clinical symptoms in TMJ dysfunction are: localized and referred pain, changes in mandibular growth, reductible or irreductible disc displacement, limitation in mouth opening . Diagnostic and treatment protocol is established after careful examination of the causes and clinical manifestations: -mounting models; -CBCT for the changes in shape and volume of bone structures; -MRI changes for the disc and soft tissue analysis. As a therapeutic tool we use upper jaw splint to get into a musculoskeletal stable position.

**OP 589 DENTAL PATHOLOGY IN PATIENTS WITH SCHIZOPHRENIA**

ANAMARIA CIUBARA, DANA TEODORA ANTON PADURARU, STEFAN LUCIAN BURLEA, ILINCA UNTU

*Romania*

**INTERDISCIPLINARITY**

**Introduction:** Patients with chronic psychiatric disorders, particularly those with schizophrenia are most likely susceptible to dental pathologies, due to the negligence to oral hygiene, because of the adverse effects of psychotropic medications (xerostomia) or poor socioeconomic status. **Objectives:** The present study aims to highlight the oral side effects of antipsychotic medication , used in schizophrenia and also to asses the importance of socioeconomic status and of the unhealthy habits (smoking) on the deterioration and aggravation of dental

pathology in patients with schizophrenia. **Materials and methods:** This study contains data gathered from 50 male patients, smokers, aged between 40-60 years old, all of them diagnosed with schizophrenia for more than 10 years and in treatment with antipsychotic medication for at least 5 years, admitted in Psychiatric Hospital Socola Iasi Romania between January-March 2014. All patients underwent general dental evaluation and all their socioeconomic and family data were registered. **Results:** It was evaluated the extent of dental pathology from periodontitis to edentation, the oral side effects of antipsychotic(xerostomia) and also the presence of sociofamilial support of the patients. **Conclusions:** Patients with long term schizophrenia under treatment with antipsychotics and having consecutive xerostomia, smokers with a poor sociofamilial support have severe dental pathology, with a high impact on the quality of life on those patients.

**OP 618** **DIAGNOSIS PROCEDURES AND THERAPEUTIC MANAGEMENT OF ENDODONTIC EMERGENCIES**

MĂDĂLINA MATEI, KAMEL EARAR, MĂLINA COMAN, RĂZVAN LEAȚĂ,  
MIHAELA MOISEI  
*Romania*

**INTERDISCIPLINARITY**

Given the issues related to pain in therapeutic emergencies situations requiring recognition, the correct diagnosis, prompt intervention and the establishment of appropriate therapies, we conducted a clinical study on the frequency statistics in everyday practice and their management in the dental medicine office. **Materials and methods:** We studied a representative number of patients who presented with pain / swelling of endodontic origin. Recording of historical data, and intraoral examination were focused on the customized management of these patients which was different, depending on the general condition and endodontic diagnosis. **Results and Discussion:** The studied patients presented (1) initial therapeutic emergencies, (2) pain/swelling symptoms after the initiation of endodontic therapy and (3) symptoms of pain or swelling after the root canal fillings. The therapeutic management included (a) only endodontic procedures; (b) endodontic therapy and analgesic/anti-inflammatory medication; (c) endodontic therapy, analgesic/anti-inflammatory medication and antibiotic, (d) all of the above and endodontic surgery (incision-drainage). **Conclusions:** Most often, patients with dental emergencies are presented outside office hours program, exhausted after several sleepless days, and nights and poorly fed. Under these circumstances, granting emergency treatment must combat both pain and anxiety. In these conditions, the clinician must demonstrate professional virtuosity in making a quick and accurate diagnosis and the swift establishment of therapeutic procedures.

# ABSTRACTS POSTER PRESENTATIONS



## ABSTRACTS – POSTER PRESENTATIONS

**PP 6** **MULTIDISCIPLINARY TREATMENT OF AN AVULSED TOOTH: CASE REPORT**  
EMRE KORKUT; ARSLAN TERLEMEZ; HAKKI CELEBI; YAGMUR SENER  
*Turkey*

### PAEDIATRIC DENTISTRY

**Background:** Tooth avulsion is defined as the complete displacement of the tooth out of its alveolar socket. Management of tooth avulsion in the permanent dentition often presents a challenge. Replantation of avulsed teeth is the most accepted treatment approach considering aesthetic and functionality. The aim of this case report is to present the multidisciplinary treatment approach and long-term follow up of a patient with avulsed teeth. **Methods and materials:** Avulsed maxillary central teeth were observed in a patient. The teeth were replanted with finger pressure and splinted. After three years of follow-up, beginning of teeth root resorption was identified in the radiography. In the examination performed after 4-year follow-up, hypermobility was identified in left maxillary central incisor. The left maxillary incisor tooth was extracted and fiber-supported bridge was made by using the patient's extracted tooth. During the follow-ups and controls, around year six, right maxillary central incisor was decided to be extracted due to its increasing mobility. Finally the patient lost his replanted teeth 6 years after avulsion, therefore prosthetic rehabilitation with zirconia was administered. **Results and Conclusion:** Replantation of the avulsed teeth can be administered by considering that the missing tooth will create aesthetic and functional needs, and permanent prosthetic solutions are not suitable for the growth and development period in pediatric patients.

**PP 7** **CLINICAL EXPERIENCES WITH OCCLUSAL SPLINTS IN DENTISTRY**  
GORDANA KOVACEVSKA; NINA KOVACEVSKI ; BILJANA KAPUSEVSKA;  
JADRANKA BUNDEVSKA; BILJANA KOSEVA  
*FYROM*

### FIXED PROSTHODONTICS

**Objective:** The target of this study is to present clinical experiences with the different types of dental splints. The primary objective is to provide an overview of current methods and materials of their technical preparation, and the importance of applying the dental splints in everyday clinical practice. **Materials and methods:** In order to achieve this objective, the data is received by dental labs and clinical experiences in all dental disciplines (Prosthetics, Implant Prosthetics, Cosmetics and Preventive dentistry). **Results:** The results of this study indicate that application of different types of dental splints in all dental disciplines leads to an improvement of the situation in the oral cavity. **Conclusion:** Based on the results we concluded that the application of therapeutic dental

splints for patients with parafunctional activity or as ancillary aid in certain therapeutic procedures enabling correction of certain disorders - difficulties in orofacial system.

**PP 8 RESTORATION OF FUNCTIONAL OCCLUSION WITH SELECTIVE TEETH GRINDING**

BILJANA KAPUSEVSKA; NIKOLA DEREBAN; GULABA DEREBAN;  
ANETA MIJOSKA; BUDIMA PEJKOVSKA - SAHPASKA  
FYROM

**INTERDISCIPLINARITY**

The purpose of our study is to emphasize the clinical significance of the selective teeth grinding technique for the restoration of functional occlusion. We have gathered clinical cases exhibiting abnormalities in the occlusion that could lead to moderate or severe damage to the teeth, the periodoncium and ultimately the TMJ. The patients were partitioned into three different groups: patients with frontal cross bites, patients with imposed mesioocclusion by a premature teeth contact and patients with traumatic occlusion. We located the irregularities in the occlusion of each of the groups using articulating paper and bite wax and subsequently removed them in the following dental appointments that were scheduled once a month. We followed the condition of the patients for 18 months and noticed consequential improvement of the periodontal health, cease of dental attrition and improved esthetics of the dentofacial proportions of the patients. The conclusion was that although the technique of teeth gridding is invasive and requires removal of healthy teeth substance, the merits of this procedure far exceed the imperfections and the shortcomings.

**PP 10 THERAPEUTIC APPROACH IN PATIENTS WITH DISLOCATION OF THE ARTICULAR DISC WITH REDUCTION**

BILJANA KAPUSEVSKA; NIKOLA DEREBAN; VESNA JURUKOVSKA -  
SHORTAROVSKA; MARJAN PETKOV; BORJAN NAUMOVSKI  
FYROM

**FIXED PROSTHODONTICS**

The dislocation of the articular disc with reduction is the most common diagnosis in patients with clicking and popping sounds in the TMJ. Purpose is to present a therapeutic approach in patients with dislocation of the articular disc with reduction. As a material for study we used 50patients from our ongoing clinical practice in which a dislocation of the articular disc with reduction was diagnosed. The diagnosis was confirmed by anamnestic and clinical examination during which the patient opened his/hers mouth, the condyle simultaneously moved translatory forward and repositioned from the back to the middle part of the articulating disc causing clicking and popping sounds. Our therapeutic approach consisted of patient education comprised of advices on mastication and limitation of the mouth opening, prosthodontic construction and fabrication of repositioning splints. The patients were observed after 1week, 1, 3 and 6 months from the treatment initiation. After 2 weeks, in 4(8%) of the observed patients, the education by itself was sufficient to eliminate the clicking and popping sounds from the TMJ. After 1month, in 10(20%) of patients, the

clicking, popping and pain afflictions were reduced. After 3 months from the therapeutic approach in 20(40%) patients, and after 6months in 48(96%) of patients the pain disappeared. Repositioning splints are a satisfactory method for occlusal treatment in patients with dislocated articular disc with reduction because they guide the mandible in a downward and forward direction repositioning the condyle in retruded therapeutic location. The repositioning splints alleviate the pressure from the articulating disc and reduce its inflammation.

**PP 12 THE CORRELATION BETWEEN GINGIVAL INFLAMMATION AND CHARTERS' TOOTH BRUSHING TECHNIQUE ON PATIENTS WITH FIXED PROSTHODONTICS**

BILJANA KAPUSEVSKA; KRISTIJAN SHUKOV; MIRJANA POPOVSKA;  
MARIJA ANDONOVSKA; NATASA STAVREVA  
FYROM

**FIXED PROSTHODONTICS**

**Introduction:** The appropriate use of Charters' tooth brushing technique is of significant value in the therapy and prevention of gingival inflammation. Goal: This papers goal was to show how severe was the correlation between gingival inflammation and Charters' tooth brushing technique on patients with fixed prosthodontics. **Material and methods:** We instructed 30 patients whit fixed prosthodontics on the tooth brushing technique by Charters', verbally and with the use of instructional fliers. We noted the gingival inflammation according to Cowell's index in individual patient files in the following 4 time periods - on the patients first visit, after 15 days, after 1 month and after 3 months. **Results:** The value of the index for gingival inflammation in the group of subjects on their first visit varied in an interval of  $1,72 \pm 0,53$ ;  $\pm 95,00\% CI: 1,50-1,94$ , the minimum value being 0, and the maximum 2.50. In the subsequent visits, the value of the index for gingival inflammation after three months (Mean=0.76) of receiving the instructions on Charters' technique, where  $Z=4.29$  and  $p < 0.001$  ( $p.000$ ), the value decreased significantly compared to the value of the index on the group's first visit (Mean=1.72). **Conclusion:** The results of the study on the gingival inflammation on patients with fixed prosthodontics, showed that using appropriately using Charters' tooth brushing technique can lead to significant improvements in the periodontal health, improving the index of the group by 55.8%, a fact that leads us to the conclusion that this is the most adequate tooth brushing technique for patients with fixed prosthodontics.

**PP 13 ALVEOLAR FRACTURE AND TREATMENT PLANNING: A CASE REPORT**

SINAN YASIN ERTEM; MURUDE YAZAN  
Turkey

**ORAL SURGERY AND ORAL MAXILLOFACIAL SURGERY**

Falls, sports activities, traffic accidents, etc. often cause maxillofacial trauma and traumatic dental injuries. The types of injuries vary depend on the type and location of the force exerted during the injury (1). During dental and alveolar development, children and adolescents are mostly affected (2). Glendor stated that most traumatic dental injuries affect especially the anterior teeth

and particularly maxillary incisors in a 12-year systematic review of the literature (3). Teeth associated with alveolar fractures are characterized by mobility of the alveolar process; several teeth typically will move as a unit when mobility is checked. Occlusal interference is often present. A 9-year-old female who injured her maxillary anterior region and lip during a fall was presented to our department. Her upper lip was lacerated with swelling and epistaxis, and she had a maxillary alveolar bone fracture. Teeth associated with alveolar fracture had mobility with the fracture segment. Under local anesthesia, we repositioned bone segment and fixed the teeth with splinting. In prognosis of our case, no symptoms of inflammatory root resorption or ankyloses have observed for 6 months of follow up based on both clinical and radiographic findings. The aim of this report is to describe and discuss the management of a pediatric patient with a maxillary alveolar bone fracture.

**PP 17 THE USE OF ALLOGRAFTS IN THE ATROPHIC POSTERIOR MANDIBLE PRIOR TO IMPLANT PLACEMENT**

LUAN MAVRIQI; ILMA ROBO; EGRESA BACA; ARIONA DEMIRAJ;  
BLEDAR MAVRIQI

*Albania*

**ORAL IMPLANTOLOGY**

**Backgrounds:** New technique for vertical ridge augmentation in severe atrophic mandible.

**Material and methods:** A 49-year-old female patient was presented with a bilaterally atrophic mandible and a need for implant therapy. Con-beam Ro showed mandibular ridges that were not suitable for immediate implant placement in terms of height (6,2 mm on the left side and 7,2 on the right side). Two vertical and one horizontal bone cuts using piezoelectric instrument were made 2 mm above the mental foramen. The more mesial vertical cut was performed 2 mm away from the adjacent tooth. The bone segment was then raised upward to leave space for the bone graft. An allogeneic bone block was inserted interpositionally and placed in the middle of the space formerly created without any fixation between the basal segment and the cranial segment. The remaining spaces in both ends were filled with particular bone graft. The wound was then closed primarily. After 3 months endosseous implants were inserted, two into the right side, and three in the left side of the mandible, measuring 4 mm in diameter and 10 mm in length. **Results:** In this case the placement of implants of 10 mm in height was made possible with vertical ridge augmentation (6,2 mm on the left side and 7,2 on the right side), using the technique of sandwich osteotomy. **Conclusion:** The technique permits dental rehabilitation in terms of raising the bone above the nerve, reshaping the alveolar crest, and normalizing the interocclusal distance and the crown-implant ratio.

**PP 18 SQUAMOUS CELL CARCINOMA OF ORAL MUCOSA: A CASE REPORT**

BURCU KIRSAN; ALI ABU HANTTASH; HAKAN EREN

*Turkey*

**ORAL PATHOLOGY-ORAL MEDICINE**

**Introduction:** Squamous cell carcinoma (SCC) is the most seen malignant tumor of the oral cavity. There are several histopathological subtypes of this neoplasm, and also, every subtype has a

different clinical expression and specific behavior. Although uncertain that there is an association between SCC development and bad oral habits like use of alcohol, smoking or bad oral hygiene, survival rate is generally low in these patients. The most common regions that SCC develops are the most frequently exposed to chronic trauma in oral cavity. **Case Report:** This case report represents a 62 years old female patient who has been referred to our hospital with an ulceration in the left cheek mucosa. Patient's anamnesis and clinical examination have shown that development of the tumor might be related to chronic trauma of removable partial prosthesis. Clinical and histopathological findings were also expressed. **Result:** Chronic trauma causes SCC in the oral cavity. Clinicians should be aware of unhealed ulcerations in the oral mucosa.

**PP 19 HODGKIN'S LYMPHOMA OF MAXILLA: A CASE REPORT**

CEREN YILDIRIM; ÖZLEM MARTI AKGÜN; MEHMET KAPLAN;  
EDA ARAT MADEN

*Turkey*

**ORAL PATHOLOGY-ORAL MEDICINE**

**Aim:** Hodgkin's lymphoma (HL) is a cancer of the lymphatic system. In HL, lymphocytes grow abnormally and out of control. It is not known exactly what causes this cancer; it can occur at any age, but is most common in adolescence. This case report concerns a 13-year-old boy with an unerupted maxillary premolar tooth caused by Hodgkin's lymphoma. **Case report:** A 13-year-old boy was referred to the Pediatric Dentistry Department complaining of an unerupted maxillary premolar tooth. Radiographic examination revealed a radiopaque mass in close proximity to the crown of an unerupted tooth. This lesion was an obstructed eruption of the maxillary right premolar tooth. During a consultation at the oral and maxillofacial surgery department, the lesion was surgically excised. The lesion was diagnosed via a biopsy as Hodgkin's lymphoma. The patient was followed up after six and 12 months postoperatively. After the surgery, the tooth slowly progressed to eruption. **Conclusion:** HL accounts for less than 5% of malignancies in children under the age of 15 years. Biopsy and early diagnosis of HL are crucial in order to choose an appropriate therapy.

**PP 20 TONSILLOLITH OF PALATINE TONSILS: A CASE REPORT**

ALI ALTINDAG; MEHMET HAKAN KURT; MEHMET ERAY KOLSUZ

*Turkey*

**ORAL DIAGNOSIS-ORAL RADIOLOGY**

**Introduction:** Tonsilloliths are calcifications within a tonsillar crypt, involve primarily the palatine tonsil caused by dystrophic calcification as a result of chronic inflammation. Tonsilloliths are relatively uncommon findings. Tonsillolith are usually asymptomatic however tonsillar concretions sometimes produce symptoms which include non-specific chronic halitosis, irritable cough, dysphagia, otalgia and foreign body-like sensation or foul taste. They are usually single and unilateral, but occasionally may be multiple or bilateral. In this case we reported bilateral tonsillolith occurrence. **Case report:** 55-year-old man was admitted to our clinic on the

recommendation of a dentist, due to the many small radiopaque mass which seen on panoramic radiographs. Clinical intra-oral examination showed white plaques on the left tonsil, asymptomatic and with no history of recurrent tonsil inflammation. For the exact location of the images, a computed tomography scan of the maxillofacial region/head and neck was requested; with hyperdense images being seen on both palatine tonsils, confirming the diagnosis of tonsillolith. **Conclusion:** Unilateral or bilateral tonsilloliths are an extremely rare finding, which may be detected on routine radiographic examination. It should be considered in the differential diagnosis of radiopaque lesions comprising the mandible. When in doubt, advanced imaging techniques such as CBCT scan and MRI may verify substantial in establishing a definitive diagnosis.

**PP 21** EVALUATION OF REINFORCEMENT EFFECT ON TEETH BY USING INTERNAL MATRIX COMBINED WITH MTA

EMRE BAYRAM; HUDA MELIKE BAYRAM; HAKAN EREN

*Turkey*

**ENDODONTOLOGY**

**Aim:** The aim of this study was to determine the effect of the apical foramen diameter and different application methods of MTA on the fracture resistance of simulated immature teeth using a Universal Testing Machine. **Material and methods:** Ninety extracted human teeth were used for the fracture resistance test. In our study, the apical foramen was prepared to a diameter of 1-1.4 mm in width to simulate the open apex of immature teeth. MTA was mixed according to manufacturer's recommendations and placed into the root canals with different apical foramen diameter by four different root filling techniques: retrograde, two-phased orthograde, and ortograde with or without internal matrix way. Prepared roots were marked 2 mm below the cement-enamel junction, embedded in transparent acrylic resin and poured into cylinder moulds. Vertical force was applied along the long axis of the tooth at a speed of 5 mm/min, and the maximum resistance to fracture for each tooth was determined in Newtons. SPSS 20 software was used for statistical analysis of fracture resistance data. The data was analyzed with one-way ANOVA and post-hoc Tukey tests. **Results:** A statistically significant difference could not be observed between the groups; there was a statistically significant difference between the test groups and control groups only. **Conclusion:** There was no significant difference between different vertical root filling techniques in increasing the fracture strength of teeth. The width of the apical opening did not have a significant effect on the fracture resistance.

**PP 24** HODGKIN'S LYMPHOMA OF MAXILLA: A CASE REPORT

CEREN YILDIRIM; ÖZLEM MARTI AKGÜN; MEHMET KAPLAN;

EDA ARAT MADEN

*Turkey*

**HOSPITAL DENTISTRY**

**Aim:** Hodgkin's lymphoma (HL) is a cancer of the lymphatic system. In HL, lymphocytes grow abnormally and out of control. It is not known exactly what causes this cancer; it can occur at any age, but is most common in adolescence. This case report concerns a 13-year-old boy with an

unerupted maxillary premolar tooth caused by Hodgkin's lymphoma. **Case report:** A 13-year-old-boy was referred to the Pediatric Dentistry Department complaining of an unerupted maxillary premolar tooth. Radiographic examination revealed a radiopaque mass in close proximity to the crown of an unerupted tooth. This lesion was an obstructed eruption of the maxillary right premolar tooth. During a consultation at the oral and maxillofacial surgery department, the lesion was surgically excised. The lesion was diagnosed via a biopsy as Hodgkin's lymphoma. The patient was followed up after six and 12 months postoperatively. After the surgery, the tooth slowly progressed to eruption. **Conclusion:** HL accounts for less than 5% of malignancies in children under the age of 15 years. Biopsy and early diagnosis of HL are crucial in order to choose an appropriate therapy.

**PP 28** **TEMPERATURE FLUCTUATIONS IN SOFT TISSUES DURING THE TREATMENT OF PERIODONTITIS CRONICA GRANULOMATOSA DIFFUSA CUM FISTULAE**  
MARIA DENCHEVA; OLIA MARTINOV; STELLA HRISTOVA

*Bulgaria*

**NEW TECHNOLOGIES**

**Background:** Thermovisiography is considered to be an easily accessible and highly innovative diagnostic method in contemporary dentistry. It is based on detection and analysis of temperature fluctuations of the soft tissues in the maxillofacial region and it is a fundamental procedure in the overall process of focal dental diagnostics. Applying Infrared diagnostics allows for detecting functional changes in tissues and close monitoring of affected areas throughout the duration of the healing process. **Methods and Materials:** We are presenting a thermovisiography diagnostics case of a 47 year old female diagnosed with Periodontitis chronica granulomatosa diffusa cum fistulae on tooth #12. Our treatment protocol consisted of a few consecutive appointments for mechanical and chemical treatment of the root canal. The intention was to prevent further infection and stimulate the healing process. One iontophoretic procedure with I-KI was applied as well. After each manipulation a thermal image was captured by Flir T620 camera. **Results:** The temperatures observed during the treatment process correlated with the subsiding clinical infection. After the application of one iontophoretic procedure we found a clinical exacerbation along with a 1.2°C increase in local temperature. **Conclusion:** The temperature of soft tissues surrounding the fistula correlates with the healing process. By using thermovisiography we found exacerbation of the periodontitis and increase in inflammatory symptoms immediately after the iontophoretic procedure due to which we made alterations in our treatment plan.

**PP 29** **CLINICAL-BIOLOGICAL STUDY OF RHEUMATOID ARTHRITIS INFLUENCE ON SALIVARY BIOMARKERS ON PATIENTS WITH PERIODONTAL DISEASE**  
RADU-MĂDĂLIN BOATCĂ; LOREDANA HURJUI; IOANA RUDNIC;  
OVIDIU NICOLAICIUC; SILVIA MĂRȚU

*Romania*

**PERIODONTOLOGY**

**Background:** Our purpose was to identify if rheumatoid arthritis (RA) influenced levels of salivary biomarkers of periodontal disease. **Materials and method:** Biological assessments and

periodontal examinations were performed on 15 patients with RA, 10 patients with chronic periodontitis and 11 healthy patients as control group. Unstimulated whole saliva samples were analyzed for interleukin-1b (IL-1b) and tumor necrosis factor- $\alpha$  (TNF- $\alpha$ ) concentrations. **Results:** The arthritis and healthy groups had significantly less oral disease than the periodontitis group but the arthritis group having significantly more sites bleeding on probing (BOP) than control group. Salivary levels of IL-1b were significantly elevated in the periodontal disease group and IL-1b was the only biomarker with significantly higher levels in the arthritis group compared with control group. Arthritis patients receiving anti-TNF- $\alpha$  antibody therapy had significantly lower IL-1b and TNF- $\alpha$  levels compared with arthritis patients not on anti-TNF- $\alpha$  therapy and healthy controls, respectively. **Conclusion:** RA patients have higher levels of periodontal inflammation than healthy control group and also an increased BOP. Systemic inflammation appears to influence levels of select salivary biomarkers of periodontal disease, and anti-TNF- $\alpha$  therapy significantly modify in lowers salivary levels IL-1b and TNF- $\alpha$  levels in RA. Keywords: salivary biomarkers, interleukin 1b, tumor necrosis factor (TNF) periodontal disease, rheumatoid arthritis.

**PP 30 IATROGENIC EFFECTS OF ADULT ORTHODONTIC TREATMENT ON ROOT RESORPTION DEGREE AT INCISORS**

CĂTĂLINA DĂNILĂ; IOANA RUDNIC; ANCA MIHAELA STUPU; SILVIA MĂRȚU  
*Romania*

**PERIODONTOLOGY**

**Background:** Iatrogenic effects associated with orthodontic treatment are: the effect of orthodontic rings on periodontium; gingival recession; effect on dental root (root resorption); effect on alveolar bone height; mobility and pain associated with orthodontic treatment. The purpose of the study is assessing the degree of root resorption of incisors after orthodontic treatment in a group of 88 adults with malocclusions. **Materials and methods:** The study included 48 young adult patients, 35 women and 13 men aged 18-30years who received fixed orthodontic treatment. To assess the degree of root resorption (changes of contour length of root and apical zone) were performed periapical and panoramic radiographs at beginning and at the end of orthodontic treatment at maxillary and mandibular incisors. **Results:** The severity of the degree of root resorption was determined at the beginning and end of orthodontic treatment at the central and lateral incisors, maxillary and mandibular. Severe resorption which interested in more than a quarter of root length have a reduced incidence. Severe root resorption occurred at only 9 incisors, ie 1.4% of the total 639 examined incisors. **Conclusions:** Root resorption is a multifactorial phenomenon on that primarily affect supper incisors, lateral incisors and teeth with specific root form. Results of our study shows that orthodontic treatment generally occurs in adult with iatrogenic effects clinically acceptable for to achieve functional and aesthetic objectives.



PP 31

**LASER ASSISTED VERSUS CONVENTIONAL FRENECTOMY IN ORTHODONTIC PATIENTS**IONUT LUCHIAN; IOANA MÂRȚU; ANCUȚA GORIUC; MONICA TATARCIUC;  
IRINA ZETU; SILVIA MÂRȚU*Romania*

PERIODONTOLOGY

**Background:** The aim of this study was to evaluate the laser assisted frenectomies versus conventional ones from the technique and the post-op recovery point of view. **Material and method:** We selected a sample population of 20 patients with thick, low inserted maxillary midline frenum and midline diastema. We randomly divided the sample population into two groups named A and B with an equal number of patients. Patients included in group A were randomly treated with conventional technique while patients included in group B were benefited of laser assisted frenectomy. **Results:** Our findings showed that laser assisted procedure was much faster to perform than the conventional one due to the easier protocol, absence of sutures and better cooperation from the patient side. In the same time it provided a better comfort degree to the patient and an accelerated healing. **Conclusions:** Laser assisted technique for maxillary midline frenectomy in conjunction with orthodontic treatment proved to be superior to the conventional one because it saves time, it's minimally invasive and provides a better cooperation with the child.

PP 33

**EVALUATION OF THE EFFICIENCY OF TWO TYPES OF PERIODONTAL PROBING**ALEXANDRA MÂRȚU; COSMIN POPA; IONUT LUCHIAN; IOANA MÂRȚU;  
CORNELIA OANȚĂ; SILVIA MÂRȚU*Romania*

PERIODONTOLOGY

**Background:** We proposed a comparative evaluation of the efficiency of periodontal probing with conventional periodontal probe and electronic periodontal probe. **Materials and methods:** We examined 57 patients, each patient being subjected to conventional and electronic probing. We assessed the tolerance degree for each probing type and also the time consumed by probing and periodontal charting. **Results:** The periodontal probing with the electronic probe revealed superior results regarding the accuracy of the measurements, the tolerance level and the time consumed. The electronic periodontal probe an exceptional accurate method, with a high value in establishing the diagnosis and also in assessing the treatment results. **Conclusions:** The electronic periodontal probe represents an efficient and useful tool for measurements of the gingival sulcus and periodontal pockets and also for the determination of the periodontal risk.

**LASER ASSISTED SURGICAL MANAGEMENT OF DIFFERENT TYPES OF GINGIVAL ENLARGEMENTS**

IOANA MÂRTU; IONUT LUCHIAN; ANCUȚA GORIUC; ALEXANDRA MÂRȚU;  
DIANA MIRWALD; MONICA TATARCIUC

*Romania*

**PERIODONTOLOGY**

**Background:** Neoplasms account for a comparatively small proportion of gingival enlargements and make up a small percentage of the total number of oral neoplasms. The same authors underline that in a survey of 257 oral tumors, approximately 8% occurred on the gingiva. This poster will try to emphasize how to establish the correct diagnosis and proper surgical decision regarding different types of gingival benign tumors. **Materials and method:** We have selected a sample population of 10 patients referred to the periodontist by general dentists with different types of gingival enlargements. We have used a 940 nm wavelength laser to perform the surgeries and we have requested a histopathology exam in order to confirm our clinical diagnosis. We will present particularities of the surgical technique specific to each type of tumor and we will try to underline the minimally invasive dimension of it on preserving the soft tissues. **Results:** The use of lasers as a replacement of the scalpel has the great advantage that you can mark the limit of the incision prior the cutting procedure. This will help the operator on one hand to set a correct safety limit inside the healthy tissue and on the other hand to be minimally invasive with these types of soft tissues. **Conclusions:** The laser assisted surgeries are faster, with insignificant bleeding and painless postoperative recovery. Although most of the gingival benign tumors have a high recurrence rate after laser assisted surgery we have registered none in our sample population.

**EVALUATION OF CLINICAL EFFECTS OF OCCLUSAL TRAUMA ON GINGIVAL RECESSION**

MIHAELA MOISEI; COSMIN POPA; IOANA RUDNIC; NICOLETA IOANID;  
DANA POPA; SILVIA MARTU

*Romania*

**PERIODONTOLOGY**

**Background:** The aim of this study was to investigate the occlusal contacts during maximum intercuspation to protrusive, lateroprotrusive and lateral excursive movements and their effects on gingival recession. **Material and method:** Fourteen subjects having gingival recession aged by 18–53 years old were selected, examined about the location and extent of gingival recession and occlusal wear facets were recorded. The type of occlusion and the nature of occlusal contact in maximum intercuspation and eccentric mandibular movements were also recorded using articulating foil. **Results:** Our results indicated that gingival recession was more frequent in patients with occlusal function group than at patients with occlusal canine protection. At patients with occlusal canine protection gingival recession was located on the labial surface while at patients with function group recession was equally distributed on vestibular surface of the teeth in the anterior and posterior areas. Almost all patients with interference in protrusive, lateroprotrusive movements had teeth with gingival recession. Also abrasion was observed in most teeth with gingival recession.

**Conclusions:** These results suggest that occlusal interferences in maximum intercuspation and eccentric movements in one form or the other and absence of mutually protected occlusion can contribute to gingival lesions such as gingival recessions.

**PP 37 THE ASSOCIATION BETWEEN THE SEVERITY OF CHRONIC PERIODONTITIS AND CAROTID IMT IN PATIENTS WITH ATHEROSCLEROSIS**

OVIDIU NICOLAICIUC; IRINA URSARESCU; TEODOR ȘTEFANACHE;  
DIANA NIȚESCU; LILIANA PĂȘĂRIN; SILVIA MARTU

*Romania*

**PERIODONTOLOGY**

**Background:** Our aim was to evaluate the relationship between the degree of carotid atherosclerosis and severity of periodontitis in a patient cohort. **Material and methods:** The study was conducted on 35 adult patients receiving carotid duplex scans. Patients were divided into two main groups: the test group had IMT  $\geq 1$  mm or the presence of any carotid atherosclerotic plaque (n=20), and the control group had IMT  $< 1$  mm and absence of atherosclerotic plaques (n=15). Periodontal evaluation was performed in all the teeth and characterized according to the clinical attachment loss, which between 1 mm and 2 mm was classified as slight, 3 mm and 4 mm as moderate and  $\geq 5$  mm as severe. **Results:** The most common diagnosis was severe periodontitis (40%); moderate and slight periodontitis were also frequent occurrences (32% and 28%, respectively). In the control group, 53.3% had slight, 33.3% had moderate and 13.3% had severe periodontitis. In the test group, those percentages were respectively 22.2%, 44.4% and 33.3%. Patients with atheroma plaque had the highest percentage of severe periodontitis (70.6%). **Conclusions:** We demonstrated an association between periodontitis severity and carotid atherosclerosis, suggesting that periodontal disease might be a risk indicator for atherosclerotic disease.

**PP 38 THE EVALUATION OF THE ASSOCIATION BETWEEN CHRONIC PERIODONTITIS AND THE PREVALENCE OF HEAD-NECK CARCINOMA**

DIANA NIȚESCU; IOANA MARTU; CRISTIAN MARTU; IRINA URSĂRESCU;  
TEODOR ȘTEFANACHE; SILVIA MARTU

*Romania*

**PERIODONTOLOGY**

**Background:** The aim of this study was to assess the effect of chronic periodontitis on head and neck squamous cell carcinoma (HNSCC). **Materials and methods:** The study population consisted of 46 patients, divided in two groups: patients diagnosed with primary HNSCC (n=26) (the study group) and patients negative for malignancy (n=20) (control group). The severity of periodontitis was measured by alveolar bone loss (ABL) from standardized panoramic radiographs. **Results:** Each millimeter of ABL was associated with  $>4$ -fold increased risk of HNSCC. The strength of the association was greatest in the oral cavity, followed by oropharynx and larynx. The association persisted in subjects who never used tobacco and alcohol. **Conclusions:** Chronic

periodontitis could represent an independent risk factor for HNSCC. These results have implications for practical and safe strategies for prevention, diagnosis, and treatment of HNSCC.

PP 39

**THE EFFECTS OF THE GLICEMIC CONTROL AND OF NON-SURGICAL PERIODONTAL THERAPY IN DIABETES MELLITUS PATIENTS**

CORNELIA OANȚĂ; ALEXANDRA MÂRȚU; LILIANA PĂȘĂRIN; MIHAELA MOISEI; IRINA URSĂRESCU; SILVIA MARTU

*Romania*

**PERIODONTOLOGY**

**Background:** The aim of the study was to evaluate the relationship between the diabetic status and the severity of the periodontal involvement and also of the non-surgical periodontal therapy on the periodontal status in patients with diabetes mellitus. **Materials and method:** The study was conducted on 21 patients with type I diabetes mellitus (study group) and 10 systemically healthy subjects (control group). We examined: the glycemc control (by measuring the glycosylated hemoglobin), the periodontal and oral hygiene parameters at the baseline and after 4 weeks, 6 months and 12 months after the periodontal treatment which consisted in scaling and root planning. **Results:** The subjects with a poor glycemc control presented a higher percentage of sites with attachment loss, significantly higher amounts of bacterial plaque and sub-gingival calculus and gingival bleeding when compared with the control group or the subjects with good or moderated glycemc control. In the same group we observed a rapid recurrence of the deep periodontal pockets after 12 months. **Conclusions:** The prolonged poor control of glycaemia and the lasting of the diabetes were closely related with its complications. The comparisons between the diabetes and the control groups demonstrated that diabetes mellitus is a risk factor for the periodontal disease.

PP 40

**THE INFLUENCE OF SCALING AND ROOT PLANING ON THE GLICEMIC STATUS IN DIABETES MELLITUS PATIENTS**

LILIANA PĂȘĂRIN; IRINA URSĂRESCU; SORINA-MIHAELA SOLOMON; ALEXANDRA MÂRȚU; TEODOR ȘTEFANACHE; SILVIA MARTU

*Romania*

**PERIODONTOLOGY**

**Background:** The study proposes an assessment of the influence of the periodontal disease therapy by scaling and root planning on the glycemc status in patients with type II diabetes mellitus. **Materials and methods:** The study was conducted on 36 patients (18 patients - treatment group: patients with type II diabetes mellitus who received therapy for chronic periodontitis during a 9 month period and 18 patients - control group: patients with diabetes mellitus type II who did not receive periodontal treatment). Glucose control was determined by measures of glycated hemoglobin. **Results:** There was a 6.7% improvement in glycemc control in the control group when compared to a 17.1% improvement in the treatment group, a statistically significant difference. Several parameters that could confound or moderate this glycemc control were explored. These included the treatment of non-dental infections, weight and medication changes. No moderating

effect was associated with any of these variables. **Conclusions:** The periodontal therapy generated an improved glycemic control in patients with type II diabetes mellitus and chronic periodontitis.

**PP 41** **EVALUATION OF THE OCCLUSAL TRAUMA UPON THE ODONTO - PERIODONTAL STATUS OF PROSTHESES PATIENTS**  
COSMIN POPA; IONUT LUCHIAN; IOANA MÂRȚU; ALEXANDER MIRWALD;  
IOANA RUDNIC; SILVIA MARTU  
*Romania*

#### PERIODONTOLOGY

**Background:** The scope of the present study was to clinically evaluate the iatrogenic factors as well as the odonto-periodontal status of the teeth included in prosthetic works and their relations with the neighboring ones. **Materials and method:** The experimental group was formed of 40 patients subjected to prosthetic treatment, including thorough clinical evaluations, analysis of all factors contributing to the occurrence of occlusal trauma and, implicitly, of the subsequent periodontal disease. The mean values were calculated with the statistical Wilcoxon and t tests, permitting to compare the evaluations. **Results:** Out of the total number of patients considered for the study, 68.18% have been treated through fixed prosthetic therapy and 31.82% - through mixed prostheses. Among them, 47.27% had occlusal trauma. More numerous occlusal disorders were registered in patients with mixed prostheses (61.20%), comparatively with those with fixed prosthesis (43.58%). **Conclusions:** The results of the present study evidence that the teeth involved in mixed prosthetic works may frequently show signs of occlusal trauma, but not necessarily and always accompanied by an irreversible destruction of the periodontal tissue.

**PP 42** **MICROBIOLOGICAL EVALUATION OF INTERFERENCE BETWEEN HSV-1 AND PERIODONTAL BACTERIA SPECIES**  
IOANA RUDNIC; CĂTĂLINA DĂNILĂ; MARIUS ANDREI DINU; VERONICA  
ȘERBAN; ANCA MIHAELA STUPU; SIMONA GRIGORAȘ  
*Romania*

#### PERIODONTOLOGY

**Background:** This research investigates the presence of herpes simplex virus type 1 in the lesions of chronic and aggressive periodontitis and the association of this virus with potential periodontal bacteria. **Material and method:** Subgingival plaque samples were collected from 19 patients diagnosed after clinical examination and laboratory with periodontal disease (12 patients with chronic periodontitis, 7 patients with aggressive periodontitis). Work steps have provided for: preparation of samples; preparation of reagents; processing of samples. **Results:** HSV- 1 + T. denticola was detected in a higher proportion (21% for CP group and 12% for the group AMP) is followed by HSV- 1 + P. intermedia with 10% CP and 19% for the group for the group page, the lowest value was recorded for HSV-1 + E. corrodens (1% to 4% respectively CP group group for PAG group). Crevicular fluid microbiological assays revealed that P. gingivalis, P. intermedia and A.actinomycetemcomitans were detected in a higher proportion (18%, 23% and 12%) in the group

with HSV cohabitation and aggressive periodontitis. Representative values were recorded for HSV-1 and T.denticola (19% in the group with chronic periodontitis and 17% at the aggressive). **Conclusions:** The results support the hypothesis that the clinical situation encountered in certain types of severe periodontal infection depends on the presence of herpes-specific and specific pathogens. Our findings lead to further testing of a variety of hypotheses concerning the association of viruses bacteria in areas affected by periodontal disease.

**PP 44 THE CLINICAL EFFECTS OF THE DRUG ADJUNCTIVE THERAPY IN THE CHRONIC GENERALIZED PERIODONTITIS-OSTEOPOROTIC DISEASE ASSOCIATION**

IRINA-GEORGETA URSĂRESCU; LILIANA PĂȘĂRIN;

SORINA-MIHAELA SOLOMON; ALEXANDRA MĂRȚU; SILVIA MĂRȚU

*Romania*

**PERIODONTOLOGY**

**Background:** The present study proposes an assessment of the clinical effects on periodontal level generated by the adjunctive periodontal therapy with sub-antimicrobial doses of doxycycline in patients with chronic periodontitis and osteoporosis. **Materials and methods:** The study group was comprised of a number of 26 patients with chronic periodontitis and osteoporosis, divided in study group (classical periodontal debridement and sub-antimicrobial doses of doxycycline for 3 months) and the control group (classical debridement only). We analyzed the periodontal parameters (probing depth, clinical attachment level, the PBI and PI indices) at baseline, in the last day of medication and at 3 months after the drug therapy. **Results:** The reduction of the moderate and profound pockets was higher for the group with drug adjunctive therapy. The sites with an initial depth of 0-3mm in the study group presented also a slight attachment gain. **Conclusions:** The therapy with sub-antimicrobial doses of doxycycline generated significant clinical improvement in patients with chronic periodontitis and osteoporosis, an improvement which can reduce the necessity of surgical procedures.

**PP 46 CLINICAL SUCCESS OF TWO MATERIAL ON DIRECT PULP CAPPING**

MEHMET SAHIN OGUZCAN; ISMAIL HAKKI

*Turkey*

**RESTORATIVE AND ADHESIVE DENTISTRY**

**Background:** The aim of this study is to evaluate clinical and radiographic success rate of two different direct pulp capping materials (a light cured, resin-modified calcium silicate filled liner, and mineral trioxide aggregate) when used as direct pulp capping material in primary molar teeth. **Methods and materials:** 24 patients who had at least two primary molar teeth with deep caries was chosen on that clinical study. 48 molar teeth in 24 patients were treated, following teeth anaesthetization, during cavity preparation caries were removed and pulps were exposed, and after activation of haemostasis, exposure points were capped with MTA or TheraCal LC, based with zinc-oxide eugenol cement and restored with amalgam. Clinical and radiographic follow up were called

after 12 months. **Results and Conclusion:** Twelve month clinical and radiographic follow-up were 44 teeth. 2 patients were failed to return after follow up. There were no clinical or radiographic evaluations did show experimental groups. There is no significant difference between treatment outcomes of direct pulp capping with either mineral trioxide aggregate or light cured resin modified calcium silicate liner can be used for direct pulp capping in primary teeth, further histological investigations are needed to support studies.

**PP 47** **THERAPY APPROACH IN TREATMENT OF COMBINED ENDO-PERIO LESION**  
ANETA ATANASOVSKA STOJANOVSKA; SASHKA TODOROSKA; MIRJANA  
POPOVSKA; VERA RADOJKOVA NIKOLOVSKA; ILIJANA MURATOVSKA  
*FYROM*

#### PERIODONTOLOGY

Periodontal disease in its final stage leads in to loss of periodontal tissues, it can even endanger dental pulp. Sometimes untreated primary endodontic lesion may become secondarily involved with periodontal breakdown. **Aim of the study:** This case report shows a combination of endodontic and periodontal surgical procedures with ultimate goal to save a tooth previously defined as hopeless. **Material and method:** A 42- year- old male, was referred to our clinic with pain coming from a deep periodontal pocket around the tooth 16. The tooth was already under endodontic treatment. Radiography, clinical probing depths and attachment level were recorded before the treatment and tree months after. A periodontal treatment was conducted, directions for good oral hygiene were given and antibiotic was prescribed. Two weeks later, clinical parameters were improved and appointment for periodontal surgery was scheduled. Modified Widman flap was raised and careful scaling and root planning on teeth 17, 16 and 15. Vertical bone defects were filled with Bio-Oss. Flap was adapted to the teeth and fixed with stitches. Ten days later, clinical findings were fair, patient had no pain. Tree month's later we recorded reduction in pocket depth and gain in clinical attachment level. **Result:** With periodontal regenerative therapy we have accomplished reduction in probing depth and gain in clinical attachment level. Combining periodontal regenerative and endodontic microsurgery achieved good therapeutic effect for endo-perio lesion in our case. **Conclusion:** Therapy directed at the resolution of inflammation, removal of the periopathogens and application of Bio-oss, enhance clinician ability to deal with complex clinical problems.

**PP 49** **COMPLICATED CROWN FRACTURE WITH IMMATURE ROOT DEVELOPMENT -**  
**A CASE REPORT**  
ZORAN MANDINIC; ANA VUKOVIC; MOMIR CAREVIC; JELENA MANDIC;  
SVETLANA NOVAKOVIC  
*Serbia*

#### PAEDIATRIC DENTISTRY

**Background:** Crown fractures of permanent upper incisors, occur most frequently in comparison to all dental injuries. **Case report:** An 8- year-old boy was referred to the Clinic of Paediatric and Preventive Dentistry, School of Dental Medicine, University of Belgrade with

complicated crown fracture of both permanent upper central incisors (11 and 21), 24 hours after the accident. A fracture of enamel and dentine with pulp exposed and immature root development was diagnosed based on clinical and radiographic evidence. Immediate treatment involved partial pulpotomy on tooth 11 and 21, while definitive restoration was achieved by composite restorations. After 6 months, a complication of injury was occurred on tooth 21, regarding pulp necrosis which required root canal treatment. During next 12 months, root canal was filled by the sterile paste of  $Ca(OH)_2$  every 30 days in order to induce apexification. One year later on tooth 21 the apical perforation was closed and tooth was definitely endodontically treated by the Apexit® sealer and gutta percha points. Follow-up controls of tooth 11 gave positive results to pulp testing at electric pulp test and chlor - ethil test. Two years later, clinical and radiographic examinations revealed no signs of pathology and the patient was satisfied with his aesthetic appearance. **Conclusion:** The present report emphasizes the need to follow a child with severe dental injury and to take an appropriate treatment plan as a key of successful prognosis. Supported by grant of Ministry of Science and Technology, Republic of Serbia no. III 46009.

**PP 52**    **ENDODONTIC TREATMENT OF AN UNUSUAL MAXILLARY MOLAR TOOTH FUSED WITH A PARAMOLAR, A CASE REPORT**

ARSLAN TERLEMEZ; MELEK AKMAN

*Turkey*

**ENDODONTOLOGY**

Fusion is a developmental anomaly of dental hard tissues and defined as a union between the dentin and-or enamel of two or more separate developing teeth. Most cases occur in the anterior region of both the primary and permanent dentitions. Fusion of permanent and supernumerary teeth often occurs in the maxillary anterior region, but a paramolar tooth fused with a molar is a rare case. In the present case the endodontic treatment of a maxillary molar tooth that is uncommon fused with a paramolar tooth, is reported. A 29 year male patient was referred to our clinic with a pain in the maxillary right molar region. Radiographs and intraoral examination showed that the affected tooth was maxillary right first molar tooth, which had fused with a paramolar and been filled with amalgam at the juncture of the 2 tooth crowns. Removal of the filling induced severe bleeding and root canal treatment was performed. The root was observed to be wide in the buccopalatal direction, and endodontic examination revealed that the root canals are united at apical region. Oral clinical findings showed that the fused tooth was composed of two crowns and one root with two united canals, and indicate that each crown and canal should have been treated separately. Because of the fissures or grooves in the union between the fused teeth involved, these teeth have a high predisposition to caries. Dental practitioners should be aware of this unusual teeth and their different canal morphology.



**Background:** The aim of this study was to examine the microleakage values of two different composite resin (Filtek P 60, Clearfil Photo Posterior) in boric acid treated and untreated Class V cavities. **Methods and materials:** Forty caries and restoration-free human premolar teeth were used in this study. Class V cavities were prepared on buccal and palatal surfaces of teeth. Then teeth were divided into 4 groups randomly 10 specimens in each group: Group 1: Boric acid application(1 min.), Single bond universal, Filtek P 60, Group 2: Single bond universal, Filtek P 60, Group 3: Boric acid application(1 min.), Clearfil SE bond, Clearfil Photo Posterior Group 4: Clearfil SE bond, Clearfil Photo Posterior. All restorations were placed by using incremental technique in accordance with the recommendations of the manufacturer and were polymerized using a LED light source. All the teeth were stored in 0.5% methylene blue in 24 hours. The teeth were cut bucco-palatal direction, scored examining under stereomicroscope. The obtained data were evaluated by using Kruskal-Wallis and Mann Whitney U tests. **Results and Conclusion:** When the effect of the application of boric acid on occlusal and gingival scores were analyzed, no significant difference was observed (respectively  $p=0,946$  and  $p=657$ ). Despite the boric acid application created lower microleakage values on Clearfil SE Bond and Clearfil Photo Posterior materials; a statistically significant difference was not observed. Clinical studies are needed in order to support the results of the study.

**Background:** The evaluation of microleakage of different composite placement techniques and new restorative materials are important for assesing the success of the used materials and techniques. The aim of this study was to evaluate the microleakage levels at the margins of the new generation bulk-fill composites which could be placed to the preparation 4 milimeters thickness. **Methods and materials:** Eighty sound and freshly extractad human third molar teeth used in this study. Class V cavities were prepared 4 milimeters depth using diamond cylindrical bur. The prepared teeth divided 4 groups randomly. ( $n=20$ ) Group 1 were restored with a low viscosity bulk-fill composite. (Filtek Bulk-Fill Flowable Restorative, 3M ESPE, Germany) Group 2 and 3 were restored with a posterior bulk-fill composite. (Tetric Evo Ceram Bulk-Fill, Ivoclar Vivadent, USA and SonicFill, Kerr, USA respectively) The Group 4 were restored with a conventional hybrit composite. (Photo Posterior, Kuraray, Japan) All groups divided 2 subgroups. ( $n2=10$ ) One of the subgroups were termocycled 5-55 °C for 1000 cycles. The other ones were not termocycled. Dye penetration was evaluated after immersion in %0.05 basic fuchsin by examining longitudinal

sections in a stereomicroscope. The data analyzed with Pearson Chi-Square test in SPSS 16.0 program. **Results and Conclusion:** All groups showed approximately similar results in gingival and occlusal walls. ( $p>0.05$ ) The gingival cavity walls showed significantly more dye penetration than occlusal walls ( $p<0.05$ ) Finally, it was found that the bulk-fill composites showed similar leakage results with the conventional composite and termocycling were increased the microleakage in all groups.

**PP 57** **COMPARISON OF SHEER BOND STRENGTH OF BULK FILL COMPOSITES WITH POSTERIOR COMPOSITES**

ERTUGRUL ERCAN; ABDÜLKADIR ŞENGÜN ; DAMLA IBRAHIMOV; ESRA GULAL;  
M. MUSTAFA HAMIDI

*Turkey*

**RESTORATIVE AND ADHESIVE DENTISTRY**

**Background:** The aim of this study was to evaluate the shear bond strength of different bulk fill and posterior composite resins. **Methods and materials:** Sixty-caries free human molar teeth were used in this study. Smooth dentin surfaces were revealed by cutting occlusal enamel and standart smear layer was obtained by using 600-800-1000 grid sandpaper, teeth were divided into 4 groups randomly 15 specimens in each group: Group 1: Optibond all in one + Sonicfill composite Group 2: Single bond universal + Filtek P 60 posterior restorative Group 3: Clearfil S3 bond + Clearfil photo posterior Group 4: AdheSE bond+ Tetric evoceram bulkfill 2x3-mm cylindric composite restorations were prepared using application apparatus. After specimens were kept for 24 hours, at 37°C, in distilled water, shear bond strength test was measured with a universal test machine (Esetron) and data were statistically evaluated. **Results and Conclusion:** Sheer bond strength values in groups from high to low, Group III, Group I, Group II and Group IV are listed as. The highest value was observed in Group III study ( $61.49 \pm 18.5$ ) and the lowest bond strength observed value of Group IV ( $47.57 \pm 11.77$ ) respectively. There are significant differences between the two groups ( $p = 0.046$ ) However, there is no statistically significant difference between the bond strength values of other groups. In general, two bulk-fill system values in our study were observed to be lower than the other posterior composite resin group. There is a need for further clinical studies to support the results.

**PP 58** **THE INVESTIGATION OF CAVITY ADAPTATION OF CAD/CAM INLAY SYSTEMS BY SILICON REPLICA TECHNIQUE**

ABDÜLKADIR ŞENGÜN; BERNA ARFAT; DAMLA DOĞAN; ESRA ÜZÜMCÜ

*Turkey*

**RESTORATIVE AND ADHESIVE DENTISTRY**

**Aim:** The aim of this study was to evaluate the occlusal axial fit, and marginal adaptation of inlays made of two composite and computer-aided manufacturing two zirconia-based restorations. **Methods:** Randomly selected eighty molars were divided into four groups. ( $n = 20$ ). Inley cavities were prepared in accordance with the inley principals located 1 mm above the

cemento-enamel junction. The materials used for inlay restorations; Group 1: Clearfill Photo posterior, (Kuraray Medical Tokyo, Japan) Group 2: Filtek P60 (3M Espe, MN, USA) Group 3: Bruxzir (Z-CAD Metoxit AG., Thayngen, Switzerland) Group 4: Prozir (Dental Zirconia, Seramdent Eskişehir, Türkiye) The spaces between inlays and cavities were filled by different coloured light-body polyvinyl siloxane material. Different coloured polyvinyl siloxane material thickness between cavity and inlay was measured at three points (marginal, axial and occlusal gap) using stereomicroscopy with a magnification of 20×. Data was analysed by using Friedman test. **Results:** In comparison of gap formation at occlusal regions and gingival floors, there was no difference in gap values between composite resins ( $P > 0.05$ ). In comparison of gap formation at occlusal and gingival regions, while the two composite group Filtek p60 and Clearfill showed highest gap values, the Prozir group revealed the lowest ( $P < 0.002$ ). Axial gap; Brukzir group revealed the lowest while the two composite group Filtek p60 and Clearfill showed highest gap values ( $P < 0.000$ ). **Conclusions:** In present study the zirconia ceramic showed improved occlusal, axial and marginal adaptation.

**PP 59** HEMISECTION AS A TREATMENT OPTION AFTER ROOT FRACTURE ON MANDIBULAR MOLARS - A CASE REPORT

ELKA RADEVA; TSONKO USUNOV

*Bulgaria*

**ENDODONTOLOGY**

**Background:** Vertical root fractures most frequently occur in posterior teeth. Hemisection is a treatment option in these cases. This procedure represents a form of conservative dentistry, aiming to retain as much of the original tooth structure as possible. **Case report:** This case report presents a hemisection as a treatment option after vertical root fracture of the distal root on mandibular teeth. The patients presented with a dull chronic pain in area of lower first molar and presents of fistula. A radiolucent lesion was noted extending coronal from the apical tip to the furcation around distal root. Root canal treatment was performed years ago and the teeth were restored with composite restoration. The crowns were sectioned at the level of furcation using high speed handpiece and diamond conical bur. The broken distal roots were extracted under local anesthesia. A finishing bur was used to smooth on the margins of the remaining structure. The healing and recovery process is monitored. **Conclusions:** Vertical root fracture is a serious complication with a poor prognosis, often with no other treatment option than extraction of the tooth. Hemisection is an alternative procedure to save part of multi-rooted tooth with root fracture.

**PP 60** EFFECTS OF FILLING TECHNIQUES ON MICROLEAKAGE OF CLASS II RESTORATIONS: ER:YAG LASER VERSUS BUR PREPARATION

EMRE OZEL; ELIF BAHAR TUNA; ERHAN FIRATLI

*Turkey*

**RESTORATIVE AND ADHESIVE DENTISTRY**

**Background:** The purpose of this study was to investigate the effects of two cavity filling techniques on microleakage of Class II resin restorations prepared with Er:YAG laser and diamond bur. **Methods and materials:** Standard MO and DO cavities were performed in 20 extracted third

molars. The teeth were randomly divided into four groups (n=10). Group-1: Herculite Ultra (bur prepared cavity); Group-2: Herculite Ultra (laser prepared cavity); Group-3: Sonicfill (bur prepared cavity); Group-4: Sonicfill (laser prepared cavity). For Groups 2 and 4, cavities were prepared by using an Er:YAG laser with a wavelength of 2.94µm. The output power and repetition rate were 200mJ/pulse and 20Hz. Teeth were restored with a one-step self-etch adhesive material, a nanofill composite and a bulk-fill composite (Sonicfill) according to the manufacturer's instructions. All the teeth were then immersed in 0.5% methylene blue solution for 24h after thermocycling for 1000 cycles (5°C-55°C). Data were analyzed by Kruskal-Wallis and Mann-Whitney U tests(p<0.05). **Results:** Data showed that more microleakage was observed in cervical regions versus occlusal regions in all groups(p<0.05). Group-2 yielded a higher degree of marginal leakage as compared with Group-3 in terms of occlusal surfaces(p<0.05). For cervical regions, statistical significant difference was observed Group-2 versus Group-3 and Group-2 versus Group-4(p<0.05). Group-3 exhibited significantly better marginal sealing compared against Group-1 at the cervical regionn(p<0.05). **Conclusion:** It may be concluded that the cavities prepared by Er:YAG laser showed higher degree of microleakage than those conventionally prepared by bur, regardless of the restorative material at occlusal and cervical margins.

**PP 62 ESTHETIC AND FUNCTIONAL REHABILITATION OF AMELOGENESIS IMPERFECTA WITH DIRECT COMPOSITE RESTORATIONS: REPORT OF FOUR CASES**

NESLIHAN TEKCE; GIZEM GUDER; MUSTAFA DEMIRCI; SAFA TUNCER;  
ALPER SINANOGLU  
*Turkey*

**RESTORATIVE AND ADHESIVE DENTISTRY**

**Background:** The purpose of this case report is to evaluate the performance of conservative and minimally invasive dentistry, in cases of structural anomaly of enamel on four patients who were diagnosed with Amelogenesis Imperfecta. **Methods and materials:** 17 (Case-1), 19 (Case-2), 30 (Case-3) and 17 (Case-4) year-old female patients presented to our clinic because of esthetic reasons regarding Amelogenesis Imperfecta. For the preparation of anterior composite laminate veneers, minimally invasive dentistry was performed; only affected, most external, porous and colored enamel layer was removed about 0.5mm depth and were restored with Clearfil Universal Bond-Clearfil Majesty ES2 composite (shade A2, nanohybrid, Kuraray, Japan) and Single Bond Universal-Filtek Ultimate Body composite (shade A2, nanofilled, 3M ESPE, USA). Also posterior restorations were completed with same approach. Finishing and polishing procedures of the restorations were performed using sequential Sof-Lex discs (3M ESPE, Germany). **Results:** All posterior and anterior direct restorations of the four cases were performed with direct resin composites. The treatment procedures were conservative and inexpensive whereas the esthetical and functional results were satisfactory for the patients. The loss of oral esthetics and function of four patients with Amelogenesis Imperfecta diagnosis were restored conservatively and successfully with contemporary restorative systems. On the other hand, this treatment procedure is a preferable alternative to the other techniques. **Conclusion:** Rehabilitation of esthetics and function with direct resin restorations is not only an inexpensive treatment choice for the patient but also a more conservative technique which reduces the amount of preparation of already disturbed teeth.

**PP 63 TREATMENT OF MODERATE FLUOROSIS WITH COMBINED BLEACHING  
PRTOCOLS**

ISMAIL HAKKI BALTACIOGLU; RUHSAN MÜDÜROĞLU

*Turkey*

**RESTORATIVE AND ADHESIVE DENTISTRY**

**Background:** The patient's concern was the appearance of her maxillary and mandibular teeth, which had a mottled, brown-yellow enamel dysmineralization due to moderate fluorosis. The patient was 45 years old, had lived in Isparta region where drinking water has high concentration of Fluoride ion. Patient was a female doctor and was concerned that the appearance of his teeth would negatively impact interactions with her patients and social life. **Methods and materials:** Step I: Office Bleaching + Home Bleaching (with tray): In-office bleaching treatment (35% hydrogen peroxide gel) applied to patient 1 week after periodontal treatment. Two bleaching trays were fabricated for the maxillary and mandibular arches, and the patient was given a 16% carbamide peroxide bleaching gel to be used with 5 hours tray application for 3 times for every other day. Step II: Enamel Microabrasion One week after initial office bleaching, areas, which still have moderate discolorations treated with micro abrasion paste. Step III: Office Bleaching + Home Bleaching (with tray) One day after microabrasion in-office bleaching treatment applied again and tray bleaching application used 3 times more. **Results and Conclusion:** The combination of micro abrasion, in-office and home bleaching provided faster, non-invasive and satisfactory results.

**PP 65 THE INFLUENCE OF SMOKING ON DENTURE STOMATITIS INCIDENCE**  
SNEZANA RADISIC; SLOBODAN IVIC

*Serbia*

**REMOVABLE PROSTHODONTICS**

**Introduction:** Denture stomatitis is an inflammatory process that spreads over palatal mucous membranes covered with total or partial denture. It is characterized by the mucous inflammation. Patients are complaining about tingling, discomfort, taste disorder. A prevalence of denture stomatitis with patients wearing dentures is in the range from 15% to 75% and it predominantly appears with elder persons and women. Most often, it is the consequence of chronic infection and mechanical injury. *Candida albicans* fungi are the most common causes of the infection. **Aim:** Denture stomatitis recognition, examination of its incidence in regards to smoking as an etiological factor. **Method:** Population of the patients who were coming to denture practice at Health Center Rakovica in the period from July 15th,2014 to January 15th,2015. All of the patients with stomatitis were questioned about their habits, particularly the smoking ones. **Result:** Out of 110 patients who came 18 have had inflammation of the mucous membrane. 12 out of 18 were smokers thus making 66,6%. All patients were suggested a medical nutrition and new dentures have been made if that was necessary. **Conclusion:** Etiopathogenesis of denture stomatitis is multifactorial and the factors themselves could be local and general. As for general factors, apart from diabetes, use of antibiotics, lack of vitamin B12, the smoking is one of the most significant. The

examination has shown that 66% respondents were smokers, which is explained by thermal and toxic effects of tobacco smoke.

**PP 72 REESTABLISHMENT OF OCCLUSION WITH FULL MOUTH REHABILITATION:  
REPORT OF THREE CASES**

YELİZ ARSLAN; HÜSEYİN YAZICIOĞLU; MERVE BANKOĞLU GÜNGÖR

*Turkey*

**INTERDISCIPLINARITY**

Solution of occlusion related problems comes first for good clinical practice and has been a subject of major interest in all areas of dentistry. Occlusal rehabilitation is undertaken for various reasons, most common is improving the stomatognathic function of patients who have dysfunction or disability in chewing or speech because of reduced occlusal vertical dimension, tooth loss or other reasons. Three cases that need occlusal rehabilitation are presented in this case report. First patient was 26 year-old woman who complained about lack of posterior occlusion. The patient was treated with full mouth metal-ceramic fixed dentures. Second patient was 58 year-old woman who had reduced occlusal vertical dimension, poor esthetic, and reduced masticatory function. The patient had five dental implants in the upper jaw and six implants in the lower jaw with remaining teeth. The old prostheses were removed, occlusal vertical dimension were increased, and full mouth metal-ceramic fixed dentures were applied. The third patient was 75 year-old man with reduced occlusal vertical dimension and severe teeth surface loss on the maxillary anterior teeth. The temporary prosthesis with accurate vertical dimension was applied during two weeks period. And the patient didn't complain about the new vertical dimension of the prosthesis. Afterwards remaining teeth were prepared and prostheses were finished at new vertical dimension.

**PP 73 PROSTHETIC REHABILITATION OF PATIENT WITH BILATERAL  
TEMPROMANDIBULAR JOINT ANKYLOSIS : CLINICAL REPORT**

BETÜL KÖKDOĞAN BOYACI

*Turkey*

**REMOVABLE PROSTHODONTICS**

Temporomandibular joint (TMJ) ankylosis is triggered by infection, trauma, and systemic diseases and often impairs oral functions of patients. This case report presents a case of bilateral TMJ ankylosis resulting from trauma. A 70 year-old woman with bilateral ankylosis was referred to prosthetic department. Orthopantomogram examination revealed that the patient was treated with total joint prostheses. Moreover, limited mouth opening was observed in intraoral examination. The patient was treated with total prostheses. However, since lateral jaw movement was not possible, occlusion was regulated in accordance with opening and closing of the mouth. During the observation period, the patient obtained a satisfied function of eating and speaking with prostheses.

**Background:** The self - confidence of the child is related to the perception of their malocclusions and its psychosocial impact. Experiences related with teasing and bullying at school, may play a role in the perception of their malocclusions and the acceptance of orthodontic treatment. **Aims:** To determine the impact of the experience of bullying on The perception of dental aesthetics; The Dental self-confidence level, Psycho-social importance of dental appearance; Aesthetic aspects of dental appearance and The need for treatment among adolescents. **Methods and materials:** The research was conducted among randomly picked 295;16-20 years old students from Macedonia through a questionnaire consisting the PIDAQ; IOTN(AC); Chi square test, t-test, Mann-Whitney U test Kruskal-Wallis, Analysis of Variance, Linear Regression Analysis, Pearson-Conn's coefficient of linear correlation were used. **Results:** There isn't statistically significant difference in the perception of adolescent's dental aesthetics depending registered bullying from peers or the environment, but there is statistically significant ( $p = 0.01$ ) impact of the experiences of bullying from the environment on the subjective treatment need. There is highly statistically significant differences between different IOTN (AC) groups and the level of dental self-confidence, social, psychological impact and aesthetic aspects of malocclusion. The adolescent victims of bullying about dental aesthetics from peers or the environment reported stronger psychological and social impact and lower dental self-confidence. **Conclusion:** The victims of bullying have stronger psychological and social impact of malocclusion and present lower dental self-confidence. The experience of bullying from the environment significantly affects the subjective need for treatment among adolescents. Bullied children have greater need for orthodontic treatment.

**Background:** In teeth with open apices the absence of normal apical constriction of the root canal complicates the management of root filling materials. Therefore root canal filling materials extrude beyond the apex into the periradicular tissues. MTA is used for regeneration of periradicular tissues. MTA is biocompatible with periodontal tissues and it has an excellent sealing ability in the presence of moisture. Also MTA's mechanical properties are adequate as an apical sealing material. **Methods and materials:** In this case a 32 year old male patient suffered trauma to his maxillary central incisors. Right maxillary central incisor tooth has chronic apical periodontitis and left maxillary incisor has necrotic pulp and an open apex. Both teeth were asymptomatic and devital. After the biomechanical preparation, root canal filled with a paste by mixing Calcium Hydroxide powder and salin solution. This step was repeated twice in 14 day period. Then the paste was removed and the root canal of right maxillary incisor was obturated with gutta percha

cones and root canal sealer. For the root canal of the left maxillary incisor the MTA mixture was placed apical portion of the canal (3-4 mm) as an apical barrier. The rest of the canal was obturated with gutta percha and root canal sealer, then the tooth was coronally sealed with composite resin material. **Results:** At 6 months follow-up both teeth were asymptomatic and decreased periapical radiolucency was observed.

**PP 81** A CLINICAL CASE OF COMPLICATION BY SODIUM HYPOCHLORITE DURING ENDODONTIC TREATMENT

AIDA METO; AGRON METO; EMILJANO TRAGAJ; FAUSTINA KOLA

*Albania*

**ENDODONTOLOGY**

**Introduction:** According to several authors, a large number of complications in endodontics are caused due to the incorrect entrance in the endodontic cavity or due to the misuse of the root canal instruments, which relates with the obturation of the canal system, or canal rinse. We are focusing on the sodium hypochlorite solution of 5.25 %. Each root canal irrigant, regardless of toxicity can cause problems if it emerges into the periradicular tissue. **Materials and methods:** A male patient, aged 27, in tooth number 25, diagnosed with symptoms of a total pulpitis. Chemical and physical tests proved positive, without mobility and destructed tooth crown. After that we achieved the extirpation of the corono-radicular pulp in both canals, vestibular and palatine. The rinse was made in passive manners using 5.25% of sodium hypochlorite irrigant. But, at a certain point while the patient was taking the second syringe of irrigation, he sensed a paresthesia pain distributed in the molar and premolar area up to the infraorbital region. **Results:** Antibiotic and cortisone therapy treatment affected the edema and the postoperative pain. Clinical signs were normalized after 8 days, while the ecchymosis after 1 month. This is considered to be a rarely case, anyway it should not be surpassed. **Conclusion:** Complications from the hypochlorite accidentally happens due to the active increasing of pressure by the solution. More attention should be paid not to pass on extremis for the extraction of the tooth; otherwise it should be handled and reconstructed in order to be putted into function. The result is not affected by the sophistry, but from the healing of the periodontium and beyond.

**PP 82** ANTIMICROBIAL ACTIVITY OF PHOTODYNAMIC THERAPY AND FOTOSAN

VIOLETA DOGANDZHIYSKA; SLAVCHO DIMITROV; TSONKO UZUNOV

*Bulgaria*

**LASERS**

**Background:** In recent years the increase of bacterial resistance to various antimicrobial agents stimulate a development of new, alternative methods of treatment such as photodynamic therapy (PDT). The expected effect of photodynamic disinfection in treatment of deep carious lesions is an optimal antimicrobial effect and dental pulp prevention against direct and indirect bacterial injure. **Methods and materials:** The aim of our study was to determine the antimicrobial activity of PDT against four reference bacterial strains - *S.mutans*, *E. faecalis*, *MRSA*, *C. albicans*. There were used photosensitizer FotoSan, with active substance toluidine blue, applied in two concentrations (88,6  $\mu$ M and 44,3  $\mu$ M) and light source- diode laser,  $\lambda = 635$  nm, exposure time 1 and



5 minutes. After treatment, the number of colonies was presented in CFU / ml. **Results:** The most significant antimicrobial effect was determined in application of PDT against *S. mutans* and MRSA strains. *E. faecalis* was more resistant to photodynamic action- maximum effectiveness was established only upon irradiation 5 min for the two tested concentrations. *C. albicans* was the most resistant microorganism to PDT in this study - the effect of photodynamic disinfection was minimal. In control groups were determined negligible dark and light toxicity. **Conclusion:** The appropriate combination of concentration/ dose of photosensitizer and light can lead to full photodynamic response without surviving microorganisms. In dental practice FotoSan is applied undiluted and the expected result is even higher antimicrobial activity in real conditions.

**PP 85 TREATMENT OF TWO CASES OF EARLY CHILDHOOD CARIES UNDER GENERAL ANESTHESIA.**

EIRINI ATHANASIADOU; ANASTASIA DERMATA; AFRODITI CHALKIDOU;  
KONSTANTINOS ARAPOSTATHIS

*Greece*

**PAEDIATRIC DENTISTRY**

**Background:** The disease of early childhood caries (ECC) is the presence of one or more decayed, missing (due to caries), or filled tooth surfaces in any primary tooth in children under age of six. Young patients often present behavioral problems, as the developmental stage of their mental ability does not allow the establishment of necessary communication. This is the presentation of two clinical cases of ecc. **Methods and materials:** A 3 years old male patient visited a pediatric dentistry private practice complaining for pain of 84. Another 4 years old male patient visited the same practice due to esthetic reasons. Patients diagnosed with severe ECC and very poor cooperation. It was decided to complete the treatment under general anesthesia. **Results:** Periapical x-rays were taken under general anesthesia. Restorations of 54,55,63,65,73,75,85, extractions of 51,52,61,62,74,84 and placement of a stainless steel crown on 64 were performed on the first patient. The second patient was treated with pulpotomies of 74,84,85, restorations of 51,52,61,62,74,75,84,85 and extractions of 54,64. The duration of each treatment was about two hours. Both patients were treated under one-day care. **Conclusion:** There exists a patient population for whom routine dental care using nonpharmacologic behavior guidance techniques is not viable. In these instances general anaesthesia provides the clinician with the opportunity to perform comprehensive, fast and safe dental treatment. Behavior management techniques should follow general anaesthesia to manage the children's cooperation.

**PP 86 IMPACTED MAXILLARY CENTRAL INCISOR ASSOCIATED WITH SUPERNUMERARY MESIODENS.CASE REPORT**

SOFIA-ANNA PANARETOU; MARIA KALELI

*Greece*

**ORAL SURGERY AND ORAL MAXILLOFACIAL SURGERY**

Impacted maxillary central incisors are not very frequent (up to 2,6%). They are usually associated with supernumerary mesiodens which cause failure of eruption.although they are very easily diagnosed if not treated on time they can cause major aesthetical, functional and orthodontic

problems. Treatment planning consists of a combined surgical and orthodontic approach. A 10-year old girl with delayed eruption of one maxillary central incisor is presented. Radiographic examination showed an impacted maxillary central incisor and a supernumerary mesiodens. Treatment plan consists of a two-stage approach. At first, there was performed surgical exposure of the impacted tooth by labial approach followed by orthodontic alignment of the tooth using brackets. After the impacted tooth was erupted there was a surgical extraction of the supernumerary tooth by palatal approach. All radiographical and clinical data are presented. Although impacted maxillary incisors are not frequent, their treatment is crucial. It consists of a combined surgical and orthodontic approach with optimal results.

**PP 88** INVESTIGATION OF ANTIBACTERIAL ACTIVITY OF PAD WITH FOTOSAN, ND:YAG LASER AND CONVENTIONAL ENDODONTIC TREATMENT.  
TZVETELINA GUEORGIEVA; SLAVCHO DIMITROV; RAINA GERGOVA  
*Bulgaria*

**LASERS**

**Background:** Microbial infection is a main reason of dental pulp and periodontal diseases. PAD (photo-activated disinfection) and Nd:YAG-laser used as a complementary method to conventional endodontic treatment, lead to a significant reduction in bacterial infection. The **aim** of our study was to compare antibacterial activity of PAD with FotoSan, ND:YAG laser and standard endodontic therapy in the treatment of infected root canals. **Materials and methods:** Our study include 54 teeth in patients who are diagnosed with gangrene of the dental pulp and chronic apical periodontitis. The teeth were divided into three groups depending on the method used for disinfection of root canals: Nd:YAG- laser, PAD, irrigation with 10 ml 2.5% NaOCL and 10 ml 17% EDTA. Microbiological sample was taken before and after treatment. **Results:** In all three methods there are a significant differences in the amounts of microorganisms before and after treatment ( $p < 0.001$ ). PAD with FotoSan and a 2.5% solution of NaOCL have better antimicrobial activity then Nd: YAG- laser. **Conclusion:** Results of this clinical study show very good antibacterial effect of PAD with FotoSan. This method can be successfully used in endodontic treatment for additional disinfection of infected root canals, especially when lower concentrations of rinsing solutions are used.

**PP 90** DENTIGEROUS CYST ASSOCIATED WITH MANDIBULAR CANINE : A CASE REPORT  
GÜLSÜM KÖŞTEN; ALI HANTTASH; KAAAN ORHAN  
*Turkey*

**ORAL DIAGNOSIS-ORAL RADIOLOGY**

**Introduction:** Dentigerous cysts are the most common odontogenic cysts of the jaws after the radicular cyst, usually associated with the crown of an unerupted tooth. Dentigerous cysts mostly in the molar region of the mandible, especially the 3rd molar and maxillary canine and 3rd molars. Rarely associated with other teeth. Dentigerous cysts are usually solitary. Bilateral or multiple cysts are usually seen as associated with a syndrome or systemic disease. Rarely associated

with mandibular canine. **Case report:** Thirty-six-year-old male patient presented with a pain and swelling in the mandibula anterior region of 1 month duration. Intraoral examination detected swelling and sensitivity to palpation in anterior region. Panoramic radiograph showed, large radiolucent lesion associated with mandibular canine and migration of teeth. The CBCT imaging demonstrated well-defined radiolucent lesion and perforation of the buccal-lingual bone. Enucleation of the cyst was performed under general anesthesia which concluded after pathology report to be dentigerous cyst. **Conclusion:** Dentigerous cysts may develop asymptomatic and cause large bone defects. Therefore during the routine clinical examination of unerupted teeth, radiographic examination and follow up is mandatory.

**PP 91** USING MTA AS AN APICAL BARRIER IN A MAXILLARY INCISOR WITH INTERNAL RESORPTION

HANDE CINAR; FUNDA YILMAZ; MELIS ALAV; DURMUS ASICIOGLU;  
ESRA YAMAN

*Turkey*

**ENDODONTOLOGY**

**Introduction:** Internal root resorption is a resorptive defect of the internal aspect of the root following necrosis of odontoblasts. MTA was proposed by Torabinejad et al and has been indicated for being a good dental barrier material. **Methods and materials:** In this cage, a 52 years old female patient was referred to our clinic without any symptoms. Both of the maxillary central incisors had inadequate root canal fillings. Left maxillary central incisor had chronic apical periodontitis and right maxillary incisor had internal resorption and open apex. After removing the filling materials and biomechanic preparation, a paste which contains calcium hydroxide and steril saline solution was placed into the root canal systems. This procedure was applied twice in a two weeks period. After the paste was removed, into the apical region of the right maxillary incisor a MTA mixture was placed and a wet cotton pellet was placed in the pulp chamber and the cavity was sealed with cavit. After 3 days the cavit and the cotton pellet was removed. Then both of the canals were obturated with gutta percha cones and root canal sealer. The coronal access cavities were sealed with composite resin. The 6 months follow-up of the treatment was clinically and radiographically successful. **Discussions:** It is important to diagnose the teeth with resorption both clinically and radiographically and to apply the treatment with the right procedure with using appropriate materials. With being aware of all, successful results can be achieved.

**PP 92** FEAR OF DENTAL TREATMENT IN CHILDREN

SNEZANA MATIJEVIC

*Montenegro*

**PAEDIATRIC DENTISTRY**

**Introduction:** Fear of dental treatment, especially of pain, is widespread in everyday dental practice. Modern dentistry, especially pediatric dentistry, is based on painless treatment. In order to achieve this it is necessary to use all available procedures. Conventional methods of communication can be used to overcome dental fear in large number of children whereas in small number of

children sedative medication should be used. Patients are under conscious sedation and they have their reflexes intact (e.g. cough) which is of importance in dental treatment. **Aim:** The aim of this study is to raise awareness of the impact of dental fear in children as well as the possibility of its prevention in order to carry out dental treatment and achieve desired results. **Results:** Sedation was used in 35 patients out of 102 patients aged six to twelve years. Diazepam (bensedin) 2 mg and 5mg was used as a sedative. Apart from rapid onset and good effects of sedation as well as mild amnesia the drug is eliminated after one and a half to two hours making it safe for use. **Conclusion:** Nowadays the sedation is used in pediatric dental clinics all over the world but unfortunately it is rarely used in our country. The knowledge and experience of the pediatric dentist are very important in assessing and selecting patients for oral sedation. Also, the detailed knowledge of the properties of the drug administered, especially possibility of any adverse effect is very important as well as monitoring and treatment of possible complications.

### PP 93 ORTHODONTIC TREATMENT IN ADULT PATIENTS

JASMINKA ANDJELIC

*Montenegro*

#### ORTHODONTICS

**Introduction:** The most common reason for orthodontic treatment in adult patients is usually for aesthetics reasons as a result of unsolved orthodontic problem from the childhood. In recent years it is the fastest-growing part of orthodontics. **Aim:** The aim of this study is to show the incidence of these patients in both sexes. **Materials and methods:** The sample included randomly selected 100 orthodontic patients who were treated in the period January 2013 to January 2014. The most frequent diagnosis was the protrusion of the upper front with crowding and canine ectopia. Firstly, the upper premolars, usually first ones, were extracted. The results were already very good within the first six months of the treatment. **Conclusion:** The frequency of female patients (75%) was higher than male patients (25%) in this age group. The main goal of treatment is to improve condition of their teeth and supporting structures in these patients. Incorrect position of teeth and disorder in occlusion hinders the oral hygiene maintenance which contributes to the development of dental caries, diseases affecting tooth-supporting structures and premature tooth loss. If orthodontic problems are not treated at the appropriate time they worsen with age.

### PP 96 A RARE CASE OF HYALINIZING CLEAR CELL CARCINOMA IN THE MAXILLA

ERSUN GUSHI; KAAH ORHAN; UMUT SEKI

*Turkey*

#### ORAL DIAGNOSIS-ORAL RADIOLOGY

**Introduction:** Hyalinizing clear cell carcinoma (HCCC) is a rare neoplasm of salivary gland origin which is low-grade in nature. HCCC shows female predominance and older age in diagnosis (between fifth and seventh decades), with the vast majority of cases occurring in the oral cavity. The most frequent locations of this tumor are the palate and tongue. The aim of this presentation was to present a rare case of hyalinizing clear cell carcinoma in the maxilla. **Case report:** 31-year-old woman admitted to our clinic in January 2015 for the diagnosis of an exophytic mass in the right

upper vestibule. The panoramic radiography showed the displacements of premolar teeth with a radio-lucent lesion in the maxilla. An excisional biopsy was performed as 1,5 cm<sup>3</sup>, and histologic examination showed trabeculae and cords of organized, wide clear cells with a vascularized and hyalinized stroma. Pleomorphism and mitotic activities are low at tumor cells. **Conclusion:** HCCC is difficult to diagnose, because it shares or overlaps immunohistological characteristics with other malignant tumors of the salivary glands. It must be differentiated from, among others, mucoepidermoid carcinoma, oncocytic clear cell tumors and metastasis of renal cell or other clear cell carcinomas. Maxillofacial radiologist as well as general practitioners must be aware from this rare entity.

PP 97

#### VISITS TO THE DENTIST

BOJANA DAVIDOVIC; SVJETLANA JANKOVIC; MIRJANA IVANOVIC; MIHAEL STANOJEVIC; BRANKICA DAVIDOVIC

*Bosnia and Herzegovina*

#### PREVENTIVE DENTISTRY

**Introduction and aim:** The presence of fear of dental procedures in children is the most common reason for avoiding them. The aim of this study was to investigate the presence of anxiety when visiting the dentist, and to identify possible reasons. **Methods:** The study included 136 school children. For the assessment of attitudes and habits that children have in relation to the frequency and reasons for visiting the dentist, we have used a survey, formulated for this study. Parents and children were informed about the purpose of research, and gave approval for participation in the same. **Results:** The largest percentage of respondents (39.7%) occasionally visits the dentist, while 5.1% so far have never been to the dentist. The most common intervention was sealing of fissure (45.6%). More than half of the respondents declared that they are not afraid of the dentist. Reasons for not coming respondents bind to the expressed fear of dental needles, buzzing dental equipment, bleeding or thinking about the intervention itself. **Conclusion:** The existence of bad experiences in childhood is an important factor in the creation of specific anxiety of the dentist. For the dental treatment to be successful, it is important to establish a good relationship with the child, given the often presence of dental phobia. It is necessary to emphasize the importance of the first contact with a dentist at an early period of life, when there are no painful conditions in the oral cavity.

PP 98

#### MANAGEMENT OF SECOND TRAUMATIC INJURED COMPLICATED CROWN ROOT FRACTURE PERMANENT MAXILLARY CENTRAL INCISOR

BADE SONAT; MELTEM ÖZTAN; DURMUŞ AŞICIOĞLU

*Turkey*

#### ENDODONTOLOGY

**Introduction:** Tooth fracture can occur at any age due to trauma. Sports accidents are more common among teenagers. Prevalence of trauma to anterior teeth has been reported as %37 and crown root fractures are about %5 of all dental traumas. Crown- root fractures are complex injuries that are both difficult to evaluate and to treat. **Purpose:** This case report describes the management of endodontic and restorative treatment of complicated crown root fractured in maxillary central

incisor in which there had been a second trauma on the same tooth. **Case report:** 16 year old male patient who fell down and crashed his tooth (21) while playing football. The patient reported a second injury in the same tooth. In the radiographic examination, this tooth pre-made root canal treatment which had thin-walled root was seen. Periapical area was found to be normal. All the other incisors and canines responded normally to thermal and electric pulp testing, which signifies healthy pulp tissue. In clinic examination intraorally lacerations, bleeding and swelling were present on buccal mucosa and crown-root fracture extending below palatal margin were observed. Broken mobile fragment was removed and sealed to access cavity with temporary filling and then waited one week for healing. Postoperative clinic view was found normal and root canal preparation for the post space was done. Finally, tooth was restorated with fiber post and composite resin.

**PP 99 ROOT CANAL MORPHOLOGY OF THE MAXILLARY SECOND PREMOLARS**

BRANKICA DAVIDOVIC; NIKOLA STOJANOVIC; SVJETLANA JANKOVIC;

BOJANA DAVIDOVIC; IVANA SIMIC

*Bosnia and Herzegovina*

**RESTORATIVE AND ADHESIVE DENTISTRY**

**Introduction:** Relative simplicity and uniformity of external root surface most often masks the internal perplexity and complexity. The aim of the study was to determine the number of canals, anastomotic sites and the number of apical openings by using technique of decalcification and dyeing. **Methods and material:** A total of 150 extracted human permanent maxillary second premolars were collected. Access cavity was prepared with endo access kit, all samples were placed in 5% nitric acid for decalcification, for 72 hours. They were rendered transparent by immersion in methyl salicylate for 2 hours and then hematoxylin dye was injected into the access cavity. The anatomy of the root canal was observed where is the certain number of canals, anastomosis location and number of apical openings. **Results:** In maxillar second premolar 70,7% had one canal and 29,3% two canals. Anastomosis are not found in the 42%. On examined teeth, 8,7% had cervical, 42,7% median and 6,7% apical anastomosis. One apical opening was found in 69,3% and two and more in 30,7% examined teeth **Conclusion:** The upper second premolar tooth is complexed, and to note the complexity of the root canal system is imperative for any therapist. **Keywords:** upper second premolar, canal number, apical openings number, anastomosis, decalcification, dyeing.

**PP 100 OSSIFYING FIBROMA OF THE MANDIBLE - CASE REPORT AND LITERATURE REVIEW**

MARTIN RUBIEV; ELITSA DELIVERSKA; LUTCHEZAR STEFANOV;

DIMITAR YOVCHEV; ANELIA BOBEVA

*Bulgaria*

**ORAL SURGERY AND ORAL MAXILLOFACIAL SURGERY**

**Background:** Ossifying fibroma (OF) is a rare neoplasm of the craniofacial skeleton. It can affect all ages, although it is discovered mostly in the second to fourth decade of life. It occurs predominantly in females and most common site is the mandible (molar and premolar region). OF is a benign tumor with usually slow and asymptomatic development. In some cases described as

“juvenile” more rapid and aggressive behavior is observed. **Materials and Methods:** We report a case of 26-year-old woman with OF of the mandible that was presented to our department. The patient was referred to us for clinical evaluation, diagnosis and treatment of an asymptomatic, mixed radiolucent/radiopaque lesion from second left mandibular incisor to the first left mandibular premolar. A decision for excisional biopsy was taken. **Results and Conclusion:** The patient underwent operation under local anesthesia – enucleation of the tumor and peripheral osteotomy, the histopathological findings were conclusive with OF. No recurrence was seen after 2 years follow up.

**PP 101 INFLUENCE OF RISK FACTORS FOR CARIES IN DEAF CHILDREN FROM SOFIA CITY, BULGARIA**

LILIYA DOICHINOVA; MILENA PENEVA; PETER BAKARDJIEV

*Bulgaria*

**PAEDIATRIC DENTISTRY**

**Background:** Socio-economic status of the family, oral hygiene, lifestyle and the model of eating can have a major influence on the caries-resistance or the development of dental caries in children with disabilities. **Aim:** This study has for objective to make an assessment of the relationship between dental caries and the influence of socioeconomic status, oral hygiene and consumption of carbohydrate foods in children with impaired hearing. **Methods and materials:** The study covers 100 deaf children from age 5 to 12 years. To them was performed targeted medical history for assessment of the social status and to establish what are the health habits and food preferences of the children. The prevalence of dental caries was registered with the DMFT index of Klein, Palmer & Knutson. **Results:** The frequency of dental caries in 89% of children is over 4 DMFT, in 1% were recorded value up to 4 DMFT and the in 10% they are up to 2 DMFT. The majority of the children (70%) are from families with middle and 30% have a low social status. Nearly two-thirds of the deaf children are with poor oral hygiene and often eat throughout the day low molecular carbohydrates. To them has reported a high incidence of dental caries, the results are with statistical significance ( $p < 0.001$ ). **Conclusion:** The prevalence of dental caries is directly connected with the social status of the family, level of oral hygiene and food preferences of the studied deaf children.

**PP 103 SUSCEPTIBILITY OF DENTAL BIOFILM TO PHOTODYNAMIC THERAPY: AN IN VITRO STUDY**

VICTOR GRECU; AURELIA SPINEI

*Republic of Moldavia*

**PAEDIATRIC DENTISTRY**

The Photodynamic Therapy (PDT) is based on photochemical reactions triggered by the interaction of photosensitive substances and light with a specific wavelength, resulting in the formation of singlet oxygen and free radicals that destroy bacteria. The purpose of the present study was evaluating in vitro the effect of PDT with application of various types of photosensitizing agents on streptococci strains in dental biofilm. **Material and methods:** We conducted an in vitro

evaluation of the efficiency of PDT action on isolated streptococci in dental biofilm. We assessed the total number of microorganisms. The identification of streptococci in dental biofilm samples was conducted based on morphological, tinctorial, cultural, and biochemical properties by using GPI card for detecting Gram positive cocci of the automated system Vitek2. We researched the sensitivity of microbial strains to LED irradiation without photosensitizer and later with photosensitizer. The bactericidal effect of photosensitizing substances and subsequent irradiation with LED 420-480 nm was assessed by measuring the total reduction areas of microorganism growth within 24 hours after applying PDT. The study was approved by the Ethics Committee for Research, SUMF. **Results:** The data obtained in the research conducted in vitro showed that applying the PDT method with erythrosine as photosensitizing substance and a catalyst causes a total destruction of strains: *Streptococcus mutans*, *Streptococcus mitis*, *Streptococcus gordonii*, *Streptococcus sobrinus*, etc. In **conclusion**, the application of PDT provides new opportunities for developing efficient methods for prevention and treatment of dental caries.

**PP 104 RESTORATIVE THERAPY OF EROSION**

NATASHA DENKOVA; IVONA KOVACEVSKA; SLOBODAN RUSHKOVSKI;  
SANJA NASHKOVA  
FYROM

**RESTORATIVE AND ADHESIVE DENTISTRY**

When substance loss caused by erosive tooth wear reaches a certain degree, oral rehabilitation becomes necessary. Prior to the most recent decade, the severely eroded dentition could only be rehabilitated by the provision of extensive crown and bridge work or removable overdentures. Now it became possible eroded dentition to rehabilitate in a less invasive manner. However, even today advanced erosive destruction requires the placement of more extensive restorations such as ceramic veneers or overlays and crowns. Etiology of the erosive lesions needs to be determined in order to halt the disease, otherwise the erosive process will continue to destroy tooth substance. Restorative treatment is dependent on individual circumstances and the perceived needs and concerns of the patient. This overview presents aspects concerning the restorative materials as well as the treatment options available to rehabilitate patients with erosion, from minimally invasive direct to composite reconstructions. Long-term success is only possible when the cause is eliminated. In all situations, the restorative preparations have to follow the principles of minimally invasive treatment.

**PP 105 PERIRADICULAR HEALING IN AN OPEN APEX MAXILLARY INCISOR BY USING MTA AS AN APICAL BARRIER**

DURMUŞ AŞICIOĞLU  
*Turkey*

**ENDODONTOLOGY**

**Background:** The major problem in performing endodontics in teeth with wide open apices and necrotic pulp is obtaining an optimal seal of the root canal system. MTA is an excellent sealing material in the presence of moisture so MTA is used as a potential material to create an apical plug at the end of the root canal system. The aim of this barrier is to limit bacterial infection and create an



environment that helps producing mineralized tissue in the apical region. **Methods and materials:** A 38 year old female patient had suffered a trauma to the maxillary right central incisor. Based on clinic and radiographic findings, pulp necrosis and open apex was found for the right maxillary central incisor. The biomechanical preparation was made. Calcium hydroxide was applied twice in a two weeks period. MTA mixture was placed in the apical region of the canal (4 mm). A wet cotton pellet was placed in the pulp chamber and the access cavity was sealed. The rest of the canal was obturated with gutta percha cones and root canal sealer. The coronal access cavity was sealed with composite resin. **Result:** At 9 months follow-up the right maxillary central incisor was asymptomatic. The healing of the periapical and the formation of the apical closure was seen radiographically.

**PP 106** **INCIDENTAL FINDING OF AN ECTOPIC IMPACTED TOOTH IN MAXILLARY SINUS**

HILAL DEMIR; FÜSUN YAŞAR

*Turkey*

**ORAL DIAGNOSIS-ORAL RADIOLOGY**

**Background:** Ectopic tooth eruption in a non-dental region like nasal cavity, chin, orbital cavity, mandibular condyle, coronoid process, palate and maxillary sinus is a rare occasion. **Material and methods:** In this case report, a 20 year old male patient with tooth in the right maxillary sinus was presented. He had no systemic disease. He wasn't aware of this tooth and there was no complaint. In a routine examination, ectopic tooth was seen on panoramic radiography. CT examination was preferred to evaluate relationship between tooth and contiguous tissues. **Results:** There was no pathological lesion on panoramic radiography and CT. So the tooth was not removed surgically. It was decided to follow up the patient with routine controls. **Conclusion:** Panoramic radiography is useful for diagnosing the incidental findings and CT can also be preferred to assess the relation of tooth with neighboring anatomical structures.

**PP 107** **MANAGEMENT OF BENIGN TUMOR OF OROMAXILLOFACIAL AREA WITH 980 NM DIODE LASER**

MERITA BARDHOSHI; ESAT BARDHOSHI; EDIT XHAJANKA; ALKETA QAFMOLLA;  
NEADA HYSENAJ

*Albania*

**LASERS**

**Introduction:** Benign tumors are a common entity managed by oro- maxillofacial surgeons in the course of daily practice. They may be small, moderate or large and they may be flat, sessile or pedunculated. They can be localized on the tongue, buccal mucosa, gingiva, hard palate, floor of the mouth, lip. Because of wide diversity of clinical presentations the management of these lesions is varied and complex. Treatment technique for their management may include incisional biopsy, excisional biopsy, ablation. Laser is a good modality for the treatment of tumor benign of the oromaxillofacial region. Different laser systems can be used like: Co2 Laser, Er: YAG, Er, Cr: YAG laser, diode laser 810 nm, 940 nm, 980 nm. **Material and method:** In this study I report my experience in

the treatment of benign tumor of the oro-maxillofacial area. All patients were treated as outpatients in the University Dental School, Oral Surgery Department, Tirana Albania. Lesions were localized on the lip, buccal mucosa, gingiva, hard palate. For all treatment an 980 nm diode laser was used and after the surgical resection all specimens were histopathologically examined to confirm the diagnosis. The operative treatment and post-operative follow up were documented for the evaluation of early and long-term results. **Results:** Diode laser surgery was rapid and bloodless. Postoperative period was without complication and a comfortable and good wound healing without functional disturbance. After one month no scar formation was reported and from 1-3 years of follow-up no recurrence was recorded. **Conclusion:** 980 nm diode laser is a good modality for the treatment of benign tumor of oro-maxillofacial area. This treatment provides satisfactory results and is also well-accepted by all age groups.

**PP 108 CONSERVATIVE TREATMENT APPROACH FOR ANTERIOR DENTAL EROSION: REPORT OF TWO CASES**

HALE KARAKUYU; ASLIHAN GOKTURK; NESLIHAN TEKCE; EMRE OZEL

*Turkey*

**RESTORATIVE AND ADHESIVE DENTISTRY**

**Background:** The purpose of this report is to present esthetic rehabilitation of anterior teeth eroded by consumption of acidic foods and drinks. **Methods and materials:** 40-year old female (Case 1) and 14-year old female (Case 2) patients with an esthetic complaint on maxillary central incisors was referred to our clinic. During the intraoral examination, dental erosion on maxillary central incisors (for both cases) and enamel defects on mandibular incisors (for Case 1) were diagnosed. The teeth were restored as direct resin composite veneer restorations using one-step self-etch adhesive system (Universal Bond, 3MESP, USA) and nanohybrid resin composite (Clearfil Majesty Esthetic, Kuraray, Japan). Finishing and polishing procedures were performed by discs and diamond burs and a second polishing procedure was performed at the end of one week. Recall was performed at the end of six months. **Results:** Clinically successful direct resin composite restoration can be achieved with one-step self-etch adhesive system and nanohybrid resin composite. The restorations were found to be successful at the six-months recall. **Conclusion:** It may be concluded that direct composite resin restorations leads to functional and esthetic rehabilitation even in cases with dental erosion.

**PP 109 ASPERGILLOSIS OF THE MAXILLARY SINUS CAUSED BY ENDODONTIC OBTURATION MATERIALS: A CASE REPORT**

YAVUZ TOLGA KORKMAZ; BURAK CEZAYIRLI; NURAY YILMAZ ALTINTAŞ;  
EMRE BALABAN; CENK DURMUSLAR

*Turkey*

**ORAL PATHOLOGY-ORAL MEDICINE**

Aspergillosis of the paranasal sinuses has been regarded as a rare disease in nonimmuno compromised patients. Approximately more than 10% of all patients with chronic sinusitis are found to have an aspergilloma. Extrusion of endodontic obturation materials into the maxillary sinus can lead to the occurrence of aspergillosis in the maxillary sinus as a complication of the

extruded obturation materials. The suggested treatment for the maxillary sinus aspergillosis is surgical removal of the mass. The tendency to recur after proper removal of the mass is unexpected. A 28-year-old female who had a routine examination at the clinic of Karadeniz Technical University, Faculty of Dentistry, Türkiye, Trabzon. A dental examination using panoramic and CBCT imaging revealed a extruded radiopaque substance was in the left maxillary sinus. The patient had undergone root canal treatment by a general practitioner about 2 years ago. Her chief complaint was a mild pain and reduced nasal breathing on her left side. Patient operated under local anesthesia with a initial diagnose of chronic sinusitis. A lateral window approach was used to remove the endodontic obturation materials and the granulation tissues. Histopathological examinations showed a maxillary sinus aspergillosis. After 3 months follow-up, patient was free of symptoms. Although aspergillosis of the maxillary sinus is a rare disease, the initial diagnosis of aspergillosis should be keep in mind when the appearance of a radiopacity foreign body in the maxillary sinus was observed radiologically.

**PP 110 NUTRITIONAL HABITS AND DENTAL CARIES IN PRESCHOOL CHILDREN**

PETER BAKARDJIEV; MILENA PENEVA; LILIYA DOICHINOVA

*Bulgaria*

**PAEDIATRIC DENTISTRY**

**Background:** The promotion of oral health includes planning of health programs aimed at different groups. The objective of preventive measures is to improve the general and dental health. Childhood is an important period for the receipt of health education. Learned in this part of life affects the future behavior of the child. This period is associated with a high risk of developing caries. Evaluation of the diet is one of the most frequently used measures in these programs. Oral health in preschoolers can be influenced largely by nutrition or diet. **Aim:** The aim of this study is to assess food preferences in children 4 to 6 years of age and the risk of developing dental caries and to make recommendations to improve their diet. **Methods and materials:** The study includes 140 children from 4 to 6 years of age. Using a log for a period of three days for the analysis of food habits and mode of each child. Data was reported as the type and frequency of carbohydrates intake. The prevalence of dental caries was registered with the DMFT index WHO. **Results:** The analysis of the diets showed unhealthy eating habits in 60,71% of children with readings over 4 DMFT. Were given recommendations on the control of carbohydrate feeding avoid carbohydrate intake between meals. **Conclusion:** The motivation of children and their parents through the provision of food information, which are the basis for a good diet will improve oral health and dental health.

**PP 111 A MULTIDISCIPLINARY APPROACH FOR REHABILITATING A PATIENT WITH UNSUCCESSFUL TREATMENT HISTORY: A CASE REPORT**

BADE SONAT; AYŞEGÜL KÖKLÜ; ASLI ŞENOL; İSMAİL BALTACIOĞLU

*Turkey*

**RESTORATIVE AND ADHESIVE DENTISTRY**

This case report presents post operative orthodontic, restorative treatment and endodontic observation of an adult female patient with severe skeletal Cl III malocclusion. According to the

patient history she had unsuccessful orthognathic surgery treatment. The chief complaint was mandibular protrusion, midfacial retrusion, crowding and aesthetic problems. **Methods and materials:** The patient had fixed orthodontic appliances when she applied to the clinic of our department. According to the clinical examination and archive documents belonged to her we learned that the treatment progress included; fixed orthodontic appliance treatment followed by bimaxillary orthognathic surgery. After radiographic examination root resorption (12, 11, 21) was revealed. The teeth were decided to be under observation by an endodontist because of being asymptomatic. The skeletal disharmony was corrected and the nonesthetic profile was improved succesfully. However due to the ankylosis of the canine tooth, CI I canine relationship wasn't achieved in the right maxillar quadrant. Therefore a new multidisciplinary treatment was planned to establish a stable occlusion. However, the ankylosis of canine prevented the orthodontic movement of the tooth and led to inadequate space for premolar restoration and diastema between canine and lateral teeth. After orthodontic treatment, maxillary anterior teeth were rehabilitated with composite laminate veneer restorations. Multidisciplinary approach yielded successful results. Treatment objectives were achieved and functional occlusion and esthetic smile were obtained.

**PP 112 CORRECTION OF ANTERIOR CROSSBITE AS A MEANS OF INTERCEPTIVE GUIDANCE OF DENTITION**

TAMER TÜZÜNER; GÖRKEM YAHYAOĞLU; MEHMET BIROL ÖZEL; ÖZGÜL BAYGIN

*Turkey*

**ORTHODONTICS**

Dentoalveolar anterior crossbite exhibits a linguoversion of one or more maxillary anterior teeth with the consequence of 'locking' behind the opposing mandibular teeth in full closure. Crossbite commonly interferes the normal occlusion development of maxillary anterior teeth. To overcome the above mentioned problems in mixed dentition; passive incisal guides, expansion, protrusion with orthodontic active appliances and extraction have been described as treatment alternatives. If serial extraction is not planned, extraction of primary canines for resolving anterior crowding would be an erroneous approach. Correction of anterior crossbite of permanent left maxillary lateral tooth in a 9 years old female will be presented by the application of root canal treatment for adequate trimming of left maxillary primary canine and also utilizing an orthodontic appliance for three months.

**PP 113 MALIGNANT TUMORS OF THE ORAL CAVITY, RETROSPECTIVE IN THE PERIOD 2009-2013, OUR EXPERIENCES**

MARINA MILINKOVIĆ; MIROSLAV OBRENOVIĆ; JELENA OBRENOVIĆ; BRANKICA DAVIDOVIC; TANJA IVANOVIĆ

*Bosnia and Herzegovina*

**ORAL SURGERY AND ORAL MAXILLOFACIAL SURGERY**

**Introduction:** Malignant tumors of the oral cavity are very rare, they are appearing in both sexes, although more often in the male population. **The goal:** To determine the incidence of the oral cavity malignant tumors in the male and the female population in University Hospital Foča

regarding the age, in 2009-2013 period. **Material and the method:** The data used is originating from the Maxillofacial ward of the University Hospital in Foča. The same is qualified by the age, sex, chronic and acute diseases. The diagnosis was made by clinical examination, biopsy changes and histological findings. **Results:** Research has shown that in 2009, 2.39% of tumors were surgically treated, patients were women and men older than 60 years. In 2010, we operated 1.28% of patients, where all the patients were men over 50 years old. By the end of December 2011 there was 1.82% operated malignancies, with 80% of the operated were male population. For 2012, the incidence of surgically treated amounted to 0.88%, while in the total number of operated there was only one woman. In the period of 2013 the number was 1.23%, and 60% of the operated patients were men. **Conclusion:** The results show that malignant tumors of the oral cavity are very rare. The most commonly happens to people over sixty years old. Compared to the gender those are represented in a greater percentage in the male population.

**PP 114** **CLINICAL DENTAL REVIEW IN THE PREVENTION OF CANCER LIPS**  
JELENA OBRENOVIĆ; MARINA MILINKOVIĆ; MIROSLAV OBRENOVIĆ;  
JOVANA HRISA SAMARDŽIJA; BOJAN KUJUNDŽIĆ  
*Bosnia and Herzegovina*

#### ORAL SURGERY AND ORAL MAXILLOFACIAL SURGERY

**Introduction:** The lips cancer usually starts developing on the border of skin and mucosa. More often it strikes the lower lip, and males are more often influenced than women. The upper lip cancer has more of malignant potential. The goal: To see the full extent of the lip cancer comparing to the other lip malignants, sex and age structure, and also anatomic regions influenced with the malignant tumor. **Material and method:** The research is covering 29 of patients with the lips malignant, of the maxillofacial ward of the hospital Foča, in 01.01.2009 to 29.12.2013 period. **Results:** Based on the results its determined that in 17 of 29 patients with the oral cavity malignant there's the lip cancer diagnosis. From the overall number of patients 10 of 17 were the male sex patients, and 7 of 17 were females. More than half of the patients 13 of 17 were patients between 50 and 70 years old. In the majority of the cases, symptoms like pain, nodules and thickenings were present, and in 12 of 17 patients the cancer was localized on the lower lip. **Conclusion:** The lip cancer presents risky illness, especially if not diagnosed early, and for that reason monthly dentist control should be awareness of the every individual, just like the basic preventing measures against the same disease.

**PP 116** **PORPHYROMONAS GINGIVALIS LIPOPOLYSACCARIDE DOSE HETEROGENCITY DIFFERENTIALLY MODULATES THE PROLIFERATION IN GINGIVAL AND PERIODONTAL LIGAMENT FIBROBLASTS**  
VAHDI UMUT BENGI; İŞİL SAYGUN; MEHMET VEHBI BAL; CANSEL KOSE OZKAN;  
FERIT AVCU  
*Turkey*

#### PERIODONTOLOGY

**Aim:** Periodontal Ligament and gingival fibroblasts are considered important cells in periodontium. Porphyromonas Gingivalis Lipopolysaccharide (P.Gin.LPS) effect the expression of

the cyclooxygenase-2 which contribute to the periodontal pathogenesis. However, different doses of P.Gin. LPS have been used for in vitro studies. The aim of this study is evaluate the effect of different P.Gin. LPS doses on Gingival Fibroblasts (GF) and Periodontal Ligament Fibroblasts (PDLF) with real time cell analysis system (xCelligence) to determine its appropriate dose for in vitro studies on inflammatory process of periodontal disease when stimulated with different doses of LPS from P.Gin. affected cell proliferation and cytotoxicity. **Material and method:** GF cells were harvested from gingival tissues of healthy patients who had second implant surgery and PDLF cells were harvested from root surfaces of freshly extracted premolars for orthodontic treatment.  $2 \times 10^4$  GF and PDLF cells were challenged with different doses of P.Gin.LPS and cells seeded in the xCELLigence analysis system's E-plates to evaluate the effects of five different dose (100 nmol, 200 nmol, 1  $\mu$ M, 5  $\mu$ M, 10  $\mu$ M) of P.Gin.LPS on proliferation of cells by comparing control group and test groups according to cell index and monitored for a period of 72 hours. **Results:** The normalized and baseline normalized cell index values revealed that 1  $\mu$ M P.Gin.LPS application had significantly proliferative effect on GF and PDLF cells. **Conclusion:** The present study suggests that P.Gin.LPS dose heterogeneity may differentially modulate the cell proliferation in GF and PDLF.

#### PP 117 MULTIPLE IMPACTED MOLARS IN THE MANDIBLE: A CASE REPORT

MEHMET ERAY KOLSUZ; POYZAN BOZKURT

*Turkey*

#### ORAL SURGERY AND ORAL MAXILLOFACIAL SURGERY

A 43 year old male patient with no known systemic diseases admitted to Ankara University Faculty of Dentistry with complaints of pain and swelling in the left mandible molar area. Clinical and radiological examination revealed impacted second and third molars with an associated cyst. Surgery was planned for treatment. The multiple impacted molars were extracted and the associated cyst was enucleated. Patient was prescribed antibiotics, analgesic drugs and mouth-wash. At 7 days follow-up sutures were removed and healing was observed. The patient didn't have any postoperative complaints.

#### PP 119 DIRECT TECHNIQUE FOR RESTORING THE ESTHETIC APPEARANCE OF PEG-SHAPED LATERAL INCISORS

ASLIHAN GOKTURK; EMRE OZEL

*Turkey*

#### RESTORATIVE AND ADHESIVE DENTISTRY

**Background:** The purpose of this report is to present direct technique for restoring the esthetic appearance of peg-shaped lateral incisors. **Methods and materials:** A 20-year-old male patient was referred to our clinic complaining about aesthetic appearance. After clinical and radiographic examination the presence of peg-shaped permanent maxillary right and left lateral incisors were observed. It was decided to restore the peg-shaped laterals using direct composite technique. Only left lateral incisor was prepared for providing bite. Teeth were etched with 37% phosphoric acid for 30 seconds, rinsed and dried. Then the lateral incisors were restored using one-step self-etch adhesive system (Universal Bond, 3M/SPE, USA) and nanohybrid resin composite

(Clearfil Majesty Esthetic, Kuraray, Japan). Finishing and polishing procedures were performed by discs and diamond burs. Recall was performed at the end of six months. **Results:** Clinically successful direct resin veneer composite restoration can be achieved with one-step self-etch adhesive system and nanohybrid resin composite for peg-shaped lateral incisors. The restorations were found to be successful, at the six-months recall. **Conclusion:** It may be concluded that direct resin composite veneer restorations leads to functional and esthetic rehabilitation on peg-shaped permanent maxillary right and left lateral incisors.

**PP 121** **RESTORATION OF A MAXILLARY ANTERIOR TOOTH SPACE USING FIBER-REINFORCED COMPOSITE AND THE PATIENT'S OWN TOOTH**  
FATIH MEHMET KORKMAZ; ESRA BALTACIOGLU; YAVUZ TOLGA KORKMAZ;  
GUVEN AYDIN; BORA BAGIS  
*Turkey*

#### RESTORATIVE AND ADHESIVE DENTISTRY

The loss of anterior tooth impairs patients both socially and psychologically. Conservative and esthetic rehabilitation of a single edentulous space in the anterior maxilla is a challenge for the clinician. Immediate chairside replacement of an anterior tooth may present esthetic, comfort, function to the patient when the patient needs a short-term solution. Chairside tooth replacement is an excellent application of fiber-reinforced composites (FRC) technology. The present case report describes the prosthetic treatment of a maxillary anterior edentulous space with FRC (Ribbond, Ribbond Inc., Seattle, WA) using patient's own tooth with the aid of silicon index. FRC offer a rapid, innovative, conservative, esthetic and relatively cheaper restorative solution when compared to the other techniques.

**PP 122** **CARIES INFILTRATION OF PROXIMAL ENAMEL LESIONS WITH RESINS.A CLINICAL GUIDELINE.**  
PANAGIOTIS NTOVAS; CHRISTOS RAHIOTIS  
*Greece*

#### RESTORATIVE AND ADHESIVE DENTISTRY

**Background:** Dental caries on proximal tooth surfaces constitutes a widespread health issue. Dental research on minimal intervention dentistry has procured a tissue preserving approach to arrest and control incipient lesions. Resin infiltrants are able to penetrate into subsurface lesion, thus reduce microporosities, afford mechanical support and obstruct the acids, hampering demineralization. While clinical research evidence on the technique is considerable, literature lacks guidelines for the selection, the accurate application and the wider treatment plan. **Methods and materials:** We searched the Cochrane Library, Embase, MedLine, PubMed, and Scopus for published papers. The main search terms were 'proximal caries', 'resin infiltration', 'sealant' and 'white spot lesion'. From them a total of 15 in vivo studies and 12 systematic reviews and 1 economic evaluation met our criteria and were assessed by 2 individuals using SIGN checklists. **results:** From systematic reviews and clinical trials 3 assessed as high quality respectively. 3 reviews

and 9 trials assessed as acceptable, 3 reviews as low quality and 3 were rejected. The guideline covers all aspects of the management of proximal enamel lesions upon resin infiltration. The final judgment must be made by the dentists responsible for clinical decisions regarding a particular clinical procedure or treatment plan, after discussing with the patient. **Conclusion:** Caries infiltration is a clinically feasible and effective method for the treatment of interproximal lesions with high success rates. The right management of the cases and the accurate application technique in combination with a substantial caries remineralization program places proximal caries lesions to a controlled ultraconservative restorative approach.

**PP 123 REHABILITATION SMILE HARMONY WITH CONSERVATIVE APPROACH AND DIRECT COMPOSITE PLACEMENT: REPORT OF THREE CASES**

MERVE EFE-SERIM; EMRE OZEL

*Turkey*

**RESTORATIVE AND ADHESIVE DENTISTRY**

**Background:** The purpose of this case report was to present reconstitution of aesthetic by use of the closure of interdental spaces utilizing proximal build-ups with resin composite to three cases. **Methods and material:** 45-year-old female (Case 1), 18-year-old female (Case 2) and 30-year-old male (Case 3) patients presented to our clinic complaining about the diastema presence. Clinical examinations confirmed that maxillary midline diastema was diagnosed for Case 1 and 3 and the multiple diastemas on maxillary teeth was diagnosed for Case 2. In all cases, minimal invasive technique was used for the preparations of teeth. The teeth were etched with %37 phosphoric acid, restored with self-etch adhesive material (Single Bond Universal, 3M ESPE, US) and nanohybrid composite resin (Clearfil Majesty Esthetic, Kuraray, USA). Finishing and polishing procedures were performed by using discs and burs. **Results:** Closure of diastema with direct composite resin treatment proved to be effective for the establishment and maintenance of an esthetic and pleasant smile. Patient's expectations were satisfied in a single visit as economically and aesthetically. **Conclusion:** Gradually procedure is proposed for illustrating the proper implementation of an additive-only and noninvasive indirect technique that provides a satisfactory clinical and esthetic outcome for clinician and patient. Without needing extra processing such as measurement operation is another advantage over the prosthetic process.

**PP 124 GENDER DETERMINATION BY ODONTOMETRICS IN A SERBIAN POPULATION**

GORDANA FILIPOVIC; BOJANA CETENOVIC

*Serbia*

**ORTHODONTICS**

**Aim:** The presence of sexual dimorphism in the size of the teeth is important in identification unknown individuals from a forensic context. The purpose of this study was to investigate the accuracy with which gender can be differentiated by odontometric analyses in the Serbian population. **Material and method:** Measurements were taken on 200 individuals, both



sexes, ages between 18-25 years, on plaster casts by a digital caliper of Japan production with precision of 0.01 mm. Percentages of sexual dimorphism were calculated for mesiodistal and buccolingual dimensions using the formula of Garn et al. Student t-test and Mann-Whitney U test descriptive statistics were obtained from the sample. **Results:** Most of the teeth examined were larger in males than in females but most of the differences were not statistically significant. For the mesiodistal dimension the only significant differences were found in maxillary and mandibular canines. Measurements for the buccolingual dimensions were significantly higher in males with p values of <0.05 for mandibular I1, <0.01 for maxillary I1, mandibular I2 and P2, <0.001 for maxillary I2, C and M1 and mandibular C, P1 and M1. **Conclusions:** The results of this study indicate that there are significant differences between gender for dimorphic some teeth. These findings support the usefulness of especially the canines in gender determination by odontometric analyses.

**PP 126 CORRECTION OF CLASS II DIVISION 1 MALOCCLUSION TREATMENT OF ADULT PATIENT: CASE REPORT**

ENES TAN; I. ERHAN GELGOR

*Turkey*

**ORTHODONTICS**

Different treatment modalities have been presented for the treatment for the class II, div 1 malocclusions. In this case report, we describe the treatment of 16 years old male adult patient who had a class II Division 1 malocclusion with a severe overjet (7 mm), a deep overbite (5 mm). Arch length discrepancies in upper right and left were -1,8 mm and -6,1 mm respectively, in lower right and left were 0,3 mm, -3,6 mm respectively. Ideal treatment of patient is orthognathic surgery but the patient and his family certainly do not want to have surgery. So our treatment plan was extraction of upper first premolar with fixed treatment and using servical headgear in night time to prevent the posterior teeth mesially. Treatment lasted 1 year and after orthodontic treatment essix plates above the lingual retainer were applied for retention.

**PP 127 TEN MONTHS IN VITRO EVALUATION OF MARGINAL ADAPTATION OF THREE LOW-SHRINKAGE RESIN COMPOSITES**

SEVDA YANTCHEVA; RADOSVETA VASILEVA

*Bulgaria*

**RESTORATIVE AND ADHESIVE DENTISTRY**

**Aim:** This in vitro study compared marginal integrity of three low-shrinkage resin composites used for II-class restorations before and after 10 mounds aging. **Materials and methods:** 60 standardized class II cavities with gingival margins below cemento-enamel junction were prepared in extracted human molars. The teeth were randomly divided into 3 groups (n=20) based on the composites used for restorations (F.Silorane, Kalore, SonicFill). After restorations of the cavities were done all specimens were thermocycled (1000 thermal cycles of 5C°/55C°). One half of the specimens from each group were subjected to aging in saline for 10 mounds, while other half were sputtered with gold and directly SEM analyzed for marginal adaptation. After 10 mounds,

aged half of the specimens were SEM analyzed the same manner. Data before and after aging were statistically analyzed and compared. **Results:** There were statistical difference between marginal quality in enamel and dentin. Silorane shows better results for dentin margins ( $p=0.0031$ ). Kalore and SonicFill demonstrated more marginal gaps for dentin margins. For all margins there was no statistical difference between Silorane and Kalore. Statistical difference existed between Silorane and SonicFill for dentin margins( $p=0.001$ ). After aging the tendency were the same, but results for all materials were reduced. Aging affected predominantly dentin margins, presence of marginal gaps increased statistically ( $p=0.001$ ). For enamel margins there were only marginal influence of aging ( $p=0.084$ ).

**PP 128 THE 980 NM DIODE LASER:A GOOD MODALITY FOR THE TREATMENT OF PROMINENT FRENULUM**

ELTON GJINI; MERITA BARDHOSHI; ESAT BARDHOSHI; ALKETA QAFMOLLA;  
NEADA HYSENAJ  
*Albania*

**LASERS**

**Introduction:** Labial frenectomy is a common surgical procedure in the field of oral surgery. A diode laser is portable, compact, efficient and has good bactericide and coagulation properties. Diode lase can be used in cw or pulsed way, non-contact and contact mode. **Material and method:** In this study we report our experience in the treatment of prominent laial and lingual frenulum with 980 nm diode laser. The technique of frenectomy was used under local anesthesia laser parameter: cw, 4 w, contact. The patients are follow up after one week, one month, six months for the evaluation of early and long term results. **Results:** None of the patient reported pain and swelling after one week from the treatment. Three weeks after treatment oral mucosa were completely healed. **Conclusion:** The technique of frenectomy is easy, fast and safe to be performed with 980 nm diode laser. This modality is well accepted by all patients.

**PP 130 EFFECTS OF SYSTEMIC DISEASES AND MEDICATION ON SALIVARY FLOW AND SUBJECTIVE ORAL DRYNESS**

MEHMET OĞUZ BORAHAN; FILIZ NAMDAR PEKINER; TURHAN ATALAY  
*Turkey*

**ORAL DIAGNOSIS-ORAL RADIOLOGY**

**Objectives:** The aim of this study is to evaluate the association of systemic diseases and medication with salivary flow and subjective oral dryness. **Methods:** Four groups are formed. First group includes the patients with unstimulated salivary flow  $< 0,1$  ml/min and subjective oral dryness; second group includes the patients with unstimulated salivary flow  $> 0,1$  ml/min and subjective oral dryness; and third group includes the patients with no subjective oral dryness and unstimulated salivary flow  $< 0,1$  ml/min. These three groups were independently compared with the control group which includes the patients with unstimulated salivary flow  $> 0,1$  ml/min and no subjective oral dryness. All diagnosed diseases and intake of medication were registered for all

participants. Hyposalivation was defined as an unstimulated salivary flow rate < 0,1 mL/min The question “Does your mouth usually feel dry?” was used as an indicator of subjective oral dryness. **Results:** Statistical differences were observed in the distribution of systemic diseases and medication among groups. **Conclusion:** In our study, systemic diseases and medication were found to play an important role in salivary flow rate reduce and of subjective oral dryness increase.

**PP 131 ELIMINATION OF DIASTEMAS ON MAXILLARY ANTERIOR REGION WITH MINIMAL INVASIVE REHABILITATION: A CASE REPORT**

BETUL AKA; BILAL YAŞA ; SERHAT KOSEOGLU; ESRA UZER ÇELİK

*Turkey*

**RESTORATIVE AND ADHESIVE DENTISTRY**

**Background:** Diastemas in the general population are mostly localized to the maxillary anterior region, with a hypertrophic upper lip frenulum or periodontal disease being the most commonly observed etiologies in the clinic setting. Direct anterior restorations are the first choice of treatment. Here we describe the treatment of diastemas associated with periodontal disease in the maxillary anterior region using direct composite restorations. **Methods and materials:** A male patient was referred to our clinic with a chief complaint of gaps between his maxillary anterior teeth. Intraoral examination revealed chronic periodontitis in this region. Initial treatment included scaling and polishing with oral hygiene instruction and gingivoplasty for the right central incisor. Then, the distobuccal edge of the left central incisor was abraded using a diamond bur. Finally, the diastemas were closed using an etch-and-rinse adhesive system (Optibond FL, Kerr, Orange, USA) and nanohybrid composite resin (3M ESPE, Filtek Ultimate, Germany). The restorations were finished with ultrafine burs and polished with Sof-Lex (3M Espe, USA) polishing discs and pastes. **Results:** The composite restorations for diastema closure showed a satisfactory color match and marginal adaptation, and patient satisfaction with the treatment outcome was high. No defect or discoloration in the restorations was observed at a 6-month follow-up visit. **Conclusion:** The success of restorative treatment depends on the esthetic integration between soft and hard tissues; therefore, direct composite restorations must be applied using appropriate techniques and materials, particularly in the anterior region.

**PP 133 AN ENDODONTICALLY TREATED MOLAR RESTORED WITH RESIN NANOCERAMIC CAD/CAM ENDOCROWN: A CASE REPORT**

FATMA YILMAZ; BILAL YAŞA; ESRA UZER ÇELİK

*Turkey*

**RESTORATIVE AND ADHESIVE DENTISTRY**

**Background:** Resulting from the development of adhesive and digital dentistry, the restoration of endodontically treated teeth has become simpler, more economical, and biocompatible in a single session. The endocrown, a type of total crowns, makes use of both pulpal walls as macromechanical retention and adhesive cementation as micromechanical and chemical retention by eliminating the use of a post and filling core. Nowadays, endocrowns fabricated by

resin nano-ceramics that have closed elastic modulus to dentin can be practicable with the support of CAD/CAM technology. **Methods and materials:** This case report describes the restoration stages of endodontically treated mandibular first molar that remains only buccal wall. After preparation, the restoration was designed and prepared with CAD/CAM technique using Cerec 3 (Sirona Dental Systems GmbH, Bensheim, Germany) system. As restorative material, Lava Ultimate (3M ESPE, St. Paul, MN, USA) that is a resin nano-ceramic was used. For cementation, Variolink® II (Ivoclar Vivadent, Schaan, Principality of Liechtenstein) was performed according to the manufacturers' instructions as a luting cement. **Results:** The endocrown has shown satisfactory performance and the satisfaction of the patient was quite good. **Conclusion:** Clinical studies have shown that the endocrown has functional longevity, and has become a promising alternative in the esthetic and functional recovery of endodontically treated molar teeth.

**PP 137 COMPARISON OF ADHESIVE MATERIALS IN CLASS V COMPOSITE RESTORATIONS PREPARED BY ER:YAG LASER AND BUR**

EMRE OZEL; ELIF BAHAR TUNA; ERHAN FIRATLI

*Turkey*

**RESTORATIVE AND ADHESIVE DENTISTRY**

**Purpose:** The purpose of this study was to compare total-etch, self-etch and selective etching techniques on the marginal microleakage of Class V composite restorations prepared by Er:YAG laser and bur. **Methods and materials:** Class V cavities prepared on both buccal and lingual surface of 30 premolars by Er:YAG laser or bur and divided into six groups. The occlusal margins were in enamel and the cervical margins were in cementum. Group-1: bur preparation (bp) + Adper Single Bond 2 (ASB) + Filtek Z550 (FZ); Group-2: laser preparation (lp) + (ASB) + (FZ); Group-3: bp + Clearfil S3 Bond Plus (CSBP) + (FZ); Group-4: lp + (CSBP) + (FZ); Group 5: bp + acid etching + (CSBP) + (FZ); Group 6: lp + acid etching + (CSBP) + (FZ). All teeth were stored in distilled water at 37°C for 24 hours, thermocycled 1000 times (50°C-55°C) and immersed in 0.5% methylene blue dye for 24 hours. After immersing, the teeth were sectioned and observed under a stereomicroscope for dye penetration. Data were analyzed by Kruskal-Wallis and Mann-Whitney U tests ( $p < 0.05$ ). **Results:** More microleakage was observed in cervical regions compared to occlusal regions in Groups 3, 5 and 6 respectively ( $p < 0.05$ ). There is no statistical significant difference in Groups 1, 2 and 4 respectively, in terms of cervical regions versus occlusal regions ( $p > 0.05$ ). No significant difference was observed among all groups in terms of occlusal and cervical surfaces, separately ( $p > 0.05$ ). **Conclusion:** Different etching techniques did not influence microleakage of Class V restorations prepared by Er:YAG laser and bur.

**PP 138 EVALUATING THE EFFECTS OF CAPPARIDACEAE SPINOSA ON PULP CELLS WITH XCELLIGENCE SYSTEM**

HUSEYIN TORT; ELIF AYBALA OKTAY; FULYA TOKSOY TOPCU

*Turkey*

**DENTAL BIOMATERIALS AND DEVICES**

**Objective:** The aim of this in vitro study is to assess the cytotoxicity of Capparidaceae Spinosa as an alternative cavity disinfection for % 2 chlorhexidine solution that has possible

cytotoxic effects on dental pulp cells with real time analysis system called xCelligence. **Material and method:** Dental pulp cells were harvested from freshly extracted third molars. 2x10<sup>4</sup> dental pulp cell/well concentration in the xCELLigence analysis system's E-plates to evaluate the effects of 10% Capparidaceae spinosa and 2% chlorhexidine solution on cell viability of cells by comparing control group according to cell index for a period of 72 hours. The cavity disinfection solutions were applied on explanation phase of cell growth after approximate 17 hours the system had started. **Results:** The possible cytotoxic effects of 10% Capparidaceae spinosa and 2% chlorhexidine solution on dental pulp cells were evaluated by using normalized cell index and baseline-normalized cells index graphics of the analysis system. The results revealed that Capparidaceae spinosa application on dental pulp cells have proliferative effect at first 24 hours, but both applications showed no cytotoxic effect at the end of 72 hours when we compared with control cell group. **Conclusions:** So, within the limitations of this study, it can be suggested that the use of 10% Capparidaceae spinosa and 2% chlorhexidine solution have no cytotoxic effect on dental pulp cells and additionally, 10% Capparidaceae spinosa showed less effect on cell proliferation.

**PP 139 ASSOCIATION STUDY FOR THE ROLE OF GLUT2 GENE IN CARIES SUSCEPTIBILITY, DIETARY HABITS AND BMI**

DOBRINA KARAYASHEVA; MARIA GLUSHKOVA; EKATERINA BOTEVA;  
VANIO MITEV; TANIA KADIYSKA  
*Bulgaria*

**PREVENTIVE DENTISTRY**

It is well known that various exogenous and endogenous risk factors contribute to dental caries development and progression. Recent genome-wide association studies (GWAS) led to the identification of hundreds gene loci associated with the risk of developing dental caries. GLUT2 is a member of the glucose transport protein family and it has been associated with a higher habitual consumption of sugar and is a good potential candidate for caries development. In order to determine whether the GLUT2 gene polymorphism (rs5400, Thr110Ile) is related to dental caries susceptibility, we performed an association study with 108 Bulgarian volunteers, all of them students in Sofia Medical University. The participants completed a questionnaire about their dietary habits, snacking between meals and BMI. Based on DMFT indexes, they were classified into three groups: caries free (CF, DMFT=0); low caries experience (LCE, DMFT≤5) and high caries experience (HCE, DMFT≥5). DNA analysis was performed by polymerase chain reaction (PCR) and direct sequencing. Data was processed with IBM SPSS Statistics version 19. No significant differences for the allele and genotype frequencies were found between the three groups of CF, LCE and HCE. The Ile allele carriers had slightly higher BMI (24,4 vs 23,2) and were more frequently snacking between meals (74% vs 63,5%). The conclusion is that the GLUT2 gene is unlikely to be associated with dental caries development in the Bulgarian population. However it could be barely related to individuals' BMI and dietary habits. **Acknowledgements:** The survey was supported by The Medical Scientific Council, Medical University of Sofia, Bulgaria.

**Background:** Bisphosphonate-induced osteonecrosis of the jaw, is osteonecrosis of the jaw in a person with a history of bisphosphonate use who undergoes subsequent dental surgery. Longer treatment with either the oral or intravenous preparations appears to be associated with increased risk. The use of plasma-rich growth factors (PRGF) therapy is still unclear but some benefits of this treatment have recently been described in association with discontinuation of bisphosphonate treatment and conventional therapy (medical or/and surgical). **Material and methods:** A 58-years old female patient reported for treatment with Zometa for 4 years. The clinical examination revealed areas of exposed bone in the molar region of the mandible bilaterally and movable upper right incisor with presence of pain and supuration. The treatment plan included administration of triple antibacterial therapy and extraction of sequestered teeth, necrectomy and debridment under endotracheal general anesthesia. Flap was dissected by neighborhood and the bone wounds were filled with autologous PRGF obtained by centrifuged blood. The suture and soft tissue plastic followed the PRGF application. No postoperative complications were observed. The nutrition was carried out through an early inserted nasogastric probe for 5 days. Oral antiseptic solutions were used to maintain the hygiene. **Results and Conclusion:** The applied surgical and medical therapy in combination with the application of a PRGF leads to the successful outcome in the treatment of BRONJ. The absence of oral food intake during the early postoperative period allowed maximum decontamination of the surgical site that contributes for this result.

**Introduction:** Although a number of approaches to implant-supported restoration of severely atrophic maxilla and mandibles have been developed, most of these treatments are costly and protracted. The All-on-Four concept, which uses only 4 implants to support an acrylic, screw-retained provisional prosthesis delivered on the day of implant placement, followed by a definitive prosthesis 3 months later. **Presentation of case:** 73 years old male patient with totally edentulous maxilla, and a partially edentulous mandible was referred to our clinic with the complaint of aesthetics and function. Complete arch immediately loaded prostheses supported by 4 implants were placed to the areas of maxillary premolar and molar. 24 hours after implant placement, screw-retained full-arch temporary prostheses were positioned. For the mandible, 4 more implant placed to the areas of premolar and molar teeth both side and anterior teeth from left to the right first premolars were prepared and zirconia restorations were cemented by dual cure resin cement. Radiographic assessments were obtained immediately after surgery and at each follow-up visit.

**Results:** After 6-month follow-up, no implant failed and all restorations were stable. The patient had a fracture on his provisional prostheses during treatment but it was repaired and had no other complications till to the definitive prostheses. **Conclusions:** This clinical case describes a technique used to supporting a fixed prosthesis in the completely edentulous maxilla following the all-on-four concept with immediate load. Longer follow-ups are needed.

**PP 143 TREATMENT OF ADOLESCENT RAMPANT CARIES WITH GIOMER RESTORATIONS**

GÜRKAN GÜR; GÜLBIKE DEMIREL

*Turkey*

**RESTORATIVE AND ADHESIVE DENTISTRY**

Rampant caries is defined as suddenly appearing, widespread, rapidly burrowing type of caries resulting in early involvement of pulp. Patients affected with rampant caries often have compromised aesthetics and function. Restoration of the carious lesion is a challenge since they are deeply burrowing into the enamel and dentine. **Case summary:** A 16 year old female patient reported to the Ankara University Restorative Dentistry Clinics with a chief complaint of cold sensitivity in anterior teeth and discolorisation. On clinical examination, atypic dentin caries were detected in her vestibule side of maxillary and mandibular anterior region. A treatment plan was made to do 12 direct composite restorations over three appointments after a prophylaxis, oral hygiene education and tray-delivered home topical fluoride delivery. The plan included laser gingivoplasty followed by restorations with Beautifil II giomer restorative for its esthetics, fluoride release and versatility. **Results:** The dental caries risk for an adolescent represents a challenge for the adolescent and the dental professional. The giomer materials have excellent esthetics and strength, which combined with the high longterm fluoride release make these materials a strong consideration in most all direct restorative cases. The patient has continued fluoride treatments at home on average about every one to two weeks.

**PP 144 MANAGEMENT OF A SEVERE EXTERNAL ROOT RESORPTION OF AN AVULSED MAXILLARY PERMANENT INCISOR WITH MTA**

EMINE KAYA; MESUT ELBAY; ÜLKÜ SERMET ELBAY

*Turkmenistan*

**PAEDIATRIC DENTISTRY**

**Background:** Avulsion is one of the most severe types of dental traumatic injuries. It represents a very complex wound because of the damages to the periodontal ligament, the pulp or the alveolar bone. Root canal treatment is an essential component of the treatment strategy. Failure to remove the necrotic pulp will result in infection-related resorption. In the presence of inflammatory root resorption, the usage of non-setting calcium hydroxide paste and replacing appropriately in the canal is recommended to control root resorption. Although advantages of MTA are well described in the literature, MTA has not been employed very often in the treatment of root resorption. This report demonstrated treatment of a severe external root resorption due to delayed

root canal treatment of an avulsed maxillary incisor with MTA. **Methods and materials:** An 11-year-old girl patient presented with a previously avulsed and replaced maxillary right central incisor after two months of injury. Clinical examinations revealed no mobility and no pocket depths around the tooth. Radiographic examination revealed a large periradicular lesion involving pathologic resorption. The tooth was treated with CaOH<sub>2</sub> for 2 months and apical third of the tooth was filled with MTA. Then the canal was obturated with gutta-percha and coronal restoration was completed with resin composite. **Results and Conclusion:** After 1 year, advanced osseous healing of the periradicular region had occurred and no clinical symptoms or signs were apparent.

**PP 145 MONOSTATIC FIBROUS DYSPLASIA: A CASE REPORT**

AYDAN KELES; KIVANC KAMBUROGLU; RANA NALCACI; BURCU KIRSAN

*Turkey*

**ORAL DIAGNOSIS-ORAL RADIOLOGY**

**Introduction:** Fibrous dysplasia results from a localized change in normal bone metabolism that results in the replacement of all the components of cancellous bone by fibrous tissue containing varying amounts of abnormal-appearing bone. Fibrous dysplasia may be solitary or multiple or may occur in another multiple form associated with McCune-Albright syndrome. The monostatic form of fibrous dysplasia, which accounts for 70% of all cases, is the type that most involves the jaws. **Case report:** A 34 year-old female patient was referred to our clinic with the complaint of sensitivity on the left mandibular posterior teeth. In intraoral examination, the existence of an expansion on lingual aspect of the left mandibular premolar site is revealed. Panoramic radiography showed both the migration on the root of left mandibular second premolar tooth and ground-glass appearance on the left mandibular premolar site. CBCT is performed for detailed examination. CBCT scans showed that trabeculae, which are located on the left mandibular premolar site, are shorter, thinner, irregularly shaped, and more numerous than normal trabeculae are. **Results:** Patient, who has FD lesion, must be informed that FD is not a malignant disease. If the findings show that the lesions are polyostotic form, consultation for defining the form and dissemination of FD lesions must be performed with Radiology and Endocrinology Department. Treatment must be planned according to the results of the consultation, especially while the dental operation is being performed on the site of FD lesion.

**PP 147 EFFECTS OF A CUSTOM MANDIBULAR ADVANCEMENT DEVICE ON THE UPPER AIRWAY OF A SEVERE OSA PATIENT**

BULENT PISKIN; BAHADIR EZMEK; ALPER UYAR

*Turkey*

**REMOVABLE PROSTHODONTICS**

Obstructive sleep apnea (OSA) is a life-threatening disease characterized with repetitive cessation in air flow during sleep. The prevalence of the OSA can vary from 2% to 4% in adult population. OSA may cause some chronic health problem such as hypertension and cardiac arrhythmia. However, in some severe cases, stroke and sudden death can occur during sleep. Many



treatment modalities such as; providing sleep hygiene, surfical interventions and posivite airway pressure (PAP) have been proposed for OSA till now. Among them, the most efficuous treatment modality is PAP. However, PAP therapies have some serious disadvantages. Additionally usage of this device is not comfortable for many subjects. Since 1982, oral appliance therapy has been emerged as a new promissing treatment modality for patient. The device is many advantages such as low cost, ease of usage. In this study, we aimed to present a dramatical changes in upper airway dimension of a severe OSA patient after the usage of mandibular advancement device.

**PP 148 OVERLAYS AND “TABLE TOPS” IN PATIENTS WITH PATHOLOGIC ATTRITION. A 3D FINITE ELEMENT ANALYSIS**

CORINA MARCAUTEANU; FLORIN TOPALA; ENIKO TUNDE STOICA;  
COSMIN SINESCU; LAVINIA MEDA NEGRUTIU

*Romania*

**RESTORATIVE AND ADHESIVE DENTISTRY**

**Introduction:** Pathologic attrition is the mechanical wear resulting from parafunction (for example bruxism) limited to the contacting surfaces of the teeth. The dental literature recommends adhesive partial crowns for the restoration of posterior teeth affected by this type of wear. **Purpose:** We evaluated overlays and “table tops” made from Tizian zirconia reinforced composite by a 3D finite element method, under normal and parafunctional occlusal forces. **Materials and methods:** 3D models of the maxillary first premolar and of his neighboring teeth were developed, using the Blender 2.55 beta program. We compared the stress profiles in the dental tissues and restorative materials subjected to functional (200 N) and parafunctional (800 N) occlusal loads. The tooth preparation for an overlay had total cusps coverage and a circular shoulder. For the “table top” we chose a minimal occlusal reduction, with or without preservation of the natural marginal ridges. We also tested three depth of preparation: 0,8 mm, 1 mm and 1,2 mm. **Results:** The highest maximum equivalent tensions values (Pa) appeared in the case of 0,8 mm thick table tops with the conservation of the marginal ridges, both at 200 N and 800 N. The lowest maximum equivalent tensions values (Pa) appeared in the case of 1,2 mm thick table tops with the conservation of the marginal ridges at 200 N. **Conclusions:** In order to avoid the breakdown of Tizian partial crowns in bruxing patients we recommend the conservation of the natural marginal ridges and a restorative material thickness of more than 1 mm.

**PP 149 PRESSED ALL-CERAMIC PARTIAL CROWNS IN PATIENTS WITH DENTAL EROSION. A 3D FINITE ELEMENT METHOD STUDY**

ENIKO TUNDE STOICA; FLORIN TOPALA; CORINA MARCAUTEANU;  
COSMIN SINESCU; LAVINIA MEDA NEGRUTIU

*Romania*

**RESTORATIVE AND ADHESIVE DENTISTRY**

**Introduction:** Erosion is the progressive loss of tooth substance by chemical processes that do not involve bacterial action. The affected posterior teeth can be restored pressed all-ceramic partial crowns (overlays or “table tops”, depending on the progression of erosion). **Purpose.** We

evaluated adhesive partial crowns made of IPS e.max Press by a 3D finite element method, under normal occlusal forces (200 N). **Materials and methods:** We developed 3D models of the maxillary first premolar and of his neighboring teeth, using the Blender 2.55 beta program. We used three preparation designs: total cusps coverage and a circular shoulder, placed at 1 mm from the occlusal contact point (for overlays) and minimal occlusal reduction for “table tops”, with or without preservation of the natural marginal ridges. **Results:** The highest maximum equivalent tensions values (Pa) appeared in the case of 0,8 mm thick table tops with the conservation of the marginal ridges. The lowest maximum equivalent tensions values (Pa) appeared in the case of 1,2 mm thick table tops with the conservation of the marginal ridges. The stress profiles are similar for all three preparation designs. The maximum equivalent tensions values (Pa) are located at the loading points; a stress concentration at the interdental areas can be also observed. **Conclusions:** 1,2 mm thick “table tops” made of IPS e.max Press, with the preservation of natural marginal ridges are highly recommended for the restoration of teeth affected by erosive wear.

**PP 151 COMPLEX ORODENTAL REHABILITATION IN ELDERLY PACIENTS**

MIHAELA ROMANITA GLIGOR; MIHAELA CERNUSCA MITARIU

*Romania*

**REMOVABLE PROSTHODONTICS**

Prosthetic treatment in elderly patient is most of the time the first solution for toothless extended situation, frequently met at old age. Chronic disease with this complex treatment with many secondary reactions is restricting the large scale of solution treatments. The goal of a good treatment solution is to preserve the existing teeth and to realize prosthesis with transmission of occlusal force in the long axis of the tooth. Special prosthodontic systems with occlusal attachment cap system allow technical solution for overdenture which protects edentulous crest from decubitus lesions, and offer good stability, comfort and aesthetics. More occlusal attachment systems on dental supports results more stable the overdenture.

**PP 152 INVESTIGATION OF FRACTURE RESISTANCE OF ENDOCROWN AND DIFFERENT POST SYSTEMS**

HAKKI CELEBI; EMRE KORKUT; ARSLAN TERLEMEZ; SERHAN AKMAN; YAĞMUR SENER

*Turkey*

**ENDODONTOLOGY**

**Objective:** The aim of this in vitro study was to evaluate the different restoring configurations of mandibular molars with excessive coronal damage, in order to compare the shear bond strength and failure modes of restored teeth. **Materials and methods:** Forty extracted mandibular molars were endodontically treated and divided into four groups (n=10). Glass fiber posts were used in Group A and restored with composite resin. Also glass fiber posts used in Group B and restored with zirconia crowns. Fiber reinforced posts and composite resin was used to treat Group C. Finally the teeth in the Group D were restored with endocrowns. Specimens were mounted in a universal test machine and were submitted to an oblique compression load, at an angle of 135 degrees to the long axis of the tooth, until failure. Statistical evaluation performed by

the ANOVA showed no significant differences between the groups ( $p=0.045$ ). The dominant failure pattern in groups was fracture of the root and fracture of the tooth on the side of force application. **Conclusion:** There are so many different techniques to restore endodontically treated teeth. From the results obtained, it may be concluded that endocrown may be an alternative approach for endodontically treated molar teeth with extensive loss of coronal structure.

**PP 153 PROSTHETIC REHABILITATION AT EXCESSIVELY WORN DENTITION: A CASE REPORT**

ZINDE GUDER; ONJEN TAK

*Turkey*

**FIXED PROSTHODONTICS**

**Background:** Dental wear depends on some etiological factors such as attrition, erosion, abrasion and abfraction. Tooth wear not only causes functional and aesthetic loss but also causes pathological consequences that depend on the loss of vertical dimension. Patients who suffer loss of vertical dimension because of dental wear can be prosthetically treated with zirconia and metal based ceramic restorations in order to gain aesthetics and resistance of fracture. **Methods and materials:** A 60 year-old male patient was referred to our clinic with the complaint of excessive tooth wear. After the clinical examinations the loss of vertical dimension was determined as 6 millimeters and a full mouth fixed restoration was planned for both jaws. At first the patient used a removable nightguard for adaptation to the new vertical dimension for 6 weeks. After the adaptation period the teeth preparations were done and the final impressions were made. For the posterior region porcelain fused to metal restorations and for the anterior region zirconia based ceramic restorations was fabricated. **Results:** The patient's 6 mm loss of vertical dimension recovered in single step. After one year follow-up the patient has no complaint in TMJ, good aesthetic results were achieved, and at the end of the follow-up period neither biological nor biomechanical complications were observed. **Conclusion:** The loss of vertical dimensions could be reestablished by full mouth restorations which are suitable and reliable treatment options even in these exaggerated types of cases.

**PP 154 EFFICIENCY OF MEDICATIONS ON REGENERATIVE CAPACITY OF GINGIVA AFTER FRENECTOMY**

JELENA MANDIC; ZORAN MANDINIC; DUSAN KOSANOVIC

*Serbia*

**PAEDIATRIC DENTISTRY**

**Background:** Even though the regenerative capacity of gingiva in children is very good, it is necessary to speed up the process of healing and reduce the risk of the post-operative problems. Goal was to examine the efficiency and effects of medication for epithelization on surgical wound after frenectomy. **Materials and methods:** The study was performed on 10 patients, ages 7-17 ( $10,3\pm 2,75$ ), which were divided in 2 groups. Experimental group consisted of 5 patients that applied Solcoseryl® after surgery, for the duration of 30 days, 3 times each day. Control Group consisted of 5 patients that did not use any medication. Patients were clinically examined on the day of the intervention, then on 7th, 15th, and 30th day, and following parameters were noted: level of

inflammation (oedema and hiperemie levels), presence of petechiae, ulcerations and bleeding, as well as dimensions of the surgical wound. The patients noted on a visual-analog scale (adjusted for children) levels of pain, burning sensations, itching, as well as difficulties during speech, eating and swallowing. **Results:** Statistical significance was noted on the 7th day in experimental group in size of the surgical wound, oedema and hiperemie levels. Experimental group did not show petechiae, ulcerations, bleeding, or pain sensations at 7th day checkup, as opposed to control. No statistical difference was observed at 15th and 30th day checkups. **Conclusions:** After 7 days, experimental group demonstrated faster wound regeneration, lower levels of inflammation and lower level of post-operative problems.

**PP 155** **STUDY REGARDING SOME RADIOLOGICAL ASPECTS IN ROOT PERFORATIONS**

LIANA AMINOV; MIHAELA SALCEANU; ANCA MELIAN; CRISTIAN GIUROIU;  
MARIA VATAMAN; MICHAEL TIMOTHEATOS  
*Romania*

**ENDODONTOLOGY**

**Introduction:** Radiological evaluation plays an essential role in the management of endodontic treatment, from diagnosis to treatment monitoring. Unfortunately, this method is not infallible, due to the limited ability of conventional radiography to show the three-dimensional dental anatomy. Therefore, an important principle in radiological imaging is to examine the concerned structures by a more accurate method. The study aims to highlight the differences in the use of two radiological techniques in patients with lesions occurring at different levels due to root perforations. **Materials and method:** 26 patients of both sexes (15 men and 11 women), aged between 27 and 54 years, were submitted to CBCT investigations. The CT-s were made with a 3D SCANORA® camera (SOREDEX) and operator parameters have been set to 3.0 mA and 80 kV, with exposure time of 17: 5 sec. Sections were made at 1mm in three spatial directions: sagittal, frontal and transverse through the lesion. Using the computer program for data analysis, were determined the three coordinates of the defects. **Results:** There was a difference between the two types of radiological examinations with an average value of  $2 \pm 0.3$  mm, higher for CBCT compared to periapical radiographs (PAR), 25 of the 26 cases (96% of the total), implying a more accurate description of lesions dimensions on CBCT compared to PAR. **Conclusions:** The advantages of CBCT in the evaluation of root perforations include an increased accuracy, a high resolution and a scan time reduction.

**PP 156** **PAEDODONTO-ORTHODONTIC INTEGRATIVE INTERFERENCES: EARLY CHILDHOOD CARIES**

DANA CRISTIANA MAXIM; IONUT LUCHIAN; LIANA AMINOV;  
CHRISTINA MARKOMANOLAKI; VERONICA PINTILICIUC SERBAN; ANA PETCU  
*Romania*

**PAEDIATRIC DENTISTRY**

**Background:** Early Childhood Caries (ECC) and Severe Early Childhood Caries (SECC) represents an important public health challenge, that can begin early in life, progresses rapidly in

those children who are at high caries risk and very often goes untreated. The etiology of ECC is multifactorial and is associated with poor diet and bad oral habits. **Aim of the study:** To review the dental literature that focusses on early childhood caries (ECC) and severe early childhood caries (SECC). **Material and methods:** A PubMed search was undertaken from 1998 to the present day. We have used the following search terms: early childhood caries, severe early childhood caries, baby bottle tooth decay, rampant caries. **Results:** A total of 45 articles were selected. Of these, 15 articles involved aetiology, 15 articles involved options of management of ECC and SECC, 10 articles were prevalence studies and 5 studies were reviews. The treatment of ECC depends on the progression of the disease, the child's age, the social, behavioural and medical history of the child. Children at low risk may not need restorative therapy. Children at moderate risk may require restoration of cavitated and progressive lesions. Children at high caries risk may require earlier restorative interventions of enamel proximal lesions. **Conclusions:** This disease increased in the past 10 years and is mostly untreated in preschool children. Significant research is needed to understand the biological and socio-demographic factors and also the preventive strategies to treat this kind of disease.

**PP 159 DETERMINING THE JAW RELATION IN TOTAL REMOVABLE DENTURES THROUGH INSTRUMENTAL METHODS**

EDIT XHAJANKA; GERTA KAÇANI; MERITA BARDHOSHI; ENDRI PAPARISTO;  
NEADA HYSENAJ

*Albania*

**REMOVABLE PROSTHODONTICS**

The preparation of total removable dentures requires special attention in determining of the centric occlusion which is important in the success of the denture retention. There are a lot of discussions if there should be a total compliance between the central occlusion and the centric jaw relation. To determine the Centric Relation (CR) a lot of physiological methods are used. Aim of the study: To determine the Centric Occlusion (Centric Relation) in the edentulous patients especially on those with a habitual occlusion, patients who have been denture wearers for many years. Material and method: 50 patients were treated with new dentures. Primary the Centric Occlusion was determined with manual methods (chin guide, linguo- mandible omotropia etc.) and after this it was determined again with the graphic method through a gnathometer. Both methods were compared with each other. Results: the Centric Occlusion was well determined through the manual method in 78% of the cases but in 22% it presented deviations of CR determined manually compared to the graphic method Conclusions: The Graphic method is a more reliable method especially in those patients with atypical condylar movement and severe mandible atrophy, in patients that have been denture wearers for years and in those with habitual occlusion.

## PAEDIATRIC DENTISTRY

**Background:** MIH syndrome term (molar incisor hypomineralisation) was first introduced by Weerheijm and col. in 2001 to define hypomineralisation of systemic origin affecting one to four first permanent molars frequently associated with hypomineralisation of the incisors. **Aim of the study:** to review the dental literature which focuses on MIH syndrome. **Material and methods:** A PubMed and an Embase search of the dental literature was undertaken from 2001 to the present day. The search terms used were: MIH, hypomineralisation, cheese molars, treatment or management of molar incisor hypomineralisation. The abstract of every article was read and the relevant ones were read fully. **Results:** a total of 40 articles were selected. Of these, 10 articles were prevalence studies, 10 articles involved etiology, 12 articles concerned treatment outcomes and modalities, and 8 articles were reviews and questionnaires of MIH. The treatment of permanent first molars is difficult on the one hand because of the difficulties with the small patient often anxious on the other hand due to the dental lesions difficult to be restored. Mathu-Muju and Wright (2006), suggest treatment plans depending on the severity of dental caries (mild, moderate, severe) and the time needed for treatment. **Conclusions:** all the information that has been provided on management of MIH syndrome in the international literature is quite limited. Early identification and management of MIH syndrome helps in preventing first permanent molar morbidity and mortality. More studies to help clarify the aetiology are required and further research is needed into restorative options.

## REMOVABLE PROSTHODONTICS

Patients with severe jaw atrophy are presented every day in the dental practice. These cases present a real challenge for the prosthodontist especially the denture in the lower jaw where is difficult to achieve good retention. The stability of the denture in the lower jaw is influenced by the relationship with periproshtetic organs (tongue, cheeks and lips) and the neutral space. **Aim of the study:** To describe the piesographic impression in total removable dentures as a method that can improve denture retention, stability and function in the lower jaw denture, through a case report. **Material and method:** An edentulous patient for more than 20 years, with a severe jaw atrophy was presented in our practice. The piesographic method was used to record the polished surface of the denture and the neutral mucosa through the functional movements of soft tissue and muscles. During the registration the patient was instructed to pronounce certain consonants. The material used was Ufi Gel P (silicon based soft liner) which can bond well with the occlusal rims. It has a long setting time and very good visco-elasticity properties. **Results:** After the treatment it was found an improvement of the esthetics, comfort and stability. **Conclusions:** Piesographic

impression can help to recreate accurate functional contours of the dentures and strictly placement of the teeth in the neutral space. This method shows great improvements of the denture especially in those patients with severe jaw atrophy, improves the retention and facilitates fitting process.

**PP 162 ETIOLOGY OF TRAUMATIC DENTAL INJURIES IN CHILDREN IN JAGODINA DISTRICT, SERBIA**

MARKO JEREMIC; ANA VUKOVIC; DEJAN MARKOVIC

*Serbia*

**PAEDIATRIC DENTISTRY**

**Background:** Traumatic dental injuries are considered important public health problem in preschoolers and school children in Serbia. The **aim** of this study was to analyze factors related to the traumatic dental injuries in children referred to Department of Pediatric and Preventive Dentistry, Jagodina Health Care Center. **Methods and materials:** The study sample included patients with traumatic dental injuries who received dental treatment during the period from 01/01/2013 to 01/01/2015 in Jagodina Health Care Center. Data were obtained from dental trauma records and included epidemiological and clinical data regarding etiology of injury, type of injury and provided treatment. **Results:** Total of 30 patients aged 2 to 17 years referred to health care center due to traumatic dental injury. Seventeen patients presented with hard dental tissue injury, 11 with periodontal tissue injury and 2 had concomitant injury. Boys were more frequently injured than girls both in primary (58%) and permanent dentition (77%). Uncomplicated crown fractures were the most common type of injury in permanent dentition (61%), and luxations were more frequent in primary dentition (64%). The most common place of injury in primary dentition was home and day care, while in mixed and permanent dentition injuries occurred most frequently in school yard, while riding a bicycle or playing contact sports. The most common cause of injury in both dentitions were fall and strike. **Conclusion:** Knowledge regarding etiology of traumatic dental injuries enables designing adequate prevention protocols and educational programs for community which are necessary considering public health importance of these injuries.

**PP 163 TREATMENT OF SEVERE DENTAL CROWDING: CASE REPORT**

MARIELLA ORICCHIO; ROZAFI DRAGUSHA; ANNA DI NUNNO;  
GIUSEPPE MARZO; LIVIO GALLOTTINI

*Italy*

**ORTHODONTICS**

**Background:** Severe dental crowding has great negative influences on the dentomaxillary system. Besides the esthetic problem, which is the main factor motivating the patient to ask for dental treatment, there are a lot of functional consequences influencing also periodontal condition. **Methods and materials:** The patient is 26 years old, she is a female and she shows anterior open bite, class II malocclusion, narrow upper arch and severe dental crowding. We make a superior and inferior metallic orthodontic bonding with Damon System technique. The expected length of therapy is about 24 months. In final stage we use a fixed retainer (post orthodontic splinting)

associated with removable retainer that can be worn at night. **Results:** At the end of therapy the patient shows proper dental alignment of upper arch. **Conclusions:** Damon System technique allows to obtain excellent results in patients with severe dental crowding, and in many cases allows to avoid dental extractions.

**PP 164 SURGICAL-ORTHODONTIC TREATMENT OF IMPACTED SECOND PERMANENT MOLAR: CASE REPORT.**

ALMIRA ISUFI; MARIELLA ORICCHIO; ANNA DI NUNNO; RUGGERO INGLETTO;  
LIVIO GALLOTTINI

*Italy*

ORTHODONTICS

**Background:** Impaction of the second permanent molars is not common. The etiology of impaction may be related to an insufficient arch length, excessive tooth size or excessive axial inclination. An impacted mandibular second molar represents a condition of great clinical interest because of its role in obtaining a balanced occlusion and a correct vertical dimension. **Methods and materials:** The patient is 14 years old, he is a male, he shows late mixed dentition and 4.7 is mesially impacted. First of all we make an inferior orthodontic bonding with MBT technique. Later we choose a surgical-orthodontic salvage with vestibular approach. Time to allow the disimpaction is about 5 months. In the end we use a removable retention appliance. **Results:** Post treatment intraoral and radiographic examination shows the corrected inclination of the impacted right lower molar (4.7) with proper interdigitation. **Conclusions:** This surgical-orthodontic disimpaction technique can be an excellent therapeutic choice in patients with mesially impacted mandibular second molar.

**PP 165 TREATMENT OF II CLASS MALOCCLUSION WITH MANDIBULAR RETRUSION IN CHILDREN: CASE REPORT**

BARBARA MUZZARELLI; MARIELLA ORICCHIO; GIOVANNI MANES GRAVINA;  
GIUSEPPE MARZO; LIVIO GALLOTTINI

*Italy*

ORTHODONTICS

**Background:** Class II malocclusion is the most common malocclusion seen in day-to-day practice, It can be due to protrusive maxilla, retrusive mandible, or a combination of both but mandibular retrusion is the most common feature of class II malocclusion in growing children. **Methods and materials:** The patient is a female, she is 12 years old and she shows late mixed dentition and class II malocclusion with mandibular retrusion (SNA: 84 SNB: 78 ANB:6). We treat the patient during the pubertal growth spurt with Balters twin-block (16 hours a day) for 18 months. **Results:** At the end of therapy the patient shows class I relationship and her class II profile becomes more balanced. **Conclusions:** Functional therapy with Balters twin-block can be an excellent therapeutic choice in correcting II class malocclusion with mandibular retrusion in children.



**PP 166 THE ADVANTAGES OF USING CBCT IN MANAGEMENT OF PERIAPICAL LESIONS**

BOGDAN DOBROVAT; IOANA RADU; ROXANA POPESCU; DANISIA HABA

*Romania*

**ORAL DIAGNOSIS-ORAL RADIOLOGY**

This study is an attempt to compare the prevalence of periapical lesions on distinct roots of teeth which have received an endodontical treatment as viewed with periapical radiography and with CBCT. **Methods:** There have been taken digital periapical radiographs and CBCT scans of 20 teeth from 15 patients who have been diagnosed with asymptomatic periapical lesions. In this study there have also been included teeth which have received an endodontic treatment one year ago and which have been reevaluated with the help of periapical radiographs and CBCT scans. Three calibrated examiners assessed the presence or absence of periapical lesions by analyzing the PA and the CBCT views. **Results:** Views of 50 roots which have received an endodontic treatment have been evaluated through digital periapical radiographs and as well as through CBCT scans. The comparison between the views which have been obtained show that periapical lesions are present in 7 cases where the roots have received an endodontic treatment (14%) and are absent in 43 cases (86%) where the roots have received an endodontic treatment. The same root fillings/obturations have also been evaluated through the CBCT scans, and thus the periapical lesions have been present in 44 (88%) cases and absent in 6 (12%) cases. The prevalence of the periapical lesions which have been detected through CBCT scans is significantly greater. **Conclusions:** This study highlights the advantages of using CBCT in management of periapical lesions present in teeth which have received an endodontic treatment three years ago.

**PP 167 ENDODONTIC MANAGEMENT OF DENS INVAGINATUS: USING BIODENTINE AS AN APICAL BARRIER TECHNIQUE**

CANSU GÜR; DILEK HELVACIOGLU YIGIT

*Turkey*

**ENDODONTOLOGY**

**Introduction:** Dens invaginatus is a tooth malformation and frequently presents a complex internal anatomy and might be associated with apical development. **Aim:** This case report presents non-surgical endodontic treatment of immature maxillary lateral incisor affected by dens invaginatus using Biodentine (Septodont, France) apical plug technique. **Method:** A 37 years old female patient referred to the Faculty of Dentistry, Kocaeli University, with a history of pain. Clinical examination revealed the presence of a sinus tract in the periradicular area of lateral incisor. Initial periapical radiograph revealed the presence of the immature apex with apical periodontitis. The canal length is determined with radiography. The root canal was prepared using hand files under copious irrigation with 2.5% sodium hypochlorite. Calcium hydroxide (Sultan Healthcare, USA) was placed into the root canal. After a 2-week interval, Biodentine (Septodont, France) apical barrier technique was performed. After placement of Biodentin plug, a control radiography was taken and overflow of the material was noticed. Endodontic treatment was completed using warm

compaction of gutta-percha with the backfill technique (BeeFill 2 in 1 VDW, Germany). **Results:** Although Biodentine overflowed into periapical tissues, acute immune response wasn't observed. After three months, the radiological findings revealed a slight decrease in the size of radiolucency but no apical closure. **Conclusion:** Biodentine can be used as a root end filling material and clinical findings support that Biodentine was biocompatible with periapical tissue.

**PP 169 3D LASER SCANNING FOR ASSESSMENT THE FACIAL SURFACE CHANGES OF EDENTULOUS PATIENTS AFTER PROSTHETIC REHABILITATION**

ANCA JIVANESCU; DANA CRISTINA BRATU; ALEXANDRA MAROIU;

LUCIAN TOMESCU; EMANUEL BRATU

*Romania*

**REMOVABLE PROSTHODONTICS**

**Background:** In the last decade, medical imaging evolved to more complex three-dimensional techniques. The laser scanner can be used as a soft tissue scanner and it is part of an array of imaging devices utilized for obtaining 3D images. **Methods and material:** Fourteen edentulous patients were randomly selected from the Department of Prosthodontics, at the Faculty of Dental Medicine in Timișoara, Romania. The changes that occurred in the lower third of the face after prosthodontic treatment were assessed quantitatively by measuring the vertical projection of the distances between two sets of anthropometric landmarks (D1 and D2), with the complete dentures both removed from and inserted in the patients' mouth. A two-way repeated measures ANOVA model design was carried out to test for significant interactions, main effects and differences between the two types of measuring devices and between the initial and final rehabilitation time points. **Results:** The measurement results obtained with the selected methods showed no statistically significant differences ( $p = 0.24$  for D1 and  $p = 0.39$  for D2), between the initial and the final rehabilitation time points. Regarding the main effect of time, there were statistically significant differences in both the measured distances, D1 and D2 ( $p = 0.001$ ), between the initial and the final points. **Conclusion:** The two methods of measurement were equally reliable in the assessment of lower face morphology changes in edentulous patients after prosthodontic rehabilitation with bimaxillary complete dentures. The differences between the measurements taken before and after prosthodontic rehabilitation proved to be statistically significant.

**PP 171 MISSING ANTERIOR TEETH TREATMENT WITH FIBER-REINFORCED COMPOSITE BRIDGES: TWO CASE REPORTS**

NURAY GUNAYDIN; DERYA DINC; HAYRİYE ESRA ULKER

*Turkey*

**RESTORATIVE AND ADHESIVE DENTISTRY**

**Background:** The purpose of this article was to present a clinical case of tooth replacement of a traumatically or periodontal missing anterior tooth by the agency of Fiber-reinforced composite (FRC). **Methods:** A 18 years old male and 30 years old female patients were admitted dentistry faculty of Selçuk University. First patient complained traumatically missing 11 numbered teeth. Second patients lost 41 and 42 numbered teeth with periodontal causes. We considered the bridge fabrication was done in the dental office using a restorative composite resin. Pontic was prepared by

composite material (Filtek Ultimate, 3M, USA) outside the mouth. Polyethylene fiber (Ribbond, USA) was placed 13-23 numbered tooth opening groove for first patient and 33-43 numbered tooth opening groove for second patient. And prepared pontic was pasted by composite on polyethylene fiber. **Results:** FRC bridge for easy applying and single visiting for the patient is beneficial and cheaper than the others. The clinical controls of the cases showed good stabilization, periodontal health and aesthetics **conclusions:** FRC bridges may be an effective therapeutic option for replacing missing tooth when an aesthetic restoration with minimal tooth reduction is required. Strengthening the connection between the pontic and abutment teeth is important to the achievement of such restorations, and FRC provides increased strength in the critical connector area, decreasing the potential for fractures and ensuring good bonding to the composite pontic. Fiber-reinforced composite bridges can be a good alternative to conventional prosthetic techniques.

**PP 172** **INDIRECT COMPOSITE INLAY RESTORATIONS: CASE REPORT**

NURAY GUNAYDIN; ALI RIZA CETIN

*Turkey*

**RESTORATIVE AND ADHESIVE DENTISTRY**

**Background:** Polymerization shrinkage of composite resins are one of the main causes of leakage and post-operative sensitivity. The aim of this work was to present a clinical case of a patient with molar class II MOD cavities restored with indirect inlays to eliminate polymerization shrinkage of composites. **Material and methods:** A twenty- four years old female patient admitted to Selçuk University Faculty of Dentistry for replace her amalgam restorations. The old amalgam restorations of 16 and 26 numbered of teeth were removed. Tooth was prepared for inlay conservatively and then impression was taken with Aquasil (Dentsply) and obtained the gypsum model. Indirect inlays were prepared with Estenia (KURARAY.JAPAN) indirect composite. Final polymerization/tempering was performed in the CS-110 light & curing system (KURARAY.JAPAN) by means of light and heat. Inlay was luted with Panavia F 2.0 (KURARAY, JAPAN). **Result:** The clinical and radiological controls of the cases showed good stabilization, periodontal health and aesthetics. **Conclusion:** The indirect inlay restorations with indirect composites of permanent molar with extensive cavities had good resistance similar to amalgam and better aesthetic. Although many studies, there is no consensus, what kind of teeth reconstruction – direct or indirect composite restorations are the most beneficial and the most durable. Equivalent stresses in the tooth structures restored with inlays and in the restoration material itself and contact stresses at the tooth-luting cement adhesive interface are many times lower compared to teeth with direct composite restorations.

**PP 176** **THE INCIDENCE OF CERVICAL SPINE ANOMALIES AMONG SAGITTAL SKELETAL ANOMALIES**

HAKAN KEKLIK; HASAN KAMAK

*Turkey*

**ORTHODONTICS**

The anatomy of cervical vertebra, may be effective on head and neck posture, craniofacial morphology, upper respiratory cavity, occlusion and temporomandibular joint disorders. Cervical

vertebra anomalies divided into two categories as posterior arch deficiency (partial cleft and dehiscence) and fusion anomalies (fusion, block fusion, and occipitalization). The classification of the sagittal skeletal anomaly is performed according to the ANB angle. Individuals are defined as ANB angle with 0 degrees and smaller Class III, between 0 and 4 degrees Class I and greater than 4 degrees Class II. The aim of this study to investigate that whether there is a difference among skeletal Class I, Class II and Class III individuals for the cervical spine anomalies. The study was performed on lateral cephalometric radiographs which were taken at the Department of Orthodontics, Faculty of Dentistry, Kırıkkale University. A total of 180 individuals (54 Class I, 57 Class II and 69 Class III) were included in the study. The radiographs were obtained with the teeth in occlusion and in a standardized head posture. The first five cervical vertebrae were examined in radiographs. Data analysis was performed with SPSS 20.0 software using the Chi-Square test. 10 individuals (4 Class I, 4 Class II, 2 Class III) had posterior arch deficiency and the 16 individuals (4 Class I, 6 Class II, 6 Class III) had fusion defects. The difference among the sagittal skeletal anomalies was not statistically significant ( $p>0,05$ ). A relationship between the sagittal skeletal classification and incidence of anomalies could not be determined.

**PP 177** **DISTRIBUTION OF THE CERVICAL VERTEBRAE ANOMALIES ACCORDING TO GENDER**

HAKAN KEKLIK; HASAN KAMAK

*Turkey*

**ORTHODONTICS**

**Aim:** The studies described the cervical vertebrae anomalies as related to craniofacial abnormalities, syndromes, head posture and mandibular condylar hypoplasia. Characteristics of the cervical Vertebrae Anomalies were classified divided into two categories as 'posterior arch deficiency' and 'fusion anomalies'. Posterior arch deficiency consisted of partial cleft and dehiscence and fusion anomalies of fusion, block fusion, and occipitalization. The aim of this study was to determine the observed anomalies of the cervical vertebrae whether a difference between male and female individuals. **Materials and Methods:** The study were performed on lateral cephalometric radiographs which were taken 1009 (562 girls, 447 boys) patients who treated in Department of Orthodontics, Faculty of Dentistry, Kırıkkale University. The radiographs were obtained with the teeth in occlusion and in a standardized head posture. The visual assessment of the cervical vertebrae included the first five cervical vertebral units that are normally seen on a standardized lateral cephalometric radiograph. Data analysis was performed with SPSS 16.0 software using the Chi-Square test. **Results:** 55 people from 1009 subjects (27 female, 28 male) were identified with posterior arch deficiency, while 82 people from 1009 subjects (31 females, 51 males) were identified as the fusion anomalies. The difference between male and female were statistically significant ( $p<0,001$ ). **Conclusion:** Probability of occurrence of cervical spine anomalies in males is higher than females.

**PP 178** **ENDODONTIC RETREATMENT OF S-SHAPED SECOND MAXILLARY PREMOLAR. A CASE REPORT**

CHRISTINA RAZCHA; THANASIS KARAMPASIS; LAMPROS INTZES;  
NIKOS OIKONOMIDIS; KLEONIKI LIROUDIA

*Greece*

**ENDODONTOLOGY**

Precise knowledge of the dental anatomy and its variations is essential for the success of endodontic treatment. Complex and unusual root canal morphology is an often occurring phenomenon. Understanding these unusual morphologies is a real challenge for the clinician and will facilitate proper access preparation, orifice location, cleaning and shaping of the root canal system and therefore a satisfactory final result. Maxillary premolars are the teeth with the widest variety of anatomic variations. One such variation, that occurs often in the maxillary premolars, is the 'S' shaped or bayonet shaped root canal. This report discusses the endodontic treatment of a maxillary second premolar with an 'S' shaped root canal, treated in the postgraduate clinic of the department of Endodontology of the Aristotle University of Thessaloniki School of Dentistry.

**PP 180** **MULTIPLE TEETH WITH HYPERCEMENTOSIS: A CASE REPORT**

POYZAN BOZKURT

*Turkey*

**ORAL SURGERY AND ORAL MAXILLOFACIAL SURGERY**

Hypercementosis is an idiopathic, non-neoplastic condition characterized by the excessive buildup of normal cementum on the roots of one or more teeth. A thicker layer of cementum can give the tooth an enlarged appearance, which mainly occurs at the apex or apices of the tooth. Extractions of these teeth are harder and may require bone removal. This is a case report of a patient with third molars and an impacted maxillary fourth molar with hypercementosis. Extraction of both impacted and erupted teeth required minor surgery.

**PP 181** **RATIONAL ADMINISTRATION OF ANALGESICS DURING ORTHODONTIC TREATMENT**

SOFIA A. PAPADAKI; IOANNIS PILALAS; ANASTASIOS A. ZAFEIRIADIS

*Greece*

**ORTHODONTICS**

**Background:** Orthodontic tooth movement is based on remodeling the bone around teeth; something which results in an acute inflammatory response of the periodontal ligament caused by the application of mechanical forces, mediated by prostaglandin synthesis. An analgesic is often administered if patients are intolerant of the pain in the initial phase of orthodontic treatment. However, some potential medications could affect the inflammatory process, which is associated with inhibition of prostaglandin synthesis. The orthodontist should be aware of the range of drugs available and be prepared to propose an appropriate analgesic capable of reducing discomfort

without interfering with the orthodontic treatment. **Aim:** To present different modalities of relieving the patient discomfort or pain during orthodontic treatment. **Materials and methods:** An electronic search of literature using Pubmed and Scopus databases. **Results:** Acetaminophen and Nonsteroidal anti-inflammatory drugs (NSAIDs) show similar results in regard to pain control; however, Acetaminophen does not appear to influence the synthesis of prostaglandins and affect the inflammatory process in contrast to the action of NSAIDs. **Conclusion:** There are indications that acetaminophen, as an inactive inflammatory agent, is the medication of choice in orthodontic treatment.

**PP 182** TREATMENT OF PATIENT WITH ANTERIOR OPENBITE USING BY MODIFIED TRANSPALATAL ARCH APPLIANCE: A CASE REPORT  
GÜLDEN UZGÖREN; HASAN KAMAK; HAKAN KEKLIK  
*Turkey*

#### ORTHODONTICS

**Aim:** The aim of this case report is to show the treatment results of a patient with anterior openbite treated by a TPA appliance with soldered tongue habit breaker and C hook for maxillary lateral teeth. **Material and method:** The radiographs, photos and cast records of the patient who has applied to our clinic because of crowded teeth were evaluated. The patient had a normal growth pattern, skeletal Class I and dental Class II anomaly. Her initial overjet was 3,8 mm and overbite was -0,5 mm. Based on our treatment plan, after extraction of maxillary first premolars, fixed orthodontic treatment of patient was started and a TPA appliance with soldered tongue habit breaker and C hook for maxillary lateral teeth was applied to her maxillary first molars. **Result:** At the end of the treatment, Angle Class I canine and Class II molar relationship, appropriate overjet-overbite values have been achieved, and the anterior openbite has been treated. According to results of our treatment, using this modified appliance has been showed as an effective treatment method.

**PP 184** TREATMENT OF CONGENITALLY MISSING LATERAL INCISOR WITH DIRECT COMPOSITE VENEER: CASE REPORT  
FIKRET YILMAZ; UMUT MISILLI  
*Turkey*

#### RESTORATIVE AND ADHESIVE DENTISTRY

Diastema can be caused by the differences in tooth size or the presence of teeth that is smaller than the width of the arch. Tooth loss or congenitally missing teeth can also cause the formation of the diastema. Maxillary lateral incisor deficiency is one of the most common encountered congenital tooth missing anomalies. This lack of teeth also brings great aesthetic problems. In this case, improvement anterior aesthetic of a patient have double-sided lack of lateral tooth with direct composite resin was aimed. **Case Report:** A-17-year-old female patient was admitted to our clinic with a request of the restoration of the upper front teeth due to aesthetic discomfort. The clinical and radiological examinations were determined not occur with congenital upper lateral teeth of patient. Moreover, periodontal problems or dental caries were not observed in

this patient. Treatment alternatives were explained to the patient. Then it was decided to restore teeth with the application of direct composite resin veneers. **Conclusion:** This conservative approach that involved conversion of the canine to lateral incisor provided an aesthetical appearance in a short time. There are different treatment alternatives for diastemas. This treatment alternatives are porcelain and direct composite laminate veneers, orthodontic treatments and prosthodontic treatments. Among these methods direct composite veneers, provided aesthetics in a single session, low cost and the most conservative treatment approach.

**PP 186** **EXPRESSION OF INTERLEUKIN-6 IN HUMAN CYTOMEGALOVIRUS INFECTED CHRONIC PERIAPICAL LESIONS**

JELENA POPOVIC; JOVANKA GASIC; ALEKSANDAR MITIC; MARIJA NIKOLIC

*Serbia*

**ENDODONTOLOGY**

**Background:** Chronic infection of dental pulp stimulates the development of inflammatory processes in periapical tissue. Inflammatory environment coupled with local bacteria can cause activation of herpesviruses. Herpesvirus infection may enhance the production of proinflammatory cytokines leading to immunosuppression and immunomediated periapical tissue destruction. The purpose of this study was to evaluate the presence of human cytomegalovirus (HCMV) in the samples of chronic human periapical lesions, to determine the concentration of interleukin-6 (IL-6), and to compare the findings with clinical characteristics of the analyzed lesions. **Methods and materials:** Twenty samples of chronic periapical lesions, obtained at the time of tooth extraction, were analyzed in this study. Each sample was cut into two equal parts. One part was used for detection of HCMV DNA using polymerase chain reaction (PCR). The other part of sample was prepared as 10% homogenate in order to determine the level of IL-6 using enzyme-linked immunosorbent assay (ELISA). **Results:** PCR analysis showed that ten periapical samples were HCMV positive, while ten were HCMV negative. HCMV active infection was detected in 61% of symptomatic and 28% of asymptomatic lesions. HCMV positive lesions showed higher concentrations of IL-6 (1391pg/ml) compared to HCMV negative (376pg/ml) and the difference was statistically significant ( $p < 0.05$ ). **Conclusion:** Detection of HCMV in the samples of periapical lesions suggests an important role of herpesviruses in the periapical tissue destruction. HCMV infections were more frequent in symptomatic lesions compared to asymptomatic. HCMV infection was associated with high concentration of IL-6.

**PP 187** **IMPLANT TREATMENT IN THE SEVERE ATROPHIC POSTERIOR MANDIBLE**

LUAN MAVRIQI

*Albania*

**ORAL IMPLANTOLOGY**

**Backgrounds:** New technique for vertical ridge augmentation in severe atrophic mandible. **Material and methods:** A 49-year-old female patient was presented with a bilaterally atrophic mandible and a need for implant therapy. Con-beam Ro showed mandibular ridges that were not suitable for immediate implant placement in terms of height (6,2 mm on the left side and 7,2 on the right side). Two vertical and one horizontal bone cuts using piezoelectric instrument were made 2

mm above the mental foramen. The more mesial vertical cut was performed 2 mm away from the adjacent tooth. The bone segment was then raised upward to leave space for the bone graft. An allogeneic bone block was inserted interpositionally and placed in the middle of the space formerly created without any fixation between the basal segment and the cranial segment. The remaining spaces in both ends were filled with particulate bone graft. The wound was then closed primarily. After 3 months endosseous implants were inserted, two into the right side, and three in the left side of the mandible, measuring 4 mm in diameter and 10 mm in length. **Results:** In this case the placement of implants of 10 mm in height was made possible with vertical ridge augmentation (6,2 mm on the left side and 7,2 on the right side), using the technique of sandwich osteotomy. **Conclusion:** The technique permits dental rehabilitation in terms of raising the bone above the nerve, reshaping the alveolar crest, and normalizing the interocclusal distance and the crown-implant ratio.

**PP 191** INVESTIGATION OF ANTIBACTERIAL ACTIVITY OF PAD WITH FOTOSAN, ND:YAG - LASER AND STANDARD ENDODONTIC TREATMENT  
TZVETELINA GUEORGIEVA; SLAVCHO DIMITROV; RAINA GERGOVA  
*Bulgaria*

#### LASERS

**Background:** Microbial infection is a main reason of dental pulp and periodontal diseases. PAD (photo-activated disinfection) and Nd:YAG-laser used as a complementary method to conventional endodontic treatment, lead to a significant reduction in bacterial infection. The **aim** of our study was to compare antibacterial activity of PAD with FotoSan, ND:YAG-laser and standard endodontic therapy in the treatment of infected root canals. **Materials and methods:** Our study include 54 teeth of patients who are diagnosed with gangrene of the dental pulp and chronic apical periodontitis. The teeth were divided into three groups depending on the method used for disinfection of root canals: Nd:YAG- laser, PAD, irrigation with 10 ml 2.5% NaOCL and 10 ml 17% EDTA. Microbiological sample was taken before and after treatment. **Results:** In all three methods there are a significant differences in the amount of microorganisms before and after treatment ( $p < 0.001$ ). PAD with FotoSan and irrigation with 2.5% solution of NaOCL have better antimicrobial activity then Nd: YAG-laser. **Conclusion:** Results of this clinical study show very good antibacterial effect of PAD with FotoSan. This method can be successfully used in endodontic treatment for additional disinfection of infected root canals, especially when lower concentrations of rinsing solutions are used.

**PP 193** EFFECT OF DIFFERENT IRRIGATION PROTOCOLS ON UNTOUCHED CANAL WALLS MORPHOLOGY: A SCANNING ELECTRON MICROSCOPIC STUDY  
JOVANKA GASIC; RADOMIR BARAC; JELENA POPOVIC;  
ALEKSANDAR PETROVIC; MARIJA NIKOLIC  
*Serbia*

#### ENDODONTOLOGY

**Background:** Some areas of the root canal wall remain untouched by normal hand and rotary instrumentation, harboring bacteria that can lead to root canal therapy failure. The purpose



of this study was to evaluate the morphology of untouched areas in the root canal after different irrigation protocols and compare with instrumented canal walls morphology. **Methods and materials:** A total of 36 single-rooted freshly extracted teeth were divided into six experimental groups. The canals were instrumented to size 40 file with crown-down technique and with an attempt to avoid the preparation of the entire canal. Experimental groups were irrigated with: (i) distilled water; (ii) 1% sodium hypochlorite (NaOCl); (iii) 17% ethylene-diamine-tetra-acetic acid (EDTA); (iv) 1%NaOCl+17%EDTA; (v) 1% NaOCl +17%EDTA and 1% NaOCl as final; (vi) 1% NaOCl+17% EDTA and 2%chlorhexidine as final. Six additional teeth served as controls. They had the same irrigation treatment, but without instrumentation. The roots were split longitudinally and prepared for SEM analysis. **Results:** In untouched areas of experimental groups was observed: (i) pulpal debris covering dentin; (ii) calcospherites; (iii) calcospherites absent, present opened tubules; (iv) calcospherites remnants, present opened tubules; (v) very enlarged tubules; (vi) clean areas with opened tubules. There are obvious differences in morphological appearance between untouched and instrumented canal walls, but some differences between the untouched areas and uninstrumented canal walls were observed. **Conclusion:** It seems that the untouched areas are inevitable and, with complex anatomy of the root canal system, indicate the importance of chemical means of cleaning and disinfecting all areas of the root canal.

**PP 194 IN VITRO EFFECT OF SOME ALCOHOLIC BEVERAGES ON DENTAL ENAMEL SURFACE MORFOLOGY AND SURFACE ROUGHNESS**

RADOMIR BARAC; JOVANKA GASIC; JELENA POPOVIC; ALEKSANDAR MITIC;  
MARIJA NIKOLIC

*Serbia*

**RESTORATIVE AND ADHESIVE DENTISTRY**

**Background:** There is little data about the erosive potential of alcoholic beverages. The purpose of this study was to evaluate in vitro effect of some alcoholic beverages on enamel surface morphology and surface roughness. **Methods and materials:** Enamel specimens (n=48) were assigned to one control and five experimental groups. Experimental samples were one-time immersed in: red and white wine, beer and two cocktails (Long Island and Sex on the Beach) for 3 hours. The initial pH of beverages was evaluated by pH-meter, titratable acidity (TA) by titration with NaOH, ultrastructure of enamel surfaces by scanning electron microscopy, and surface roughness by Stylus profilometer. Statistical analysis was performed using One-Way ANOVA. **Results:** the pH values of the beverages were below the critical and ranged from 2,98 (cocktail Long Island) to 4,18 (beer). White wine had the highest TA (10,2ml of NaOH to reach pH 7.0), while cocktail Long Island lowest (5,86 ml). All experimental samples, except those submerged in a cocktail Sex on the Beach (atypical etching), showed type-1 enamel erosion. The TA-parameter of experimental samples (except for those submerged in beer) was significantly different from the control. There was no difference among the samples submerged in white and red wine and two cocktails. **Conclusion:** All tested alcoholic beverages (except beer) were found to be erosive. Not established a unique enamel erosion ultrastructural model after one-time exposure to alcoholic beverages for 3 hours. Profilometric parameter confirms the enamel surface roughness, which was in accordance with the erosive potential of the tested beverages.

**PP 195** **MATRIX METALLOPROTEINASE-8 GENE POLYMORPHISM IN CHRONIC PERIAPICAL LESIONS**  
EVROSIMOVSKA BILJANA  
FYROM

**ORAL SURGERY AND ORAL MAXILLOFACIAL SURGERY**

**Background/Aim:** Increased levels of matrix metalloproteinase-8 (MMP-8) have been associated with risk of developing chronic periapical lesion (CPL). Gene polymorphisms are contributing factors in the pathogenesis of inflammation. The aim of this study was to analyze polymorphism in the gene MMP-8 and their association and influence on clinical manifestation of CPL. **Methods:** A total of 240 unrelated Macedonian subjects were included in the present study. Polymorphism -799 C/T in the gene MMP-8 detected with restriction enzyme BgIII was study in 120 patients with CPL and 120 controls without any signs of chronic or acute inflammatory process in the jaw. The amplification of the region of selected gene was made with polymerase chain reaction-restriction fragment length polymorphism (PCR-RFLP). **Results:** Our results showed that there was a differences in the allele and genotype frequencies of the MMP8 -799 C/T polymorphisms between patients with CPL and controls ( $p < 0.05$ ). Also this study suggests that MMP-8 polymorphism -799 C/T was a risk for expression of CPL ( $OR = 8.27 < 3.44$ ).

**PP 196** **COMPARISON OF SURFACE ROUGHNESS OF THREE BULK AND ONE POSTERIOR RESIN COMPOSITE**  
ALI IHSAN ERKAN; YUSUF BAYRAKTAR; SELIN BILGIN ERTUĞRUL ERCAN  
Turkey

**RESTORATIVE AND ADHESIVE DENTISTRY**

**Background:** Bulk composites are relatively new materials in restorative dentistry. Surface roughness is important feature for polishing, hence long life and color change of composite material. Thus, the aim of this study was to assess surface roughness of these materials. **Material and methods:** 60 disk shaped specimens (diameter 5mm, thickness-2 mm) were prepared from three bulk composite and one posterior composite and divided into four groups. Group 1; Tetric EvoCeram(Ivoclar vivadent, Germany), Group 2; Clearfil PhotoPosterior(Kuraray, Japan), Group 3; Filtek Bulk Fill (3M, USA), Group 4; Sonicfill (Kerr, Germany), Each specimen was cured under the mylar strips for 20 seconds from each of top and bottom surfaces. Top surfaces of all composites polished with discs from thick to thin types. All the specimens were stored in distilled water for 24 h at 37°C. Measurements of surface roughness (Ra) values were performed with a profilometer. For each specimen 3 measurements were performed. Data were statistically analyzed using one way ANOVA and Tukey's post-hoc test (SPSS 21) ( $p = 0.05$ ). **Results:** Mean values of groups were; Group 1a ( $0.37 \pm 0.24$ ), Group 2ab ( $0.53 \pm 0.19$ ), Group 3a ( $0.33 \pm 0.12$ ), Group 4b ( $0.49 \pm 0.26$ ). There was no difference between Group 1, 2 and 3. Also there was no difference between Group 2 and 4. **Conclusion:** According to the results higher values observed in Filtek Bulk Fill group and lower values observed in Sonicfill group. It seems bulk composites can show nearly polishing performance like long used posterior composites.

**PP 198 USING PATIENT'S OWN TEETH BY USING RIBBOND: CASE REPORT**

ALI IHSAN ERKAN

*Turkey*

**RESTORATIVE AND ADHESIVE DENTISTRY**

**Background:** Polythene fibers can be used for making periodontal splints, endodontically posts, temporary bridges after trauma and treatment of one teeth lose cases. In this case, it will be showed of treatment patient's teeth loss by using polythene fiber and his/her own teeth. **Method:** 21 years old male patient admitted to Selcuk University Faculty of Dentistry Department of Restorative Dentistry Clinic due to teeth loss of mandibular left central teeth. The cause of teeth loss was trauma. As a result anamnesis of the patient was not determined any inconvenience. In oral examination, determined a quantity of periodontal disorder. Lost teeth has made root canal treatment extraorally. After local anesthesia a 2 mm wide sulcus has prepared with diamond bur on mesial side of right mandibular canine to mesial side of left mandibular canine. Bonding agent (Clearfil SE Bond, Kuraray, Japan) was applied both dentine and enamel surface. Polthene fiber (Ribbond.Ribbond, USA) has filmed over bonding agent and applied in sulcus which is on tooth and light cured. Lost teeth was placed on fiber and signed with a pen for locating cavity area. After that a similar sulcus was prepared. Similar bonding agent procedures was applied on lost teeth and adapted on fiber. A composite resin (Ultimate, 3M, USA) was applied to all prepared tooth. **Conclusion:** Due to the anatomical structure of the mandibular front teeth, porcelain bridges fail to meet esthetically expectation and cause a lot of plaque amount. Also dental implants are expensive for many patients. Whereas adhesive bridges can meet expectations without these disadvantages.

**PP 199 COMBINATION OF OFFICE BLEACHING AND COMPOSITE VENEER AT TREATMENT OF FLOROSIS: CASE REPORT**

ALI IHSAN ERKAN

*Turkey*

**RESTORATIVE AND ADHESIVE DENTISTRY**

**Background:** Bleaching of fluorosis teeth which ranging from yellow to dark brown coloration is difficult for dentists. Further, in heavy discoloration cases, only composite veneer restorations don't fully enough to restore esthetic expectations. **Methods:** Seventeen years old female patient came to Selcuk University Faculty of Dentistry Department of Restorative Dentistry Clinic about esthetic complaint of anterior teeth. As a result anamnesis of the patient was not determined any inconvenience. We decided after the oral examination of these cases was fluorosis. Because of heavy discoloration two steps of treatments were planned. At step 1, office bleaching procedure was applied. Bleaching agent (Opalescence® Boost, Ultradent) was applied for 20 minutes after placing of gingiva protector. At step 2, tooth was treated with composite veneer (Ultimate, 3M) after one week of office bleaching. **Conclusion:** Composite resin has a wide range of applications all over the world. With fast development of dental industry, features of these are is moving towards perfection. But now, at hard cases due to inability to mask all discolorations,

bleaching like treatments are needed. With combination of materials, dentists can make adequate, fast and relatively cheap restorations.

**PP 201 EFFECT OF IN-VITRO AGING ON THE MECHANICAL PROPERTIES OF MONOLITHIC ZIRCONIA CERAMICS FOR DENTAL RESTORATIONS**

ELEANA KONTONASAKI; DESPOINA DELICHRISTOU; PANAGIOTIS KAVOURAS;  
PETROS KOIDIS

*Greece*

**DENTAL BIOMATERIALS AND DEVICES**

Yttrium stabilized zirconia (Y-TZP) all-ceramic restorations present high strength and considerably higher hardness (H) and Young's modulus (E\*) compared to all other dental ceramics, although they are prone to low temperature degradation (LTD) after aging that decreases their mechanical properties. Currently full-contour monolithic zirconia restorations have become the restoration of choice for many dentists due their strength and ease of fabrication. However their susceptibility to LTD has not been investigated. The aim of the present study was to investigate the hardness and Young's modulus of two monolithic zirconia ceramics after in vitro aging. The null hypothesis was that the hardness and Young's modulus of monolithic ceramics will not be affected by in vitro aging. Three rectangular specimens (1x10x10mm) from two zirconia blocks Bruxzir (BruxZir® Solid Zirconia, USA) and Zircon BioStar (SILADENT Dr. Böhme & Schöps GmbH, Germany) were cut by CAD/CAM technology, fully sintered and mirror-polished. The mechanical properties (nano-hardness (H) and elastic modulus (E\*)) were investigated by nano-indentation tests before and after in vitro aging (134oC, 2 bars, 10 hours). One-way Anova was used to test the statistically significant differences at p<0.05. In vitro aging resulted in a reduction of both H and E\* for both ceramics which was statistically significant (p<0.001) for the Bruxzir group (the null hypothesis was rejected). Under the limitations of this in vitro study it can be concluded that the clinical performance of monolithic zirconia ceramics may be affected during aging in the oral cavity, resulting in increased probability of failure.

**PP 202 MATERNAL PERIODONTAL STATUS AND PRETERM BIRTH**

SASA CAKIC; LJUBINKA NIKOLIC; MIA RAKIC; VANJA PETROVIC;  
NEDA PERUNOVIC

*Serbia*

**PERIODONTOLOGY**

**Background:** Preterm birth is considered as the major source of neonatal mortality and significant cause of neonatal morbidity. Maternal periodontitis represents the high risk factor for preterm birth. The exact pathogenic mechanism between preterm birth and maternal periodontitis still remains unknown. **Methods and materials:** The study included 120 sistematically healthy women : 60 preterm birth women (delivery before completed 37 weeks of gestation)- PTB group and 60 full term birth women (delivery after completed 37 weeks of gestation)- FTB group. All participants underwent periodontal examination within 48 hours following delivery and were stratified based on the periodontal status (periodontally healthy subjects, gingivitis and periodontitis). A full-mouth periodontal measurements were performed to record following clinical

parameters: probing depth (PD), clinical attachment level (CAL), bleeding on probing (BOP) and visible plaque accumulation (PI). **Results:** No significant difference in mean age was observed between preterm birth women and full term birth women ( $p=0.641$ ). All measured clinical parameters were significantly higher in PTB group compared to FTB group ( $p<0.001$ ). Analysis of periodontal status between investigated groups demonstrated significantly higher frequency of periodontitis in PTB group compared to FTB group ( $p<0.05$ ) and significantly higher frequency of periodontally healthy participants in FTB group compared to PTB group ( $p<0.05$ ). **Conclusion:** Preterm birth women showed higher rate of periodontitis and worse periodontal parameters compared to full term birth women.

**PP 204 EVALUATION OF CROSS INFECTION CONTROL IN DENTAL LABORATORIES**

DIANA ANTONELA DIACONU; MONICA SILVIA TATARCIUC;  
DIANA TATARCIUC; ANCA VITALARIU

*Romania*

**INTERDISCIPLINARITY**

The purpose of our study consisted in the evaluation of the cross infections knowledge in dental laboratories located in Iasi related to the prophylactic measures according to the patients and dental staff. In contrast to the dental treatment room and surgical operatories, the dental laboratory is often overlooked when planning effective infection control and exposure control measures. We realized for our research a questionnaire containing thirteen questions conceived by the authors. We received 218 answers out of 229 representing an answer rate of 95.57%. The study was conducted between March - September 2014. We noticed that most technicians, 95.4%, are aware of the existence of a real contamination risk, both of the lab surfaces and the personnel, however we have noticed a decrease of vigilance when they are forced to reduce the lab budget. Depending on their length of service corroborated with the effects of budget reduction, the analysis carried out demonstrates the existence of some statistically significant differences between the three age groups, the reduction of expenses determined by the economic crises is higher for those having a medium length of service as compared to the younger or older ones. Impressions, casts, impression trays, record bases, occlusal rims, articulators and dental prostheses can all transmit pathogenic microorganisms from the dental office to the dental laboratory. Our recommendations consist in providing practical courses for the reevaluation of knowledge and behavior towards the standard procedures for infection control in the dental laboratory and elaboration of guidelines for practitioners.

**PP 206 EVALUATION WITH SEM OF DIFFERENT FINISH LINES OF TOOTH PREPARATION**

SIDRIT BEQIRAJ

*Albania*

**FIXED PROSTHODONTICS**

The aim of this study was to assess, with electron microscope SEM, the marginal space of different configuration of finish lines of tooth preparation. 54 extracted teeth were randomly divided in 4 groups. In the first group ( $n=12$ ) was prepared the simple shoulder finish line. In the

second group (n=14) was prepared the chamfer finish line. In the third group (n=15) was prepared the 50 degree finish line and in the fourth group (n=13) was prepared the feather edge finish line. The assesment with SEM x200 is done in cross sectional section in three deffrent areas for each tooth. For each tooth examined, it was cemented a full prosthetic crown in all ceramic, full metal and porcelain fused to metal crown depend on specific configuration finish line. Analysis of Variances (ANOVA), with a Bonferroni multiple comparison test, showed significantly more marginal space in the fourth group with feather edge finish line compared with the three other groups (p<.0.05). Most with the examined teeth in the fourth group was covered with full metal and with the porcelain fused to metal crowns. Higher marginal space results in feather edge finish line configuration of tooth preparation compared with other three groups.

**PP 214 ORAL TONGUE AND FLOOR OF THE MOUTH CANCERS IN BELGRADE POPULATION**

GORAN VIDENOVIĆ; ZORAN VLAHOVIĆ; VOJKAN LAZIĆ;  
VLADIMIR MATVIJENKO; DRAGAN MARJANOVIĆ  
*Serbia*

**ORAL SURGERY AND ORAL MAXILLOFACIAL SURGERY**

**Introduction:** Cancers of the oral tongue (OT) and floor of mouth (FOM) are frequently brought together as tongue and floor of mouth (TFOM) carcinoma. The aim of this study was to analyze trends in age-standardized incidence rates of OT and FOM cancers among the Belgrade population during 12-years period. **Method:** From The Serbian Cancer Registry, we extracted all cases of TFOM cancers registered in Belgrade from 1999 to 2010. Age-standardized incidence rates (ASR) were estimated using the direct standardization method to the world standard population and presented as incidence rate per 100.000 persons in a year. Joinpoint regression analysis was used to define trends and annual percentage change (APC). **Result:** A total number of 638 (484 in men and 154 in women) TFOM cancers meeting the criteria were reported in The Registry during the study period. Among men ASR for OT cancers changed from 1.55 in 1999 to 3.02 in 2010 with APC of 4.4% (P<0.05) and among women from 0.63 in 1999 to 0.76 with APC of -0.7%. When TFOM cancers are considered separately ASR among men increased from 1.06 to 1.86 with APC of 4.4% and among women from 0.18 to 0.33 with APC of 5.2. **Conclusion:** Our results showed an increasing trend in the incidence rate for oral tongue and floor of the mouth cancers among the population of the city of Belgrade.

**PP 216 EVALUATION OF SMEAR LAYER REMOVING WITH CHEMICAL AND FIZICAL METHODS: SEM ANALYSIS**

IVONA KOVACEVSKA; CENA DIMOVA; ANA RADESKA; MIHAJLO PETROVSKI;  
GEORGIEV ZLATKO  
*Macedonia*

**ENDODONTOLOGY**

**Background:** Crucial action during the endodontic therapy is canal disinfection and elimination of smear layer. The aim of the paper was to make evaluation of smear layer elimination with EDTA and Nd: YAG laser. **Material and method:** 60 single root human teeth extracted from

prosthetic or orthodontic reasons were included in this study. After removal of the crowns of teeth endodontic treatment was realized. According to the method of removing the smear layer teeth were divided into two groups: in the first group of 30 teeth, after the final irrigation we had used 17% EDTA for 2 minutes, and in the second group of 30 teeth 8 sec. irradiation with Nd: YAG laser was used. After the elimination of smear layer, all examined teeth were longitudinally cut and prepared for SEM analysis, in coronary, middle and apical third of the root. **Results:** The elimination of smear layer is an important procedure in the endodontic therapy and multiple methods can be used for that. The results of our research showed that both methodologies are effective for smear layer elimination. EDTA solution efficiently and simpler in combination with irrigation successfully eliminates smear layer in the coronary and middle third of the root of the tooth. Nd: YAG laser is successful method for sterilization of channel space but requires specific equipment. **Conclusion:** Both methods are effective for removing smear layer but the choice still depends from the pulp disease, the endodontic treatment itself and from the selection and the decision of the therapist.

**PP 218 OVERFILLING OF ENDODONTIC MATERIAL INTO THE MANDIBULAR CANAL: A CASE REPORT**

EVGENIYA POPOVA; VIOLETA DOGANDZHIYSKA; TSONKO UZUNOV;  
PELO PELOV  
*Bulgaria*

**LASERS**

**Background:** Overfilling of root canal material is a common complication in endodontic treatment. The extrusion of endodontic materials into the mandibular canal leads to sensory disturbances such as pain, dysesthesia, paresthesia, hypoesthesia and anesthesia. Two fundamental mechanisms are responsible for the injury: the chemical neurotoxicity and the mechanical compression caused by the extruded material. **Case report:** We report a case of pain and paresthesia of the lower left lip of a 18-year-old woman after endodontic treatment of a mandibular left second molar. Panoramic radiograph revealed extensive leakage of root canal filling material into the mandibular canal. Conducted a non-surgical treatment with low-level laser therapy. **Results:** After treatment, the pain decreased and almost disappeared. Until the third month after treatment the response to paresthesia is negligible.

**PP 219 TRANSMIGRATIONS OF MANDIBULAR CANINES: TWO CASE REPORTS**

KADIR KAPLANOGLU  
*Turkey*

**ORAL DIAGNOSIS-ORAL RADIOLOGY**

**Background:** Pre-eruptive migration of a tooth across the midline termed "transmigration". This condition has not been reported for teeth other than mandibular canines. The aim of this report is to present two different patients with impacted transmigrant mandibular canines. **Material and methods:** A 28-year-old male patient referred to our clinic for routine control. Orthodontic treatment requirement was the complaint of the other patient who was 17-year-old male. They had no systemic disease. **Results:** Intraoral examination revealed the absence of right

mandibular permanent canine teeth in both patients. The transmigrated canine tooth was detected and there were no pathological entity both of them on panoramic radiography. Such migratory teeth have been discovered more frequently with using routine panoramic radiographic examination. The right permanent mandibular canine was located near the inferior border of mandible and below the apices of the incisor and left canine teeth in the 17-year-old male patient. In the other case transmigrant mandibular canine completely crossed the midline. **Conclusion:** Transmigration of the mandibular canine across the mandibular midline is an uncommon event described in the dental literature. Most of the time the canine just migrates without any pathological entity, there are no symptoms and such teeth have been discovered at the time of radiological examination.

**PP 220 KNOWLEDGE OF DENTURE ADHESIVES IN ALBANIAN DENTISTS.**

NEADA HYSENAJ; MERITA BARDHOSHI; EDIT XHAJANKA; SUELA TABAKU;  
FLORION TABAKU

*Albania*

**REMOVABLE PROSTHODONTICS**

**Background:** The aim of the study is to evaluate the knowledge and use of denture adhesives among dentists in Albania. **Materials and methods:** A questionnaire was mailed to 100 dentists who were sporadically chosen. The questions were with four alternatives: very good, good, moderate, weak and lack of knowledge. **Results:** The study showed that 31% of the general dentists had very good knowledge of denture adhesives, while 24% good, 33% weak and 12% had lack of knowledge for denture. The statistical test showed that there is significant statistical relation between knowledge and experiences of dentists. **Discussion:** There are multiple issues related to the clinical significance of a denture adhesive, but most important is its efficacy in improving function and its effect on the health of the underlying tissues. **Conclusion:** This study demonstrated that the rate of knowledge of these 100 general dentists in Albania towards denture adhesives has not been in a very good situation. It is believed that denture adhesive be able to enhance the fitness of a denture and provide psychological relief to the patient. Dentists agreed that education, not only for practitioners but also for patients, would raise the advantageous features and reduce the misuse of denture adhesive.

**PP 221 EFFECTS OF FIXED ORTHODONTIC TREATMENT ON ORAL HYGIENE HABITS AND GINGIVAL HEALTH**

GÜLEN KAMAK; HAKAN KEKLIK

*Turkey*

**PERIODONTOLOGY**

**Background:** Fixed orthodontic treatment process is a critical period for gingival health because it requires more careful oral hygiene applications. Especially additional applications such as superfloss have a place in adequate oral hygiene in this process. Although oral hygiene instructions are given to orthodontic patients more often, gingival problems can be seen more serious in the patients undergoing fixed orthodontic appliances. The aim of this study is to



investigate if there is an effect of fixed orthodontic treatment on oral hygiene habits and gingival health of the patients. **Materials and methods:** Seventy five patients (15-17 years old) were enrolled in the study. Oral Hygiene Indices(OHI) which consists of items covering domains such as brushing frequency, interdental cleaning, brushing times, etc. was performed to investigate the oral hygiene habits. Gingival Indices (GI) and Plaque indices (PI) were recorded to examine the gingival condition of the patients. OHI, GI and PI were recorded at prior to treatment, and three different times of the fixed orthodontic treatment. **Results and Conclusion:** A significant increase in OHI was found after the treatment was initiated. ( $p<0.05$ ) In the first and third month there was significant increase in GI and PI, too. ( $p<0.05$ ) After the first month of the treatment, no significant change was seen in OHI. However, in GI and PI there was significant increase during the first three months. In conclusion, fixed orthodontic treatment affects gingival health adversely in the first three months although improves oral hygiene habits.

**PP 222 UPPER LIP FRENECTOMY WITH DIODE LASER AND ER, CR: YSGG LASER: COMPARISON OF TWO CASES**

GÜLEN KAMAK; ENES TAN

*Turkey*

**PERIODONTOLOGY**

**Background:** High frenum attachment may lead to problems for the gingival health either due to interference in the plaque control or due to a muscle pull. These two cases demonstrate the surgical removal of high frenum by using two different laser systems. **Case Reports:** In case I, the area was anaesthetized with a local infiltration. A GaAlAs laser device with a continuous wavelength of 940nm was used to incise the frenum. 2 W of laser power was applied during surgery. In Case II, Er:Cr:YSGG laser with wavelength of 2780nm was applied to perform surgery. Frenum was incised by applying 1W of laser power. **Results and Conclusion:** In both cases, healing was uneventful. No complication, pain or bleeding was recorded. The results of two cases indicate that there was no difference between the two cases regarding the degree of pain, bleeding and post op complications. However as a result of needlessness of anesthesia, Er:Cr:YSGG is more advantageous than diode laser in frenum operation.

**PP 224 ORTHODONTIC TREATMENT AND ORAL HEALTH RELATED QUALITY OF LIFE: A PROSPECTIVE STUDY**

GÜLEN KAMAK; HAKAN KEKLIK; ENES TAN; SERHAT DEMİNER

*Turkey*

**PERIODONTOLOGY**

**Background:** Oral health related quality of life (OHQL) is defined as the absence of negative impacts of oral conditions on social life and a positive sense of dentofacial self-confidence. Patients who apply for fixed orthodontic treatment (FOT) are concerned with problems of their appearance and social acceptance, often more than functional reasons. Enhancing these aspects of quality of life is an important motive for the patients. The aim of this study was to evaluate the changes occur in oral health quality of life during FOT. **Materials and methods:** Eighty patients (15-17 years old) who had registered for FOT at the Department of Orthodontics were enrolled in the

study. A questionnaire of general conditions was filled out by patients to determine their demographic data, such as gender, age, race, and marital status. GOHAI which consists of 12 items covering three domains: oral functional limitations, oral pain and discomfort, and the psychological and behavioral impacts of oral conditions was applied to the patients to assess OHQL. Questionnaire was performed at baseline, at first month, 3rd month and 12th month of the FOT. **Results and Conclusion:** A significant increase in total GOHAI score was found after the treatment was initiated. ( $p < 0.05$ ) This increase was also significant for the subdomains functional limitations, oral pain, and psychological status. ( $p < 0.05$ ) After the first month of the treatment, no significant change was seen between first month, 3rd month and 12th month of the treatment. In conclusion, OHQL deteriorates in patients during the first year of orthodontic treatment.

**PP 226 COMPOSITE RESIN RESTORATION OF TURNER'S TOOTH - CASE REPORT**

LEJLA DELIĆ; TANJA PEJČINOVIĆ-JANEČEK; SEDIN KOBAŠLIJA; ELMEDIN BAJRIĆ  
*Bosnia and Herzegovina*

**PAEDIATRIC DENTISTRY**

**Background:** Turner's hypoplasia is structural anomaly of the teeth. It is usually expressed with hypoplastic defects, affects premolars and molars and changes its occlusal surface in a form of a cauliflower. Turner's hypoplasia is often resulting of a dental trauma up to third year of life. It can also occur as a result of an inflammatory changes in periapical area of primary teeth that disturb mineralization process of permanent successor. Rehabilitation of a patient with teeth structure anomalies represents great challenge from functional and also from esthetic aspect. **Case report:** 9 years old female patient comes into dental office of the Health Care Center Sarajevo due to dental caries. After dental history and clinical examination we assumed that the cause of structural anomaly of first upper right premolar is periapical lesion of first upper right primary molar. After conservative treatment of carious teeth, extraction of retained primary teeth roots we decided to esthetic reconstruction of first upper right premolar. Restorative procedure was performed with Artemis microhybrid composite resin material, which has wide offer of esthetic shades for reconstruction of enamel and dentin. This esthetic reconstruction is conducted by multi-layer technique of composite resin restoration, together with using of transparent and opaque shades of this material. **Conclusion:** It is possible to achieve satisfying functional and esthetic results with use of modern composite resin materials and principles of minimal invasive treatment. This is also of great significance in child patients.

**PP 227 POSSIBILITIES TREATMENT POSTEXTRACTION PAIN**

DZENAD GANJOLA; OLGA DJURIC; MAJA DELIC; SNEZANA RAZNATOVIC  
*Montenegro*

**ORAL SURGERY AND ORAL MAXILLOFACIAL SURGERY**

Postextraction pain or alveolitis sicca dolorosa is a complication which appears after tooth extraction, usually in the molar region of the lower jaw. In this paper two methods were compared: conservative and surgical- conservative method. The research was carried in order to establish which method is more advantageous and more effective. The pain treatment lasted for one year.

Thirty patients were treated and each of them was separately conducted during three weeks after the treatment. Fifteen patients were submitted to conservative therapy, and fifteen others to surgical-conservative therapy. The results (tables and charts) show that both methods are effective and that both methods lead to symptom termination. However, surgical- conservative method appeared to be more effective, because in the first seven days after the therapy, approximately 75% of the patients no longer had alveolitis symptoms.

**PP 228 LABIAL FRENECTOMY USING ER,CR:YSSG LASER (2780NM)- CASES REPORT**

AFRODITI CHALKIDOU; EIRINI ATHANASIADOU; KONSTANTINOS

ARAPOSTATHIS

*Greece*

**LASERS**

**Background:** Labial frenectomy is indicated when the presence of an anomalous or abnormal frenum is associated with functional, orthodontic, esthetic or periodontal problems. The **aim** of this study is to present laser assisted frenectomy using a 2780 nm ER,CR:USGG laser. **Methods and materials:** Laser assisted labial frenectomy was carried out to 3 healthy children, 6 to 12 years old. All children had an anomalous or abnormal frenum (class III, IV or V). The surgical procedure was similar in all the cases. Local anesthesia with 0,5-0,7 ml articain 4%, adrenaline 1:100000 was delivered 8 mm away from the frenum to avoid deformation of the surrounding tissue. The stretched frenum was dissected using a 600 µm tip, in contact mode and continuous motion with average power 1 watt, pulse duration 60 msec, water 30% and air 60%. No hemorrhage occurred and no sutures were applied. Oral hygiene instructions were given to the patients and to their parents. **Results:** The patients did not have any pain or hemorrhage during surgery and healing. No medication was prescribed. Healing occurred within 10 days. **Conclusion:** Use of 2780 nm ER,CR:YSSG laser is effective in the removal of labial frenum. The procedure is widely accepted from patients since it provides a simple, fast, non-bloody and painless procedure.

**PP 230 BLEACHING OF DISCOLOURED, ENDODONTICALLY TREATED ANTERIOR TEETH: 2 CASE REPORT**

DERYA DINC; NEVIN COBANOGLU; MURAT SELIM BOTSALI

*Turkey*

**RESTORATIVE AND ADHESIVE DENTISTRY**

**Background:** Discoloration of endodontically treated teeth is an important esthetic problem. One of the techniques commonly used for bleaching of these teeth is “walking bleach technique, which in many cases provides satisfying results. This paper reports esthetic rehabilitation of endodontically treated and discolored anterior teeth by bleaching and composite restorations. **Methods and materials:** In two patients 30 and 35 years of age, endodontically treated and discolored, mandibular right lateral incisor, canine and maxillary right central incisor was determined. Existing restorations were removed, gutta-percha were cut from 1 mm below cemento-enamel junction and a zinc phosphate cement barrier was placed. Bleaching agent, 35% hydrogen

peroxide, (Opalescence® Endo - Ultradent Products, Inc.) were placed in the pulp chamber and temporary restoration were made with zinc phosphate cement. Bleaching agent were changed every 4 days. After 3 visits bleaching agent removed and teeth were temporally restored with zinc phosphate cement. One week later, teeth were restored using a nano composite resin. ((Filtek Ultimate (3M,USA)). **Results:** At the end of therapy, the teeth bleached enough to allow the patient's esthetics. **Conclusion:** 35% hydrogen peroxide with walking bleach technique can successfully bleach discolored endodontically treated teeth.

**PP 231 GUMMY SMILE CORRECTION AND ALVEOLAR RIDGE AUGMENTATION USING SUBEPITHELIAL CONNECTIVE TISSUE**

ARIONA DEMIRAJ; LUAN MAVRIQI; EGRESA BACA

*Albania*

**PERIODONTOLOGY**

**Backgrounds:** This case report provides an approach for the correction of the gummy smile and alveolar ridge augmentation using sub-epithelial connective tissue grafts. **Materials and methods:** A 40-year-old woman was presented with the hope of improving only the aesthetic appearance of her anterior maxillary prosthesis. The patient had a gummy smile. Radiographic examination showed teeth loss (14, 16, 21, 24, 26, 27, 36, 45, 46). Surgical ridge augmentation was discussed and crown lengthening for the teeth 17, 15, 13, 12, 11, 22, 23, 25, to correct the uneven gum line. The correction of the gum line was used the Laser to remodel the soft tissue of the gingival margin. A sulcular incision was done and after flap rising, crown lengthening was performed with bone remodeling. The connective tissue grafts were harvested from the palate. The soft tissue graft was positioned and light compressed to shape the edentulous ridge. The wounds both of the donor and recipient sites were sutured. The sutures were removed 10 days after surgery. The ovate pontics were adjusted at regular post-surgery follow-up appointments to achieve optimal cervical contour. Expected ridge improvement was realized with adequate bucco-lingual and apico-coronal contours. Thus, after 2 months the final impression was taken, and the final fixed prosthesis in metal-ceramic was fabricated and cemented. **Results:** The results achieved in this clinical case were horizontal ridge augmentation and high aesthetic outcome. **Conclusions:** This case report illustrates the aesthetic correction of the gummy smile and alveolar ridge augmentation using sub-epithelial connective tissue grafts. The apico-coronal and bucco-lingual augmentation of the edentulous ridge improves both functional and aesthetic outcomes.

**PP 232 DIASTEMA CLOSURE AND VITAL DENTAL BLEACHING**

MEHMET TARTICI; RUHSAN MÜDÜROĞLU; GÜRKAN GÜR

*Turkey*

**RESTORATIVE AND ADHESIVE DENTISTRY**

Diastemas are spaces of varying magnitude between the crowns of fully erupted maxillary and mandibular teeth. Some of the etiological factors for diastemas are developmental, pathological and neuromuscular. Direct bonding restorations are fast, predictable and low cost treatment to achieve harmony in terms of a patient's aesthetics, function and health. A 23 year old female patient came to the Department of Restorative Dentistry Ankara University Dental Hospital, complaining

about spaces among maxillary anterior teeth and staining in aesthetic areas. Through a clinical examination the aesthetic problems of the patient in maxillary anterior part were spaces among teeth between right lateral to left lateral incisor. On the first visit enamel microabrasion is indicated for the removal of superficial stains and irregularities of the enamel mainly located between maxillary second premolar teeth. The technique involves the mechanical rubbing of acidic and abrasive agents on the altered surface. After microabrasion vital bleaching agent %40 hydrogen peroxide (Opalescence Boost) was applied on surface of these teeth for 20 minutes and it was repeated twice. Models were prepared and a closed gap was designed. Silicone template method was used. After etching, priming, bonding of teeth surfaces teeth restored with resin composites and diastemas are closed. Polishing discs used to finish and polish the final restorations. Successful diastema closure treatment depends on different factors such as analysis of case, material choice. This procedure is considered a safe, conservative and atraumatic method for removing superficial enamel stains and defects also close diastemas.

**PP 233 IMPACTED CANINES - PROBLEMS AND PROGNOSIS**

SNEZANA RAZNATOVIC; DZENAD GANJOLA; MAJA DELIC

*Montenegro*

**ORTHODONTICS**

**Background:** Canines are the most commonly impacted teeth, second only to third molars. The incidence of canine impaction is approximately 1-4% of the population and is twice common in female, in the maxilla more than twice that in mandible. Of all patients who have impacted canines, 8% have bilateral impactions. Approximately one-third of impacted maxillary canines are located labially and two-thirds are located palatally. **Methods and materials:** The study group consisted of 23 patients with unilateral impacted canines. The position of the impacted canines was assessed on periapical films and panoramic images. The treatment protocol of the impacted canines included surgical exposure and fixed orthodontic appliances. **Results:** Bone loss, root resorption and gingival recession around the treated teeth are some of the most common complications. Prognosis is determining: age of patient, availability of space, favorable position of canine (canine angulation to midline, vertical height of impacted canine, position of the canine apex and mesiodistal position of canine tip to adjacent tooth), presence of adequate width of attached gingiva. **Conclusions:** The management of impacted canines has a multidisciplinary approach as it plays a vital role in esthetics, function and in quality of life.

**PP 236 TREATMENT OF PERIAPICAL LESIONS BY THE CONSERVATIVE WAY**

MAJA DELIC; SNEZANA RAZNATOVIC; DANIJELA SUBOTIC; DZENAD GANJOLA

*Montenegro*

**ENDODONTOLOGY**

**Introduction:** Patients with periapical lesions are very common in our clinic. The purpose of this study is to evaluate the conservative approach in the treatment of periapical lesions for our patients, based on all the characteristics that accompany them. **Materials and methods:** We have treated 50 patients with conservative treatment with granuloma, cystoze granuloma and cyst

(treatment of chronic periapical lesions). Differential diagnosis, control of endodontic infection, expansion located in the apical foramen and filling of the cavity or granulomatosis cystic with paste containing calcium hydroxide and iodoform were important procedures for the resolution of cases. The study included 50 patients with periapical lesions, which are treated with this paste and followed for a period of 2 years. **Results:** All patients who were treated with the above method not only reacted very well, but during the assessment with radiography, the cases present elimination of these lesions and bone regeneration. The only factors related to duration of treatment and the slowdown of the speed of bone formation was prolonged time of pathology, age, sex and malnutrition. **Discussion:** Based on the latest literature on treatment of periapical lesions and our clinical experience we can say that conservative treatment is appropriate and quite healthy, especially in the treatment of patients in our country.

**PP 239 SURGICAL REMOVAL OF POLY-ETHER-ETHER-KETONE DERIVED BASAL TYPE IMPLANTS: A CASE REPORT**

ILKER KESKINER; AHMET AYDOGDU; SEDA OZTURAN

*Turkey*

**ORAL IMPLANTOLOGY**

Poly-ether-ether-ketone (PEEK) is a radiolucent material commonly used in spinal surgery substitute for titanium. It is used as a dental implant material. However, related literature is very limited. This case report presented the surgical removal of PEEK derived basal dental implants due to failure of osseointegration. A 58-year-old female referred our clinic with the complaint of mobility and pain related with PEEK derived implants. The removal of dental implants was planned due to infection after intraoral and radiographic examination. The implants were removed following the reflection of mucoperiosteal flap from the insertion gap in the vestibule. Due to having limited knowledge about PEEK implants, it should be provident in application and when the removal is needed, the shape and the structure of implant should be taken into consideration in surgical approach.

**PP 240 INTERDISCIPLINARY TREATMENT OF IMPACTED TEETH AFTER CAR ACCIDENT: CASE REPORT**

MEHMET EMRE YILMAZ; MEHMET AKIN

*Turkey*

**ORTHODONTICS**

**Aim:** Orthodontic treatment in adult patients is one of the most frequently encountered components involving multidisciplinary approaches. Orthodontic treatment aims at providing an acceptable functional and aesthetic occlusion with appropriate tooth movements. These movements are strongly related to interactions of teeth with their supportive periodontal tissues. In modern clinical practice, the contribution of the orthodontist, the periodontist and the prosthodontist is essential for optimized treatment outcomes. The aim of this case-report is to present the treatment result of combined orthodontic and prosthetic treatment of three maxillary incisors after car accident. **Materials and methods:** The patient was a 27 year-old-boy seeking best treatment for his

teeth after car accident. Clinically patient had impacted 21, 22 and 12 number of teeth and Class II malocclusion with very low angle profile. The panoramic radiograph showed three impacted teeth and two mini plates at zigoma region. Maxillary and mandibular fixed brackets (Equilibrium®2, Dentaaurum, Phorzeim, Germany 0,018"x0,025") were used. After initial leveling, impacted teeth surfaces opened surgically and ligated to the main archwire to erupt. **Results:** Impacted teeth were erupted orthodontically and vertical dimensions of the patient increased. More lower incisor appearance achieved. At the end of the orthodontic treatment, dental prosthesis of patient was applied to the impacted teeth. **Conclusions:** After successful orthodontic treatment patients vertical lengths in lateral cephalograms increased. We believe that patient got better appearance with interdisciplinary treatment.

**PP 242 THE RELATIONSHIP BETWEEN THE DURATION AND THE SIZE OF NONMELANOMA SKIN CANCER**

VOJKAN LAZIĆ; GORAN VIDENOVIC; ZORAN VLAHOVIĆ;  
DRAGAN MARJANOVIĆ; VLADIMIR MATVIJENKO

*Serbia*

**ORAL SURGERY AND ORAL MAXILLOFACIAL SURGERY**

**Introduction:** Nonmelanoma skin cancers (nm-sc) are in the literature mainly related to basal cell (bcc) and squamous cell skin carcinoma (sc). Although the mortality rate of nonmelanoma skin cancers is low they can cause significant morbidity especially on highly visible areas such as head, neck and face. The **aim** of this prospective study is to determine the relationship between the duration and the size nonmelanoma skin cancers. **Methods:** Linear regressive analysis was used for establishing the correlation between the diameters of tumors and their duration. **Results:** The average growth was 4.3 mm annually for bcc and 6.1 mm for sc. The values of the coefficient of linear correlation for bcc was 0.94 and for sc 0.82. **Conclusion:** Tumor duration is a significant indicator for biological aggressiveness or skin cancer.

**PP 245 IMPLICATIONS OF ORTHODONTIC TREATMENT ON THE PERIODONTAL TISSUE IN CHILDREN AND TEENAGERS WITH DENTO-MAXILLARY ANOMALIES**

IONELA ELISABETA CIOBANU; PETRA SURLIN; RAUL POPESCU; LUCIAN DRAGOMIR; ANNE-MARIE RAUTEN

*Romania*

**ORTHODONTICS**

**Purpose:** Dento-maxillary anomalies and their therapy may represent risk factors for periodontal disease. The aim of this study was to establish the main favorable and unfavourable aspects when initiating orthodontic treatment on the architecture of the dento-maxillary complex in children and teenagers with dento-maxillary anomalies based on its initial structural features as well as on the consequences following the adjunction of inflammation during orthodontic therapy. **Material and method:** the data required for this study have been gathered for 4 years by examination of a group of 162 patients with dento-maxillary anomalies aged between 7-19 years following orthodontic treatment. **Results:** At the end of the orthodontic treatment 5,55% of the

subjects were experiencing gum folds at each post-extraction space of first molars; in 3,7037% the orthopantomogram performed at the end of the treatment highlighted a slight rounding of the incisors root apexes, and in 5,55% alveolar limbus loss in one (3,6585%), or several teeth (7,317%). Simple chronic gingivitis was present in 14,814%; hyperplastic gingivitis was found in 20,987% of the subjects; and 5,55% experienced gingival retractions ( $\geq 2$ mm). **Conclusion:** If orthodontic treatment is performed correctly, it will not incur additional periodontal alterations, even if performed in a patient with a reduced but healthy periodontium. An incorrect orthodontic treatment can lead to the emergence or worsening of periodontal problems, especially when combining the presence of the gingival inflammation and the occlusal trauma with inadequate orthodontic forces.

**PP 246 LASER-ASSISTED NON-SURGICAL TREATMENT OF GENERALIZED AGGRESSIVE PERIODONTITIS: A CASE REPORT**

ELIF INONU; FERHAT DANISMAN; SEMA S. HAKKI

*Turkey*

**PERIODONTOLOGY**

**Background:** The aim of this case report is to demonstrate the effect of diode laser decontamination as an adjunct to nonsurgical periodontal therapy in the treatment of aggressive periodontitis. **Material and method:** A-32-year-old female patient with aggressive periodontitis has applied to Selcuk University Department of Periodontology with gingival bleeding, tooth mobility and esthetic complaint. The pocket depths and clinical attachment levels were evaluated. Since she was in breastfeeding period, antibiotics could not be prescribed. She had received diode laser decontamination as an adjunct to scaling and root planning. Diode laser decontamination Second scaling and root planning treatment was applied with Laser treatment was performed by using a 940 nm indium gallium aluminum-phosphate diode laser). The periodontal pocket was set at 1.5 W with a pulse interval of 20 ms and pulse length of 20 ms delivering 20s/cm<sup>2</sup> and 15 J/cm<sup>2</sup> of energy. Laser application was done from mesial to distal at the buccal aspect for 10 s and distal to mesial at the lingual aspect for 10 s reaching a total of 20 s for each tooth. **Results:** Diode laser decontamination as an adjunct to non-surgical periodontal therapy improved clinical parameters including clinical attachment level and probing pocket depth. **Conclusion:** Diode laser can be used as alternative to antibiotic therapy as an adjunct to mechanical periodontal therapy, when the patients have contraindication for antibiotic usage due to systemic disease, allergy or breast feeding period. Further randomized controlled clinical studies are required to clarify the effectiveness diode laser in periodontal therapy.

**PP 247 IMPORTANCE OF ORAL-DENTAL ABNORMALITIES FOR THE DIAGNOSIS OF RARE GENETIC DISORDERS**

CIHAN ALP SONMEZ; SIBEL YILDIRIM

*Turkey*

**PAEDIATRIC DENTISTRY**

**Background:** Adams-Oliver syndrome is a rare genetic disorder present at birth and its prevalence is unknown. The primary features are abnormality in skin development (called aplasia



cutis congenita) and malformations of limbs. Abnormalities of hands and feet are also common in people with Adams-Oliver syndrome. Frequently seen symptoms are abnormal nails, fingers or toes that are fused together (syndactyly), and abnormally short or missing fingers or toes (brachydactyly or oligodactyly). In some cases, bone under the skin is also underdeveloped like maxillary bone. Various bone and soft tissue disorders may be signs of Adams-Oliver Syndrome. **Material and method:** 11 years old male. This patient applied to our clinic with pain complaint in 26 numbered tooth. Patient's skin and hands was malformed. Patient has cardiovascular disorder. Patient's teeth were misaligned, mouth opening was narrow and patient has maxillary growth retardation (Class III). **Result:** Multiplicity of oral-dental abnormalities directed us to genetical consultation, which gave us an outcome of very rare genetic disorder: Adams Oliver Syndrome. **Conclusion:** In this syndrome there are several needs for oral-dental rehabilitation. However, in the case presented it was only # 26 need for invasive intervention. Tooth was extracted because of limited mouth opening and gag reflex. Patient was referred to orthodontic treatment because of maxillary growth retardation and misaligned teeth.

**PP 248 THE ROLE OF PROGESTERONE ON PREGNANCY GINGIVITIS**

VERA RADOJKOVA-NIKOLOVSKA; M POPOVSKA; A MINOVSKA; B DZIPUNOVA;  
B NIKOLOVSKI  
FYROM

**PERIODONTOLOGY**

**Introduction:** The biggest physiological and hormonal changes in a woman's life occur during pregnancy when all functions of the body of the mother adapt to the new conditions. **Aim:** To determine serum and salivary level of sexual hormone progesterone in pregnant patients and to determine its effect on gingival health followed by indices of gingival status. **Material and method:** For the realization of the investigation, we examined 30 pregnant patients in the last trimester of pregnancy. Clinical trials were conducted to assess gingival health followed by indices of dental plaque (Silness-Loe), gingival inflammation (Loe-Silness) and gingival enlargement. The examination of serum and salivary levels of progesterone are performed using Progesterone RIA - DSL technology. **Results and Conclusion:** The analysis of correlative values that we found comparing serum and salivary levels of progesterone and indices of gingival status in pregnant patients, suggest a strong correlation on each of them ( $r=0.77-0.92$ ). The results of investigation of hormone concentrations in both media, without exception, show potent influence which they manifest on periodontal health, which in turn suggests the role of dentists in the prevention and treatment modalities in pregnancy, as a significant physiological period of life.

**PP 250 ADDRESSABILITY OF THE ELDERLY TO DENTAL CARE**

MIHAELA MONICA SCUTARIU, DRAGOS FRATILA, AMELIA SURDU,  
GEORGIANA MACOVEI  
Romania

**GERODONTOLOGY**

**Background of the study:** highlighting sanitary dental organizing issues mainly related to population's addressability to the dental office. One of the important dimensions of optimizing the

dental care, next to the increase of the accessibility, is represented by the increase of population's addressability. Addressability to dental care is the self-knowledge level of the needs in this field and the extent in which the population requests this care in early stages of buccal-dental diseases; the phenomenon depends, to the greatest extent, on the level of the sanitary culture, awareness of the population in requesting dental care in time and the importance of a complete and scheduled conservative treatment. **Motivation of research:** importance and necessity of knowing objective and subjective causes on which the early access of the population to curative dental care depends. **Material and method:** the study consisted in investigating 98 elderly subjects (50 male subjects - 51.00%; 48 female subjects - 49.00%) through sociological interview and direct observation method. **Results:** the dental hygiene status of the studied group was studied only by inspection (calculus and soft deposits, pigmentations), not by dental plaque staining test. The actual state of the buccal-dental health (respectively, disease) was appreciated through the proportion of various constant dental conditions of the subjects in the studied group; one can notice a high prevalence of the caries (64.3%) and of periodontal diseases (22.4%). The proportion of the patients with prostheses (25.5%) is smaller than the one of the patients without prostheses (38.8%). Out of 82 subjects (83.67%) suffering from dental conditions (subjective symptoms), only 9 (9.18%) state that they ask for dental care from the very first signs of disease, therefore in a small proportion. **Conclusions:** In general, the addressability is late and incomplete, which explains the insufficient degree of solving the need for curative dental care. It is necessary to intensify the sanitary education measures related to prevention and control of buccal-dental diseases, necessity of oral hygiene, way of presenting to dental care, and the importance of conservative treatment.

**PP 251** **MENTAL NERVE PARESTHESIA TREATMENT OF AN OLD LADY**  
SUZAN BAYER; AMEER SHANI DAHHAN; NIHAT DEMIRTAŞ; GAMZE ER  
*Turkey*

**LASERS**

Paresthesia usually manifests as burning, prickling, numbness, and itching. Altered sensation and pain of the involved areas may interfere with speaking, eating, drinking, shaving, tooth brushing and other events of social interaction which will have a disturbing affect on the patient. After extraction and curettage of the tooth with periapical infection, inferior alveolar nerve or mental nerve paresthesia may occur. The duration of paresthesia differs from days to weeks or to several months and in some cases paresthesia may be permanent due to actual irreversible nerve damage as a result of laceration and prolonged pressure on the nerve. Paresthesia treatment must be started immediately to have better outcomes. The present poster describes a case of 84 year old patient who referred to our clinic with mental nerve paresthesia arising after tooth extraction of right mandibular premolar which was managed successfully by conservative treatment by 3 months diode laser low level therapy (810 nm).

**PP 255 DIFFERENTIATION POTENTIAL OF DENTAL PULP MESENCHYMAL STEM CELLS**

NIKOLAY ISHKITIEV; VANYO MITEV; KEN YAEGAKI

*Bulgaria*

**INTERDISCIPLINARITY**

The objective of the present study is to assess the multiline age differentiation capacity of stem cells from human exfoliated deciduous teeth (SHED) and adult dental pulp stem cells (DPSC). Mesenchymal cells from deciduous and wisdom tooth pulp was isolated and expanded in vitro. We separated CD117-positive DPSC and SHED using magnetic activated cell sorter (MACS). Cells were characterized using known stem-cell markers. The cells were then divided and subjected to osteogenic, adipogenic, hepatogenic and pancreatic differentiation serum-free media (SFM). After 3-4 weeks of differentiation both cultures were positively stained for Ca<sup>2+</sup> aggregates with Alizarin red proving osteogenic differentiation. The Oil Red O staining revealed number of fatty droplets in the cytoplasm of the adipogenically differentiated cells. After the pancreatic differentiation the expression of endocrine markers insulin, glucagon, somatostatin and pancreatic polypeptide, GLUT2, and the exocrine marker pancreatic amylase were found positive by immunocytochemistry and flow-cytometry. Real time RT-PCR revealed the expression of pancreatic specific transcription factors. Both cells demonstrated significant number of cells positive for  $\alpha$ -fetoprotein, albumin, hepatic nuclear factor 4 $\alpha$ , insulin-like growth factor 1 and CPS-1 and increase of urea in the media after hepatic differentiation. Glycogen was found in the cytoplasm of differentiated cells. SHED and DPSC cultures grown in SFM acquired morphological and functional characteristics of osteoblasts, adipocytes, pancreatic cells, and hepatocytes. Multiline age differentiation of dental pulp stem cells in medium without animal products can bring in vitro cell differentiation methods closer to clinics.

**PP 257 A STUDENT PERSPECTIVE ON DENTAL TRAINING USING VIRTUAL PATIENTS**

ADRIAN DOLOCA; OANA TĂNCULESCU; SIMONA STOLERIU; GABRIELA IFTENI

*Romania*

**INTERDISCIPLINARITY**

This research focuses on the use of virtual patients (VP) in dental training, especially on the impact of this novel educational approach from the student perspective. This type of technology supported way of learning has gained in popularity over the past years and nowadays many universities introduced virtual patients as complementary activities in the medical education curricula. For the dental education, VPs can be especially useful by providing a safe training environment before the students can engage in dental procedures on real patients. Using VPs as a clinical simulation, dental students can develop clinical skills in many types of scenarios with no limitations regarding student's location, access to clinical facilities, training duration, etc. The intended purpose of this research was to evaluate the qualitative impact of VP clinical simulations on dentistry students. 105 students participated in this study. They were questioned as to the previous experience with VP software and to their expectations about the VP features (ease of use, multimedia features, interactivity and simulation degree, etc.). After the students used two

dentistry VPs they were presented a second questionnaire which acquired information about the existing VP characteristics. By corroborating data from both questionnaires, the research provided a set of guidelines related to VP authoring for optimized acceptance in students and for maximizing the educational efficiency.

**PP 258 MECHANICAL PERFORMANCES OF FIBRE REINFORCED COMPOSITES SYSTEMS**

OANA TANCULESCU; RALUCA MOCANU; GIANINA IOVAN; ANCA VITALARIU; GABRIELA IFTENI

*Romania*

**FIXED PROSTHODONTICS**

Fibre reinforced composites (FRC) are used in restorative dentistry, periodontology, prosthodontics, and orthodontics, being a reliable non-invasive restorative alternative. The biomechanical performances of FRC are related to both fibres and composites. The **aim** of the study was to assess and compare the maximum load, maximum deflection, flexural strength, flexural modulus, shear strength and the fracture pattern for different systems of fibre reinforced composite. A total of 80 standard bar-shaped specimens were subjected to a three-point bending test. The specimens were divided in 16 groups, according to the fibre type and width (Construct, Interlig, Splint-It) and composite resin used (Filtek Z250, Premise Packable, Premise Flowable, Brilliant Flowable). For all FRC, it was observed that the shear strength was approximately 50% lower than the flexural strength of the composite. This aspect implies that the destruction of the specimens was due to composite fracture, and that the interlaminar shear stress represents a secondary mechanism of failure. The fibre width influences the resistance of the specimens. Considering the different widths of polyethylene fibres, one can notice that the flexural strength and the shear strength were higher in specimens with 3 mm than in groups with 2 mm fibre, for all types of composite used. The type of the fibre has a great influence on the flexural strength of specimens. Based on the critical evaluation of the available FRC systems, recommendations for individualized clinical FRC selection can be made, which is of great importance for successful outcomes of this type of adhesive restorations.

**PP 261 TREATMENT OF SKELETAL CLASS II MALOCCLUSION IN GROWING PATIENTS WITH FORSUS™ FATIGUE RESISTANT DEVICE**

HATICE KUBRA DEMIRTAS; MERVE EROL; FARUK AYHAN BASCIFTCI

*Turkey*

**ORTHODONTICS**

**Aim:** This presentation shows the skeletal class II malocclusion treatment in a patient with severely crowded arches, deep-bite, decreased lower anterior facial height and retrognathic mandible. **Materials and methods:** A 13-year-old, male Class II patient with a retrognathic mandible admitted to our clinic because of severe crowding. Pretreatment cephalometric values confirmed a class II skeletal relationship with a ANB of 4°, FMA of 21°, and SN-GoGn of 23°. Firstly, Damon 3 brackets were bonded and the leveling was started with 0.014.

**PP 265** **P 53, P16 AND KI67 IMMUNOEXPRESSION IN ORAL SQUAMOUS CARCINOMAS**  
LUCIAN PAUL DRAGOMIR; DORA POPESCU; MIHAELA POPESCU;  
ANNE-MARIE RAUTEN; MIHAI RAUL POPESCU  
*Romania*

#### ORAL PATHOLOGY-ORAL MEDICINE

**Introduction:** Oral carcinogenesis is a multistage process, precancerous lesions, invasive and metastases being often present simultaneously. The purpose of this study was to analyze p53, p16, Ki67 immunoexpression in oral carcinomas and adjacent dysplastic epithelium, given their role in regulating cellular cycle and proliferation. **Material and methods:** The biologic material was represented by pieces of tumor resection, processed for embedding in paraffin and staining with Hematoxylin-eosin. Immunohistochemical analysis was performed on serial sections, as indicated on LSAB™ + Technical Kit / HRP for p53 and Ki67, and of CINtec® Histology Kit for determination of p16. Development of reactions was performed with diaminobenzidine tetrahydrochloride. **Results:** Immunoexpression analysis of p53, p16 and Ki67 did not reveal statistically significant differences between the expression of markers and clinical or histopathological parameters, except Ki67 whose increased expression was associated to the decrease of the degree of tumoral differentiation and with high degree dysplasia. The positivity index and the intensity of reaction were increased at the level of dysplastic epithelium for p16 and at the level of tumoral invasion front for the p53 and Ki67. The ANOVA test of comparing the index values of positivity for p53, p16 and Ki67 has no significant differences at a tumoral level and highly significant values at the level of invasion front and of dysplastic epithelium. **Conclusion:** The performed study demonstrates the specificity of the p16 immunostain at the dysplastic lesions of oral mucosa, while p53 and Ki67 markers seem to have prognostic value especially for the invasive carcinomas.

**PP 267** **THE IMMUNOEXPRESSION EGFR AND HER2/NEU IN ORAL SCUAMOUS CARCINOMA-OSC**  
MIHAI RAUL POPESCU; LUCIAN PAUL DRAGOMIR; MIHAELA POPESCU;  
DORA POPESCU; IULIANA MANUELA DRAGOMIR  
*Romania*

#### ORAL PATHOLOGY-ORAL MEDICINE

**Introduction:** This study took into consideration the EGFR and Her2/neu expression, the purpose being to identify their role in oral carcinogenesis, following, in the same time, the possible connections between them or between them and the analyzed clinic-morphological parameters and choosing those with statistical significance. **Materials and methods:** The study contained 44 surgical excisions diagnosed with OSC. The working systems for the immunohistochemical reactions have been represented by CSA II, Biotin-Free, Catalyzed Amplification System for EGFR and LSAB+ System-HRP for Her2/neu, their visualization being obtained with 3,3' - diaminobenzidine. The validation of the reaction was achieved by using negative external controls, with primary antibody omission. **Results:** The immunomarking for EGFR was cytoplasmic and membranous, with variable intensity and distribution, frequently heterogeneous. There has been no correlation between the immunostain OSC and the differentiation levels, but we observed that all well and moderately OSC cases have been positive with moderate or high intensity, while poorly differentiated OSC

corresponded to a moderate or low intensity immunostain. The analysis for Her2 expression indicated positive results in a small number of cases, respectively in 11 cases (25% of analyzed OSC). The marking was a membranous one, complete or incomplete, with different proportions of intensity. **Conclusions:** The presence of the EGFR and HER-2/neu expression in both lesional groups, dysplasias and carcinomas, indicate their intervention in the oral carcinogenesis, even from their early stages, at least for a part of the tumors.

**PP 269 GRAPHITE TATTOO ON GINGIVA: A CASE REPORT**

MURAT AKKAYA; NECMETTIN YETA; NAZ YETA

*Turkey*

**PERIODONTOLOGY**

Gingival pigmentation is a major concern for a large number of patients visiting the dentist. Pigmented entities may arise from intrinsic and extrinsic sources. Localized traumatic pigmentation can be due to injuries contaminated by foreign material. These tattoos are most often found in the area of the marginal gingiva or the buccal mucosa. Graphite pencil, may cause traumatic injury especially during early childhood. In this case the diagnosis and periodontal surgical treatment of a graphite tattoo on maxillary incisor mucosa will be presented. **Case Report:** A 24 year old female patient was referred to periodontology department because of a blue lesion on the upper gum. The lesion has occur in her childhood. Intraoral examination showed an asymptomatic, firm, blue-black macule in 5 mm diameter involving the attached gingiva between labial mucosa of maxillary left central and lateral incisors. Periapical radiograph of the anterior maxillary region did not show any pathological changes. Under local anesthesia the pigmentation area was removed by using excisional incision. After removing the soft tissue, residues of solid black granules were seen. Pigmented alveolar bone was removed and the defect was closed by laterally advanced flap technique. Histopathological examination revealed pencil graphite particles.

**PP 272 SALIVARY AND SERUM BIOMARKERS FOR THE STUDY OF SIDE EFFECTS OF ARIPIPRAZOLE AND MIRTAZAPINE**

PETRA SURLIN; MARIA BOGDAN; ISABELA SILOSI; ANDREI ADRIAN TICA;  
OANA SORINA TICA

*Romania*

**INTERDISCIPLINARITY**

**Background:** The aim of this study was to investigate two potential biomarkers for weight gain and lipid metabolism disorders as side effects of mirtazapine and of its association with aripiprazole. **Materials and methods:** Adult male Wistar rats were randomly assigned to four groups: control (saline 10ml/kg), aripiprazole (4.05 mg/kg), mirtazapine (10 mg/kg) and aripiprazole + mirtazapine (4.05 mg/kg + 10 mg/kg). The drugs were administered by gavage, daily at the same hour, for 6 weeks. Tumor necrosis factor alpha (TNF- $\alpha$ ) and liver fatty acid binding protein (L-FABP) were determined in serum, from intraventricular blood, and in saliva. Also from intraventricular blood, serum levels for total cholesterol (TC), low and high-density lipoprotein (LDL, HDL) and triglycerides (TG) were assessed. **Results:** Mirtazapine determined significantly differences of TNF- $\alpha$  and L-FABP serum levels; final body weight; TC and LDL levels,

leading to higher concentrations than its association with aripiprazole. Although not statistically significant, mirtazapine group experienced higher values for salivary levels of TNF- $\alpha$  and TG, and lower values for HDL, compared to combination group. Positive and statistically significant ( $P < 0.05$ ) correlations between serum and salivary levels of TNF- $\alpha$  and L-FABP were found. **Conclusions:** The results suggest that: aripiprazole might improve some of the disturbances caused by mirtazapine, TNF- $\alpha$  and L-FABP levels can be helpful as biomarkers for metabolic disturbances, and that their salivary determination can replace serum determination. **Acknowledgment.** This paper was published under the frame of European Social Found, Human Resources Development Operational Programme 2007-2013, project no. POSDRU/159/1.5/S/136893.

**PP 274 FREE GINGIVAL GRAFTS TO INCREASE KERATINIZED TISSUE BEFORE DENTAL IMPLANT PLACEMENT: A CASE REPORT**

ZEYNEP TAŞTAN EROĞLU; BÜLENT KURTIŞ

*Turkey*

**PERIODONTOLOGY**

The absence of adequate keratinized mucosa around implants is associated with higher plaque accumulation, gingival inflammation, bleeding on probing, and mucosal recession. Free Gingival Graft (FGG) can be used in increase width of keratinized gingiva in the edentulous area before implant placement. 32 year-old female systemically healthy patient referred to placement the implant to the department of periodontology. Implant placement was planned in the left and right mandibular molar regions. Following to the clinical and radiographic examination of the areas sufficient bone volume detected but insufficient keratinized tissue occur. It was decided to perform FGG surgery in order to increase width of keratinized tissue before implants placement. After preparation of recipient bed, the amount of donor tissue needed was accurately determined by using a foil template. The graft obtained with no 15 scalpel blade was inspected for any glandular or fatty tissue remnants. The graft was placed on the recipient bed and suture by means of interrupted sutures (3-0 silk sutures) at the coronal and apical borders and a vertical stretching suture was given for close adaption of the graft to edentulous area. Following the healing period roughly after 2 months sufficient keratinized tissue was obtained for implant placement and implant surgery was performed.

**PP 275 PREOPERATIVE ORTHOPEDIC TREATMENT OF UNILATERAL COMPLETE CLEFT LIP AND PALATE**

SEVTAP ALP; MEHMET AKIN

*Turkey*

**ORTHODONTICS**

**Aim:** Cleft lip and palate is the most common congenital deformity of the craniofacial region. Nasoalveolar molding is a treatment method which is used for moving segments towards eachother and forming nose shape. The aim of this case is to provide a proper infrastructure in hard and soft tissues before the lip surgery. **Methods:** A-week-old newborn baby with unilateral cleft lip and palate (UCLP) was brought to our clinic for feeding and esthetical problems. Nasoalveolar molding treatment was started immediately. The modification of the molding plate was achieved by

adding soft acrylic resin and removing hard acrylic in order to align the alveolar cleft segments. Five weeks after the beginning of the therapy, a nasal stent was built up to elongate the columella and elevate the nasal cartilage. The nasal stent was prepared with a 0,6 mm round stainless steel wire and hard and soft acrylic resin. **Results:** 5 months later, the alveolar segments came close to each other. In the fifth month, the surgical operation of the lip and nose was performed. Moreover, sufficient length of the columella and acceptable nasal projection were achieved before the surgical procedure. **Conclusion:** The nasoalveolar molding therapy is an effective method to reduce the severity of the deformity in infants with unilateral complete lip and palate cleft.

**PP 276 TASTE DISSATISFACTION CORRELATED FACTORS IN ELDERLY PATIENTS WITH COMPLETE DENTURES**

KATERINA ZLATANOVSKA; JULIJA ZARKOVA; ANA RADESKA; CENA DIMOVA;  
KIRO PAPAOKA  
FYROM

**REMOVABLE PROSTHODONTICS**

**Background:** The aim of this study was to investigate taste sensation in elderly patients with complete dentures and to assign the relationship among subjective dissatisfaction with taste ability and factors such as age, gender and oral status. **Methods and materials:** The study comprised of 110 elderly patients with complete dentures, 61 males and 49 females, ranging in age from 52 to 80 who attended two dental offices in Shtip, Macedonia. A self-administered structured questionnaire was given to the participants. The questionnaire included self-assessed items on general health, dry mouth, chewing and taste satisfaction. Respondents underwent investigation of dental status and gustatory testing using a taste mixture (sucrose and tartaric acid). **Results:** Chi-squared tests showed that the factors associated with dissatisfaction with taste ability were female gender, older age, educational level, burning mouth, oral dryness, accumulation of bacterial plaque on the tongue, wearing dentures covering the entire hard palate and dentures worn overnight. Smoking, presence of medical conditions and use of medications were not found to be significantly correlated with taste discrimination ( $p>0.05$ ). **Conclusions:** We found a significant association between subjective taste dissatisfaction and certain oral factors like bacterial plaque on the tongue, burning mouth, oral dryness, wearing dentures overnight and lower educational levels were significantly related to dissatisfaction with taste ability in this study. Taste discrimination levels were significantly impaired after maintaining tongue care and removal of the dentures overnight, hence, when patients complain about diminished taste, dentists must assess oral status as well as taste sensation.

**PP 280 WHAT ARE ALBANIANS REQUIREMENTS FROM AESTHETIC DENTISTRY?**

ROZAFI DRAGUSHA; LIVIO GALLOTTINI; RUZHDIJE QAFMOLLA  
*Albania*

**RESTORATIVE AND ADHESIVE DENTISTRY**

**Background:** During aesthetic treatments, to achieve a successfully predictable result, is essential to understand what the patient wants and expects. Different studies have revealed that the concept of a "beautiful smile" differs between people, between countries, because of cultural, social-



economic reasons. The aim of this study is to create an idea about Albanian patients' requirements, since Albania has its own cultural, social-economic features and our Aesthetic Dentistry is in its first steps. Enabling to create a panorama, to understand where will be oriented aesthetic treatments in the near future, and take a first step to a possible applying and adaptation of different self evaluation aesthetic scales, like OES, OHIP etc. **Methods and materials:** We used the "Smile Analysis" self-evaluating questionnaire, used during aesthetic diagnosis, in 180 people (15y-70y), non-patients, from different cities, adapted, with the criteria of OES, focusing in oral part: mouth, alignment, color and form of teeth, gingival and overall pleasure, adding questions about existing restorations, age, gender, profession and city. **Results:** We saw a discordance between pleasure (74%) and desire (83 % wanted whiter teeth and 52% straighter). 32 % accepted that were uninformed and concerned for the results. **Conclusion:** We noticed a relative satisfaction, conditioned by economic and information, deriving in lower expectation from dental treatment then their real desires. The most required change was having whiter teeth, somewhat the less detailed requirement; we connect it with the lack of information in aesthetic dentistry.

**PP 281 FLUORIDE RELEASE AND RECHARGE ABILITIES OF NEW DENTAL SEALANTS**

THRASYVOULOS SFEIKOS; DIMITRIOS DIONYSOPOULOS; KOSMAS TOLIDIS

*Greece*

**PREVENTIVE DENTISTRY**

**Purpose:** The purpose of this in vitro study was to investigate the fluoride release and recharge abilities of three recently introduced dental sealants. **Materials and methods:** Three sealants were investigated in this study; Teethmate F-1 (Kuraray), Fissurit FX (Voco), BeautiSealant (Shofu), and a conventional glass ionomer cement FX-II (Shofu) and was used as control. Eight disk-specimens of each material were prepared and immersed individually in 4 ml deionized water in plastic vials. Fluoride release was assessed over a 30-day period for all materials using fluoride ion-selective electrode. On day 30 specimens were soaked for 5 min in solution of 0.05% NaF and daily, fluoride release was determined for 5 days. The data were statistically analyzed by one-way ANOVA and Bonferroni post hoc test and the level of significance was preset at  $\alpha=0.05$ . **Results:** In terms of total fluoride released over the 30 days period: FX-II (408.56  $\mu\text{g}/\text{cm}^2$ ) > Teethmate F-1 (89.45  $\mu\text{g}/\text{cm}^2$ ) > Fissurit FX (68.62  $\mu\text{g}/\text{cm}^2$ ) > BeautiSealant (33.32  $\mu\text{g}/\text{cm}^2$ ), ( $p<0.05$ ). After the refluoridation of the specimens with 0.05% NaF the cumulative fluoride re-release during the 5-day period for each material was: FX-II (99.53  $\mu\text{g}/\text{cm}^2$ ) > Teethmate F-1 (9.76  $\mu\text{g}/\text{cm}^2$ ) > BeautiSealant (5.69  $\mu\text{g}/\text{cm}^2$ ) > Fissurit FX (4.76  $\mu\text{g}/\text{cm}^2$ ), ( $p<0.05$ ). **Conclusions:** The three tested sealants showed an ability to release and uptake fluoride, but in different extent.

**PP 282 ANTI-HELMINTHIC MEDICATION IN RECURRENT APTHOUS**

LILIANA FOIA; DANIEL CIOLOCA; MIOARA TRANDAFIRESCU;

CATALINA HOLBAN CIOLOCA; ANCA CHIRIAC

*Romania*

**ORAL PATHOLOGY-ORAL MEDICINE**

Recurrent apthous stomatitis is a multifactorial disease, with an insufficient acknowledged etiology, clinically characterized by ulcerations, pain, dysphagia and a great impact on quality of

life, especially in recurrent form. Topical therapies like antimicrobial mouthwashes and topical corticosteroids can cut down pain and favor the healing process. In severe and prolonged cases, systemic therapy is recommended based on: corticosteroids, dapsone, colchicine, thalidomide, pentoxifylline, low-dose interferon- $\alpha$  and, more recently levamisole. Levamisole has been used as anti-helminthic for the last decades but it is also known that it displays immunomodulatory effects as well. It is recommended in intermittent use because of the risk of agranulocytosis. Its action based on increased cellular immunity could explain its approval in many autoimmune and inflammatory diseases. A case of recurrent aphthous stomatitis in a 17 year-old girl, with long history of therapeutically approaches, is presented. The administration of levamisole 50mg twice weekly for 3 consecutive months was recommended, resulting in positive results. Levamisole reduced significantly the healing time and the number of ulcers, with no side effects. Levamisole could be therefore a choice in treating recurrent aphthous stomatitis.

**PP 284 IMMUNOHISTOCHEMICAL STUDY OF PAPILOMATOSIS GINGIVAL MUCOSA IN PATIENT WITH DENTURE INDUCED STOMATITIS**

VERONICA MERCUT; MONICA SCRIECIU; SANDA MIHAELA POPESCU;  
DIANA LUCIA DIACONU; MIHAELA NICULESCU

*Romania*

**REMOVABLE PROSTHODONTICS**

**Introduction:** Denture induced-stomatitis is a widespread condition, with plurifactorial aetiology, often without symptoms, and diagnosis is based on clinical signs. **Material and method:** **Case report:** 58 years old male patient was diagnosed with denture related stomatitis type III Newton. On the alveolar ridge was observed hyperplasia of the mucosa due to over-extended borders of complete denture. Sample of mucosa was obtained through excision. Serial sections of 3  $\mu\text{m}$  in thickness were obtained from formalin-fixed paraffin-embedded tissue. Sections were stained with Haematoxylin - Eosin(HE) and immunohistochemical processed using the LSAB 2 System HRP- Universal Labeled method (Streptavidin Biotin 2 System Horseradish Peroxidase, DAKO, Denmark). **Results:** The histological diagnosis was papilomatosis with discrete parakeratosis and rich chronic inflammatory infiltrate with diffuse widespread lymphocytes and ectasiated blood vessels with passive hyperaemia. The immunohistochemical analysis highlighted a weak positive CD45 RO reaction for lymphocytes T diffusely scattered in lamina propria and intense perivascular disposed. Lymphocytes T and their precursors with intense CD3 and CD20 positive reaction were observed in superficial chorion. It was observed an intense positive CD 20 and CD79 a reaction for lymphocytes B in superficial chorion and the same reaction was weak in deep lamina propria. **Conclusion:** Hyperplasia mucosa due to over-extended edges of complete denture was histological associated with papilomatosis and inflammatory infiltrate rich in CR20 and CD3 lymphocytes T and CD20 and CD79a lymphocytes B in superficial lamina propria.

**PP 287 TEN MONTHS IN VITRO EVALUATION OF MARGINAL ADAPTATION OF THREE LOW-SHRINKAGE RESIN COMPOSITES**

SEVDA YANTCHEVA; RADOSVETA VASILEVA

*Bulgaria*

**RESTORATIVE AND ADHESIVE DENTISTRY**

**Aim:** This in vitro study compared marginal integrity of three low-shrinkage resin composites used for II-class restorations before and after a 10 months aging period. **Materials and methods:** 60 standardized class II cavities with gingival margins below cemento-enamel junction were prepared on extracted human molars. The teeth were randomly divided into 3 groups (n=20) based on the composites used for restorations (F.Silorane, Kalore, SonicFill). After restorations of the cavities were done all specimens were thermocycled (1000 cycles of 5C°/55C°). One half of the specimens from each group were subjected to aging in saline for 10 months, while the other half were sputtered with gold and directly SEM analyzed for marginal adaptation. After 10 months, the aged half of the specimens were SEM analyzed the same manner. Data before and after aging were statistically analyzed. **Results:** There was statistical difference between marginal quality in enamel and dentin. Silorane showed better results for dentin margins (p=0031). Kalore and SonicFill demonstrated more marginal gaps for dentin margins. For all margins there was no statistical difference between Silorane and Kalore. Statistical difference existed between Silorane and SonicFill for dentin margins (p=0.001). After aging the tendencies were the same, but adaptation for all materials was worsened. Aging affected predominantly dentin margins, presence of marginal gaps increased (p=0.001). For enamel margins there was only marginal influence of aging (p=0.084).

**PP 288 IMPLANT FOLLOW UP. BASIC INSTRUCTIONS AND GUIDELINES BASED ON PERIODONTICS AND PROSTHODONTICS.**

ANTIGONE DELANTONI; ATHINA KONDYLIDOU; STERGOULA PAPAMANOLI; FOTEINI PAPANIKOLAOU; GEORGIOS KARATHANOS

*Greece*

**ORAL IMPLANTOLOGY**

**Background:** The purpose of this study is to evaluate the guidelines regarding dental implant placement follow-up. An investigation on periodontal follow up, occlusion recheck and radiographic follow up and their international guidelines will be presented. **Material and methods:** This literature review was carried out by searching Pub-Med, Google Scholar, Scopus and scientific books in the library of Aristotle University of Thessaloniki. **Results:** Regarding the periodontal clinical examination a systematic control as part of active treatment is necessary based on the various scientific guidelines established by different organizations. This is recommended one month after implant placement, three months later, and then every six months for the first two years. However, the frequency of reexamination remains subjective and is determined according to the specifics of each case. The basic pursuit of retesting is to avoid complications particularly periimplantitis. The standard control method is clinical periodontal examination. If it presents signs and symptoms, a radiographic examination is required otherwise radiographic inspection is performed twelve months after placement for evaluation of bone condition. Subsequent radiographic retesting is performed annually for two- three years to confirm that the bone levels remain constant. Special attention when designing the final prosthetic should be taken to avoid

periodontal tissues implications, and not apply excessive occlusal forces. **Conclusion:** There are several sources and protocols regarding periodontal health after implant placement. Few are those related to prosthetic rehabilitation. Therefore, it is necessary that organizations, associations and conferences reach a clear protocol regarding the postoperative management of implant patients.

**PP 289 MOLAR ROOT RESECTION AS AN ALTERNATIVE TREATMENT IN FIXED PROSTHODONTICS**

ANTIGONE DELANTONI; OLGA NAKA; FOTEINI PAPANIKOLAOU; STERGOULA PAPAMANOLI; STEFANIA VLACHOU

*Greece*

**FIXED PROSTHODONTICS**

**Background:** Root- resection of molars is a process by which a part of a tooth is preserved in function while the unhealthy root is removed. This procedure has been proposed as an alternative approach for compromised teeth with critical strategic value, for patients who refuse to accept dental implant treatment or for patients with financial restrictions. **Materials and methods:** A comprehensive literature review was performed via electronic databases and supplemental hand-search of relevant reference lists and citations. Through a predefined review process potentially appropriate article were identified and evaluated for eligibility. **Results:** For each of the selected papers, study characteristics and main outcomes were extracted in order the existing evidence regarding molar root resection to be detected. Root -resection therapy has been suggested for teeth with periodontal problems, endodontic problems or root fractures, limited only to a part of the tooth. Inadequate bone support or great bone loss at the area of the division, unsuitability for endodontic treatment and fused and close related roots have been mentioned as contraindications for this approach. Although the study design of the selected studies was different, the survival rate of root-resected molars recorded was higher than 90%. **Conclusion:** Root-resection therapy presented high degree of functional success and seemed to be an efficient treatment option for patients who want to preserve their teeth, time and money. However, the appropriate patient's selection and a carefully designed treatment plan are the prerequisites for a successful long-term treatment outcome.

**PP 290 SOCKET PRESERVATION WITH IMPLANT PLACEMENT IN THE DAILY PRACTICE - CASE REPORT**

KIRO PAPAKOCA; CENA DIMOVA; GORDANA PAPAKOCA; ANA RADESKA-PANOSKA; KATERINA ZLATANOVSKA

*FYROM*

**ORAL IMPLANTOLOGY**

**Introduction:** The purpose was to show that significant changes in bone volume and morphology following tooth extraction can make prosthetic - implant rehabilitation very difficult. In order to prevent ridge atrophy and optimize esthetic in the posterior mandibular area, the local process of socket preservation procedure and exposes, is important as an available treatment. **Case report:** Male patient, age 32 with a noncontributory medical history, presents to our clinic. The clinical evaluation showed indication for tooth 36 extraction due periodontitis. After tooth (36) was

carefully removed with forceps technique, the extraction site was grafted with an osseointegrative bone graft. Implant placement was made 6 months after extraction of the tooth. After 4 months implant placement prosthetic rehabilitation was made. **Results:** advantages of an augmented alveolar ridge with sufficient bone volume to adjust for uncompromised and esthetic implant placement, renders these procedures more than effective for majority of patients. **Conclusion:** Loss of teeth due to complicated caries, often result in hard and soft tissue collapse, therefore the preservation of bone volume is of major importance in order to insure the proper implant and esthetic rehabilitation. In order to insure the success of prosthetic - implant therapy, surgical reconstruction of the tissues and the procedure of ridge augmentation are necessary.

**PP 292 EXTRUSION OF ROOT CANAL SEALER IN PERIAPICAL TISSUES. REPORT OF CASES WITH DIFFERENT TREATMENT MANAGEMENT.**

ATHINA DALOPOULOU; NIKOLAOS EKONOMIDES

*Greece*

**ENDODONTOLOGY**

**Introduction:** Extrusion of root canal sealers may cause damage to the surrounding anatomic structures. Clinical symptoms like pain, swelling and paresthesia or anesthesia may be present. **Purpose:** The purpose of this presentation is to describe two cases of root canal sealer penetration into periapical tissues. Different treatment management was followed in each case. **Methods and materials:** Case 1. A 55 year-old man underwent root canal retreatment of the right mandibular first molar tooth due to periapical lesion. Postoperative periapical radiographs revealed the presence of root canal sealer (AH 26) beyond the apex in the distal root in proximity with the mandibular canal. The patient reported pain for the next 7 days. Radiographic examination after 1 year showed complete healing of the periapical area and a small absorption of the root canal sealer. Case2. A 42 year-old woman was referred complained of swelling and pain in the area of the right maxillary first incisor. Radiographic examination showed extrusion of root canal sealer in the periapical area associated with periapical lesion. Surgical intervention was decided upon, which included removal of the sealer, apicoectomy of the tooth and retrograde filling with MTA. After 1 year, complete healing of the area was observed. **Conclusion:** In cases of root canal sealer extrusion, surgical treatment should be decided only if it is associated with clinical symptoms or with radiographic evidence of increasing periapical lesion.

**PP 293 ERUPTION DISTURBANCES: REVIEW AND REPORT OF SIMILAR CASES**

DIMITRIOS PAPALEXIOU; ANASTASIA VIOLESTI; FOIVOS-ANTONIOS

DALAMPIRAS; GEORGIA BARKA; ANTIGONE DELANTONI

*Greece*

**ORAL SURGERY AND ORAL MAXILLOFACIAL SURGERY**

**Background:** Normal eruption of teeth and their adjustment in dental arch is a process that is based on the regulation of genes expressed in the dental follicle at chronologically critical times. Deviation of this normal process can be commonly encountered in clinical practice and can be attributed to various environmental and genetic factors and may depend on systemic or on local factors. **Results:** The aim of this study is to analyze the major factors causing tooth retention or

delayed eruption and to present some clinical cases encountered in our Faculty, referring to the major causes of eruption disturbances, combined with review of the literature. Systemic conditions such as Cleidocranial Dysostosis and Pseudohypoparathyroidism will be demonstrated through cases, and local isolated cases of impaction or delayed eruption will be analyzed. **Material and methods:** Papers of high validation from 1990 to 2014 were included in the present study based on webserches made with pubmed and Scopus. The classification and the major causes of eruption disturbances will be presented. **Conclusion:** Eruption disturbances must be identified at the earliest possible timeframe. To have a better treatment planning and management of the patient, a thorough analysis of the possible cause should be made. The dentist can then better plan treatment when one can be aware of what to expect in such cases whether of systemic or of local origin.

**PP 294** **EFFICACY OF ANTIBIOTIC THERAPY IN IMPACTED THIRD MOLAR SURGERY**  
KIRO PAPAKOCA; KATERINA ZLATANOVSKA; ANA RADESKA-PANOVSKA;  
BILJANA EVROSIMOVSKA; JULIJA ZARKOVA  
FYROM

#### ORAL SURGERY AND ORAL MAXILLOFACIAL SURGERY

The use of routine antibiotic therapy in patients undergoing surgical third molar extraction is controversial. The efficacy of antibiotic therapy in preventing postoperative complications following surgical third molar extractions was evaluated in 80 patients. In the test group (45 patients), the protocol utilized a regimen of 2 g of amoxicillin orally daily for 5 d postoperatively, starting at the completion of surgery. In the control group (35 patients), no antibiotic therapy was given. No significant difference was found between the test group and the control group in the incidence of postoperative sequelae, i.e. fever, pain, swelling and alveolar osteitis. A statistically significant association between smoking, habitual drinking and increased postoperative pain and fever was found. Patient age  $\geq$  18 yr was positively correlated with an increased incidence of alveolar osteitis. Swelling was found to be gender-related, in that female patients experienced more swelling than male patients. No correlation was found between the time required for surgery or difficulty of extraction and post-operative pain. In conclusion, no difference was found between patients receiving postoperative amoxicillin and the control group in the incidence of postoperative sequelae.

**PP 295** **ANATOMICAL EVALUATION OF ROOT APEX MORPHOLOGY IN FRONTAL MAXILLARY TEETH**  
KATERINA ZLATANOVSKA; KIRO PAPAKOCA; IVONA KOVACEVSKA; LIDIJA POPOVSKA; GEORGIEV ZLATKO  
FYROM

#### ORAL SURGERY AND ORAL MAXILLOFACIAL SURGERY

The success of root canal therapy is dependent on the clinician's knowledge of root canal morphology with goal to precisely locate all canals, properly clean, shape and obturate the canal space. The aim in our study was to determine the morphological shape and position of the root apex and the major foramen in maxillary teeth. A total of 100 maxillary human frontal maxillary

teeth with completely formed apices were evaluated. Each root specimen was measured at each root apex by using a calibrated microscope at magnification of 20X. The anatomic parameters evaluated were the shapes of peripheral contours of major apical foramen (rounded, oval, asymmetric, semi-lunar) and the root apex (rounded, flat, beveled, elliptical). The location was recorded and classified as center, buccal, lingual, mesial, or distal surface for both root apex and the major apical foramen. The most common morphology of the root apex in incisors and canines was the round shape. The most common shape of the major foramen in all groups was round, followed by oval. The root apex was most commonly located in the center in all groups followed by distal and buccal locations.

**PP 297** **ORTHOGRADE AND SURGICAL RETREATMENT IN A MOLAR OBTURATED WITH SILVER CONES. A CASE REPORT**

KONSTANTINOS SIDIROPOULOS; NIKOLAOS ECONOMIDES

*Greece*

**ENDODONTOLOGY**

**Introduction:** Endodontic failure may arise mainly because of persistent intra-radicular infection from remaining bacteria in the root canal. As a result, retreatment is the most appropriate way to deal with failed cases. The aim of the following study was to describe a case where conservative and surgical retreatment was applied in a molar. **Methods:** A forty-year old female patient expressed complaints of extra-oral fistula and intra-oral swelling, associated with) the first lower right molar (46). Radiographic examination showed a periapical lesion associated with the lower molar which had previously been obturated in the mesial root with silver-cones. A part of the silver cone had been broken and extruded from the periapical area. An orthograde retreatment was performed, which included the removal of the silver cones and obturation of the root canal with gutta-percha and sealer (AH 26). As a last step, the broken silver cone was removed surgically. **Results:** After one month the tooth was asymptomatic and the intra-oral swelling had disappeared. The extra-oral fistula was inactive. At the one year recall, complete healing of the periapical area could be observed. **Conclusion:** Orthograde retreatment combined with surgical intervention can be a treatment option in cases where filling materials or endodontic instruments are extracted in periapical area.

**PP 299** **PERIODONTAL AND ODONTAL LESIONS IN PATIENTS WITH TYPE 1 DIABETES**

ANA-MARIA RICA; DORA POPESCU; LUCIAN DRAGOMIR;  
ANNE-MARIE RAUTEN; PETRA SURLIN

*Romania*

**PERIODONTOLOGY**

Periodontal and odontal lesions in patients with type 1 diabetes **Background:** The aim of the study is to establish correlations between parameters and highlight features disturbance of carbohydrate metabolism and the main forms of periodontal disease and to establish correlations between the dental statuses of patients with type 1 diabetes. **Materials and methods:** The study was conducted on two groups of patients, both with odontal and periodontal lesions, the first group

with type 1 diabetes and the second group of patients without type 1 diabetes. For assessing the periodontal status we have used the Silness and Loe plaque index and have also noted the number of teeth presenting pockets exceeding 6mm. Based on the odontal examination we have determined that the frequency of incipient caries was higher in the temporary dentition, unlike the advanced destructive forms with evidence of root residues that were more frequent in the permanent dentition. **Results:** The plaque index in the test group of adults with diabetes and periodontal disease is higher than the indices in the control group calculated for adults. The plaque index in the control group of adults is lower than the index found in the children control group. Patients with type 1 diabetes have had an increased number of lesions such as incipient caries, complicated caries and/or destructive caries. **Conclusions:** We have found that patients with type 1 diabetes have had an increased number of odontal and periodontal lesions unlike the patients in the control group.

### PP 300 ORTHODONTIC TREATMENT OF POLYDIASTEMA: A CASE REPORT

MELIHA OSMAN; AHMET KUBILAY EROGLU; MEHMET AKIN

*Turkey*

#### ORTHODONTICS

**Aim:** Polydiastema states numerous diastemas that exist in diffuse form in the dental arches. Especially the condition that there are diastemas between all the teeth in the anterior region is called polydiastema (1). Heredity, bad habits like finger sucking and incorrect breathing and systemic conditions like some hormonal disorders and syndromes can be considered among the reasons of polydiastema (2). **Materials and methods:** A 15 years-old male patient referred to the department of Orthodontics. Cephalometric analysis showed skeletal class I malocclusion with SNA=80,7° SNB=79,2° ANB=1,5° and SN-GoGn=33,5° FMA=21,2°. Clinical examination showed Angle's class III subdivision molar relationship. The overjet was 6mm and the overbite was 2mm and upper incisors was procline. The case was banded with 0.022 slot molar bands and bonded with 0.022 slot braces. Alignment was done with NiTi wires in both arches. Dental arches were segmented three sections by collecting the incisor teeth in the anterior region and collecting the canines, premolar and molar teeth in the posterior region. Finally free spaces were closed by retracting the incisors through the T loops that banded by using 0.016x0.022 SS (Stainless steel) wires. **Results:** The goal of orthodontic treatment was to close the diastemas, fix proclination of upper incisors and correct the molar relationship to class I on both sides. All of these goals were achieved. **Conclusions:** In polydiastema cases, the orthodontic treatment is an effective method to obtain a harmonic occlusion and achieve an aesthetic aspect.

### PP 303 ORTHODONTIC MANAGEMENT OF MAXILLARY CANINE FIRST PREMOLAR TRANSPOSITION: CASE REPORT

ENES TAN; MURAT ÇAĞLAR OĞLU

*Turkey*

#### ORTHODONTICS

Dental transposition and impaction are disorders related to ectopic eruption or failure in tooth eruption, which can affect child physical, mental and social development and may be difficult to be clinically solved. Among dentitional anomalies, tooth transposition is considered the most



difficult to manage clinically. We describe a case of transposition between the upper right canine and first premolar in a 12-year-old girl who had a Class I malocclusion. Arch length discrepancies in upper right and left were -0,5 mm and 2,5 mm respectively, in lower teeth there were no crowding and spaces. The canine was transposed between the premolars close to the first premolar root so it effected the root resorption of this teeth. So our treatment plan was mesialisation of first premolar and opening the canine space to erupt. Treatment lasted 22 months and after orthodontic treatment essix plates was applied for retention.

**PP 306 PERIODONTAL HEALTH IN PATIENTS WITH ELEVATED BODY MASS**

SVJETLANA JANKOVIC; BOJANA DAVIDOVIC; BRANKICA DAVIDOVIC;  
MIRJANA IVANOVIC; MIHAEL STANOJEVIC

*Bosnia and Herzegovina*

**PAEDIATRIC DENTISTRY**

**Introduction:** Obesity is a significant problem that negatively affects the general health today. There are scarce data about the effect of excessive nutrition on oral health. The **aim** of this study was to assess gingival and periodontal health in patients with elevated body mass. **Material and methods:** The study included 190 school children. Nutritional status was estimated by Body Mass Index- BMI. Löe i Silness index was used for gingival status assessment (GI), and Community Periodontal Index of Treatment Needs was used for periodontal status assessment (CPITN). **Results:** There were more boys (64.2%) than girls (35.8%), in the study. The values of GI are higher in the experimental group ( $0.64 \pm 0.37$ ) compared to the control group ( $0.55 \pm 0.35$ ), but no statistical significance was found between the groups. CPITN index values are higher in the experimental group ( $1.33 \pm 0.49$ ) compared to the control group ( $0.77 \pm 0.61$ ), what was confirmed by a statistically significant difference as  $p < 0.05$ . **Conclusion:** Children with elevated body mass show higher level of periodontal disease, indicating that obesity reflects on the oral health. It is very important to form positive habits, even in early childhood, as well as to take all precautionary measures in order to prevent the occurrence of obesity and all negative effects on the health that may occur.

**PP 307 STUDY REGARDING THE SALIVARY MICROCRYSTALLIZATION INDEX**

**VARIATION ON THE PATIENTS HAVING DENTAL EROSION LESIONS**

PANCU GALINA; SORIN ANDRIAN; IRINA NICA; ANTONIA MOLDOVANU

*Romania*

**ORAL PATHOLOGY-ORAL MEDICINE**

The aim of this study was to evaluate the variation of salivary microcrystallization index (IMK) to the patients having gastroesophageal reflux disease after using a remineralization product. **Material and method:** Twelve patients having gastroesophageal reflux disease were included in this study. Unstimulated saliva was collected in the same day and at the same hour for each patient. A total amount of 0.5 ml of unstimulated saliva was placed on a glass plate, dried for 30 minutes in a thermostat at  $+37^{\circ}\text{C}$ , and then studied using a Nikon Eclipse E 600. The images were saved and stored on a computer. The IMK index was determined using the formula:  $\text{IMK} = \frac{\text{no of the eye network points projected on crystals}}{\text{no of the eye network points projected on the entire saliva}}$

drop. All the patients were subjected to dental hard tissues remineralization using Recaldent MI Paste (GC Corporation) for 3 weeks. After 3 weeks the IMK index was determined for each patient. **Results:** The appearance of the crystals formed by saliva precipitation on the plates corresponds to one of these aspects: dendrite-shaped crystals, camomile flower, multiple points, micronetwork, cube or egg-shaped forms. The mean values of IMK index varied from 0.4 before treatment to 0.9 after remineralization using Recaldent MI Paste. **Conclusions:** Recaldent MI Paste increased the remineralization capacity of saliva when used to the patients having gastroesophageal reflux disease.

**PP 308 EFFECT OF BOTULINUM TOXIN ON MASSETER HYPERTROPHY VALIDATED WITH BITESTRIP: A CASE REPORT**

FOUAD SALEH NAJAFI; YENER OKUTAN

*Turkey*

**ORAL SURGERY AND ORAL MAXILLOFACIAL SURGERY**

**Objective:** Masseter hypertrophy is a benign condition mostly caused by bruxism. Bruxism is considered to be a disorder during sleep and is characterized by tooth clenching and/or grinding. Bitestrip is similar to a portable surface EMG device and it helps the professional diagnosis of Bruxism as well as the clinical evaluation of treatments. **Case Report:** A 28-year-old-male patient with no systemic disease referred to our clinic with the chief complaint of intense pain and swelling on his masseteric region. After further oral examination abrasion detected on teeth and bruxism diagnosed. For validation of diagnoses bitestrip was used. For treatment, 35 units of Botulinum Toxin A (BOTOX®) injected to masseter muscle. Second bitestrip used to evaluate the effects of the treatment. Bitestrip results showed decrease of the value on bruxism. **Conclusion:** The Bitestrip can be considered as a moderate screening method for the diagnosis of bruxism. Botulinum toxin A injection on masseter is an effective and relatively non-invasive choice of treatment for masseter hypertrophy and pain syndrome.

**PP 309 NO ASSOCIATION BETWEEN EMPLOYMENT, UNEMPLOYMENT AND RETIREMENT WITH PERIODONTAL HEALTH STATUS IN AN OLDER POPULATION**

EFTHYMIA CHALVATZOGLOU; GEORGIOS CHATZOPOULOS; LAZAROS TSALIKIS

*Greece*

**PREVENTIVE DENTISTRY**

**Background:** Periodontal diseases are considered as multifactorial pathogenic entities that are initiated and sustained by bacteria. Local and systemic determinant factors as well as socio-economic status influence onset and progression of periodontal disease. The objective of the study was to assess whether employment, unemployment and retirement were associated with periodontal treatment needs in an older population in Greece. **Methods and materials:** A total of 262 individuals aged 55 years and more who visited Aristotle University of Thessaloniki seeking dental therapy participated in the study. Demographic data such as gender, age, smoking and working status were recorded. Clinical measurements of the periodontal health status were obtained by a single calibrated examiner using a community periodontal treatment needs (CPITN)

probe. **Results:** 127 (48.5%) were retired, 75 (28.6%) were unemployed, while 44 (16.8%) of the sample were employed. The majority of the population (179 individuals, 68.4%) displayed CPITN scores 3-4. The employed, unemployed and retired individuals exhibited similar high periodontal treatment needs ( $p>0.05$ ), as over 64% of each group displayed moderate to severe periodontal treatment needs. Gender-related differences were recorded according to occupation ( $p<0.001$ ) and clinical measurements ( $p=0.003$ ): unlike males, females were mainly retired and unemployed with low treatment needs. High CPITN scores were associated with lower age as a strong negative correlation was observed. **Conclusion:** The study revealed that employment, unemployment and retirement were not associated with the periodontal treatment needs. Factors such as smoking habits, age and gender played a significant role.

**PP 310 PARTICULARITIES OF THE CHEMICAL COMPOSITION OF DENTAL ENAMEL IN CHILDREN WITH SEVERE NEUROLOGICAL DISEASES**

OLGA BĂLTEANU; AURELIA SPINEI; SVETLANA PLAMADEALĂ

*Republic of Moldavia*

**PAEDIATRIC DENTISTRY**

In this work we made an analysis of the particularities of dental enamel chemical composition in children suffering from neurological diseases. The purpose is to study the particularities of the dental enamel chemical composition in children suffering from severe pathology of the central nervous system. **Material and methods:** Using the Fourier transform spectroscopy method (FTIR) we have studied the structure and the chemical composition of various areas of the dental enamel, namely 36 pieces of prepared enamel from 12 extracted teeth from children aged between 13 and 15, following orthodontic indications. The study was approved by the Ethics Committee for Research of SUMF. **Results:** In the result of the study we established that in the enamel of the children suffering from severe neurological diseases the weight of the organic component of enamel is increased, the contents of hydroxyapatite contents is reduced, it contains carbon substituted hydroxyapatite with low intensity of peak phosphorus and significant increase of organic components. The detected particularities of the chemical composition of dental enamel indicate the considerable reduction of the enamel resistance to acid attack, thus leading to a high risk of new carious lesions. **Conclusions:** The FTIR spectroscopy method of dental enamel offers new opportunities in the study of pathogenic mechanisms involved in the initiation and evolution of carious lesions, to make a prediction of these disorders, to elaborate measures for the prevention of tooth decay and evaluate their efficiency.

**PP 311 CHEMICOPHYSICAL PROPERTIES OF NEW NANOSTRUCTURED MATERIAL FOR APPLICATION IN DENTISTRY**

BOJANA CETENOVIC; DEJAN MARKOVIC; GORDANA FILIPOVIC; VUKOMAN JOKANOVIC

*Serbia*

**DENTAL BIOMATERIALS AND DEVICES**

**Aim:** The aim of this paper was to analyze the chemicophysical properties of a new dental material based on nanostructured highly active calcium silicates (ALBO-MPCA). **Materials and**

**methods:** Phase analysis was performed by X-ray diffraction, and the morphology of the samples was studied by SEM. The pH measurements were performed using pH meter with combined electrode, while the total amount of released ions was determined using ICP-OES. The time required for the start of the material's setting and the time needed for its completion were established by Vicat needle, according to ASTM C191 standard. The compressive strength measurements were taken using Instron machine with previous preparation of the samples. **Results:** X-ray diffraction showed that active silicate phases were transformed into tobermorite phase, while carbonates remained unchanged. SEM analysis revealed that calcium silicate phase was mostly consists of agglomerates built up from nanoparticles. These particles are preferentially spherical and ellipsoidal, more or less elongated along one direction. The setting of ALBO-MPCA started 20 min after its mixing with water, and it ended after 70 min. The compressive strengths were: 29 MPa (1 day), 42.7 MPa (7 days), and 53 MPa (28 days). pH was high alkaline and increase over time:  $11.54 \pm 0.01$  (1 hour),  $11.70 \pm 0.01$  (3 hours) and  $12.13 \pm 0.15$  (24 hours). The cumulative calcium and silicium ion release was the highest and increased over time. **Conclusions:** The obtained results are very promising for potential application in dental practice because beside very easy preparation and manipulation with ALBO-MPCA, satisfied chemico-physical properties were achieved.

**PP 312 EVALUATION OF THERMAL EFFECTS OF DIODE LASER ON ROOT CANAL DENTIN**

BAGDAGUL HELVACIOGLU KIVANC; HACER DENIZ ARISU;  
BARAN CAN SAGLAM; GULCIN AKCA; GULIZ GORGUL  
*Turkey*

**ENDODONTOLOGY**

**Introduction:** Thermal injury to periodontal tissues is a major concern when applying laser irradiation to intracanal areas. Before clinical application for endodontic treatment, the thermal effect of the lasers on periodontal tissues should be evaluated. **Purpose:** The objective of this study was to evaluate the temperature variation in the apical third of root external wall by the use of diode laser during the biomechanical procedures. **Method and materials:** Thirty-six teeth were sectioned and chemomechanically prepared. The roots were irrigated with 2.5% sodium hypochlorite and 17% EDTA. The specimens were randomly divided into 3 groups (n=12): G1, irradiated by diode laser at 1.2 W; G2, irradiated by diode laser at 2 W; G3, irradiated by diode laser at 3 W. The temperature increases were measured on the external apical third of the root surface using a thermocouple. The mean values of temperature changes for each group were compared using one way analysis of variance (ANOVA) and Tukey test ( $p=0.05$ ). **Results:** There was a significant difference between groups ( $p<0.05$ ). Temperature rises were significantly higher in Group 3, in Group 2 and in Group 1 respectively ( $p<0.05$ ). **Conclusion:** Irradiation of diode laser at 2W and 3 W cause a higher temperature rise at the apical third of the root surface which can cause periodontal damage.

**PP 313 IMPLANTATION AND IMMEDIATE IMPLANT LOADING - A CASE REPORT**

DUSICA BOZOVIC BEHARA; MLADEN BEHARA; SLADJANA SICOVIC;  
LENA JOVANOVIC; NATASHA RANDJELOVIC

*Serbia*

**ORAL IMPLANTOLOGY**

Osseointegration is the direct abutment of bone to implant surface such that osteoblasts can be seen on electron micrographs to be growing on the implant surface. In addition, a tight fibrous/epithelial attachment above the crestal bone between gingiva and implant is essential. Finally, the implant must be designed to resist displacement and evenly dissipate occlusal loads. With good planning the success rate rose to 98%. **Case report 1**- a 66-year old male patient visited me and expressed his wish to have implants placed ( 22 fracture ) instead of them, and two more instead of teeth 44 and 46,47.The places, angle in the sagittal and transverse planes as well as the length were determined on the basis 3D diagnostics. **Case report 2** - a 43- year man came and expressed his wish to have implants placed 24, 26, 28, 45, 47. The conclusion is that the proper planning of treatment is the key element of successful implantation and long-term implant survival. For proper planning it is necessary to know the basic principles of prosthetic rehabilitation of orthognatic system. All the above must be systematically approached and not a single phase can be avoided. It is a must to have a well-trained and well-equipped dental laboratory technician on the team. The application of computerized 3D radiography does not increase the precision much more than 2D radiography with manual measuring in fabricating a 3D model. The most important issue is the comfort which the patients gets with direct implant loading.

**PP 314 EXPERIMENTAL TIP FOR SONIC HANDPIECE FOR ANATOMICAL ROOT CANAL PREPARATION**

STILIYAN HRISTOV; HRISTO KISOV; STOYAN YANKOV; DANIEL DIMITROV;  
DOBROMIRA SHOPOVA

*Bulgaria*

**RESTORATIVE AND ADHESIVE DENTISTRY**

**Background:** Restoration of endodontically treated teeth with post and core is very common in the dental practice. Root canal drills with round shape are used for preparing the root canals. The roots however have oval or highly flattened sections. The problem of root canal preparation with a form different from round is the lack of proper instruments. Purpose: Sonic handpieces are used with tips, which do not perform rotational motions like the classical handpieces. Vibrational motions enable the usage of an anatomically shaped tip. **Materials and methods:** The Sonic handpieces are developed for the purposes of dental practices transfer vibrations to the tip with a frequency of 6000 Hz. Vibrational, not rotational motion enables the development of anatomically shaped experimental tip for post preparation. That also enables fabrication of standard fiber reinforced composite posts corresponding to the tip. **Results:** Developed anatomically shaped experimental tip for sonic handpiece for root canal preparation.

**Background:** Studies in both developed and developing countries have demonstrated the effect of socioeconomic conditions on oral health status. Oral health is known to be influenced by a multitude of sociobehavioural and environmental factors led by unhealthy lifestyles and limited access to services. The aim of this cross-sectional study was to investigate the effect of social status and fixed partial denture prevalence between dental students. **Methods and materials:** A comprehensive social, cultural and dental assessment questionnaire was designed and distributed among 173 second and third grade students of Selcuk University Faculty of Dentistry. Oral health statuses, oral hygiene knowledge, prosthetic restoration prevalence, social and economic conditions of students were evaluated. Restoration prevalence in students from towns and districts compared with the students from cities. The questionnaire contained different types of prosthetic treatments such as fixed partial denture, implant supported restorations, laminate veneers, inlay-onlay restorations and night guards. Restored teeth with filling materials and the missing teeth were also evaluated. Finally, data of the study were statistically analyzed. **Results:** According to the results, only 11 students had a prosthetic restoration. Restored teeth with a filling material were detected in 117 students. One of the interesting result of this study was 67 students (38.7 %) were detected with a dental anxiety. Additionally, most of the students have a mean average of economical income. **Conclusion:** The results of this study revealed that socioeconomic condition is an important factor on oral health status.

**Aim:** The present study determined the effects of different factors on DMFT components of Turkish schoolchildren. **Material and methods:** This study was carried out on 188 adolescents (14-16 years old) of both gender who attending Dentistry Faculty of Konya, Turkey. Mean DMFT (decay, missing and filling tooth), DT, FT, MT scores were identified for every individual. The World Health Organization (WHO) criteria and bitewing radiographs were utilized to diagnose the carious status of the subjects. Data on age, gender, oral health habits, parental educational status and mean family income were collected by a questionnaire completed by the subjects. Chi-square, Kruskal-Wallis and Mann-Whitney U tests were used for statistical analyze. **Results:** The female/male number was found 106/82. The mean DMFT, DT, MT, FT was found 2.83; 1.35; 0.05; 1.43, respectively. There were association was found with mean DT score and brushing before bedtime ( $p=0,044$ ), mean FT score and age ( $p=0,010$ ). There were no significant association with DMFT components and gender, brushing frequency, mother and father educational level and mean

family income ( $p > 0,05$ ). **Conclusions:** It is thought to brushing before bedtime is extremely important for children's oral care and in terms of reducing the overall caries risk.

**PP 318 THE DENTAL HEALTH IN THE EARLY CHILDHOOD IN PARTICIPANTS FROM SKOPJE**

S. NASHKOVA; J. ALIMANI- JAKUPI; F. VENINOV; S. ILJOVSKA; T. KUTLOVCI  
FYROM

**PAEDIATRIC DENTISTRY**

The goal of the research is to make an assessment of the prevalence and the severity of the caries in the early childhood (CEC) in preschool children. The research is an analytical study of the example cut of 30% of 979 preschool children from municipality Center Skopje, in children from different socio-economical status families in whom the situation was noted on the teeth and the caries in the early childhood. The results have shown that without caries were 173 (20.47%) from the participants, with caries 465 (55.03%) and with CEC 207 (24.50%). The total DMFS of the participants were 2.6, from which with filled teeth were 0.46, with caries 1.47 and with extracted teeth were 0.681. With caries in the early childhood were 207 children from which 102 boys and 105 girls, which meant there weren't any significant differences according the gender. Depending on the clinical forms of caries in the early childhood and the age of the children we established that with the initial form of CEC at the age of 2 were 75.6% of the children, with mild caries were 24.4%; with initial form of CEC at the age of 3 were 48.6%, with mild form were 35.1%, with medium were 13.7%, with severe form of caries were 2.2% and with severe form with complications were 10.04% of the children. With initial form of CEC at the age of 4 were 10.9%, with mild form 42.3%, medium form 18.2%, with severe form 7.4% and with severe form with complications were 21.2%; at the age of 5 with initial form of CEC were 18.9% and with mild were 24.3%. In the complex interaction of the predisposing factors of the social environment as the socio-economical status, the health education, the living environment significantly affect the prevalence of the caries and the severity of the caries in the early childhood among young children and preschool children in our environment.

**PP 319 REMOVABLE PROSTHESES IN 2015**

LUCIANA GOGUTA; ANCA JIVANESCU; EMANUEL BRATU;  
CORINA MARCAUTEANU; ALEXANDRA MAROIU  
Romania

**GERODONTOLOGY**

Removable dentures are still frequently used in the treatment of extended partially edentulous cases. There are few cases which are treated using implant removable dentures in elderly population. **Purpose:** Our purpose was to determine the prevalence of different type of direct retainers in elderly population. **Materials and method:** The different type of direct retainers (clasps, extra coronal slide attachments, ball attachments and telescopic crowns) were counted and the satisfaction with these types of direct retainers was also evaluated. The number of patients wearing at least one removable denture was 367. The overall satisfaction of the patients with these

removable partial dentures retainers was measured on a scale from 1 to 5. **Results:** The number of the direct retainers was: cast clasps 132, 402 extra coronal slide attachments and ball attachments (mostly "Bredent", Cologne, Germany) and 223 telescopic crowns (Friction Grip System "Bredent", Cologne, Germany). The best result was obtained in the cases where the extra coronal slide attachments and ball attachments were used (5) followed by the telescopic removable dentures (4) and the clasp retained removable dentures (2). The main complaint was the lack of aesthetics when clasp as used and also the medium retention of the removable denture using cast clasps. **Conclusion:** This study shows that direct retainers are still used in elderly people where fixed implant supported dentures are not indicated. In order to evaluate the performances of the removable dentures retainers the study must be extended on more patients and on a longer time period.

**PP 320 WHICH FACTORS AFFECTING ADOLESCENTS TOOTH BRUSHING PATTERN?**

SAİD KARABEKİROĞLU; MERVE YILDIZ; ELİF ÖNCÜ; NİMET ÜNLÜ

*Turkey*

**PREVENTIVE DENTISTRY**

**Aim:** The present study determined the brushing habits and related factors of Turkish schoolchildren. **Material and methods:** This study was carried out on 217 adolescents (14-16 years old) of both gender who attending Dentistry Faculty of Konya, Turkey. Data on age, gender, oral health habits, age of first dental visit, parental educational status and mean family income were collected by a questionnaire completed by the subjects. Subjects were divided into four groups according to tooth brushing pattern (sometimes, twice a week, daily, twice a day) after recording all data. Chi-square and Kruskal-Wallis tests were used for statistical analyze. **Results:** The female/male number was found 122/95. There were association was found tooth brushing pattern and gender ( $p=0,002$ ), age of first dental visit ( $p=0,030$ ) and father educational level ( $p=0,001$ ). There were no significant association with tooth brushing habits and age ( $p=0,954$ ), mother educational level ( $p=0,066$ ) and mean family income ( $p=0,570$ ). **Conclusions:** Gender, father educational level and age of first dental visit seem to be very important factors for adolescents tooth brushing habits.

**PP 323 CALCIFYING CYSTIC ODONTOGENIC TUMOR: REPORT OF TWO CASES IN THE MANDIBULAR POSTERIOR REGION**

EMRE BARIŞ; BURCU SENGÜVEN; FARYD MUSEYİBOV; DENİZ YAMAN;  
AYŞENUR NERGİZ TANIDIR

*Turkey*

**ORAL PATHOLOGY-ORAL MEDICINE**

The calcifying cystic odontogenic tumor (CCOT) or Gorlin cyst is a benign cystic neoplasm of odontogenic origin that is normally presents as a painless, slow-growing mass. CCOTs considered as rare and account for 2% to 6% of all odontogenic lesions of the jaws involving both maxilla and mandible, primarily the anterior region. CCOT generally affects young adults in the second to third decades, with no gender predilection. Two case reports of CCOT in male patients,



one at 54 years old and the other at 69 years old are presented. Enucleation of the tumors was the treatment chosen. Based on the histopathological findings, the diagnosis of two cases was confirmed as CCOT. The purpose of this presentation is to emphasize on CCOT's histological features and treatment, because of its rarity.

**PP 324**    **SOFT RELINING MATERIALS - AN AID IN OVERCOMING DIFFICULT CLINICAL SITUATIONS**

ILIAN HRISTOV; HRISTO KISOV; BOYAN PAVLOV; STEFAN ZLATEV;  
YOSIF STANEV

*Bulgaria*

**REMOVABLE PROSTHODONTICS**

**Background:** A situation of severe, uneven, nonsymmetrical resorption of mandibular ridge is quite a challenge. Such case may become even complicated if there is a narrow, sharp alveolar ridge, thin mucosa, exostoses, painful areas around mandibular hyoid line and mental foramen. Overdeveloped palatal torus and retentive maxillary tuberosity could also be a problem. The even distribution of masticatory forces, when having such anatomical topographic conditions is quite complicated. The prosthesis must transfer the masticatory pressure in a different way, when there are such unfavorable conditions in the mouth. A construction that satisfies these requirements is the two-layer prosthesis. The **aim** of the current investigation is to get the colleagues acquainted with the soft relining materials, their nature, properties, and application. **Materials and methods:** VERTEX SOFT (VERTEX), ELITE SOFT (ZHERMACK), TISSUE CONDITIONER (GC), MOLLOPLAST B (DETAX). Relining of ready to use prosthesis using direct or indirect method. Fabrication of new two-layer prosthesis entirely in laboratory conditions. **Results:** The achieved results are quite encouraging. The retention and stability are grater. The patients' comfort and confidence are higher. **Conclusions:** Despite their indisputable advantages, the soft relining materials have disadvantages as well (they are getting colored very easily, become rigid quite soon, the connection with the basis is not reliable etc.). We consider that the two-layer prosthesis are a reasonable alternative to implant wearing overdentures, for patients with allergies, post-surgical prosthesis etc.

**PP 326**    **STUDY INTO THE VIEW OF DENTISTS REGARDING THE USE OF LABORATORY COMPOSITE RESIN.**

SVETLIN ALEKSANDROV; GEORGI TODOROV; TANYA BOJKOVA;  
RADA KAZAKOVA; VIKTOR HADJIGAEV

*Bulgaria*

**FIXED PROSTHODONTICS**

**Background:** A survey is conducted among the practicing dentists by the means of inquiry method. For that purpose a standardized inquiry form was prepared. The survey covered 10 randomly chosen regional cities on the territory of the republic of Bulgaria. Purpose: Inquiry study into the view of the dentists and technicians regarding the use of laboratory composite resin in daily practice. **Materials and methods:** 330 dentists participated in this inquiry study. Inquiries were made in the period of September 2012 - May 2013. We used direct inquiry method in form of a

written questionnaire, in which the respondents answer in written form of the present questions and answers. Data analysis is performed with software for statistical processing SPSS version 13. The following analyses are used – descriptive, correlation and dispersion.  $\chi^2$  is used to determine the correlational dependences. **Results:** According to the explicit data, a rise of the use of laboratory composite resin is apparent. **Conclusion:** Tendency to rise of the use of laboratory composite resin among the dentist with greater length of service is at hand.

**PP 328 RECONSTRUCTION OF ANTERIOR DEFECTS DUE TO TRAUMA USING SPLIT OSTEOTOMY: A CASE REPORT**

HASAN KUCUKKOLBASI; YENER OKUTAN

*Turkey*

**ORAL IMPLANTOLOGY**

**Background:** Ridge split procedures are commonly performed for horizontal augmentation of narrow ridges which would preclude implant placement. Grafting materials have been used for horizontal ridge augmentation to enable implant placement in optimal positions. The purpose of this report was to describe a combined surgical bone-split and graft techniques for performing horizontal alveolar distraction of the maxillary and mandibular ridges. **Case Report:** A healthy, 23-year-old patient, who have a trauma history was referred to our clinic with the chief complaint of the missing teeth on the anterior region. Intraoral examination revealed that the inadequate bone volume and narrow ridges for implant placement. After the clinical and radiographic examination the treatment was discussed and planned. The surgical technique involved alveolar bone splitting technique and also graft augmentation for horizontal ridge augmentation of the maxillary and mandibular anterior regions. Thereafter, totally 3 implants were placed 5 months later. After 3 months, a successful prosthetic rehabilitation was done following a healing process. Radiological and clinical controls were done both 6 months and 1 year after the treatment. The patient successfully met with the functional and aesthetic results. **Conclusion:** According to the result of this case report it can be concluded that the alveolar bone splitting technique is a promising treatment of deficient alveolar ridges to allow implant placement in optimal position.

**PP 329 INFRARED THERMOGRAPHY - CASE REPORT OF ALOPECIA AREATA**

RAYA GROZDANOVA; IVAN CHAKALOV; TODOR UZUNOV

*Bulgaria*

**ORAL PATHOLOGY-ORAL MEDICINE**

It is an interesting case report that proves the many advantages of infrared thermography as a new diagnostic tool which can be successfully used in detection of hidden pathological processes. The **case report** is about 40 years old female patient that has alopecia areata at the right fronto-temporal region - 5 cm lesion. The dermatological treatment gave no results, so the patient was referred to us for focal diagnostics. We performed infrared thermography - a new, non-invasive and very informative diagnostic tool in the maxillo-facial region and the whole body. We found out two sites with thermal changes of active focal infection. The first one is from dental origin - tooth 36

with periodontitis chronica granulomatosa, which has already been treated a year ago but the root canal retreatment did not lead to sanation. An epicutaneous test for allergy to dental materials showed allergy to iodoform but lack of allergy to potassium iodide. New root canal treatment has been performed with three ionophoresis with potassium iodide before canal obturation and final restoration. The second site with focal infection was found in the genital area - thermal picture of endometriozis and this diagnose has been confirmed by gynecologist. A gynecological operation has been performed. After elimination of focal infection the hairless lesion begin to recover slowly. This and many other cases give us reason to consider infrared thermography to be new perspective, non-invasive and objective diagnostic tool for clarification of difficult to diagnose cases.

**PP 330 CORRELATION BETWEEN THE APPLICATION OF FLUORIDE PROPHYLAXIS AND THE STATE OF ORAL HEALTH**

NATASHA DENKOVA; SNEZANA ILJOVSKA; MIHAJLO PETROVSKI  
FYROM

**RESTORATIVE AND ADHESIVE DENTISTRY**

Caries most often is result of sufficiently knowledgeable and not responsible behavior of the population in relation to the mouth and teeth. Head goal of this study is to determinate the correlation between the condition of oral health and application of any prophylaxis with Fluor. **Materials and methods:** The study included selected groups of students 15 years of age (120 from urban and 120 from RURAL areas) and their parents who completed questionnaires for the parents' education level (elementary, middle, high, Ph.D.), habits to visit the dentist and information on prophylaxis with fluoride. **Results:** The results of the X<sup>2</sup>- test indicates constation that there is statistically significant difference ( $p < 0.05$ ) from the values obtained when and how refer to prophylaxis with fluorine between respondents from the experimental groups A and B. The results of the X<sup>2</sup>- test indicates constation that there is statistically significant difference ( $p < 0.05$ ) from the values obtained when and how is maintaining oral hygiene between respondents from the experimental groups A and B. This shows the need for changes the behavior of the individual, groups or communities as a whole, in terms of establishing correct mode in nutrition, on establishing habits for maintaining oral hygiene and use of fluoride. Health education as one of the most important aspects of preventive dental activities, have a particularly important role in the achievement of health oral administration.

**PP 332 THE ENDODONTIC RETREATMENT - ALWAYS THE FIRST SOLUTION WHEN TREATING CHRONIC APICAL PERIODONTITIS**

OANA ANDREEA DIACONU; LELIA GHEORGHITA; IREN MORARU;  
CRISTIAN PETCU; MIHAELA TUCULINA  
*Romania*

**ENDODONTOLOGY**

**Introduction:** There are several factors causing the failure of the endodontic treatment. One of these factors is the lack of knowledge regarding the internal anatomy of the endodontic space. In the cases of the inferior frontals, this type of failure might often appear due to errors in preparing the access cavity, which eventually leads to omitting the instrumentation, the lavage and the

obturation of the second canal. The aim of the clinical case presented was to demonstrate the efficiency of the endodontic retreatment in such cases. **Methodology:** 42 years old male patient was presented to the Endodontics Clinic of the Faculty of Dentistry of Craiova with acute apical periodontitis symptoms on 4.2., 4.1, 3.1, 3.2. teeth which were changed color in red, probably because of an old endodontic treatment. Radiologically, it was observed a large apical lesion on the specify teeth. The clinical case presented was cured through retreating the teeth in question following the standard protocol therapy and monitoring the healing process of the apical lesions, both radiological monitoring and through CBCT, after 6, 12 and 24 months. **Results:** During recalls, we noticed the reduction of apical radiolucency from the first year after finishing treatment and the disappearing of the radiolucency after 2,5 years. On CBCT exam, we observed however only the reduction not the total disappearing of apical radiolucency **Conclusions:** The endodontic retreatment provides the patient with a chance to save the roots of the teeth which underwent incorrect endodontic treatments and which should otherwise suffer apical surgery or be removed.

**PP 334 MULTIDISCIPLINARY TREATMENT OF CONGENITALLY MISSING MAXILLARY LATERAL INCISORS (CASE REPORT)**

ALMIRO GURAKUQI; STOJANKA PALLKO; CELJANA TOTI; ALBA BIMO

*Albania*

**ORAL IMPLANTOLOGY**

Multidisciplinary treatment of congenitally missing maxillary lateral incisors (case report) Almiro Gurakuqi<sup>1</sup>; Stojanka Pallko<sup>2</sup>; Çeljana Toti<sup>3</sup>; Alba Bimo<sup>4</sup>. **The aim:** The aim of this presentation is to show our experience in the multidisciplinary treatment of bilaterally missing teeth. **Material and method:** The patient A.A, female, was 15 years old. The panoramic X-ray confirmed agenesis of both maxillary lateral incisors and a slight deviation of the median line. The patient had Class I molar relationship. The parents persisted to substitute the missing teeth, but clinically there was not enough space for this treatment. On the other hand tooth 11 and 12 presented a palatal inclination associated with retruded upper lip which compromised the profile. The multidisciplinary treatment plane provided as the first step the orthodontic treatment to create the space for lateral incisors as well as the correct alignment of dental arch. The next step was the application of implants. The removal of fix appliance coincided with the time of replacement of the crowns on implants. **Results and Conclusions:** The patient was satisfied at the end of the treatment. The canine class I relationship was achieved. The space was gained and the missing teeth were substituted. Teamwork was very important in this case offering treatment modalities and various options for replacing missing maxillary lateral incisors in space opening.

**PP 335 NON-SURGICAL ENDODONTIC MANAGEMENT OF UNILATERAL FUSED MANDIBULAR ANTERIOR INCISORS: A CASE REPORT**

SEDA AYDEMIR; GÖZE ARUKASLAN

*Turkey*

**ENDODONTOLOGY**

**Background:** Fusion is developmental anomaly of teeth that may require endodontic treatment. The incidence of fusion in mandibular anterior is rare. This case report describes the

successful endodontic treatment of unilateral fused right mandibular central and lateral incisors. **Materials and methods:** A 35-year-old female patient with spontaneous pain was referred to our clinic. During intraoral and extraoral clinical and radiographic examinations, fusion of the right mandibular central incisor with mandibular lateral incisor was detected. Pulp vitality tests were negative for teeth. Under rubber dam isolation, teeth were accessed and the pulp chamber was then irrigated with 2.5 % sodium hypochlorite. Working length was determined using an electronic apex locator and confirmed with periapical radiograph. The root canals were shaped with ProTaper rotary instruments and dried with sterile paper points. Then calcium hydroxide paste was used as intracanal medicament, and the access was sealed with Cavit. After 2 weeks, the teeth were asymptomatic. The root canals obturated with gutta-percha and Ah Plus. A postoperative final radiograph was taken and the coronal restorations were made with a universal composite resin restorative material. **Results:** The patient returned to the clinic after 12 months for re-evaluation. Clinical examination revealed that teeth were asymptomatic and were not sensitive to percussion and palpation. Radiographic examination revealed appreciable healing. **Conclusions:** Because of the abnormal morphology of the crown and the complexity of the root canal system in fused teeth, treatment protocols require special attention.

**PP 336 PARTICULARITIES OF THE ORAL LIQUID'S MICROCRYSTALLIZATION IN CHILDREN WITH DENTAL CARIES**

SVETLANA PLAMADEALĂ; AURELIA SPINEI; OLGA BĂLTEANU

*Republic of Moldavia*

**PAEDIATRIC DENTISTRY**

In this work we made a comparative analysis of the oral liquid's crystal structure in children with different levels of caries resistance. The purpose of the paper work was to study the particularities of oral liquid micro-crystallization in children with dental caries. **Material and methods:** 200 children have been clinically examined: 100 (50%) children with dental caries constituted the research group, and 100 (50%) healthy children - the controls. The study of crystallographic changes of the oral liquid in children with dental caries and in caries free ones. Dehydration of the oral liquid drops happened in the thermostat at  $t=37^{\circ}\text{C}$ , being protected from dust. Micropreparations have been examined with the scanning electron microscope VEGA TESCAN TS 5130 MM. The study was conducted in accordance with the requirements of the Code of Ethics for scientific research. **Results:** The result of the research determined that the degree of oral liquid's micro-crystallization in children with carious lesions is 2.1 times lower than the same indicator considered in healthy children, which was correlated with the duration of dental caries and the work of caries process. **Conclusion:** The study of structural particularities of dehydrated droplet of oral liquid in children with dental caries has elucidated a number of markers of the changes produced in the oral cavity that can be applied later in the screening research in dental practice, development of cariopreventive measures and evaluation of their effectiveness.

**PP 339 AIDING PROTHESES FOR MARSUPIALIZATION OF CYSTS :A CASE SERIES**

KÜBRA DEĞİRMENCI; AYŞE KOÇAK BÜYÜKDERE; ÖNJEN TAK;  
SERKAN SARIDAĞ

*Turkey*

**INTERDISCIPLINARITY**

**Background:** Cystic lesions can be treated enucleating or marsupialization. Enucleating is often preferred. Marsupialization can be advantageous in many cases to close the anatomic structures. To open or fenestrate on the outer wall of the cyst is the main principle of marsupialization. Therefore, cystic content can drain into the oral cavity and mean to lead to bony in growth in the cavity. Gradually, cyst is reduced in size to an extent that cystic lining becomes continuous with the oral epithelium and is changed by metaplasia into oral mucous membrane. **Methods and materials:** Four patients (1 woman, 3 men) with large cysts which opened fenestrations outer wall of large cysts in different regions presented at the Prosthetic Department of Kocaeli University. Patients ages differ from 23 to 59. In all cases, the drains were placed in window on cysts and impression was taken. The drains on aiding protheses were patterned on opening side of cysts. After 3 months, increase of bone amount could be compared with panoramic radiographs. **Results:** The cysts became smaller and bone amount increased in all cases about 3 months later. **Conclusion:** Aiding protheses can be used for marsupialization. Marsupialization is successful because, once the liquid contents are released, cystic lining has an inherent tendency. These protheses can be cleaned easily, do not require suture.

**PP 340 PERIODONTAL PATIENT PROFILE, ATTITUDE AND SATISFACTION IN FINANCIAL CRISIS: PRELIMINARY STUDY**

KONSTANTINOS TZIMAS; MARIA TSITSARA; GEORGIOS CHATZOPOULOS;  
LAZAROS TSALIKIS; ANTONIOS KONSTANTINIDIS

*Greece*

**PERIODONTOLOGY**

**Introduction:** Inequalities in access to public health service have risen during the last years due to the economic crisis. The quality of dental care in a university periodontal clinic plays a pivotal role in patients' compliance and treatment success. The purpose of the current study is to evaluate the profile, attitude and satisfaction ration of patients seeking periodontal therapy at school of dentistry, Aristotle University of Thessaloniki, Greece. **Methods and materials:** 80 patients visited the undergraduate clinic of the department of preventive dentistry, periodontology and implant dentistry seeking periodontal treatment in a 3-month period. 87.5% of the individuals answered the questionnaire while the others denied their participation in the study. The questionnaires consisted of 6 groups of questions regarding their profile, attitude and satisfaction. **Results:** The majority of the study population was females, married, non-smokers, residing in urban areas, with secondary level of education and adequate oral hygiene habits. Severe periodontitis was the most often diagnosed disease. Although economic crisis was the main reason for visiting the undergraduate clinic, satisfaction ratio proved to be extremely high. The great majority of the participating patients felt confident about the treatment outcome and well-informed after their visit.

**Conclusion:** Within the limitation of this study, rising socio-economical inequalities influence the average periodontal patients' profile visiting a university clinic. The average patient is younger, higher educated, less often smokers suffering from more advanced periodontal destruction than in the past. The level of satisfaction remains significantly high.

**PP 342 CRANIOFACIAL AND DENTAL CHARACTERISTICS OF PATIENT WITH CLEIDOCRANIAL DYSPLASIA**

BILJANA DZIPUNOVA; MIRA POPOVSKA; ILIJANA MURATOVSKA; KATERINA TOSHESKA-TRAJKOVSKA; ZORAN SPASOV  
FYROM

**ORTHODONTICS**

**Introduction:** Cleidocranial dysplasia (CCD) is a rare congenital autosomal skeletal disorder, caused by mutations in the RUNX2 gene, located on the short arm of chromosome 6, that is responsible for osteoblast differentiation. It is characterised by defective ossification, delayed bone and tooth development. CCD is associated with clavicular hypoplasia or aplasia, delayed closure of cranial sutures, brachycephalic skull, and many changes in skeletal patterning and growth. This condition is of clinical significance to dentistry due to the involvement of the facial bones, craniofacial, stomatognathic and dental abnormalities- altered eruption patterns and multiple supernumerary teeth. **Case presentation:** A 12-year old girl, presented with a chief complaint of delayed exfoliation of the primary teeth and delayed eruption of the permanent teeth. Her general physical and facial findings were reported. Oral, dental and gnathometric examination revealed mixed dentition with Class III malocclusion with anterior and posterior crossbite, narrow maxillary dental arch with high narrow palate, dental crowding. Radiological dental findings showed prolonged retention of deciduous dentition and delayed eruption of permanent teeth, supernumerary teeth, underdeveloped condyles. Craniocephalometric analysis showed mandibular prognathism with retroclination of the lower incisors, deficient growth of the midface, increased horizontal mandibular growth and decreased lower facial height. **Conclusions:** Patients with CCD seek treatment mainly for dental problems. Early diagnosis of CCD is crucial for timely initiation of an appropriate treatment approach. A multidisciplinary approach is required, comprising pediatric, orthodontic, surgical and pedodontic teams for management.

**PP 343 EVALUATION OF ALVEOLAR STRUCTURES IN PRE-TREATED SKELETALLY MATURE PATIENTS WITH MALOCCLUSIONS IN DIFFERENT ANGLE CLASSIFICATIONS**

HASAN KAMAK; BURCU ŞENEL; HAKAN KEKLIK  
Turkey

**ORTHODONTICS**

**Aim:** The aim of this study was to evaluate the maxillary and mandibular alveolar structures of pre-treated skeletally mature patients (aged 10,08-48 years old) with malocclusions in different Angle classifications on standardized lateral cephalometric radiographs. **Material and methods:** 129 lateral cephalometric films were randomly selected from the records of pretreatment adult patients in the Kırıkkale University Faculty of Dentistry Department of Orthodontics. The

inclusion criteria were good quality lateral cephalograms and absence of congenital craniofacial anomalies or syndromes. Exclusion criteria were presence of congenital craniofacial abnormalities or syndromes, patients with missed teeth. Upper incisor alveolar heights (UIAH), upper molar alveolar heights (UMAH), lower incisor alveolar heights (LIAH), lower molar alveolar heights (LMAH), the thinnest width of symphysis values (B-B'), mandibular alveolar width (Id-Id') and maxillary palatal width were assessed as described by Esenlik et al (2010). Data analysis was performed with SPSS 20.0 software using the One-way ANOVA test. **Results:** UIAH, UMAH, LIAH, LMAH, B-B', Id-Id' and maxillary palatal width measurements were not statistically significant among the different Angle classifications ( $p>0,05$ ). **Discussion and conclusion:** A relationship between the Angle classifications and maxillary and mandibular alveolar structures could not be determined.

**PP 344** **COMPARATIVE ANALYSIS REGARDING SOME PHYSICO-CHEMICAL PROPERTIES OF ENDODONTIC SEALERS**

MIHAELA SALCEANU; ANCA MELIAN; LIANA AMINOV; CRISTIAN GIUROIU;  
MARIA VATAMAN

*Romania*

**ENDODONTOLOGY**

**Introduction:** The knowledge of physico-chemical properties of endodontic sealers allows the dentist to obtain higher rate of success in the treatment of chronic periapical lesions. The aim of study is to assess the baseline pH values, the dynamic evolution of pH values and solubility rates of some important endodontic sealers used in dental practice. **Materials and methods:** The pH assessment was performed on AH26 (DeTrey Dentsply), SEALAPEX (Kerr), ENDOMETHASONE (Septodont), ENDOFLAS (Sanlor). pH was recorded at baseline, after 24 hours, 7 days, 14 days, using pH-meter SEIBOLD WIEN. The analysis of solubility was focused on two hydroxid calcium based endodontic sealers (SEALAPEX- Septodont, ENDOFLAS- Sanlor) immersed in two artificial solutions with pH 6 and pH 7,5. The solubility was assessed at 48 h and 72 h, measuring the solid substance dissolved in 100 ml specific solvent. **Results:** At baseline pH values were 6.70 (AH26), 8.65 (SEALAPEX), 8.55 (ENDOMETHASONE), 7.20 (ENDOFLAS). After 14 days pH values decreased to 6.60 for AH26 and raised to 9.10 (SEALAPEX), 8.80 (ENDOMETHASONE), 8.40 (ENDOFLAS). For both time periods (24 h, 72 h), SEALAPEX presents lower solubility at pH 6 and pH 7.5. **Conclusions:** The studied endodontic sealers present high variability regarding both baseline and dynamic evolution of pH values as well as solubility rates.

**PP 345** **EVALUATION OF MAXILLARY AND MANDIBULAR ALVEOLAR STRUCTURES BETWEEN MAIL AND FEMAIL PRE-TREATED SKELETALLY MATURE PATIENTS**

HASAN KAMAK; BURCU ŞENEL; HAKAN KEKLIK

*Turkey*

**ORTHODONTICS**

**Aim:** The aim of this study was to evaluate the maxillary and mandibular alveolar structures of mail and female pre-treated skeletally mature patients (aged 10,08-48 years old) with different malocclusions on standardized lateral cephalometric radiographs. **Material and Methods:**



129 lateral cephalometric films were randomly selected from the records of pretreatment adult patients (female:88, male:41) in the Kırıkkale University Faculty of Dentistry Department of Orthodontics. The inclusion criteria were good quality lateral cephalograms and absence of congenital craniofacial anomalies or syndromes. Exclusion criteria were presence of congenital craniofacial abnormalities or syndromes, patients with missed teeth. Upper incisor alveolar heights (UIAH), upper molar alveolar heights (UMAH), lower incisor alveolar heights (LIAH), lower molar alveolar heights (LMAH), the thinnest width of symphysis values (B-B'), mandibular alveolar width (Id-Id') and maxillary palatal width were assessed as described by Esenlik et al (2010). Data analysis was performed with SPSS 20.0 software using the One-way ANOVA test. **Results:** UIAH, UMAH, LIAH, LMAH, B-B', Id-Id' and maxillary palatal width measurements were statistically significant among the male and female patients ( $p < 0,05$ ). All measurements were greater in male patients. There was high significance in maxillary width, UIAH, UMAH, LIAH, LMAH measurements ( $p = 0,000$ ) and Id-Id' measurement ( $p = 0,001$ ). **Conclusion:** All of the measurements of maxillary and mandibular alveolar structures of male patients were greater than female patients'.

**PP 346 TREATMENT OF BABY WITH PIERRE ROBIN SYNDROME USING MODIFIED NUTRITION PLATE: A CASE REPORT**

A.FURKAN KARAKOYUNLU; HASAN KAMAK; HAKAN KEKLIK

*Turkey*

**ORTHODONTICS**

**Objective:** Pierre Robin Syndrome (PRS) was defined by Robin in 1923 and it is a triad of micrognathia, glossoptosis, and cleft palate that results in upper airway obstruction and feeding problems. If untreated, this problem can lead to exhaustion, cardiac failure, and ultimately death, especially during the early months of life. **Case:** A four days old boy with complaints of cleft palate, malnutrition, and respiratory distress was brought to the our clinic. The baby was the first child of the parents and there was no syndromic finding and familial cleft lip and palate trait. It was decided that a modified nutrition plate should be applied so that vital functions could be restored and the tongue could be brought to its normal position within the mouth. Impressions from the baby were taken with a silicone-based material in Newborn Department at Research Hospital of the Faculty of Medicine in Kırıkkale University. To prevent the tongue from falling back into the oropharynx, a wire which was prepared from 0.9-mm diameter stainless steel extension would be to the nutrition plate. The acrylic portions of the plate were prepared using typical methods. To prevent the wire extension from damaging the soft tissues, the end of the extension was covered with an acrylic button. **Conclusion:** Modified nutrition plate is a very effective appliance which facilitates both breathing and feeding of the babies having PRS.

**PP 347 BIO AESTHETIC RECONSTRUCTION OF ABRADED TEETH USING METAL FREE AND METAL CERAMIC RESTORATIONS**

NATASHA STAVREVA; LJUBEN GUGUVCHEVSKI; BILJANA KAPUSHEVSKA;  
ANETA MIJOSKA; VESNA AMBARKOVA  
FYROM

**FIXED PROSTHODONTICS**

**Background:** Damage of hard tooth-tissue, which is not caused by caries, is a physiological process present throughout the whole life, but some factors can bring about great losses of the hard tissue. This damage can be caused by a combination of different etiological factors, such as genetical and functional ones. In everyday practice we are very often challenged with patients, who have abraded teeth. The aim of this study is to present a prosthetic rehabilitation with metal free and metal free ceramic restorations. **Materials and methods:** A 50 years old patient is having a large teeth abrasion and loss of vertical dimension and slipping of the lower jaw into protrusion. The treatment of both jaws was a combination of metal-ceramic restorations in lateral segments and metal-free ceramic based on zirconium (IPS e.max ZirPress, Ivoclar Vivadent, Schaan, Liechtenstein) in frontal area. **Results:** The patient and the doctor were satisfied with the restorations, both aesthetically and functionally. After six months restorations were also found successful in terms of marginal adaptation, secondary caries, regaining of vertical dimension and occlusion. **Conclusion:** Using a combined treatment biological health, function and aesthetics and perfect clinical results in both frontal and lateral segments were achieved, and surgical elongation of clinical crown has been avoided.

**PP 349 TREATMENT OF CLASS III SKELETAL ANOMALIES WITH PREMAXILLARY DISTRACTION OSTEOGENESIS: A CASE REPORT**

İREM GEÇEROĞLU; HASAN KAMAK; HAKAN KEKLIK  
*Turkey*

**ORTHODONTICS**

**Background:** Distraction osteogenesis is a biological process involving the formation of new bone between viable bone segments that are gradually separated by traction. Premaxillary distraction is a new method for correcting mild to moderate facial insufficiency. **Method:** 19-year-old female patient admitted to our clinic. Class III skeletal anomalies were diagnosed by using cephalometric evaluation. Maxillary lateral incisors are missing congenitally. Dental relations were Angle Class II and anterior cross-bite was present. Premaxillary distraction was decided to done for resolve the deficiencies in the premaxillary region and it was accepted by patients. Mini screw were placed in premaxillary region; length of 8 mm and diameter of 1.6 mm. Le Fort I corticotomy was performed under general anesthesia. Distraction was started 7 days later. Screw the first 7 days 2 turns. Translation to a total of 28 turns. Consolidation phase began after 3 months the patient's fixed treatment. **Conclusion:** In the premaxillary region individuals with developmental disabilities while promoting Le Fort I incision indicated premaxillary distraction; especially anteriorly with Class I molar region close to that seen in individuals with cross-over may be preferred because it contains more minimal surgical procedures.

PP 350 THE CHALLENGES OF A FLAPLESS DENTAL IMPLANT PLACEMENT

KHADER ALQAWASMEH; RAKSHA BATAJOO; SUMBAL RAHMAN

Romania

ORAL IMPLANTOLOGY

We aim to analyze the advantages and disadvantage of flapless dental implant indications and contraindications as a component of complex oral rehabilitation. **Materials and methods:** 57 patients ranging in age from 24 to 86 years, 29 implants were placed. The parameters evaluated were total surgical time, implant survival, bone quality and quantity, implant position by tooth type, depth from mucosal margin to bone crest, implant length, probing depth inflammation and crestal bone changes. **Results:** In terms of the surgical procedure itself, two approaches have been suggested for initial soft tissue and bone penetration during the flapless surgery technique. The first approach requires a long slender drill with a pointed tip to penetrate the soft tissue as well as the underlying bone. The second surgical technique involves the use of soft-tissue punches of 3.0, 4.0 and 5.0 mm diameter that have been tested in dogs. **Discussions:** When the mucosa was perforated with a 3.0-mm tissue punch the length of the junctional epithelium was shorter the probing depth was shallow and less crestal bone loss occurred compared to results using a tissue punch with a diameter > 4.0 mm. **Conclusions:** The following diagnostic treatment planning criteria indicates, flapless surgery using minimally invasive technique is a predictable procedure. Benefits of the procedure are lessened surgical time, minimal changes in crestal bone levels, probing depth and inflammation, lessened postoperative discomfort while still needs further studies in order to identify the proper role of the technique in oral rehabilitation.

PP 351 UNILATERAL CERVICAL HEADGEAR TREATMENT OF A PATIENT WITH UNILATERAL CLASS II MOLAR RELATIONSHIP:A CASE REPORT

HASAN KAMAK; BURKU SENEL; GULEN KAMAK; HAKAN KEKLIK

Turkey

ORTHODONTICS

**Aim:** Class II malocclusion which is seen in about 20% of population is one of the most common abnormalities. Sometimes in Class II malocclusion, unilateral Class II molar relationship (Class II subdivision) is possible. One of the alternative methods is unilateral headgear which correct to unilateral Class II molar relationship and prevent the change of Class I molar relationship in the opposing arch. The aim of this study is to present treatment with unilateral CHG in a patient with skeletal Class I, dental Class II subdivision (unilateral Class II molar relationship). **Subjects and Methods:** 13,9-year-old female patient with anterior crowding was referred orthodontic treatment. In clinical and radiographic evaluation, the patient had normal intermaxillary relationship, dental Class II subdivision malocclusion and moderate crowding. Unilateral cervical headgear was used to obtain dental effect which was provided to apply force about 600 grams for at least 16 hours, together with fixed appliances. Right outer bow was shortened and left outer bow was not change. They were inclined upward in order to apply force on the resistance center of the upper first molars and provide parallel movement of the upper molars. **Results:** Overjet and overbite relationship which showed slight deviation from normal value was corrected. In treatment

of Class II molar relationship with unilateral CHG was observed without changing Class I molar relationship. Furthermore, Class II canine relationship on one side was corrected to Class I relationship. **Conclusion:** It is concluded that unilateral CHG corrects Class II subdivision malocclusion effectively providing to cooperation of patient.

**PP 355** **ORAL HEALTH AND QUALITY OF LIFE OF GERIATRIC POPULATION IN RM**  
NATASHA STAVREVA; LJUBICA SIMJANOVSKA;  
MIRJANA MARKOVSKA ARSOVSKA  
FYROM

#### GERODONTOLOGY

**Background:** In geriatric population due to their specific needs and disease significant changes in the structure of diseases occurs. Oral health condition is essential component of quality of life of the overall population. Poor oral health undermines the overall health. Difficulties in chewing and speech with lost teeth lead to the need of incorporating oral-prosthetic dentures. **Materials and methods:** The survey was prospective cross-sectional study conducted among 165 institutionally sheltered patients at Gerontology Institute in Skopje and 170 patients from dental specialist clinics, both aged 65 and over. The significance of difference depending on the type and distribution of responses was tested with statistical program (Chi-square, Fisher-exact test, Mann-Whitney test, Kruskal Wallis test, t-test for independent samples, Analysis of variance) using statistical significance of  $p < 0.05$ . **Results:** During clinical examination, two groups are dominated by patients with internal upper and lower total dentures (43.6% vs 26.5%). From the analyzed results obtained from answers to GOHAI questionnaire we could see that at the institutional sheltered patients there is substantial difference in quality of life compared with adults from the dental clinics. **Conclusion:** Total score obtained using GOHAI indicator shows that institutionally sheltered patients have unsatisfactory condition of oral health and quality of life. This is indicated by the fact that the highest score is 40 and maximum score by Licker-scale is 48. The oral health and quality of life need to be improved. Key words: Geriatric population, oral health, quality of life, GOHAI indicator.

**PP 356** **FABRICATING FINAL PROSTHETIC RESTORATION OF CLEFT PALATE**  
**PATIENT AFTER DISTRACTION SURGERY**  
BETÜL KÖKDOĞAN BOYACI; MUSTAFA KOCACIKLI  
*Turkey*

#### REMOVABLE PROSTHODONTICS

The patient 30 years old who had cleft palate disease has lost his premaxillae. After two surgical distraction and flap operation the final removable prostheses are fabricated.

PP 362 ORAL HEALTH IN CHILDREN WITH DIABETES MELLITUS TYPE I

MIRJANA DJURICKOVIC

Montenegro

PAEDIATRIC DENTISTRY

**Aim:** The main goal of this research is to determine the state of oral health of children with diabetes mellitus type I in Montenegro. **Methods:** For this research was obtained approval of the Ethics Committee of the Clinical Center of Montenegro in Podgorica. Informed parental consent was gained for every child. This study includes 177 patients aged 10 to 15 years, of both sexes, divided into two groups; the first group D, 87 of them, made up of children with diabetes mellitus type I. Second, the control group K, 90 of them, representing the healthy children. The status of the tooth is registered with the Klein Palmer system. In order to determine the oral hygiene applied the Plaque Index by Silness-Loe and Index of Tartar by Green, and the clinical assessment of the gingiva was applied using Silness-Loe's index. **Results:** There were no statistically significant differences in the mean values of DMFT index between the diabetics and non-diabetics children. However the mean Plaque index and the mean Index of Tartar was significantly higher in diabetic subjects than non-diabetics ( $p < 0.05$ ). The children with type I DM had significantly higher mean values of GI compared with the non-diabetic subjects ( $p < 0.001$ ). Gingival bleeding upon probing was most frequent in the percentage of the diseased population, while the percentage of healthy periodontium forefront in the control group ( $p < 0.001$ ). **Conclusion:** Children with diabetes mellitus have worse oral health compared to healthy children of the same age.

PP 363 FRENECTOMY. IS THERE A CLINICAL SIGNIFICANCE NOWADAYS?

ANASTASIA VIOLESTI; DIMITRIS PAPALEXIOY; ANTREAS GRIGORIADIS;  
ANTIGONE DELANTONI; IOANNIS VOUROS

Greece

PERIODONTOLOGY

**Background:** Frenectomy is a surgical procedure performed in dentistry. The papillary attachment of the frenum (most frequently the labial one) may be pathological. **Materials and methods:** Pathological attachment is considered when by applying tension to the frenum the movement of the papillary tip produces ischemia to the region. A surgical procedure may be required in specific cases and under particular indications. The major indications are: 1) A persistent midline diastema after complete eruption of the anterior teeth 2) Prevention of relapse after orthodontic closure of midline diastema 3) Hypertrophic thick frenum 4) V-shaped intermaxillary suture radiographically 5) High frenal attachment associated with gingival recession and insufficient attached gingiva There is a number of techniques used for labial frenectomy, such as the classical frenectomy (Archer's technique), Vestibular sulcus extension, Z-plasty, V-Y plasty, Miller's technique, Edward's technique and free gingival graft. **Results:** A thorough and complete description of the techniques and their indications will be presented and a detailed analysis of the periodontal implications and complications will be analyzed through the presentation of different cases. Emphasis will be given on the importance of free gingival graft technique aiming at establishing healthy conditions in the surrounding periodontal tissues. **Conclusions:** Frenectomy is

a technique with specific indications. The clinical methodology requires specific skills and a thorough knowledge of the background of each case for the best results individually.

**PP 364 THE ENDODONTIC MANAGEMENT OF PERMANENT MAXILLARY RIGHT CENTRAL INCISOR WITH LATERAL LUXATION: A CASE REPORT**

FEVZI BUYUKGEBIZ; ISMAIL OZKOC AK; HAKAN GOKTURK

*Turkey*

**ENDODONTOLOGY**

**Introduction:** A lateral luxation injury produces displacement of a tooth in a direction other than axial, occurs in conjunction with comminution or fracture of the alveolar socket and renders the tooth immobile. **Purpose:** The aim of this study was to present the endodontic treatment after lateral luxation of permanent maxillary right central tooth. **Material and method:** An 10-year-old male patient had applied a clinic after suffering trauma to the anterior maxilla and a rigid-splint was performed by dentist. After 3 weeks, the patient was referred to our clinic with mild pain for the re-evaluation and possible treatment. After radiographic and clinical examinations; tooth didn't respond to electrical pulp tests. No history of mobility, tenderness to percussion and palpation was noted. Root canal treatment was performed. **Results:** Examinations 6 and 12 months after the treatment revealed success with the observance of normal function, esthetics and healthy surrounding periodontal structures. **Conclusions:** Traumatic dental injuries of permanent teeth occur frequently in children and young adults. Luxations are the most commonly occurring of all dental injuries. After traumatic dental injuries; diagnose, examinations, treatment procedures should be considered in details and carefully.

**PP 365 TREATMENT OF NON-MELANOMA SKIN CANCER USING 3D NON -MOH'S SURGERY**

GORAN VIDENOVIC; ZORAN VLAHOVIC; VOJKAN LAZIC

*Serbia*

**ORAL SURGERY AND ORAL MAXILLOFACIAL SURGERY**

**Introduction:** Treatment of non-melanoma skin cancer (nm-sc) comprises of complete tumor masses removal as well as removal of subclinical tumor extension which spreads out of the clinical border of the main tumor. The aim of this study is to present correlation between subclinical tumor extension (ste) and size of the nm-sc using 3d non-mohs surgery method. **Method:** We treated 64 patients with primary nm-sc. Following a clinical examination and surgical procedure, histological investigations were performed using breuninger's 3d method. We performed statistical linear correlation analyses. **Results:** In the group of tumors size < 10mm 47% of tumors had ste less than 2mm, 11.8 % had ste more than 3mm. In group of tumors size from 11 to 20 mm 84 % of tumors had ste less than 5mm. In group of tumors size from 21 to 30 mm 85% of tumors had ste less than 7mm and in group of tumors size > 31mm minimal ste was 5mm. **Conclusion:** There was high level of correlation between size of the tumor and subclinical tumor extension.

**PP 370 THE SHORTCOMINGS OF CONVENTIONAL OCCLUSAL REGISTRATION METHODS**

CARMEN IOANA BIRIS; MONICA DANA MONEA; DIANA POP;  
CLAUDIU VASILE HORGA; MIRCEA SUCIU

*Romania*

**DENTAL BIOMATERIALS AND DEVICES**

**Background:** The registration with maximum accuracy of the occlusal contacts, both physiological and pathological, should be a priority for the dentists. The usual methods of recording occlusal contacts show the location of the contacts without appreciating the intensity and sequence. Therefore there are reservations about their accuracy and safety. A safer quantitative method is the use of T-scan system, Prescale and photo-occlusion method. This method provides a determination of the intensity and sequence of the occlusal contacts. **Aim:** The study aim was to compare the occlusal registration indicators, determining their accuracy, by measuring occlusion areas of each one. **Material and methods:** The study included 20 patients, average age of 22.5 years, with the upper and lower first molars present and not restored in any way. Was conducted occlusal registrations using articulating paper of 8, 80 and 200 $\mu$  and computerized occlusal analysis, in centric occlusion. The determination was performed both in the dry and wet conditions. **Results:** Following this study, and corresponding it with the medical literature, we found that 200 $\mu$  articulation paper marks larger areas and a greater number of occlusal contacts in comparison to 8 and 80 $\mu$ , both. The T-scan ensures both very precise location and sequence of the occlusal contracts and occlusal forces, parameters which cannot be determined by using the conventional registrations. **Conclusions:** Computerized occlusal analysis quantitatively determines the interceptive contacts and it is able to objectively distinguish them from contacts in MIP, therefore becoming advisable to be of commonly use.

**PP 373 DURABILITY ORAL REHABILITATION OF PATIENTS TREATED WITH REMOVABLE PARTIAL DENTURES WITH BALL ATTACHMENT SYSTEM**

CLAUDIU VASILE HORGA; CARMEN IOANA BIRIS; DIANA POP;  
RADU HOREA BOSTAN; MIRCEA SUCIU

*Romania*

**REMOVABLE PROSTHODONTICS**

**Background:** Specific studies show that frequency of large edentouism is between 20-35% depending on the patient's age. In this situation one of the main problems facing dental prosthetic practitioners is the difficulty of the partial large bi-terminal edentouism treatment, but also the treatment of sub-total edentations. **Objectives:** This paper proposes to praise the advantages of using the special means of attachment, prop and stabilization - ball attachment, but also analyzing their limits. For this purpose we have followed-up for ten years different clinical cases we have treated. **Material and method:** The study were included, following selection criteria, 30 patients, of both genders, average age 54.9 years old, who received removable partial dentures with ball attachments. Patients were evaluated at three, five and ten years. Statistical interpretation was made

using Fisher Exact Test ( $p < 0.005$ ). **Results:** This study praised the importance of selection an optimal therapeutical solution pointing out the frequency and the nature of the occurred accidents, but also the durability of this type of prosthetic restorations. After three years we observed that association between type of prosthetic restoration and viability of this are not statistically significant ( $p = 0,2994$ ), statistical correlation occurring after five and ten years of wearing the removable partial dentures.

**PP 376 SUBGINGIVAL TOOTH FRACTURE MANAGEMENT THROUGH CLINICAL CROWN LENGTHENING. A CASE REPORT**

THEODOROS GKOMOZIAS; DIMITRA VAKOU; DIMITRA DIOMATARI;  
MAGDALINI KOKKONI; SPIRIDON SILVESTROS

*Greece*

**PERIODONTOLOGY**

**Background:** Crown lengthening is the surgical procedure, during which part of the periodontal tissues is removed in order to increase clinical crown height. The presence of a subgingival tooth fracture is a major indication to apply this surgical procedure. The aim of this presentation is to demonstrate a clinical case, in which surgical crown lengthening was performed so that prosthetic restoration could be achieved, after an extensive crown fracture. **Materials and methods:** The patient was referred to our dental clinic with crown fracture on tooth #36, which extended subgingivally on the lingual side. The existing amalgam restoration was overcontoured and secondary caries was detected. After caries debridement, it was decided that crown lengthening was needed in order the tooth could be restored with a fixed restoration. An apically positioned flap combined with ostectomy was performed. Five weeks after the surgery, a post and core was fabricated and the final porcelain-fused-to-metal crown was cemented two months later. **Results:** The performed surgical crown lengthening facilitated sufficiently the prosthetic management providing the proper biological width, for the reattachment of epithelium and the connective tissue fibers. **Conclusions:** Crown-lengthening surgery is a crucial technique in restorative dentistry. Although it is a very predictable procedure, the clinician must be familiar with the indications, as well as the limitations of this technique for achieving an optimal biologic as well as restorative outcome.

**PP 378 COMPLETE DENTURE REHABILITATION OF A PATIENT WITH ORAL MUCOSAL HYPERPLASIA AND PARKINSON'S DISEASE. CASE PRESENTATION**  
MONICA MIHAELA CRAITOIU; CLAUDIU MARGARITESCU

*Romania*

**REMOVABLE PROSTHODONTICS**

A 66 year old female patient was referred to us for prosthodontic treatment. The patient was completely edentulous and was wearing thirteen years old, ill-fitting dentures. She had been diagnosed with Parkinson disease four years before, was taking specific medication and presented resting tremor, slight postural instability and speech difficulties. The orofacial examination showed



angular cheilitis that was caused by reduced occlusal vertical dimension, but is also a common finding among patients suffering from Parkinsons disease. The intraoral examination revealed the following: severely resorbed mandibular ridge and oral mucosal hyperplasia in the front lower vestibule area, due to prolonged wear of an instable lower complete denture. It also revealed upper denture stomatitis and the patient stated that she was experiencing soreness. We asked the patient to stop wearing the old dentures and referred her for a mycological examination that showed the presence of *Candida albicans*. Local and general treatment was initiated. We surgically removed the oral mucosal hyperplasia and histological examination was performed. One month later, the local stomatitis symptoms had disappeared and the surgical site was completely healed. The prosthodontic treatment we chose consisted of stable complete dentures restoring the occlusal vertical dimension.

**PP 380** **SOCIOLOGICAL SURVEY AMONG THE BULGARIAN DENTISTS FOR THEIR READINESS TO TREAT CHILDREN WITH TALASSEMIA MAJOR**

HRISTO BOZUKOV; VESELINA KONDEVA; NINA MILCHEVA;  
RADOSVETA ANDREEVA

*Bulgaria*

**PAEDIATRIC DENTISTRY**

**Background:**  $\beta$ -thalassemias are inherited anemias due to lowered or absent synthesis of  $\beta$ -globin chain which results in reduction of hemoglobin and the number of erythrocytes. Thalassemia major is the most severe form. The absence of monthly blood transfusions leads to fatal end for the affected children. Specific and non-specific oral changes are observed. There are 240 registered patients and 170 000 carriers in Bulgaria. About 100 of the patients are children under 18-years-old. **Methods and materials:** The study includes 200 dentists from 4 cities of Bulgaria: Varna, Plovdiv, Sofia and Stara Zagora. Each of them field in questioner. The aim of the study is to research the awareness of dentists on the disease thalassemia major and the oral changes that it provides. **Results:** In this study it is found that more than 50% of Bulgarian dentists don't know enough about Thalassemia major. 40% of participants in the inquiry prefer to not work that kind of patients and send them to another dentist. Under10% of the dentist know how to act when having such a patient. **Conclusions:** Due to lack of information most of dentists avoid treating patients with thalassemia major which leads to mistreatment and affects the quality of life of the small patients.

**PP 381** **COMPARISON OF ANTHROPOMETRIC AND CALIPERIMETRIC DATA OF ACTIVE ATHLETIC AND NON ACTIVE CHILDREN AND ADOLESCENTS.**

ALEKSANDAR ATANASOVSKI; VESELINA KONDEVA; VELINA STOEVA

*Bulgaria*

**PAEDIATRIC DENTISTRY**

**Introduction:** Football is the most preferred sport among young boys in Bulgaria. Statistically every fifth child has active participation in sport, such as football. Physical exercise affects development, growth and maturation of children but also puts them at risk as a result of

stressful training, increased carbohydrate intake and dehydration. The availability of data in foreign literature motivates us to investigate the problem in Bulgaria. **Aim:** To compare the anthropometric and caliperimetric data of active athletic and non active children and adolescents. **Materials and methods:** The study included 300 children actively participating in sport in two professional football clubs. Children are from 8 to 17 years old, divided by 30 in each age group. The measurements are height, weight, BMI, body fat percentage and body water percentage. The mean values from the study are compared with reference values of children who are not actively exercising. **Results:** In all groups the data for weight, BMI, and percentage of body water are lower than the reference values of children who do not participate actively in sports. **Conclusion:** Sports positively affects the growth and development of children and adolescents. The data obtained from the study will serve as a basis for comparison with oral health indicator.

**PP 382 A STUDY OF QUALITY OF DECONTAMINATION BEFORE STERILIZATION OF DENTAL INSTRUMENTS IN ROUTINE DENTAL PRACTICE**

VELINA STOEVA; VESELINA KONDEVA; ANI KEVORKYAN;  
ALEKSANDAR ATANASOVSKI; ALICA RAYCHEVA

*Bulgaria*

**INTERDISCIPLINARITY**

**Introduction:** In dental practice are used instruments with complex design of the working end, retentive for blood. In Bulgaria is used hand decontamination of instruments, which is risky for both patients and the dental team. The Ultrasonic cleaners are much less used. **Aim:** To investigate the effectiveness of routine hand decontamination of large and small instruments in dental practice and in addition the effect of dental ultrasonic cleaner by testing for residual traces of blood. **Materials and methods:** In January-February 2015 were taken 485 samples (205 large and 280 small instruments, visibly contaminated with blood) from five dental offices within five visits. Benzidine test is used to establish the residual traces of blood. Samples of instruments, that are positive after the hand decontamination, are placed in an ultrasonic cleaner. **Results:** Of the total 485 analyzed samples, 63 (12.98%) have residual traces of blood. Among large instruments - 7.8% positive samples and 16.78% among small instruments ( $u = 3.08$ ,  $p < 0.01$ ). Of all positive instruments ultrasonic decontamination was achieved in all large instruments, while small-12.69% of nerve extractors are not decontaminated. **Conclusion:** Manual cleaning does not guarantee reliable decontamination of dental instruments, unlike ultrasonic cleaner guarantee for large instruments . In small, traces of blood are seen after ultrasonic treatment, which requires its combination with a suitable enzyme product and use of disposable nerve extractors.

**PP 385 RESTORATION OF A MISSING TOOTH WITH IMMEDIATE IMPLANT PLACEMENT**

ANASTASIOS PETRIDIS; MARIA HATZIPARASKEVA

*Greece*

**ORAL IMPLANTOLOGY**

**Introduction:** Restoring missing teeth with implant placement is a common option in dentistry, however there is a dilemma in whether there should be immediate loading on the

implants or not. Furthermore, if loading it immediately will this affect their stability and their prognosis? Purpose of this poster is to demonstrate that under certain circumstances immediate implant loading is possible, hence solving the problem of waiting until the final restoration. **Case report:** A woman, 67 years old, came to the clinic with pain in the area of #12-13. After clinical radiographic examination, root fracture was revealed at both #12-13. Extraction of these teeth was decided and immediate implant placement with Neodent implant 410 at the place of #12. The patient had already two implants 3i 411 and 511 at the places of #14, 16. Thus, after placing the implant at place #12, an immediate loading with metal-acrylic bridge 16-12 was conducted with the minimum forces in the occlusal surface at #12,13. **Conclusion:** In cases that the implants that are placed are in a position where their osseointegration can't be obstructed by severe forces dentists can proceed at immediate loading of the implants and so solving the problem of waiting for 4 months.

**PP 386 PRESENTATION OF AN AESTHETIC RESTORATION IN THE ANTERIOR ZONE WITH ZIRCONIUM  $\frac{3}{4}$  CROWNS**

MARIA HATZIPARASKEVA; ANASTASIOS PETRIDIS

*Greece*

**RESTORATIVE AND ADHESIVE DENTISTRY**

**Introduction:** A common aesthetic problem in dentistry is the appearance of erosions on the buccal surfaces of all teeth. Causative factor of creating erosions in most cases is proven to be the constant consumption of acidic foods and drinks. The purpose of this poster is to present the restoration of the anterior zone where a patient had severe erosions and desired to change the aesthetic result at the anterior aesthetic zone. **Case report:** A 45 years old man came to the clinic with severe erosions at the anterior zone and specifically on the buccal surface of 12,11,21,22. The erosion was so severe that dentine was revealed in most teeth. The teeth were prepared in two sessions in order to receive zirconium  $\frac{3}{4}$  crowns. The margin placement was at the same height with the gingiva with a feather edge. After the teeth preparations, temporary acrylic crowns were made, with the use of a silicon key in the clinic. Finally, after checking the zirconium frame, choosing crown color, checking occlusion, the crowns were permanently placed using variolink (dual curing composite for the adhesive cementation of indirect all ceramic restorations). **Conclusion:** Prosthetic aesthetic problems of the anterior zone can be restored by placing partial coverage crowns, thus avoiding large preparations of the teeth.

**PP 388 TREATMENT OF DISTAL BITE IN PERMANENT DENTITION BY FIXED APPLIANCES - CASE REPORT**

ZORANA STAMENKOVIC; VANJA RAICKOVIC; NATASA RANDJELOVIC;  
TINA PAJEVIC; EMIRA LAZIC

*Serbia*

**ORTHODONTICS**

**Aim:** The aim of this paper was to show that moderate skeletal Class II in permanent dentition can be successfully treated by fixed appliances. **Material and methods:** In this case 16 years old female patient, with skeletal and dentoalveolar Class II, was treated by fixed appliances.

Study cast analysis and lateral cephalogram have been done before and after treatment. Before treatment, overjet was 6mm, overbite 6mm, there was no crowding in dental arches, the width of upper and lower teeth was proportional, SNA was 77°, SNB 71°, ANB 6°, Bjork's polygon 391°, Jarabak ratio 67%, I/SpP 73° and i/MP 83°. Non-extraction treatment was done because of bimaxillary retrognathism, so that facial aesthetics at the end of the treatment would be satisfying. Patient wore appliances for 16 months. In the final stages of treatment, intermaxillary Class II elastics were used for four months. **Results:** At the end of the treatment overjet was 3mm, overbite 2,5mm, SNA 76°, SNB 72°, ANB 4°, Bjork's polygon 394°, Jarabak ratio 65.3%, I/SpP 76° and i/MP 80°. Patient is now in period of retention, without signs of relapse and wears positioner every night. On orthopantomogram tooth germs of all four third molars were noticed, and their extractions planned. **Conclusion:** Successful treatment of distal bite in permanent dentition by fixed appliances and intermaxillary Class II elastics can be expected in patients without severe skeletal discrepancies, crowding in dental arches, large protrusion of frontal teeth and with balanced vertical growth.

**PP 389** **STUDY ON ROOT MORPHOLOGY VARIABILITY OF MANDIBULAR MOLARS 3**  
TIBERIU TIRCA; MARINA AMARASCU  
*Romania*

#### INTERDISCIPLINARITY

**Introduction:** The knowledge of root morphology and variability of roots number of third maxillary molar is essential in the optimal performing of endodontic treatments and dental extraction as well as to avoid intra- and post-extraction complications. The aim of study is to highlight the variability of root morphology of third maxillary molar regarding roots number, form and dimension. **Materials and methods:** The study was performed on a study group of 82 patients (age 20-60). A total number of 100 third maxillary molars were examined and data regarding number, form and dimension of third maxillary molar. **Results:** The study highlighted the existence of third maxillary molar with one root (20%), 2 roots (3%), three roots (74%), four roots (2%). Nanic maxillary third molar was found in 1% cases. **Conclusions:** Third maxillary molar presents a high variability regarding the number, form and dimension of roots.

**PP 390** **STUDY REGARDING THE SALIVARY MICROCRYSTALLIZATION INDEX VARIATION ON THE PATIENTS HAVING DENTAL EROSION LESIONS**  
GALINA PANCU; SORIN ANDRIAN; IRINA NICA; ANTONIA MOLDOVANU;  
SIMONA STOLERIU  
*Romania*

#### RESTORATIVE AND ADHESIVE DENTISTRY

The aim of this study was to evaluate the variation of salivary micro crystallization index (IMK) to the patients having gastro esophageal reflux disease after using a remineralization product. **Material and method:** Twelve patients having gastro esophageal reflux disease were included in this study. Unstimulated saliva was collected in the same day and at the same hour for each patient. A total amount of 0.5 ml of unstimulated saliva was placed on a glass plate, dried for 30 minutes in a thermostat at +37°C, and then studied using a Nikon Eclipse E 600. The images were saved and stored on a computer. The IMK index was determined using the formula:  $IMK = no$

of the eye network points projected on crystals/ no of the eye network points projected on the entire saliva drop. All the patients were subjected to dental hard tissues demineralization using Decadent MI Paste (GC Corporation) for 3 weeks. After 3 weeks the IMK index was determined for each patient. **Results:** The appearance of the crystals formed by saliva precipitation on the plates corresponds to one of these aspects: dendrite-shaped crystals, chamomile flower, multiple points, micro network, cube or egg-shaped forms. The mean values of IMK index varied from 0.4 before treatment to 0.9 after remineralization using Recaldent MI Paste. **Conclusions:** Recaldent MI Paste increased the remineralization capacity of saliva when used to the patients having gastro esophageal reflux disease.

**PP 393** **POSSIBILITY OF USING PLATELED-RICH FIBRIN (PRF) IN CORRECTION OF FACIAL ASYMMETRIES**

NIKOLA MIKOVIĆ; DRAGO JELOVAC; MILAN PETROVIĆ;  
VITOMIR KONSTANTINOVIĆ

*Serbia*

**NEW TECHNOLOGIES**

**Introduction:** Platelet concentrates for surgical use (Platelet-Rich Plasma - PRP and Platelet-Rich Fibrin - PRF) are blood extracts frequently used nowadays oral and maxillofacial surgery. Platelet-rich fibrin gel was first described by Choukroun in France. **Case report:** 25-year-old female presented with facial asymmetry. The treatment results are documented by history files, historical data, clinical and histological features of disease, photos before and after surgical treatment. The required quantity of venous blood (120ml) is drawn into the Syringes (12 syringes within 10 ml of venous blood) These 12 syringes are centrifuged using a table-top centrifuge for 15 min at 1500 rpm according to the newest protocol for preparing PRF). After centrifuge fibrin clot was separated and had been put in PRF kit in order to make PRF membranes. It requires 15 minutes. After that, the membranes were soaked in PRF exudate which is obtained by pressing in order to release growth factors from membrane into exudate. Membrane was incorporated into exudate for 15 minutes. It was followed by aspiration of the exudate. This PRF product is placed into the superficial muscular aponeurotic system (SMAS) and muscle layer in order to correct asymmetry. **Discussion:** It is the one of the first cases in the literature which describes using of PRF in the treatment of patient with facial asymmetry. It could be suggested that the use of PRF could be of importance in correction of facial appearance as additional treatment after bimaxillary surgery. Further studying is necessary order to improve our findings.

**PP 396** **SOCIOLOGICAL SURVEY AMONG THE BULGARIAN DENTISTS FOR THEIR READINESS TO USE SPACE MAINTAINERS .**

RADOVETA ANDREEVA; A. BELCHEVA; HRISTO BOZUKOV; NINA MILCHEVA;  
H. ARNAUTSKA

*Bulgaria*

**PAEDIATRIC DENTISTRY**

**Background:** The space maintainers are appliances that are used to prevent the lack of space after the early loss of primary teeth. About 7 % of children in the North-Eastern Bulgaria

between 5 and 9 years old are with prematurely extracted teeth. The usage of space maintainers could prevent some of the malocclusions in the future. The **aim** of the study is to research the awareness of dentists on the use age of maintainers in order to prevent malocclusions in the future **Methods and materials:** The study includes 100 dentists from the North -Eastern Bulgaria. Each of them field in questioner. The orthodontists were not included in this survey. **Results:** In this study it is found that only 14% of the Bulgarian dentists use space maintainers. About 70 % of them advised their patients to visit an orthodontist when there is a premature extraction of primary teeth and 16% don't take any measures. **Conclusions:** Due to lack of experience most of dentists avoid the usage of space maintainers as a part of the treatment of the children with an early loss of primary teeth. It leads to future complications, concerning occurrence of malocclusions.

**PP 397 INTRODUCTION OF NEW METHODS FOR PRECISE FABRICATION OF METAL FRAMEWORKS**

NEVENA KOYCHEVA

*Bulgaria*

**FIXED PROSTHODONTICS**

The need of accuracy of the prosthetic constructions led to the development of new laboratory technologies. Utilizing digital manufacturing technologies such as CAD/CAM and Selective Laser Sintering offers lots of advantages and possibilities. **Purpose:** Aiming to introduce the benefits of the new technologies – CAD/CAM and DMLS / Direct Metal Laser Sintering/, used not only for production of porcelain fused to metal restorations, but also for bars over implants and frameworks of model cast partial dentures. **Methods and materials:** Cad-Cam technology and SLS for producing metal-ceramic/resin restorations. **Clinical case:** Discussion: The components of CAD/CAM: 1.Scanner 2.Design software3.Processing devices. CAD/CAM milling is performed on either a solid block of titanium or Co-Cr; Advantages of Titanium. SLS : This high tech process builds up each framework in a series of successive thin layers /0,02 mm thick/. A high powered laser beam is focused onto a bed of powdered metal. **Results:** The patient's restorations correspond exactly to all esthetic, functional and prophylactic demands. **Conclusion:** The use of CAD/CAM and SLS gives us the chance to do our best.

**PP 398 THE ORTHODONTIC TREATMENT OF IMPACTED CENTRAL INCISOR TEETH - CASE STUDY**

SLOBODAN IVIĆ; LJILJANA STOJANOVIĆ ; SNEŽANA RADIŠIĆ

*Serbia*

**ORTHODONTICS**

**Introduction:** An impacted tooth is one that fails to erupt into the dental arch within the expected time. In most cases impacted tooth need to be surgically exposed and orthodontic-aligned into his normal physiologic position. The central incisor is the most frequently impacted incisor. The frequency of maxillary incisor impaction ranges from 0.06% to 0.2%. The most common causes of impaction are odontoma, supernumerary teeth and loss of space. **The aim** of the paper is to present extrusion of the upper right central incisor with the help of fixed orthodontic appliances. **Method:** A 12 year old male patient was diagnosed with impacted central upper right incisor which led to the

misaligned anterior teeth. Orthopan analysis has shown its presence in the maxilla. Necessary space was determined measuring the diameter of present central incisive. Maxillary dental arch was bonded using 0.022"x0.028" slot MBT bracket and 0.016" round nickeltitanium arch wire was placed, then replaced by 0.018" later by 0.016"x0.022" followed by 0.017"x0.025" and at the end by 0.017"x0.025" rectangular stainless steel arch wire. Surgical exposure of impacted central incisor was done and bracket was bonded on the labial surface. Orthodontic traction was started using elastic thread. Lower arch bonding was done. Final detailing was done. **Result:** The maxillary right central incisor was brought into an acceptable position. **Conclusion:** Impaction of maxillary incisors is rare. If eruption is delayed, it is necessary to begin orthodontic treatment and bring tooth in the correct physiologic position because of the function and aesthetics.

**PP 399** **STUDY REGARDING THE INFLUENCE OF DIFFERENT TOOTHPASTES ON SURFACE ROUGHNESS OF COMPOSITE RESINS**

SIMONA STOLERIU; GALINA PANCU; GIANINA IOVAN;  
CLAUDIU TOPOLICEANU; SORIN ANDRIAN

*Romania*

**RESTORATIVE AND ADHESIVE DENTISTRY**

The aim of this study was to evaluate the effect of three commercial whitening toothpastes on surface roughness of a hybrid, microhybrid and nanohybrid composite resin. **Methods and materials:** Three composite resins (Valux Plus, 3M ESPE, Filtek Z 250, 3M ESPE, and Herculite XRV Ultra, Kerr) and three whitening toothpastes (Opalescence PF Toothpaste, Ultradent Products, Colgate Max White One Optic, Colgate Romania, Blend-A-Med 3D White, Procter&Gamble, Romania) were chosen for this study. Twenty-eight samples of each composite resin were prepared and were equally split in 4 groups: 7 samples were stored in distilled water (control group). In the three study groups the samples were subjected to 20,000 toothbrushing cycles, with a brush load of 200g using the three whitening toothpastes. The samples were submitted to roughness evaluation using atomic force microscopy. The results were expressed as root mean square roughness. **Results:** Statistically significant results were obtained when compared the surface roughness of all composite resins samples after brushing to control group (ANOVA and post hoc Bonferroni test,  $p < 0.05$ ). **Conclusion:** All the toothpastes tested in this study increased the composite resins surface roughness. The hybrid resin recorded the highest roughness after brushing, followed in descending order by microhybrid and nanohybrid composite resin.

**PP 400** **AUTOGENOUS BONE GRAFTING AND IMPLANT PLACEMENT OF ANTERIOR MAXILLA WITH ALVEOLAR DEFECT: A CASE REPORT**

SINAN ERTEM

*Turkey*

**ORAL SURGERY AND ORAL MAXILLOFACIAL SURGERY**

**Purpose:** The purpose of this study is to evaluate autogenous onlay bone grafting harvested from symphysis area on patient who has defect on anterior maxilla and insufficient alveolar width for rehabilitate with implant supported dentures. **Case Presentation:** 20 years old male patient was referred to our clinic for early lost of his tooth and has defect on the alveolus of

maxilla anterior. The patient was informed about surgery protocol before onlay bone grafting derived from symphysis area. Two pieces of block graft harvested from symphysis area and fixed to the edentulous alveolus with two mini screws for upgrading the horizontal width of the alveolar ridge. The patient waits 6 months after grafting for recovering the surgical site and conjunction with block graft and alveolar ridge. The patient is operated for implant surgery and before insertion the implant, both of two mini screws removed from grafting site. Then another 6 months waited for osseointegration of the implants. Healing cap for osseointegrated implant established and prosthetic procedure completed. **Results:** Symphysis block grafting for patient is very successfully merged and combined with alveolar ridge without any complications and widening the alveolar ridge has been done successfully. **Conclusion:** Autogenous block grafting method for patients, who has defect on the alveolar ridge or lacking on the alveolar structure for any reason, is palmy and has very good results especially before implant insertion.

**PP 401 BENEFITS IMPRESSION WITH AN OPEN TRAY AN COMPLETELY EDENTATIONS IN IMPLANT RESTAURATIONS**

VASILE NICOLAE; DANA ELENA DUMITRA; SILVIU NICOLAE

*Romania*

**ORAL IMPLANTOLOGY**

**Introduction:** In the implant prosthesis of the complete edentulous prosthetic field, the functional impression includes certain particularities concerning both the impression technique and the necessary materials. The aim of the presentation is to introduce the particular stages in the impression of the completely edentulous, when the implant prosthesis is desired, both in the fixed prosthesis and in the mobile one. **Material and method:** The study has been done on 45 patients, male and female, clinically and paraclinical investigated, who have had an implant treatment. After the osseointegration period the cases have been completed through prosthesis. Some of them have had a mobile denture on caps and on bars - out of financial reasons, and the rest have had a fixed denture with ceramic components. Each patient has had a research and study chart done which contains anatomo-clinical particularities information, ways of surgical approach, aspects of the postoperative evolution and the evolution after the completion of the implanto-prosthetic treatment. **Results and Discussions:** The studies on a period of 5 years after the prostheses operation indicate satisfactory results both for the patients with mobile prostheses and for those with a fixed one on implants. **Conclusions:** It seems that the survival rate of the implants is not quite influenced by the type of prostheses (fixed or mobile) but by the oral hygiene which represents one of the decision factors concerning the survival rate of the implants.

**PP 402 PERIIMPLANT INFECTIONS. THE THERAPY ATTITUDE**

VASILE NICOLAE; DANA ELENA DUMITRA; SILVIU NICOLAE

*Romania*

**ORAL IMPLANTOLOGY**

**Introduction:** The prosthetic treatment was really improved by using the dental implants, offering the chance for prosthesis exclusively on implants or mixt, in all type of edentations. The rate of success in time appears to be better at the healthy patients with a good oral status. **Purpose:**



The purpose is to underline the importance of the early recognition of the periimplant infection in order to establish the earliest treatment in the context of the treatment for support after implantation, and also to observe the rate of infection appearance at patients with local or general disabilities. **Material and method:** In order to obtain the appropriate results, we made the following: clinical and paraclinical study (dental X-ray, blood biology), and also, a histological exam of the periimplant tissues. **Results and Discussions:** To strongly reduce or to avoid some of the mechanic or biological complications it is necessary to do the local and general examination clinical and paraclinical, very detailed. In the production and progression of the infection are involved besides the local microbial colonization, other specific factors which are connected to patient and to the mechanic overloading. **Conclusions:** In the conditions of using an increasing number of implants with a long standing function, in the maintenance implant therapy, it is necessary a careful monitoring of the patients for an early recognition of the periimplant diseases and to treat them at the right moment. The chronic systemic diseases also need early recognition and control.

**PP 403 MISUSAGE OF REMOVABLE PARTIAL DENTURE CAUSES CONJUNCTION TO THE ALVEOLAR MUCOSA: A CASE REPORT**

SINAN ERTEM

*Turkey*

**ORAL SURGERY AND ORAL MAXILLOFACIAL SURGERY**

**Purpose:** The case reported for evaluation of postoperative information about using removable partial denture which has been given to patients who has partial edentulous area and intrigue the clinicians what can cause misuse of removable prosthesis. **Material and method:** Merged partial denture to the alveolar mucosa is dissected under local anesthesia. Aseptic conditions provided and a scalpel used for dissection the removable partial denture from alveolar mucosa. After surgical procedure the wound was closed with 3.0 vicryl suture and one week later suture had removed. The healing process was completed successfully and follow up period was 36 months. Three weeks after surgical treatment the new partial denture was prepared. **Results:** A very well response had obtained from alveolar mucosa after applied minor dissection surgery and wound had healed successfully after surgery. **Conclusion:** The clinician who performs removable partial denture or total denture to their patients have to be thoughtful and carefully informs their patients about utilization protocols of their prosthesis.

**PP 405 MISUSAGE OF FIXED PARTIAL DENTURE: A CASE REPORT**

SINAN YASIN ERTEM; FETHI ATIL; ILGI BARAN

*Turkey*

**ORAL SURGERY AND ORAL MAXILLOFACIAL SURGERY**

**Purpose:** Periodontal diseases are one of the most seen intraoral problems. The progress of periodontal diseases may cause mobility, luxation and even avulsion of the teeth. Especially patients with lower level socio-economic status blow off these diseases and postpone the treatment procedures. To avoid these problems, patients have to be well informed about periodontal diseases. **Case Report:** 45 years old male patient was referred to our clinic for rehabilitation of dental restorations. Clinic examination shows that patient's abutment teeth lost their periodontal support

and could be removed from their alveolar socket whenever patient need. After examination the patient was informed about not to use his fixed partial denture anymore then alveolar sockets were curettaged and sufficient oral hygiene motivation obtained. After 10 days dental sockets covered by alveolar mucosa properly and had healed satisfactorily. **Conclusion:** Patients has to be educated about having routine dental controls. The importance of dental care must be underlined especially for the people who have low socio-economic status.

**PP 407 MODIFICATIONS IN THE STANDARD PROTOCOL OF PERIAPICAL SURGERY. A CASE SERIES STUDY.**

THANASIS KARAMPASIS; CHRISTINA RAZCHA; CHARIS BELTES

*Greece*

**ORAL SURGERY AND ORAL MAXILLOFACIAL SURGERY**

Periapical surgery is chosen as the treatment plan in cases where non-surgical retreatment of endodontic therapy fails or is not feasible. Apicoectomy of the last three millimeters of the apex, root-end preparation and retrograde obturation are key steps for a successful outcome. In specific cases though, there is a possibility that some of the above steps need to be modified and surgical endodontic treatment is completed without being performed. **Aim:** The aim of the current study is to present a series of cases in which certain modifications are made on the periapical surgery protocol, due to anatomical and morphological varieties in each case. **Materials and methods:** Three indicative cases of periapical surgery are presented where: a) only retrograde obturation was made, without resection of the apex b) selective resection, retrograde obturation of the buccal roots of a maxillary first molar and c) retrograde preparation more than 3 millimeters in the root canal **Conclusions:** In individual cases it is possible that some of the key stages of periapical surgery can be amended without adversely affecting the final prognosis. Cases with pre-existing unfavorable crown to root ratio, sizeable posts, proximity of the periapical area with anatomical structures that involve a high invasive risk (inferior alveolar nerve and sinus), roots with incomplete development of the apex, cases of external root resorption and also with inadequate or calcified root canals are some cases that may require some modifications.

**PP 408 A NEW MODIFIED LASER PROCEDURE FOR MONOLITHIC TRANSLUCENT ZIRCONIA SURFACE**

IPEK GULDAS; ESRA TALAY; ISA YONDEM; HAMDİ SUKUR;  
ABDULLAH KEPCEOĞLU

*Turkey*

**FIXED PROSTHODONTICS**

**Introduction:** Zirconia is a nonetchable material because of its polycrystalline microstructure. Lately, to increase the bond strength between resin and ceramic surfaces, several studies have been done using different techniques as airborne-particle abrasion, tribochemical silica coating, hydrofluoric acid and laser treatment. The purpose of this study was to compare and evaluate the effects of various "Femtosecond (FS) Laser" power on surface roughness of 4 different monolithic translucent zirconia. **Material and methods:** 120 monolithic translucent zirconia (Lava Plus, Prettau, White Peaks and Supra) ceramic discs (10 mm diameter and 1,2 mm thickness) were

prepared according to the CAD-CAM technique recommended by the manufacturer instructions. Then, discs of each type of ceramic (n = 30) were randomly divided into three groups (n = 10), according to the surface treatments to be applied. Each specimen was scanned with one of different repetition times (1, 3 or 5 times) and average power (725, 525 or 325mW). The surface roughness of the specimens was evaluated using a profilometer (NanoMap LS, USA). The average values of these measurements were considered to be the Ra values. One-way ANOVA was used to analyze the data for significant differences. **Results:** One-way ANOVA indicated that surface roughness was significantly affected by the different repetition times and average power ( $p < 0.05$ ). The highest values were recorded for 725mW average power and 5X scanned specimens. **Conclusions:** The results showed that FS laser treatment produced it appears to be an effective method for bonding resin cement to monolithic translucent zirconia ceramic surfaces.

**PP 409** CALCIFYING CYSTIC ODONTOGENIC TUMOR: A RARE CASE REPORT

SINAN YASIN ERTEM; ESER BOLAT

*Turkey*

**ORAL SURGERY AND ORAL MAXILLOFACIAL SURGERY**

The calcifying cystic odontogenic tumor (CCOT) is an asymptomatic, radiolucent, rarely seen tumor. That represents a very small amount of odontogenic tumors and cysts. We report a female patient, admitted to our department with a history of swelling in the mandible premolar region. The lesion was asymptomatic, radiolucent, well-circumscribed and unilocular in the radiographic examination. In this case we emphasize and evaluate surgical treatment of a CCOT in the mandibular premolar region. The excisional biopsy was performed and the histological examination revealed that calcified ghost cells which lost their nucleus and intracellular hyalin could be seen. There was no complication and no recurrence occurred after surgery during 6 month follow up period.

**PP 412** ORAL HEALTH-RELATED QUALITY OF LIFE IN ROMANIAN PATIENTS WITH RHEUMATOID ARTHRITIS AND PERIODONTITIS

ROXANA-ELENA TRISTIU; BIANCA DUMITRU; LIANA LASCU; ANTON SCULEAN;  
RALUCA COSGAREA

*Romania*

**PERIODONTOLOGY**

**Aim:** The aim of the present study was to determine the oral health-related quality of life (OH-QoL) among patients suffering of rheumatoid arthritis (RA) and periodontitis (PA) as compared to RA patients. **Methods:** 17 patients diagnosed with RA and moderate to severe chronic periodontitis (RA-PA) and 17 patients with RA were evaluated for their OH-QoL by means of the OHIP-14 questionnaire; visual analog-scale (VAS) was used to determine the pain-level. Furthermore, all patients received comprehensive dental, periodontal and rheumatologic clinical examinations. Comparisons between the two patient groups were performed for all investigated parameters using Wilcoxon ranked test. **Results:** All patients presented a disease activity score (DAS-28) for RA  $\geq 3.2$ , with no statistical significant differences between the two patient groups ( $p < 0.05$ ) and no demographic intergroup differences (RA-PA:  $53.62 \pm 10.69$  years, 13 female, RA:

52.11±13.52, 14 female). 17.64% of all patients admitted permanent pain (ranging up to 10 on the VAS) with no intergroup differences (RA-PA: 17.64%, RA: 11.76%,  $p < 0.05$ ); 14.70% patients showed physical impairment (VAS up to 10), RA-PA patients admitting physical disability in a statistical significant higher number (23.52%) as compared to the RA patients (5.88%). Psychological impairment was registered uniformly in both groups (11.76% in RA-PA vs. 5.88% in RA). **Conclusion:** Periodontitis may negatively influence the quality of life of patients with rheumatoid arthritis, especially the physical abilities. Further studies with higher number of patients are needed to investigate the influence of PA on the QoL of RA patients.

**PP 419 ERUPTED UNILATERAL SUPPLEMENTAL PRIMARY MAXILLARY LATERAL TOOTH IN A NON-SYNDROMIC CHILD.**

BARIS KARABULUT; ALPER KAYA

*Turkey*

**PAEDIATRIC DENTISTRY**

Supernumerary tooth which resembles tooth shape and supplements for occlusion is called as supplemental tooth. In the primary dentition, it has been reported that the majority occur in the maxillary lateral incisor region. The prevalence in the primary dentition and statistics mentioned in the dental literature are inconsistent. This may be because of spacing that often present in the primary dentition and may allow supernumerary teeth to erupt into reasonable alignment and remain unnoticed. Supplemental teeth may cause esthetic problems, delayed eruption and crowding. A girl aged 2 years and 8 months was referred concerning the presence of a supernumerary right primary lateral appearing distal to a lateral incisor. On examination, extra-orally there were no obvious abnormalities. There was no family history of congenital anomalies. Generally the treatment of such teeth has been reported to be depended on their type, position and possible complications detected in clinical and radiography examination as supernumerary teeth in primary dentition may superseded by extra teeth in the same location in the permanent dentition. Unilateral persistence of a deciduous incisor, failure of eruption of a permanent incisor, a wide diastema, particularly aberrations in the eruptive pattern should alert the clinician to the possible presence of supernumerary teeth and indicate appropriate radiographic investigation. Root development of the maxillary incisors should be complete by the age of ten years. This patient will be kept under observation till the eruption of permanent incisors during early mixed dentition.

**PP 421 INTRAORAL REPAIRMENT OF ALL-CERAMIC ZIRCONIA RESTORATIONS**

ANETA MIJOSKA; BILJANA KAPUSEVSKA; VESNA JURUKOVSKA;

NATASHA STAVREVA

*FYROM*

**FIXED PROSTHODONTICS**

**Background:** Due to constant demand for better esthetic, higher biocompatibility and strength, all-ceramic restorations are increasingly used. Veneered zirconia core for single crowns and bridges in frontal and posterior regions showed more fractures than metal-ceramic. When veneered porcelain is chipped without core fracture intraoral repair is best and fastest solution. **Methods and materials:** Zirconia has inert surface which is hard to condition with standard

procedures and zirconia primers and silanization is method of choice. We used two different primers Monobond Plus (Ivoclar Vivadent, Leichtenstain) and Rely X (3M ESPE, USA) on exposed zirconia surface for 60 seconds and air dried. Control group was restored without primers. When surface conditioning was done, restorative composite resin Tetric EvoCeram (Ivoclar Vivadent, Leichtenstain) was applied and light cured for 20 seconds. **Results:** Patients were checked on regular bases after first week, first month and every third month during the first year. Forty percent of repaired crowns in control group failed during the first year, only one repaired crown conditioned with primer Monobond Plus failed immediately after first month, while others were successfully restored and showed no damage in the period. **Conclusion:** Monobond Plus phosphoric acid group bond to zirconia surface, while methacrylate group bond with organic components of the composite and provide bonding. Rely X Ceramic Primer's silane provides chemical bonding, while organic part increases the wettability of ceramic surface and provides intimate micromechanical adhesion. Universal and Zirconia primers provide good composite adhesion and are method of choice for intraoral repairment.

#### PP 425 HOW DOES SMOKING INFLUENCE TOOTH COLOR

JULIJA ZARKOVA; KATERINA ZLATANOVSKA; ANA RADESKA- PANOSKA;  
KIRO PAPAKOCA; KATERINA FOTEVA  
FYROM

#### INTERDISCIPLINARITY

**Introduction and aim:** Smoking cigarettes is a major risk factor for many general and oral diseases. As a result of tooth discoloration this bad habit at first influence mainly on dental esthetics. The aim of this study was to find how does smoking affect tooth color characteristics value  $L^*$  and chromatic variables  $a^*$  and  $b^*$ ). **Material and methods:** The tooth color of 235 healthy patients was evaluated using intra-oral spectrophotometer ShadePilotTM (Degu Dent, Germany). Measurements were taken from the middle third of the left or right central incisors without caries, internal discoloration, filings or crowns. According the questionnaire two groups were formed, non-smokers 123(52,4%) and 112(47,6%) smokers. The collected data was statistically analyzed using ANOVA/MANOVA Factorial Anova (F). **Results:** There was statistically significant influence of smoking on tooth value  $L^*$  ( $F=7,7$  и  $p<0,01(p=0,006)$ ). Smokers have lower level of tooth value  $L^*$  and the Delta L between two groups was 0.66. There was no significant difference on chromatic variables  $a^*$  ( $F=0,84$   $p<0,05(p=0,36)$ ) and  $b^*$  ( $F=0,02$  и  $p<0,05(p=0,90)$ ) between smokers and non-smokers. **Conclusions:** Due to higher level of value  $L^*$  we can say that non-smokers has significantly more brighter and lighter teeth than smokers, but the difference in tooth color (since chromatic variables are not different in the two groups) generally came from the external yellow and brown discolorations from the nicotine and tar contained in cigarette smoke.

**PP 427 MARGINAL FIT OF SINGLE TOOTH ZIRCONIA COPINGS FABRICATED WITH DIGITAL AND CONVENTIONAL METHODS**

S. PARK; E. SHIN; M. VANG; H. YANG; H. LIM; K. YUN

*Republic of Korea*

**FIXED PROSTHODONTICS**

**Objectives:** Recent development of digital impression taking methods using dental scanner has eliminated risks of patient discomfort, dimensional changes, need for additional cast storage, and etc. The aim of this study is to analyze and compare marginal fit of zirconia coping fabricated from 3 types of dental scanners (I-Tero, Care stream, Trios), and conventional silicone impression. **Methods:** Abutment was prepared with a deep chamfer margin, buccal walls with sub-gingival margin, lingual walls with supra-gingival margin, and sub-gingival finishing line was exposed with gingival retraction cords using double cord technique. After taking digital impression of the abutment ten times utilizing 3 types of dental scanners(I-Tero, Care stream, Trios) respectively,10 zirconia copings were fabricated with CAD/CAM system. As a control group, silicone impression of the abutment was taken ten times and poured with type IV stone. **Results:** Absolute marginal discrepancy of MD and BL was the lowest in Trios (201.21±24.43) and the highest in I-Tero, and similarity was detected between Trios and I-Tero. **Conclusions:** 1. The full digital impression provides better fitting margin than the conventional method. 2, In general, Trios intraoral scanner showed a significant difference in marginal and internal gap. 3. Both methods showed overextended margin on buccolingual side generally. 4. Intraoral scanner groups showed larger horizontal gap than vertical gap.

**PP 429 PLAGICEPHALY INCIDENCE IN SCHOOLS OF THE REPUBLIC OF MOLDOVA WITH SPECIAL EDUCATIONAL NEEDS**

SILVIA RAILEAN; ION LUPAN

*Republic of Moldavia*

**PAEDIATRIC DENTISTRY**

**Purpose:** Cranial deformities of positional plagiocephaly (PP) or functional type are diagnosed at early age. PP incidence is determined in 1 of 300 newborns in 1974, and in 1996 was found in 1 of 60 newborns. The **aim** of the study was to evaluate the incidence of cranial deformations, including PP, in school children, in Republic Moldova. **Method:** The examination was conducted at the Department of Oral and Maxillofacial Paediatric Surgery, Pedodontics and Orthodontics. Schools of the Republic of Moldova with special educational needs were examined based on oral health program developed by the Department staff. The shape of the skull was examined manually and by application of bandages on the skull. **Results:** 2311 children were examined: girls - 36,8%, boys - 63,2%. Age 7 to 11 - 36,4%, and 12-18 years old - 64,8%. Number of children without cranial deformities - 79,6%, with craniostenosis - 1,2% , cranial deformities of functional type (PP) - 17,1 % , other deformities - 2,1. I and III types are the most frequently encountered deformities of functional type: 26,8% of 396 children with such deformities. In the research group the incidence of deformities is 1 to 5,8 children. **Conclusions:** The incidence of

patients with cranial deformities of functional type (PP) in older children was 17.1%. In the research group the incidence of cranial deformities of positional plagiocephaly is 1 to 5,8 children.

**PP 430 TREATMENT OF REVERSIBLE PULPITIS IN PRIMARY TEETH WITH INDIRECT OR DIRECT PULP CAPPING**

NINA MILCHEVA; ROSITSA KABAKTCHIEVA

*Bulgaria*

**PAEDIATRIC DENTISTRY**

**Background:** Vital methods for treatment of reversible pulpitis in permanent dentition may be adopted for pulp treatment in primary teeth as well because of new evidences about the ability of the primary dental pulp for reparation and regeneration. Odontoblasts and odontoblast-like cells are stimulated to produce new portions of hard dental tissue after covering the inflamed pulp with appropriate pulp capping material. The aim of this study is to compare the level of success between two different biological method used for treatment of asymptomatic pulpitis in primary teeth- indirect (IPC) and direct pulp capping (DPC). **Material and methods:** 20 primary molars were included in the study, all were diagnosed with reversible pulpitis, children were 4 to 8 years old. Ten of the cases received indirect pulp treatment, after deciding to leave a layer of demineralized dentin over the pulp and covering it with calcium hydroxide cement. Another 10 cases received complete caries removal after which a pinpoint pulp expose was observed. The pulp was covered with MTA. All teeth got compomer with adhesive system as a permanent filling. Cases were followed up clinically and radiographically for 2 years. **Results:** Six months after the treatment we had 100% and 90% clinical success of IPC and DPC respectively. At the end of follow up period (2 years later) it had 90% and 80% success of IPC and DPC respectively according to clinical and radiographic criteria. **Conclusion:** Both IPC and DPC are acceptable methods for treating reversible pulpitis of primary teeth.

**PP 431 INADEQUATE ROOT CANAL TREATMENT OF ADJACENT TOOTH : RISK FACTOR CAUSING PERIIMPLANTITIS? CLINICAL CASE REPORT**

SONJA LIVRINIKJ; BOJANA STEFANOVIKJ; KRENAR PAPRANIKU;  
ALEKSANDRA PIVKOVA VELJANOVSKADA; DARKO VELJANOVSKI  
*FYROM*

**ORAL SURGERY AND ORAL MAXILLOFACIAL SURGERY**

**Background:** Periimplantitis is a destructive inflammatory disease affecting soft and hard tissues surrounding dental implants. Periimplantitis may also have iatrogenic causes, mostly related to bad treatment planning. **Aim:** To discover to which extent inadequate RCT of adjacent to implant tooth negatively affects the osseointegrated implant. **Material and methods:** 45 yrs old female patient presented with periapical inflammation of tooth 22 and was diagnosed with periapical granuloma. The tooth was adjacent to the osseointegrated implant on site 23, in proper prosthetic position and a mesial abutment to a 3 unit bridge. Radiographic findings revealed insufficient root canal filling and periapical lesion in close proximity to the implant apex. The patient was given

instructions for antiseptic use, prescribed with peroral antibiotic and scheduled for apicectomy with retrograde filling of the tooth 22. After performing an esthetic buccal flap, pathological tissue was removed, root of tooth 22 was resected and retrogradely filled with MTA. Exposed implant threads were debrided with titanium curette and treated with 5% citric acid. The whole area was decontaminated with 0.2% chlorhexidine. A bovine bone xenograft was introduced to the site, without membrane. The flap was sutured with 4-0 polypropilene sutures. **Results:** Postoperative healing was clinically uneventful. Sutures were removed at 7 days postoperatively. Clinical and radiographic follow up was done at one and three months postoperatively, showing excellent results. **Conclusion:** Early treatment of periapical infections of teeth is important for preventing periimplantitis to adjacent implants. Inadequate root canal therapy of adjacent teeth may be an important iatrogenic factor for developing periimplantitis.

**PP 443** **ADVANCES IN TEACHING HEAD AND NECK SEMIOLOGY. A MULTIDISCIPLINARY APPROACH**

SILVIA CRISTINA TONE; GHEORGHE GH. BALAN; ADRIANA BALAN

*Romania*

**INTERDISCIPLINARITY**

Through their complex anatomical structures hosting part of the central nervous system, the major sensory organs and the oral cavity, the head and neck regions are seemingly challenging in what the clinical examination and regional assessments are concerned. The aim of our poster is to present an algorithm based on new techniques, especially designed in order to achieve optimal physical examination and history recording in day to day care. Professionals of both dental and general medicine would often encounter complex symptoms and intricate signs during the head and neck physical examination and history taking. All these require high medical and clinical skills in order to achieve a proper clinical investigation. Therefore, medical and dental teaching staff should make their students accustomed to special patterns of grouping and interrelating anatomy and physiology on the first hand and examination methods on the other hand. Multi-disciplinary assessment of the H(ead)E(yes)M(outh)E(ars)N(ose)T(hroat) method followed by complex investigation of prevention and counseling actions would be the best way to properly examine the head and neck regions. Numerous international studies investigated the best way to clinically assess the head and neck and serious debates were generated because of the multitude of disciplines involved. Our method promotes vigilance in examination, possession of good communication skills and general promotion of health, all these by following a dynamic, time effective and generally suited algorithm.

**PP 444** **CORRECTION OF A MIDFACE DEFICIENCY USING REVERSE HEADGEAR: A CASE REPORT**

MELIHA OSMAN; ZEHRA ILERI; KEMAL FERIZ

*Turkey*

**ORTHODONTICS**

**Aim:** The aim of this case report was to present the treatment of a skeletal Class III patient with midface deficiency using reverse headgear. **Material and methods:** 14 years old female patient



referred to the Department of Orthodontics. Clinic examination showed that the patient had midface and maxillary deficiency, negative overjet, mild open bite, mandibular posterior diastema. Cephalometric tracings were done pre and post treatment to determine the anatomic changes during the course of treatment. Initial cephalometric analysis showed skeletal Class III with  $SNA=79.1^\circ$ ,  $SNB=81.2^\circ$  and  $ANB=-2.1^\circ$ . Skeletal Class III malocclusion treated without surgical intervention using reverse headgear in the first stage of treatment and during the fixed appliance therapy, Class III intermaxillary elastics were used. At the end of the treatment, cephalometric analysis showed skeletal Class I malocclusion with  $SNA=82^\circ$ ,  $SNB=81^\circ$ , and  $ANB=1^\circ$ . **Results:** The sagittal depth of maxilla was increased and upper lip was protruded significantly. Better profile appearance was obtained by using reverse headgear after treatment. Angle Class I occlusion was achieved with an acceptable overjet and overbite. The results were aesthetically and functionally satisfying with a decrease in maxillary deficiency and mild open bite and an improvement in overjet. **Conclusion:** The pronounced anterior movement of point A demonstrates that using the reverse headgear positively affects the correction of the midface and maxillary deficiency and achieving satisfying aesthetically results.

**PP 445 ALVEOLAR RIDGE EXPANSION VIA BONE SPLITTING TECHNIQUE. A CASE REPORT**

GEORGIOS-ALEXANDROS VAKIRTZIAN; ALEXANDROS-PANTELEIMON KONGOIANNIS; ANASTASIA ZIGRIDIS; STILIANOS KARAMANIS

*Greece*

**ORAL SURGERY AND ORAL MAXILLOFACIAL SURGERY**

Male 64 years old, with edentulous area in 23-26 positions was referred for implant restoration. The CBCT showed sufficient bone height for implant insertion but the bone width of the ridge was narrow. Expansion of bony ridge with bone splitting technique was planned. A full thickness incision was created along the alveolar crest and two vertical incisions in the mesial and distal aspect and the flap was elevated buccally. A horizontal osteotomy was performed on the top of the alveolar ridge, followed by two vertical osteotomies mesially and distally. Subsequently three chisel with different widths were used in order to displace the buccal plate more buccally. The space that was created was filled with allogenic bone substitute (C+ TBS Austria), and the area was covered with collagen absorbable membrane (Remaix Matricel Germany). Seven months later the CBCT examination showed that the average width of the alveolar ridge in the positions 23, 24, 26, were 6 mm, 5.8mm and 5.2 mm respectively. The treatment plan is the placement of three implants in those positions with length of 13mm and diameter 3.75, 3.75 and 3.30 respectively. In this case it was not decided the simultaneous implant placement after the splitting procedure due to the fact that, the alveolar ridge was expanded not only on the top and in the middle portion, but also in the base portion. It was estimated that in this case simultaneous implant placement might have resulted in problematic primary stability of the latter.

**PP 447 THERAPEUTIC AND PREVENTIVE CHALLENGES IN DENTISTRY-CASE REPORT**  
LJILJANA BAJIC  
*Serbia*

**ORAL PATHOLOGY-ORAL MEDICINE**

Modern aspects of successful treatment and prevention in dentistry often require participation of the great number of specialists obeying important protocols. The aim of this report was to evaluate and determine possible deviation from the general rule in treatment and prevention of oral diseases, caused by low oral hygiene and low socio-economic status of the patient. This report documents oral clinical and radiographic feature of the 20-year-old female patient, who was referred to Clinic of Dentistry, complaining of the excrescence of gingiva above the upper lateral incisor 12, later confirmed as Epulis granulomatosis, by histopathological analysis after the biopsy was taken. After detailed clinical examination of the teeth and the oral cavity, supported by using of microbial, histopathological and radiographic diagnostic methods, the complex surgical, endodontic, periodontal, orthodontic and prosthodontic treatment was demanded, but, also, it was restricted by the poor oral hygiene and low socio-economic status. The improvement of the oral hygiene was successful and periodic control examination and motivation of the patient was needed. Necessary, but possible therapeutic methods were successfully used. Both, the therapist and the patient were content with attained results. Still, therapy was incomplete and deviated from the general rule because of the limiting factors. Considering these results, Oral care program, that excludes socio-economic status as a limiting factor in treatment and prevention must be provided as extenuating circumstance.

**PP 449 THE EFFECT OF DESENSITIZING AGENT ON MICROLEAKAGE OF ADHESIVE AGENT**  
ŞEYDA HERGÜNER SİSO; NAZMIYE DÖNMEZ; BÜŞRA KABADAYI  
*Turkey*

**RESTORATIVE AND ADHESIVE DENTISTRY**

**Aim:** This study evaluated the effect of calcium phosphate-containing desensitizing agent on the marginal microleakage of composite restorations bonded by multimode adhesive agent. **Material and method:** Class V cavities were prepared on the buccal surfaces of 40 extracted premolars at the cement-enamel junction and randomly divided into 4 groups of 10 each. The cavities were restored using Clearfil Universal Bond (CUB) + Clearfil APX (CAPX) and Calcium phosphate-containing desensitizing agent (Teethmate). In group 1, Clearfil Universal Bond (CUB/self-etch) was applied according to manufacturer's instructions. Group 2, after the application of Teethmate to the cavities, and (CUB/self-etch) was applied according to manufacturer's instructions. Group 3 Clearfil Universal Bond (CUB/total etch) was applied according to manufacturer's instructions, Group 4 after the application of Teethmate to the cavities and (CUB/total etch ) was applied according to manufacturer's instructions. After thermocycling, the specimens were stained with 0.5% aqueous basic fuxin dye and sectioned bucco-lingually. Dye penetration was then scored. The data were analyzed using the Kruskal-Wallis with Dunn tests and Mann-Whitney U tests. **Results:** There were no statistically significant differences found between in

any groups ( $p>0.05$ ). **Conclusions:** In composite restorations, desensitizing agents can be used to reduce post-operative sensitivity and we considered that clinical following must be done.

**PP 450** **ENDODONTICALLY TREATED TEETH RESTORED WITH INTERNAL AND EXTERNAL FERRULE: IN VITRO STUDY**

SASHO JOVANOVSKI; TRAJCHE JOVANOVSKI; PETER JEVNIKAR  
FYROM

**FIXED PROSTHODONTICS**

**Statement of problem:** The ferrule have a significant effect on fracture resistance of endodontically treated teeth (ETT), restored with posts/cores/crowns. **Purpose:** This in vitro study investigates fracture resistance of ETT prepared with ferrule (internal/external), and restored with two different dimensions of zirconia posts. **Material and methods:** A 8 groups of 12 maxillary central incisors were endodontically treated and restored with two different diameter (1.4mm-1.6mm) Y-TZPost(IJS-MF) with retention rings, core build-up and crowns (E-max press, Ivoclar). Groups A to D, (1.4mm) and E to H (1.6mm) represented teeth prepared with a 0/0mm, 0/2mm, 2/0mm, 2/2mm internal/external ferrule. The zirconia posts were cemented (Multilink Automix), embeded in acrylic resin blocks (ProBase Polymer/Monomer) and loaded (1mm/min) at an angle of 45° on Instron Machine 4301, until fracture. Fracture loads (N) and modes (repairable or catastrophic) were recorded. Two-way analysis of variance was used for statistical analysis ( $p<0.05$ ). Failure patterns were analyzed in the optical microscope Stereo Discovery V.8 (Carl Zeiss, Germany). **Results:** The fracture loads (N) were for the groups A-D: 503,07 ( $\pm 94.5$ ); 609,61 ( $\pm 64.9$ ); 725.49 ( $\pm 70.2$ ); 749.01 ( $\pm 104.7$ ); and group E-H: 515.05 ( $\pm 90.0$ ); 663.34 ( $\pm 79.2$ ); 698,88 ( $\pm 115.7$ ); 770.31 ( $\pm 174.5$ ). Failure patterns revealed non catastrophic failure in 75-75% (0/0mm); 85-85% (0/2mm); 75-85% (2/0mm) and 60-70% (2/2mm). **Conclusion:** With the limitations of this in vitro study, the prepared teeth with ferrule (internal/external) showed that the ferrule significantly increased the fracture resistance and didn't depend from the diameter (1.4mm-1.6mm) of the posts. The strength of ETT is significantly related to the prepared remaining tooth structure (ferrule).

**PP 451** **FIBER POSTS - SIGNIFICANT FACTOR IN AESTHETIC AND FUNCTIONAL REHABILITATION OF ENDODONTIC TREATED TEETH**

VESNA JURUKOVSKA SHOTAROVSKA; BILJANA KAPUSHEVSKA;  
SASHO JOVANOVSKI; ANETA MIJOSKA; DANIELA CVETANOVSKA STOJCEVA  
FYROM

**RESTORATIVE AND ADHESIVE DENTISTRY**

Esthetics, as one of the most valued world trends in modern dentistry, inspires the use of post-and-core systems that satisfy the patients' needs. FRC- posts, rapidly take over the lead in esthetic-restoration dentistry. The aim is to analyze the characteristics according FRC post systems of various products. How is their impact on the aesthetic and functional rehabilitation in endodontic treated teeth. As material we used fiber post system of 3M ESPE and Zirix-Nordin, with different diameter, which were applied in the treated root canals in different patients. Posts were

cemented and upgrade with composite material. Simple apply, appropriateness, length and diameter of the post, high modulus of elasticity, reduce the possibility of fractures in endodontic treated teeth and it satisfies the aesthetic needs of the patients. FRC posts, their transparency and elastic modulus similar to dentin sets primacy in the aesthetic and functionality rehabilitation of endodontic treated teeth.

**PP 452 EFFECT OF DENTURE BASE MATERIALS IMMERSION IN NATURAL AND ARTIFICIAL SALIVA**

ALEXANDRU-TITUS FARCASIU; OANA-CELLA ANDREI; MIHAELA PAUNA;  
CATALINA FARCASIU

*Romania*

**DENTAL BIOMATERIALS AND DEVICES**

Literature data attest the adsorption of salivary glycoproteins on the resin substrate of denture bases. This layer increases the surface energy of the substrate through improving its wettability. An increased wettability associated with the perfect fit principle and the maximum physiological extension of the denture base, provide a better retention of the dentures. Artificial saliva should represent a mandatory part of the prosthetic treatment in xerostomic patients. Six denture base materials: Acry Pol (x2 thermo-cure cycles), Eco Cryl Hot, Polyan, Biodentaplast, BMS 014, Superacryl, were investigated regarding wettability change following immersion in natural and artificial saliva (Xerostom, Biocosmetics Laboratioires). Natural saliva was collected from a single healthy patient and stored in optimal conditions during the experiment. The resin specimens were fabricated following manufacturer's indications and the immersion conditions were standardized. Contact angle measurements (using CAM 101, KSV Instruments) were carried out to evaluate wettability modification. The liquid used for measurements was natural saliva for a more appropriate reproduction of the biological phenomenon. The samples were dried before the contact angle measurement, which were made after 1 and 7 days for immersion in natural saliva and after 1 day for immersion in artificial saliva. Both salivas improve the wettability of the substrate. Artificial saliva has an almost uniform effect on all materials. Natural saliva improves wettability with slight variations depending on the substrate and duration of immersion.

**PP 453 THE EFFECT DESENSITIZIG AGENT ON MICROLEAKAGE OF ADHESIVE AGENT**

ŞEYDA HERGÜNER SISO; NAZMI YEDONMEZ; BÜŞRA KABADAYI

*Turkey*

**RESTORATIVE AND ADHESIVE DENTISTRY**

The effect of Calcium phosphate-containing desensitizig agent on the microleakage of multimode adhesive agent Şeyda Hergüner Siso<sup>1</sup>, Nazmiye Dönmez<sup>1</sup>, Büşra Kabadayı<sup>1</sup> Aim: This study evaluated the effect of calcium phosphate-containing desensitizig agent on the marginal microleakage of composite restorations bonded by multimode adhesive agent. Material-Method: Class V cavities were prepared on the buccal surfaces of 40 extracted premolars at the cement-

enamel junction and randomly divided into 4 groups of 10 each. The cavities were restored using Clearfil Universal Bond (CUB) + Clearfil APX (CAPX) and Calcium phosphate-containing desensitizing agent (Teethmate). In group 1, Clearfil Universal Bond (CUB/self-etch) was applied according to manufacturer's instructions. Group 2, after the application of Teethmate to the cavities, and (CUB/self-etch) was applied according to manufacturer's instructions. Group 3 Clearfil Universal Bond (CUB/total etch) was applied according to manufacturer's instructions. Group 4 after the application of Teethmate to the cavities and (CUB/total etch) was applied according to manufacturer's instructions. After thermocycling, the specimens were stained with 0.5% aqueous basic fuchsin dye and sectioned buccal-lingual. Dye penetration was then scored. The data were analyzed using the Kruskal-Wallis with Dunn tests and Mann-Whitney U tests. Results: There were no statistically significant differences found between in any groups ( $p > 0.05$ ). Conclusions: In composite restorations, desensitizing agents can be used to reduce post-operative sensitivity and we considered that clinical following must be done.

**PP 454 EVALUATION OF BOND STRENGTH BETWEEN ZIRCONIA POSTS AND COMPOSITE CORE BUILD-UP: IN VITRO STUDY**

ARIAN DACI; SASHO JOVANOVSKI; VESNA JURUKOVSKA-SHOTAROVSKA;  
ANETA ATANASOVSKA  
FYROM

**FIXED PROSTHODONTICS**

Zirconium oxide ceramics in contemporary dental prosthetics are often used as a replacement for metal dental alloys. The transparency of all-ceramic crowns is achieved with the use of ceramic posts. With procedure of sandblasting we prepared the surface, thus improving adhesiveness during cementation. The purpose of the in vitro study was to evaluate the effects of sandblasting on the adhesion of Y-TZP ceramics posts to the composite core build up materials. In this study, 24 experimental specimens were used and divided into 2 groups of 12 (sandblasted and as sintered-control). The experimental samples were build-up using resin material (MultiCore-Ivoclar Vivadent). The post / composite specimens were loaded at an angle of 90° degrees and loaded to fracture testing with in an Instron Testing Machine 4301 (Instron Corp., USA) at a crosshead speed of 1 mm/min, until fracture. The average stress values of the groups were statistically analyzed using 2-way ANOVA followed by the Tuckey test HSD ( $t < 0.05$ ). The results confirm the working hypothesis that the procedure of sandblasting improves adhesion between ceramic Y-TZP Cosmopost and MultiCore.

**PP 456 PINK ESTHETICS MANAGEMENT THROUGH PROSTHETIC REHABILITATION ON IMPLANT SUPPORTED RESTORATIONS**

MAGDALINI KOKKONI; DIMITRIOS KOLOVOS; DOMNA MOLDOVANI;  
SPIRIDON SILVESTROS; VASILEIOS CHRONOPOULOS  
Greece

**FIXED PROSTHODONTICS**

**Background:** Surgical reconstructive procedures have been used for the improvement of hard and soft tissue deficiencies, although, they do not always offer a predictable esthetic result.

Prosthetic rehabilitation of missing soft tissues is an alternative treatment solution. The materials that are used for gingiva imitation are ceramics, composite resin and acrylic resin. The aim of this poster is to illustrate four clinical cases, in which ridge deformities are treated by the use of pink materials. **Methods and materials:** The first case describes the restoration of the edentulous maxilla with implant supported fixed prosthesis (FDP) utilizing metal framework, porcelain for the teeth and composite resin as a pink material. Cases two and three illustrate two hybrid fixed prostheses in the mandible. The second reconstruction has a metal framework, denture teeth and acrylic resin for imitating the gums. The third has a metal framework dressed with composite resin materials. Tooth colored for the teeth and pink for the gingiva. Finally, the last case presents the rehabilitation of the edentulous mandible by the use of three implant supported porcelain fused to metal prostheses (FDP) with pink porcelain for gum imitation. **Results:** After three years of function all the prosthetic reconstructions are without any technical or biological complications. All patients are able to perform effective oral hygiene around implants and are very satisfied with the esthetics. **Conclusion:** The availability of pink materials has increased significantly and offers the restorative clinician a new armamentarium for improving esthetics on implant restorations, where soft tissue architecture presents discrepancies.

**PP 459 IMPLANT THERAPY IN THE PERIODONTALLY COMPROMISED PATIENT**

DIMITRA KANAKOUSAKI; IOANNIS VOURO

*Greece*

**PERIODONTOLOGY**

The aim of this poster is to present cases with long-term outcomes of periodontally compromised patients (PCP), who received implant supported restorations. All cases were assigned to a supportive periodontal treatment program, aiming at the maintenance and good function of the implant born prosthesis. Periodontal and peri-implant therapy was carried out as needed during the follow up period. As far as the maintenance treatment is concerned, a full-mouth plaque score (FMPS) of <25% and full-mouth bleeding score (FMBS) <25% was set as the prerequisite for successful implant therapy. Overall, patients with a history of periodontitis presented a lower survival rate and a statistically significantly higher number of sites with peri-implant bone loss. Furthermore, periodontally compromised patients, who did not completely adhere to the SPT, were found to present a higher implant failure rate. This underlines the value of the SPT in enhancing the long-term outcomes of implant-therapy, particularly in subjects affected by periodontitis, in order to control reinfection and limit biological complications.

**PP 461 COMPARATIVE EVALUATION OF DIMENSIONAL CHANGES OF THREE COMMERCIALY AVAILABLE HEAT CURING RESINS**

ARMAND ALUSHI

*Albania*

**REMOVABLE PROSTHODONTICS**

**Aim:** The purpose of this study is to access the linear dimensional changes of three resins before and after curing. **Materials and methods:** Eighteen patients irrespective of age and sex were taken and three commercially available brands were procured. After the teeth arrangement on the

mandibular trial denture two pins were fixed in central fossae of first molar on both sides and one pin in the cingulum of right central incisor. Interacryl heat cure resin was use in group A, megadur was used in group B and vertex heat cure was used in group C. Linear measurements of the trial wax up before and after curing and before and after finishing and polishing were measured and compared. Collected data was analyzed with analysis of variance and 't' test at 96% level of confidence (p=0.05) **Results:** The maximum percentage changes were seen in cases of group A (interacryl) followed by group B and group C. Interacryl showed the highest percentage change i.e. 1.18% and vertex showed least percentage change of 0,37%. **Conclusions:** Shrinkage occurred after curing and after finishing and polishing, which varies significantly with the three commercially available heat cure acrylic resins. Among the three different brands group C(vertex) had the least linear dimensional changes after curing and after finishing and polishing, so that vertex could be the material of choice of fabrication of complete denture among the three brands.

**PP 463** **LOW LEVEL LASER THERAPY IN POSTSURGICAL TREATMENT OF GRAFTED SOCKETS**

ADRIANA MARIA MONEA; GABRIELA BERESESCU; FLORENTIN BERNEANU;  
SORIN POPSOR

*Romania*

**LASERS**

The present study investigates whether low level laser therapy (LLLT) can decrease the time needed for socket regeneration in sockets grafted with particulate allograft material covered with resorbable collagen wound dressing. Forty-six patients had extractions and sockets grafted; they were randomly divided in two groups (n=24), one receiving postoperative LLLT treatment, and the other without postoperative laser treatment served as control. The assessment of bone formation was done in both groups at several time intervals after surgery by histostomorphomeric analysis. Better results were obtained in the treated group, with the decrease of 50% in the time needed for socket regeneration. In conclusion, LLLT and LED photobiomodulation has the ability to speed up the healing time after the grafting in the extraction sockets. Histological evidence suggests that in about 60 days there is new bone formation in the sockets compared to a minimum of 120 days for the non LLLT treated sites.

**PP 465** **SIX ESTHETIC HORIZONTAL LINES OF SMILE**

LUELA ALUSHI; ARMAND ALUSHI

*Albania*

**ORTHODONTICS**

**Introduction:** Smile analysis is an important stage for the diagnosis, planning, treatment and prognosis of any dental treatment involving aesthetic objectives. The evaluation of the intrinsic characteristics of the smile is a necessary procedure to achieve consistent form in orthodontic treatments, which in turn makes it necessary to recognize the components and factors that affect these characteristics. at the end of the treatment it is very important to achieve an aesthetic smile so

that the orthodontic treatment was worth it. **Objective:** The objective of this work is to present six horizontal smile lines and their importance in obtaining the desired results in orthodontic treatments. They are: 1)diagram of facial aesthetic references 2)cervical line 3)incisal line 4)contact points line 5)papillary line 6)upper lip line and lower lip line conclusion: the analysis of the six horizontal smile lines facilitates the understanding of the intrinsic characteristics that interfere in the aesthetics of the mouth. Moreover, a harmonization of these lines gives each professional a higher possibility of success in their treatments that include aesthetic objectives. It is necessary to reach what we can do to achieve the wonderful smile although that evaluating the beauty is always objective.

**PP 467 SEVERITY OF PERIODONTAL DISEASE IN TYPE 2 DIABETES MELLITUS PATIENTS IN MURES COUNTY**

ADRIANA MARIA MONEA; BUKHARI CSILLA; LIA MARIA YERO EREMIE; K. IVACSON; A. CSINSZKA; GABRIELA BERESESCU  
*Romania*

**PERIODONTOLOGY**

Our objective was to study the prevalence and severity of periodontal disease in type 2 diabetes mellitus (DM) patients in Mures County. Fifty type 2 DM patients (Study Group) and fifty non-diabetic patients (Control Group) aged 35-75 years were included in the study. The study group was divided based on Glycated hemoglobin levels into well, moderately and poorly controlled. Relevant information regarding age, oral hygiene habits and personal habits was obtained from the patients. Diabetic status and mode of anti-diabetic therapy of the study group was obtained from the hospital records with consent from the patient. Community periodontal index (CPI) was used to assess the periodontal status. The mean CPI score and the number of missing teeth was higher in diabetics compared with non-diabetics, and was statistically significant ( $P<0.05$ ), indicating that prevalence and extent of periodontal disease was more frequent and more severe in diabetic patients. The risk factors like Glycated hemoglobin, duration of diabetes, fasting blood sugar, personal habits and oral hygiene habits showed a positive correlation with periodontal destruction, whereas mode of anti-diabetic therapy showed a negative correlation according to the multiple regression analysis. In conclusion, type 2 DM subjects manifested relatively higher prevalence and severity of periodontal disease as compared with non-diabetics. **Acknowledgement:** Internal research grant University of Medicine and Pharmacy Tg.Mures, financed by SC COSAMEXT SRL

**PP 473 SOFT TISSUE MANAGEMENT WITH FIXED PROVISIONAL RESTORATIONS**

EFTHALIA KOKLA; DOMNA MOLDOVANI; DIMITRIOS KOLOVOS;  
VASILEIOS CHRONOPOULOS; SPIRIDON SILVESTROS  
*Greece*

**FIXED PROSTHODONTICS**



**PP 477** **SIMULTANEOUS IMPLANT PLACEMENT AND BONE GRAFTING IN NON-CONTAINED BONE DEFECTS**

LUCIAN CHIRILA; CRISTIAN ROTARU; MIRCEA BALDEA; DAVIDE FARRONATO;  
IULIAN FILIPOV

*Romania*

**ORAL IMPLANTOLOGY**

**Background:** Hard tissue management during implant placement is a challenge for clinician especially in non-contained bone defects. **Aim:** The aim of this case series is to present surgical aspects for implant therapy and bone grafting in clinical situation where bone deficiency is present. **Methods:** Twenty-one patients with atrophic ridges received lateral ridge augmentations with particulate grafts placed around implants and protected with a customized titanium mesh. The following criteria were respected: - healthy patients, non-smokers or less than 5 cigarettes/day ; - non periodontal disease was adjacent to the limited teeth; - titanium mesh were positioned more than 1,5 mm from adjacent teeth; -vertical level of titanium mesh is not supposed to exceed the level of adjacent bone peaks; - autogenous bone or autogenous mixed with substitute grafting material is a must; -thick gingival biotype or soft tissue augmentation is a mandatory criterion of success; Between 4-9 months after the surgery (depending on the grafting material) titanium mesh were removed. **Results:** The treated defects were successfully regenerated. The three-dimensional contour of the compromised alveolus was reestablished using titanium mesh with rigid screw fixation by the means of implant cover screw or additional mini screws/internal sutures. 9 of the 21 treated sites were in the anterior esthetic zone. All the implants were functionally and esthetically restored by the means of dental crowns. **Conclusion:** Within the limit of this restricted study, the use of titanium mesh at the time of implant placement is a reliable option of bone grafting.

**PP 481** **HOSPITAL DENTIST VERSUS PRIVATE DENTIST**

AFRODITI CHALKIDOU

*Greece*

**HOSPITAL DENTISTRY**

**Background:** Hospital dentist must be skilled in all the knowledge and the clinical efficiency in order to be able to contribute to prevention and cure of oral diseases and problems in stomatognathic area. Hospital dentist is called to treat more than every private dentist special patients (patients with general, mental or contagious diseases, physical or mental disability and patients in emergency) as these patients are regularly referred to hospital because they need particular treatment. **Methods and materials:** A PUBMED search was conducted of papers using the following terms (hospital dentist, special care dentistry, patients with special needs). **Results:** As long as hospital dentist is the most responsible for patients with special needs, it is necessary to be able to recognize the general diseases which could cause complications during the dental cure and endanger patient's life. Therefore hospital's dentist education which has to be triennial according to international standards must include all the knowledge and clinical experience about general and contagious diseases, complications of every pharmacological treatment and treatment of the patients with physical or mental disability. **Conclusions:** Conclusively, the necessity for triennial

academic and clinical education is undisputed in order to be an efficient hospital dentist. The private dentist cannot deal with these patients with special needs because of the absence of specialization and required equipment. Finally, hospital dental care is a significant offer to patients but also to private dentists who refer their patients with special needs to hospital in order to receive special treatment.

**PP 482 COLOR STABILITY OF RESIN COMPOSITE MATERIALS**

NEADA HYSENAJ; MERITA BARDHOSHI; SUELA TABAKU; EDIT XHAJANKA;  
DITMIR BORIÇI

*Albania*

**FIXED PROSTHODONTICS**

**Introduction:** It is necessary to have information on the color stability of composite resin materials. **The aim:** The aim of this study was to evaluate the stability of resin composite materials stored in different solutions. **Material and methods:** Light-polymerizing resin, auto-polymerizing resin, dual-polymerizing resin specimens were produced and stored in red wine, chlorhexidine, black tea for 4 weeks. Color parameters were evaluated through a colorimeter before and after storage. **Results:** Red wine caused the most severe discoloration, followed by black tea with perceptible to clinically unacceptable discoloration. Colored mouth rinses discolored the materials to a lesser extent with clinically acceptable values. Dual-polymerizing resin adhesives showed a higher amount of discoloration. **Conclusions:** Current restorative and adhesive composite resin materials discolor over time under the influence of different storage solutions. The composition related to the polymerizing mode seemed to be a causative factor.

**PP 484 PROSTHETIC REHABILITATION OF A PATIENT WITH WORN UPPER TEETH AND EDENTULOUS MANDIBLE**

EDA OZDERE; MEHMET FATIH TUNCER

*Turkey*

**REMOVABLE PROSTHODONTICS**

**Background:** The restorations of worn teeth are difficult to treat because of limited remaining tooth structure. Full crowns that are used for the restorations of worn teeth usually provide good esthetic results. But the rehabilitation becomes more complicated when the other jaw is totally edentulous. **Materials and methods:** A 43-year-old woman was referred to Selcuk University Department of Prosthodontics complaining principally about the worn maxillary anterior teeth and lower edentulous mandible. Maxillary anterior teeth crown length was decreased because of old, incompatible mandibular anterior porcelain restorations. Two implants were placed in canine region of edentulous mandible and an overdenture with locator attachment was performed. The worn maxillary anterior teeth were restored with full crowns and then a conventional removable denture was made for maxillary prosthetic rehabilitation. **Results and Conclusion:** The use of implants and crowns, with satisfactory results in excessive wear situation

for a patient with limited finances, was described as an alternative treatment. The patient was successfully rehabilitated with acceptable esthetic results.

**PP 485 THE USE OF OPTICAL DETECTION SYSTEM IN EARLY DETECTION OF (PRE)MALIGNANCIES: A SYSTEMATIC REVIEW**

BRUNO NIKOLOVSKI; ANA MINOVSKA; DANICA POPOVIC-MONEVSKA;  
MIRJANA POPOVSKA; VERA RADOJKOVA-NIKOLOVSKA  
FYROM

**ORAL PATHOLOGY-ORAL MEDICINE**

**Background:** Fluorescence is used in the life sciences as a non-destructive way of tracking or analyzing biological molecules by means of fluorescence. Some proteins or small molecules in cells are naturally fluorescent, which is called intrinsic fluorescence or autofluorescence. Autofluorescence is the natural emission of light by biological structures when they have absorbed light, and is used to distinguish the light originating from artificially added fluorescent markers. **AIM** To evaluate the effectiveness of the device that utilizes the principle of autofluorescence as adjuncts in the detection of oral cancer and oral potentially malignant disorders (OPMDs). **Methods:** A systematic review of the published literature to evaluate the effectiveness of the the VELscope™ as aid in the detection of oral cancer and OPMDs. **Results:** Thirteen primary studies published between 2004 and 2014 satisfied our criteria for selection. Processed studies testify a sensitivity of 95.9% and specificity of 96.2% in a training set of 46 subjects, and with a sensitivity of 100% and specificity of 91.4% in a validation set of 21 subjects. **Conclusions:** The VELscope™ system, is a simple, non-invasive test of the oral mucosa, which can help the clinician to find oral precursor malignant lesions and has potential to augment oral cancer screening efforts in community settings. We can fully recommend the incorporating of the VELscope™ into routine general dental practice, without compromising patient care.

**PP 488 DIAGNOSTIC VALUE OF TRIGEMINAL REFLEXES INDICES FOR CHILDREN WITH ANGLE CLASS III MALOCCLUSION**

VALENTINA TRIFAN; ION LUPAN; VICTOR LACUSTA  
*Republic of Moldavia*

**ORTHODONTICS**

**Aim of the study:** Evaluation of the diagnostic value (Se - sensibility, Sp - specificity) of the trigeminal reflexes, which display the functional status of the superior, middle and inferior brain stem regions of children with Angle Class III malocclusion. Fifty-eight children, aged 10-15 years, were evaluated in the study. The trigeminal reflexes were measured by electric stimulation of f. mentale, f. infraorbitale, f. supraorbitale and by surface electromyography of the masseter muscle (masseter inhibitory reflex - MIR), cervical semispinal muscles (trigemino-cervical reflex - TCR) and of the extraocular muscles (blink reflex - BR). We have determined the following diagnostic values for MIR (Sp - 85.5%, Se - 81.2%); TCR (Sp - 40.4%, Se - 48.5%) and BR (Sp - 58.3%; Se - 49.2%). The trigeminal reflexes are more informative than classical surface electromyography (Sp -

42%, Se - 30%). Our results show that MIR can be used as a presymptomatic test of trigemino-trigeminal disorders in the absence of pain syndrome. We proved that MIR changes are statistically significant ( $p < 0.05$ ) in sensorial disorders during the orthodontic treatment. The association of the trigeminal reflexes (MIR+TCR+BR) has increased the diagnostic value (Sp - 87.5%, Se - 83.4%). Usage of MIR during diagnosis and treatment of children with Class III malocclusion, allowed treatment individualization, occlusal function monitoring and assessment of occlusion rehabilitation efficiency.

**PP 489 PREDICTION THE TENDENCY OF IMPACTION OF MAXILLARY PERMANENT CANINES - METHOD OF ARNAUTSKA-KRUMOVA**

IVAN BACHVAROV; HRISTINA ARNAUTSKA

*Bulgaria*

**ORTHODONTICS**

**Introduction:** Clinical implication of prediction protocol of angulation and metric analysis method according to Arnautska-Krumova. **Aim:** To present 2 clinical cases approving the importance of early diagnosis of the tendency of primary canine impaction. **Methods and materials:** The method of evaluation of the position of canines, due to surrounding teeth and bone structures over panoramic radiograph. Protocol of angulation and 5 degrees scale of metric analysis are used to describe the position of permanent canines in order to predict the tendency of impaction. **Case 1:** 9 years old boy. Prediction of canine impaction. Assessment of angulation of permanent UL canine due to permanent UL incisor and primary canine shows a high probability of impaction. Extraction protocol is applied. **Case 2:** 8 years old boy. Is showing the clinical use of prediction method and application of extraction protocol in cases of canine impaction. **Conclusion:** Early diagnosis and prognosis is important in orthodontic management of impacted canines.

**PP 490 PERIODONTITIS-ORGAN (HEART)-TARGET CONCEPT - MODERN PARADIGM IN PERIODONTOLOGY**

VICTOR LACUSTA; ION LUPAN; VALERIU BURLACU; VALERIU FALA;  
GHEORGHE BORDENIUC

*Republic of Moldavia*

**PERIODONTOLOGY**

**Background:** The association between the periodontitis and systemic diseases, especially the cardiovascular diseases is supported by various recent findings. A new method, the ECG dispersion mapping is used to identify preclinical ischemic myocardial signs (PIMS). In order to further research the subject, it's imperative to establish the correlations between chronic periodontitis and PIMS. **Materials and methods:** Ninety-four patients with moderate and severe chronic periodontitis (aged between 25-58 years) participated in the study. Periodontitis was diagnosed by clinical and radiological exam. ECG dispersion mapping was used to identify preclinical ischemic myocardial signs (PIMS). Several tests were conducted (masticatory test, oral hygiene test) for identifying various correlations. **Results:** We have observed the following

correlations: between PIMS and periodontitis severity ( $R_{xy} 0.75, p < 0.001$ ); PIMS – periodontitis duration ( $R_{xy} 0.59, p < 0.01$ ), PIMS – patient's age ( $R_{xy} 0.42, p < 0.05$ ); PIMS – systolic blood pressure ( $R_{xy} 0.46, p < 0.05$ ). The study allowed us to propose the periodontitis-organ(heart)-target concept, based on the following arguments: PIMS appear in 85% of patients with signs of chronic periodontitis; PIMS reduction/disappearance after efficient periodontal treatment; PIMS worsen during elevated functional loading (masticatory test); PIMS show a phasic behavior (worsening during the first minutes/hours after conducting a test) with later improvement after several hours/days; correlation of chronic periodontitis duration with the level of PIMS expression. **Conclusion:** In order to optimize the diagnosis and treatment of chronic periodontitis, it is reasonable to identify PIMS for an efficient prophylaxis of myocardial disorders.

**PP 491** **EARLY IDENTIFICATION OF BRUXISM SIGNS AND SYMPTOMS FOR PREVENTION OF TEMPOROMANDIBULAR DYSFUNCTIONS**  
VALERIU FALA; VITALIE GRIBENCO; LILIAN NISTOR; VITALIE PANTEA;  
IULIAN URSU  
*Republic of Moldavia*

#### REMOVABLE PROSTHODONTICS

**Background:** Recent data shows that bruxism is widespread, affecting between 6-20% of adult population and 70% for patients with temporomandibular dysfunctions. It's imperative to identify early bruxism signs and monitor the parameters of bruxism episodes in order to prevent the temporomandibular dysfunctions. **Materials and methods:** Twenty-three patients (18 m, 5 f, age between 32-52 years) with signs and symptoms of night bruxism were examined and selected for this study. Patients have taken a behavioral questionnaire. The methodology of the morpho-functional clinical exam of the stomatognathic system was made in accordance with a systematized scheme of examination. The following paraclinic exam methods were used: x-rays, condylography, radiological cephalometry, functional-instrumental diagnosis on study models. **Results:** Particularities of night bruxism that associated it with the appearance of temporomandibular dysfunctions are: the average duration of 12 minutes/night with 30s long episodes; dental wear pattern observed in excentric mandibular positions; behavioral questionnaire results with predominance of type A behavioral personality. **Conclusion:** Early identification of the bruxism signs and symptoms has allowed the planning of efficient therapeutic measures in order to reduce the bruxism episodes and to prevent the appearance of temporo-mandibular dysfunctions.

**PP 492** **TREATMENT OF AN ORAL PREGNANCY TUMOUR: A CASE REPORT**  
MEHMET FATIH TUNCER; ILKNUR TUNCER  
*Turkey*

#### ORAL PATHOLOGY-ORAL MEDICINE

Oral pregnancy tumor (PT) (also known as a "Granuloma gravidarum," or "Pregnancy tumor") is a primarily oral disease which appears in the mouth as an overgrowth of tissue due to irritation, physical trauma or hormonal factors. PT tends to occur more frequently during the second and third trimester among %5 of the pregnancies. The growth is typically seen in young

adults, it may occur at age, especially with poor oral hygiene. Females are more susceptible to PT than males because of the hormonal changes during puberty, pregnancy, and menopause. The **aim** of this case report is to present the treatment procedure of the patient diagnosed with pregnancy tumor. **Materials and methods:** A 24 year-old female patient was referred to Selcuk University, Department of Oral and Maxillofacial Surgery after her 4th pregnancy with a complaint of growth in gingival tissue in the upper anterior area of oral cavity. Clinical examination revealed a 2cm x 3cm sessile rubbery nodular mass covered by smooth red mucosa with bleeding tendency between the upper incisor teeth. The lesion was removed and histopathological examination revealed the diagnosis as pregnancy tumor. **Results and Conclusion:** Treatment considerations for pregnancy tumor, a conservative approach is recommended. In absence of significant esthetic or functional problems or both, the lesion should not be excised because it has tendency for recurrence.

**PP 494** COMPARISON BETWEEN THE RETROMANDIBULAR APPROACH VERSUS MODIFIED SUBMANDIBULAR APPROACH IN CONDYLAR PROCESS FRACTURES

LUCIAN CHIRILA; CRISTIAN ROTARU; IULIAN FILIPOV

*Romania*

**ORAL SURGERY AND ORAL MAXILLOFACIAL SURGERY**

Condylar process fractures are one of the most common fractures of the jaws. The lack of anatomic reduction, especially in the subcondylar area and condylar neck area can lead to complications and permanent sequellae. **Purpose:** To compare the outcome of two different treatment approaches for open reduction with internal fixation: the retromandibular and submandibular approach. **Materials and method:** The subcondylar and condylar neck fractures (especially low condylar neck) were treated by open reduction with internal fixation using the retromandibular and modified submandibular approaches. The location of the plates was determined by the tensile strain lines. We usually place two plates in a triangular fashion. The surgical access to the bone and thus the easiness of osteosynthesis were analyzed. The functional status/occlusal outcome, interincisal opening and patient satisfaction were also taken into consideration. **Results:** 16 subcondylar and condylar neck fractures were included in the study. In all 16 cases the retromandibular (transparotidian) and modified submandibular approaches were used. **Conclusion:** In both surgical approaches the interincisal deviation immediately after surgery was present and because of it the use of guiding elastics was necessary. Transient facial nerve palsies were comparable in both procedures. This two approaches provide the same osteosynthesis outcome, but the modified submandibular facilitate greater bone exposure and thus is useful in more complicated cases.

**PP 496** NON NUTRITIVE ORAL HABITS IN PRESCHOOL-AGED CHILDREN  
AFRODITI CHALKIDOU; EIRINI ATHANASIADOU\*; VICTORIA ADAMIDOU

*Greece*

**PAEDIATRIC DENTISTRY**

The **aim** of this report is to present the non-nutritive oral habits in preschool-aged children (thumb sucking, use of a pacifier, lip sucking, nail biting, object biting, tongue thrust, bruxism,

mouth breathing and self-injuries oral habits) and to present the recent opinions of the bibliography about the appropriate treating of oral habits in preschool-aged children. **Methods and materials:** A PubMed search was conducted of papers published between 2010 and 2015 in the English language using the following terms (oral habits, thumb sucking, pacifier, nail biting, lip sucking, tongue thrust, bruxism, mouth breathing) results: non-nutritive oral habits in preschool-aged children show up more than 65 per cent in children in industrial countries. The most frequent of these oral habits are thumb sucking and use of the pacifier. There is no significant difference among the two sexes. Regarding the appropriate treating, behavior managements, reduction of the abidance of the finger or the pacifier in the oral cavity and oral devices are indicated. **Conclusions:** the importance of effects of oral habits depends on the frequency, intensity and duration of the habit. Interception of the oral habit before the age of five does not induce serious permanent disorders in mixed dentition. If these oral habits continue long after the age of five the intervention of a pediatrician is recommended. Finally, if there is genetic disposition, the disorder will show up regardless the presence of the oral habit.

**PP 497 THE EFFECT OF PRE-ORTHODONTIC FORCE APPLICATION ON PERIODONTAL TISSUE FOR REPLANTATION**

JIN-HYOUNG CHO; KI-HEON LEE; KYUNG-MIN LEE; HYEON-SHIK HWANG;  
*Republic of Korea*

**ORTHODONTICS**

**Aims:** A transplantation of tooth has been a major alternative approach to replace missing or hopeless tooth. It was known that the periodontal ligament act as critical part for healing in transplantation. The purpose of this study is to investigate the effect of the application of orthodontic forces to the donor teeth on the periodontal healing after transplantation. **Material and methods:** Replantation of both maxillary first molars after application of orthodontic force for 7 days to the left maxillary first molar was done in sixty 7-week-old Sprague-Dawley rats. A resin-wire fixation was performed for retention. After 1, 2, 3, and 4 weeks from replantation, bone block with maxillary first molar was taken for analysis. Hematoxylin and eosin stain was conducted for the histologic analysis, and Polymerase chain reaction (PCR) & Real-time PCR was performed for 10 mRNA related bone remodeling and periodontal ligament regeneration. **Results:** The application of orthodontic force for 7 days prior to replantation increased velocity of new attachment of the periodontal ligament and activated many chemokines (CXCL2, CCL, MMP, IL-24, RANKL, OPG, Amelx, SOX, Runx2), especially in 1 and 2 weeks. **Conclusion:** It is assumed that the activated periodontal ligament cells could be remained in the donor teeth after preapplication of orthodontic force, and these could help the periodontal healing of transplanted teeth.

**PP 498** CONVENTIONAL ENDODONTIC THERAPY COMBINED WITH SURGICAL DECOMPRESSION IN THE TREATMENT OF RADICULAR CYST

ANCA MELIAN; MIHAELA SALCEANU; GIUROIU CRISTIAN; MELIAN GABRIEL

*Romania*

**ENDODONTOLOGY**

The **aim** of this study is to demonstrate that very large radicular cysts of endodontic origin can be treated by conventional endodontic therapy, combined with an additional treatment – surgical decompression. **Methods and materials:** The study followed four patients over two years. Each case was diagnosed with large radicular cysts but the surgical treatment (cyst enucleation) damaged the adjacent teeth and bone. To avoid this situation, a conventional endodontic therapy combined with surgical decompression was performed and gave positive results (healing). The protocol we respected was: biomechanical preparation, ultrasonic irrigation of roots canals, using sodium hypochlorite 3.5% and calcium hydroxide intracanal dressings. The surgical decompression has been carried out with latex tubing in place, irrigation with physiologic saline solution and chlorhexidine gluconate 0.2%. **Results:** Healing was further confirmed in all cases by radiological and clinical tests in a period of four months to a year, depending on the size of the cyst. **Conclusions:** The results are satisfactory even if the treatment did not lead to overall healing as important dimensional reduction of the lesion periapical surgery would involve addressing strict affected tooth, no neighbors or adjacent bone and teeth.

**PP 499** EVALUATION OF ORAL FUNCTION AND ORAL HEALTH AFTER REMOVABLE PARTIAL – CLINICAL STUDY IN FACULTY OF DENTAL MEDICINE IN IASI, ROMANIA

DAN NICOLAE BOSINCEANU; DANA GABRIELA BOSINCEANU; AMELIA SURDU; NORINA FORNA

*Romania*

**REMOVABLE PROSTHODONTICS**

**Introduction:** Tooth loss results in deterioration of functional, psychological and social status of an individual. Removable partial denture represents one of the major treatment modalities for the replacement of missing teeth. **Aim:** This study aimed to evaluate the oral function after removable partial denture therapy from patients perspective. **Material and method:** A total of 58 edentulous subjects were studied. All the subjects were given oral health impact profile -14 questionnaire before and one month after provision of removable partial denture. Before and after treatment responses were recorded on 5 point Lickert scale. The post treatment scores were compared with pretreatment baseline scores and improvement in oral functional problems were assessed. **Results:** 94% of the study group had problems before removable partial denture treatment, which improved in 50% of study population after therapy. **Conclusions:** Removable partial dentures had a positive impact on oral function in almost half of the population.



**PP 500 ASSESMENT OF PARTIAL DENTURE WEARERS SATISFACTION IN RELATION TO GENERAL AND LOCAL FACTORS**

DANA GABRIELA BOSINCEANU; DAN NICOLAE BOSINCEANU; ALEXANDRU BREZOESCU; NORINA FORNA

*Romania*

**REMOVABLE PROSTHODONTICS**

**Introduction:** Subjective assessment of partial denture is given by patient and patient's satisfaction is hardly to define. **Aim:** The aim of this study was to assess patient's satisfaction with retention, aesthetics, chewing, speech and comfort of wearing removable partial denture. Also, the aim of this study is to assess the influence of factors, such as previous wearing of denture, age, gender, marital status, level of education, presence of chronic disease and smoking habits on patient's satisfaction with therapy. **Material and method:** Study was done at Clinic and Department of Removable Prosthodontics, School of Dental Medicine in Iasi. In study were involved 75 patients who have removable partial denture. They filled out questionnaire with personal data about wearing of the denture, age, gender, marital status, level of education, presence of chronic disease, smoking habits. **Results:** According to our results, statistically significant difference was found between males and females for satisfaction with chewing. **Conclusions:** There is difference between patients of different gender in a level of satisfaction.

**PP 501 HISTOPATHOLOGICAL ASPECTS IN ORAL LICHEN PLANUS VERSUS LICHENOID REACTION**

ANA MARIA FILIOREANU; EUGENIA POPESCU; CRISTINA POPA

*Romania*

**ORAL PATHOLOGY-ORAL MEDICINE**

Lichen planus is a mucocutaneous genodermatosis often affecting oral mucosa, genital mucosa, scalp and appendages. Oral lichenoid reactions are versions of oral lichen planus that can be considered a pathological entity in itself or as an exacerbation of an existing lichen planus induced by drugs or dental material. This study conducted on patients of the Oral and Maxillofacial Surgery Clinic at the "St. Spiridon " Emergency Hospital in Iasi is a retrospective analysis of histological features of lichen planus versus oral lichenoid reactions, drug or allergy based, and it attempted to correlate them with their clinical symptoms. The results showed that in the case of lichen planus, the typical histopathological changes were: hydropic degeneration of epithelial cells in the basal layer, presence of colloid bodies, hyperkeratosis and predominantly lymphocyte chronic inflammatory infiltrate with deposits in the band. Histological features of lichen planus considered exclusion criteria: the absence of Civatte bodies, abnormal keratinization and hydropic degeneration of cells in the basal layer has confirmed the diagnosis of oral lichenoid reaction. The diagnosis was also supported by the presence of specific histopathological changes in connective tissue such as: heterogeneous inflammatory infiltrate rich in eosinophils in superficial and deep chorion, lymphoplasma cell chronic inflammatory infiltrate in focal perivascular position. The study showed some specific aspects allowing the differentiation of the two entities and it also revealed the need that other additional tests such as indirect immunofluorescence and patch test should be used.

Oral mucositis is one of the most frequent side effects of chematological treatment that could be the reason for infections, intense pain and ulcers that hinder feeding, swallowing and speech. The **aim** of the present study is to assess whether dentogingival status could be a predictor factor to incidence and severity of oral mucositis in patients with hematological diseases who receive treatment with chemotherapy. **Material and methods:** The study was carried out on 25 patients (range 8-15 years) admitted to the University Pediatric Clinic, Department of chematology, Skopje receiving treatment with polychemostatic therapy. A descriptive study was made, analyzing plaque index (PI) Silness-Löe, and gingival index (GI) Löe-Silnes, and evaluating their link, with the appearance of mucositis. The frequency of brushing teeth and use of additional means were determined with all patients. **Results:** The patients with high plaque (PI) and gingival (GI) indices during chemotherapy had a higher percentage of mucositis (71.4% and 62.5%) against those who had lower plaque indices. In the case of the PI, the differences were statistically significant ( $p=0.015$ ). Only 22.7% of the patients who brushed their teeth 3 times/day had mucositis, against those who did not brush, or brushed only once a day (71%), ( $p<0.05$ ). **Conclusion:** Gingival status could be an important factor related to incidence and severity of oral mucositis. Collaboration between dentists and hematologists is necessary, who, by carrying out oral hygiene programs, will bring improvement in oral health awareness and hence the general health.

The development of the study began with the controversy concerning extraction of premolar teeth and pretreatment and post-treatment of the facial profiles of patients. The decisions of extraction were based on a space analysis. They were compared with pretreatment and post-treatment profiles of the non-extraction group. The facial profile was evaluated after lower lip posture, chin prominence, profile line relationship and upper lip curl. **Results:** No significant results were found between the extraction and the non-extraction groups. The lip profile was more retrusive in the non-extraction group. Chin prominence was improved in the extraction group. Even if the extraction of permanent teeth is controversial it can create a good facial esthetic can ruin it.

**PP 505** **DIAGNOSIS AND TREATMENT OPTIMIZATION IN HERPETIC STOMATITIS**

DIANA UNCUTA

*Republic of Moldavia*

**PAEDIATRIC DENTISTRY**

here were assessed accuracy and specificity of different methods of herpetic stomatitis diagnosis in the out-patient dental clinics and diagnostic protocol was developed. For the first time cytomorphological criteria of modern diagnosis of acute and recurrent herpetic stomatitis were elaborated and the protocols of antiherpetic treatment were supplemented with remedies that lead to sustainable improvement and herpetic recurrence prevention. There were elaborated different herpetic stomatitis treatment programs to achieve sustainable recovery and prevention of herpetic recurrence, determined clinical efficiency of BioR remedy that can be applied both singly and in antiviral preparation combination, including its preventive use. The major importance consists in determined accurate and informative criteria for diagnosis of vesicular herpetic lesions in oral mucous cavity; there was assessed an accurate differentiation of herpetic infection from other viral or similar diseases.

**PP 506** **COMPARISON OF MICROLEAKAGE ON DIFFERENT RESTORATIVE MATERIALS AT CLASS II CAVITES: AN IN VITRO STUDY**

MELEK HILAL KAPLAN; YAHYA ORÇUN ZORBA; HATICE PARLAK

*Turkey*

**RESTORATIVE AND ADHESIVE DENTISTRY**

**Aim:** The aim of this study was to evaluate occlusal and cervical microleakage of Class II cavity, restored with different bonds, base and composite materials. **Materials and methods:** A total of 80 Class II (slot) cavities in 40 human molars were prepared. The cavities were randomly distributed among two groups according to adhesive system: Group 1; Clearfil SE Bond (Kuraray, Japan), Group 2; Clearfil S3 Bond (Kuraray) and each group was divided into for subgroups according to the application of base materials: Group A; SureFil SDR flow (Dentsply), Group B; EverX Posterior (GC), Group C and D; No base applied. A, B and C were restored with Clearfil Majesty Posterior Composite (Kuraray) with incremental technique; Group D was restored with Filtek Bulk Fill Posterior (3M ESPE) with bulk fill technique. Ten samples of each group were subjected to 500 cycles of thermocycling between 5-55°C. All the teeth were immersed in methylene blue for 24h and then left in tap water for 8h. **Results:** No statistically significant difference in microleakage scores emerged among bonds used ( $p>0.05$ ). At the occlusal microleakage no statistically significant differences were observed between the composite resin groups ( $p=0,079$ ). Although, cervical microleakage was significantly influenced by the composite ( $p<0.05$ ). **Conclusions:** Using bond type had no influence on marginal leakage at both the cervical and occlusal margins. Filtek Bulk Fill Posterior composite was better than Clearfil Majesty Posterior at cervical margin. Further in vitro and long-term clinical trials are needed to fully understand the performance of these materials.

## ENDODONTOLOGY

**Aim:** When examining dental trauma, upper incisors, in the group dental all most exposed to trauma because of their position and the condition is known to usually result in serious material loss at crown. To regain aesthetic and function, immediately adhering a fragment of broken teeth is a good alternative for emergency treatment. In this case report, treatment with bonding to the upper central tooth fragment crown fracture that occurs after trauma is described. **Case Report:** 21 year old male patient trauma fracture of the upper right central tooth was admitted to our clinic. By radiographic evaluation results, horizontal fractures were detected in the coronal third. After conventional root canal therapy, fiber post placed into the canal and the broken pieces are bonded to each other by using dual cure resin cement, finally esthetic restorations are completed with hybrid composite. **Result:** Complicated crown-root fractures which especially often encountered in anterior teeth can be successfully restored by using fragment the original tooth and with support of fiber-reinforced post system. This approach may be preferred is a alternative treatment because of ensuring adequate aesthetic, the treatment to be completed in a short time and more economical when compared to prosthetic approach.

## PERIODONTOLOGY

**Background:** Depending on the degree of periodontal disease, clinician may be faced with many problems such as malposition, mobility, longer clinical crowns, and aesthetic problems. This case report presents aesthetic rehabilitation of a patient with generalized chronic periodontitis. **Methods and materials:** In 2004, a 49-year-old male applied to Department of Periodontology at Kocaeli University, complaining about the severe periodontal disease and unaesthetic oral appearance. Detailed clinical and radiographic examination revealed horizontal and vertical bone loss, tooth mobility, gingival recession and longer clinical crowns. Full mouth scaling and root planning was performed for sites with probing depth (PD)  $\geq 5$  mm and bleeding on probing (BOP)(+). At recall visit, 5 mm PD was seen at the mesial surface of #23 and periodontal flap surgery was performed, #11, #12 and #22 were extracted. After surgery, a temporary prosthesis was placed. Seven days later, sutures were removed. The healing was uneventful. Two months later, fixed partial dentures were done for the upper jaw. Maryland bridge was planned for the anterior lower teeth in order to be more conservative and to splint lower teeth from right premolars to left premolars. **Results:** PD reduction and establishment of favorable occlusal relationship were achieved. The treatment recovered the aesthetic and the psychological health of the patient, the normal masticatory function and the speech. **Conclusion:** A satisfactory final result both for

clinicians and patient was obtained through the collaboration between a prosthodontist and a periodontologist. The patient is still at follow -up period.

**PP 510 THE CYCLIC FATIGUE RESISTANCE OF D-RACE AND PROTAPER RETREATMENT INSTRUMENTS IN CURVED ARTIFICIAL CANALS**

GAMZE TOPÇUOĞLU; H.SINAN TOPÇUOĞLU; AHMET AKTI

*Turkey*

**ENDODONTOLOGY**

**Aim:** To compare the cyclic fatigue resistance of D-RaCe and ProTaper rotary nickel-titanium (NiTi) retreatment files when used in curved artificial canals. **Methodology:** A total of 120 new D-RaCe DR2 and ProTaper D3 retreatment files were tested in artificial canals having 45° and 60° angles of curvature. Thirty instruments of each of the 2 file systems were tested in both angles of curvature (n = 30). The retreatment instruments were rotated until fracture to calculate the number of cycles to failure. The length of each fractured fragment was recorded. Mean values were calculated and analyzed using 2-way analysis of variance. **Results:** Among the instruments used in the canal with a 45° angle of curvature, there was no statistical difference between the D-RaCe DR2 and ProTaper D3 instruments (P > 0.05). Among the instruments used in the canal with a 60° angle of curvature, the D-RaCe DR2 retreatment instruments showed better cyclic fatigue resistance than ProTaper D3 instruments (P < 0.05). There was no statistical difference in the lengths of fractured fragments for either the D-RaCe DR2 or ProTaper D3 files used for either angle size (P > 0.05). **Conclusions:** This study showed that the D-RaCe DR2 instrument used in the artificial canal with a 60° angle exhibited greater cyclic fatigue resistance than did the ProTaper D3 files.

**PP 511 MASTICATORY FUNCTION IN PATIENTS WITH REMOVABLE PROSTHESIS- LITERATURE REVIEW**

ALEXANDRA MELANIA ONCESCU MORARU; CRISTINA TEODORA PREOTEASA; CATALINA MURARIU-MAGUREANU; CRISTINA-DIANA RIZEA; ELENA PREOTEASA

*Romania*

**REMOVABLE PROSTHODONTICS**

Edentulism, condition characterized by loss of all teeth, is most frequently treated by conventional dentures, treatment alternative recognized as having multiple short coming, among those being not adequately restoring the masticatory function. **Purpose:** The aim of this literature review was to evaluate the masticatory function and related aspects in edentulous patients, treated by different types of removable prosthesis, i.e. conventional dentures, teeth and implant supported overdenture. **Materials and methods:** A search of the literature in PubMed, from January 2010 up to January 2015, was conducted. A number of in 258 articles were identified, of which 67 on the masticatory function. Fourteen studies were selected and discussed. **Results:** Evidence, of low and moderate quality, suggest that overdenture, compared to treatment by conventional dentures, have better treatment outcome in terms of masticatory function restoration, patient satisfaction and ORQoL, probably linked to their better retention. **Conclusions:** There is moderate evidence that suggests implant overdenture have better treatment outcome compared to conventional dentures,

in terms of masticatory function restoration. However, more high quality research is needed in order to acknowledge how big difference these treatment alternatives make.

**PP 512 SEM ANALYSIS OF IMPLANT SYSTEMS DESIGNED FOR INCREASING REMOVABLE PROSTHESIS RETENTION**

DANIELA MIHAELA MEGHEA; CRISTINA TEODORA PREOTEASA;  
MIHAELA MARIN; ELENA PREOTEASA  
*Romania*

**REMOVABLE PROSTHODONTICS**

**Background:** Implant overdenture is a treatment alternative for complete edentulism that registers an increasing use, most probable because it ensures better retention compared to the most frequently treatment alternative, namely conventional complete denture. The **aim** of this study was to analyze by SEM (scanning electron microscopy) implant systems designed for increasing removable prosthesis retention from different manufactures. **Methods and materials:** Four implant systems designed for increasing removable prosthesis retention were selected, namely TSVB-MTX (Zimmer), MiniSky1 (Bredent), Implantium (Dentium) and MDI (3M ESPE). SEM and EDS analysis was performed. **Results:** The commercial products analyzed present various surface characteristics, which most probably influences the osseointegration process. EDS indicated dental implants were made from both pure titanium and titanium alloys, namely Ti-Al-V, and the matrices were made from titanium and stainless steel alloys. **Conclusions:** Dental implant systems designed for increasing removable prosthesis retention, from different manufactures presents variable morphological and chemical characteristics. High quality clinical research is needed in order to establish their most adequate features.

**PP 514 GCF VOLUME RATE IN COMBINED PERIODONTAL-ORTHODONTIC TREATMENT OF ADULT PATIENTS**

ALEXANDRU IIANU; STEFAN STRATUL; DOINA ONISEI; CIPRIAN SARBU  
*Romania*

**ORTHODONTICS**

**Introduction:** Gingival crevicular fluid (GCF) is an important source of biomarkers related to the health of periodontium. Monitoring them we can determine the effectiveness of orthodontic treatment and the response of the alveolar bone to orthodontic forces. The biomarkers change in special clinical situations, such as severe periodontal disease or orthodontic tooth movements. **Objectives:** The main objective of this study was to determine the volume changes of GCF during orthodontic treatment of adult patients with stabilized periodontal disease. **Materials and methods:** The study was made on 5 patients, each having one tooth selected upon which orthodontic forces were applied. GCF volume determination was made with the Periotron 8000 (Oraflow Inc. USA). Each tooth was sampled using Periostrips (Oraflow Inc. USA) for 30s in the sulcus. For each site 3 strips were used and the arithmetical mean was noted as the final result. GCF samples were taken before bonding the orthodontic appliance (t0), 1h after (t1), 4h (t2), 24h (t3) 1 week (t4) and 1 month (t5). **Results:** There was a significant increase of GCF volume in the first 24h after applying orthodontic forces. Most patients were close to the initial value (t0) after 1 month (t5). **Conclusion:**

GCF volume suffers significant increase during the first 24h of orthodontic forces and tends to level back to the initial values after a period of 1 month. Therefore we can assume that the GCF volume is influenced during the initial period of orthodontic treatment.

**PP 515 MMP 8 LEVELS IN ADULT PERIODONTIC PATIENTS UNDERGOING ORTHODONTIC TREATMENT**

ALEXANDRU IIANU; STEFAN STRATUL; DOINA ONISEI; CIPRIAN SARBU

*Romania*

**ORTHODONTICS**

**Introduction:** Matrix metalloproteinase (MMP) 8 is an important biomarker for periodontal tissue breakdown. Maintaining a healthy periodontium is vital to the success of orthodontic treatment and the stabilization of periodontal disease. **Objectives:** The aim of this study was to determine the levels of MMP 8 in adult patients with treated periodontal problems undergoing orthodontic treatment. **Methods and materials:** The study included 10 adult patients with treated periodontal problems which required orthodontic alignment of teeth. For each patient the tooth with the highest probing pocket depth was selected. From each site gingival crevicular fluid (GCF) was sampled using paper tips (2 per site). The paper strips were each placed 30s into the sulcus and transferred into vials containing PBS transfer medium. MMP 8 levels were determined prior to the bonding of brackets, 1 day after and 1 month after, using Human matrix metalloproteinase 8 ELISA kit (MyBioSource USA). **Results:** MMP 8 levels were significantly higher at 1 week, up to 12 times higher than the initial values. After a period of 1 month the overall values were lowered but still remained high. **Conclusion:** MMP8 levels show a significant increase in adult patients undergoing orthodontic treatment indicating that significant periodontal tissue stress is present.

**PP 517 SMOKING EFFECTS ON ORAL HEALTH: COMPARISON OF CLINICAL PERIODONTAL PARAMETERS OF SMOKERS AND NONSMOKERS**

TATIANA POROSENCOVA; VALERIU BURLACU

*Republic of Moldavia*

**PREVENTIVE DENTISTRY**

**Aim:** To estimate the oral hygiene status of regular and occasional smokers and compare it with that of nonsmokers. **Methods:** A cross-sectional study was carried out in a sample of 96 of patients aged 20-60 years, were divided in three groups, who were exclusive regular smokers, occasional smokers or non-tobacco users. The participants received a questionnaire regarding dental visits, oral hygiene behavior questions and tobacco consumption habits. The oral hygiene status was assessed by clinical measurement of levels of bacterial plaque (PLI), gingival inflammation (GI) and loss of epithelial attachment (LA). All measurements were carried out on four sites of all teeth present, using the automated probe „Florida Probe” (except third molars) and the mean values for periodontal parameters were calculated. A detailed medical history was also taken to exclude medically compromised subjects, especially diabetics and drugs intake that can induce the gingival hyperplasia. **Results:** Findings revealed that the overall periodontitis levels were significantly higher in regular smokers, especially males (22.9%) than in occasional smokers

and nonsmokers. As well, a majority of occasional smokers (OccS) and non-smokers (NS) were females (11.5% OccS and 38.5% NS) who indicated good oral hygiene behaviors and a periodic dental visit at least once a year, thus presented lower levels of PLI, GI and LA. However, the effect of quantified tobacco use was considered limited when compared to that of oral hygiene. **Conclusion:** Tobacco use appears to have considerable adverse effects on the inflammatory process, thereby promoting the progression of periodontal disease in smokers.

**PP 518 IN-VITRO ANTIBACTERIAL EFFECTS OF TWO DENTINE PRIMERS CONTAINING FLUOR WITH OR WITHOUT MDPB**

ILIJANA MURATOVSKA; BILJANA KAPUSEVSKA;

A ATANASOVSKA-STOJANOVSKA; V STOJANOVSKA; E ZABOKOVA-BILBILOVA  
FYROM

**RESTORATIVE AND ADHESIVE DENTISTRY**

The aim of our study is to compare the antimicrobial potential on dental caries pathogens *Streptococcus mutans* and *Lactobacillus acidophilus* of new dental primer containing antibacterial monomer 12-methacryloyloxydodecylpyridinium bromide (MDPB) and Fluor- CLEARFIL SE PROTECT and Prime & Bond NT with Cetylamine Fluoride Source. Inhibitory effects against *Streptococcus mutans* or *Lactobacillus acidophilus* were examined by an agar-disc diffusion method using the primers with long-term Fluoride release. The minimum inhibitory/bactericidal concentrations (MIC/MBC) of each primer for the two bacterial species were determined by serial microdilution assays. For testing the bactericidal effects seen in dentin, the primer was applied to demineralized dentin blocks, 500 µm thickness placed between the bacteria and the test substances, in which *S. mutans* had been impregnated, and numbers of viable bacteria were counted. The data were analyzed statistically using one way ANOVA and Tukey's test. Results: CLEARFIL SE PROTECT had antibacterial effect by the two tests and against the two examined bacteria significantly higher than Prime & Bond NT.

**PP 521 LEAF-GAUGE TECHNIQUE FOR RECORDING CENTRIC RELATION IN PATIENTS WITH TEMPORO-MANDIBULAR DISORDERS**

VITALIE PÂNTEA; OLEG SOLOMON; VITALIE GRIBENCO; DANIELA CHIRITA;

CRISTINA ROŞCA

*Republic of Moldavia*

**REMOVABLE PROSTHODONTICS**

**Background:** The Leaf-Gauge technique is used in dental practice for the registration of jaw records in centric relation and may be used to assist the recording of a reproducible jaw position for restorative and prosthodontics treatment. This technique for centric relation recording was assisted by electromyography. **Methods and materials:** 10 patients had been selected with signs and symptoms of the temporo-mandibular disorders. The patients were examined clinical and paraclinical. The centric relation was determined using the Leaf-Gauge technique for further splint therapy treatment. A random amount of leaves is placed between the patients central incisors at the midline, parallel to the lingual surface of the maxillary central incisors. The patient is asked to slide forward, back and bite slightly. The contacts between lateral teeth are absent. Further, several leaves



are removed until the patient feels the posterior contact. This contact was verified with articulating paper and represents the centric relation, with the condyles in the anterior-superior position. The Leaf-Gauge technique was assisted by electromyography. **Results:** Using this technique of centric relation recording, we obtained the temporo-mandibular joint loading, identification of the first contact in centric relation, lateral pterygomandibular muscle deprogramming and centric relation recording. The electromyography results revealed the reduction of pathologic muscular activity, as seen in the absence of pathological engrams. **Conclusion:** The Leaf-Gauge technique allows the neuromuscular system to seat the condyles in their individual centric relation position, the ideal position for treatment.

**PP 526** **TREATMENT OPTIONS FOR RETAINED PRIMARY TEETH. A CASE REPORT**  
RODICA BODEA; DIANA GASPAR; ALEXANDRU JIANU; RODICA JIANU  
*Romania*

#### ORTHODONTICS

The purpose of the study was to investigate the persistence of primary second molars corroborated with the agenesis of the second premolars. The primary teeth only lack in rare cases. Primary teeth are generally in good condition, root resorption being unaltered. Even when the permanent tooth is present it may fail to erupt leaving the primary tooth in its place. Our study focuses on a twelve year old patient, who came to us with this anomaly. The agenesis of the second premolar can be an acceptable semi-permanent solution for the patient. If this could be a long term solution, will be shown in future studies. Our treatment plan was to keep teeth in the agenesis region without any other treatment, till the root conditions allow them to be kept as a permanent solution.

**PP 529** **TREATMENT OF PERIAPICAL LESIONS. A CASE REPORT**  
RODICA BODEA; DIANA GASPAR; ALEXANDRU JIANU; RODICA JIANU  
*Romania*

#### ENDODONTOLOGY

Periapical lesions are generally the result of infection due to the death of the pulp. Pulp death can occur from a variety of causes, such as trauma or deep restoration, but the main one remains bacterial infection due to a large carious lesion that extends towards the pulp chamber. A 43 year old patient came to us showing signs of swelling in the right maxillary region. Clinical examination showed that the right maxillary first molar had a profound cavity. Periapical radiographs showed a large, well defined radiolucent lesion surrounding the palatal root. Pulp tests were conducted and they indicated necrosis of the pulp. The root canal therapy was carried out using the manual and rotary Pro Taper system, and calcium hydroxide as temporary canal filing. 6 months later, radiographic evidence showed signs of resorption of the periapical lesion. 14 months later the lesion has disappeared completely and the patient is asymptomatic ever since.

**PP 530 EFFECT OF CURCUMIN AND EPIGALLOCATECHIN GALLATE ON STEM CELLS DERIVED FROM HUMAN PERIODONTIUM**

ADINA BIANCA BOSCA; OLGA SORITAU; ARANKA ILEA;  
RADU SEPTIMIU CAMPAN; ALINA ELENA PARVU

*Romania*

**PERIODONTOLOGY**

Plant extracts with antioxidant properties were reported to have no side effects when used as prophylactic and therapeutic agents in periodontology. However, little is known about their exact action on periodontal cells. **Aim:** We investigated the effect of Curcumin and Epigallocatechin gallate (EGCG) on stem cells derived from human periodontium. **Methods:** We isolated mesenchymal stem cells from the circular ligament (CLSCs), periodontal ligament (PDLSCs) and the inter-radicular alveolar bone (ABSCs) of healthy premolars extracted for orthodontic purpose. Cells were cultured on 96-well plates and treated with standardized Curcumin in DMSO (2-500 $\mu$ M), Curcumin in ethanol (0.1-100 $\mu$ M) and EGCG in bidistilled water (0.1-200 $\mu$ M). After 24 and 48h, each well was exposed to 1mg/ml MTT (Thiazolyl Blue Tetrazolium Bromide); the supernatant was read with a microplate reader. Statistical analysis used Dunnett's Multiple Comparison Test. **Results:** Curcumin in doses of 100-500 $\mu$ M exerted significant cytotoxic effect at 24 and 48h; doses lower than 25 $\mu$ M were comparable to control. DMSO at high doses was significantly more toxic than ethanol. EGCG showed no cytotoxic effect, but induced cell proliferation at 75-200 $\mu$ M; doses lower than 50  $\mu$ M were not significantly different from control. ABSCs showed significant increased sensitivity to Curcumin and EGCG, compared with CLSCs and PDLSCs. **Conclusions:** Curcumin and EGCG exerted a dose-dependent effect on periodontium-derived stem cells in culture. Curcumin in higher doses exerted a cytotoxic effect, whereas EGCG was better tolerated. However, cells showed selective responses, according to their origin.

**PP 532 THE VALUE OF PREEMPTIVE ANALGESIA IN DENTAL ALVEOLAR OUTPATIENT SURGERY**

CARMEN STELEA; OANA CIURCANU; CRISTIAN BUDACU; OVIDIU STEFANESCU

*Romania*

**ORAL SURGERY AND ORAL MAXILLOFACIAL SURGERY**

Preemptive analgesia (loco-regional anesthesia + analgesia) is established before applying a painful stimulus - surgical procedure. Many authors have suggested three drug classes: local anesthetics, anti-inflammatory non-steroidal drugs (NSAIDs), opioid analgesics or their combination. The novelty of our study lies in our intention to introduce into dental alveolar outpatient surgery practice our own drug schemes of preoperative analgesia - using as an agent the tramadol - as an alternative to hardly accessible methods, and generally not risk free in order to reduce disease-type postoperative manifestations. Therefore, we conducted our research on a human sample made of 134 patients treated in the oral and maxillofacial surgery outpatient clinic between 1.01.2013 and 31.09.2014. On an upward axis - representing the detected incidence of postoperative events, local pain is located at the peak of the curve (with a statistical average of 38%), closely followed by the pain + edema (32%), low fever (27%), and pain + edema + trismus (15%). The lowest percentage is assigned only to trismus (8%). Incidence of postoperative events

(postoperative edema + moderate pain) showed a modulation of the anesthetic combination (Ira + analgesia) used for surgical approach. The main reason that motivated us to advocate for the introduction of preemptive analgesia method into current dental alveolar surgery was that the method alters the “pain memory”.

**PP 534** **DIAGNOSIS AND TREATMENT OF MYOGENIC DISORDERS OF THE STOMATOGNATHIC SYSTEM**

ANDREI FACHIRA; OLEG SOLOMON; VITALIE GRIBENCO; DANIELA CHIRITA  
*Republic of Moldavia*

**FIXED PROSTHODONTICS**

The diagnosis of muscular disorders (myofascial pain, myositis, muscle spasm) can be made after a thorough case history and a complete clinical examination. Staging treatment is based on data obtained from the patient examination, using the individualization approach in relation to the etiology of the disease. **Materials and methods:** 15 patients were selected and examined (8; 7) aged between 27 and 58 years who were later grouped by gender, age, profession, alcohol consumption and smoking. Anamnestic data were included in the standard questionnaires developed by us, which were subsequently analyzed to determine the cause of the occurrence of muscle disorders. The clinical and paraclinical evaluation of the patients consisted in data systematization of the subjective and objective examination by differentiating the cranial arto muscle forms. **Results:** The results obtained from the data analysis, the subjective and objective examination allowed us to build the individualized treatment sequences, depending on the clinical form of the acute temporomandibular dysfunction. These sequences were systematized in: pharmacotherapy (drug use); exercises of cognitive behavioral self-regulation; physiotherapy; target point management; orthopedic treatment (application trays). **Conclusion:** The treatment of TMJ myogenic dysfunction must be primarily etiological, which requires a deep knowledge of neuromuscular component pathologies. Analysis of data from the standard questionnaires and systemized clinical and paraclinical examination results enable the development and implementation of individualized treatment sequences.

**PP 538** **RELAXATION MOUTHGUARDS AT STUDENTS IN STRESS CONDITION FOR TONIC EQUILIBRATION OF MANDUCATORY MUSCLES**

LAURA CHECHERITA; NORINA FORNA  
*Romania*

**FIXED PROSTHODONTICS**

Occlusal mouthguards have a reversible character, modifying the occlusion in order to reduce the activity of masticatory muscles. The objective of occlusal treatment is to create and establish an occlusal non-conflicting situation between the two dental arches, ensuring an equilibrate position of the mandible that allows the exercise of stomatognathic system functions. The sample comprising 49 subjects, 18 males and 31 females, ages between 18 and 33 years. We have used mouthguards manufactured only from transparent material (resin) that can be flexible or rigid.

The rigid resin is the material of choice, and the mouthguards can be made with occlusal cover: partial or total. These can be applied on mandible or maxilla. It is indispensable the association between de-stressing therapy, a therapy of self-acknowledge by the patient of his/her illness, of avoiding the movements that provoke the symptoms; The etiological treatment of neuromuscular component consists of substitutive relaxation methods.

**PP 541 PREVALENCE OF ORAL MANIFESTATIONS IN PATIENTS ON RENAL REPLACEMENT THERAPY**

ANA BELAZELKOVSKA; MIRJANA POPOVSKA; KRISTINA MITIC;  
SVETLANA CEKOVSKA  
FYROM

**ORAL PATHOLOGY-ORAL MEDICINE**

**Aim:** To determine the prevalence and severity of oral manifestations that occurs in patients with chronic renal failure (CRF) undergoing different replacement therapy. **Material and method:** For realization of the goal sixty patients with diagnosed end stage of renal disease were evaluated, divided into two groups: thirty patients undergoing hemodialysis treatment and thirty patients who had underwent renal transplantation. Both study groups were examined extra orally and intra orally and clinical findings were diagnosed and treated. **Results:** Most frequent oral changes in both study groups were coated tongue (90%), pale oral mucosa (80%) and thirst (70%). Certain oral manifestations showed a predisposition to a particular event in a group of patients, such as petechiae and ecchymoses in the dialysis patients and gingival overgrowth in renal-transplant patients. Some oral symptoms and changes such as burning tongue ( $p<0,001$ ), dry fissured lips ( $p<0,001$ ), and angular cheilitis ( $p<0,001$ ) were significantly more prevalent in dialysis patients than in renal-transplant patients. Among both study groups we registered equal percent of cases with uremic stomatitis (13.33%). **Conclusion:** Patients with CRF who were on treatment with hemodialysis had higher prevalence of oral manifestations compared with patients with renal transplantation. The significant prevalence of oral manifestations indicates that there is association between oral health and chronic renal failure, as well as that the type of renal replacement treatment has influence on the severity of oral clinical findings.

**PP 542 COMPARATIVE STUDY REGARDING THE MICRO-HARDNESS OF SOME AESTHETIC RESTORATIVE MATERIALS**

IRINA GRĂDINARU; ELENA RALUCA BACIU; DANIELA CALAMAZ;  
MARIA BACIU  
*Romania*

**DENTAL BIOMATERIALS AND DEVICES**

**Background:** In recent years and mainly after 2000, the trends in terms of the structure of dental composites have addressed the progressive decrease of filler particle size down to nanometric level. All these result from the need to continuously improve the properties of the composite material such as their hardness, mechanical resilience, contraction to polymerization and

polymerization stress. The present study aimed to test the microhardness and to determine its variation in case of some coronary esthetic restorative materials commonly used in dental practice. **Material and methods:** Experimental researches concerning the determination of the microhardness variations were performed on four direct dental restorative light-curing composite (Herculite XRV Ultra, Synergy D6 and Brilliant - nanohybrid composite and Latelux -microhybrid composite).Specimens, with a diameter of 10 × 10 mm and 4 mm thick, were developed in the Dental Materials laboratory of the Dental Medicine Faculty of "Gr. T. Popa " University of Medicine and Pharmacy of Iasi, in accordance with the manufacturer indications. Micro-hardness testing was performed in the Department of Material Engineering and Industrial Security of the Faculty of Materials Science and Engineering from "Gheorghe Asachi" Technical University of Iași. **Results:** Tests have revealed that direct composite resin Brilliant from Coltene Whaledent presents the highest values of Vickers micro-hardness. **Conclusions:** For the selection and use of direct composite resins dentist must take into account the composition, clinical performance, handling characteristics and their biomechanical behavior, an important parameter being the micro-hardness.

**PP 543 LOCALIZED ALVEOLAR BONE DEFECT MANAGEMENT IN DENTAL IMPLANT SUPPORTED RESTAURATION**

LUCIAN CHIRILA; RADU DRAGUTESCU

*Romania*

**ORAL IMPLANTOLOGY**

Placement of dental implants in the jawbone is mandatory to obtain optimal results accordingly to the long term success criteria for the analysis the dental implant. However, the three dimensional positioning of the implant is done following the restoration driven implant placement" and often it involves positioning the implant partially outside the available bone substance. **Purpose:** Recovery involves restoring the bone support resorbed periimplantar, but within genetically determined bone volume and without exceeding the housing bone. **Methods:** There are two guided bone regeneration techniques peri / preimplantation that restore the bone volume and, consequently, poor local aesthetics. Modelling the physiological limits bone infrastructure creates prerequisites for dental implants long-term stability. **Results:** Volumetric bone restoration with allograft or xenograft type biomaterials and autologous bone offers support to the gum tissue. Bone regeneration and stability also determine the stability of all periimplantar tissues. **Conclusions:** GBR is a predictable procedure if there is an accurate three-dimensional positioning of the implant, allowing for the advance prosthetic restoration to be integrated into the local morphology. Planning of dedicated procedures in order to improve and maintain the volumetric tissue is also important for the implant stability and for the functional and aesthetic effects.

**Introduction:** The evaluation of influence exerted by the finishing techniques by polishing on *Candida albicans* biofilm from the surfaces of metal components of the prosthetic devices may be the result of predictive analyses. **Materials and methods:** The influence of the finishing techniques was materialized by Rz measured for each polished surface whereas the process of formation and growth of cellular biofilms was highlighted by parameters (CFU) and (g) whose values were determined by electronic microscopy SEM. The functional dependence among the three variables taken into consideration in case of the Kera N alloy was solved by using Mathematica 8.0 program. **Results:** The analysis of real regression surface shows that the observance of the interdependence relation between Rz, UFC and g parameters shall occur for values of  $Rz = 0.72...2.65 \mu\text{m}$ , to which shall correspond medium thicknesses of the cellular layer  $g = 19.7...28.8 \mu\text{m}$ . Similarly, from the regression surface of the predictive values it results that the satisfaction of the regression function shall occur for values of  $Rz = 0.98...2.47 \mu\text{m}$ , whereas for parameter g we will have the value interval:  $17.8...23.6 \mu\text{m}$ . **Conclusions:** For the samples of Kera N alloy under study, all theoretical values obtained by predictive analysis for the variable parameters Rz, CFU and g show that the finishing techniques applied to the surfaces of metal components of prosthetic restorations shall exert their influence on the formation and growth of *Candida albicans* biofilms.

**Aim:** To find the relationship between the patients with dyspeptic difficulties of *H. Pylori* in the stomach and oral cavity with oral clinical findings. **Material and method:** 60 patients with dyspeptic difficulties were divided at two groups: the first consisted of 30 patients where the presence of *H. Pylori* was not registered, and the second group (30 patients) with *H. Pylori*. A bioptic material was taken after endoscopic examination and the presence of *H. Pylori* was determined implementing Pronto Dry tests (CLO- test®). A clinical examination was performed at all patients in order to determine the oral changes. The data analysis was done in the statistical program Statistica 7.1 for Windows и SPSS Statistics 17. **Results:** Halitosis was confirmed in 21 patients (35%) with *H. Pylori*, hypertrophy of tongue in 16 (26,67%) versus 2 patients (3,33%) without *H. Pylori*, ignition and burning, apthous ulcers, and sour taste in 4 (6,67%) versus 2 patients (3,33%) without *H. Pylori*. Higher values of IgG (B=2,999) were detected at patients with positive findings of *H. Pylori* in relation to patients with negative findings of *H. Pylori*. ( $p < 0,001$ ). **Conclusion:** The results have confirmed the correlation of *H. Pylori* in the stomach and *H. Pylori* in

the oral cavity, with the prevalence of clinical findings in patients with CLO- positive test. Key words: H. Pylori, oral symptoms, halitosis, burning, aphthous ulcers, sour taste.

**PP 550 THE CLINICAL-TECHNOLOGICAL ALGORITHM OF EXTENDED EDENTATION REHABILITATION - CASE REPORT**

IRINA GRĂDINARU; RALUCA ELENA BACIU; NORINA FORNA

*Romania*

**REMOVABLE PROSTHODONTICS**

**Introduction:** Extended edentation is a frequent diagnosis in dental practice, addressing to a variety of age groups, linked to a variety of factors that can influence the choice of therapeutic solution. **Material and methods:** The clinical-technological algorithm is presented to the female patient HD, aged 46 years, clinical and paraclinical evaluated, diagnosed with extended mandibular edentation, I Kennedy class, D Lejoyeux subclass and subtotal maxillary edentation, VI Applegate class, D Lejoyeux subclass, who coached various forms of local and locally complications. **Results and discussion:** The therapeutic solution was the classic skeletalized partial removable denture, using systemic clasps, determined by clinical-biological, odontal-periodontal, muco-bone and locally indices. **Conclusions:** Variants of therapeutic solutions for extended edentation are diverse, from simple to complex, constituting the premises of a successful rehabilitation by correcting complications and restore functionality of the entire stomatognathic system.

**PP 555 TREATMENT OF A RARE ENDODONTIC COMPLICATION CAUSED BY A DENTAL MALPRACTICE: A CASE REPORT**

NAZIRE NURDAN ÇAKIR; SEZER DEMIRBUĞA

*Turkey*

**RESTORATIVE AND ADHESIVE DENTISTRY**

This case report describes the correction of an endodontic complication caused by a dentist. A sixty-eight- year -old female patient admitted to Erciyes University, Faculty of Dentistry with complaints of pain in the lower anterior region. According to clinical and radiographic examination, 3 months ago root canal treatment was performed for lower left lateral incisor that lightly had percussion sensitivity. Existing periapical radiography showed root canal filling did not entirely proceed along the root canal. We suspected it was not inside root canal and took an angled radiograph that confirmed our thesis. It was observed in the distal periodontal space. After that, cavity entrance was opened and reached to gutta-percha. A #15 H-type file was placed parallel to gutta-percha and progressed 12-13 mm approximately. The gutta-percha was successfully removed and root canal therapy has been completed in the same session. The perforation area was covered by using MTA. At one week recall and first month control sessions the patient had no symptoms and totally healed.

**PP 558 DENTAL STUDENT EMPLOYABILITY PROFILE**

RAMONA FEIER; CRISTINA GENA DASCALU; ANDREEA ZODERU; NORIN FORNA  
*Romania*

**REMOVABLE PROSTHODONTICS**

To propose strategies to facilitate the transition to the labor market, it is necessary to know what are the requirements and needs of different stakeholders regarding the preparation of graduates. **Aim:** Based on their needs, the goal of higher education is to identify the profile of skills that make graduates preferred by employers. We used instruments developed by the National Quality Barometer report, based on feedback from students, teachers and hiring companies. **Material and methods:** The questionnaire applied to students of dentistry aims to identify the characteristics of good student, statistically interpreted by SPSS 12. **Results:** For teachers good student is mobilized by thirst for knowledge, the desire to grow personally through learning, while 20% of respondents share this opinion. The following are good learner characteristics: reliability, conscientiousness, diligence, ability to listen and intelligence. We note that the most important criteria are not so focused on skills general or specific ones (as expected from the results of studies in the literature), but on some features related to the way of being the candidate (promptness, honesty, motivation). These results show that employing companies do not necessarily relate to the work experience of the candidates, but rather to their attitude to work. **Conclusions:** To conclude, the profile of qualities that make a graduate a desirable employee we identified the most important features in terms of the three categories of stakeholders (teachers, students, employing companies). These are related to way of being of students / graduates: thirst for knowledge, diligence, conscientiousness and to inspire confidence.

**PP 560 SURFACE TREATMENTS FOR IMPROVING ZIRCONIA CERAMIC BONDING**

ANETA MIJOSKA; BILJANA KAPUSEVSKA; VESNA JURUKOVSKA;  
KRISTINA MITIK  
*FYROM*

**FIXED PROSTHODONTICS**

**Background:** Several different methods can be used to create surface roughness and improve resin bonding to zirconium ceramics. Acid etching, air abrasion and silane coupling are most common. Air abrasion can compromise the ceramic strength, make surface defects and decrease durable bonding. **Methods and materials:** We tested three different surface treatments on zirconia specimens and evaluated the adhesion with in vitro shear bond tensile test. Ceramic specimens were air-abraded or sandblasted with Al<sub>2</sub>O<sub>3</sub>, polished and air-abraded/primed, put in water storage for 24 hours and tested afterwards. **Results:** Combination of air-abrasion/primers showed highest value of bonding adhesion and polishing showed lowest value. **Conclusion:** Surface treatments on zirconia core can improve and provide better bonding of resin to zirconia and combined treatment air-abrasion with silane coupling showed highest values of bonding strength and that's why it is most recommended.



**PP 562 COMPLEX ORAL REHABILITATION WITH REMOVABLE FLEXIBLE PROSTHESIS FOR A SCHIZOPHRENIA PATIENT**

ELENA MC ADAM; CAROLE MAHLER; JULIE MULLER; MICHAEL TIMOTHEATOS;  
NICOLETA IOANID

*Romania*

**REMOVABLE PROSTHODONTICS**

Patient aged 47 years, partially toothless bimaxillary with a history of paranoid schizophrenia, for 15 years, currently under treatment. Lack of teeth is slight in the maxillary and extensive in the mandible. The patient uses a maxillary joint dental prosthesis and a partial elastic removable prosthesis in the mandible. Despite the patient's antecedent, oral rehabilitation was successful due to the relationship of trust established with the patient and the adaptation of phases of treatment to medication. The patient is totally satisfied.

**PP 563 THE AWARENESS AND EFFECT OF SMOKING ON PERIODONTAL HEALTH AMONGST DENTAL STUDENTS**

CRISTALA NITESCU; MARWA ARZOKY; MOHAMMAD KABIR KHAN; SORINA MIHAELA SOLOMON

*Romania*

**PERIODONTOLOGY**

The **aim** of this study is to highlight the awareness of the 5th and 6th year dental students in that smoking is a risk factor for developing periodontal disease and to compare the periodontal health of smokers and non-smokers. **Materials and methods:** The materials used for this study included questionnaires to see the level of awareness of the dental students in 5th and 6th year; asking them different questions regarding smoking and periodontal health. 32 dental students were examined, 16 smokers and 16 non-smokers. Their periodontal history was taken, and their current periodontal status was determined by using plaque index, probing depth index and papilla bleeding index. All values were gathered within periodontal charts and the mean was calculated. The instruments used were: Dental mirror, forceps, probe, periodontal probe (WHO) and discoloring agent (metilen blue). The teeth that were examined were 16, 12, 24, 36, 32, and 44. **Results:** The data that was collected from the questionnaires and clinical examinations shows a strong association between smoking and periodontal disease. Clinical and biochemical signs of periodontitis were seen, as well as an increased probing depth and clinical attachment level in smokers, greater amount of plaque in smokers and greater papilla bleeding index for non-smokers. These results are due to the masking of some periodontal signs that can be due to nicotine's vasoconstrictor effect **Conclusions:** This study showed that smokers had deeper probing depths, greater attachment loss, increased plaque and found poorer oral hygiene compared to non-smokers.

**PP 564 CHLORHEXIDINE GLUCONATE APPLICATION AND ITS INFLUENCE IN PATIENTS WITH PERIODONTITIS**

MIRJANA POPOVSKA; SAHMEDIN SALI; ANETA ATANASOVSKA STOJANOVSKA; VERA RADOJKOVA-NIKOLOVSKA; ILIJANA MURATOVSKA  
FYROM

**PERIODONTOLOGY**

**Aim:** To evaluate the influence of two different treatment procedures such as application of 0.12 % chlorhexidine digluconate solution versus application of PerioChip after scaling and root planning (SRP) in patients with periodontal disease. **Methods:** 30 patients suffering from periodontitis with at least two bilateral periodontal pockets with PD $\geq$  5 mm were examined. The selected sites were treated with SRP plus subgingival irrigation of 0.12 % chlorhexidine digluconate solution or SRP plus subgingival application of PerioChip. 15, 30 and 90 days after treatment two periodontal indexes were recorded - gingival inflammation (GI) as well as dental plaque index (PI). Method of liquid chromatography was used to determine the concentration of chlorhexidine digluconate in GCF. **Results:** After three months clinical parameters were better in the group treated with SRP plus subgingival insertion of the PerioChip. The values of chlorhexidine digluconate in GCF were highest one hour after the application of the PerioChip. They remained above 125  $\mu\text{g mL}^{-1}$  seven days after starting the treatment. The application of 0.12 % chlorhexidine digluconate solution resulted in concentrations below the limit of detection. **Conclusion:** Application of PerioChip as adjunctive remedy with slow-release of chlorhexidine might be recommended in the treatment of gingival inflammation and periodontal disease, which can reduce the need of other therapeutic modalities.

**PP 565 THE IMPACT OF THE VERTICAL CRANIOFACIAL DISPROPORTIONS ON THE CERVICOVERTEBRAL MORPHOLOGY IN ADULT SUBJECTS**

EMIRA LAZIC; ALEKSANDAR JAKOVLJEVIC; KSENIJA ZELIC MIHAJLOVIC;  
NENAD NEDELJKOVIC  
*Serbia*

**ORTHODONTICS**

**Background:** Orthodontic diagnosis includes the interpretation of the relations between the craniofacial and cervical system, given the potential impact of the irregularities from one system to another. **Aims:** The aim of this study was to examine morphological characteristics of the cervical spine, depending on the parameters of the vertical craniofacial growth and gender in adult subjects. **Methods:** The sample comprised lateral cephalograms of 60 males and 60 females with different vertical facial growth, aged 17.5-35 years. Measured parameters were: anterior and posterior vertebral body height (ABHC2-C5, PBHC2-C5), anterior and posterior intervertebral space (AISC2-C5, PISC2-C5), distance between vertebrae and point sella (SC2, SC3, SC4), pterygomaxillare (PmC2), gonion (GoC2) and basion (BaC4); cervical spine angulation (OPT/CVT) and inclination (OPT/HOR, CVT/HOR). **Results:** Results showed that subjects with anterior facial growth rotation have greater values for BaC4, OPT/HOR, CVT/HOR, OPT/CVT, anterior and posterior vertebral body heights and intervertebral spaces and lower values for GoC2 and PmC2. Higher values in males were found for: anterior and posterior vertebral body heights, distances SC2, SC3, SC4 and

BaC4. In females, the greater values were for GoC2 and OPT/CVT. **Conclusion:** Subjects with anterior facial growth rotation have greater cervical spine inclination and angulation, higher cervical vertebrae and intervertebral spaces, longer upper cervical spines and shorter distances GoC2 and PmC2. Males show smaller cervical column curvature, but higher cervical vertebrae and greater length of the upper cervical spine.

**PP 568** **ROBOT SYSTEM INVOLVED IN PERFORMED ACTIVITY OF DENTAL STUDENTS**

DORIANA AGOP FORNA; MARINA CRISTINA IORDACHE

*Romania*

**ORAL IMPLANTOLOGY**

The fundamental characteristics of contemporary dental medicine are precision, avant-garde, technologization and successful clinical finality. In order to become competent on a permanently evolving field, governed by exigency, esthetic rehabilitation and rigor, it is essential to have an excellent theoretical and practical training. The purpose of this study is to individualize the performance methods applied in the territory of dentistry with profound impact in theory and practice of the future practitioner. The use of simulation systems 3D-DentSim offers the possibility of precision in preparing the nowadays restorations creating the backups of maximum exigency approaches. The use of 3D navigation systems in oral implantology gives the maximum precision to the implant manipulation. In the teaching process, the simulation takes an essential role, being the first before practical manoeuvre, aspect which leads to the cultivation of practical abilities on each of dentistry clinical entity. The complexity of the simulation through evolutionary steps, from preparation to the arch level on models systems to computer-assisted simulation, a performant facet of the present, which leads to accurate manoeuvre and to ideal preparation forms. Another facet of the simulation can be found in 3D modellings, adapted to each clinical case, correlated with the type of biomaterial, the type of dental prosthetics and biomechanics type corresponding to each biosystem. To predict, to give definite trajectories of certain predictability, are essential features that anchor in the field of the new and concrete.

**PP 570** **EFFECT OF PHOTOACTIVATED DISINFECTION IN TREATMENT OF AGGRESSIVE PERIODONTITIS**

GABRIELA BERESESCU; ALINA ORMENISAN; SIMONA MUCENIC; ALINA CAMARASAN; ADRIANA MARIA MONEA

*Romania*

**PERIODONTOLOGY**

The purpose of our study was to determine the effect of photoactivated disinfection on periodontal clinical parameters. Twenty patients aged between 16-25 were enrolled in the study, according to inclusion and exclusion criteria. All the patients received full-mouth nonsurgical treatment (SRP) and were randomly divided in two groups of ten patients each. Group 1 (test group) received application of photoactivated disinfection (PAD) on the day of SRP as well as at follow-up after one week. The time of exposure was 30s and 60s. Group 2 (control group) received

no treatment with PAD. The following parameters were recorded at baseline and three months after start of treatment: gingival index (GI), plaque index (PI), gingival recession (GR), bleeding on probing (BOP), probing depth (PD). After three months, GI, PI and BOP were significantly reduced in both groups ( $p < 0.001$ ) and different significantly between the groups. In both groups, GR was not significantly modified. The results showed significant improvement in clinical parameters in both groups, with the test group showing significantly higher improvement as compared with the control group. In conclusion, the effect of photoactivated disinfection used as adjuvant in scaling and root planning has been successfully proved. Photoactivated disinfection might have potential as an adjunctive treatment when the biofilm is mechanically disrupted.

**PP 571** **COMPUTERIZED 3D SIMULATION (DENTSIM) IN DENTISTRY**

MARINA CRISTINA IORDACHE; DORIANA AGOP FORNA

*Romania*

**NEW TECHNOLOGIES**

**Introduction:** The main characteristics of contemporary dental medicine are represented by avant-garde, precision, high technology and successful clinical finality. In order to be competent in a continuously evolving field, governed by exigencies, esthetic rehabilitation and rigor, it is essential to have an excellent theoretical and practical training. During the didactical process simulation has an important part prefacing practical maneuvers which leads to the training of practical abilities on each clinical entity of dental medicine. **Purpose:** The purpose of the study was to quantify the importance of 3D simulation in the educational practice of the student and to underline the best method in its edification. **Material and method:** A group of 3rd year students at Dental Medicine was followed during an observational study being divided into subgroups (A and B). Subgroup A was enabled through 3D simulation technique, whereas subgroup B was reported as control group, being trained only with the classical methods of education. **Results:** During the study several parameters were analyzed: the execution time, the preciseness of executing a maneuver, the correctness of applying the maneuvers and using the adequate instruments. We have registered significant abnormalities for all parameters in subjects included in the subgroup A as compared to those included in the subgroup B. **Conclusions:** In conclusion we demonstrated that the 3D system is the most developed and advanced method used for the practical informing of the student.

**PP 574** **PSYCHOSOMATIC INTEGRATION OF PATIENTS WITH REMOVABLE PARTIAL DENTURES**

COSMIN ONICIUC; MANUELA CIOCOIU; RUXANDRA SAVINESCU;

LARISA TARIEVICI; MIRELA LEONTE; DANA LAZARUC; NORINA FORNA

*Romania*

**REMOVABLE PROSTHODONTICS**

**Background:** The psychosomatic integration of patients with removable partial dentures is a complex process with local, loco-regional and general implications. The psychosomatic disorders, in patients with removable partial dentures, appear more frequently in specific types of personality with increased emotional reactivity, exaggerated susceptibility and cortical processes stiffness.

Patients responses are modulated by genetic and personality factors. The psycho-behavior indicators, in edentatulous patients, show a prolonged stress with specific released hormones. The stress released hormones, in cases of patients with removable partial dentures with improved esthetics and function, could be modified in a good way by the patients psychic status, called eustress. The purpose of this study is to evaluate the removable partial dentures acceptance starting with the idea that the psychosomatic integration of patients is a complex process that needs local, loco-regional, general and in particular psychic aspects balancing. **Methods:** A total of 42 patients were evaluated and treated, in Prosthodontic Department of the University of Medicine and Pharmacy "Gr.T.Popa" Iasi, using a questionnaire, clinical and laboratory examination. **Results:** 77% of the examined patients obtained the psychosomatic integration, 4% were not satisfied with the aesthetics and 19% could not cope with the idea of removable dentures. **Conclusions:** After assessing the questionnaires, the clinical and laboratory tests we concluded that it is possible to have some degree of predictability of the cases in which the psychosomatic integration is more difficult or impossible, just by using the questionnaires, clinical and laboratory tests results.

**PP 577 PROGNOSIS STUDY REGARDING THE ANNUAL RATIO OF MALOCCLUSION REPORTED CASES IN IASI USING THE TIME-SERIES ANALYSIS**

CRISTINA GENA DASCALU; GEORGETA ZEGAN

Romania

**INTERDISCIPLINARITY**

The time series analysis is a method of statistical analysis used to produce forecasts through the numerical study of the observations and of their apparition order. Based on these information empiric mathematical models are generated, which require a significant number of observations, as well as the knowing of the analyzed process laws of development. The quality of obtained models depends on the quantity of available data and must be permanently evaluated, by checking the concordance between the forecasted and the observed data in a certain moment in time. One of the most known models in this type of analysis is ARIMA (Autoregressive Integrated Moving Average), created by Box and Jenkins in 1976; this model contains 3 parameters, ARIMA (p, d, q) where p represents the autoregressive part, d is the differentiated transformation phase shift and q is the mobile average. Having a series of temporal data  $\xi_t$ , where t represents a moment in time and  $\xi_t$  is a real value, the general equation of the model will be:

$$(1 - \sum_{i=1}^p \phi_i L^i)(1 - L)^d \cdot \xi_t = (1 + \sum_{i=1}^q \theta_i L^i) \varepsilon_t, \text{ where:}$$

L is the lag operator, used in the time series analysis to obtain previous moments in time by starting with a given moment,  $L\xi_t = \xi_{t-1}$  for any  $t > 1$ s, where the temporal series is denoted by  $(\xi_1, \xi_2, \dots, \xi_t)$ ;  $\phi_i$  are the parameters of the autoregressive part of the model,  $\theta_i$  are the parameters of the mobile average and  $\varepsilon_i$  are error terms – independent values with a normal distribution with average 0.

We used this model on a database with monthly new recorded cases of malocclusions in the Orthodontics Clinic, "Sf. Spiridon" Universitary Hospital from Iasi, during a period of 10 years

(2004 – 2014). The analysis was made in SPSS, using the Expert Modeler for Time Series Analysis. We used for the forecast the values recorded in the first 9 years and we compared the outcomes of the analysis for the 10<sup>th</sup> year with the real number of cases recorded in the hospital files – obtained a good match between these values, which showed the viability of the analysis.

**PP 578** **THE CHARACTERISTICS OF CRANIOFACIAL AND CERVICOVERTEBRAL MORPHOLOGY IN DIFFERENT GENETIC SYNDROMES - THREE CASE REPORTS**  
EMIRA LAZIC; KSENIJA ZELIC MIHAJLOVIC; ALEKSANDAR JAKOVLJEVIC;  
NENAD NEDELJKOVIC  
*Serbia*

**ORTHODONTICS**

**Introduction:** Patients with genetic syndromes were characterized with variety of skeletal craniofacial and cervicovertebral morphology. Skeletal anomalies are recognized concomitants of the various genetic syndromes. This study aimed to present the characteristics of craniofacial and cervicovertebral morphology in three patients with different genetic syndromes. **Case report:** We reported radiographic analysis of craniofacial and cervicovertebral morphology in patients with cleidocranial dysostosis, Crouzon and Treacher Collins syndromes. The most characteristic findings of cervicovertebral morphology were presence of cervical spine fusions in all three patients. **Conclusion:** The limitation of cervical range of motion resultant from these anomalies may have clinical significance with respect to multidisciplinary management approach in these patients. Recent advances in dentistry yielded better diagnostic and therapeutic options and outcomes for individuals with genetic syndromes.

**PP 579** **CORE BIOPSY MINIMAL INVASIVE DIAGNOSIS METHOD IN JAW TUMORS - CASE REPORT**  
CARMEN ADRIAN; ADINA MANDA; BOGDAN TURCULEANU  
*Romania*

**ORAL SURGERY AND ORAL MAXILLOFACIAL SURGERY**

Jaw tumors are relatively frequent pathology in maxillofacial field .In many cases the therapeutic solution is segmental resection of the mandible. Decision treatment is often difficult, especially when patients are children or histo-pathological form is uncertain after clinical and paraclinical investigations. In this present we study a case of a teenage girl with a right jaw tumors diagnosed by core biopsy with fibroids osifiant juvenile subsequently confirmed histo- pathological ordinary examination.

**PP 580 THE EFFECTS OF AGMATINE ON MITOCHONDRIAL MEMBRANE POTENTIAL IN RAT GINGIVAL FIBROBLASTS**

DRAGOȘ DANIEL ACATRINEI; ANCUȚA GORIUC; GEANINA BOGZA;  
DECEBAL VASINCU; MARCEL COSTULEANU

Romania

**PERIODONTOLOGY**

**Background:** Agmatine ((4-aminobutyl)guanidine) is the decarboxylation product of the amino acid arginine and is an intermediate in polyamine biosynthesis. Agmatine selectively suppresses growth in cells with high proliferative kinetics through depletion of intracellular polyamine levels. **Materials and methods:** We tested the effects of 10  $\mu$ M Agmatine on mitochondrial membrane potential in rat gingival fibroblasts using JC-1 as marker. Explanted rat gingival fibroblasts were cultured in DMEM medium, supplemented with 2 mM L-glutamine, 100 U/ml penicillin G, 100  $\mu$ g/ml streptomycin, 10% FBS, and incubated at 37°C and 5% CO<sub>2</sub> atmosphere. The analysis using flow cytometry (Becton Dickinson of type FACSCalibur™) was done at 24 and 48 h, after an initial incubation with 5  $\mu$ g/ml JC-1 at 37°C for 20 min. **Results:** Our results showed that 10  $\mu$ M AGM collapsed the normal mitochondrial membrane potential in rat gingival fibroblasts by almost 48% as average (15 experiments), meaning the induced apoptosis in a large number of cells. **Conclusion:** This is the first report of mitochondrial membrane potential collapsing in rat gingival fibroblasts by Agmatine. This might explain the suppression of growth in cells with high proliferative kinetics, besides its effects of depleting the intracellular polyamine levels. **Acknowledgment:** This work received financial support through project CERO - "CAREER PROFILE: Romanian researchers' contract no. HRD 159 / 1.5 / S / 135760, project co-financed by the European Social Fund through Sectoral Operational Programme Human Resources Development 2007-2013.

**PP 581 THE EFFECTS OF TYRPHOSTIN AG 1295 ON MITOCHONDRIAL MEMBRANE POTENTIAL IN RAT GINGIVAL FIBROBLASTS**

CARMEN GENTIMIR (AMITITELOAIE); ANCUȚA GORIUC; GEANINA BOGZA;  
LILIANA CHELARU; MARCEL COSTULEANU

Romania

**PERIODONTOLOGY**

**Background:** AG 1295 is a selective inhibitor of tyrosine kinase of PDGF receptor. Apparently, there is no interaction with Cytosporone B (CSB), the first naturally occurring agonist for nuclear orphan receptor Nur77. **Materials and methods:** We tested the effects of 1  $\mu$ M Tyrphostin AG 1295 (Tyr AG 1295) on mitochondrial membrane potential in rat gingival fibroblasts using JC-1 as marker. We also tested the effects of 1  $\mu$ M Tyr AG 1295 on 50  $\mu$ M CSB-induced apoptosis. Explanted cells were cultured in DMEM medium, supplemented with 2 mM L-glutamine, 100 U/ml penicillin G, 100  $\mu$ g/ml streptomycin, 10% FBS, and incubated at 37°C and 5% CO<sub>2</sub> atmosphere. The analysis using flow cytometry (Becton Dickinson of type FACSCalibur™) was done at 24 and 48 h. **Results:** Our results showed that 1  $\mu$ M Tyr AG 1295 collapsed the normal mitochondrial membrane potential in rat gingival fibroblasts by almost 70% as average (12 experiments), meaning the induced apoptosis in a very large number of cells. Moreover, it facilitated the apoptotic effects of CSB in rat gingival fibroblasts. **Conclusion:** This is the first report

of mitochondrial membrane potential collapsing in rat gingival fibroblasts by Tyr AG 1295 and its facilitating effects on Cytosporone B.



# Alphabetical index

## Alphabetical Index

- A ATANASOVSKA-STOJANOVSKA, 392  
A MINOVSKA, 313  
A. BELCHEVA, 357  
A. CSINSZKA, 376  
A. NEMTOI, 229  
A.FURKAN KARAKOYUNLU, 345  
ABDÜLKADIR ŞENGÜN, 157, 250  
ABDULLAH DEMIR, 193  
ABDULLAH KEPCEOGLU, 362  
ADELA SOCACIU, 168  
ADINA BIANCA BOSCA, 394  
ADINA COROABĂ, 175  
ADINA MANDA, 406  
ADINA SIRBU, 228, 230  
ADNAN EGE KÖSELER, 278  
ADRIAN BANCESCU, 125  
ADRIAN DOLOCA, 315  
ADRIAN FRONIE, 123  
ADRIAN GHEORGHE PODOLEANU, 119  
ADRIAN MANESCU, 120  
ADRIANA BALAN, 22, 185, 216, 224, 368  
ADRIANA MARIA MONEA, 375, 376, 403  
AFRODITI CHALKIDOU, 257, 307, 377, 382  
AGRON METO, 256  
AHMET AKTI, 388, 389  
AHMET AYDOGDU, 310  
AHMET KUBILAY EROGLU, 328  
AHMET VURAL, 178, 179  
AIDA METO, 256  
AKTAS BILAL, 181  
ALBA BIMO, 340  
ALEKSANDAR ATANASOVSKI, 353, 354  
ALEKSANDAR JAKOVLJEVIC, 402, 406  
ALEKSANDAR MITIC, 295, 297  
ALEKSANDAR PETROVIC, 296  
ALEKSANDAR TODOROVIC, 154  
ALEKSANDRA CAIROVIC, 153, 164  
ALEKSANDRA PIVKOVA VELJANOVSKADA, 367  
ALEXANDER MIRWALD, 245  
ALEXANDRA MARIA LARGU, 175  
ALEXANDRA MAROIU, 290, 335  
ALEXANDRA MÂRȚU, 241, 242, 244, 246  
ALEXANDRA MELANIA ONCESCU MORARU, 389  
ALEXANDROS KOLOKOTRONIS, 174  
ALEXANDROS-PANTELEIMON KONTOGIANNIS, 369  
ALEXANDRU ANDREI ILIESCU, 227  
ALEXANDRU BUCUR, 36, 67, 208  
ALEXANDRU CALIN, 226  
ALEXANDRU JIANU, 386, 390, 391, 393  
ALEXANDRU PETRE, 212  
ALEXANDRU-TITUS FARCASIU, 372  
ALI ABU HANTTASH, 236  
ALI ALTINDAG, 237  
ALI HANTTASH, 258  
ALI IHSAN ERKAN, 166, 167, 169, 170, 171, 172, 182, 183, 298, 299  
ALI MURAT AKTAN, 174, 214  
ALI RIZA CETIN, 291  
ALI UNLU, 170  
ALICA RAYCHEVA, 354  
ALIIHSAN ERKAN, 160, 249  
ALINA CAMARASAN, 403  
ALINA ELENA PARVU, 394  
ALINA ORMENISAN, 403  
ALINA SODOR, 187, 209, 219  
ALKETA QAFMOLLA, 23, 25, 164, 265, 274  
ALMIRA ISUFI, 288  
ALMIRO GURAKUQI, 340  
ALPER KAYA, 364  
ALPER SINANOGLU, 252  
ALPER UYAR, 280  
AMEER SHANI DAHHAN, 314  
AMELIA SURDU, 313  
ANA BELAZELKOVSKA, 386, 396  
ANA BUNDALEVSKA, 217  
ANA MARIA FILIOREANU, 21, 385  
ANA MARIA TANCU, 211  
ANA MARIA TROFIN, 194, 196  
ANA MINOVSKA, 202, 217, 379, 398  
ANA PETCU, 24, 216, 224, 229, 284  
ANA PUCAR, 200  
ANA RADESKA, 302, 320, 324, 326, 365  
ANA VUKOVIC, 247, 287  
ANAMARIA CIUBARA, 224, 230  
ANA-MARIA RICA, 327  
ANASTASIA DERMATA, 257  
ANASTASIA VIOLESTI, 325, 349  
ANASTASIA ZIGRIDI, 369  
ANASTASIOS A. ZAFEIRIADIS, 293  
ANASTASIOS PETRIDIS, 354, 355  
ANASTASIOS VOSSOS, 199  
ANCA CHIRIAC, 321  
ANCA IONEL, 228, 230  
ANCA JIVANESCU, 290, 335  
ANCA MELIAN, 227, 284, 344, 384  
ANCA MIHAELA STUPU, 240, 245  
ANCA VITALARIU, 301, 316  
ANCUTA GORIUC, 185, 241, 242, 407  
ANCUTA IGNAT, 224  
ANDON FILTCHEV, 163  
ANDREADIS DIMITRIOS, 174  
ANDREEA FOCSA, 215  
ANDREEA ZODERU, 225, 400  
ANDREEA-SIMONA POP, 221  
ANDREI ADRIAN TICA, 318

ANDREI FACHIRA, 395  
 ANDREI KOZMA, 23, 129  
 ANELIA BOBEVA, 262  
 ANETA ATANASOVSKA, 373  
 ANETA ATANASOVSKA STOJANOVSKA, 219, 247,  
 398, 402  
 ANETA MIJOSKA, 234, 346, 364, 371, 400  
 ANETA MIJOVSKA, 386  
 ANETA MUNTEANU, 215  
 ANGELA GHIORGHE, 220  
 ANI KEVORKYAN, 354  
 ANILA VJESHTA, 207, 216  
 ANNA DI NUNNO, 287, 288  
 ANNA DIMITRIOU, 174  
 ANNE-MARIE RAUTEN, 311, 317, 327  
 ANTIGONE DELANTONI, 21, 43, 120, 323, 324, 325, 349  
 ANTON SCULEAN, 363  
 ANTONIA MOLDOVANU, 329, 356  
 ANTONIOS KONSTANTINIDIS, 176, 342  
 ANTREAS GRIGORIADIS, 349  
 ARANKA ILEA, 211, 221, 394  
 ARGIRIOS PISIOTIS, 147  
 ARIAN DACI, 373  
 ARINA VINEREANU, 210, 215  
 ARIONA DEMIRAJ, 236, 308  
 ARMAND ALUSHI, 374, 375  
 ARSLAN TERLEMEZ, 233, 248, 282  
 ARSO VUKICEVIC, 146  
 ASIYE NUR DINCER, 190, 205  
 ASLI SEÇILMIŞ, 194, 200  
 ASLI ŞENOL, 267  
 ASLIHAN GOKTURK, 266, 270  
 ASLIHAN USUMEZ, 207  
 ATHANASIOS KARAMPASIS, 188  
 ATHANASIOS POULOPOULOS, 188  
 ATHANASIOS SYNARELLIS, 197  
 ATHINA DALOPOULOU, 325  
 ATHINA KONDYLIDOU, 323  
 AURELIA SPINEL, 24, 129, 130, 131, 132, 133, 134, 135,  
 136, 137, 138, 139, 140, 141, 142, 143, 263, 331, 341  
 AYDAN KELES, 280  
 AYSE CANAN TUTKU ATMACA, 166  
 AYŞE GÜLŞEN, 171  
 AYŞE KOÇAK BÜYÜKDERE, 342, 388  
 AYŞEGÜL KÖKLÜ, 267  
 AYŞENUR NERGİZ TANIDIR, 336  
 AYŞİM ŞENOL, 171  
 B DZIPUNOVA, 313  
 B NIKOLOVSKI, 313  
 BADE SONAT, 261, 267  
 BAGDAGUL HELVACIOGLU KIVANC, 332  
 BAHADIR EZMEK, 280  
 BARAN CAN SAGLAM, 332  
 BARBARA MUZZARELLI, 288  
 BARDIS DIMITRIOS, 199  
 BARIS KARABULUT, 364  
 BASSIL RAYMOND VICTOR, 221  
 BERNA ARFAT, 250  
 BETUL AKA, 275  
 BETÜL KÖKDOĞAN BOYACI, 254, 348  
 BIANCA BOŞÇA, 211  
 BIANCA DUMITRU, 363  
 BILAL YAŞA, 275  
 BILJANA DZIPUNOVA, 343  
 BILJANA EVROSIMOVSKA, 326  
 BILJANA KAPUSEVSKA, 20, 69, 233, 234, 235, 364, 392,  
 400  
 BILJANA KAPUSHEVSKA, 346, 371  
 BILJANA KOSEVA, 233  
 BILJANA MILICIC, 148  
 BLEDAR MAVRIQI, 236  
 BOGDAN CIUNTU, 194, 196  
 BOGDAN CRISAN, 168, 223  
 BOGDAN DOBROVAT, 289  
 BOGDAN TURCULEANU, 406  
 BOGENA KOCHEVA, 163  
 BOJAN KUJUNDŽIĆ, 269  
 BOJAN RAKONJAC, 186  
 BOJANA CETENOVIC, 272, 331  
 BOJANA DAVIDOVIC, 261, 262, 329  
 BOJANA STEFANOVIKJ, 367  
 BORA BAGIS, 271  
 BORJAN NAUMOVSKI, 234  
 BOSKO TOLJIC, 200  
 BOYAN PAVLOV, 337  
 BRANKICA DAVIDOVIC, 261, 262, 268, 329  
 BRUNO NIKOLOVSKI, 202, 217, 379  
 BUDIMA PEJKOVSKA – SAHPASKA, 234  
 BUKET OZKAYA, 162, 206  
 BUKHARI CSILLA, 376  
 BÜLENT KURTIŞ, 319  
 BULENT PISKIN, 165, 280  
 BURAK CEZAIRLI, 266  
 BURCU BACAŞIZ, 222  
 BURCU KIRSAN, 236, 280  
 BURCU ŞENEL, 343, 344  
 BURCU SENGÜVEN, 336  
 BURKU SENEL, 347  
 BÜŞRA KABADAYI, 370, 372  
 BUSRA YILMAZ, 214  
 C. BUDACU, 229  
 C. MIHAI, 229  
 CAGLAR KORCUK, 162, 163, 165, 200, 206  
 CAGRI DELILBASI, 198  
 CALIN TATARU, 226  
 CAMELIA GEANINA IVĂNESCU, 177  
 CAN POYRAZ, 194  
 CANSEL KOSE OZKAN, 269  
 CANSU GÜR, 289  
 CARINA BALCOS, 215, 222  
 CARMEN ADRIAN, 406  
 CARMEN GENTIMIR (AMITITELOAIE), 407  
 CARMEN IOANA BIRIS, 351  
 CARMEN MANCIUC, 22, 175  
 CARMEN SAVIN, 23, 216, 224, 286  
 CARMEN STELEA, 394  
 CAROLE MAHLER, 401  
 CATALINA CIOLOCA HOLBAN, 227  
 CĂTĂLINA DĂNILĂ, 240, 245  
 CATALINA FARCASIU, 215, 372  
 CATALINA HOLBAN CIOLOCA, 321  
 CATALINA IULIA SAVEANU, 126  
 CATALINA MURARIU-MAGUREANU, 389  
 CELJANA TOTI, 112, 216

ÇELJANA TOTI, 340  
 CENA DIMOVA, 302, 320, 324  
 CENK DURMUSLAR, 266  
 CERASELLA SINCAR, 155  
 CEREN YILDIRIM, 237, 238  
 CHANGE-HEUN PARK, 123  
 CHARIS BELTES, 23, 44, 124, 362  
 CHRISTINA MARKOMANOLAKI, 284  
 CHRISTINA RAZCHA, 293, 362  
 CHRISTOS RAHIOTIS, 271  
 CIBELA CARAS, 217  
 CIGDEM GULER, 178  
 CIHAN ALP SONMEZ, 312  
 CİHAN ÖZ, 202  
 CIPRIAN SARBU, 390, 391  
 CIPRIAN VASILUTA, 194, 196  
 CLAUDIA FLORIDA COSTEA, 177  
 CLAUDIU MARGARITescu, 352  
 CLAUDIU TOPOLICEANU, 359  
 CLAUDIU VASILE HORGA, 351  
 COBANOGLU NEVIN, 181  
 CONSTANTIN BACIU, 398  
 CORINA MARCAUTEANU, 281, 335  
 CORNELIA OANȚĂ, 241, 244  
 COSMIN ONICIUC, 404  
 COSMIN POPA, 241, 242, 245  
 COSMIN SINESCU, 20, 66, 119, 120, 161, 204, 281  
 COSMIN TOTAN, 208  
 CRINGUTA PARASCHIV, 179  
 CRISTALA NITESCU, 401  
 CRISTIAN BUDACU, 394  
 CRISTIAN GIUROIU, 227, 284, 344  
 CRISTIAN LUPASCU, 196  
 CRISTIAN MARTU, 243  
 CRISTIAN PETCU, 339  
 CRISTIAN ROTARU, 377, 382  
 CRISTIAN VLĂDAN, 208  
 CRISTIANA GLAVCE, 129  
 CRISTINA CORALIA NISTOR, 203  
 CRISTINA GENA DASCALU, 115, 184, 225, 400, 405  
 CRISTINA MARIA BORTUN, 21, 119, 120, 161  
 CRISTINA MARINA IORDACHE, 228  
 CRISTINA NICOLAU, 175  
 CRISTINA POPA, 385  
 CRISTINA ROȘCA, 392  
 CRISTINA RUSU, 177  
 CRISTINA TEODORA PREOTEASA, 198, 211, 389, 390  
 CRISTINA-DIANA RIZEA, 389  
 DALIBOR NIKOLIC, 146  
 DAMLA DOĞAN, 250  
 DAMLA IBRAHIMOV, 249, 250  
 DAN NICOLAE BOSINCEANU, 384, 385  
 DANA BACIU, 215  
 DANA CRISTIANA MAXIM, 175, 284, 286  
 DANA CRISTINA BRATU, 290  
 DANA ELENA DUMITRA, 360  
 DANA GABRIELA BOSINCEANU, 384, 385  
 DANA LAZARUC, 404  
 DANA MAXIM, 224  
 DANA MIHAELA TURLIUC, 177  
 DANA POPA, 242  
 DANA TEODORA ANTON PADURARU, 230  
 DAN-CRISTIAN IONEL, 213  
 DANICA POPOVIC-MONEVSKA, 202, 379  
 DANIEL CIOLOCA, 286, 321  
 DANIEL DIMITROV, 333  
 DANIEL PETRU CIOLOCA, 185  
 DANIELA ANISTOROAEI, 184, 187, 209, 219  
 DANIELA C.STOJCEVA, 217  
 DANIELA CALAMAZ, 396  
 DANIELA CHIRITA, 392, 395  
 DANIELA CVETANOVSKA STOJCEVA, 371  
 DANIELA MIHAELA MEGHEA, 390  
 DANIJELA SUBOTIC, 309  
 DANISIA HABA, 229, 289  
 DARKO VELJANOVSKI, 367  
 DAVIDE FARRONATO, 377  
 DECEBAL VASINCU, 407  
 DEJAN MARKOVIC, 287, 331  
 DEJAN STAMENKOVIC, 154  
 DELIA FLORINA ANDRIESI-RUSU, 194, 196  
 DENIZ YAMAN, 336  
 DERYA DINC, 290, 307  
 DERYA ICOZ, 159  
 DERYA SÛRMELIOGLU, 222  
 DESPOINA DELICHRISTOU, 300  
 DIANA ANTONELA DIACONU, 301  
 DIANA DANIELA DACIANA ZMARANDACHE, 220  
 DIANA GASPARGAR, 386, 393  
 DIANA LUCIA DIACONU, 322  
 DIANA MIRWALD, 242  
 DIANA NIȚESCU, 243  
 DIANA POP, 351  
 DIANA TATARCIUC, 301  
 DIANA UNCUTA, 20, 57, 71, 143, 387  
 DILARA ARSLAN, 190, 205, 207  
 DILEK GUNES, 178  
 DILEK HELVACIOGLU YIGIT, 289  
 DIMITAR FILTCHEV, 163  
 DIMITAR YOVCHEV, 262  
 DIMITRA DIOMATARI, 196, 201, 352  
 DIMITRA KANAKOUSAKI, 374  
 DIMITRA VAKOU, 196, 352  
 DIMITRIOS ANDREADIS, 188  
 DIMITRIOS DIONYSOPOULOS, 172, 201, 321  
 DIMITRIOS KOLOVOS, 373, 376  
 DIMITRIOS PAPALEXIOU, 325  
 DIMITRIOS STRAKAS, 172, 197  
 DIMITRIS PAPALEXIOY, 349  
 DINÇ DERYA, 181  
 DITMIR BORIÇI, 378  
 DJORDJE ANTONIJEVIC, 169  
 DLER MOURAD, 195  
 DOBRINA KARAYASHEVA, 277  
 DOBROMIRA SHOPOVA, 333  
 DOINA BOAZU, 213  
 DOINA ONISEI, 390, 391  
 DOMNA MOLDOVANI, 373, 376  
 DORA POPESCU, 181, 317, 327  
 DORIANA AGOP FORNA, 20, 223, 226, 227, 228, 229, 403, 404  
 DORIANA AGOP-FORNA, 230  
 DORIN GHEORGHE, 181  
 DRAGAN ILIC, 169

DRAGAN MARJANOVIĆ, 302, 311  
 DRAGANA RAKASEVIC, 186  
 DRAGICA STOJIC, 153  
 DRAGO JELOVAC, 357  
 DRAGOŞ DANIEL ACATRINEI, 407  
 DRAGOS FRATILA, 313  
 DRAGOSLAV STAMENKOVIC, 153, 164  
 DURMUS ASICIOGLU, 259  
 DURMUŞ AŞICIOĞLU, 261, 264  
 DUSAN KOSANOVIC, 283  
 DUSICA BOZOVIC BEHARA, 152, 333  
 DZENAD GANJOLA, 306, 309  
 E ZABOKOVA-BILBILOVA, 392  
 E. SHIN, 366  
 EBUBEKIR TOY, 193  
 EDA ARAT MADEN, 237, 238  
 EDA OZDERE, 189, 378  
 EDIT XHAJANKA, 265, 285, 286, 304, 378  
 EDLIRA SUBASHI, 216  
 EDUARD CIUCĂ, 123  
 EFTHALIA KOKLA, 196, 201, 376  
 EFTHYMIA CHALVATZOGLOU, 330  
 EGOR POROSENCOV, 218  
 EGRESA BACA, 207, 236, 308  
 EIRENE BALNTOUMI, 188  
 EIRINI ATHANASIADOU, 257, 307, 382  
 EKATERINA BOTEVA, 277  
 ELEANA KONTONASAKI, 151, 158, 300  
 ELEFThERIOS ANAGNOSTOU, 174  
 ELENA MC ADAM, 401  
 ELENA PREOTEASA, 198, 211, 389, 390  
 ELENA RALUCA BACIU, 396, 398  
 ELENI EIRINAKI, 160  
 ELENI TOUFA, 157  
 ELENI-SOTIRIA PALLA, 158  
 ELIF AYBALA OKTAY, 276  
 ELIF BAHAR TUNA, 251, 276  
 ELIF INONU, 312  
 ELIF NAZ YETA, 158  
 ELİF ÖNCÜ, 336  
 ELISABETH KOULAOUZIDOU, 197  
 ELITSA DELIVERSKA, 262  
 ELKA RADEVA, 23, 118, 251  
 ELMEDIN BAJRIĆ, 306  
 ELTON GJINI, 274  
 EMANUEL BRATU, 290, 335  
 EMEL UZUNOGLU, 151  
 EMILJANO TRAGAJ, 256  
 EMINE KAYA, 279  
 EMIRA LAZIC, 355, 402, 406  
 EMIRE AYBUKE ERDUR, 178, 179  
 EMRE BALABAN, 266  
 EMRE BARIŞ, 336  
 EMRE BAYRAM, 238  
 EMRE KORKUT, 233, 282  
 EMRE OZEL, 251, 266, 270, 272, 276  
 ENDRI PAPANISTO, 285, 286  
 ENES TAN, 273, 305, 328  
 ENIKO TUNDE STOICA, 281  
 EREN ISMAN, 170, 174  
 ERHAN FIRATLI, 251, 276  
 ERKAN ALI İHSAN, 181  
 ERLIND PEPLA, 156  
 ERSUN GUSHI, 260  
 ERTUGRUL ERCAN, 249, 250  
 ERTUĞRUL ERCAN, 157, 249, 298  
 ESAT BARDHOSHI, 265, 274  
 ESER BOLAT, 363  
 ESIN DEMIR, 192  
 ESRA BALTACIOGLU, 271  
 ESRA GULAL, 249, 250  
 ESRA GUZELDEMİR-AKCAKANAT, 388  
 ESRA TALAY, 362  
 ESRA ULKER, 161, 166, 167, 171, 172, 290  
 ESRA UZER ÇELİK, 275  
 ESRA ÜZÜMCÜ, 250  
 ESRA YAMAN, 259  
 EUGENIA KOLINIOTOU-KOUMPIA, 172, 197  
 EUGENIA POPESCU, 213, 223, 227, 385  
 EUGENIU MIHALAS, 286  
 EUGENIU MIHALAŞ, 175, 216  
 EVANGELIA VAILAKI, 286  
 EVANGELOS PARCHARIDIS, 201  
 EVGENIYA POPOVA, 303  
 EVROSIMOVSKA BILJANA, 298  
 F. VENINOV, 335  
 FARUK AYHAN BASCIFTCI, 178, 179, 316  
 FARYD MUSEYIBOV, 336  
 FATİH MEHMET COŞKUNSES, 278  
 FATİH MEHMET KORKMAZ, 271  
 FATMA AYTAC, 193  
 FATMA KAPLAN, 207  
 FATMA YILMAZ, 275  
 FAUSTINA KOLA, 256  
 FERHAT DANISMAN, 312  
 FERIT AVCU, 269  
 FETHI ATIL, 361  
 FEVZI BUYUKGEBİZ, 350  
 FIKRET YILMAZ, 294  
 FILIZ NAMDAR PEKİNER, 274  
 FIRDEVŞ KAHVECİOĞLU, 167, 171  
 FİRDEVŞ KAHVECİOĞLU, 160  
 FİRDEVŞ KAHVECİOĞLU, 161  
 FLORENTIN BERNEANU, 375  
 FLORIN ROSU, 21, 227  
 FLORIN TOPALA, 281  
 FLORION TABAKU, 304  
 FOIVOS DALAMPIRAS, 157  
 FOIVOS-ANTONIOS DALAMPIRAS, 325  
 FOTEINI PAPANIKOLAOU, 323, 324  
 FOUAD SALEH NAJAFI, 330  
 FRANCISC BARTOK, 226  
 FULYA TOKSOY TOPCU, 276  
 FUNDA YILMAZ, 158, 259  
 FÜSUN YAŞAR, 265  
 GABRIEL VEISA, 156  
 GABRIELA BANCESCU, 24, 125  
 GABRIELA BERESESCU, 375, 376, 403  
 GABRIELA DUMITRESCU, 229  
 GABRIELA FLORENȚA DUMITRESCU, 177  
 GABRIELA İFTENİ, 20, 47, 48, 137, 315, 316  
 GABRIELA PADURARU, 224  
 GALINA PANCU, 356, 359  
 GAMZE ER, 205, 314

GAMZE TOPÇUOĞLU, 389  
 GEANINA BOGZA, 407  
 GEORGETA ZEGAN, 115, 184, 187, 219, 405  
 GEORGI ILIEV, 163  
 GEORGI TODOROV, 337  
 GEORGI TOMOV, 278  
 GEORGIA BARKA, 160, 325  
 GEORGIANA MACOVEI, 313  
 GEORGIEV ZLATKO, 302, 326  
 GEORGIOS CHATZOPOULOS, 330, 342  
 GEORGIOS KARATHANOS, 323  
 GEORGIOS-ALEXANDROS VAKIRTZIAN, 369  
 GERSI VËRÇANI, 164  
 GERTA KAÇANI, 285, 286  
 GHEORGHE BORDENIUC, 380  
 GHEORGHE GH. BALAN, 368  
 GIANINA IOVAN, 22, 220, 316, 359  
 GIOVANNI MANES GRAVINA, 288  
 GIUROIU CRISTIAN, 384  
 GIUSEPPE MARZO, 287, 288  
 GIZEM GUDER, 252  
 GOKCE DOGAR, 388  
 GORAN VIDENOVIC, 302, 311, 350  
 GORDANA FILIPOVIC, 272, 331  
 GORDANA JOVICIC, 146  
 GORDANA KOVACEVSKA, 233  
 GORDANA PAPAKOCA, 324  
 GÖRKEM YAHYAOĞLU, 268  
 GÖZE ARUKASLAN, 340  
 GUIDO MIGLIAU, 156  
 GUL TOSUN, 161, 178  
 GULABA DEREHAN, 234  
 GÜLBIKE DEMIREL, 279  
 GULCIN AKCA, 332  
 GULDANE MAGAT, 180  
 GÜLDEN UZGÖREN, 294  
 GULEN KAMAK, 304, 305, 347  
 GÜLEN KAMAK, 305  
 GULIZ GORGUL, 332  
 GÜLSÜM KÖŞTEN, 258  
 GÜRKAN GÜR, 279, 308  
 GUVEN AYDIN, 271  
 H. ARNAUTSKA, 357  
 H. ESRA ÜLKER, 160  
 H. LIM, 366  
 H. YANG, 366  
 H.SINAN TOPÇUOĞLU, 389  
 HACER DENİZ ARISU, 332  
 HAKAN DINC, 172  
 HAKAN EREN, 236, 238  
 HAKAN GOKTURK, 193, 350  
 HAKAN KEKLIK, 291, 292, 294, 304, 343, 344, 345, 346, 347  
 HAKAN KEKLİK, 305  
 HAKKI CELEBI, 233, 282  
 HALE KARAKUYU, 266  
 HAMDİ ACAR, 172  
 HAMDİ ACAR, 166  
 HAMDİ SUKUR, 362  
 HANA HUBALKOVA, 22, 41, 126  
 HANDE CINAR, 259  
 HASAN GUNDOGAR, 162, 163, 206, 222  
 HASAN GÜNDOĞAR, 153, 165  
 HASAN KAMAK, 291, 292, 294, 343, 344, 345, 346, 347  
 HASAN KUCUKKOLBASİ, 338  
 HATICE KUBRA DEMIRTAS, 316  
 HATICE PARLAK, 387  
 HATICE TOY, 193  
 HATICE UMay HOŞGÖREN, 165  
 HENRIETTE LERNER, 227  
 HILAL DEMİR, 265  
 HORIA-OCTAVIAN MANOLEA, 123  
 HRISTINA ARNAUTSKA, 380  
 HRISTO BOZUKOV, 353, 357  
 HRISTO KISOV, 333, 337  
 HUDA MELIKE BAYRAM, 238  
 HÜSEYİN SİNAN TOPÇUOĞLU, 388  
 HUSEYİN TORT, 276  
 HÜSEYİN YAZICIOĞLU, 254  
 HYEON-SHIK HWANG, 383  
 I. ERHAN GELGOR, 273  
 IGOR SAVELJIC, 146  
 ILGI BARAN, 361  
 ILIAN HRISTOV, 337  
 ILIAS LIAPIS, 204  
 ILIJANA MURATOVSKA, 23, 29, 219, 247, 343, 392, 402  
 ILINCA FISER, 203  
 ILINCA UNTU, 230  
 ILKER KESKİNER, 310  
 ILKNUR TUNCER, 188, 381  
 ILMA ROBO, 154, 207, 236  
 INGRITH CRENGUȚA MIRON, 177  
 IOAN DANILA, 20, 23, 126  
 IOANA MARTU, 243  
 IOANA MÂRȚU, 241, 242, 245  
 IOANA RADU, 289  
 IOANA RUDNIC, 239, 240, 242, 245  
 IOANNA PATARGIA, 174  
 IOANNA TSACHOURIDOU, 176  
 IOANNIS EMMANOUIL, 147  
 IOANNIS KIOLEOĞLU, 147  
 IOANNIS PILALAS, 293  
 IOANNIS VOUIROS, 349, 374  
 ION LUPAN, 23, 218, 366, 379, 380  
 IONELA ELISABETA CIOBANU, 311  
 IONUT LUCHIAN, 204, 241, 242, 245, 284  
 IONUȚ NISTOR, 156  
 IPEK GULDAS, 189, 362  
 İREM GEÇEROĞLU, 346  
 IREN MORARU, 339  
 IRENA MLADENOVIC, 203, 205  
 IRINA BAMBOI, 222  
 IRINA ESANU, 179  
 IRINA GRĂDINARU, 396, 398, 399  
 IRINA NICA, 64, 73, 76, 220, 329, 356  
 IRINA URSARESCU, 243  
 IRINA URSĂRESCU, 155, 156, 243, 244  
 IRINA ZETU, 24, 122, 127, 241  
 IRINA-GEORGETA URSĂRESCU, 246  
 IRIS ÇAÇANI, 216  
 ISA YONDEM, 189, 362  
 ISABELA SILOSI, 318  
 ISIL KARAOKUTAN, 190  
 İŞİL SAYGUN, 269

İSMAİL BALTACIOĞLU, 267  
 ISMAIL HAKKI, 246, 253  
 ISMAIL HAKKI BALTACIOĞLU, 253  
 ISMAIL OZKOCAK, 193, 350  
 IULIA SAVEANU, 222  
 IULIAN FILIPOV, 377, 382  
 IULIAN URSU, 381  
 IULIANA MANUELA DRAGOMIR, 317  
 IUSTIN OLARIU, 204, 212  
 IVA DIMOVSKA, 255  
 IVAN BACHVAROV, 380  
 IVAN CHAKALOV, 338  
 IVAN NACHKOV, 278  
 IVANA SIMIC, 262  
 IVICA STANCIC, 205  
 IVONA KOVACEVSKA, 264, 302, 326  
 J. ALIMANI- JAKUPI, 335  
 JADRANKA BUNDEVSKA, 233  
 JASMINKA ANDJELIC, 260  
 JELENA MANDIC, 247, 283  
 JELENA OBRENOVIĆ, 268, 269  
 JELENA POPOVIC, 295, 296, 297  
 JELENA ROGANOVIC, 153  
 JENDOUBI SABRINE, 221  
 JINDRICH CHARVAT, 126  
 JIN-HYOUNG CHO, 383  
 JIRI MAZANEK, 126  
 JOVANA HRISA SAMARDŽIJA, 269  
 JOVANA KUZMANOVIC, 148, 200  
 JOVANA KUZMANOVIC PFICER, 148  
 JOVANKA GASIC, 295, 296, 297  
 JULIE MULLER, 401  
 JULIJA ZARKOVA, 320, 326, 365  
 K. IVACSON, 376  
 K. YUN, 366  
 KAAAN ORHAN, 20, 21, 39, 152, 258, 260  
 KADIR KAPLANOGLU, 303  
 KALLIOPI PAPAZOGLU, 196, 201  
 KAMEL EARAR, 116, 231  
 KAMILE ERCIYAS, 162, 163, 165, 206, 222  
 KAMİLE ERCİYAS, 153  
 KATARINA RADOVIC, 21, 38, 153  
 KATARINA RADOVIĆ, 164  
 KATERINA FOTEVA, 365  
 KATERINA TOSHESKA-TRAJKOVSKA, 343  
 KATERINA ZLATANOVSKA, 320, 324, 326, 365  
 KEMAL FERIZ, 368  
 KEMAL KORUCUOGLU, 162  
 KEMAL KORUCUOĞLU, 194, 200  
 KEMAL ÜSTÜN, 153  
 KEN YAEGAKI, 315  
 KHADER ALQAWASMEH, 347  
 KI-HEON LEE, 383  
 KIRO PAPAKOCA, 320, 324, 326, 365  
 KIVANC KAMBUROGLU, 280  
 KIVANÇ KANBUROĞLU, 158  
 KLEONIKI LIROUDIA, 293  
 KONSTANTINIA KARAOLANI, 201  
 KONSTANTINOS ARAPOSTATHIS, 257, 307  
 KONSTANTINOS MICHALAKIS, 147  
 KONSTANTINOS SIDIROPOULOS, 327  
 KONSTANTINOS TZIMAS, 342  
 KOSMAS TOLIDIS, 321  
 KRENAR PAPRANIKU, 367  
 KRISTIJAN SHUKOV, 235  
 KRISTINA MITIC, 386, 396, 398  
 KRISTINA MITIK, 400  
 KSENIJA ZELIC MIHAJLOVIC, 146, 402, 406  
 KÜBRA DEĞIRMENCI, 342  
 KWIDUG YUN, 21, 42, 125  
 KYUNG-MIN LEE, 383  
 LALE TANER, 170  
 LAMPROS INTZES, 293  
 LARISA TARIEVICI, 404  
 LAURA CHECHERITA, 395  
 LAURA CRISTINA RUSU, 161  
 LAURA GAVRILĂ, 216  
 LAURA MARIA GAVRILA VASILCA, 286  
 LAURA MARIA VASILCA, 224  
 LAURA STEF, 210  
 LAVINIA MATRICALA, 175  
 LAVINIA MEDA NEGRUTIU, 204, 281  
 LAZAROS TSALIKIS, 176, 330, 342  
 LEJLA DELIĆ, 306  
 LELIA GHEORGHITA, 339  
 LENA JOVANOVIC, 152, 333  
 LIA MARIA YERO EREMIE, 376  
 LIANA AMINOV, 227, 284, 344  
 LIANA LASCU, 363  
 LIDIJA POPOVSKA, 326  
 LILIAN NISTOR, 381  
 LILIANA CHELARU, 407  
 LILIANA FOIA, 155, 321  
 LILIANA PĂSĂRIN, 243, 244, 246  
 LILIANA POROJAN, 22, 124  
 LILIYA DOICHINOVA, 263, 267  
 LIVIA BOBU, 215, 222  
 LIVIO GALLOTTINI, 287, 288, 320  
 LIVIU GAVRILA, 204, 212  
 LIVIU PRISACARIU, 175  
 LIVIU ZETU, 127  
 LJILJANA BAJIC, 370  
 LJILJANA STOJANOVIĆ, 358  
 LJUBEN GUGUVCHEVSKI, 346  
 LJUBICA SIMJANOVSKA, 348  
 LJUBINKA NIKOLIC, 300  
 LOREDANA GOLOVCENCU, 184, 187, 209, 219  
 LOREDANA HURJUI, 185, 239  
 LUAN MAVRIQI, 207, 236, 295, 308  
 LUCIA BARLEAN, 215, 222  
 LUCIAN CHIRILA, 377, 382, 397  
 LUCIAN DRAGOMIR, 181, 311, 327  
 LUCIAN PAUL DRAGOMIR, 317  
 LUCIAN TOMESCU, 290  
 LUCIANA GOGUTA, 335  
 LUELA ALUSHI, 375  
 LUMINITA MARIA NICA, 118  
 LUTCHEZAR STEFANOV, 262  
 M DALAMPIRA, 157  
 M POPOVSKA, 313  
 M. MUSTAFA HAMIDI, 249, 250  
 M. VANG, 366  
 M.S.C. HABA, 229  
 MĂDĂLINA MATEI, 116, 231

MAGDA BARLEAN, 215  
 MAGDALINI KOKKONI, 352, 373  
 MAJA DELIC, 306, 309  
 MAJA GJOROVSKA, 199  
 MĂLINA COMAN, 116, 231  
 MANUELA CIOCOIU, 404  
 MARCEL COSTULEANU, 407  
 MARIA ALEXANDRA MĂRȚU, 155  
 MARIA BACIU, 396  
 MARIA BOGDAN, 318  
 MARIA DENCHEVA, 239  
 MARIA DIMOVA, 163  
 MARIA GLUSHKOVA, 277  
 MARIA HATZIPARASKEVA, 354, 355  
 MARIA KALELI, 257  
 MARIA KELESI, 151  
 MARIA MALLIARI, 151  
 MARIA TSITSARA, 342  
 MARIA VATAMAN, 227, 284, 344  
 MARIA-ALEXANDRA MĂRȚU, 155  
 MARIANA PACURAR, 127  
 MARIANA PĂCURAR, 122  
 MARIE BARTONOVA, 126  
 MARIELLA ORICCHIO, 287, 288  
 MARIJA ANDONOVSKA, 235  
 MARIJA DJURIC, 146  
 MARIJA NIKOLIC, 295, 296, 297  
 MARIJA ZUZELOVA, 255  
 MARIJANA POPOVIĆ BAJIĆ, 173  
 MARIN BURLEA, 24, 128, 224  
 MARINA AMARASCU, 356  
 MARINA CRISTINA IORDACHE, 403, 404  
 MARINA KACARSKA, 199  
 MARINA MELESCANU IMRE, 211  
 MARINA MILINKOVIĆ, 268, 269  
 MARINA OLIMPIA AMĂRĂSCU, 183  
 MARINA TSIRAKI, 176  
 MARIUS ANDREI DINU, 245  
 MARJAN PETKOV, 234  
 MARKO ANDJELKOVIC, 149  
 MARKO JEREMIC, 287  
 MARTIN HRISTOV, 278  
 MARTIN RUBIEV, 262  
 MARWA ARZOKY, 401  
 MASSIMO GALLI, 156  
 MEDA LAVINIA NEGRUTIU, 20, 66, 119, 120, 161  
 MEHMET AKIN, 182, 183, 310, 319, 328  
 MEHMET ALI YAVAN, 195  
 MEHMET BIROL ÖZEL, 268  
 MEHMET BURAK GUNESER, 190, 207  
 MEHMET BURAK GÜNEŞER, 205  
 MEHMET EMRE YILMAZ, 310  
 MEHMET ERAY KOLSUZ, 152, 237, 270  
 MEHMET ERTUGRUL CIFTCI, 214  
 MEHMET FATİH TUNCER, 378, 381  
 MEHMET HAKAN KURT, 237  
 MEHMET İŞIKER, 200  
 MEHMET KAPLAN, 237, 238  
 MEHMET KURKCU, 170  
 MEHMET MUSTAFA HAMIDI, 157  
 MEHMET OĞUZ BORAHAN, 274  
 MEHMET SAHIN OGUZCAN, 246  
 MEHMET SINAN DOGAN, 202  
 MEHMET TARTICI, 308  
 MEHMET TUGRAN, 182, 183  
 MEHMET UNAL, 202  
 MEHMET VEHBI BAL, 269  
 MELANIA COJOCARU, 181  
 MELEK AKMAN, 248  
 MELEK HILAL KAPLAN, 387  
 MELEK HİLAL KAPLAN, 388  
 MELIAN GABRIEL, 384  
 MELIHA OSMAN, 328, 368  
 MELIS ALAV, 259  
 MELİS ALAV, 255  
 MELTEM ÖZTAN, 261  
 MERITA BARDHOSHI, 265, 274, 285, 286, 304, 378  
 MERVE AYCAN KIR, 185, 195  
 MERVE BANKOĞLU GÜNGÖR, 254  
 MERVE EFE-SERIM, 272  
 MERVE EROL, 316  
 MERVE GOYMEN, 170, 174  
 MERVE GÖYMEN, 185, 195  
 MERVE YILDIZ, 334, 336  
 MESUT ELBAY, 279  
 MIA RAKIC, 300  
 MICHAEL TIMOTHEATOS, 284, 401  
 MIHAEL STANOJEVIC, 205, 261, 329  
 MIHAEL STANOJEVIĆ, 203  
 MIHAELA BACIUT, 20, 223  
 MIHAELA BOANCA, 179  
 MIHAELA CERNUSCA MITARIU, 210, 282  
 MIHAELA MARIN, 390  
 MIHAELA MOISEL, 116, 231, 242, 244  
 MIHAELA MONICA SCUTARIU, 313  
 MIHAELA NICULESCU, 322  
 MIHAELA PAUNA, 372  
 MIHAELA POPESCU, 46, 50, 51, 122, 317  
 MIHAELA ROMANITA GLIGOR, 210, 282  
 MIHAELA SALCEANU, 23, 227, 284, 344, 384  
 MIHAELA TUCULINA, 339  
 MIHAI BUCUR, 208  
 MIHAI CENARIU, 211  
 MIHAJLO PETROVSKI, 302, 339  
 MILAN PETROVIĆ, 357  
 MILENA PENEVA, 263, 267  
 MINODORA MOGA, 228, 230  
 MIOARA TRANDAFIRESCU, 321  
 MIRA POPOVSKA, 343  
 MIRCEA BALDEA, 377  
 MIRCEA SUCIU, 351  
 MIRELA LEONTE, 404  
 MIRJANA DJURICKOVIC, 20, 349  
 MIRJANA IVANOVIC, 261, 329  
 MIRJANA MARKOVSKA ARSOVSKA, 348  
 MIRJANA POPOVSKA, 202, 235, 247, 379, 386, 396, 398,  
 402  
 MIROSLAV OBRENOVIĆ, 268, 269  
 MLADEN BEHARA, 152, 333  
 MOHAMMAD KABIR KHAN, 401  
 MOMIR CAREVIC, 247  
 MONA GORNICIOIU, 217  
 MONICA ANDRONACHE, 217  
 MONICA CRĂIȚOIU, 123



MONICA DANA MONEA, 351  
 MONICA MIHAELA CRAITOIU, 352  
 MONICA MONEA, 122  
 MONICA SCRIECIU, 183, 322  
 MONICA SILVIA TATARCIUC, 63, 72, 73, 76, 83, 301  
 MONICA TATARCIUC, 19, 64, 73, 241, 242  
 MUNIR TOLGA YUCEL, 186, 334  
 MURAT AKKAYA, 21, 318  
 MURAT ÇAĞLAROĞLU, 328  
 MURAT CAKAN, 198  
 MURAT SELIM BOTSALI, 307  
 MURUDE YAZAN, 235  
 MUSTAFA DEMIRCI, 252  
 MUSTAFA KOCACIKLI, 348  
 MUSTAFA ULKER, 166, 171  
 MUSTAFA ÜLKER, 160, 166, 172  
 N.EREN İŞMAN, 195  
 NADJA NIKOLIC, 200  
 NATASA RANDJELOVIC, 355  
 NATASA STAVREVA, 235  
 NATASA TOSEKA-SPASOVA, 29, 219  
 NATASHA DENKOVA, 264, 339  
 NATASHA RANDJELOVIC, 152, 333  
 NATASHA STAVREVA, 346, 348, 364  
 NAZ YETA, 318  
 NAZIRE NURDAN ÇAKIR, 399  
 NAZMI YEDONMEZ, 372  
 NAZMIYE DÖNMEZ, 370  
 NEADA HYSENAJ, 265, 274, 285, 304, 378  
 NECMETTIN YETA, 318  
 NEDA PERUNOVIC, 300  
 NENAD FILIPOVIC, 146  
 NENAD NEDELJKOVIC, 402, 406  
 NERMIN DEMIRKOL, 185  
 NESLIHAN TEKCE, 252, 266  
 NEVENA KOYCHEVA, 358  
 NEVIN COBANOGU, 307  
 NICA LUMINITA, 120  
 NICOLAE GHEȚU, 175  
 NICOLETA DUMITRESCU, 229  
 NICOLETA IOANID, 242, 401  
 NIHAT DEMIRTAŞ, 314  
 NIKOLA DEREBAN, 234  
 NIKOLA MIKOVIĆ, 357  
 NIKOLA STOJANOVIC, 262  
 NIKOLAOS ECONOMIDES, 327  
 NIKOLAOS EKONOMIDES, 325  
 NIKOLAY ISHKITIEV, 315  
 NIKOLAY NIKOLOV, 278  
 NIKOLETA PASTELLI, 188  
 NIKOS OIKONOMIDIS, 293  
 NILSUN BAGIS, 152  
 NIMET UNLU, 169, 170  
 NİMET ÜNLÜ, 334, 336  
 NINA KOVACEVSKI, 233  
 NINA MILCHEVA, 353, 357, 367  
 NINETA FINO, 216  
 NORIN FORNA, 225, 400  
 NORINA FORNA, 19, 21, 60, 128, 217, 228, 229, 384, 385,  
 395, 398, 399, 404  
 NURAY GUNAYDIN, 167, 171, 290, 291  
 NURAY GÜNAYDIN, 160  
 NURAY YILMAZ ALTINTAŞ, 266  
 OANA ANDREEA DIACONU, 339  
 OANA CIURCANU, 394  
 OANA SORINA TICA, 318  
 OANA TANCULESCU, 316  
 OANA ȚĂNCULESCU, 315  
 OANA-CELLA ANDREI, 372  
 OCTAVIAN DINCĂ, 208  
 OLEG SOLOMON, 22, 55, 392, 395  
 OLGA BĂLTEANU, 331, 341  
 OLGA DJURIC, 306  
 OLGA NAKA, 324  
 OLGA SORITAU, 394  
 OLGA SORIȚĂU, 211  
 OLIA MARTINOV, 239  
 ÖMER ALPARSLAN KIR, 195  
 ONDINE LUCACIU, 168, 221, 223, 228, 230  
 ONJEN TAK, 283  
 ÖNJEN TAK, 342  
 ORAL SÖKÜCÜ, 195  
 ORHAN HAKKI KARATAS, 191, 193  
 OTILIA BOISTEANU, 213, 223  
 OVIDIU NICOLAICIUC, 239, 243  
 OVIDIU STAMATIN, 213, 217  
 OVIDIU STEFANESCU, 394  
 ÖZGÜL BAYGIN, 268  
 OZLEM ISMAN, 214  
 ÖZLEM MARTI AKGÜN, 237, 238  
 PANAGIOTIS KAVOURAS, 300  
 PANAGIOTIS NTOVAS, 271  
 PANCU GALINA, 329  
 PANTELIS KOUROS, 197  
 PAUL FREIMANN, 212  
 PAULA PERLEA, 203, 227  
 PAVLINA DIMITRIADI, 199  
 PELO PELOV, 303  
 PETER BAKARDJIEV, 263, 267  
 PETER JEVNIKAR, 371  
 PETRA SURLIN, 181, 311, 318, 327  
 PETROS KOIDIS, 21, 30, 133, 300  
 PHOEBUS DALAMPIRAS, 199  
 POPESCU EUGENIA, 230  
 POYZAN BOZKURT, 270, 293  
 PROKIĆ BRANISLAV, 173  
 RABIA MERVE CELIK, 179, 182, 183, 191, 192  
 RADA KAZAKOVA, 337  
 RADOMIR BARAC, 296, 297  
 RADOSVETA ANDREEVA, 353, 357  
 RADOSVETA VASILEVA, 273, 323  
 RADU BOGDAN MAVRU, 184  
 RADU CAMPIAN, 228, 230  
 RADU DRAGUTESCU, 397  
 RADU HOREA BOSTAN, 351  
 RADU RÎCĂ, 123  
 RADU SEPTIMIU CAMPIAN, 20, 168, 211, 223, 394  
 RADU-MĂDĂLIN BOATCĂ, 239  
 RADU-SEPTIMIU CAMPIAN, 221  
 RAINA GERGOVA, 258, 296  
 RAKSHA BATAJOO, 347  
 RALUCA COSGAREA, 363  
 RALUCA ELENA BACIU, 399  
 RALUCA MOCANU, 316

RALUCA VREME, 229  
 RAMONA FEIER, 20, 217, 225, 400  
 RANA NALCACI, 280  
 RAUL POPESCU, 311, 317  
 RAYA GROZDANOVA, 338  
 RĂZVAN LEAȚĂ, 116, 231  
 RENE FOLTAN, 126  
 RODICA BODEA, 386, 393  
 RODICA JIANU, 386, 393  
 RODICA LUCA, 213, 215, 220  
 ROSITSA KABAKTCHIEVA, 367  
 ROXANA BORDEA, 168, 223  
 ROXANA IULIA MARINESCU, 183  
 ROXANA POPESCU, 289  
 ROXANA RADU, 204  
 ROXANA-ELENA TRISTIU, 363  
 ROZAFI DRAGUSHA, 287, 320  
 RUGGERO INGLETTO, 288  
 RUHSAN MÜDÜROĞLU, 253, 308  
 RUXANDRA SAVINESCU, 404  
 RUZHDIË QAFMOLLA, 154, 320  
 RUŽICA KOZOMARA, 203  
 S. ILJOVSKA, 335  
 S. NASHKOVA, 335  
 S. PARK, 366  
 SAFA TUNCER, 252  
 SAHMEDIN SALI, 402  
 SAİD KARABEKİROĞLU, 334, 336  
 SAMER MAKKI, 163  
 SANDA MIHAELA POPESCU, 21, 183, 322  
 SANJA MATIC, 148, 200  
 SANJA NASHKOVA, 264  
 SASA CAKIC, 300  
 SASHKA TODOROSKA, 247  
 SASHO JOVANOVSKI, 209, 371, 373  
 SEBNEM KURSUN, 152  
 SEDA AYDEMİR, 340  
 SEDA OZER, 214  
 SEDA OZTURAN, 310  
 SEDA SEVINC OZBERK, 162, 163  
 SEDA SEVINÇ ÖZBERK, 206  
 SEDAT GUVEN, 202  
 SEDIN KOBAŠLIJA, 306  
 SELAHATTIN ÖZMEN, 171  
 SELIN BILGIN, 167, 298  
 SEMA S. HAKKI, 312  
 SEMA SEZGİN HAKKI, 188  
 SEMİH OZSEVIK, 222  
 SERHAN AKMAN, 282  
 SERHAT DEMİRER, 305  
 SERHAT KOSEOGU, 275  
 SERHAT ÖZDEMİR, 195  
 SERKAN SARIDAĞ, 278, 342  
 SEVDA YANTCHEVA, 273, 323  
 SEVGI SENER, 180  
 SEVINC AKTEMUR TURKER, 151  
 SEVTAP ALP, 319  
 ŞEYDA HERGÜNER SİSO, 372  
 ŞEYDA HERGÜNER SİSO, 370  
 SEYİT BİLAL OZDEMİR, 190  
 SEZER DEMİRBUÇA, 399  
 SİBEL YILDIRIM, 312  
 SİDRİT BEQİRAJ, 301  
 SILVIA CRISTINA TONE, 368  
 SILVIA MARTU, 204, 242, 243, 244, 245  
 SILVIA MÂRȚU, 155, 156, 239, 240, 241, 246  
 SILVIA RAILEAN, 366  
 SILVIU NICOLAE, 360  
 SIMONA GRIGORAŞ, 245  
 SIMONA MUCENIC, 403  
 SIMONA STOLERIU, 19, 21, 22, 63, 64, 73, 76, 220, 315, 356, 359  
 SINAN ERTEM, 359, 361  
 SINAN YASIN ERTEM, 361, 363  
 SİNAN YASİN ERTEM, 235  
 SLADJANA SICOVIC, 152, 333  
 SLAVCHO DIMITROV, 256, 258, 296  
 SLAVOLJUB ŽIVKOVIĆ, 173  
 SLOBODAN DODIC, 148  
 SLOBODAN DODIĆ, 203  
 SLOBODAN IVIC, 253, 358  
 SLOBODAN RUSHKOVSKI, 264  
 SMARANDA DIACONESCU, 24, 121, 122  
 SNEZANA ILJOVSKA, 339  
 SNEZANA MATIJEVIC, 259  
 SNEZANA RADISIC, 253  
 SNEŽANA RADIŠIĆ, 358  
 SNEZANA RAZNATOVIC, 306, 309  
 SOFIA A. PAPADAKI, 293  
 SOFIA-ANNA PANARETOU, 257  
 SONJA LIVRINIJK, 367  
 SORIN ANDRIAN, 19, 61, 65, 220, 329, 356, 359  
 SORIN POPSOR, 375  
 SORIN POROJAN, 124  
 SORINA MIHAELA SOLOMON, 401  
 SORINA SOLOMON, 22, 155, 156  
 SORINA-MIHAELA SOLOMON, 244, 246  
 SOTIRIA GKAMPESI, 148, 157, 160  
 SPIRIDON SILVESTROS, 196, 201, 352, 373, 376  
 STEFAN LUCIAN BURLEA, 230  
 STEFAN MILICESCU, 212  
 STEFAN OCTAVIAN GEORGESCU, 194  
 STEFAN STRATUL, 390, 391  
 ŞTEFAN TOMA, 398  
 STEFAN ZLATEV, 337  
 STEFANIA DINU, 122  
 STEFANIA VLACHOU, 324  
 STELLA HRISTOVA, 239  
 STERGOULA PAPAMANOLI, 323, 324  
 STILIANOS KARAMANIS, 369  
 STILİYAN HRISTOV, 333  
 STOJANKA PALLKO, 340  
 STOYAN YANKOV, 333  
 STYLIANOS DALAMPIRAS, 21, 60, 199  
 SUELA TABAKU, 304, 378  
 SÜLEYMAN ZİYA ŞENYURT, 165  
 SÜLEYMAN ZİYA ŞENYURT, 153  
 SUMBAL RAHMAN, 347  
 SUMEYYE KOZACIOGLU, 193  
 SUZAN BAYER, 314  
 SVETLANA ANTIC, 146  
 SVETLANA CEKOVSKA, 396  
 SVETLANA NOVAKOVIC, 247  
 SVETLANA PLAMADEALĂ, 331, 341

SVETLIN ALEKSANDROV, 337  
 SVETLOZAR RANGELOV, 163  
 SVJETLANA JANKOVIC, 261, 262, 329  
 T. KUTLOVCI, 335  
 TAMER TÜZÜNER, 268  
 TANIA KADIYSKA, 277  
 TANJA IVANOVIĆ, 268  
 TANJA PEJČINOVIĆ-JANEČEK, 306  
 TANYA BOJKOVA, 337  
 TATIANA POROSENCOVA, 391  
 TEODOR ȘTEFANACHE, 243, 244  
 TEODORA NIKOLAEVA BOLYAROVA-KONOVA, 119  
 THANASIS KARAMPASIS, 293, 362  
 THEODORE LAMPRIANIDIS, 148  
 THEODOROS GKOMOZIAS, 352  
 THEODOROS LILLIS, 160  
 THODORIS GKOMOZIAS, 201  
 THRASYVOULOS SFEIKOS, 321  
 TIBERIU NIȚĂ, 208  
 TIBERIU TIRCA, 356  
 TINA PAJEVIC, 355  
 TODOR UZUNOV, 338  
 TOLGA TOPCUOĞLU, 174  
 TRAJCHE JOVANOVIĆ, 371  
 TSONKO USUNOV, 251  
 TSONKO UZUNOV, 256, 303  
 TUDOR HĂNȚOIU, 122  
 TUDOR PETREUS, 209  
 TUGCE ZEYTINCI, 388  
 TURHAN ATALAY, 274  
 TZVETELINA GUEORGIEVA, 258, 296  
 ÜLKÜ SERMET ELBAY, 279  
 UMUT CAKAN, 198  
 UMUT MISILLI, 294  
 UMUT SAFIYE SAY COSKUN, 193  
 UMUT SEKI, 260  
 V STOJANOVSKA, 392  
 V. COSTAN, 229  
 VAHDI UMUT BENGI, 269  
 VALENTINA DOROBAT, 209  
 VALENTINA TRIFAN, 379  
 VALERIU BURLACU, 380, 391  
 VALERIU FALA, 21, 380, 381  
 VANIO MITEV, 277  
 VANJA PETROVIC, 300  
 VANJA RAICKOVIC, 355  
 VANYO MITEV, 315  
 VASILE NICOLAE, 360  
 VASILE VALERIU LUPU, 24, 127, 224  
 VASILEIOS CHRONOPOULOS, 373, 376  
 VASILICA TOMA, 185  
 VELINA STOEVA, 353, 354  
 VERA NIKOLOVSKA, 219  
 VERA RADOJKOVA NIKOLOVSKA, 247  
 VERA RADOJKOVA-NIKOLOVSKA, 202, 313, 379, 398,  
 402  
 VERA STOJANOVSKA, 219  
 VERICA DIMOVSKA, 255  
 VERICA MILOŠEVIĆ, 173  
 VERONICA MERCUT, 20, 22, 67, 183, 322  
 VERONICA PINTILICIUC SERBAN, 284  
 VERONICA ȘERBAN, 245  
 VESELINA KONDEVA, 353, 354  
 VESNA AMBARKOVA, 346  
 VESNA DANILOVIĆ, 173  
 VESNA JURUKOVSKA, 234, 364, 371, 373, 400  
 VESNA JURUKOVSKA - SHORTAROVSKA, 234  
 VESNA JURUKOVSKA - SHOTAROVSKA, 371  
 VICTOR GRECU, 263  
 VICTOR LACUSTA, 379, 380  
 VICTORIA ADAMIDOU, 382  
 VICTOR-VLAD COSTAN, 213, 223  
 VIKTOR HADJIGAEV, 337  
 VIOLETA DOGANDZHIYSKA, 256, 303  
 VIOREL IBRIC CIORANU, 182  
 VIORICA TARMURE, 221  
 VIRGIL FLORIN DUMA, 119, 120  
 VITALIE GRIBENCO, 381, 392, 395  
 VITALIE PANTEA, 381, 392  
 VITOMIR KONSTANTINOVIĆ, 357  
 VLADIMIR MATVIJENKO, 302, 311  
 VOJKAN LAZIC, 350  
 VOJKAN LAZIĆ, 302, 311  
 VUKOMAN JOKANOVIC, 331  
 YAGMUR SENER, 233  
 YAĞMUR SENER, 282  
 YAHYA ORÇUN ZORBA, 387  
 YAVUZ TOLGA KORKMAZ, 266, 271  
 YELIZ ARSLAN, 254  
 YENER OKUTAN, 186, 188, 190, 330, 338  
 YOSIF STANEV, 337  
 YUSUF BAYRAKTAR, 157, 249, 298  
 ZEHRA ILERI, 192, 368  
 ZEKI ARSLANOĞLU, 202  
 ZEYNEP ASLI GÜÇLÜ, 171  
 ZEYNEP TAŞTAN EROĞLU, 319  
 ZINDE GUDER, 283  
 ZORAN ALEKSIC, 186  
 ZORAN LAZIC, 186  
 ZORAN MANDINIC, 247, 283  
 ZORAN RAKOCEVIC, 146  
 ZORAN SPASOV, 343  
 ZORAN VLAHOVIC, 23, 350  
 ZORAN VLAHOVIĆ, 33, 135, 302, 311  
 ZORANA STAMENKOVIC, 355  
 ZOUMPOULIA MYLONA, 148

SPONSORS OF THE EVENT

**Colgate**<sup>®</sup>

**LISTERINE**<sup>®</sup>



**BANCA TRANSILVANIA**<sup>®</sup>

*Banca oamenilor întreprinzători*

DIVIZIA  
PENTRU  
MEDICI

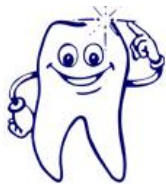**red**

RESOURCES FOR  
**EXCELLENCE**  
IN DENTISTRY



**KUWOTECH**  
Implant & Zirconia

**MIS** ROMANIA



**DENTAL PARTNER'S GRUP**

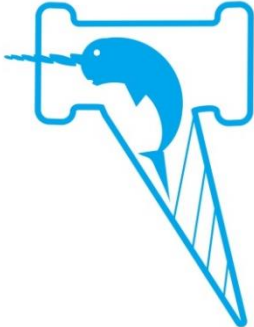
*DENTAL & MEDICAL INSTRUMENTS & TOOLS*



**MEGAGEN**

**Koinè**

**MODUS**

 **Magnetic Mallet**



GERMAN  
MEDICAL  
SUPPORT

 **NMSIS  
TRADING**

# BOOKS EXPRESS

Citește! Află mai mult.

**NOVA** IMPLANTS



QUINTESSENCE

dental  
bone & tissue  
regeneration

botiss  
biomaterials

**MACE**

SURGICAL SUPPLY CO., INC.